

Cardiovascular Club I

11:00 AM

Saturday, February 11, 2017

1 INFERIOR VENA CAVA FILTER OBSTRUCTION IN PATIENTS WITH NON-HEALING VENOUS ULCERS

C Czerwinski,² S Attanasio¹. ¹Swedish Covenant Hospital, Chicago, IL; ²St. George's University of London, London, United Kingdom.

10.1136/jim-2016-000393.1

Purpose of Study Inferior vena cava filter placement has increased significantly. Risks of filter placement include embolization and thrombosis both leading to obstruction. Obstruction of the IVC can lead to central venous hypertension with venous ulcers and furthermore is associated with significant increase in morbidity. Current wound care protocols do not include IVC filter obstruction as a cause of venous ulcer disease. Furthermore, patients with IVC filter placement have poor follow-up. In the Swedish Covenant Hospital Wound Care Center, despite optimal local wound care, patients with central obstruction are difficult to heal and we are now identifying these patients early using a multidisciplinary approach involving wound care providers and surgical/endovascular specialists to treat these patients more optimally.

Methods Used We conducted a review of active patients in the wound care center with slow-healing or non-healing venous stasis ulcers. Of these patients who had not responded to conventional therapy and had negative peripheral venous reflux scanning, we identified 10 patients thus far with IVC filters. We then investigated these patients for filter obstruction by chart review of imaging including central venography inclusive of venogram, magnetic resonance venography and CT venography.

Summary of Results Of the ten patients identified, we found three patients with complete obstruction of the central venous system including the IVC filter. Two patients had intervention to recanalize the IVC, both showing significant healing of their ulcers. The third patient is being followed. The remaining patients were found to have patency of their filters but partial central venous obstruction of the iliac veins due to chronic DVT or iliac vein compression syndromes.

Conclusions Our study demonstrates the need to include central venous obstruction, including IVC filter obstruction, as a cause of non-healing venous stasis ulcers. Treatment to relieve the obstruction can lead to significant healing. We will incorporate identification of central obstruction into our protocols. We identified patients with IVC filters and non-healing venous ulcers and reviewed not only the natural history, but validated the concept that increased vigilance is needed in following patients with IVC filter placement.

2 PREDICTION OF ECCENTRIC AND CONCENTRIC PATTERNS OF HYPERTROPHY BY STANDARD 12-LEAD ELECTROCARDIOGRAM

MR Heckle, DM Flatt, KT Weber, N Garg. *University of Tennessee Health Science Center, Memphis, TN.*

10.1136/jim-2016-000393.2

Purpose of Study Multiple studies have demonstrated that concentric hypertrophy is associated with higher all-cause mortality and incidence of cardiovascular death. The electrocardiogram (ECG) is a cost-effective screening tool to help identify patients with left ventricular hypertrophy (LVH). The objective of this study is to determine if one ECG pattern of LVH is more predictive of concentric vs. eccentric hypertrophy.

Methods Used A retrospective analysis of 3,202 patients with ECG who presented to an urban medical center between January 1, 2014 and June 30, 2015. Of the 1,370 (42.8%) patients with LVH present on ECG, 50 patients were randomly selected who had limb lead pattern (RI +SIII > 25 mm and RaVL > 13 mm) and 50 patients with chest lead pattern (SV1 + RV5 > 35 mm) of LVH. Echocardiograms of these patients were reviewed to confirm the presence of concentric or eccentric hypertrophy based on relative wall thickness and left ventricular mass index.

Summary of Results Of the 50 patients with limb lead pattern of LVH, 40 were found to have LVH on echocardiogram, 2 with eccentric and 38 with concentric hypertrophy. In the other 50 patients with chest lead pattern, 42 patients were found to have LVH on echocardiogram, 11 with eccentric and 31 with concentric hypertrophy. The positive predictive value (PPV) for LVH was 0.80 and 0.84 in the limb lead and chest lead patterns, respectively. The PPV of concentric hypertrophy was 0.76 and 0.42 in the limb and chest lead pattern, respectively. The PPV for eccentric hypertrophy was 0.04 and 0.22 in the limb and chest lead pattern, respectively.

Conclusions We conclude that the chest lead pattern of LVH is slightly more predictive of LVH by echocardiography. The limb lead pattern is strongly associated with concentric hypertrophy and the chest lead pattern is superior at identifying patients with eccentric hypertrophy. Hence, the ECG will identify LVH, but it may not reliably identify the pattern of LVH.

3 MODERATE PRE AND POST RENAL DYSFUNCTION PREDICTS A WORST OUTCOME IN PATIENTS WITH HEART TRANSPLANTATION

W González,¹ C García,¹ PI Altieri,^{1,2} HL Banchs,^{1,2} IF González-Cancel,² R Calderón,^{1,2} B Colón,¹ JJ Nieves,¹ N Escobales¹. ¹University of Puerto Rico, Medical Sciences Campus, San Juan, PR; ²Cardiovascular Center of Puerto Rico and the Caribbean, San Juan, PR.

10.1136/jim-2016-000393.3

Purpose of Study It is the purpose of this study to review the renal function of the transplanted patients (P) pre and post transplantation. Several reports have shown a poor prognosis in P with heart transplantation who developed moderate renal dysfunction post transplantation.

Methods Used We reviewed our data and survival of 140 P who underwent heart transplants in our institution.

Summary of Results 72% were males and 28% were females with a mean age of 46 years old. The ischemic period was 123 minutes. 62 P developed moderate renal dysfunction (creatinine > 2.5 mg%). We compared the pre-operative creatinine (1.83 mg%) with the creatinine at one

year. There was an increase from 1.83 ± 10 to $3.35 \text{ mg}\%$ ($P < 0.5$). The survival rate was from 1 to 5 years. The deaths were multifactorial, but the renal dysfunction was the culprit.

Conclusions The preservation of the renal function during the first year is crucial due to the high comorbidities seen in this group like diabetes mellitus, hypertension and the sub-clinical rejection which was low proven by myocardial biopsies (1 R). Strict control of these comorbidities or better selections of R will improve total survival of our group.

4 LEFT VENTRICULAR FALSE TENDONS ARE ASSOCIATED WITH LEFT VENTRICULAR DILATION AND IMPAIRED LEFT VENTRICULAR SYSTOLIC AND DIASTOLIC FUNCTION

ME Hall, JA Halinski, TA Skelton, WF Campbell, MR McMullan, RC Long, MN Alexander, JD Pollard, JE Hall, ER Fox, MD Winniford, D Kamimura. *University of Mississippi Medical Center, Jackson, MS.*

10.1136/jim-2016-000393.4

Purpose of Study Left ventricular false tendons (LVFTs) are chord-like structures that traverse the LV cavity and are generally considered to be benign. However, they have been associated with arrhythmias, left ventricular hypertrophy and LV dilation in some small studies. Our objective was to evaluate the relationships of LVFTs with LV structural and functional changes assessed by echocardiography. **Methods Used** We retrospectively evaluated echocardiographic and clinical parameters of 126 patients identified as having LVFTs within the past 2 years at a large tertiary care university medical center and compared them to 85 age and sex-matched controls without LVFTs.

Summary of Results There were no significant differences in age (52 ± 2 vs 54 ± 2 years), sex (55 ± 5 vs 59 ± 4 % men), race (36 vs 23% white), systolic blood pressure (SBP, 131 ± 2 vs 132 ± 2 mmHg) or body mass index (BMI, 31 ± 1 vs $29 \pm 1 \text{ kg/m}^2$) between controls and patients with LVFTs, respectively. Patients with LVFTs had much more prevalent heart failure compared to controls (43% vs 21%, $p = 0.001$). Patients with LVFTs had more LV dilation and reduced LV ejection fraction (18% lower) compared with controls (all $p < 0.05$). Patients with LVFTs also had more severe diastolic dysfunction (52% vs 37% with grade II-III diastolic dysfunction, $p = 0.03$) and higher E/e' , an indicator of LV end-diastolic pressure (12.4 ± 0.6 vs 10.5 ± 0.4 , $p = 0.02$). After adjustment for age, sex, race, BMI and SBP, insertion of LVFTs into the basal and middle LV segments was associated with reduced LV systolic function ($p < 0.01$) and LVFTs in the middle LV were associated with LV dilation ($p < 0.01$). LVFTs located in the apex were not associated with LV systolic dysfunction or dilation.

Conclusions Our findings suggest LVFTs may not be benign variants and LVFTs located in the basal and middle LV may have more deleterious effects. Further prospective studies should be performed to determine their

pathophysiological significance and if they play a causal role in LV dysfunction.

5 INSULIN-LIKE GROWTH FACTOR I (IGF-1) SUPPRESSED CHEMOKINES AND MONOCYTES RECRUITMENT INTO ATHEROSCLEROTIC PLAQUE: NOVEL MECHANISM CONTRIBUTING TO IGF-1-INDUCED ATHEROPROTECTION

S Sukhanov, P Snarski, Y Higashi, P Delafontaine. *University of Missouri at Columbia, Columbia, MO.*

10.1136/jim-2016-000393.5

Purpose of Study We have shown that IGF-1 decreases plaque macrophages (MF) and reduces atherosclerotic burden in high fat fed Apoe-null mice. We hypothesized that IGF-1 suppresses recruitment of circulating monocytes (MN) into atherosclerotic plaques.

Methods Used To quantify MN recruitment into plaques, Apoe-null mice were fed with a high fat diet for 8 wks, IGF-1 was administrated for 7 d (25 ug/d , i.p) or for 4 wks (1.5 mg/kg/d , mini-pumps) and circulating MN were specifically labeled by i.v. injection of red latex beads. To assess MN/MF-specific IGF-1 effects we generated scavenger receptor A-promoter driven IGF-1 overexpressing Apoe-null mice (SRA mice).

Summary of Results IGF-1 injection (7 d) reduced levels of Mac3-positive/red-labeled cells in plaques (IGF-1: 1.05 ± 0.3 cells/plaque vs. control: 1.8 ± 0.2 , $P < 0.05$) without affecting labeled splenic MN. Similarly, IGF-1 long-term administration (4 wks) decreased labeled MF in plaques (IGF-1: 1.3 ± 0.3 cells/plaque vs. control: 2.6 ± 0.4 , $P < 0.05$), indicating that IGF-1 suppressed MN infiltration into plaques.

Peritoneal MF from SRA mice had increased IGF-1 secretion ($52 \pm 9\%$ vs. control). High fat diet fed SRA mice had reduced plaque MF levels (Mac3 staining, $27.5 \pm 7\%$ decrease), and decreased atherosclerotic burden in both aortic valve ($23 \pm 6\%$ decrease) and aorta (*En face* analysis, $28.4 \pm 1.2\%$ decrease). SRA females had reduced serum levels of monocyte chemoattractant protein-1 (MCP-1) ($45 \pm 15\%$ decrease). MCP-1 is known to mediate MN recruiting into plaques. Further, IGF-1 (50 ng/ml , 24 h) decreased MCP-1 ($43 \pm 6\%$ decrease), and also reduced chemokine receptors CCR1 ($40 \pm 4\%$ decrease) and CCR2 ($38 \pm 5\%$ decrease) in cultured human THP-1 MN.

IGF-1 suppressed adhesion of calcein-labeled MN to endothelial cells (EC, $22 \pm 4\%$ decrease).

Conclusions In summary, IGF-1 administration suppressed MN recruitment into plaques and MN/MF-specific IGF-1 decreased MCP-1, reduced plaque MF and decreased atherosclerotic burden in Apoe-null mice. IGF-1 reduced chemokine expression in cultured MF and IGF-1 decreased MN adhesion to EC. These data suggest that IGF-1-induced chemokines downregulation suppresses MN recruitment into plaques and reduces atherosclerotic burden. IGF-1 has a therapeutic potential in atherosclerosis.

6 THE ROLE OF ANGIOTENSIN II ON NATRIURETIC PEPTIDE RECEPTOR-A GENE EXPRESSION

K Pandya, P Kumar, C Nguyen, M Bloodworth, KN Pandey. *Tulane University Health Sciences Center and School of Medicine, New Orleans, LA.*

10.1136/jim-2016-000393.6

Purpose of Study Atrial and brain natriuretic peptides (ANP and BNP) are classified as hypotensive hormones; their main actions are implicated in eliciting natriuretic, diuretic, vasorelaxant, and anti-proliferative effects to decrease blood volume and establish pressure homeostasis, an essential response in hypertensive patients. These peptides bind to guanylyl-cyclase/natriuretic peptide receptor-A (GC-A/NPRA), which is encoded by *Npr1* gene. The binding of ANP and BNP to NPRA causes the generation of second messenger signaling through cGMP, by which anti-hypertensive effects are promoted. Various mechanisms contribute to the activation of *Npr1* gene expression, but the molecular mechanisms are not well understood. The purpose of this study is to determine the epigenetic regulation of NPRA protein expression by Angiotensin II (Ang II).

Methods Used Mouse mesangial cells (MMCs) were cultured in Dulbecco's modified Eagles medium containing 10% fetal bovine serum and ITS (insulin, transferrin, and sodium selenite) and maintained at 37°C in an atmosphere of 5% CO₂/95% O₂ and treated with increasing concentrations of Ang II. Nuclear extract, whole cell lysate and histones were prepared from these cultures and Western blot analysis was performed to analyze the protein expression.

Summary of Results Western blot analysis revealed there was 60% reduction in NPRA protein expression in MMCs, treated with increasing concentrations of Ang II as compared with control cells. Treatment with Ang II also significantly decreased ANP-stimulated intracellular accumulation of cGMP in MMCs as compared with ANP-stimulated cells. Increasing concentrations of Ang II decreased acetylation levels of histones H3 at lysine 9 and 14 and H4 at lysine 8. In contrast, there was significant increase in histone deacetylase (HDAC) 1 and 2 protein expression, which are prohypertrophic Class 1 HDACs. Treatment of MMCs with Ang II increased HDAC activity in a dose-dependent manner.

Conclusions In summary, our results show that Ang II treatment decreases NPRA protein levels and guanylyl cyclase activity of the receptor by enhancing HDAC activity and deacetylation of histones H3 and H4 in MMCs.

7 SERUM COBALAMIN AND BNP AS MARKERS OF SPLANCHNIC AND CENTRAL CONGESTION IN PATIENTS HOSPITALIZED WITH HEART FAILURE

R Goswami,¹ KB Ramanathan,^{1,2} KT Weber.¹ *¹University of Tennessee Health Science Center, Memphis, TN; ²Memphis Veterans Affairs Medical Center, Memphis, TN.*

10.1136/jim-2016-000393.7

Purpose of Study Upon its release into the systemic circulation, elevated serum B₁₂ reflects hepatic congestion in

patients hospitalized with decompensated heart failure. We hypothesized increased serum B₁₂ levels would serve as a biomarker of hepatic congestion while a return in serum B₁₂ to the normal range (<600 pg/mL) would represent a decline in congestion with euolemia while elevated BNP would serve as a marker of cardiac chamber distention.

Methods Used In consecutive patients admitted to the Memphis Veterans Affairs Medical Center with decompensated heart failure, we monitored serum B₁₂ level and N-terminus pro brain natriuretic peptide (NT-Pro BNP) on admission and day 3 during hospitalization and on outpatient days 40. Patients were excluded if they had hepatic or splanchnic congestion due to other causes or were taking B₁₂ supplements. We estimated central congestion with both NT-Pro BNP and inferior vena caval (IVC) size and collapsibility index by 2-dimensional echocardiogram. Patients were treated with current guideline-directed medical therapy.

Summary of Results In 8 patients mean admission B₁₂ was 864±50 ng/dL and NT-Pro BNP 17231±4274 pg/mL. IVC size averaged 1.94 cm with decreased collapsibility. On day 3, B₁₂ was 663±54 ng/dL and NT-Pro BNP 9786±4677 and on outpatient day 40, 525±67 and 11,025±5800, respectively.

Conclusions A correlation between hepatic and central (or cardiac) congestion was present on admission in patients with decompensated heart failure based on elevated serum B₁₂, IVC size and collapsibility, and NT-Pro BNP. A fall in elevated B₁₂ below 600 pg/mL was associated with improved patient symptoms and IVC collapsibility irrespective of NT-Pro BNP. Serum B₁₂ may identify the resolution of hepatic and thereby splanchnic congestion and hence the appropriate reintroduction of oral medications to optimize their absorption.

8 MECHANICAL FACTORS SUCH AS JET ANGLE, COMMISSURAL FUSIONS, AND PRESENCE OR ABSENCE OF STENOSIS OR INSUFFICIENCY IN PATIENTS WITH BICUSPID AORTIC VALVES DETERMINES THE DEGREE OF AORTOPATHY

R Parker,² M Brown,² A Gupta,¹ W Lutin,¹ H Wiles.¹ *¹Children's Hospital of Georgia at Augusta University, Augusta, GA; ²Medical College of Georgia, Augusta, GA.*

10.1136/jim-2016-000393.8

Purpose of Study Bicuspid aortic valves (BAVs), a common congenital heart defect, can lead to the development of aortopathy (aortic dilation), placing patients at increased risk for complications requiring intervention. This study aims to evaluate the association between aortic variables and predict the degree of aortopathy based on echocardiographic findings.

Methods Used A retrospective echocardiographic study of 123 patients, from 2009–2016 was done. Inclusion criteria were patients of all ages identified with BAV. Excluded were patients with associated systemic illnesses or complex congenital cardiac defects that changed hemodynamic properties of the left ventricular outflow tract (LVOT). Vitals and diameters across the LVOT, aortic valve (AV), and ascending aorta (AA) were recorded, as well as the presence and

severity of aortic stenosis (AS), insufficiency (AI), and coarctation. Statistical analysis using partial correlation coefficient and ANCOVA were used.

Summary of Results Diastolic blood pressure had a positive correlation with a larger z-score for the maximum diameter of the ascending aorta (AOZ). Systolic blood pressure, heart rate, jet angle, ratio of jet width to the diameter of the LVOT in AI, peak and mean AV pressure gradients, and severity of AI had no significant correlation to AOZ. Ratios of the max diameter of the AA to the diameters of a fixed aortic position, sinotubular junction, sinus of Valsalva, AV annulus, LVOT, and descending aorta at the diaphragm all had significant correlation to the AOZ. A positive relationship was observed between AI severity and larger AV annulus z-score.

Conclusions We can conclude that certain factors are correlated with aortopathy, but other common variables across the aorta appear to have no relation. In particular, we postulate that diastolic blood pressure reflects increased vascular resistance and is associated with AOZ. Additional studies in the pediatric population are needed to help physicians better anticipate features associated with a BAV.

Adult Clinical Case Symposium

11:45 AM

Saturday, February 11, 2017

9 LEVAMISOLE INDUCED VASCULITIS: AN EMERGING CONDITION WITH COCAINE ABUSE

N salagundla, R chandra, A Islam. *Texas Tech UNV HSC Amarillo, AMARILLO, TX.*

10.1136/jim-2016-000393.9

Case Report A 66 YO African American woman with PMH of RA, COPD and MDD presented with a new purpuric rash in lower extremities for 2 weeks. This initially started as painful bruises followed by necrotic skin ulceration and crusting. She admitted to daily inhalational cocaine use. She had very recently changed her cocaine supplier. Since then she noticed the new cocaine batch felt different than the past. P/E: Vitals stable, A&O, purpuric painful skin lesions on lower extremities, chest and earlobe, some with ulceration and secondary infection. WBC-3,400, Lymphocyte count- 0.6, ESR-45, Utox positive for cocaine and marijuana. RA factor and Anti CCP were within normal limits. Antismith, RNP, Anti PR3 and Anticardiolipin IgM and IgG, antiTPO ab's were positive along with low C3. Skin biopsy revealed microscopic vasculitis and necrosis. Pt was diagnosed as Levamisole contaminated cocaine induced vasculitis. Patient was counseled on cessation of cocaine as it is the only effective therapy for this syndrome. Treated supportively with high dose steroids 1 mg/kg/day for short course, and also antibiotics for areas of secondary infection.

Discussion Levamisole induced vasculitis is a rare cutaneous vasculitis with immunological abnormalities associated with the use of levamisole adulterated cocaine. About 70% of cocaine in U.S is now adulterated with levamisole to add volume, weight and possibly to potentiate psychotropic effects of cocaine. Levamisole is an anthelmintic agent,

used in the past to treat RA, cancer etc. due to its immunomodulatory properties, but was later taken out for its side effects like vasculitis & agranulocytosis. There are reported cases of systemic autoimmune process including kidneys. Typical skin lesions present with a tender, purpuric rash in a retiform or stellate pattern with/without central necrosis. Necrotic ear lobe skin lesions are pathognomic. Subsequent sloughing and bacterial superinfection increases mortality. Labs usually show leukopenia, elevated ESR, positive auto-antibodies like ANCA (50–80%), Anti PR3, Anti TPO, Low C3 levels. Histology shows leukocytoclastic vasculitis. Spontaneous resolution occurs with Cocaine cessation. Benefit with steroids is unclear. This case reminds as clinicians we should suspect levamisole contaminated cocaine as a cause of vasculitis in high risk pts.

10 HYPONATREMIA WITH RHABDOMYOLYSIS. WHO IS TO BLAME ?

CA Munoz. *Hospital Municipal de San Juan, Santa Isabel, PR.*

10.1136/jim-2016-000393.10

Case Report Hyponatremia is defined as a serum sodium concentration of 135 mEq/l or less and represents a primary disorder of water balance or water distribution. Hyponatremia is associated to illicit drugs and the mechanism remains unclear. Rhabdomyolysis is a rare complication of hyponatremia, first reported in 1979. The following case describes a patient with severe hyponatremia complicated with rhabdomyolysis.

A 54 year old male patient with no systemic illness, drug user (cocaine and cannabis smoker) brought to hospital after being found by police officer wandering in the street. He was presenting with a clinical picture of agitation, confusion and disorientation for the previous 48 hours. Upon arriving to emergency room, vital signs were: Blood pressure: 163/76 mmHg, heart rate: 95/min regular, respiratory rate: 22/min, temperature: 37.2 C, oxygen saturation at room air 99%. Physical examination remarkable for a lethargic patient, dry oral mucosa and disoriented to person, time and place, not following commands. Imaging studies of the head and chest non contributory. Laboratories showed a hypotonic hypovolemic hyponatremia with a sodium level of 95 mm/L, creatinine phosphokinase level of 53,000 IU/L. Toxicology positive for cocaine and cannabinoids only. Hyponatremia was managed with 3% hypertonic saline intravenous boluses until neurological symptoms improved. Due to concomitant rhabdomyolysis patient was also treated with normal saline infusion with successful correction of the electrolytes disturbances without complications.

We present a patient that to our knowledge has the lowest sodium level reported in medical literature. The mechanism of illicit drug causing hyponatremia is not well understood, however there is a relationship between cocaine causing stimulation of ADH through serotonergic stimulation. There is a clear association between cocaine causing rhabdomyolysis, but after extensive literature review we propose that in our patient the hyponatremia was the culprit of rhabdomyolysis. Hyponatremia seems to cause dysfunction of the sodium-calcium pump, which

leads to cell destruction via activation of proteases. The importance of this case is to emphasize that frequent monitoring of muscle enzymes in patient with hyponatremia is important in order to provide adequate treatment and avoid complications related to muscle injury.

11 HEMATOLOGIC ABNORMALITIES INDUCED BY ANTIPSYCHOTIC USE IN THE LONG TERM CARE SETTING

MK Yadav, KN Rezkallah, A Abdo, TM Reske, EA Aguilar. *LSUHSC-New Orleans, New Orleans, LA.*

10.1136/jim-2016-000393.11

Case Report Adverse side effects (ASE) from medications are common, especially antipsychotics (AP). Long term care (LTC) residents are frequently prescribed AP off-label for behavioral symptom control. Southern states have historically been among the highest AP utilizers. Louisiana ranked #1 with a percentage rate of 25.5% compared to the national average of 19.1%. State funded initiatives have lowered the overall prescription rate, but current prescription habits still exceed the goal of significant reduction. Hematologic abnormalities account for part of the ASE with leukopenia and agranulocytosis the most common.

A 95 year-old Caucasian LTC male resident with moderate Alzheimer dementia presents with recurrent infections and weakness over a period of 3 months. Patient's physical exam showed cachexia and confusion. Labs revealed WBC 0.9 ANC 150, Hemoglobin 8.3 g/dL and Platelets 160 k. The peripheral smear review revealed no dysplasia. Further workup showed no nutritional deficits. Medication reconciliation revealed no recent changes. He was on 8 different medications, including an atypical AP. No changes in medications in the past 2 years. Because bone marrow aspiration was declined, AP was held and behavioral symptoms managed non-pharmacologically. WBC recovered and weakness improved.

12 PULMONARY AND CUTANEOUS BLASTOMYCOSIS IN AN IMMUNOCOMPETENT ADULT

C Stallings, D Narcisse, N Jain, J Gillless. *University of Tennessee Health Science Center, Memphis, TN.*

10.1136/jim-2016-000393.12

Case Report: Introduction Blastomycosis is a pyogranulomatous infection acquired via inhalation of conidia of the fungal species *Blastomyces dermatidis*. Clinical courses vary from asymptomatic infection to widespread illness.

Case A 47-year-old man with no prior history presented with weakness, productive cough, and 1–2 episodes of blood-streaked sputum. He reported a 15 lb weight loss over several months without fever or night sweats. He is a landscaper with remote history of incarceration; he denied any recent travel. Exam revealed a very thin, febrile man with temporal wasting, glossitis, and oral thrush. Left breath sounds were diminished without crackles or wheeze. A 2x2.5 cm perianal abscess, recently drained at another facility, was well-healing with granulation tissue. Initial labs were notable for a WBC of 18.2 K cells/ μ l with 88% neutrophils;

hemoglobin of 10.3 g/dL; and MCV 80.7 fL. CXR revealed a left perihilar consolidated infiltrate. Ceftriaxone, doxycycline, and fluconazole were initiated for suspected community-acquired pneumonia and oral thrush. HIV screen, sputum Gram stain and culture were negative as well as *S. pneumoniae* and *Legionella* antigens. Despite therapy, symptoms did not improve with continued fever spikes. CT scan of chest/abdomen/pelvis obtained for small axillary lymphadenopathy revealed persistent consolidated LUL infiltrate without evidence of malignancy. Diagnostic bronchoscopy was performed. Empiric itraconazole was started when serum Beta-D-glucan level resulted as elevated. An immunodeficiency work-up was within normal limits. BAL specimen demonstrated *Blastomyces dermatidis*; subsequent biopsy of the perianal abscess was consistent with blastomycosis on silver stain. A one-month follow up CXR showed noticeable improvement in the infiltrate.

Conclusion Diagnosis of blastomycosis is often delayed due to low index of suspicion. Diagnosis is confirmed via microscopic visualization of the fungus. While blastomycosis can be a severe, disseminated illness in the immunocompromised, this case demonstrates the importance of considering fungal pathogens in the differential diagnosis of pulmonary infections in all patients, especially after failure of conventional therapy.

13 KRATOM AN OLD DRUG WITH NEW CONCERNS

AC Castillo, K Nugent, D Payne. *Texas Tech University Health Sciences Center, Lubbock, TX.*

10.1136/jim-2016-000393.13

Case Report Introduction This is the case of a patient presenting with posterior reversible encephalopathy syndrome (PRES) as a result of ingesting the street drug kratom.

Case description The patient is a 22-year-old man who presented with a severe headache that started earlier that morning. He also reported having confusion, dizziness, and disorientation. The patient was on fluoxetine for depression and quetiapine fumarate for insomnia, and he occasionally used marijuana and Adderall[®]. On admission, his blood pressure was 178/103 mmHg; his heart rate was 53 beats per minute. There was no head trauma. A CT scan of the head showed a possible occipital intraparenchymal hemorrhage. A lumbar puncture was performed; the CSF had 1500 RBC/mm³ and 0 WBC/mm³. A repeat CT scan revealed bilateral low-density changes consistent edema in both cerebellar hemispheres and both occipital and parietal lobes consistent with posterior reversible encephalopathy syndrome and a left occipitoparietal intraparenchymal bleed. Neurosurgery did not recommend surgery. An MRI of the head with gadolinium contrast showed multifocal areas of abnormal T2 FLAIR signal, gyriform enhancement, restricted diffusion in the superior parietal lobes, bilateral occipital lobes, bilateral cerebellar hemispheres and minimal hemorrhage in the left superior parietal lobe. These results were consistent with atypical PRES. The patient then admitted that prior to admission he had abused Kratom and took 6 tablets of Adderall[®].

Discussion PRES is a radiographic finding that has been associated with hypertensive encephalopathy, eclampsia,

and cytotoxic or immunosuppressive drugs. These patients typically present with an altered mental status, headache, and seizures. Treatment largely involves observation and management of elevated blood pressures. Kratom has opiate and stimulant activity. Side-effects include tachycardia and hypertension. Serious toxicity involves the central nervous system (CNS); this includes seizures, coma, psychosis, and addiction. This patient was on antidepressants and took both Adderall® and kratom. Adderall® has rarely been associated with PRES. This case suggests that kratom or kratom in association with other drugs with CNS activity can cause PRES. The increasing use of kratom in the United States will likely result in more cases with serious CNS toxicity.

14 WHEN IT WALKS LIKE A DUCK AND QUACKS LIKE A DUCK, IS IT ONE?

MB Bhatia, CM Young, L Scott, RD Smalligan. *Texas Tech Univ HSC Amarillo, Amarillo, TX.*

10.1136/jim-2016-000393.14

Case Report A 49 yo Caucasian man with a hx of PTSD and GERD presented with chronic cough that progressed to pneumonia, and he was admitted. He had been deployed in Iraq and the cough began towards the end of his last tour approximately 2 years prior. He denied hemoptysis, recurrent fever and night sweats but did have unintentional weight loss. On PE he was febrile and hypoxic and had rhonchi on the right but otherwise unremarkable exam. Chest CT showed patchy infiltrates in the RUL without cavities. HIV was negative. He improved initially on broad spectrum antibiotics but sputum a few days later showed acid fast bacilli. Nucleic acid amplification test (NAAT) later came back negative for MTB complex. Meanwhile he was referred to the health department for quarantine and treatment. He was started on INH, rifampin, pyrazinamide and ethambutol under directly observed therapy. Within 2 weeks the patient's culture grew *Mycobacterium fortuitum*. He was released from quarantine and referred to his infectious disease physician for ongoing treatment.

Discussion *M. fortuitum* is a nontuberculous mycobacterium (NTM) classified by the Runyon criteria as a rapid grower. The bacteria is found in natural and processed water sources, sewage and dirt and is able to evade decontamination by chlorine, organomercurials, and alkaline glutaraldehydes. *M. fortuitum* rarely causes NTM lung disease and is more often seen in surgical-site infections, catheter-related sepsis and lymphadenitis. Disseminated disease in an immunocompetent person is extremely rare. Clinical manifestations of lung disease range from minimal to severe bronchiectasis and cavitary disease mimicking TB. Our patient was diagnosed by sputum though bronchoscopy is often needed. The organism is resistant to standard TB meds so susceptibility to doxycycline, clarithromycin and the quinolones, among others, must be sought. Treatment is individualized but in one large study patients received an average of 6 months of IV antibiotics to achieve appropriate control of the pulmonary disease. The routine use of NAAT on sputum and bronch specimens helps the clinician to accurately rule out MTB while the rapid growth *M.*

fortuitum allows relatively early referral to infectious diseases or pulmonary specialists for ongoing treatment and monitoring for cure.

15 NEW ONSET CATATONIC SYMPTOMS: CONVERSION, DEPRESSION, OR MEDICAL CONDITION?

BL McGee, LL Tynes. *LSU School of Medicine, Baton Rouge, LA.*

10.1136/jim-2016-000393.15

Case Report Catatonia is a syndrome characterized by mutism, negativism, odd posturing, and catalepsy, which occurs in affective and psychotic disorders as well as medical conditions. The etiology of catatonia is poorly understood. Putative mechanisms include structural lesions, hormonal, and neurotransmitter dysregulation. There are reports in the literature describing catatonia co-occurring with both hypoactive delirium and conversion disorder. Here we report a case of probable catatonia masked by symptoms of conversion and major depressive disorder.

Case description The patient was a 74 yo female with CNS trauma, depression, and recent femoral neck fracture transferred from a physical rehabilitation center due to prolonged altered mental status with staring spells and catatonic symptoms. Family reported the unresponsive states began abruptly 24 hrs prior to our evaluation and the patient was anxious about returning home. Except for a chronic UTI, medical work up was unrevealing. Examination revealed staring, mutism, non-responsiveness to noxious stimuli, and non-guarding to arm raise. The differential included hypoactive delirium, depression with catatonic features, and conversion disorder. Five minutes after administration of lorazepam, rapid reversal of catatonic symptoms occurred and the patient participated in the interview with a mildly impaired sensorium. Catatonic symptoms returned following a discussion of discharge around 24 hrs later. This recurrence of catatonia responded rapidly to lorazepam and the patient was placed on a scheduled regimen.

Discussion In our patient, the catatonic presentation was clear but the underlying diagnosis remained unknown. Despite a history of CNS trauma, neurological workup was unrevealing. Delirium could not be ruled out as the patient had a chronic UTI; however, improvements with lorazepam challenge and only mild concentration difficulties made delirium unlikely leaving exacerbation of an affective disorder and conversion disorder as possible diagnoses. The response to lorazepam challenge, while supportive of her catatonic presentation, did not help with diagnostic clarification. Lorazepam has been reported to treat conversion disorder and may have lessened the patient's anxiety regarding discharge.

16 LACOSAMIDE INDUCED CARBAMAZEPINE TOXICITY

G Murtaza, Z Rahman, S Zaidi, N Mungo. *East Tennessee State University, Johnson City, TN.*

10.1136/jim-2016-000393.16

Case Report Carbamazepine and lacosamide are used as anticonvulsants treating many types of seizures.

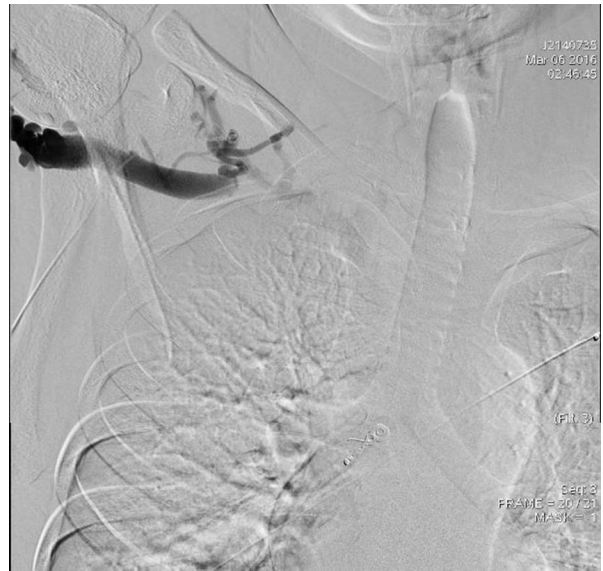Carbamazepine is an old anticonvulsant that has been used for a long time to treat seizures and is the first line drug of choice for the treatment of simple and complex partial seizures. It has a known side effect of hyperammonemia which has been manifested very rarely at common doses of carbamazepine and when used alone. Increasingly, novel antiepileptics are now being used to treat epilepsy either as monotherapy or in combination with other anti-seizure medications. We present a case of hyperammonemia precipitated by increasing the dose of lacosamide in a patient who was also taking carbamazepine. There are some case reports in literature where lacosamide caused hyperammonemia in patients who were taking valproate. Our patient was a 47 year old autistic patient with mental retardation who was living in a group home and has been taking carbamazepine and lacosamide at low dose for seizures. When his neurologist increased the dose of lacosamide from 100 mg BID to 150 mg PO BID, the patient presented to emergency department with increasing confusion, aggression and combative behavior. His ammonia level was found to be 70 in the absence of any other abnormality in laboratory data and imaging studies. He was discharged home on his old dosage of lacosamide (100 mg BID) along with carbamazepine (400 mg BID). The patient's ammonia level was checked in 3 days and it was found by 31. Interestingly, he followed up with his neurologist a few days later and he was again prescribed lacosamide 150 mg BID. Patient's ammonia level went up again to 57 within 2 days of this new change in medications. Due to his hyperammonemia, the neurologist decided to taper him off lacosamide. His lacosamide was ultimately tapered off and his ammonia level normalized. We hereby conclude that lacosamide could precipitate the side effects of carbamazepine including hyperammonemia. Clinicians should be careful in using the combinations of lacosamide and carbamazepine and or valproate due to this increased toxicity of these medications in the presence of lacosamide. We do suggest careful monitoring of ammonia level when the combination of these drugs is necessary in clinical practice for control of refractory seizures.

17 DVT CAUSING PAGET-SCHROETTER SYNDROME

M Ganji, MD Lyons, MD Aung. *UF-Jacksonville, Jacksonville, FL.*

10.1136/jim-2016-000393.17

Case Report 25-year old male presented with right upper extremity edema, discoloration, and altered sensation. The patient was diagnosed with a right subclavian deep vein thrombosis (DVT) with phlegmasia cerulea dolens and CT chest was suspicious of thoracic outlet syndrome (TOS) and started on heparin. Catheter-directed thrombolysis was performed by IR with successful thrombolysis (alteplase). During the procedure narrowing of the subclavian vein at the level of the first rib/clavicle was present with provocative maneuvers (see image), confirming TOS. The patient was offered operative decompression and rib resection to prevent future thrombosis. The patient opted for a non-surgical route and was treated with 6-month anticoagulation therapy and physical activity limitations. Negative hypercoagulable workup.



Abstract 17 Figure 1

Discussion Paget-Schroetter Syndrome is a rare condition and presents mostly after vigorous activities as well as clavicle impingement due to anatomical abnormalities. Both of which are present in our patient. Treatment of choice is systemic anticoagulation therapy or thrombolysis. For TOS and other anatomical causes, decompression and surgical intervention can correct the underlying defect.

Conclusion The patient was diagnosed with TOS secondary to Paget-Schroetter syndrome who decided to refuse other interventions and thus, treated with anticoagulation and exercise limitations with complete resolution of all symptoms on follow-up.

18 CONFUSION AND COAGULOPATHY IN AN ELDERLY: THINK SALICYLATE TOXICITY

MK Islam, S Alqassimi, A Islam, RD Smalligan. *Texas Tech Univ HSC Amarillo, Amarillo, TX.*

10.1136/jim-2016-000393.18

Case Report Case An 82 year old female with past medical history of Alzheimer's disease, hypertension, COPD, iron deficiency anemia, GERD, chronic back pain; brought to the hospital by EMS due to altered mental status. In the ER, history was unobtainable due to her confusion and poor cognition. Vitals: temperature 98.1 F, pulse 76/min, respiratory rate 24/min, BP 145/64 mmHg, SPO₂ 98% on room air. On physical exam- dehydrated, confused and disoriented, rapid deep breathing without any rales/wheezes, S1/S2 normal, no rash, no neck stiffness and focal weakness. Initial lab : Hb 7.6 gm/dl, MCV 80, WBC 4.7, Platelet 249, Na 138, K 2.8, Cl 113, HCO₃ 11, BUN/Cr 19/0.8, Blood sugar 81, Ca 7, Mg 2.1, AST 17, ALT 10, Alkaline Phosphatase 83, PT 44.9, INR 3.85, PTT 34.8. ABG showed: pH 7.47, PO₂ 89, PCO₂ 14.5, HCO₃ 11, BE (-13). Urine analysis showed ketone 2+, Blood alcohol level and urine toxicology screen were negative. Serum salicylic acid level came back as 80.9 mg/dl

(therapeutic range 10–30 mg/dl). Subsequently treated with bicarbonate infusion and one session of hemodialysis which markedly lower salicylic acid level and had significant improvement of confusion and coagulopathy.

Discussion Salicylic acid intoxication in an elderly is very tricky because it can be missed very easily. In clinical settings, the finding of a primary respiratory alkalosis with a primary metabolic acidosis is nearly pathognomonic for consequential salicylate poisoning. Salicylates are mitochondrial toxins that cause the uncoupling of oxidative phosphorylation, resulting in cellular energy failure. Neurological effects include agitation, hyperactivity and delirium. Depressed mental status and seizures may develop as the severity progresses. Three main mechanisms behind CNS symptoms due to salicylic acid intoxication include: direct stimulation via salicylic acid and their species, neuroglycopenia and cerebral edema. Coagulopathy in the setting of salicylate intoxication is very rare, most likely due to deranged vitamin K metabolism and liver injury. LFT was normal with raised PT directs more towards vitamin K metabolism. Our case reminds physicians to consider salicylate toxicity in an elderly presenting with confusion and coagulopathy as early recognition and aggressive management could be lifesaving.

Pediatric Clinical Case Symposium

11:45 AM

Saturday, February 11, 2017

19 MORE THAN MEETS THE EYE: OPHTHALMOPLÉGIA IN AN ADOLESCENT

VA Harrison, L Rowe-Hobbs. *University of Mississippi Medical Center, Jackson, MS.*

10.1136/jim-2016-000393.19

Case Report A 14 year old male presented with diplopia for 2 days. History included travel to Honduras for 2 weeks with return 48 hours prior to onset of diplopia. While abroad, patient consumed tortillas with ‘sweet syrup.’ Review of systems was positive for 1 day history of headache and emesis as well as brief nausea and diarrhea 1 week prior. On exam, patient had dilated, minimally reactive pupils and near complete ophthalmoplegia with sparing of downgaze. Neurologic exam was otherwise unremarkable. Cerebrospinal fluid (CSF) white blood cell count and protein were normal. Neurophysiologic studies were normal. Patient then developed subtle facial and upper extremity weakness. Due to concern for food-borne botulism, serum and stool samples were collected, and anti-toxin was administered. Subsequently, patient developed ataxia and hyporeflexia. Serum anti-GQ1b IgG ultimately returned elevated, confirming the diagnosis of Miller Fisher Syndrome (MFS).

MFS is a rare variant of Guillian-Barré syndrome (GBS) characterized by acute onset ophthalmoplegia, ataxia, and areflexia. An atypical form of MFS occurs more commonly in adults and involves isolated ophthalmoplegia without ataxia or areflexia. Similarly to GBS, MFS occurs after an infectious process. Pathophysiology involves antibody

production and cross-reactivity with gangliosides composing neuronal plasma membranes and myelin. Diagnosis is clinical with variable findings of CSF albuminocytological dissociation and neurophysiological abnormalities. Serum anti-GQ1b antibodies are highly sensitive for MFS and present in 90% of cases. In cases of isolated ophthalmoplegia, the presence of elevated serum anti-GQ1b antibodies allows for the diagnosis of atypical MFS.

Atypical MFS is a diagnostic challenge as the differential for isolated ophthalmoplegia is broad and includes infectious, cerebrovascular, demyelinating, neoplastic, and autoimmune disorders. This patient initially presented with isolated ophthalmoplegia. The case was further complicated by the development of facial and upper extremity weakness. With elevated serum anti-GQ1b IgG, diagnosis of MFS was confirmed. Given the rarity of atypical MFS, adult age predilection, and variability of symptoms, utilization of serum anti-GQ1b antibodies allows for prompt and accurate diagnosis and management.

20 C3 GLOMERULOPATHY PRESENTING AS POSTERIOR REVERSIBLE ENCEPHALOPATHY SYNDROME (PRES) IN A PREVIOUSLY-HEALTHY CHILD

KR Richard,^{1,2} S Fathallah-Shaykh^{1,2}. ¹University of Alabama at Birmingham, Birmingham, AL; ²Children's of Alabama, Birmingham, AL.

10.1136/jim-2016-000393.20

Case Report A nine year-old African-American male presented with ‘first-time seizures.’ The seizures began hours before presentation and were described as brief generalized tonic-clonic (GTC), but became increasingly longer with persistent confusion. Past medical history, travel history, and review of systems were negative except a scratch above one eye and a few weeks of abdominal pain. Family history was negative for seizures. On arrival, the patient’s eyes were closed but he responded to commands, saying ‘okay,’ and ‘yes,’ but without performing the actions. Initial vitals were 99.5 F axillary, HR 108, BP 168/127 mmHg, RR 24, 98% saturation on RA. Minutes after arrival, the patient had a GTC seizure with upward eye deviation and became unresponsive. His HR climbed to 141, and his BP to 175/123. The seizure was stopped with a single dose of lorazepam, but his BP continued to rise. Non-contrast head CT showed multiple hypodense cortical lesions concerning for ADEM vs. infectious cerebritis. CSF analysis was normal. Nicardipine infusion was started for BP management of presumed diagnosis of PRES, etiology unknown. An MRI showed multiple areas of decreased T1, and increased T2 and FLAIR signal in the cortex, consistent with PRES. Initial labs showed: BUN 190 mg/dL and creatinine 5.1 mg/dL. Complement level, C3 was low at 29 mg/dL, but C4 was normal. The patient was started on dialysis the same day. Slowly, his BP and neurologic function improved and he was transitioned off nicardipine by hospital day 6. Renal biopsy revealed crescentic glomerulonephritis and C3 glomerulopathy. The patient received plasmapheresis, pulse methylprednisolone and intravenous cyclophosphamide with significant improvement in kidney function and was off dialysis with BUN 16 mg/dL, Cr 0.5 mg/dL at discharge. His BP was controlled by amlodipine and labetalol.

He still has significant proteinuria and is currently maintained on monthly cyclophosphamide, for a planned six-month course.

Conclusion C3 glomerulopathy is a rare cause of acute kidney failure in children and can present with seizures secondary to severe hypertension causing PRES.

21 AN UNUSUAL ETIOLOGY OF SEPTIC SHOCK: PRIMARY THYMIC ABSCESS

KS Booker, C Poole, W Sasser. *Children's of Alabama, Birmingham, AL.*

10.1136/jim-2016-000393.21

Case Report We present the case of a four month old male with past medical history significant for severe eczema who presented in septic shock. On admission to the pediatric intensive care unit, he was started on broad spectrum empiric antibiotics, resuscitated with fluids, and intubated for sepsis, but continued to have tachycardia and fever after 48 hours of therapy. Blood, tracheal, and urine cultures, as well as viral studies and chest radiography were unrevealing. Due to culture negative sepsis with worsening clinical picture, computed tomography of the abdomen, pelvis, head and chest were performed. This demonstrated an anterior mediastinal abscess confluent with the thymus, ultimately found to be due to methicillin-resistant *Staphylococcus aureus* (MRSA). The patient required two video-assisted thorascopic surgeries to drain the abscess, which had progressed to an empyema. After surgical drainage, the patient demonstrated drastic clinical improvement. An extensive evaluation for an underlying immunodeficiency is ongoing, though not currently definitive.

This case is of clinical relevance because the unusual etiology of septic shock due to a primary MRSA abscess of the anterior mediastinum. This case also reinforces the importance of reassessing a clinical situation and reevaluating the investigative strategy when a patient is not taking the expected clinical course. Mediastinal abscesses are rare, particularly in otherwise healthy patients with no known immunodeficiency or exposure to long term antibiotics. A review of the literature reported only one case of a pediatric MRSA thymic abscess, in a patient who later developed lymphoma. Most anterior mediastinal abscesses reported are in the setting of a concurrent sternal osteomyelitis, or as a secondary infection from a different primary site. An additional interesting aspect to this case is that in post-hospitalization studies, the patient has a decreased number of T-cells, particularly naive CD4⁺ cells. This could reflect either injury to the thymus due to infection or pre-existing immunodeficiency.

22 A RARE CASE REPORT OF CYANOSIS IN A 6 WEEK OLD INFANT

A Sabapathy, O Sanchez. *University of South Alabama, Mobile, AL.*

10.1136/jim-2016-000393.22

Case Report A 6 week old female infant born at 37 weeks with uneventful neonatal course presented to an outside hospital with 2 week history of severe diarrhea, vomiting,

lethargy, poor PO feeding and failure to thrive. She was fed on cow milk protein based formula. Infant was transferred to our PICU for sudden onset of cyanosis, tachypnea and persistent diarrhea. Ultrasound abdomen and upper GI series obtained in outside facility were reported as normal.

In the PICU, infant was found to be cyanotic, tachycardic, tachypneic, irritable, moderately dehydrated with prolonged capillary refill. Oxygen saturation by pulse oximetry was 85–90% on 100% oxygen. Sepsis workup was done. Chest xray and echocardiogram were within normal limits. The stool analysis was negative except for occult blood. Blood gas showed methemoglobin level of 29% (normal <1%) and metabolic acidosis. Methemoglobinemia was treated with IV methylene blue 2 mg/kg and cyanosis improved dramatically. Repeat methemoglobin level was obtained in 2 hours and was 3%. Cytochrome b5 reductase level was within normal limits ruling out congenital Methemoglobinemia. Urine culture was positive for 10⁵ CFU of *E.Coli*. Blood culture positive for *Staphylococcus Epidermidis*. Infant was treated with Vancomycin and Cefotaxime. Esophago-gastro-duodenoscopy along with colonoscopy showed lymphoid hyperplasia and signs of milk protein intolerance. Infant was changed to amino acid based hydrolyzed formula. The diarrhea and acidosis resolved. Methemoglobin level was persistently low on follow up. Hence we report a case of cyanosis caused by methemoglobinemia due to diarrhea secondary to milk protein intolerance complicated with *E.coli* urinary tract infection (UTI).

Discussion Methemoglobinemia among infants is a rare and potentially fatal condition that can be congenital or acquired. Acquired causes include infectious diarrhea, milk protein intolerance, sepsis, UTI. Infants less than 4 months of age are at increased risk for methemoglobinemia secondary to low levels of cytochrome b5 reductase. Altered intestinal flora during diarrhea, *E.Coli* UTI can increase production of nitrites which can aggravate methemoglobinemia. Methemoglobinemia should be considered in all infants less than 4 months of age presenting with diarrhea and sudden onset of cyanosis not responding to oxygen therapy.

23 NEONATAL INNOMINATE ARTERY PSEUDOANEURYSM COMPLICATION FROM EXTENDED EXTRACORPOREAL MEMBRANE OXYGENATION WITH SUCCESSFUL TRANSFEMORAL TREATMENT

EP Masoumy, P Patel, J Bhatia. *Children's Hospital of Georgia at AU, Augusta, GA.*

10.1136/jim-2016-000393.23

Case Report Infants of diabetic mothers carry a high risk of symptomatic hypertrophic cardiomyopathy with an incidence of 12.1%, and when searched for with echocardiography shortly after birth, it is found in 30%. However, the need for venous arterial extracorporeal membrane oxygenation (VA ECMO) in these patients is significantly rare, with only four cases having been reported in the literature. We report a case of a 7 week neonate with pseudoaneurysm development off the innominate artery as a complication from ECMO cannulation. From review of the literature,

this is the not only the youngest reported case of such a complication, but also the first reported case to be successfully treated via transfemoral approach and endovascular stent placement.

A full term macrosomic infant with history of biventricular hypertrophy and pulmonary hypertension was placed on VA ECMO soon after birth. The infant required CMO support until 7 weeks of life due to persistent cardiac dysfunction. Post decannulation, a large pseudoaneurysm was found off the innominate artery by echocardiogram. To avoid surgery with cardiopulmonary bypass, the patient was taken to the catheterization lab for treatment. By angiography, the pseudoaneurysm measured 24 mm×25 mm. Two 6 mm×22 mm Atrium Cast covered stents were placed via telescoping from the innominate artery to the right subclavian artery. Follow up angiography demonstrated an excellent result with near complete bypass of the pseudoaneurysm and normal opacification of the right subclavian artery through the stent. There were no procedural or post procedural complications. The patient was subsequently transferred to the NICU and later discharged home on room air.

To our knowledge, this is the youngest and first successfully treated case in a neonate. We were able to effectively bypass the pseudoaneurysm, decreasing the risk of rupture, and maintain blood flow via the right subclavian artery. Therefore, our report demonstrates that transfemoral treatment is a safe, and feasible alternative to address this rare complication of VA ECMO in a neonate.

24 RESPIRATORY FAILURE IN STATUS ASTHMATICUS TREATED WITH CONTINUOUS MAGNESIUM SULFATE INFUSION

S Poore, W Hoover, B Turner. *University of Alabama Birmingham, Birmingham, AL.*

10.1136/jim-2016-000393.24

Case Report Patient is a 16 yo AAM with severe persistent asthma that presented with respiratory distress following exercise. Started on albuterol, steroids, and magnesium sulfate (MgSO₄) bolus. Became altered and hypercapnic, subsequently intubated. Started on steroids, continuous albuterol, atrovent, sedated, and paralyzed. Given terbutaline, ketamine, and started on heliox and isoflurane to no avail. Peak and plateau pressures were elevated during this period (50 and 30 cmH₂O). Patient extubated to CPAP after 24 hrs of steroids, but quickly had respiratory collapse, prompting re-intubation and pulmonary consultation.

Treatment Recommended MgSO₄ bolus at 40–50 mg/kg followed by MgSO₄ continuous infusion at 40 mg/kg/hr with serum goal levels between 3–4 mg/dL. Within 2 hrs on infusion, peak pressures dropped from 49 to 39 cmH₂O, plateau pressures from 30 to 19 cmH₂O. Patient given break for episode of hypotension, no pressors needed and sedation adjusted. Off drip, pressures rose back to 47 cmH₂O, but once drip restarted, pressures dropped to 34 cmH₂O within 2 hrs. Patient extubated to CPAP within 10 hrs of starting drip. MgSO₄ drip continued on CPAP, weaning steroids and stopping heliox during this

time. After 23 hrs, MgSO₄ drip stopped and patient weaned from CPAP to facemask. Patient soon weaned to room air and transferred to floor.

Discussion Few studies describe the efficacy of continuous MgSO₄ infusions in status asthmaticus. Investigations have focused on the pharmacokinetics and safety profile of MgSO₄ in asthmatic and preeclamptic patients, helping formulate this treatment plan. From this, we were able to safely titrate MgSO₄ drip based upon serum Mg levels optimal for smooth muscle relaxation. This case revealed direct pulmonary effects in response to drip, showing decreased ventilator pressures, successful extubation, and weaning of adjacent interventions. Given ability to tolerate drip on CPAP, patient had clinical effect without significant respiratory muscle depression. This therapy could be used as treatment for status asthmaticus in the intubated patient as well as serve as a bridge therapy in the ICU to prevent intubation.

25 BELL'S PALSY AS THE INITIAL PRESENTATION IN A PATIENT WITH NEW ONSET DIABETES MELLITUS

K Tierling, E Klepper, A Byrd. *Our Lady of the Lake Children's Hospital, Baton Rouge, LA.*

10.1136/jim-2016-000393.25

Purpose of Study Bell's palsy in an acute, often idiopathic, lower motor neuron palsy of cranial nerve VII. Research in the adult population has noted a correlation between poor glycemic control in diabetics and development of Bell's palsy. Diabetes mellitus, in turn, is present in more than 10 percent of patients with Bell's palsy. While this association has been studied significantly in the adult population, there is currently only one documented case report describing a correlation between Diabetes Mellitus and Bell's palsy in the pediatric population. We describe the second reported pediatric case of Diabetes Mellitus diagnosed in an adolescent patient presenting with Bell's palsy.

Methods Used A 14-year-old boy with unilateral facial nerve palsy initially presented to our hospital with a 2 day history of watering of the left eye, pain of the left cheek and on day of admission, an asymmetric smile with drooping of the left side of the face. The patient did endorse polydipsia and polyuria for the past 2 months with 34 pound unintentional weight loss in 3 months. Complete metabolic panel yielded a blood glucose of 761 and a glycosylated hemoglobin of 17.1, both consistent with a new diagnosis of diabetes mellitus.

Summary of Results Typically, Bell's palsy self-resolves as glucose levels normalize with appropriate management. Bell's palsy may be treated with corticosteroids, but with secondary effects of induced hyperglycemia, steroids were not initiated in this patient. Our patient's Bell's palsy subsequently resolved prior to discharge.

Conclusions This is the second known reported case of Diabetes Mellitus initially presenting with Bell's palsy in the adolescent population. One prior case report suggests that obese pediatric patients presenting with Bell's palsy should have blood testing performed to rule out concurrent diabetes. This case report cautioned the use of steroids in such a presentation. We build further on such management

and suggest that Bell's palsy will resolve in such a presentation via glycemic control without the use of steroids as an adjunct treatment.

26 CASE REPORT: ATHLETE'S CLOT WITH EMBOLIC STROKE

ME Willis, M Orr. *University of Alabama- Birmingham, Birmingham, AL.*

10.1136/jim-2016-000393.26

Case Report Abstract: 16 yo African American male presented with one-day history of headache, dizziness with vomiting and dehydration. Throughout first day of admission neurological exam evolved with worsening ataxia, right-sided dysmetria as well as left sided sensory deficits. MRI brain showed a right superior cerebellar peduncle acute ischemic stroke, small left cerebellar infarct, as well as multiple other areas of infarct. During evaluation for embolic stroke, he had upper and lower extremity ultrasounds, which revealed a deep vein thrombosis (DVT) of right subclavian vein. His echocardiogram showed possible patent foramen ovale (PFO), which was confirmed with bubble study. Hypercoagulable work up did not reveal any abnormalities. He was a very active football player and had recently been participating in spring training, which involves heavy weight lifting and tire pulls among other activities. Per moms report he has had significant changes in muscle mass over past 6 months which raised concerns for an effort induced thrombus such as those described with Paget- Schroetter Syndrome. He was started on anticoagulation therapy and transferred to inpatient rehabilitation service where he made significant improvements. Plans for future therapies include possible closer of patent foramen ovale as his is possibly at continued risk of additional strokes and evaluation for surgical intervention.

Discussion Paget Schroetter Syndrome, or subclavian thoracic outlet obstruction, is a rare condition described in young athletes from chronic repetitive movements resulting in compression injury to the supraclavicular vein in an already compressed outlet from a cervical rib or other anatomic abnormality. Chronic repetitive injury results in scarring, stenosis and eventual thrombus formation. Anticoagulation and surgical correction of the thoracic compression are frequently required to prevent recurrence of thrombus. PFO is a common finding in otherwise healthy individuals (up to 25% of adult population), most without any complications, but this paired with increased tendency for thrombus and theoretical risk of recurrent stroke raises the question of whether or not to close the PFO. This discussion is on-going in literature and often made on case-by-case basis.

27 DON'T FORGET YOUR GLOVES: WHEN TRAUMA IS MORE THAN IT APPEARS

P Redmond, MN Frascogna, H Dawson. *University of Mississippi Medical Center, Jackson, MS.*

10.1136/jim-2016-000393.27

Case Report The emergency room often encounters trauma following vehicular accidents. In such cases, medical history can be lacking due to the emergent nature of trauma or involvement of reliable caregivers in the accident. In this case we present a child in whom, during the course of her evaluation for trauma, was found a rare infectious disease.

A three month old female presented to a pediatric emergency room following a motor vehicle collision. The child's mother was DUI and had the child unrestrained in her lap when she crashed fleeing the authorities. The patient presented with two other siblings but mother had been taken to jail, limiting history. Primary survey was largely negative and a secondary survey revealed a papular diaper rash and tenderness to palpation of the upper extremities with palsy of the left arm. There was scant blood on her shirt but it was unclear if it belonged to the patient. Radiographs revealed bilateral forearm fractures and two left humeral fractures. Initial labs were notable for elevated transaminases and alkaline phosphatase. A closer physical exam on the floor revealed cradle cap and desquamating lesions on the sole of her left foot and palm of right hand. Further evaluation of radiographs showed diffuse prominent periosteal reactions to all upper extremity long bones including the metacarpals as well as clavicles. An osseous survey showed periosteal reactions to the lower extremity long bones. Anterior bowing and scalloping of the tibias were noted. An RPR returned positive with high titers, eliciting a presumptive diagnosis of congenital syphilis.

Per outside hospital records, mom was RPR negative and a perinatal infant titer was not obtained. TP-PA confirmatory treponemal test returned positive, confirming diagnosis of congenital syphilis. She completed penicillin treatment and followed up with infectious disease. Her fractures were managed conservatively. Notably, upon arrival to the PED several staff members could not recall if they had used gloves during the initial survey. Given the patient's active extremity rashes and potential bleeding, those staff members required RPR testing and follow up titers. To date, none were infected.

28 DIAGNOSIS OF MAY THURNER SYNDROME AND FACTOR V LEIDEN IN AN ADOLESCENT MALE

AL Hoppmann, EO Schmit, L Nassetta, A Xavier. *University of Alabama at Birmingham, Birmingham, AL.*

10.1136/jim-2016-000393.28

Case Report History and Physical: A 14-year-old African American male presented with 2 weeks of left lower extremity pain and 4 days of fever. The pain was located in the popliteal fossa, radiating superiorly to his inguinal canal and inferiorly to his calf. He endorsed no recent travel, immobilization, or infections. He denied use of medications or anabolic steroids. There was no family history of inherited thrombophilia. On exam, he had 2+ pulses throughout, with peripheral perfusion intact. Extremities had full range of motion, though the left thigh was tender to palpation circumferentially. There were no palpable cords, and he had no induration or edema.

Investigative Studies: Lower extremity Doppler ultrasound showed a nonocclusive thrombus in the distal common femoral vein, and extensive occlusive thrombus in the greater saphenous vein, superficial femoral vein and popliteal vein. Complete blood count was normal though inflammatory markers were elevated (CRP 7.8, ESR 81). Prothrombin gene mutation, Cardiolipin Antibody level, Antithrombin III assay, Lupus anticoagulant assay, and Protein C were normal. Protein S was slightly low. The patient was found to be heterozygous for Factor V Leiden mutation.

CT and MRI angiography were obtained to evaluate for venous compression. Both studies suggested May Thurner Syndrome, an anatomic variant in which the left iliac vein is compressed by the right iliac artery. Specifically, CT angiography noted a mass effect on the patient's left common iliac vein by the proximal right iliac artery. **Clinical course:** Interventional radiology performed thrombolysis and stent placement in the left common iliac vein. Enoxaparin was initiated, with a planned 3 month treatment course.

Conclusion Hereditary prothrombotic states can be exacerbated by venous compression leading to extensive thrombosis. This case discusses the unusual presentation of May Thurner Syndrome in an athletic adolescent male with Factor V Leiden. Consider the role of anatomic venous compression, particularly in patients with left lower extremity thrombosis. As illustrated, full thrombophilia evaluation is warranted in patients with May Thurner Syndrome.

29 REFRACTORY RASH: A CASE OF LANGERHAN CELL HISTOCYTOSIS IN A THREE-MONTH-OLD

K Pyburn. *University Alabama at Birmingham, Birmingham, AL.*

10.1136/jim-2016-000393.29

Case Report Rash is a common chief complaint seen by pediatricians in outpatient clinics and emergency departments across the country. While the majority of rashes are benign and self-limiting, a small subset are life threatening. For general pediatricians, it is important to consider more serious causes of rashes, especially for those initially diagnosed as common pathology but refractory standard treatment.

A three-month-old term male presented to the emergency department with a worsening skin rash. Reportedly the rash developed one week after birth. It was initially on the face and scalp and appeared flesh-colored to yellow. Over time, it spread to involve the majority of the body and became erythematous with accentuation in the skin folds. Three days prior to arrival, the rash acutely worsened and was accompanied by fever, increased fussiness, mouth sores, and difficulty breathing. Physical exam revealed an inconsolable, ill-appearing infant with increased work of breathing and scattered erythematous papules and petechiae on the scalp, trunk, and extremities as well as moist plaques in the bilateral inguinal and axillary folds. Labs were notable for pancytopenia with a white blood cell count of 4.8, hemoglobin of 6.4, hematocrit of 19.9, and platelet count of 73,000. A chest X-ray showed diffuse abnormal density throughout both lungs. A skin

biopsy showed histiocytic proliferation within the epidermis with cells staining positive with a CD1a immunohistochemical study, therefore confirming the diagnosis of Langerhans Cell Histiocytosis (LCH). Subsequent bone marrow biopsy, CT chest/abdomen, and MRI brain were obtained to evaluate for extent of disease. Initial treatment included intravenous steroids and Vinblastine to treat multisystem disease. By the time of discharge, the patient's rash had significantly improved.

LCH is a rare histiocytic disorder most commonly diagnosed in children ages one to three years old. About 40% of patients have skin involvement at the time of diagnosis. The characteristic rash can present as seborrhea of the scalp, weeping dermatitis in skin folds, and diffuse vesiculopustular eruptions. General pediatricians should consider the diagnosis of LCH in a patient with refractory cradle cap or diaper dermatitis.

Case Reports in Cardiovascular Medicine

2:00 PM

Saturday, February 11, 2017

30 ACQUIRED COARCTATION OF AORTA LEADING TO HEART FAILURE

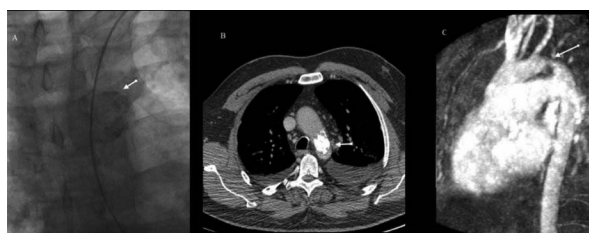G Murtaza, S Karakattu, K Sivagnanam, D Sharma, J Schoondyke, T Paul. *East Tennessee State University, Johnson City, TN.*

10.1136/jim-2016-000393.30

Introduction Occlusive atherosclerotic disease usually involves the infra renal aorta. Localized obstruction in aortic arch caused by heavily calcified polypoid lesion is uncommon. This can cause heart failure due to afterload mismatch and renal ischemia.

Case Report A 58 year old male with uncontrolled hypertension and chronic smoking presented with exertional dyspnea, lower extremity edema and 25 lbs weight gain over 2 weeks. Pertinent exam findings were 1+ lower extremity (LE) edema. Troponins and BNP were mildly elevated at 0.10 ng/ml and 250 pg/ml respectively. Transthoracic echocardiogram showed normal left ventricular function. Patient underwent evaluation for acute coronary syndrome.

During catheterization, there was difficulty in advancing J wire across aortic arch. Thus fluoroscopy was performed which showed large radiolucency around aortic arch (Panel A). Urgent CT angiogram showed focal globular calcification near the distal arch of aorta (Panel B). The vascular



Abstract 30 Figure 1

anatomy was further delineated by MR angiogram showing >75% narrowing of aortic arch (Panel C). He subsequently underwent aortic bypass graft.

Discussion Aortic narrowing due to calcified mass is rare. Acquired coarctation of aorta should be considered in patient with heart failure once common causes have been ruled out. Early release of aortic obstruction is critical to prevent irreversible end-organ damage. Our patient reported marked improvement of his symptoms on follow up.

31 AN UNFORTUNATE CASE OF HEARTBURN

N salagundla, RD Smalligan, T Vo, JP Garrido. *Texas Tech Univ HSC-Amarillo, Amarillo, TX.*

10.1136/jim-2016-000393.31

Case Report A 43yo Hispanic male with no PMH presented to the ED complaining of a fullness in his abdomen and chest that he thought was indigestion. He also described shortness of breath, fatigue, dizziness and near syncope without any chest pain. Negative SH and FMH. On P/E: A&O, NAD, BP was 101/73 mmHg, pulse 87/min, RR 16, O₂ sats 93% on RA. There was no JVD, heart sounds were distant, S1 and S2 were weak and in the second ICS along the left sternal border a crescendo-decrescendo harsh systolic murmur was appreciated. Lungs had decreased breath sounds in the bases; abdomen and extremities were normal except for slightly decreased distal pulses. His initial laboratory workup was unremarkable. A contrast abdominal CT revealed a large intracardiac filling defect. TEE was done immediately which showed a 4x10 cm mass extending from the right intra-atrial septum into the right ventricle. The mass had a heterogeneous, globular appearance and was felt to be a myxoma. After the TEE, patient went into respiratory distress and shock. He was intubated, vasopressors and inotropes were started, but his cardiogenic shock was recalcitrant. His WBC rose to 13,000; his creatinine to 2.5 mg/dl; his lactic acid to 18 mmol/L, his AST to 5,475 u/L, his ALT to 1,803 u/L, and his INR to 5.5. His ABG was pH 6.96, PCO₂: 50, PO₂: 87 on the ventilator on an FiO₂ of 1.0. He progressed to multi-organ failure and died within 12 hours.

Discussion Cardiac tumors may present as benign incidental finding or as a cause of fulminant shock. Benign tumors account for 75% of primary heart tumors, most of them are myxomas. These tumors do not usually metastasize, but can have catastrophic effects like embolism, arrhythmias and acute heart failure. Tumors of the right atrium can grow and obstruct blood flow and lead to hemodynamic instability. Typical cardiovascular signs and symptoms are those of right heart failure (peripheral edema, fatigue, ascites, hepatomegaly, and prominent 'a waves' in the jugular veins). Myxomas are the most common tumors of the right atrium, however, sarcomas and angiosarcomas have been reported. Prompt identification and removal of the mass is key. This case reminds physicians that hemodynamically significant cardiac tumors can present in otherwise relatively young, healthy patients.

32 DETOX OR DEATH? A CASE OF A DETOXIFICATION DRINK AND CARDIAC ARREST

P Masuta, R Doobay, D Gill, A Penmetsa, L Bhatta. *SUNY Upstate Medical University, Syracuse, NY.*

10.1136/jim-2016-000393.32

Case Report Many commercial products are available to help mask toxicology testing. Patients sometimes use them to dilute urine for drug testing. Most of the ingredients have limited evidence on efficacy or side effects. This is a case involving a patient who took an over the counter 'detox' drink which eventually led to sudden cardiac arrest.

A 51 year old male with no medical history suddenly collapsed and became unresponsive. CPR was initiated. He had ventricular fibrillation requiring 2 shocks, epinephrine and amiodarone. Spontaneous circulation was achieved and he was intubated. At the hospital he was found to have a sodium of 149, potassium of 2.6 and a left bundle branch block. Urine electrolytes were normal. He was taken for cardiac catheterization. It showed clean coronaries with an LVEF of 50% and mild apical hypokinesis. Therapeutic hypothermia was induced for 24 hours. He was then rewarmed and extubated successfully to baseline neurological function. Upon further inquiry, the patient admitted that he had been smoking marijuana 3 to 4 times a week and was anxious about an appointment with his primary care physician. He had taken an over the counter 'organic drink' earlier that day. He was on no other medications or supplements.

A remarkable 40% of patients on outpatient diuretics can have hypokalemia. The hypokalemia in this patient was suspected to have caused his ventricular fibrillation. The most common causes of hypokalemia are gastrointestinal or urinary losses from vomiting, diarrhea, or diuretics. He had consumed a beverage which contains 'natural' medicines with diuretic properties such as uva ursi and multiple B vitamins. This patient was fortunate in that he survived the arrest without any short term complications. This product claimed to have the ability to remove marijuana, cocaine, opiates and other illicit drugs from the body. His urine toxicology testing was positive for marijuana. This outlines two points for consideration. One being that these products may be ineffective at masking drug testing and the second that they may lead to extensive electrolyte losses through diuresis which can be potentially deadly. Our patient attempted to mask a urine drug screen, however he was unaware that severe hypokalemia would trigger a near fatal arrhythmia.

33 POSTPARTUM BREASTFEEDING AND DIFFUSE CORONARY VASOSPASM

DM Flatt, R Goswami, KT Weber, RN Khouzam. *University of Tennessee Health Science Center, Memphis, TN.*

10.1136/jim-2016-000393.33

Purpose The most common coronary complication in the peripartum period is spontaneous dissection, which usually presents as an acute ST-elevation myocardial infarction.

Coronary vasospasm, on the other hand, presents in <1% of postpartum women. Risk factors include vasoconstrictive agents such as oxytocin, prostaglandin E2 and ergonovine.

Case Report A 5-day postpartum 26-year-old breastfeeding female presented with sudden onset chest pain and was found to have inferolateral ST segment elevation on 12-lead ECG. Cardiac catheterization demonstrated diffuse coronary vasospasm of all coronary artery beds without thrombus formation or atherosclerotic disease. Vasospasm diagnosed was confirmed by vasodilation in response to intracoronary nitroglycerine and verapamil. Prior to presentation the patient reported a similar symptom complex during breastfeeding. Therapy with long acting nitrates and calcium channel blockers was initiated. L-arginine was instituted to promote endothelial release of nitric oxide and relief of her chest pain followed. The patient was discharged on calcium channel and beta blockers as well as long acting nitrates and L-arginine with no recurrent angina and stable blood pressure; in addition, cessation of breastfeeding was recommended.

Conclusions An uncommon life threatening clinical scenario of coronary artery spasm during breastfeeding is presented, raising the potential prospect of oxytocin-induced vasospasm. L-arginine increases the production of nitric oxide and the resultant vasodilator response appeared to relieve her coronary vasospasm and attendant chest pain. Recent studies have shown bromocriptine, a dopamine agonist, to reduce prolactin production and thereby reduce the production of oxytocin. Its utility in relieving coronary vasospasm in the postpartum breastfeeding patient remains to be proven.

34 BILATERAL BRACHIAL ARTERY DISEASE WITH FEATURES OF RAYNAUD'S PHENOMENON

K Seegobin, B Lyons, S Maharaj, C Baldeo, P Reddy. *University of Florida, College of Medicine Jacksonville, Jacksonville, FL.*

10.1136/jim-2016-000393.34

Case Report A 71 year old female presented with a one year history of intermittent pallor of both hands precipitated with cold objects. She had an atraumatic fall from a chair in the past. On exam bilateral radial pulses were reduced. Prior photos showed pallor of both palms. Angiogram showed stenosis of the right brachial artery and focal occlusive dissection of the left brachial artery which were treated with stenting. She was asymptomatic after five months on dual antiplatelet therapy. The autoimmune and thrombotic tests were unremarkable.

Upper-extremity vascular stenosis is uncommon. Our case was unique having bilateral brachial involvement. No alternative underlying cause was found, however one possibility is that it could have been precipitated by the prior fall. Dissection can occur following minimal trauma, and has been reported in cases with subclavian dissection. Structural changes in the vessel wall can cause vasospastic attacks; a mechanism described in secondary Raynaud's phenomenon. We hypothesize that these attacks may have been precipitated by the bilateral brachial artery disease. Furthermore, resolution of the symptoms post stent further supports this theory. Arterial thrombosis has been reported

Figure 1. Right brachial artery stenosis

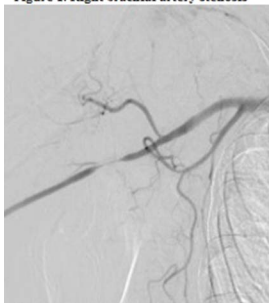

Figure 2. Left brachial artery occlusion

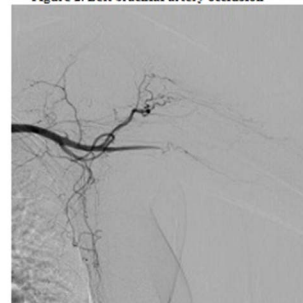


Figure 3. Pallor of the distal right palm

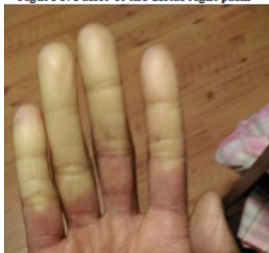
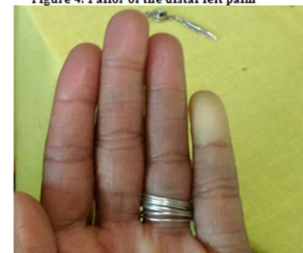
Figure 4. Pallor of the distal left palm



Abstract 34 Figure 1

as a complication of dissection, which could be the cause of her thrombus.

Coexisting brachial artery stenosis and dissection is uncommon, but treatable disease. Physicians should consider this in patients presenting with Raynaud's phenomenon.

35 THE DISAPPEARING ACT: A CASE OF THE VANISHING MURMUR

K Lynch, L Puttock, A Reine, LS Engel, C Sanders. *LSU Health Sciences Center, New Orleans, LA.*

10.1136/jim-2016-000393.35

Case Report A 59 year old woman with a past medical history of hypertension, psoriasis and latent tuberculosis presented with a 3 day course of shortness of breath. She had stopped taking pyridoxine and isoniazid about two weeks prior because of nausea and difficulty sleeping. Three days prior to hospital admission she had worsening shortness of breath. She did not have chest pain, palpitations, diaphoresis, fever, chills, or night sweats. At the time of admission, her blood pressure was 192/113. On exam, she was found to have distended neck veins with a jugular venous pressure of twelve centimeters, a grade 1/6 low-pitched systolic ejection murmur at the pulmonic area, a grade 3/6 high-pitched holosystolic murmur heard at the apex that radiated into the left axilla, a right parasternal heave, and a liver palpable eight centimeters below the right costal margin. Initial labs were remarkable for an elevated BNP of 1481, elevated AST/ALT to 68/87 with total bilirubin of 2.1. She was started on intravenous furosemide for treatment of new onset heart failure. An echocardiogram revealed severe left ventricular systolic dysfunction with an ejection fraction of 25–30% and inferior wall akinesis, severe pulmonary hypertension with pulmonary arterial pressure >70 mmHg, and severe ischemic mitral

regurgitation with Carpentier Type IIIb etiology. Right heart catheterization failed to demonstrate obstructive coronary artery disease but did show moderate elevation of the left-sided filling pressures and pulmonary arterial pressure. By her third day, her cardiac findings present on admission had resolved. A repeat echocardiogram revealed persistently low EF estimated at 20–25% with severe mitral regurgitation but completely normal pulmonary arterial pressure of <35 mmHg. The patient was referred for evaluation of mitral valve replacement.

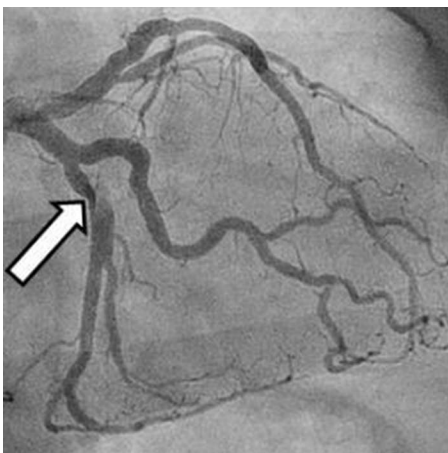
Discussion This case highlights a presentation of new onset heart failure with underlying severe mitral regurgitation. The mitral regurgitation was likely caused by or worsened by poorly controlled systemic hypertension leading to left ventricular overload which manifested as heart failure. Blood pressure control and diuresis alleviated the pressures in the heart, resolving the pulmonary hypertension and setting the stage for the mitral regurgitation murmur disappearing act.

36 SPONTANEOUS RETROGRADE LEFT CIRCUMFLEX ARTERY DISSECTION IN A BODYBUILDER

Z Bloomer, B Griffin, T Tobin, R Jeschke, M Donovan, N Bakris. *Dwight David Eisenhower Army Medical Center, Fort Gordon, GA.*

10.1136/jim-2016-000393.36

Case Report A previously healthy 40 year old male with a history of hypertension and hyperlipidemia presented to the emergency department after developing a bifrontal headache following exercise. After arrival, he developed a pressure like sensation in his anterior upper neck. Electrocardiography was unremarkable, however his serum troponin I was elevated consistent with non-ST elevation myocardial infarction. He underwent diagnostic coronary angiography which indicated retrograde dissection of the left circumflex artery, confirmed with intravascular ultrasound. Coronary dissection is a rare cause of acute myocardial infarction and is more common in young women,



Abstract 36 Figure 1 False lumen within left circumflex artery

especially during pregnancy. The typical presentation involves chest pain, shortness of breath, nausea, vomiting, diaphoresis, and hemodynamic instability. In this patient, however, the presenting complaint was headache in the setting of elevated systolic blood pressure. Cardiac pathology was not considered until the development of neck pressure, which prompted troponin measurement. This case presents an atypical presentation of an uncommon clinical entity, namely headache precipitating NSTEMI secondary to spontaneous retrograde left circumflex artery dissection.

37 A HUGE VEGETATION IN AN UNEXPECTED SITE

IJ Valle Irizarry,^{1,2} J Malpica,² A Dones,¹ I Flores². ¹San Juan City Hospital, SAN JUAN, PR; ²Auxilio Mutuo Hospital, San Juan, PR.

10.1136/jim-2016-000393.37

Case Report Endocarditis is an inflammation of the endocardium. The diagnosis of infective endocarditis is made by the Duke criteria with a specificity and a sensitivity of 80%. Right-sided infectious endocarditis happens only in 10% of cases with a mortality rate under 10%. Patients are commonly younger and with fewer comorbidities than patients with left-sided endocarditis. They often present signs and symptoms of septic pulmonary emboli like pleuritic chest pain, dyspnea and hemoptysis.

We present a case of a 27 years old Puerto Rican woman with diabetes mellitus and end stage kidney disease on hemodialysis(HD) who came to the emergency department complaining of general malaise and progressive dyspnea. Physical examination was remarkable for left lung crackles and tachycardia. Laboratory results were remarkable for anemia, thrombocytopenia, leukocytosis and increased blood urea nitrogen. Initial chest X-ray showed bilateral nodular infiltrates. Further characterization with a chest CT scan showed multiple septic pulmonary emboli. Blood and sputum cultures were ordered and she was started on antibiotic therapy, but after 72 hours of medical therapy, fever and leukocytosis persisted. Blood cultures were remarkable for *Methicillin Resistant Staphylococcus aureus*. Transthoracic echocardiogram was performed, but no significant finding was reported. A transesophageal echocardiogram was performed, and revealed findings suggestive of a vegetation on the right atrium without valve involvement. Due to persistent bacteremia, patient underwent thoracotomy and was found with an unexpected vegetation that measured 7 centimeters that extended from superior vena cava, right atrial wall and into the inferior vena cava. Patient improved and continued with antibiotic therapy for 6 weeks.

Infective endocarditis (IE) complicating bacteremia in HD patients has been noticed in up to 20% of cases. *S. aureus* represents 40% to 80% of the cases, expressing a higher risk for systemic embolization, persistent bacteremia, and death. Interestingly, there are very few cases reported of such a large sized cardiac vegetation, occupying a significant part of the heart without compromise of the valves.

38 ACUTE VALVULITIS LEADING TO SEVERE MITRAL REGURGITATION IN A CRITICALLY ILL PERIPARTUM PATIENT

P Naji, A Karkee, D Villarreal. *SUNY Upstate Medical University, Syracuse, NY.*

10.1136/jim-2016-000393.38

Introduction Acute valvulitis is rare in the absence of rheumatic heart disease. Such cases are not well studied and diagnostic and treatment modalities are not well established.

Case A 27-year-old female who had a contaminated en-route vaginal delivery 4 days prior presented with productive cough and dyspnea. She had systemic inflammatory response syndrome (SIRS) with heart rate 170 bpm, temperature 39.4 C, WBC 15 K and circulatory collapse requiring fluid resuscitation and pressor support. Chest X-ray revealed multifocal patchy infiltrates and she was intubated for respiratory failure. Broad spectrum antibiotics were started. There was no evidence of endometritis and infectious workup was negative. Bronchoscopy and bronchoalveolar lavage were normal without growth of bacteria or fungi.

Transthoracic (TTE) and transesophageal echocardiogram revealed acute severe mitral regurgitation (MR) with normal left atrial and left ventricular (LV) size and preserved LV ejection fraction. There was no vegetation or ruptured chordae. Cardiac Troponin T was elevated and trended down. Acute severe MR and abnormal troponin were attributed to acute valvulitis and carditis. ESR (112 mm/hr) and CRP (>300 mg/L) were elevated. Anti streptolysin-O titer was elevated (256 units/mL) but Anti-DNase B was negative, making acute rheumatic fever not likely. Rheumatologic workup was otherwise normal.

With the diagnosis of acute valvulitis, she was started on high dose aspirin (650 mg every 6 hours) on day 2. She came off of pressors on day 3 and was extubated on day 4. High dose aspirin and antibiotics were continued for a total of 6 days. She was discharged home on day 7. Repeat TTE at 1 month showed only trace MR.

Discussion This is a case of otherwise healthy female with profound peripartum SIRS reaction, circulatory collapse and respiratory failure without an identifiable source of infection. Her acute valvulitis leading to severe mitral regurgitation was likely caused by her severe SIRS. Acute valvulitis in the setting of inflammatory and autoimmune disorders is well-known and mitral regurgitation is the most common valvular abnormality. Anti-inflammatory treatment is the mainstay of therapy. Institution of such treatment in a critically ill patient is challenging and patients should be closely monitored.

39 SUSPECTED AMIODARONE-INDUCED THYROTOXICOSIS PRESENTING AS ATRIAL FIBRILLATION

BM Ramos, R Goswami, KT Weber. *University of Tennessee Health Science Center, Memphis, TN.*

10.1136/jim-2016-000393.39

Purpose Amiodarone is a potent antiarrhythmic agent often used to treat ventricular and supraventricular tachyarrhythmias. It is a benzofuran-derived, iodine-rich compound that bears molecular resemblance to thyroxine (T₄), containing approximately 75 mg of organic iodine per 200 mg tablet. Amiodarone may cause hypo- or hyperthyroidism as in this case thyrotoxicosis may arise from excessive iodine-induced thyroid hormone synthesis or via destructive thyroiditis with the release of pre-formed hormones.

Case Report A 66-year-old woman with history of atrial fibrillation (AF) treated with amiodarone, end-stage renal disease with recently diagnosed hyperthyroidism and hypertension, presented to the emergency room with palpitations and dyspnea. Vital signs and physical exam were remarkable for irregular tachycardia 125 bpm. ECG revealed AF with a rapid ventricular response. She was started on a Cardizem drip for rate control. Laboratory results revealed a TSH level of <0.005, all while on amiodarone for Afib and methimazole for hyperthyroidism prior to admission. Further workup revealed decreased systolic function on echocardiogram and cardiac catheterization with stent placement in the proximal left anterior descending coronary artery. Amiodarone was withheld and she tolerated metoprolol achieving rate control.

Conclusions Daily dosing of amiodarone 200 mg BID tablets results in 6–12 mg of free iodine per day, which is 40-fold above minimum daily metabolic requirements. Its metabolites affect thyroid hormone synthesis, as well as competitively inhibit cardiac myocyte specific T₃R-α1 and thyroid-specific T₃R-β1. Amiodarone-induced hyperthyroidism can result in localized inflammation via interleukin-6-based destruction of thyroid tissue with release of preformed hormone. Thus, our case is one of suspected amiodarone-induced thyrotoxicosis manifested by low TSH with AF and a rapid ventricular response.

Moving Your Clinical Case Presentation into a Published Manuscript

2:45 PM

Saturday, February 11, 2017

40 VISCERAL HETEROTAXY AND ASPLENIA IN A PATIENT PRESENTING WITH HAEMOPHILUS INFLUENZA MENINGITIS AND SEPSIS

C Schlappi, R Sellers, A Sorrentino. *University of Alabama at Birmingham, Birmingham, AL.*

10.1136/jim-2016-000393.40

Case Report The patient is a 4 year old female who presented to a tertiary care emergency department with altered mental status, abdominal pain, persistent fever, and vomiting. She had been evaluated in the same ED three days prior for abdominal pain; she was discharged home at that time as urine studies were negative and she was clinically well-appearing. A day later, the patient developed altered mental status with incoherent speech and persistent groaning. She was unable to ambulate secondary to the mental status. She again presented to the ED where her

vital signs were consistent with uncompensated septic shock. Her mental status was profoundly altered and she had signs of meningismus on physical exam. CBC showed a leukocytosis with a left shift and she was thrombocytopenic with an elevated INR, concerning for disseminated intravascular coagulation. Blood and urine cultures were obtained; lumbar puncture was initially deferred due to her coagulopathies but CSF was eventually obtained after clinical stabilization. She was fluid resuscitated and started on vancomycin and rocephin for broad spectrum antimicrobial coverage. Blood cultures began growing GNRs on hospital day two and soon speciated to Type A Haemophilus influenza; her CSF culture later grew the same organism. A CT of her abdomen was obtained due to persistent abdominal pain and revealed visceral heterotaxy and absent splenic tissue. An echocardiogram revealed normal atrial and ventricular anatomy with left sided superior and inferior vena cava. The patient was treated with ampicillin with slow improvement in her clinical status. She was ultimately discharged home on prophylactic amoxicillin with a strict personalized vaccine schedule due to her asplenia.

Discussion Heterotaxy is a fairly rare diagnosis, with incidences consistent with 1:10,000–40,000 live births. Sepsis is a known complication of heterotaxy and has a mortality rate around 30% in this population. It is rare, however, to have sepsis or meningitis as the initial clinical presentation in children with heterotaxy. It is important to consider heterotaxy and associated asplenia in cases of pediatric sepsis, especially sepsis in previously healthy children or sepsis caused by encapsulated or unusual organisms.

41 **2,8-DIHYDROXYADENINE CRYSTALLINE NEPHROPATHY: A FORGOTTEN CAUSE OF RENAL ALLOGRAFT DYSFUNCTION**

M Alzubaidi, R Pullalarevu, M Posadas. *medical University of South Carolina, Mount Pleasant, SC.*

10.1136/jim-2016-000393.41

Case Report We describe a case of 2,8-dihydroxyadenine crystalline nephropathy (DHACN) in renal allograft leading to graft dysfunction. This disease is under-recognized and frequently missed. Complications in renal allograft can be prevented by prophylaxis with allopurinol prior to kidney transplant.

Methods 39-year-old African American female with ESRD due to presumed HTN received a deceased donor kidney. A month after transplant, patient developed AKI with Cr of 5 mg/dL. Renal transplant US showed moderate hydro-nephrosis, not relieved by a Foley catheter. Kidney biopsy showed no evidence of acute rejection but brown, polarizable, crystalline material within tubular epithelium and lumina consistent with 2,8-DHA crystals. No crystals were identified on urine sediment. Urinary stone risk panel showed elevated oxalate and decreased citrate. Patient was started on allopurinol and sodium citrate. She required antegrade ureteral stent removal as stent broke during cystoscopy. Cr leveled off at 2.4 mg/dL at 4 months. Pt never had personal or familial history of kidney stones and was not on triamterene. Patient was found to have adenine phosphoribosyltransferase (APRT) deficiency by enzymatic activity testing.

Conclusions APRT deficiency is a rare AR disorder of purine metabolism. In the absence of APRT, adenine is oxidized by xanthine dehydrogenase to 2,8-DHA, which is poorly soluble and forms crystals at physiologic urine pH resulting in 2,8-DHA nephrolithiasis and crystalline nephropathy. APRT deficiency is frequently missed, owing to the absence of specific manifestations and lack of awareness of the disease among physicians. In kidney transplant patients who are not on prophylactic treatment, 2,8-DHACN can recur in the kidney transplant leading to allograft loss in more than 25% of cases. To date, only a few cases of recurrent 2,8-DHACN in kidney transplant have been reported. In a series of 9 pts with 2,8-DHACN, diagnosis was missed in all cases prior to transplant. 2,8-DHACN after kidney transplant can manifest as delayed graft function or primary graft non-function. Management of APRT deficiency includes allopurinol which reduces the generation of 2,8-DHA, fluid intake, and avoidance of purine-rich diet.

**Adolescent Medicine and Pediatrics
Joint Plenary Poster Session and Reception
4:30 PM
Saturday, February 11, 2017**

42 **EFFICACY OF TELEMEDICINE IN DELIVERING PEDIATRIC ASTHMA EDUCATION IN A RURAL WEST ALABAMA ELEMENTARY SCHOOL**

K Burgess, B Smith. *University of Alabama, College of Community Health Sciences, Tuscaloosa, AL.*

10.1136/jim-2016-000393.42

Purpose of Study Asthma affects 9% of children in the United States. The incidence of pediatric asthma in Alabama is 12.3%. Telemedicine is a modality that has been useful to improve access to care, especially in rural areas. The University of Alabama received private gift funding to provide pediatric asthma education for rural communities delivered by telemedicine. More is known about use of telemedicine for individual management of pediatric asthmatic patients rather than its use in pediatric asthma education in a group setting. This project assesses the efficacy of group asthma education presented to school children.

Methods Used 22 fourth and fifth grade students in rural Hale County, AL participated in an asthma education curriculum at school. The curriculum consisted of four weekly, 30 minute sessions. Participants were asked to complete a 20 question, multiple choice knowledge assessment before and after the curriculum.

Summary of Results 21 students completed the knowledge assessments. The aggregate average pretest score was 63% and the average posttest score was 81%. Individual scores improved on average 18%. 90% of participants had improved posttest scores.

Conclusions Telemedicine is an effective modality for group asthma education in a school setting. Given the burden asthma has on students and the secondary impact on their education, consideration should be given to routinely incorporating such programs into the school curriculum for

students with asthma, especially in rural areas where access to healthcare, particularly for illness surveillance, is limited. These programs can teach children better manage their illness and reinforce education received from their primary care provider. More research is needed to determine if this enhanced knowledge translates to other improved outcomes such as asthma symptom control, physical education participation and missed school days due to asthma. Additionally, more research is needed to determine if improved asthma knowledge persists after the conclusion of the curriculum.

43 ACCESS TO PRENATAL AND POSTNATAL CARE IN WEST ALABAMA

M Gulas, K Burgess. *University of Alabama, College of Community Health Sciences, Tuscaloosa, AL.*

10.1136/jim-2016-000393.43

Purpose of Study Obstetrical services in rural counties of Alabama are very limited. The number of providers willing to provide these services is decreasing. Lack of specialty services in rural regions leaves family medicine practitioners as the most accessible providers of this care. Despite the need for expansion of these services, studies have shown prenatal care visits to primary care physicians are declining. The closure of many labor and delivery units in rural counties has contributed to the distance between patients and their providers, with many Alabama women driving 50 miles or more for obstetric care and delivery. Nearly one fourth of women residing in Alabama's rural counties received inadequate prenatal care in 2004. This study determines the willingness of family medicine providers in West Alabama to provide prenatal and postnatal care, as well as the perceived barriers to the provision of this care.

Methods Used 60 West Alabama Medicaid family medicine practitioners were surveyed to determine if they provide prenatal and postnatal care. Practitioners who did not provide this type of care were questioned to ascertain reasons for not doing so and to ascertain what would enable them to provide prenatal and postnatal care. Provider attitude toward mid-wives and doulas was also assessed.

Summary of Results 46 providers completed the survey. 78% practice in rural areas. 13% provide prenatal care and 22% provide postnatal care. The most endorsed reasons for not providing care were insufficient training, lack of local delivery and malpractice insurance costs. Providers indicated more training and guaranteed OB/GYN backup would enable them to provide this care. 71% of respondents would support mid-wives or doulas providing prenatal, postnatal and obstetrical care.

Conclusions The number of primary care providers delivering this important care is very limited. There is potential for improvement if additional training was offered and if obstetrical backup was coordinated. Consideration to restructuring malpractice rates for different levels of care could be of benefit. These results indicate receptiveness toward other types of providers rendering this care. A multi-faceted approach is likely to have greatest success in improving access to prenatal and postnatal care and ultimately improving health outcomes for women and infants in these rural areas.

44 DOES MECHANISM OF INJURY CORRELATE WITH MORTALITY AND HEALTH CARE UTILIZATION FOR CHILDREN PRESENTING TO THE EMERGENCY DEPARTMENT WITH HEAD TRAUMA?

P Chaudhary,¹ B Weidner,² JJ Burns¹. ¹UF College of Medicine, Pensacola, FL; ²Sacred Heart Children's Hospital, Pensacola, FL.

10.1136/jim-2016-000393.44

Purpose of Study Our study will determine if the mechanisms of head injury correlates with mortality and utilization of health care resources.

Methods Used A retrospective registry review was performed for children ages 0–15 seen at Sacred Heart ED from 2010–2015 with ICD9 codes for head injury. Upon IRB approval variables including demographics, mechanism of injury, disposition after assessment (home or inpatient floor vs. ICU, death), Glasgow Coma Scores (GCS) and length of stay (LOS) were extracted from the registry.

Summary of Results There were 631 total patients in the study, 62.6% were males, mean age was 7.0 years. Of those that died 64% were from MVA, 28% were from violence, 4% struck by object and 4 falls. There were no deaths from injuries associated with sports, dog attack, ATV accidents, bicycle.

On multivariate logistic regression, MVA ($p < 0.001$; Exp (B) 15.7) and violence ($p < 0.001$; Exp(B)46.1) remained statistically significantly related to mortality.

Mortality for MVA was 7.6% vs. 2.1% for non-MVA (Chi-square $p = 0.001$).

Mortality for violence was 19.4% vs 3.0% for non-violence (Chi-square $p < 0.001$).

The average LOS for an MVA related head injury was longer than other mechanisms combined (3.70 MVA vs. 2.53 Non-MVA; Mann Whitney test: $p < 0.001$), the GCS was lower (12.4 MVA vs.13.7 Non-MVA; Mann Whitney test: $p < 0.001$), and percent admitted to PICU was higher (55.5% MVA vs. 43.9% non-MVA; $p = 0.006$).

Similarly, the average LOS for a violence related head injury was longer than other mechanisms (violence 6.81 vs. 2.72 non-violence; Mann Whitney test: $p < 0.001$), the GCS was lower (12.4 violence vs.13.7 non-violence; Mann Whitney test: $p < 0.001$), and percent admitted to PICU was higher (66.7% violence vs. 43.9% non-violence; $p = 0.019$).

Conclusions This study showed that MVA and violence associated head trauma had higher mortality, LOS, lower GCS and higher % admission to PICU when compared to other mechanisms. This should encourage greater efforts towards prevention.

45 AN UNUSUAL CASE OF HEADACHE WITH RIGHT HEMIPARESIS

JE Conley. *University of South Alabama, Mobile, AL.*

10.1136/jim-2016-000393.45

Case Report 16 year old obese female presented with two weeks history of occipital headaches and associated right eye blurry vision, followed by worsening gait instability. Physical exam noted 4/5 strength in right upper and lower

extremities, compared to 5/5 on left side; otherwise, reflexes and sensation was normal throughout. Cranial nerves were grossly intact and fundoscopic exam was negative for papilledema. MRI noted active plaques in the juxtacortical, periventricular, pericallosal, cerebellar mater, and spinal cord. Lumbar puncture revealed an elevated opening pressure of 44 cm H2O. Oligoclonal bands 1.59, IgG Index 12, and Myelin Basic Protein 28, were all positive and diagnostic for Multiple Sclerosis. These diagnostic findings provided a challenge, as the increased intracranial pressure could have been secondary to either Pseudotumor Cerebri or a rare manifestation of MS. Nevertheless, she completed a course of Methylprednisolone 1 gram daily for 5 days. Right sided hemiparesis resolved, but headache and vision changes continued to worsen. Multiple lumbar punctures were performed, and opening pressures slowly trended down. Patient was gradually titrated to Acetazolamide 750 mg QID for Pseudotumor Cerebri management. Headaches and vision changes improved, and she worked daily with physical therapy to improve strength given deconditioning over hospital course. We conclude that the diagnostic approach for acute onset of suspected demyelinating syndromes can be difficult. The incidence of Pseudotumor Cerebri in obese women ages 14–55 years is 19/100,000. In contrast, the incidence of MS is 7/100,000 among same age group. In some case reports, MS has been associated with elevated intracranial pressure or has even coexisted with Pseudotumor Cerebri. Therefore, clinicians must be aware of this rare finding and treat accordingly.

46 PROVIDER ESTIMATION OF THE HEALTH LITERACY OF PEDIATRIC CAREGIVERS IN A PREDOMINANTLY SPANISH SPEAKING POPULATION

M Cooper, R Blucker, M Grassi, C Parrish, E Griffeth, K Damron, S Gillaspay, D Thompson, M Dunlap. *Oklahoma University Health Science Center, Oklahoma City, OK.*

10.1136/jim-2016-000393.46

Purpose of Study The purpose of this study was to evaluate how well pediatric providers practicing in a primarily Spanish speaking environment could predict caregiver health literacy scores on two tools, the Newest Vital Sign (NVS) and the Short Assessment of Health Literacy Spanish and English (SAHL S&E).

Methods Used A convenience sample of 92 caregivers was obtained from the OUHSC Latino Clinic, a clinic primarily

oriented toward families who speak Spanish. Fifty caregivers were evaluated with the NVS and 42 were evaluated with the SAHL S&E. Providers (physician/NP) and medical assistants (MA) were asked to estimate the scores of the caregivers for each tool. The scores and estimates were converted to binary outcomes with a passing score of ≥ 4 for the NVS and ≥ 15 for the SAHL S&E.

Summary of Results There was discordance between the providers estimating a passing score and the caregiver passing for each of the two tools, and there were large differences between patient pass rates on the two tools (see table below). Providers correctly estimated a caregiver pass/fail for the NVS 56% of the time (CI 41.7,70.2) while MAs were correct 46% of the time (31.7,60.3). Providers correctly estimated a caregivers’s pass/fail for the SAHL S&E 42.9% of the time (CI 27.2,58.5) while MA’s were correct 47.6% of the time (31.9,63.4). Providers and MA’s were more likely to underestimate scores of the SAHL S&E and overestimate scores of the NVS. There was no difference between provider and MA estimation ability.

Conclusions Provider estimation of caregiver performance on health literacy tools is poor and varies with the tool. This, coupled with the variation in absolute scores on the tools, highlights the need for further study into provider estimation of Spanish speaking caregiver skills and health literacy measurement in Spanish speaking populations.

47 ASSESSMENT OF HEALTH LITERACY WITH MULTIPLE TOOLS IN A POPULATION OF SPANISH SPEAKING CAREGIVERS OF PEDIATRIC PATIENTS

M Cooper, M Dunlap, E Griffeth, K Damron, C Parrish, M Grassi, S Gillaspay, D Thompson, R Blucker. *Oklahoma University Health Science Center, Oklahoma City, OK.*

10.1136/jim-2016-000393.47

Purpose of Study The purpose of this study was to evaluate the health literacy of a population of Spanish speaking caregivers of pediatric patients using the Newest Vital Sign (NVS) and the Short Assessment of Health Literacy Spanish and English (SAHL S&E) and to evaluate if scores on these tools correlate to obesity or immunization status.

Methods Used A convenience sample of caregivers of 209 pediatric patients was obtained from the OUHSC Latino Clinic, a clinic primarily oriented toward families who speak Spanish as a first language. The caregivers of the first 112 were administered the Newest Vital Sign (NVS) tool,

Abstract 46 Table 1

	Provider NVS (p=0.0001)		MA NVS (p<0.0001)	
	Estimate Fail	Estimate Pass	Estimate Fail	Estimate Pass
Score Fail	20	20	15	25
Score Pass	2	8	2	8
	Provider SAHL (p<0.0001)		MA SAHL (p=0.0001)	
	Estimate Fail	Estimate Pass	Estimate Fail	Estimate Pass
Score Fail	4	2	4	2
Score Pass	22	14	20	16

and the caregivers of the next 97 were administered the Short Assessment of Health Literacy Spanish and English (SAHL S&E). Outcome measures were defined as obesity (BMI \geq 95%, measured only for children over the age of 2, n=166) and immunization status. Fully immunized was defined as having received required vaccines for age as measured by the Oklahoma state registry.

Summary of Results There was significant discordance between the results of the two tools for patients in the same population. Only 19.8% of the caregivers who took the NVS measured as health literate, but 86.6% who took the SAHL (S&E) measured as literate. Fully 89.9% of children were up to date on immunizations, and of those over age two years 32.9% were obese. Relative risks for obesity and immunization status were calculated accounting for clustering within families, and neither outcome was associated with health literacy as defined by either the NVS nor the SAHL (S&E).

Conclusions These results are consistent with previous studies findings of a significant discordance between health literacy assessment tools. Further study is needed to determine the optimal tools for assessment of caregiver health literacy. Follow up studies matching results of these tools to clinical outcomes or specific health behaviors would increase the clinical and research utility of the tools.

48 CHILDREN WITH INTRACRANIAL AND EXTRACRANIAL COMPLICATIONS OF SINUSITIS

D Wafadari, B Estrada, H Custodio. *University of South Alabama, Mobile, AL.*

10.1136/jim-2016-000393.48

Purpose of Study Sinusitis is a common infection in pediatrics. Some patients with severe complications manifest with subtle symptoms which could be easily missed, leading to a delay in diagnosis and therapy. The purpose of this study was to identify the demographics and clinical presentation of patients who developed intracranial (IC) and/or extracranial (EC) complications of sinusitis.

Methods Used Medical records of patients less than 18 years of age who developed IC and/or EC complications of sinusitis from January 1, 2006 to February 29, 2016 were

	ALL, N=78 (%)	EC, N=55 (%)	IC + EC, N=23 (%)
Age (year)	Mean	6.9	5.5
	Median	6	4
Gender	M	49 (63)	34 (62)
	F	29 (37)	21 (38)
Race	Black	43 (55)	32 (58)
	White	32 (41)	20 (36)
	Other	3 (4)	3 (6)
Congestion	47 (60)	34 (62)	13 (57)
Cough	46 (59)	33 (60)	13 (57)
Fever	46 (59)	28 (51)	18 (78)
Headache	29 (37)	10 (18)	19 (83)
Emesis	16 (21)	6 (11)	10 (44)
AMS	10 (13)	1 (2)	9 (39)
Rhinorrhea	50 (64)	34 (62)	16 (70)
Eye swelling	61 (78)	52 (95)	9 (39)
Duration (days)	Mean	5.29	4.89
	Median	4	4
Dur >7 days	26	17 (31)	9 (23)

Abstract 48 Figure 1

retrospectively reviewed. These patients were identified via ICD 9 and 10 codes for the following diagnoses: Acute/chronic sinusitis, periorbital/orbital cellulitis, orbital abscess, osteomyelitis of orbit, meningitis, intracranial abscess, epidural/subdural abscess, encephalitis.

Only the patients who were confirmed to have both sinusitis and its complications (IC and/or EC) were included in the study. Exclusion criteria included:

- Immunocompromised conditions
- CNS anomalies
- Presence of VP shunt.

Summary of Results 4781 patients were identified to have sinusitis. Of these, 78 (1.6%) were found to have IC and/or EC complications. Further details of demographic distribution and clinical presentation are provided in Table 1.

-Logistic regression analysis revealed age (older) was the only significant factor for developing IC complications of sinusitis.

-Majority (75%) of children who presented with headache and eye swelling had both IC and EC complications.

Conclusions Children more than 11 years of age may have higher risk for severe infection (IC +/- EC involvement). Brain imaging should be highly considered in children presenting with both headache and eye swelling.

49 VARIATIONS IN CONTINUITY OF CARE IN OU PEDIATRIC RESIDENCY LONGITUDINAL CARE CLINICS

R Gilpatrick, N Connolly, B Rogacki, P Darden. *University of Oklahoma Health Sciences Center, Oklahoma City, OK.*

10.1136/jim-2016-000393.49

Purpose of Study Continuity of care is an important part of a medical home model and has been shown to improve many aspects of patient care. In addition, continuity of care may also increase patients' and physicians' satisfaction; however, few resident longitudinal care clinics track continuity in a systematic fashion. This project evaluated continuity of care within the four OUHSC Pediatrics Clinics. OU Pediatrics Residency Program offers three continuity clinics: Continuity Clinic (CC), the main longitudinal care site for pediatric residents, Fostering Hope (FH), which focuses on care for children the foster care system, and Latino Clinic (LC), an off campus teaching clinic which focuses on care for the Spanish speaking community. We also included the General Pediatrics Clinic (GP), a block rotation, which does well child and acute care but does not strive for continuity, to provide context. Our specific aims included measuring and comparing continuity between the four clinics.

Methods Used De-identified data was obtained from the billing records of the 4 different pediatric teaching clinics. Explicit designation within the appointment system classifies the primary resident for a patient. All clinics primarily saw patients funded by Medicaid. Using the de-identified data, measures were calculated for continuity of care, including the Usual Provider of Care (UPC). For this report we examined 1st and 2nd year pediatric residents in fiscal year 2016 and the UPC.

Summary of Results Visit numbers were GP 7,983, CC 11,729, FH 3,066 and LC 9,940; of these, 37%, 32%,

21%, 37% and 5%, of visits, respectively, were seen by pediatric residents. UPC varied significantly by clinic with LC, 9%<GR, 14%<FH, 20%<CC, 49%. ($P<.05$). Within clinics, individual residents also showed dramatic differences in continuity: LC ranged from 5% to 15%; GR, <1% to 32%; FH, 12% to 44%; and CC, 32% to 72%.

Conclusions Even with similar administrative systems in place each clinic had dramatically different continuity of care for the pediatric residents and their patients. There are clearly clinic and personal resident factors contributing to variations in continuity. As continuity of care should be monitored and addressed on an ongoing basis, this information presents a clear opportunity for further evaluation and improvement.

50 RUMINATION DISORDER RESULTING IN SEVERE MALNUTRITION

PC Goleb. *UTHSC, Memphis, TN.*

10.1136/jim-2016-000393.50

Case Report Psychiatric and developmental disorders often contribute to acute illnesses requiring hospitalization. Specifically, autistic patients often experience restricted and stereotyped behaviors that can lead to impaired nutrition.

An 18 year old male with a past medical history of autism, developmental delay, and scoliosis was brought to the hospital by family after vomiting, weight loss, and weakness. The patient had been regurgitating food his entire life, but had acutely worsened over the last 3 weeks resulting in a weight loss of 20 pounds in 3 months. The family regularly saw a psychiatrist but had not seen their primary care physician in over a year. In the ER, temperature was 34.7°C, heart rate 61, blood pressure 90/67, and respiratory rate 16. Weight was 28.2 kg, Height was 146 cm, and BMI 13.2 (<5th percentile). Glucose was 34, albumin was 3.1, and pre-albumin was 5.6. Physical exam was notable for cachexia, lethargy, 2/6 systolic ejection murmur, and multiple open sores. The patient was admitted to the ICU and given 25% of caloric needs with IV electrolyte supplementation to avoid refeeding syndrome. On hospital day 1, vital signs normalized and the patient was transferred to the floor. Due to continued rumination, a sitter was required to assist with meals. A nasojunal (NJ) tube was placed for nutrition and total parenteral nutrition (TPN) was provided to improve nutritional status. A CT scan of the abdomen found a dilated stomach and proximal duodenum concerning for Superior Mesenteric Artery (SMA) Syndrome. An Upper GI study found no obstruction, ruling out SMA Syndrome. A esophagogastro-duodenoscopy (EGD) was performed and found only *Candida* Esophagitis. To evaluate other causes of malnutrition, a genetic workup was performed revealing a normal male genomic profile. Social work found no concerns for abuse or neglect at home.

The patient remained hospitalized for over one month. The patient continued to ruminate, which was felt to be a self-soothing action. Rumination was less frequent with the help of a sitter who provided re-direction and weight was gained with supplemental nutrition. When discharged to long term residential care, the patient had gained 13 pounds.

This case highlights the importance of identifying and addressing psychiatric disorders in the hope of establishing multidisciplinary support to prevent associated medical illnesses.

51 ASSESSING SHORT AND LONG-TERM PARENT UNDERSTANDING OF PEDIATRIC ASTHMA ACTION PLAN EDUCATION USING INTERACTIVE COMMUNICATION TOOL

D Hicks,¹ S Mathur,² R Mehta². ¹Medical College of Georgia at Augusta University, Augusta, GA; ²Augusta University, Augusta, GA.

10.1136/jim-2016-000393.51

Purpose of Study A key component of pediatric asthma care is to create and follow an Asthma Action Plan (AAP), an individualized action plan developed by providers and patients together. Recurring emergency department visits for pediatric asthma at Children's Healthcare of Georgia (CHOG) prompted a recent survey, indicating the need for substantial improvement in provider-patient communication of the AAP, although specific communication barriers were not identified. The purpose of this study was to assess parent understanding of the AAP and identify provider-patient communication gaps relating to both the frequency and overall number of AAP teachings parents receive.

Methods Used Parents of pediatric, asthmatic patients ($n=25$, 8.88 ± 3.26 years old) in the inpatient, critical care and outpatient settings of CHOG were given a 12-question quiz over aspects of the AAP on an interactive education tool via iPad. Four questions (Q1, Q8, Q11, Q12) were found to be frequently missed. Parent performance on these 4 questions was compared between patients with 7 or more AAP teachings per lifetime ($n=9$) and those with less than 7 AAP teachings per lifetime ($n=16$). Parent scores were also compared between patients with an AAP in the last 6 months ($n=11$) and those with an AAP teaching prior to the last 6 months ($n=14$).

Summary of Results There was no significant difference in parent scores between the group with a more recent AAP teaching (≤ 6 months ago) and those with a less recent teaching. As well, there was no significant difference in parent scores between the group with more numerous AAP teachings (≥ 7 teachings) and those with fewer teachings. Frequently missed concepts on the app quiz were also reviewed, showing a need for additional asthma education among parents.

Conclusions These results indicate that more recent and numerous AAP teachings alone are not enough to improve parent quiz performance and understanding. This suggests that additional barriers to parent understanding of the AAP exist and could be explored further in future studies.

52 THE ENDOSCOPIC AND HISTOLOGIC FINDINGS OF INFANTS WHO HAVE EXPERIENCED BRIEF RESOLVED UNEXPLAINED EVENTS

C Jarasvaraparn, K Crissinger, MB Rojas Gallegos. *University of South Alabama, Mobile, AL.*

10.1136/jim-2016-000393.52

Introduction A Brief Resolved Unexplained Event (BRUE) is a term used to characterize an event of an unknown

cause after an infant is found limp, cyanotic, bradycardic, abnormally breathing and/or requiring resuscitation. Some infants who experienced a BRUE underwent endoscopy as part of their evaluation.

Objective This study aimed to identify the endoscopic and histologic findings in infants who have experienced a BRUE.

Design This was a retrospective descriptive chart-review study.

Results Ninety-seven infants were diagnosed with BRUE. Nineteen (19.6%) of these infants underwent EGD and flexible sigmoidoscopy. The median age at BRUE diagnosis was 2 months (range 1–3) and the median age at endoscopy was 3 months (range 2–4). Apnea (95%) was the most common presentation of BRUE. The formulas before endoscopy were breast milk (1; 5.5%), Enfamil (1; 5.5%), Enfacare (2; 11%), Enfamil AR (4; 22%), Isomil (1; 5.5%), Nutramigen (4; 22%), Alimentum (3; 17%), and Elecare (2; 11%). The endoscopic findings showed erythematous esophagus (1; 5.2%), and lymphonodular hyperplasia in rectosigmoid colon (7; 37%). A value of >10 eosinophils/hpf was used to diagnose eosinophilia. The histologic findings demonstrated gastroesophageal reflux (2; 11%), esophageal eosinophilia (2; 11%), duodenal eosinophilia (10; 53%) and rectosigmoid eosinophilia (15; 79%).

Conclusions Rectosigmoid lymphonodular hyperplasia and eosinophilia, which are markers of milk soy protein intolerance (MSPI), were the most common findings at endoscopy and on histopathologic evaluation. Although there is no proof of association of BRUE and MSPI, inclusion of MSPI in the differential diagnosis for these BRUE infants may be warranted.

53 THE CHARACTERISTICS OF ESOPHAGEAL MULTICHANNEL INTRALUMINAL IMPEDANCE-PH MEASUREMENTS IN INFANTS EXPERIENCING BRIEF RESOLVED UNEXPLAINED EVENTS

C Jarasvaraparn, MB Rojas Gallegos, K Crissinger. *University of South Alabama, Mobile, AL.*

10.1136/jim-2016-000393.53

Introduction A Brief Resolved Unexplained Event (BRUE) is defined as an event occurring in an infant younger than the age of one year when the observer reports a sudden, brief, and now resolved episode of cyanosis or pallor, absent/decreased/irregular breathing, change in tone, and altered level of responsiveness. Gastroesophageal reflux has been proposed as one of the causes of BRUE.

Objective This study aimed to identify the characteristics of multichannel intraluminal impedance (MII) in infants who have experienced a BRUE.

Design This was a retrospective descriptive study.

Results Thirty-eight patients were included in the study. The median age at diagnosis of BRUE was two months (range 1–3). Apnea (32/38; 84%) was the most common presentation of BRUE. During the impedance study, the median number of acid reflux episodes and nonacid reflux episodes were 20 (range 10–34) and 43 (range 23–61), respectively. The median number of esophageal distal reflux episodes and esophageal proximal reflux episodes

were 69 (range 54–83) and 44 (range 38–54). The median Boix-Ochoa score was 9.3 (range 3.7–14.6; normal <16.6). The median reflux symptom index of pain, cough and vomiting (normal <50%) were 35.5% (range 14.7–70), 50% (range 25–72) and 50% (range 33–86), respectively. The median reflux symptom sensitivity index of pain, cough and vomiting (normal <10%) were 3% (range 0.8–17.8), 3.5% (range 0.8–15.3) and 3.5% (range 2–6.8), respectively. The median reflux symptom association probability of pain, cough, and vomiting (normal <95%) showed 35% (0–98), 93% (61–100) and 96% (54–100), respectively. The median impedance score (normal <73) was 68.5 (range 48–111). The severity of MII showed 13 (34%) negative, 5 (13%) mild, and 20 (53%) moderate. We found 5 (20%) acid reflux, 13 (52%) nonacid reflux and 7 (28%) both acid/nonacid reflux. At discharge, 28/38 (74%) infants were treated with a H2 receptor antagonist and 4/38 (10%) with a proton-pump inhibitor.

Conclusion Among infants experiencing a BRUE, esophageal impedance monitoring revealed acid or nonacid reflux in 2/3 of patients in this small study.

54 THE EFFECTS OF HEALTH LITERACY ON PARENTAL AND CHILD TOBACCO USE AND CHILD SECONDHAND SMOKE EXPOSURE

P Mididoddi,¹ J Waller,² M Tingen^{1,2}. ¹Augusta University, Suwanee, GA; ²Augusta University, Augusta, GA.

10.1136/jim-2016-000393.54

Purpose of Study Tobacco use is the leading cause of preventable death in the United States. Few studies have explored how health literacy affects tobacco use and secondhand smoke exposure in parents and children. It is hypothesized that higher parental health literacy is associated with lower parental smoking and with lower smoking, lower secondhand smoke exposure, and higher health literacy in children.

Methods Used 428 4th grade students and 453 parents enrolled in a randomized controlled trial, completed demographics surveys, and provided salivary cotinine samples. 199 parents and 75 children completed health literacy screens (REALM, SILS, NVS). Logistic regression was used to examine associations of parent or child health literacy with parent and child demographics, tobacco use, and smoke exposure. Pearson correlation coefficients were used to examine associations between parental and child health literacy measures.

Summary of Results Black parents were more likely to have lower health literacy REALM scores than other races. Lower income was associated with lower parent REALM scores, SILS difficulty, and lower NVS literacy. Parent and child tobacco use and child secondhand smoke exposure were not associated with parent health literacy. Child tobacco use and smoke exposure were not associated with child health literacy. A positive correlation was seen between parent and child REALM scores ($r=0.27$, $p=0.0248$).

Conclusions The findings that lower income and black parents are associated with lower health literacy emphasize the importance of tailoring health education based on

demographics. The low parental health literacy and the positive correlation between parent and child health literacy measure of REALM scores may suggest the need to promote parent literacy which could improve child health literacy and possibly overall child health outcomes.

55 PEER INFLUENCE ON ADOLESCENT USE AND PERCEPTION OF ELECTRONIC CIGARETTES

J Pane,² J Murray,¹ R Nugent,¹ M Orellana-Barrios,³ D Payne,³ K Nugent³. ¹Carnegie Mellon, Pittsburgh, PA; ²RAND Corporation, Pittsburgh, PA; ³Texas Tech Internal Medicine, Lubbock, TX.

10.1136/jim-2016-000393.55

Purpose of Study Electronic cigarettes (e-cigarettes) provide a novel source of nicotine and may lead to experimentation by adolescents and eventually to the use of conventional cigarettes. Peer influence has a strong effect on student behavior and could affect their intention to try these devices.

Methods Used The National Youth Tobacco Survey collected information from a nationally representative sample of students in 2014 to determine their experience with conventional cigarettes and e-cigarettes, their intention to use these products in the future, and their perception of harm and addiction associated with these products. We analyzed these data with ordered probit regression models to determine possible associations with demographic characteristics and their perception of harm or addiction with their 'willingness to use electronic cigarettes or cigarettes if a best friend offered one.'

Summary of Results This survey included 22,007 respondents; 50.2% were male. Seventeen and seven-tenths percent had used conventional cigarettes, and 12.4 % had used e-cigarettes. Sixteen and seven tenths percent thought e-cigarettes caused no harm, 3.2% thought that conventional cigarettes caused no harm, and 50.7% thought that e-cigarettes were less harmful than conventional cigarettes. Less than 5% of the students responded 'Definitely yes' to the question 'Do you think you will try an e-cig?' The odds ratios for willingness to try an e-cigarette offered by a best friend increased as the perception of harm decreased (1.0 for 'A lot of harm' to 4.88 (95% CI: 3.83, 6.22) for 'No harm'). These odds ratios also increased in participants who thought that e-cigarettes were less harmful than conventional cigarettes (1.65; 95%CI: 1.41, 1.94) and if they had tried other tobacco products (2.62; 95% CI: 2.59, 3.24). Odds ratios were highest in ages 13–16.

Conclusions These survey results indicate that most students have not tried e-cigarettes or conventional cigarettes. Students who think e-cigarettes pose no harm and students in the age range of 13–16 are more likely to try them if offered by a best friend. Tobacco prevention programs should focus on education regarding harm and start with students in the 12–13 year old age group.

56 MEDIASTINAL AND HILAR FIBROSIS IN AN 18 YEAR OLD MALE

JD Patterson, D Graham, A George, M Will, S Deena. San Antonio Uniformed Services Health Education Consortium, San Antonio, TX.

10.1136/jim-2016-000393.56

Case Report An 18-year-old male presented to clinic with shortness of breath. Examination revealed a well-appearing male with reduced air entry into the lower right hemithorax. CT scan confirmed a large right effusion and massive right hilar, mediastinal calcific lymphadenopathy. Bronchoscopy revealed extrinsic compression with complete obstruction of the RML bronchus. Secondary to the complex fluid collection and RML/RLL collapse, surgery was suggested. Intraoperatively, hilar dissection planes were obliterated due to a large conglomerate of lymph nodes. RML/RLL bi-lobectomy was required given extent of disease. Histologic evaluation demonstrated areas of caseating necrosis with microcalcifications that were surrounded by fibrosis, which encompassed large hilar vessels and abutted the bronchus. A GMS stain highlighted thin-walled 3–5 μm yeast-like organisms within areas of necrosis.

Histoplasmosis has been associated with chronic inflammatory complications including fibrosing mediastinitis. In our patient, the presentation was unique in regards to location of fibrosis. When localized to the hilum, the focal fibrosis may produce profound changes in the structure of the lung which can include obstruction and eventual obliteration of small airways. Histopathology and cytology remain the standard diagnostic approach for endemic mycoses. Histologic examination may reveal distinct 2–5 μm , oval, narrow-based budding yeasts suggestive of *H. capsulatum*.

The diagnosis and etiology of mediastinal and hilar fibrosis is challenging because of its nonspecific clinical and radiologic presentation. Surgical biopsy and histopathologic investigation aid in this diagnostic dilemma. As in our patient, symptoms related to mediastinal and hilar fibrosis causing compression and obstruction to vital structures benefit from a multidisciplinary team approach.

57 POINT-OF-CARE ULTRASOUND AND PEDIATRIC SKIN AND SOFT TISSUE INFECTIONS: A PROSPECTIVE, OUTCOMES-BASED STUDY

JA Buice, A Kulkarni, CM Pruitt. University of Alabama Birmingham, Birmingham, AL.

10.1136/jim-2016-000393.57

Purpose of Study Skin and soft tissue infections (SSTIs) are a common clinical entity in the emergency department (ED). Increasing evidence in both adult and pediatric populations indicates that the use of point-of-care ultrasound (POCUS) enhances diagnostic accuracy of abscesses. However, there is a paucity of data examining the impact of POCUS utilization on patient outcomes in relation to SSTIs. The purpose of our study is to determine if the use of POCUS with SSTIs is associated with improved clinical outcomes.

Methods Used Subjects 2 months - 19 years of age presenting with a chief complaint related to SSTI were prospectively enrolled by convenience sampling. In our pediatric ED, roughly half of physicians routinely use POCUS for SSTI. Thus, use of POCUS was per provider discretion (not controlled). After informed consent was obtained, medical records were retrospectively queried for demographic, clinical, and sonographic data. Caregivers

were contacted via telephone 3–7 days after their ED visit. Subjects were excluded if they were initially admitted to the hospital, if they received an ultrasound in the radiology department, or if they were lost to phone follow-up. We defined the primary endpoint of treatment failure as parental report of subsequent hospitalization; subsequent incision and drainage; or any change in antibiotic regimen. We calculated a sample size of 249 patients using an 80% power and $\alpha=0.05$ to detect a difference in treatment failure with an odds ratio of 2.0 (in favor of POCUS).

Summary of Results 165 patients have been screened at the point of this interim analysis, with 109 meeting inclusion criteria. Of these, 56 (47%) underwent POCUS. Twelve patients (7%) have experienced treatment failure, with 5/12 having received POCUS.

Conclusions Based on our preliminary results, treatment failure in pediatric SSTI is uncommon, regardless of the use of POCUS. Further data are needed to determine whether POCUS use is associated with improved outcomes for pediatric SSTIs.

58 UNDERSTANDING BARRIERS TO ADHERING TO THE ASTHMA SELF-MANAGEMENT PLAN FOR PATIENT WITH FREQUENT ASTHMA EXACERBATION

B Shin, R Mehta. *Medical College of Georgia at Augusta University, Augusta, GA.*

10.1136/jim-2016-000393.58

Purpose of Study Asthma affects over 43 million Americans and is associated with significant morbidity and healthcare expenditures. Several studies have identified that outpatient visits account for nearly 60% of direct costs. According to the NIH National Asthma Education and Prevention Program (NAEPP), costly asthma exacerbations may be prevented with guideline-based asthma care and effective self-management of asthma symptoms using education given to all the patients and parents using Asthma Action Plan (AAP). This study is designed to understand barriers to pediatric asthma self-management plan adherence by patients and families leading to frequent multiple hospital visits and r admission.

Methods Used A retrospective chart review of 100 pediatric patients who visited Children's Hospital of Georgia Emergency Room, Outpatient or Inpatient for asthma exacerbation care at three or more occasions over one year period. Data collection included demographics and various factors that could potentially affect both self-management of asthma and acute episodes, such as social dynamics, smoking, mold, pets and allergen exposures, presence of upper respiratory tract infection (URI), types of insurance, compliance to controller medication, and education using AAP. Multinomial logistic regression model was used for the statistical analysis. P value of 0.05 was considered to be significant.

Summary of Results Younger age, male, presence of URI, smoking exposure, living with a single parent, and poor compliance to controller medications were significantly associated with frequent hospital visits for asthma exacerbations. However, the number of routine follow-up visits,

presence of allergies or pets, AAP, and Social Work referral did not affect acute episodes and multiple visits to hospital. **Conclusions** This retrospective study highlights the importance of certain preventable factors, such as smoking exposure and medication compliance leading to frequent asthma exacerbation and hospital visits. Results also suggest that guideline-based asthma care, such as AAP, alone may not be effective. More comprehensive education of parents/healthcare providers and policy changes at state /federal level may be needed for effective prevention of asthma exacerbation in children causing significant morbidity and cost to overall healthcare.

59 BELL'S PALSY AND ENCEPHALITIS IN AN ADOLESCENT WITH EPSTEIN-BARR VIRUS MONONUCLEOSIS

T Tarro, RE Begue. *LSU Health Sciences Center, New Orleans, LA.*

10.1136/jim-2016-000393.59

Case Report Introduction: Epstein-Barr Virus (EBV) infects over 90% of the world population and is the causative agent of infectious mononucleosis (IM). IM is a viral illness, which classically presents in adolescents as a triad of fever, pharyngitis, and lymphadenopathy. However, serious neurological manifestations occur in 1 to 18% of patients and include encephalitis, aseptic meningitis, and cranial neuropathies including Bell's palsy.

Case An 18 year old man with a history of Ventricular Septal Defect repair presented with a 4 day course of severe headaches. The headaches progressively worsened and then he began experiencing photophobia, neck stiffness, lower back pain, and diffuse arthralgias/myalgias. On the day of admit, the patient complained of numbness/tingling on the right side of his face. He began to slur his speech and then developed complete right-sided facial paralysis. Upon admit, the patient was afebrile and exam was significant for right facial Bell's palsy. Significant labs: CSF WBC 26 (6% Lymphocytes and 94% Monocytes), CSF Glucose 55, CSF Protein 94. Comprehensive metabolic panel revealed an elevated ALT which prompted a Monospot test to be performed in the absence of IM symptoms. Monospot resulted as positive and then EBV serologies showed an elevated IgM. Patient's CSF EBV DNA also resulted as positive. MRI brain showed bilateral cortical and subcortical white matter edema with associated leptomeningeal enhancement most pronounced in the bilateral frontal lobes, right temporal lobe, and insula. MRI brain also showed enhancement along the lateral aspect of the right and left cranial nerve VII. The patient was treated with a 5-day course of corticosteroid therapy and his right facial Bell's palsy resolved.

Discussion EBV encephalitis is rare in adolescents but can have severe neurological complications. The incidence of neurological complications during EBV infection may be the only clinical manifestations of IM. Thus, EBV infection should be considered when adolescents present with acute neurological symptoms, especially in the setting of transaminitis, even in the absence of classic signs and symptoms of IM.

60 HUMAN PAPILLOMAVIRUS VACCINE SERIES COMPLETION RATES AMONG PEDIATRIC, FAMILY MEDICINE, AND GYNECOLOGY CLINICS IN WEST TEXAS

JT Thambuswamy, F Levent, M Nur. *Texas Tech University Health Sciences Center, Lubbock, TX.*

10.1136/jim-2016-000393.60

Purpose of Study To compare Human Papillomavirus (HPV) vaccine completion rates among three different academic specialty clinics in West Texas.

Methods Used After obtaining IRB approval, Current Procedural Terminology (CPT) code 90649 associated to HPV vaccination was used to identify all patients seen in any of the Pediatric, Family Medicine and Gynecology clinics affiliated to TTUHSC in Lubbock, TX between January 1, 2007 and June 27, 2016. Gender, age, race/ethnicity, provider, source of funding, and number of HPV vaccines that each patient received was collected. Vaccination was considered complete if the patient received three doses of the HPV vaccine. Statistical analysis was performed using SPSS software version 23. Demographic data was expressed as mean+SD, and frequencies (%). The difference in completion rates among the three specialty clinics was analyzed using Chi Square. A p value of <0.05 was considered statistically significant.

Summary of Results A total of 4706 patients initiated HPV vaccination, and 1333 (28.3%) completed the three dose series. The average age of initiation of the vaccine series was 12.6+2 years for patients seen in Pediatric clinics, 18.3+4.7 years for Family Medicine clinics, and 21.1+3.3 years for Gynecology clinics. As seen in Table 1, there was a statistically significant difference in HPV vaccine series completion between Family Medicine and the other two specialty clinics ($X^2=33.05$, $p=0.000$).

Conclusions Overall, the completion rates were well below the Healthy 2020 goals for HPV vaccine completion. As previously reported, patients seen in Gynecology clinics had the best completion rate, though in this study, Pediatric clinics did very similarly

Abstract 60 Table 1 HPV Vaccine Completion Rate Among Different Clinics

Clinic	Complete HPV vaccination	Incomplete HPV vaccination	Total
Family Medicine	192 (20.7%) *	735 (79.3%)	927 (100%)
Gynecology	112 (30.9%)	251 (69.1%)	363 (100%)
Pediatrics	1029 (30.1%)	2387 (69.9%)	3416 (100%)
Total	1333 (28.3%)	3373 (71.7%)	4706 (100%)

*p=0.000

61 ASSESSMENT OF BREASTFEEDING KNOWLEDGE, ATTITUDES, AND INTENTION AMONG PREGNANT WOMEN IN WEST ALABAMA

C Wallace, K Burgess. *University of Alabama, College of Community Health Sciences, Tuscaloosa, AL.*

10.1136/jim-2016-000393.61

Purpose of Study As breastfeeding rates continue to rise in the United States, the state of Alabama faces consistently low breastfeeding initiation and duration rates. Poor maternal knowledge and negative attitudes toward breastfeeding may influence infant-feeding practices and constitute barriers to improving breastfeeding rates in Alabama. This study determines intention to breastfeed and explores beliefs and barriers to initiation of breastfeeding in a sample of pregnant women in West Alabama.

Methods Used A cross-sectional, convenience sampling strategy was employed for data collection. 100 obstetric patients, between 1–40 weeks gestational age, completed a questionnaire regarding their knowledge and attitudes toward breastfeeding, infant feeding plans, demographics, resources, and social support. Mean values for attitudes towards breastfeeding were compared between mothers who intended to breastfeed, mothers who did not intend to breastfeed, and mothers who were uncertain.

Summary of Results Among 100 mothers in our trial, 26% intended to breastfeed, 56% did not intend to breastfeed, and 18% were undecided. All mothers who intended to breastfeed felt well-informed about breastfeeding. However, only 14% of mothers not intending to breastfeed felt well-informed, and only 11% of undecided mothers felt well-informed about breastfeeding. Breastfeeding intention was most positively correlated with knowledge of breastfeeding benefits in infants followed by maternal education level and strong social support. Enrollment in the Women, Infants, and Children (WIC) Supplemental Nutrition Program was a negative predictor of breastfeeding intention.

Conclusions Maternal knowledge and social influences are important predictors of breastfeeding intention. Family, spousal, and employer attitudes and beliefs greatly influence maternal breastfeeding intention. In order to improve breastfeeding rates in Alabama, breastfeeding classes and consultations should include both the patient and members of their social support system. More research is necessary to determine the best venues for providing this education.

62 DO PEDIATRIC AND INTERNAL MEDICINE/PEDIATRIC RESIDENTS DO PELVIC EXAMS ON ADOLESCENTS?

W Ariel,¹ C Shepherd,² S Arnold¹. ¹University of Tennessee Health Science Center, Memphis, TN; ²University of Tennessee, Memphis, TN.

10.1136/jim-2016-000393.62

Purpose of Study Adolescent women have a high risk of pelvic inflammatory disease (PID). Residents caring for

adolescents should be trained to perform pelvic exams to diagnose PID and other gynecologic disorders. This survey evaluated pediatric and medicine/pediatric (med/ped) resident experience and comfort with pelvic exams in adolescents to identify barriers to their performance.

Methods Used Pediatric and med/ped residents at 6 programs in the Southeast were surveyed from June to July 2016. They were questioned about experience and opportunities to perform adolescent pelvic exams in medical school and residency through June 30, 2016, as well as comfort with the procedure and discussing sexual health. They were asked to identify indications for a pelvic exam and gynecology referral. Analysis included descriptive statistics and chi-square to compare proportions.

Summary of Results Overall, 94/335 residents (27.7%) responded to the survey. Most respondents were categorical pediatric residents (67%) and 72% were female. The rate of performing inspection examinations in medical school was similar to during residency (80% vs 78%, $p=0.8$) but exposure to speculum and bimanual exams decreased during residency (speculum: 70% vs 39%, $p<0.01$, bimanual: 70% vs 30%, $p<0.01$). Seventeen percent of residents had not performed a full pelvic exam in residency. Comfort level with pelvic exams improved with year of training. Most (80%) full pelvic exams were performed in acute settings such as the emergency department or inpatient floor. Residents felt comfortable obtaining a sexual history but 4% had discomfort with pelvic exams due to the sexual nature. Over 50% of residents correctly identified indications for a pelvic exam and gynecology referral. All but one of 33 med/ped residents were more comfortable performing pelvic exams in adults than adolescents regardless of experience.

Conclusions Comfort with performing adolescent pelvic exams improves during residency, but exposure to training is limited especially in primary care setting even though pelvic exams are recommended as part of routine adolescent outpatient care. Further investigation with a larger resident population is needed to better understand how resident exposure to pelvic exam training impacts clinical practice.

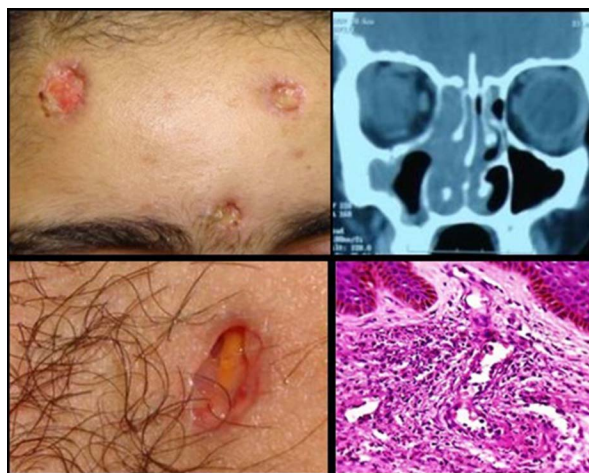Allergy, Immunology, and Rheumatology Joint Plenary Poster Session and Reception 4:30 PM Saturday, February 11, 2017

63 CUTANEOUS ULCERATIONS: AN UNCOMMON PRESENTATION OF WEGENER'S GRANULOMATOSIS

N Ahmed,^{1,2} H Schroeder¹. ¹UAB Division Clinical Immunology & Rheumatology, Birmingham, AL; ²Zagazig university, Zagazig, Egypt.

10.1136/jim-2016-000393.63

Case Report Wegener's granulomatosis (WG) is a small vessel vasculitis characterized by necrotizing granulomas of the upper and lower respiratory tracts, skin, and eyes and focal necrotizing glomerulonephritis. Pathogenesis may include abnormal antibody ANCA and antibodies against proteinase 3. Skin involvement includes various cutaneous



Abstract 63 Figure 1

lesions. A positive c-ANCA confirms the diagnosis, while a negative result does not necessarily rule out the diagnosis.

We report here a case of 16 years old female presented to our dermatology unit with 2 months history of acute progressive course of ulcers on the face and axilla associated with epistaxis and hemoptysis. Examination revealed deep necrotizing ulcers on the forehead, cheek and axilla. ENT examination revealed sinonasal polyps and hypoglossal paralysis. Investigation with CBC revealed anaemia, leucocytosis with neutrophilia with elevated ESR, -ve ANCA and -ve sputum examination with ziehl neelsen stain and normal urine and kidney functions. CT of the paranasal sinuses showed marked sinusitis of the ethmoid, frontal and maxillary sinuses with sinonasal polyp. CT chest revealed necrotizing pneumonia of RT middle and medial lobes of RT lung. A biopsy was taken from the edge of ulcer on the cheek revealing heavy infiltrate within the dermis extending into subcutaneous fat with fibrinoid necrosis of dermal blood vessels and wall infiltration with PNLs and nuclear dust. Based on the characteristic findings our final diagnosis was WG. Our patient received systemic prednisone and I.V cyclophosphamide with excellent response.

64 LEUKOCYTOCLASTIC VASCULITIS AS A PRESENTING FEATURE IN PRIMARY SJÖGREN'S SYNDROME

S Chalasani, L Maher. University of Mississippi, Jackson, MS.

10.1136/jim-2016-000393.64

Introduction Leukocytoclastic Vasculitis (LCV) is a vasculitis of the small vessels with inflammatory infiltrate composed of neutrophils. LCV could be idiopathic or can be secondary to medication, infections, collagen vascular diseases, or malignancy. Primary Sjögren's Syndrome (PSS) is one of the most common autoimmune disorder and vasculitis is one of the extra glandular manifestation. We present a case with LCV as a presenting feature for PSS.

Case 71-year-old female presented to us with an elevated rheumatoid factor (RF) and a positive ANA, speckled pattern, with recent diagnosis of LCV by dermatology. She

was seen in our service 2 years ago for positive RF and was discharged from our services as she did not have the clinical picture of rheumatoid arthritis. This time she noted purpuric rash on her lower legs that started about a year prior. Rash did not itch nor was it raised. Patient was referred to dermatology who biopsied and diagnosed her as LCV. Her other complaints were dry eyes, and a burning sensation in her mouth with intolerance to salt or spices. On examination her vitals were stable. Skin showed petechial rash across her lower extremity becoming ecchymosis in the ankle region. Mouth was dry with no ulcers; she was edentulous. Rest of her examination was normal. Labs showed sedimentation rate 43 Hm/Hr, RF 417 IU/ml, positive Sjögren's antibodies. Her other vasculitis work up antineutrophil cytoplasmic antibodies, cryoglobulins, complements C3/C4, hepatitis B and C serologies, were negative. Chest x-ray showed fullness and possible nodule in the right infrahilar region. Patient was diagnosed as PSS with LCV. Further evaluation with Computerized Tomography scan of the chest is pending to rule out malignancy. Patient was started on prednisone 20 mg and hydroxychloroquine 200 mg twice daily.

Discussion PSS is a systemic autoimmune disease that can occur at any age, but most commonly in older women. It mainly affects the exocrine glands and presents with persistent dryness of the eyes and the mouth. Cutaneous vasculitis occurs in 10 percent of the patients with PSS and the RF may be positive in 40–70 percent of patients with PSS. One has to be vigilant as Sjögren's patients with cutaneous vasculitis may be more likely to develop other extra glandular manifestations including lymphoma.

65 SPORADIC POLYARTERITIS NODOSA PRESENTING AS ABDOMINAL PAIN

S Chalasani, S Gonnalagadda, L Maher, V Majithia. *University of Mississippi, Jackson, MS.*

10.1136/jim-2016-000393.65

Introduction Polyarteritis Nodosa (PAN) is a necrotizing vasculitis of medium-sized vessels of unknown origin with a prevalence of 20–330/100000. It is associated with hepatitis B but due to universal vaccination, new cases are rare and sporadic. Here, we present two cases who came in with abdominal symptoms.

Case 1 A 38-year-old white male with history of diverticulitis presented with abdominal pain, nausea and vomiting. His abdomen was distended and tender on exam. Computerized Tomography Angiography (CTA) showed circumferential soft tissue encasement and narrowing of the abdominal aorta from level of the superior mesenteric artery (SMA) to the bifurcation. Mild stenosis of SMA and moderate stenosis of Inferior Mesenteric Artery origin was also noted. Evaluation for vasculitis; anti-nuclear antibody, antineutrophil cytoplasmic antibodies, cryoglobulins, C3/C4, IgG subclasses, Hepatitis B and C serologies were negative. He was started on Prednisone 60 mg daily with dramatic response. Upon discharge, his symptoms recurred along with a new testicular pain as he tapered prednisone to 10 mg/day.

Case 2 A 53-year-old African American male with history of diabetes, hypertension, and end stage renal disease presented with abdominal pain worsening over a several month period. In the last year, he had 50-pound weight loss and developed rapid acute on chronic renal failure. Patient's exam was notable for abdominal tenderness with guarding. CTA of the abdomen showed accelerated atherosclerosis and a new aneurysmal dilatation of the proximal SMA with vessel wall thickening and perivascular irregularity. Stenosis of SMA, celiac and both renal arteries were also noted. The vasculitis workup as in the previous case was also negative. Patient showed significant improvement with pulse steroids and oral prednisone. He was discharged with plans for Rituximab IV infusion.

Discussion PAN is a necrotizing vasculitis of medium-sized vessels associated with Hepatitis B. Diagnosis may be difficult without biopsy. In both these cases, clinical presentation and imaging with CTA were essential. There are only a few reported cases of PAN with aortic involvement. The first case demonstrates the rare involvement of large abdominal vessels and the second case highlights the occurrence of accelerated atherosclerosis in PAN.

66 POTENTIAL ROLE OF CANNABIS IN REDUCING RECURRENT EPISODES OF HEREDITARY ANGIOEDEMA

P Chariyawong, J Tarbox. *Texas Tech University Health Sciences Center, Lubbock, TX.*

10.1136/jim-2016-000393.66

Introduction Hereditary angioedema (HAE) is a rare disease affecting estimated 1 in 50,000 individual in the United States. Clinical manifestation characterized by recurrent episodes of angioedema, without urticarial or pruritus, in mucosal tissues of various organ systems. Excessive production of bradykinin causes potent vasodilator mechanism, leading to significant edema. We report a case of HAE type II who has smoked cannabis to control recurrent episodes of angioedema.

Case A 23 year-old African-American male who has history of HAE type II diagnosed since the age of 13. Episodes usually involve swelling of the extremities and groin that last 2–3 days and resolve spontaneously. Rarely, his face, throat and abdomen are involved. There is no family history of angioedema. He denies usage of NSAIDs, ACE inhibitors, narcotics, or any acute or prophylactic medication. He smokes marijuana several times daily and notices reduction in frequency of attacks. His last severe attacks were years ago. However, he experiences more frequent attacks in the past 4 months. He attributes this to anxiety from completing his photography degree and less frequent use of marijuana. He presented to hospital in New Mexico with facial and posterior oropharynx swelling along with dysarthria. He received IV diphenhydramine, methylprednisolone and was intubated to protect his airway. He was then transferred to University Medical Center in Lubbock, TX for higher level of care. C1 esterase inhibitor was administered with excellent response.

Discussion From a previous case report, there is evidence that cannabis helps control recurrent episodes of idiopathic

angioedema.¹ Our patient use of cannabis has been associated with good clinical outcome, in term of reduction in frequency of hereditary angioedema for years without any other medications. The mechanism of action of cannabis is not clearly understood. Cannabinoids have anti-inflammatory properties by inhibiting pro-inflammatory cytokine/chemokine production and by upregulating anti-inflammatory cytokines which may play a role to control symptom of HAE.

REFERENCE

- 1 Frenkel A, Roy-Shapira A, Evgeni B, *et al.* Life Threatening Idiopathic Recurrent Angioedema Responding to Cannabis. *Case Reports Immunol* 2015;2015:780824.

67 A HIDDEN DISEASE WITH AN OBVIOUS DIAGNOSIS: A CASE OF DERMATOMYOSITIS ASSOCIATED WITH SEMINOMA

T Chatterjee,² A Islam,¹ RD Smalligan,¹ F Hardwicke³. ¹Texas Tech Univ HSC Amarillo, Amarillo, TX; ²Texas Tech Univ HSC-Amarillo, Amarillo, TX; ³Texas Tech Univ HSC-Lubbock, Lubbock, TX.

10.1136/jim-2016-000393.67

Case Report A 34-year-old man with a past medical history of gastroesophageal reflux disease and allergic rhinitis presented to the clinic with progressive muscle weakness and a generalized urticarial rash which had spread to his torso, neck and extremities. Skin findings also included Gottron's papules. Skin biopsy showed spongiotic dermatitis with superficial perivascular lymphocytic infiltrate with scattered neutrophils and eosinophils, consistent with the diagnosis of dermatomyositis. Systemic immunosuppression was initiated including mycophenolate, prednisone and tacrolimus. The patient initially responded but later presented some months later with a non-tender right testicular mass and an associated elevated beta-HCG level. Seminoma was diagnosed and his mycophenolate was stopped as part of the therapy.

Discussion Dermatomyositis is an idiopathic inflammatory myopathy characterized by proximal skeletal muscle weakness, evidence of muscle inflammation and various associated cutaneous manifestations. Inflammatory arthritis, interstitial lung disease, Raynaud phenomenon, and the presence of autoantibodies are also common features of the disorder. An association between inflammatory myopathies and malignancy has been noted previously and the association is stronger for patients with dermatomyositis than with other myopathies. The risk of cancer is increased seven-fold compared to the general population. Some factors that correlate with the risk of cancer include dysphagia at presentation and older age at onset. The cancers whose incidences are most correlated with dermatomyositis include ovarian, lung, pancreatic and stomach. Seminoma was not a type of cancer mentioned in reports we could find in the literature. This case reminds clinicians to be alert for cancers of any type when following patients with dermatomyositis. It also confirms the value of a thorough genitourinary exam as part of the initial and follow-up physical examination of patients with the disorder.

68 AN EYE-POPPING DIAGNOSIS: PROPTOSIS AS A PRESENTING SYMPTOM OF IGG4-RELATED DISEASE

C Cranford, R deShazo. *University of Mississippi Medical Center, Jackson, MS.*

10.1136/jim-2016-000393.68

Case Report A 53-year-old male with chronic rhinosinusitis presented to clinic with hyper eosinophilia and episodic proptosis of the left eye. Prior work-up for hyper eosinophilia was unrevealing. He reported left eye proptosis associated with swelling, pain, decreased vision, and fatigue. Lab work showed polyclonal hypergammaglobulinemia with elevated IgG and IgE. IgG subclasses 1–3 were elevated. Absolute eosinophil count (AEC) was 410 cells per microliter (cells/ μ L) on Prednisone. He developed increased symptoms of left-sided eye pain, swelling, and cough. Computed tomography (CT) of his sinuses revealed pansinusitis and hypertrophy of both lacrimal glands with bilateral proptosis. CT of the chest, abdomen, and pelvis showed multifocal pneumonia and inflammatory changes of the GU system. He was admitted and started on antibiotics. AEC was 2600 cells/ μ L. Hyper eosinophilia work-up was negative for c-ANCA, p-ANCA, JAK2 v617F and FIP1L1/PDGFR mutations, and HIV with normal tryptase level. Work-up for parasites was negative. Biopsy of his nasal mucosa showed focal squamous metaplasia and inflammation. Lacrimal gland biopsy showed abundant lymphoid tissue with hyperplastic changes and increased IgG4 plasma cells. He was diagnosed with IgG4-related disease and started on Azathioprine.

IgG4-related disease is an emerging condition with varying presentations making it difficult to diagnose. It is characterized by lymphoplasmacytic infiltration of tissue with an increased concentration of IgG4 plasma cells in the affected tissue. Two-thirds of patients have elevated serum IgG4 levels. This disease commonly presents in middle-aged men. Patients often have peripheral eosinophilia. Almost any system can be affected including ophthalmic, nasopharyngeal, pulmonary, pancreatic, renal, dermal, and lymphatic tissues. CD4⁺ T lymphocytes have also been found in lesions, suggesting a potential role of these cells in pathogenesis. Lab findings include elevated IgG and IgE with hypocomplementemia if renal involvement is present. Several patterns of lung involvement have been described. Diagnosis is based on biopsy findings demonstrating characteristic pathology. Steroids are first-line treatment. Rituximab, Azathioprine, or Mycophenolate mofetil are reserved for refractory cases. The majority of patients will relapse.

69 COMPLICATED SEQUELA OF ALLERGIC FUNGAL SINUSITIS

N Dhawan. *Tulane University, New Orleans, LA.*

10.1136/jim-2016-000393.69

Purpose of Study Allergic fungal sinusitis results from an intense inflammatory response against noninvasive fungi. Involvement of the sphenoid sinus can result in serious pathology due to close proximity of the optic nerve,

cavernous sinus, and carotid artery. Allergic fungal sinusitis results from an intense inflammatory response against non-invasive fungi. Involvement of the sphenoid sinus can result in serious pathology due to close proximity of the optic nerve, cavernous sinus, and carotid artery.

Methods Used A 15 year old girl presents with diminished vision in her left eye and diplopia. She could only count hand motions with the involved eye. MRI of the brain revealed a large mass occupying the sphenoid and ethmoid sinuses which extended superiorly toward the frontal sinuses. A mass effect was seen upon the medial wall of the left globe, which narrowed the optic canal. The high signal around the mass was consistent with significant sinus disease. The patient underwent a functional endoscopic sinus surgery and a small amount of fungal material from the lateral aspect of her sphenoid sinus was removed. Of interest, she had no history of rhinosinusitis symptoms.

Summary of Results Pathology results revealed inflamed nasal mucosa, allergic mucin, and eosinophils. Silver stain suggested the presence of fungal hyphae within the mucus and showed no invasion of tissue. The patient's vision improved after surgery and was ultimately discharged home on high dose steroids.

Conclusions Isolated vision loss with no associated signs and symptoms of sinus disease is a peculiar presentation of allergic fungal sinusitis. This case emphasizes the importance of early recognition of complicated sinus disease and prompt treatment to avoid complications.

70 VARIABILITY OF PRIMARY IMMUNODEFICIENCY AND PROGRESSION TO CVID: A CASE REPORT

A Dixon, T Hwangpo, HW Schroeder. *University of Alabama at Birmingham, Birmingham, AL.*

10.1136/jim-2016-000393.70

Purpose of Study Common variable immunodeficiency (CVID) is the most common symptomatic primary antibody deficiency. Patients may present with mild symptoms to recurrent sinopulmonary infections, as well as autoimmune phenomena. Many patients who present with unexplained recurrent sinopulmonary infections demonstrate a spectrum of antibody deficits that do not fit cleanly within the strict ESID definition of CVID. We describe a patient followed for 15 years who displays a wide range of antibody deficits, infections, pulmonary function deficits, and B cell numbers over time who ultimately met the criteria for CVID and demonstrates the need for long term surveillance in susceptible individuals.

Methods Used Clinical symptoms, serum immunoglobulin levels, B cell counts, vaccination titers, and pulmonary function testing were recorded and reviewed.

Summary of Results The patient presented with one year of recurrent sinusitis and otitis media; a positive family history of autoimmune disease; and an IgG1 and IgG2 subclass deficiency. She responded to pneumococcal vaccination and was treated with prophylactic antibiotics. At six-month follow-up, her IgG1 had normalized, but her IgG2 remained depressed. Over time, she developed more frequent and severe episodes of sinusitis along with declining IgG levels. Three years after diagnosis of IgG2 subclass

deficiency, her IgA fell below normal. Two years following, her total IgG fell below 500 mg/dl, and she demonstrated a reduction in FEV1 and FEF 25%-75%. She was started on replacement gammaglobulin infusions and responded with normalization of pulmonary function. Throughout her clinical course, her IgG, IgA and B cell counts varied remarkably. However, as her total IgG level decreased, her total B cell numbers increased and the percentage of IgM and class switched memory B cells decreased. Following initiation of IVIG and concomitant with the improvement in lung function, her total B cell count fell below normal.

Conclusions The progression to and course of CVID can be quite variable. Patients with a suspected antibody deficiency can benefit from repeated monitoring for progression of their disease.

71 BULLOUS SYSTEMIC LUPUS ERYTHEMATOSUS

S Gonnalagadda,¹ V Majithia,¹ L Maher,¹ J King,² R Brodell,^{2,2} M Cosulich². ¹University Of Mississippi Medical Center, Jackson, MS; ²University of Mississippi Medical Center, Jackson, MS.

10.1136/jim-2016-000393.71

Case Report Bullous systemic lupus erythematosus (BSLE) is a rare cutaneous manifestation of systemic lupus erythematosus (SLE) characterized by vesiculobullous eruption mediated by auto-antibodies to collagen VII components. Cutaneous manifestations are seen in up to 76% of SLE patients, however, vesiculobullous lesions in less than 1%. We present a case of BSLE who was intolerant to the standard therapy and started on rituximab.

A 24 year old African American female with known history of systemic lupus erythematosus presented with a new onset intensely pruritic rash on her elbows, knees and trunk which started as bullae with associated polyarthralgia. She was noted to have a tense bulla on her right knee along with lichenified plaques with excoriations on her elbows and trunk. Biopsy of the right knee bulla revealed findings consistent with BSLE and the patient was started on dapson and tapering doses of prednisone. She was continued on hydroxychloroquine 200 mg twice daily. She could not tolerate dapson and discontinued it. Prednisone did not help her rash which progressed to multiple tense violaceous vesiculobullous lesions involving her dorsal hands, fingers, elbows, feet, knees, trunk and oral mucosa. The patient was reluctant to restart dapson at a lower dose due to her previous side effects, could not tolerate higher doses of azathioprine and had side effects with methotrexate. Due to intolerance to multiple medications, we decided to start rituximab.

BSLE has distinctive clinical and pathological features that needs to be differentiated from other forms of cutaneous lupus as well as other vesiculobullous diseases, as treatment varies. BSLE has relative resistance to steroids and immunosuppressive medications and patients typically show a dramatic improvement with dapson. We thereby conclude that BSLE can involve oral mucosa and every effort should be made to start dapson. Dapson remains the drug of choice for BSLE and resistant cases can be treated with rituximab per anecdotal data. Rituximab, a B-cell depleting agent likely reduces circulating

anti-collagen VII antibodies, the underlying pathophysiology in BSLE.

72 THE COMPLEXITY OF NEUROPSYCHIATRIC SYSTEMIC LUPUS ERYTHEMATOSUS

T Heavener, S Seago. *Texas A&M - Scott and White Hospital, Temple, TX.*

10.1136/jim-2016-000393.72

Introduction Systemic lupus erythematosus (SLE) is an autoimmune condition that may affect any organ system giving a multifactorial clinical presentation. There are 11 criteria for diagnosis of SLE. One criterion is the presence of neuropsychiatric (NP) disorders; normally, they present as headache and mood disorders, but they may also present in the peripheral nervous system as neuropathy and in the central nervous system as aseptic meningitis, seizures, psychosis, and/or cerebral vascular disease. The clinical manifestations of SLE are thought to have multifactorial causes such as immune complexes, autoantibodies, autoreactive lymphocytes, and vascular compromise. Diagnosing NP SLE is done by excluding the presence of alternative disease processes. We present a case of NP lupus in the setting of multiple medical co-morbidities to illustrate the complexity of making a timely diagnosis and treatment plan for this disease.

Discussion A twenty-three-year-old female with medical history of childhood seizures, SLE, end stage renal disease, and depression presented with altered mental status and agitation after missing two sessions of hemodialysis. On arrival, she was alert and oriented only to self, and she would cry out and moan if touched. Initial lab testing was remarkable for blood urea nitrogen 50 mg/dl and creatinine 17 mg/dl. Her initial mental status failed to improve following hemodialysis. Magnetic resonance imaging of brain, electroencephalogram, and lumbar puncture were all obtained with nonspecific findings. She was started on vancomycin, ceftriaxone and acyclovir. Unfortunately, her clinical status continued to decline, eventually leading to seizures. Given her history of SLE and failure to improve, rheumatology was consulted on hospital day 12, and she was started on high dose methylprednisolone 1 mg/kg daily for three days followed by a five day course of plasmapheresis and a prolonged oral prednisone taper with interval improvement in her mental status.

Conclusion This case provides an excellent example of the difficulty of diagnosing and treating NP SLE, as differentials included electrolytes, renal, primary psychiatric, infection, primary seizure. However, only following treatment for NP SLE did the patient markedly improve.

73 IMPACT OF DIAGNOSIS AGE ON QUALITY OF LIFE AMONG PATIENTS WITH SYSTEMIC LUPUS ERYTHEMATOSUS

C Kearse, J Oates, G Gilkeson, D Kamen. *Medical University of South Carolina, Charleston, SC.*

10.1136/jim-2016-000393.73

Purpose of Study Systemic lupus erythematosus (SLE) is a chronic autoimmune disorder disproportionately affecting minority women of child-bearing age. However, 15–20%

of all patients with SLE are diagnosed as children. This study compares the health-related quality of life (HRQOL) in childhood-onset SLE (cSLE) to HRQOL in adult-onset SLE (aSLE).

Methods Used Data was collected as part of an ongoing SLE longitudinal registry at MUSC, including demographics, clinical disease manifestations and patient-reported responses to the Short Form-36 (SF-36) v2 questionnaire. For this study, two SF-36 questionnaires were analyzed from each patient. Scores were analyzed across eight physical and mental health domains including physical functioning, role physical, bodily pain, social functioning, mental health, role emotional, vitality, and general health. SF-36 scores were then compared between cSLE patients, defined as diagnosed prior to age 18 years, and aSLE patients.

Summary of Results aSLE patient (n=323) and cSLE patients (n=9) were similar in racial (68.4% black) and gender (94.0% female) distribution. Mean normalized scores for all eight of the SF-36 domains were higher for cSLE patients compared to aSLE patients, with statistical significance found in two domains: physical functioning (52.1±6.1 cSLE vs 38.8±12.4 aSLE, p=0.0016) and role physical (50.1±7.1 cSLE vs 38.6±12.5 aSLE, p=0.0067). We did not find significant differences in SF-36 scores based on race, gender or disease-specific manifestations such as renal disease.

Conclusions These findings suggest that having been diagnosed at an earlier age and having lived most of their life with a systemic autoimmune disease may contribute to the higher health-related quality of life reported by patients with cSLE. Of interest, the contrast between cSLE and aSLE patient scores was greatest within the physical functioning and role physical domains despite the limited sample size of cSLE patients with completed questionnaires.

74 FAMILIAL MEDITERRANEAN FEVER: A TREATMENT DILEMMA

ME Lindsey, V Majithia, A Nicholson. *University of Mississippi, Jackson, MS.*

10.1136/jim-2016-000393.74

Case Report Familial Mediterranean Fever is a rare autosomal recessive disease characterized by periodic fevers and episodes of serositis. Typical attacks last 1–4 days and are separated by asymptomatic periods. Clinical diagnosis is made based on a combination of major and minor criteria, and standard treatment is with colchicine. Goal of treatment is to prevent both disease flares and development of secondary amyloidosis, which is a major cause of mortality in these patients.

A 36-year-old Caucasian male presented to the rheumatology clinic for management of Familial Mediterranean Fever. He had a history of recurrent illnesses that began around age two, which included 1–2 episodes per year of fever, dyspnea, and chest discomfort, several episodes of lymphadenopathy with splenomegaly, and recurrent outbreaks of erythematous skin lesions. Multiple evaluations yielded no diagnosis, and these events stopped prior to age twenty-five. In his early thirties he developed episodes of fever and rash again, now associated with extreme

abdominal pain. This led to multiple emergency department visits, use of several abdominal imaging modalities, and an exploratory laparotomy, none of which provided a clear answer to his discomfort. He was referred to Mayo Clinic, where a clinical diagnosis of Familial Mediterranean Fever was made and supported with the finding of an MEFV gene mutation. He was started on colchicine and referred to our clinic for chronic management. Unfortunately, the patient has been unable to tolerate colchicine, even at a lower dose and frequency. He developed significant arthralgias and a pruritic rash that resolved only with discontinuation of colchicine. The ultimate concern is that amyloidosis may develop if appropriate therapy cannot be determined. We are now looking into alternative treatments such as the interleukin-1 receptor antagonist anakinra.

While the case above illustrates a prime example of a difficult clinical diagnosis, the true dilemma now lies in determining how to prevent progression of disease and decrease overall mortality. Colchicine is a well-established, safe, and effective therapy for patients with Familial Mediterranean Fever, but studies are limited in regards to long term safety and efficacy of alternative treatment options.

75 SCLERODERMA IN THE SETTING OF METHAMPHETAMINE ABUSE: CONNECTION OR COINCIDENCE?

ME Lindsey, V Majithia. *University of Mississippi, Jackson, MS.*

10.1136/jim-2016-000393.75

Case Report Systemic sclerosis is characterized by multi-organ fibrosis and vascular dysfunction, and a hallmark feature is the presence of scleroderma, which is a term for skin that is indurated and thickened. Systemic sclerosis is categorized as limited or diffuse based on the extent of cutaneous involvement either distal or proximal to the metacarpophalangeal or metatarsophalangeal joints respectively. Scleroderma-like skin changes may be present in a variety of conditions or exposures.

A 42 year old Caucasian female with a past medical history of hypertension and methamphetamine abuse presented with dyspnea and swelling to her upper extremities. These symptoms had been worsening for several months without chest pain, hemoptysis, or fever. Evaluation revealed uncontrolled hypertension with end-organ damage manifested as transient acute kidney injury and left ventricular systolic dysfunction with RVSP of 40, deemed to be the cause of her dyspnea. Physical exam was remarkable for nonpitting edema and scleroderma to her bilateral upper extremities extending from her fingertips to her shoulders. These changes were also on her upper thighs; no abnormalities were seen below her knees. Skin exam revealed no digital ulcers or telangiectasias and grossly normal-appearing nailbeds. Range of motion was restricted to the elbows, wrists, and small joints of the fingers, and these areas had severe flexion contractures. Patient denied a history of Raynaud's phenomenon, but she did admit to chronic acid reflux. Lab evaluation yielded negative autoantibodies. Urine drug screen was positive for methamphetamine, and patient did admit to use. Patient is

currently scheduled for skin biopsy. It is however felt that she has diffuse cutaneous systemic sclerosis with atypical features of negative ANA and a lack of Raynaud's, nailfold abnormalities, or internal organ involvement.

The pathogenesis of systemic sclerosis remains unclear, but it is felt to involve a complex combination of vascular damage and immune activation. These events may be triggered by environmental exposures, including illicit drugs. The case above illustrates an example of atypical systemic sclerosis that raises the question of whether or not the patient's methamphetamine exposure contributed to its onset.

76 DELAYED DIAGNOSIS: A CASE OF GRANULOMATOSIS WITH POLYANGIITIS

S McElroy, S Travis. *University of Oklahoma Health Sciences Center, Oklahoma City, OK.*

10.1136/jim-2016-000393.76

Case Report A 17 year old female presented with hemoptysis, abdominal pain, and possible lung abscess. She had left upper quadrant pain for 2 days, exacerbated by breathing and coughing. An abdominal CT showed a mass in the left lung. She had a recent history of recurrent cold symptoms, ear infections, and several courses of antibiotics and steroids over the last 4 months. Cough for three months had progressed to being almost constant and she had hemoptysis two days prior to admission. She had weight loss, night sweats and fever, but no known risk factors for TB infection. Two months prior, she had nasal biopsies and blood work performed. ANCA testing at that time was negative. Three weeks before admission she had surgery on her sinuses. Histopathology showed no formed granulomas but revealed geographic necrosis associated with neutrophils and giant cells.

Chest CT showed a large cavitary mass with internal gas in the left lung. TB and fungal studies were negative. Atypical c-ANCA was positive at 1:20. ANA screen and p-ANCA were negative. Proteinase-3 (PR-3) was negative on IF staining. Lung biopsy was felt to be consistent with Granulomatosis with Polyangiitis (GPA). Treatment was initiated with rituximab, methylprednisolone and weekly methotrexate.

Discussion This case demonstrates the difficulty in diagnosing GPA in children, especially when the presenting symptoms are ENT and often nonspecific. In the limited form of GPA lacking renal findings, diagnosis can be delayed by months. This patient was diagnosed with sinus infections, given multiple antibiotics and oral steroids until developing more severe symptoms. Even the upper airway biopsy, done early on in this patient, is not always diagnostic due to significant necrosis and scar tissue. c-ANCA, although not tested extensively in the pediatric population, is positive in a majority of GPA cases. In c-ANCA positive patients, EIA IF staining is almost always positive for PR-3. In limited disease, c-ANCA and PR-3 may be negative in up to 50% of cases. This patient was positive for atypical c-ANCA but negative for PR-3. This is a rare and serious disease in the pediatric population, even in the limited form. In a previously healthy patient, especially a female adolescent, with recurrent ENT infections, GPA should be considered in the differential.

Cardiovascular

Joint Plenary Poster Session and Reception

4:30 PM

Saturday, February 11, 2017

77 MILD RENAL INSUFFICIENCY AS A PROGNOSTIC INDEX IN HEART TRANSPLANTATION

W González,¹ C García,¹ PI Altieri,^{1,2} HL Banchs,^{1,2} IF González-Cancel,² R Calderón,^{1,2} B Colón,¹ JJ Nieves,¹ N Escobales¹. ¹University of Puerto Rico, San Juan, PR; ²Cardiovascular Center of Puerto Rico and the Caribbean, San Juan, PR.

10.1136/jim-2016-000393.77

Purpose of Study Renal complications have been reported in the heart transplant population. Epidemiologic studies have previously reported an association between renal complications, including acute kidney injury, and end stage renal disease, which can lead to an increase in mortality. It has been reported that approximately 20% of patients (P) had a progressive deterioration and 13% of acute renal failure in the immediate heart transplant period.

Methods Used In view of this, we evaluated the development of renal dysfunction, including post-operative and long term phase in transplanted P. A retrospective study was done with a sample of 140 P. who were transplanted from 1999–2015, to review the possible outcomes related to renal dysfunction after heart transplant. Demographic data was recorded, as well as long-term variables related to follow up at one year of heart transplant.

Summary of Results From the study population (N=140), 72% (n=102) of P. were male, with a mean age of 46 years (46±14.7). The most common comorbidities reported were hyperlipidemia, hypertension, and diabetes mellitus.

The mean ischemic period time was 123 minutes. Most donors were males (n=111; 79%). Data compared before and after heart transplant revealed a mild increase of blood urea nitrogen (21.9± 11.5³/427.56±11.1 mg/dl), and creatinine (1.22±1.71³/42.12±7.7 mg/dl) one year after heart transplant. No acute renal failure post- transplant was observed. On follow up one year after transplantation, the grade of rejection in the graft biopsy remained in 1R.

Conclusions In view of this, renal complications should be monitor closely to avoid early deterioration of renal function which will end in chronic dialysis. Only 5 P. are in chronic dialysis.

78 METABOLIC CHANGES OBSERVED IN HISPANICS PATIENTS ONE YEAR AFTER UNDERGOING SLEEVE GASTRECTOMY SURGICAL INTERVENTION FOR WEIGHT REDUCTION

H Núñez,¹ PI Altieri,^{1,2} A Suárez,¹ HL Banchs,^{1,2} N Escobales¹. ¹University of Puerto Rico, Medical Sciences Campus, San Juan, PR; ²Cardiovascular Center of Puerto Rico and the Caribbean, San Juan, PR.

10.1136/jim-2016-000393.78

Purpose of Study The increasing prevalence of obesity is a mayor medical problem in Puerto Rico. We are reporting our results after sleeve surgery to reduce obesity and see

the metabolic changes observed after the procedure.

Methods Used A retrospective medical chart analysis of 134 Hispanic adults (89.5%) percent females, mean age at surgery 38.62 years ±9.18 who underwent sleeve gastrectomy from 2013 to 2016. Evaluated values included BMI, FBS, HDL, LDL, TC and TGs. A total of 34 cases (23.7%) that completed follow up evaluation at one year were used.

Summary of Results Statistical reduction (P value <0.05) in BMI was observed at one month and one year after surgery with a mean value of 45.97 kg/m²±7.30 kg/m² (pre-op), 40.92±6.89 kg/m² (one month), 32.14±5.96 kg/m² (one year). Significant statistical differences (P value <0.05) were found in reduction of FBS means of 101.1±23.44 mg/dl (pre-op), 91.09±13.07 mg/dl (one month), 87.21±15.05 mg/dl (one year), elevation in HDL mean values 41.94±9.52 mg/dl (pre-op), 38.20±7.87 mg/dl (one month), 51.63±10.06 mg/dl (one year). No statistical significant reduction or elevation was found on TC, LDL, TGs.

Conclusions Sleeve gastrectomy surgery results in a significant BMI reduction and FBS one year after intervention and elevation of HDL.

79 BROKEN HEART SYNDROME IN A PATIENT ON MAINTENANCE HEMODIALYSIS

S Bhogal, ES Josan, V Ladia, P Sitwala, T Paul. East Tennessee State University, Johnson City, TN.

10.1136/jim-2016-000393.79

Case Report 75 year old female presented to our hospital with chest pressure that started during her maintenance hemodialysis (HD) session. She had past medical history of end stage renal disease (ESRD) and was on HD since last

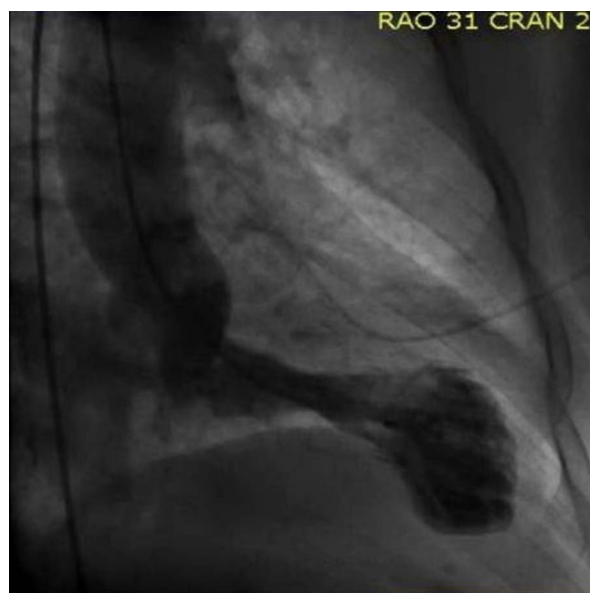

Figure 1- Ventriculogram demonstrating akinesis of apical left ventricular wall consistent with takotsubo cardiomyopathy.

Abstract 79 Figure 1

five years. She reported recent hospitalization of her husband for an acute illness. Electrocardiogram showed ST elevation and T wave inversion in V3-V6 leads. Troponin levels were found to be elevated 8.06 ng/ml. Emergent left heart catheterization was done that showed normal coronaries and ventriculogram revealed akinesis of apical left ventricular wall consistent with takotsubo cardiomyopathy (TC) (figure 1).

TC or broken heart syndrome is characterized by transient left ventricular apical ballooning that mimics acute coronary syndrome but without any angiographic evidence of coronary artery disease. It is generally seen in postmenopausal women. It has been speculated that inappropriate catecholamine release in relation to emotional stress may be underlying pathological factor. Sustained activity of sympathetic nervous system has been exhibited in patients with ESRD on HD. These patient suffers from significant psychological illness. So far, only eight cases of TC are present in the literature. Interestingly, more than half of these patients 5/9 (55.5%) didn't have chest pain.

Conclusion TC may be an underdiagnosed entity in patients on HD. However, it is should be considered in differential diagnosis in patients on HD particularly who presents with chest pain.

80 AN UNUSUAL CASE OF INTRAMURAL HEMATOMA FOLLOWING PERCUTANEOUS CORONARY INTERVENTION

S Bhogal,¹ HB Panchal,¹ D Merrick,² T Paul¹. ¹East Tennessee State University, Johnson City, TN; ²Mountain State Health Alliance, Johnson city, TN.

10.1136/jim-2016-000393.80

Case Report 77 year old male presented to our hospital with chest pain. He was discharged 16 days back after undergoing percutaneous coronary intervention (PCI) on dual antiplatelet therapy and warfarin for atrial fibrillation. 11 days after PCI he presented with chest pain. Computed tomography angiogram (CTA) of chest and abdomen revealed intramural hematoma extending into abdominal aorta. He opted for medical management. 5 days after discharge, he presented again with worsening chest pain. His international normalized ratio was 1.5. CTA showed expansion of intramural hematoma with diameter of 1.4 cm (figure 1). He was started on esmolol. Warfarin was discontinued. Emergent endovascular repair of thoracic aorta was performed.

Aortic Intramural Hematoma (IMH) is an exceedingly uncommon but catastrophic illness with similar presentation to aortic dissection. Incidence is estimated to be 6.7% post-PCI based. The common site of dissection is the junction of thinnest plaque and adjacent normal aortic wall which is a high pressure region. It occurs as a result of bleeding into aortic media without intimal tear. The course of IMH is highly variable with either resolution or expansion to an overt aneurysm or dissection. The presentation includes chest or back pain. CTA demonstrate IMH as hyperdense layer in acute stages. Type A IMH is generally treated with surgery and type B IMH with medical management.

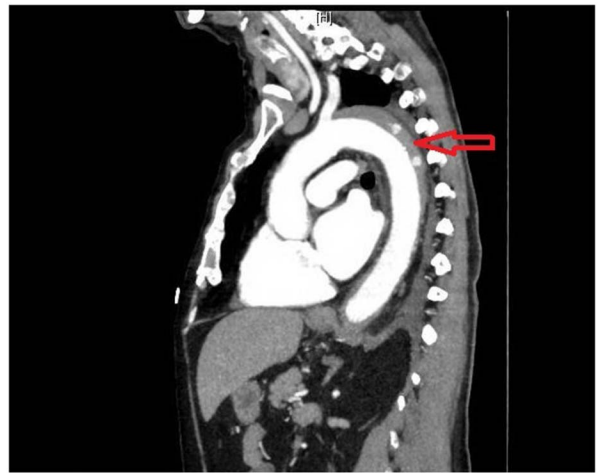

Figure 3- Coronal section of CT abdomen showing intramural hematoma (arrow).

Abstract 80 Figure 1

Conclusion We propose that IMH should be considered in differentials in patients presenting with chest pain after PCI.

81 PATIENTS WITH BICUSPID AORTIC VALVE WITH AORTIC STENOSIS OR INSUFFICIENCY DEVELOP AORTOPATHY MORE RAPIDLY THAN PATIENTS WITH COMPETENT NON-STENOTIC VALVES

A Gupta,¹ M Brown,² R Parker,² W Lutin,¹ H Wiles¹. ¹Children's Hospital of Georgia at Augusta University, Augusta, GA; ²Medical College of Georgia, Augusta, GA.

10.1136/jim-2016-000393.81

Purpose of Study Bicuspid aortic valve (BAV) is one of the most common congenital heart defects, present in 0.5–2% of the population. It can lead to aortopathy (dilated aorta), which can further lead to serious complications, such as aortic dissection, which BAV is an independent risk factor. In this study, we attempted to determine which anatomic and physiological variables associated with the presence of BAV lead to aortopathy most rapidly.

Methods Used A retrospective, longitudinal study was done in 116 patients, from 2009–2016 (total: 376 echocardiograms). We measured echocardiographic parameters of each patient, using each as his/her own control. All patients with BAV, plus or minus accompanying coarctation were included, while patients with complex heart defects that affected hemodynamics of the left ventricular outflow tract were excluded. Echocardiographic images were examined to determine the dimensional and hemodynamic characteristics of the aortic valve and presence/degree of aortopathy. **Summary of Results** Partial correlation demonstrated that the severity of aortic insufficiency (AI) was positively correlated over time with the aortic valve annulus z score up to 4 years past baseline. The severity was not significantly correlated over time with the ascending aorta maximum z-score. Regression analyses demonstrated a statistically significant positive correlation between the quantitative evaluation of AI with the ascending aorta maximum z-score at

baseline, while the qualitative evaluation of AI did not have a significant correlation. Neither peak nor mean gradient positively correlated with the ascending aorta maximum z-score at baseline.

Conclusions There is an unclear relationship between the hemodynamics of BAV and the echocardiographic aortic diameters. Additional studies are warranted to further assess the relationship between these parameters and the development of aortopathy over time in pediatric patients with BAV.

82 ELECTROCARDIOGRAPHIC LVH, QTc PROLONGATION AND VENTRICULAR ARRHYTHMIAS

BZ Heard, DM Flatt, R Bomb, MR Heckle, P Valasareddy, KT Weber.
University of Tennessee Health Science Center, Memphis, TN.

10.1136/jim-2016-000393.82

Purpose of Study QTc prolongation with delayed repolarization of myocytes and is a known risk factor for ventricular arrhythmias (VA). Underlying heart disease, such as LVH, may impede electrical impulse propagation to impose a risk for VA. We previously hypothesized QTc prolongation with LVH would be predictive of VA. Two groups were compared: patients with LVH by ECG versus patients having both LVH and QTc prolongation. Results showed an increased incidence of VA in patients with both LVH and QTc prolongation versus LVH alone. However, the incidence of VA was not analyzed. Herein, we *hypothesized* QTc prolongation with LVH would be more predictive of VA as compared to QTc prolongation or LVH alone. Additionally, we explored relationships between groups with presence or absence of QTc prolongation and LVH with respect to VA.

Methods Used A retrospective chart review of 3186 patients with standard 12-lead ECG at an urban medical center from Jan 1, 2014 to June 30, 2015 was performed. Presence of LVH was assessed by ECG and included the presence or absence of premature ventricular contractions. QTc prolongation was defined as QTc interval >450 ms. During assessment of QTc prolongation, entries of patients with QTc prolonging medications were excluded.

Summary of Results Data was sorted based on the four groups: neither LVH nor QTc prolongation; LVH without QTc Prolongation; QTc prolongation without LVH; and LVH with QTc prolongation. QTc prolongation without LVH had the highest incidence of VA (10.2%) and was followed by LVH with QTc prolongation (6.2%). Pearson chi squared analysis revealed significant difference in VA across the groups.

Conclusions The increased incidence of VA with LVH and QTc prolongation as compared to LVH and QTc prolongation groups alone did not have the compounding affect as expected. QTc prolongation alone is most predicative of VA. As QTc prolongation can be manipulated, it should be corrected when possible through electrolyte correction and avoidance of QTc prolonging medications.

83 EFFECTS OF METHADONE ON QT INTERVALS IN PEDIATRIC PATIENTS – A RETROSPECTIVE REVIEW

S Henson, A Shah. *University of Oklahoma, Oklahoma City, OK.*

10.1136/jim-2016-000393.83

Purpose of Study Prolonged QT interval (QTc) secondary to methadone treatment is well documented in adult populations. There are clinical guidelines for monitoring adult patients on methadone treatment including before, during, and after treatment electrocardiograms (ECGs). Methadone treatment is used frequently in pediatric populations for indications such as pain, post-ICU sedation tapers, and opioid withdrawal. Although methadone use in pediatric patients is not uncommon, it is typically used in substantially smaller doses than in adult patients. As such the risk of QT prolongation in pediatric patients on methadone remains unclear.

The goal of our study is to better define the effects of methadone on pediatric QT intervals and identify whether a significant QT effect is present with typical dosing in pediatric patients.

Methods Used A retrospective review of pediatric patients on methadone therapy. Patients under the age of 18 years who were on methadone over the past 3 years were analyzed using retrospective case control design. ECGs on and off methadone therapy were extracted and QTc manually measured. Measurements on and off therapy were then compared.

Summary of Results Of 307 patients that were on methadone, 56 patients had ECGs while on methadone therapy. The QTc of the ECG done on methadone therapy, or mean QTc on therapy for those patients who had multiple ECGs while on therapy, were compared to their mean QTc on ECGs either before therapy or after being off therapy for more than 2 weeks. In the overall cohort, the average QTc was well within the normal range at 422–424 for both on therapy and off therapy groups. When compared in case control fashion the mean difference for individuals when on therapy versus off therapy was 2 msec which was not a significant difference (p 0.76).

Conclusions Methadone therapy in pediatric patients at our institution in typical pediatric dosing ranges does not appear to have any significant effect on the QT interval. This suggests that current standards of methadone use in pediatrics are unlikely to place patients at significant QT prolongation risk. However, our study is limited by its retrospective design and small proportion of overall patients on methadone who received ECG surveillance.

84 QTc INTERVAL IN PATIENTS WITH HEART FAILURE WITH REDUCED EJECTION FRACTION VS. HEART FAILURE WITH PRESERVED EJECTION FRACTION

LA John, EA Christian, YI Harper, DM Flatt, MR Heckle, BZ Heard, JB Jasper, BM Ramos, KT Weber. *University of Tennessee Health Science Center, Memphis, TN.*

10.1136/jim-2016-000393.84

Purpose of Study The QTc interval of the electrocardiogram represents the duration of ventricular repolarization.

Hypokalemia and hypomagnesemia are associated with prolonged QTc. Patients having heart failure with reduced ejection fraction (HFrEF) are often on loop diuretic therapy, which is associated with potassium and magnesium wasting. They therefore may have a propensity to QTc prolongation. We therefore compared the QTc interval in patients with echocardiographic HFrEF (<40%) versus heart failure with preserved ejection fraction (HFpEF).

Methods Used A retrospective chart review of 3310 patients from an inner-city hospital in an urban setting was performed. From this sample, 24 patients with HFrEF were compared to those (n=31) with HFpEF. The average QTc in both groups was compared.

Summary of Results Patients with HFpEF had a QTc of 466 ± 8 msec whereas patients with HFrEF had an average QTc of 451 ± 13 msec. Patients with HFpEF demonstrated a non-statistically significant prolonged QTc interval when compared to patients with HFrEF ($p=0.32$).

Conclusions Our findings demonstrate that the QTc interval tended to be more prolonged in patients with HFpEF as compared to patients with HFrEF. Based on these results, we need to increase our sample size to increase the power of our study to address this question more fully.

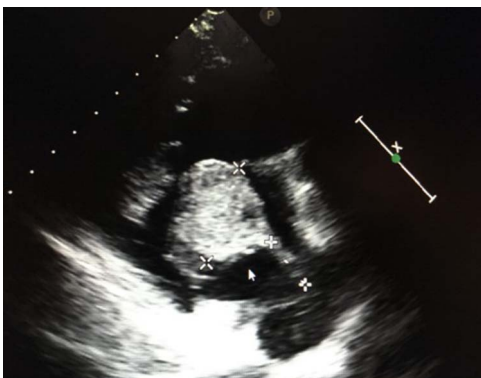85 IN-TRANSIT RIGHT HEART THROMBUS: A SIGN OF IMPENDING DOOM

M Jbara,¹ G Murtaza,¹ N Bentley,² SM Zaidi,¹ T Paul.² ¹East Tennessee state University, Johnson City, TN; ²East Tennessee State University, Johnson City, TN.

10.1136/jim-2016-000393.85

Case Report A 57 year old male with metastatic urothelial cancer was admitted with dyspnea, respiratory distress. He had h/o pulmonary embolism and DVT and was switched from lovenox to Xarelto 3 weeks before admission. Echocardiogram showed thrombus in right atrium extending from IVC (fig 1,2). Thrombolysis was attempted, however, patient suffered a cardiopulmonary arrest and wasn't able to be resuscitated.

Right heart in transit thrombus is a life threatening emergency and requires urgent treatment with thrombolysis or surgical embolectomy. In our patient, the presence of metastatic cancer and the h/o thromboembolism created the



Abstract 85 Figure 1

right environment for in transit thrombus to develop. High index of suspicion and early recognition is needed as delaying treatment usually results in worsening condition and death.

86 ATRIAL FIBRILLATION IN THE ELDERLY

BM Ramos, EA Christian, DM Flatt, YI Harper, MR Heckle, BZ Heard, JB Jasper, LA John, KT Weber. *University of Tennessee Health Science Center, Memphis, TN.*

10.1136/jim-2016-000393.86

Purpose of Study Atrial fibrillation (AF) is a common sustained tachyarrhythmia associated with increased cardiovascular morbidity, mortality and preventable stroke. It accounts for a third of all hospitalizations for cardiac dysrhythmias. The incidence of AF rises with advancing age. Herein, we reviewed the profiles of elderly patients diagnosed with AF to determine if certain variables were characteristic of these patients.

Methods Used A retrospective review of 120 patients with AF followed at an urban medical center from November 1, 2015 to April 30, 2016, of which 59 were >65 years of age. The following variables were analyzed: sex, electrolytes (potassium, magnesium, calcium), brain natriuretic peptide and thyroid-stimulating hormone, serum creatinine, two-dimensional echocardiogram (ejection fraction, left atrial size), and the electrocardiogram for corrected QT interval. Variables were compared with identical features in patients <65 yrs (n=61).

Summary of Results Brain natriuretic peptide and serum creatinine levels were higher in the elderly with AF in comparison to their younger counterparts; this trend, however, was not statistically significant. There was also no significant difference between the two groups for the other above-mentioned variables.

Conclusions A trend of elevated brain natriuretic peptide (BNP) and serum creatinine in the elderly is noteworthy. Although elevated BNP may be the result of decreased creatinine clearance, it may also be a marker of cardiac chamber stretch predisposing to atrial fibrillation. A larger sample size will be required to further assess AF in the elderly followed at this medical center.

87 METABOLIC CHARACTERIZATION OF CIRCULATING HUMAN ENDOTHELIAL COLONY FORMING CELLS

B Stansfield, R Tritz. *Augusta University, Augusta, GA.*

10.1136/jim-2016-000393.87

Purpose of Study The purpose of our study is to provide a metabolic fingerprint for circulating human endothelial cells, termed endothelial colony forming cells (ECFC).

Methods Used All protocols were approved by the Institutional Review Board at Augusta University. ECFC were isolated from the peripheral blood of three healthy adult subjects and pooled for study. Human umbilical vein endothelial cells (HUVEC) were purchased from ATCC. Cells were cultured and expanded in standard growth media. ECFC and HUVEC were plated at the same cell

density in a 96-well Seahorse utility plate for 24 hours and then analyzed using the Seahorse XFe96 Analyzer. For glycolysis stress test, injection ports were loaded with glucose, oligomycin, and 2-deoxyglucose. For mitochondrial stress test, injection ports were loaded with oligomycin, FCCP, and antimycin-A/Ronenone. In some experiments, ECFC and HUVEC were pre-treated with vascular endothelial growth factor (VEGF), fetal bovine serum (FBS), p21 Ras inhibitors, or glycolysis inhibitors. Standard curves were based on the analysis of 12 wells per condition.

Summary of Results ECFC are a highly proliferative and metabolically active subpopulation of endothelial cells (EC). Under basal conditions and in response to VEGF, ECFC doubling time is significantly reduced compared to HUVEC. Incubation with VEGF, FBS, or glucose dramatically increases ECFC glycolysis and glycolytic capacity as compared to HUVEC under the same conditions. Co-incubation with a p21 Ras inhibitor impairs the glycolytic capacity of ECFC and HUVEC. FBS and VEGF also increase ATP-linked and maximal energy production in the mitochondria of ECFC, but have little effect on mitochondrial reserve capacity. A similar, but diminished relationship between FBS and VEGF and mitochondrial energy production is observed in HUVEC.

Conclusions ECFC are a metabolically active subpopulation of EC, which may explain their potential to differentiate and regenerate endothelial cell populations. As ECFC number is reduced in premature neonates and negatively correlates with bronchopulmonary dysplasia severity, characterization of their metabolic profile and energy capacity is critical for understanding how these cells may participate in neonatal and pediatric pathology.

88 NEURODEVELOPMENTAL OUTCOMES OF CHILDREN WITH CONGENITAL HEART DEFECTS

A Steffens, M Peralta-Carcelen. *University of Alabama School of Medicine, Birmingham, AL.*

10.1136/jim-2016-000393.88

Purpose of Study Pediatric patients with complex congenital heart defects (CHD) that required surgical correction have an increased risk of adverse neurodevelopmental outcomes. The primary objective of this study was to explore and compare the developmental scores of a cohort of pediatric CHD patients and their associated surgical mortality risk measured by the STS-EACTS Congenital Heart Surgery Mortality Categories.

Methods Used This was a single center retrospective chart review of pediatric patients with complex CHD. In this study, children with CHD underwent developmental screening assessments at 2 and 3 years of age from 2009–2014. The primary outcome measures were the cognitive and language scores of the Bayley Scales of Infant Development (BSID), third edition, and the Differential Ability Scales-II (DAS-II). The developmental scores were compared by gestational age, STS-EACTS mortality category, and associated genetic syndromes.

Summary of Results One hundred and twenty-two patients were included. The mean birth weight was 2904 g (SD 650). The mean gestational age was 37.7 weeks (range,

27.4 to 41). Seventy percent of the patient population was insured under Medicaid; thirty percent had private insurance. Twenty-two patients had known genetic syndromes: trisomy 21 (9), velo-cardio-facial syndrome (8), Turner syndrome (3), other deletions/duplications (2). The BSID cognitive and language mean composite scores were 87 (SD 19) and 86 (SD 19), respectively. The mean composite score for DAS verbal, nonverbal, and general conceptual ability were 92, 90, and 91 (SD 15), respectively. No statistically significant difference was found between STS-EACTS mortality categories with regards to developmental scores. Patients with genetic syndromes had lower mean scores compared to patients without/with an unknown syndrome. The BSID cognitive and language mean composite scores were 77 (SD 4) and 78 (SD 4), respectively, for patients with genetic syndromes compared to 93 (SD 2) and 90 (SD 2) without syndromes. The mean composite score for DAS verbal was 81 (SD 4) and 94 (SD 3) for patients with and without genetic syndromes, respectively.

Conclusions In this cohort of children, there was no statistically significant difference in developmental scores between STS-EACTS mortality categories; however, there was lower mean scores among patients with genetic syndromes.

89 METHADONE AND QT PROLONGATION

SM Zaidi, M Al Madani, G El Khoury, O Khraisha, G Murtaza, T Paul. *East Tennessee State University, Johnson City, TN.*

10.1136/jim-2016-000393.89

Case Report We present a 56 year old female who presented to the ED with altered mental status. She required intubation for respiratory failure and received a single dose of propofol for sedation. Immediately she developed onset of a rapid, wide complex tachycardia with waxing and waning amplitude. Propofol was discontinued and the dysrhythmia resolved. Torsades de Pointes (TdP) was diagnosed and her corrected QT interval was 0.6 ms which decreased to 0.4 ms over the next few hours.

Further history obtained from the patient's brother revealed that she was a patient at a methadone clinic.

A significantly lower dose of methadone was given with recrudescence of TdP and methadone was discontinued altogether.

Withdrawal symptoms were subsequently noted and low-dose buprenorphine and later fentanyl were given, each with recrudescence of TdP. Overdrive pacing with paracental lidocaine was finally efficacious after failure of amiodarone to control the aberrant rhythm.

Ultimately the patient was diagnosed with congenital QT prolongation and discharged to a non-medical drug rehab program.

Methadone use for analgesia in palliative care patients continues to increase as it has over the past decade. Its effectiveness as an analgesic, cheap cost and the absence of tolerance to its analgesic effects remains the primary reasons for the growth in its use.

After reports of methadone associated TdP in 2002, attention has begun to focus on the QT prolongation

effects of methadone. While this QT prolongation has been demonstrated to be dose related in multiple studies, its actual incidence in clinical practice remains rare and typically is limited to patients with multiple risk factors for TdP or those receiving doses in excess of 120 mg/day.

Given that this uncommon and potentially fatal complication exists, a five step approach has been suggested by medical consensus in March of 2009 that includes, disclosure of potential QT prolongation, history and physical examination, EKG screening, risk stratification and finally continuous assessment for drug interactions.

The final decision regarding methadone should be ultimately guided by a 'common sense approach' backed up with risk to benefit analyses for each patient to reach an ethical balance between relieving suffering and doing no harm.

90 HYPERCALCEMIA AND ST SEGMENT ELEVATION

M Agarwal, YI Harper, N Jain, KT Weber. *University of Tennessee Health Science Center, Memphis, TN.*

10.1136/jim-2016-000393.90

Case Report: Purpose The most commonly described ECG abnormality seen with hypercalcemia is a shortening of the QT interval. In severe hypercalcemia, Osborn waves (J waves) may be seen in addition to ventricular irritability and ventricular fibrillation arrest in extreme cases. ST segment elevation is an infrequent association with hypercalcemia.

Case Report A 70-yr-old African-American male with history of hypertension, osteoarthritis and oropharyngeal squamous cell carcinoma was admitted after developing dizziness and syncope during an outpatient dental visit. He also reported dysphagia, weight loss, anorexia and anxiety for the last several months. He denied chest pain, nausea, diaphoresis, vomiting, abdominal, shoulder, neck or jaw pain. His initial BP was 77/55, and corrected to 110/70 after 3 L saline. Examination including cardiovascular system was normal, except a large irregular mass on the left lateral neck erupting into oropharynx with palpable axillary lymphadenopathy. ECG revealed QTc interval 388 ms with diffuse ST elevation and Osborne waves in leads V4-V6. Initial laboratory test, including chest imaging and troponins, and a basic metabolic panel were unrevealing other than a serum calcium of 13.0 mg/dL. A transthoracic echocardiogram showed hyperdynamic LV function with a trace pericardial effusion. Based on his symptoms, clinical presentation and lab results, the ST segment changes its pathophysiologic origin were attributed to malignancy associated hypercalcemia and managed with fluids, zoledronic acid and calcitonin. Over the next 2 days, his clinical symptoms improved and calcium levels normalized with a significant flattening of the ST segment on follow-up ECG. During the patient's subsequent admissions, ST segments elevation was again noted and in keeping with his hypercalcemia.

Conclusions ST elevation associated with hypercalcemia is uncommon, but should be considered in the differential diagnosis of ST segment elevation not associated with myocardial infarction.

91 A RARE CASE OF COXSACKIE A MYOCARDITIS

K Akhtar, A Zayac, T Szombathy. *SUNY Upstate Medical University, Syracuse, NY.*

10.1136/jim-2016-000393.91

Case Report Coxsackie virus is a known cause of disease in children as well as adults. Typically, Coxsackie A virus affects mucus membranes and skin while Coxsackie B causes myocarditis or pericarditis. We present a case of a young man admitted to our cardiac care unit, with persistent fever, leukocytosis and shock, found to be asplenic, developing non-ischemic cardiomyopathy with cardiogenic shock from a remote Coxsackie A24 viral infection.

This is a 29 year old male with past medical history significant for hypertension, thoracic aortic dissection status post stent placement, who presented as a transfer for new-onset cardiomyopathy and evaluation for cardiac catheterization. He initially presented after failing outpatient treatment found an upper respiratory infection with Levofloxacin; he developed acute hypoxic respiratory failure and was emergently intubated. He was started on broad spectrum antibiotic therapy following blood, sputum and urine cultures. A chest x-ray showed pulmonary edema with an elevated proBNP; a transthoracic echocardiogram ultimately showed an LVEF of 35% and global hypokinesis, prompting transfer for catheterization. He required initial pressor support due to shock with leukocytosis of 21.54 and lactic acidosis of 6.5. Cardiac catheterization revealed elevated LVEDP without evidence of ischemia. His cardiomyopathy was thought to be of infectious in nature; testing for Brucella, Echovirus, Q fever, EBV, Anaplasmosis, were negative, except for a positive IgG for Coxsackie A24. Despite broad spectrum antibiotic therapy, he remained febrile with a high temperature of 38.9 C and persistent leucocytosis of 23. He was switched to Doxycycline without improvement. Venous extremity dopplers revealed an acute LLE DVT managed with a heparin infusion. Despite adequate anticoagulation, the patient's clinical picture did not improve. He underwent imaging including CT Thorax, Abdomen Pelvis, which were unrevealing of a source for his sepsis, but showed asplenia. Hematology was consulted for persistent leukocytosis and fevers due to concern for malignancy. A peripheral smear revealed Howell Jowell bodies and thrombocytosis attributed to his asplenia.

Viral myocarditis is a common cause of dilated cardiomyopathy. While Coxsackie virus B3 is the major etiologic agent of this disease, Coxsackie virus A less commonly associated with it.

92 AN UNCOMMON CAUSE OF SYNCOPE IN A YOUNG FEMALE

E Bueno, K Rizg, J Ruiz, M Cisneros. *University of Florida College of Medicine, Jacksonville, FL.*

10.1136/jim-2016-000393.92

Case Report In young adults and the elderly presenting with syncope in the setting of a systolic cardiac murmur the most likely causes include Hypertrophic Obstructive

Cardiomyopathy (HOCM) and Aortic Stenosis (AS), respectively. Nevertheless subvalvular aortic stenosis (SAS), a rare pathologic entity, can mimic both HOCM and AS. Subvalvular aortic stenosis is the second-most common form of fixed left ventricular outflow obstruction (LVOTO), compromising 8–20% of all forms of LVOTO. SAS is almost exclusively reported in pediatric patients as it is associated with significant congenital heart defects, such as septal defects, Shone complex, and coarctation of the aorta; and it has rapid hemodynamic progression in children. In spite of this, there have been a handful of case reports of SAS in young adults and the elderly.

Our case is of a 33 year old female who was experiencing recurrent episodes of syncope, in addition to intermittent chest pains and exertional dyspnea who had self-reported history of cardiac murmur when she was younger. On physical exam she had a 3/6 systolic murmur and mildly delayed and prolonged carotid upstroke. Transthoracic echocardiogram (TTE) displayed a LVOT gradient of 40 mmHg with marked flow acceleration in LVOT (Left Ventricular Outflow Tract), suggestive of subaortic membrane. To better visualize the SAS not visualized on TTE, a transesophageal echocardiogram measured a 15 mm LVOT, as well as a thin membrane 1.6 cm proximal to the aortic valve. Cardiac catheterization further demonstrated an increased LVOT gradient from 20 mmHg at rest, to 50 mmHg with administration of dobutamine. Our patient had resection of her subaortic membrane with excellent results. A postoperative TTE showed a decrease in the LVOT gradients at rest, and with stress, with a significant improvement in her symptoms.

The purpose of this case presentation is to present an adult case of subvalvular aortic stenosis, and to emphasize that in the presence of clinical findings, SAS should be considered a possible etiology, among the more common causes of syncope.

93 BALANCED ISCHEMIA OR NO ISCHEMIA: ROLE OF FRACTIONAL FLOW RESERVE IN THE SETTING OF EXTENSIVE CORONARY COLLATERALIZATION AND A NORMAL MYOCARDIAL PERFUSION SCAN

KK Chawla, N Sethi, D Chaudhuri. *SUNY Upstate Medical University, Syracuse, NY.*

10.1136/jim-2016-000393.93

Background Balanced ischemia detected on pharmacological myocardial perfusion imaging can mask underlying multi-vessel disease. Suboptimal uptake of tracer due to low perfusion gives a global reduction of detected photon counts which can be interpreted as a normal scan without perfusion abnormalities. Collateralization can result in perfusion of viable territories and can mask perfusion defects.

Case presentation A 78 YO female underwent a pharmacological stress test using Tc99 Sestamibi Lexiscan to evaluate her progressively worsening dyspnea. The scan failed to reveal any perfusion defects with a summed stress score of zero stratifying the patient as low risk. She was medically managed with optimization of her sleep apnea and COPD. Two months later, she presented with pneumonia and non-STelevation myocardial infarction thought to be caused

by supply demand ischemia. Patient underwent coronary angiography to better characterize her coronary anatomy. Severe lesions were noted in the mid left anterior descending (LAD) artery, first obtuse marginal (OM) branch of the left circumflex artery (LCX) and distal right coronary artery (RCA). Rentrop's grade III collaterals were noted from LAD to OM, LCX artery to LAD, left system to RCA. All territories showed appropriate angiographic perfusion. Given the results of normal nuclear scan, medical management of her coronary artery disease was advised. Two months later, she presented with angina and worsening shortness of breath. Echocardiogram showed acute changes including a reduced left ventricular ejection fraction of 30% and global hypokinesis. Coronary angiography was again performed and revealed unchanged anatomy. Fractional Flow Reserve (FFR) was performed and found to be below the threshold of 0.80 in all three vessels.

Discussion Our patient's normal perfusion scan was likely a result of balanced ischemia with extensive coronary collateralization masking underlying coronary disease. FFR accounts for the coronary collaterals and thus can help assess pressure gradients to guide therapy. FFR can be helpful in these difficult cases to understand the physiological significance of stenotic lesions.

94 CORONARY CAMERAL FISTULAE: A CASE SERIES

T Gilotra, K Sivagnanam, K Balbissi. *East Tennessee State University, Johnson City, TN.*

10.1136/jim-2016-000393.94

Introduction Coronary fistulae are uncommon anomalous coronary connections either directly with the cardiac chambers (coronary cameral fistulae, CCF) or the central venous structures (coronary arterio-venous fistulae). Although usually asymptomatic they can have varied presentations. We present rare cases including arrhythmias and angina possibly attributed to CCF, simultaneous left and right sided CCF (reported <5%), left ventricle (LV) terminating fistula, and fistula detected on echocardiography.

Case Presentations: Case 1 56 year old with recurrent supraventricular tachycardia (SVT). Echocardiography detected anomalous diastolic flow in the right ventricle (RV) consistent with right coronary artery (RCA) to RV fistula, possibly contributing to pulmonary artery hypertension (PAH). PAH has been related to SVT but has not been described with CCF. CCF are rarely diagnosed on echocardiography.

Case 2 63 year old with episodic chest pressure and palpitations. Angiography revealed a fistula between the 1st diagonal artery and the LV, possibly contributing to elevated LV pressure and the patient's symptoms. CCF rarely have LV termination.

Case 3 51 year old with intermittent chest pain. Nuclear perfusion imaging demonstrated anterior and inferior ischemia. Angiography detected CCF from the left anterior descending (LAD) artery to the LV. Ischemia and symptoms were presumably from coronary steal phenomenon due to reversal of blood flow from the LAD to LV.

Case 4 40 year old with atypical chest pain. Nuclear stress suggested inferior wall ischemia. Angiography revealed

CCF from the right postero-lateral artery (PLA) to LV, again possibly contributing to coronary steal phenomenon. **Case 5** 65 year old with recurrent angina. Angiography identified rare bilateral CCF involving both LAD and RCA/PLA draining into LV. CCF more commonly drain into the right heart or vessels, making this a unique presentation of LV terminating bilateral fistulae.

Clinical Significance Coronary artery fistulae are rare anomalies and usually asymptomatic. However, the cases described above reflect uncommon causes of common clinical presentations. Given the ACC/AHA Class 1 recommendation for the closure of symptomatic or large shunt fistulae, CCF should be differentially considered.

95 ACUTE RIGHT VENTRICULAR FAILURE AFTER ORTHOTOPIC LIVER TRANSPLANT REQUIRING MECHANICAL CIRCULATORY SUPPORT

R Goswami, BJ King, DM Flatt, KT Weber, RN Khouzam. *University of Tennessee Health Science Center, Memphis, TN.*

10.1136/jim-2016-000393.95

Purpose Acute pulmonary hypertension with right ventricular failure is a rare complication of postorthotopic liver transplantation. This case highlights the clinical challenge in decision making with regards to management of acute pulmonary hypertension and frank right ventricular failure in a recent liver transplant patient in whom pre-transplant left and right ventricular function were normal.

Case Report A 47-year-old female with history of cirrhosis secondary to non-alcoholic steatohepatitis had undergone liver transplantation. She presented two months later complaining of worsening ascites and dyspnea. She was compliant with immunosuppressive therapy, including tacrolimus. Routine echocardiogram showed newly detected severe right ventricular dysfunction and an estimated right ventricular systolic pressure of 75 mmHg. A ventilation:perfusion scan revealed low probability pulmonary embolism. Right heart catheterization indicated elevated pulmonary artery pressure 96/41 mmHg (mean 60 mmHg), pulmonary capillary wedge pressure 30 mmHg, and pulmonary vascular resistance 13 woods units. The patient was adequately diuresed, but was refractory to all other medical therapies and required a right ventricular circulatory support device (RP Impella), as well as intravenous sildenafil to promote pulmonary vasodilation. She expired a week later.

Conclusions Our patient presented a complex clinical picture with newly developed pulmonary hypertension and right ventricular failure of uncertain etiology after orthotopic liver transplantation. Her case raises the question of porto-pulmonary hypertension following liver transplantation vs. interstitial pneumonitis and endothelial dysfunction due to tacrolimus therapy as responsible for her new onset pulmonary hypertension.

96 A CASE OF HEMODYNAMIC COMPROMISE DUE TO TENSE ASCITES AND RIGHT ATRIAL COLLAPSE

MR Heckle, R Goswami, M Nayyar, AE Urban, TD Woods. *University of Tennessee Health Science Center, Memphis, TN.*

10.1136/jim-2016-000393.96

Purpose Although hemodynamic compromise can result from tamponade physiology in pericardial effusion, extrinsic compression of any cardiac chamber from fluid or mass can also result in reduced cardiac filling. Herein, we describe a patient with a moderate size pericardial effusion with no clear 2D or Doppler findings of tamponade, but was also found to have tense ascites and resultant hemodynamically significant extrinsic compression of the right atrium. We present this case to highlight the utility of serial echocardiography as an adjunct to diagnosis and differentiation of hypotension in the critically ill patient.

Case Report A 40-year-old male with a history of hypertension was transferred for evaluation of liver transplantation for his cirrhosis secondary to non-alcoholic steatohepatitis. On initial evaluation, the patient had encephalopathy, hypotension and tense ascites. Bedside transthoracic echocardiogram revealed a moderate size pericardial effusion, but no clear 2D or Doppler findings to suggest tamponade. Severe extrinsic compression of the right atrium was noted, and thought to result in limitation of right heart filling. Despite paracentesis, intravenous fluid administration and albumin, the patient's clinical status continued to decline. Serial echocardiography revealed a left ventricle that appeared hyperdynamic with new appearance of mitral systolic anterior motion and dynamic outflow tract gradient, with no change in size of the pericardial effusion.

Conclusions Comprehensive evaluation of all available data in this case highlights the importance of clinical evaluation in conjunction with serial echocardiography in hemodynamically unstable patients. In this case, no clear data for the presence of tamponade was found. When making the diagnosis of tamponade right ventricular diastolic collapse is more sensitive and specific when compared to right atrial early systolic collapse or mitral valve inflow velocity respiratory variation. Herein, we describe an unusual presentation of shock with two etiologies dependent upon reduced RV filling due to tense ascites followed by dynamic outflow tract obstruction of the left ventricle.

97 POTENTIAL OF A PHARMACOGENETIC-GUIDED ALGORITHM TO PREDICT OPTIMAL WARFARIN DOSING IN A HIGH-RISK HISPANIC PATIENT: ROLE OF A NOVEL NQO1*2 POLYMORPHISM

DF Hernandez-Suarez, JE Mirabal-Arroyo, K Claudio, BA Torres, A Lopez-Candales, J Duconge. *University of Puerto Rico School of Medicine, Carolina, PR.*

10.1136/jim-2016-000393.97

Case Report Deep abdominal vein thrombosis (DAVT) is extremely rare among thrombotic events secondary to the use of contraceptives. A case to illustrate the clinical utility of ethno-specific pharmacogenetic testing in warfarin management of a Hispanic patient is reported. A 37 year-old Hispanic Puerto Rican, non-gravid female with past medical history of abnormal uterine bleeding on hormonal contraceptive therapy was evaluated for abdominal pain. Physical exam was remarkable for unspicific diffuse abdominal tenderness and general initial laboratory results -including coagulation parameters- were unremarkable. A

contrast-enhanced computed tomography showed a massive thrombosis of the main portal, splenic and superior mesenteric veins. Upon admission patient was started on oral anticoagulation therapy with warfarin at 10 mg/day and low molecular weight heparin. The prediction of an effective warfarin dose of 7.5 mg/day, estimated by using a recently developed pharmacogenetic-guided algorithm for Caribbean Hispanics, coincided with the actual patient's warfarin dose to reach the INR target. We speculate that the slow rise in patient's INRs observed upon the initiation of warfarin therapy, the resulting high risk for thromboembolic events and the required warfarin dose of 7.5 mg/day, are attributable in some part to the presence of the *NQO1**2 (g.559C>T, p.P187S) polymorphism, which seems to be significantly associated with resistance to warfarin in Hispanics. By adding genotyping results of this novel variant, the predictive model can inform clinicians better about the optimal warfarin dose in Caribbean Hispanics. The results highlight the potential for pharmacogenetic testing of warfarin to improve patient care.

98 ISOLATED LEFT SUBCLAVIAN ARTERY FROM THE PULMONARY ARTERY MASKED BY PULMONARY HYPERTENSION

DH McVadon. *University of Mississippi Medical Center, Ridgeland, MS.*

10.1136/jim-2016-000393.98

Case Report The patient is an 8 mo female with Trisomy 21, large VSD, suspected patent ductus arteriosus (PDA), and PHTN. She never exhibited signs of over circulation and was managed medically after birth on daily Lasix 1 mg/kg. Echocardiogram continued to show what appeared to be a 3 mm PDA with bidirectional flow, moderate-to-large VSD, and severe right ventricular hypertension. Radial, femoral, and dorsalis pedis pulses were 2+ and equal bilaterally with brisk capillary refill and no cyanosis or pallor. Four extremity blood pressures had no significant difference. She was referred her for catheterization to aid in operative planning, to perform vasodilator testing and occlude the suspected PDA. Her hemodynamics were notable for a pulmonary vascular resistance (PVR) of 8 indexed Wood units (iWU) which was slightly responsive to pulmonary vasodilators, decreasing to 5 iWU when respiring both nitric oxide and 100% oxygen. Initial aortic arch angiography failed to demonstrate a PDA. In addition, her left subclavian artery (LSCA) did not opacify. There was also no evidence of a ductal ampulla or LSCA stump. Injection in the left common carotid artery demonstrated a small amount of retrograde flow down the left vertebral artery, however the contrast was briskly washed away suggesting antegrade flow in the LSCA. A pulmonary artery angiogram demonstrated a left ISCAPO. A focused repeat echocardiogram confirmed the left ISCAPO with no true PDA. 4-extremity pulse-oximetry measured a left arm saturation of 82% vs. 94–96% in all other limbs. She subsequently underwent operation to close the VSD and reimplant the LSCA into the base of the left common carotid artery. She recovered appropriately, with oxygen and nitric oxide used in the immediate perioperative period. She is now on medication to treat the PHTN, and

most recent echocardiogram demonstrated no residual VSD and a patent, unobstructed reimplanted LSCA.

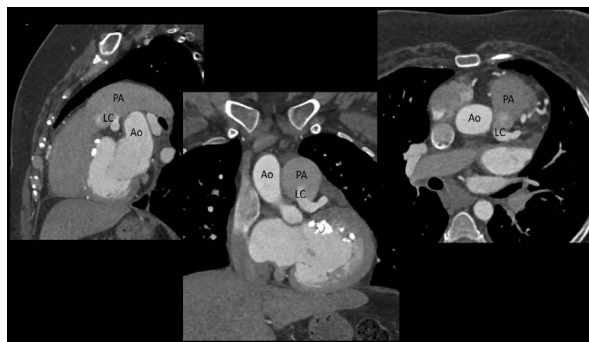
99 ANOMALOUS ORIGIN OF THE LEFT CORONARY ARTERY FROM THE PULMONARY ARTERY

G Murtaza,¹ V Gangadharan,¹ K Sivagnanam,¹ M Ponders,² O Teixeira,² T Paul¹. ¹East Tennessee state University, Johnson City, TN; ²East Tennessee State University, Johnson City, TN.

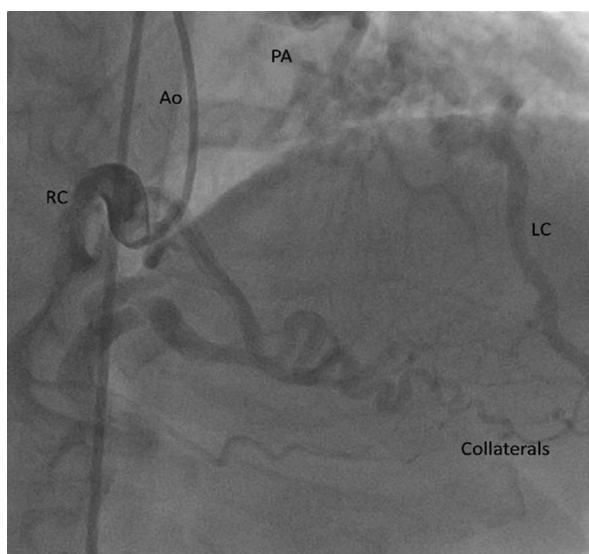
10.1136/jim-2016-000393.99

Case Report A 36-year-old female with exertional chest pain and shortness of breath was evaluated following an abnormal stress test. Physical exam was unremarkable. Coronary CT angiogram revealed an anomalous origin of the left coronary artery system from the main pulmonary artery (Fig 1). Coronary angiography showed a large tortuous RCA with collaterals to LAD that drained into the main pulmonary artery (Fig 2). She was referred for surgery.

ALCAPA is a rare coronary anomaly in adults. High pulmonary pressures at birth ensure adequate perfusion to myocardium but as the physiologic decrease in pulmonary



Abstract 99 Figure 1



Abstract 99 Figure 2

artery resistance and pressure occurs, blood flow through the anomalous coronary is compromised resulting in ischemia. Clinical manifestations may include severe congestive heart failure and recurrent myocardial ischemic events.

100 A RARE CASE OF ARTERIOVENOUS MALFORMATIONS IN CORONARY, COLON AND SUBLINGUAL CIRCULATION IN A SINGLE HUMAN BEING

Patel Akshar, Patel Bharat. *Bay Area Heart Center, Webster, TX*

10.1136/jim-2016-000393.100

Purpose of Study To report a rare case of arteriovenous malformations in coronary, colon and sublingual circulation in a single human being.

Methods Used A retrospective study of a rare case of arteriovenous malformations in coronary, colon and sublingual circulation in a single human being.

Summary of Results AL is a 66 year old Caucasian female who presented to the emergency room with chest pain and electrocardiographic changes consistent with nontransmural ischemia. Coronary arteriogram was performed which revealed arteriovenous malformations in left anterior descending and circumflex circulation. A colonoscopy was performed as a work up for accompanying mild anemia which revealed a 3 by 3 cm arteriovenous malformation in ascending colon. An incidental finding of an arteriovenous malformation was also noted in a sublingual circulation on physical examination.

Conclusions A review of literature revealed that such arteriovenous malformations in multiple organ systems in a single human being are extremely rare.

101 A RARE CASE OF EXTREME GENERALIZED WEAKNESS AND WEIGHT LOSS ON SIMVASTATIN

Patel Akshar, Patel Bharat. *Bay Area Heart Center, Webster, TX*

10.1136/jim-2016-000393.101

Case Report RP is a 76 year old Caucasian male with prior coronary bypass surgery, moderately severe right carotid artery stenosis and diabetes mellitus with moderately severe obesity who presented to the office with 40 lbs weight loss along with extremely severe generalized weakness while taking 40 mg of Simvastatin a day. Patient also had accompanying mild hypocalcemia with negative work up for parathyroid disorder. Also accompanying past history of moderately severe anemia with negative colonoscopy was noted. Anemia was corrected with iron and vitamin replacement therapy. MRI of brain revealed mild generalized brain atrophy consistent with microvascular cerebral disease. Serum PSA was normal. Generalized weakness has partially improved upon physical therapy and stoppage of Simvastatin. Review of literature revealed that such extreme generalized weakness and weight loss on Simvastatin is extremely rare.

102 SUDDEN CARDIAC DEATH IN LEFT VENTRICULAR NONCOMPACTION

P Patel, J Ruiz, P Staiano, J Greco, P Reddy. *University of Florida College of Medicine-Jacksonville, Jacksonville, FL*

10.1136/jim-2016-000393.102

Case Report 28 yo female presented to the ED for hypertensive emergency. Patient had a history of HTN, non-obstructed hypertrophic cardiomyopathy. The patient endorsed chest pain and SOB and had BP of 263/193, tachycardic. Physical exam was unremarkable. She was admitted and placed on a nitroglycerin drip with stabilization of BP and symptoms. She had complaint of blurry vision and was found with AMS and had sluggish pupillary reaction of her left eye otherwise neurologically intact. Soon after, she was found obtunded responsive to sternal rub and deteriorated with multiple cardiac arrests and ventricular fibrillation requiring defibrillation. She expired after exhausting all reasonable resuscitation measures. Postmortem, an autopsy was performed revealing thickened LV papillary muscle with increased trabeculation indicating Ventricular Noncompaction (VNC) in setting of hypertrophic cardiomyopathy.

VNC is a rare condition defined by increase in trabeculated, noncompacted tissue and deep intratrabecular recesses adjacent to compacted myocardium caused by developmental arrest. Diagnosis is multifaceted with no definite guidelines in place. 2-D echocardiology is the most common initial test however diagnostic criteria is controversial. Subxiphoid long axis will show prominent trabeculations, increased depth of intratrabecular recesses and apical thickening. 3-D imaging can be helpful to evaluate LV function and quantify trabeculations. Cardiac MRI is useful at delineating compacted and noncompacted myocardium. Management of these patients is based on limited data. Patients with reduced EF should follow standard of care for cardiomyopathy. VNC places patients at an increased risk for VTE disease. Anticoagulation should be based on CHADS₂-Vasc scores if there is atrial fibrillation or started if there is ventricular clot identified. As in this case, patients are at risk for SCD and it is clear that patients with VNC and reduced EF should be candidates for primary prevention with internal cardiac defibrillator. Assessing risk for SCD in patients with normal EF must take into account family history of SCD, nonsustained Ventricular tachycardia seen on Holter Monitor, and multiple episodes or syncope. Patients with VNC have a higher incidence of heart failure, SCD, and transplant.

103 ATYPICAL TAKOTSUBO CARDIOMYOPATHY SECONDARY TO SEROTONIN SYNDROME AND OPIATE OVERDOSE

X Solis, T Warmoth, C Perez. *TTUHSC, Lubbock, TX*

10.1136/jim-2016-000393.103

Case Report Takotsubo Cardiomyopathy or 'Broken Heart Syndrome' was first described in 1990 Japan, with the

classic apical ballooning and basal hyperkinesis. This syndrome was classically seen in young females experiencing extreme emotional distress, which was believed to be due to catecholamine surge. Atypical variants of this syndrome exist, which constitute approximately 20% of cases. Here we describe a case of Atypical Takotsubo Cardiomyopathy in a woman after intentional overdose of selective serotonin reuptake inhibitors (SSRIs) and opiates.

A 55-year-old female was transferred to our facility for higher level of care after she was found unresponsive by her mother, next to two empty bottles of Norco, one empty bottle of tramadol, and she was covered in multiple fentanyl patches. She was reported to take multiple doses of her home escitalopram. She was intubated en route due to acute respiratory distress. Upon admission to our facility, Trop T trended 0.65->0.38->0.28->0.09, CKMB: 19.6, EKG showed 1^o AV Block with QTC 439. Cardiology was consulted and performed a transthoracic echocardiogram that showed an ejection fraction of 40–44% with akinetic circumferential base and hyperkinetic apex. She was taken for left heart angiogram, which showed no evidence of CAD, including LVEF of 68%, no regional wall abnormalities, aortic pressure of 167/98, and no calcifications of blockages of coronary arteries. She was diagnosed with atypical Takotsubo Cardiomyopathy as a result of a combination of serotonin syndrome and opioid overdose.

There have been many previously identified causes of Atypical Takotsubo Cardiomyopathy, but only one other case has been identified with serotonin syndrome. Review of literature does not reveal any cases reported after acute stress from both serotonin syndrome and opiate overdose. Treatment is usually supportive, as depression of LVEF usually recovers in the months following the initial insult.

104 REFRACTORY PRINZMETAL'S ANGINA REQUIRING FULL METAL JACKET

X Solis, B Rosales, C Perez. *TTUHSC, Lubbock, TX.*

10.1136/jim-2016-000393.104

Case Report Prinzmetal's angina also referred to as Vasospastic or Variant angina is a clinical entity that is described as episodes of rest angina that promptly responds to short acting nitrates and is attributable to coronary artery vasospasm. Transient EKG changes, less than 15 minutes, can be seen such as ST-segment elevation, ST-depression, and new U-wave formation. Patients with this condition need to be evaluated for high grade fixed obstruction, by coronary angiogram, to determine if ischemia is causing ischemic changes on EKG. Calcium channel blockers, sublingual nitroglycerin, and long-acting nitrates are first line therapy and usually effective.

A 59 yo M presented to our facility for suspicion of acute STEMI after EKG showed ST-elevation in the inferior leads, and the patient was experiencing daily sub-sternal chest pain that radiated to the left arm and shoulder. Pain was usually alleviated by nitroglycerin, but this episode did not relate to medical therapy. The patient was taken for emergent left-heart catheterization. During the procedure, the RCA was noted to diffusely vasospasm and ST elevation was seen in the inferior leads. This spasm resolved with

intracoronary nitroglycerin administration. The patient was discharged on 120 mg nifedipine XR, Imdur 120 mg, and as needed nitroglycerin. 2 month after first admission he was once again admitted due to continued symptoms of daily chest pain and ST elevation in the inferior leads. The decision was made to give the patient full stenting, or 'full metal jacket', of the RCA. The patient remained asymptomatic in the post-procedure period and was discharged.

While nitrates and calcium channel blockers remain the mainstay treatment for Prinzmetal's Angina, a small population with this disorder remains symptomatic despite maximal medical therapy. Some cases have been reported illustrating the success of full coronary stenting for refractory vasospasm, but this is not yet a recommendation by the JACC. Here we present a case of a patient who experienced relief of symptoms with this unique and experimental intervention.

105 COULD IT BE A RARE PRESENTATION OF BLAND – WHITE GARLAND SYNDROME

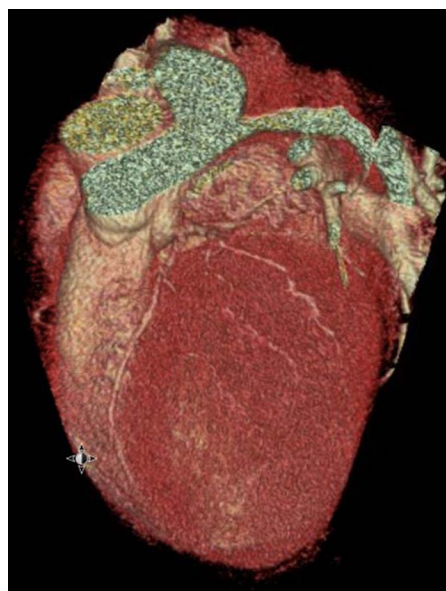A Sultan, R Panikkath, L Jenkins. *Texas Tech University Health Sciences Center, Lubbock, TX.*

10.1136/jim-2016-000393.105

Case Report Bland white Garland syndrome also known as aberrant L main coronary artery arising from pulmonary artery) is a rare but serious congenital cardiac anomaly.

First time described in 1866, however the first clinical description was given in 1933 by Bland and Colleagues following autopsy findings.

Here we are presenting a case of a 59 years old female who was transferred to our facility for the LHC and coronary angiogram following an abnormal stress test which showed reversible ischemic changes of the inferior and anterolateral wall. TTE showed 55% EF with elevated RVSP of 42 mmHG and mildly enlarged L atrium.



Abstract 105 Figure 1

Patient underwent planned angiogram and LHC while angiogram showed difficulty is accessing the L coronary artery therefore aortogram was performed which showed L main coronary artery arising from the L cusp with 50% distal stenosis. Concern was low for an interarterial course hence CTA was performed prior to consulting CT surgery which confirmed the interarterial course of the L main coronary artery.

CT surgery was consulted and the patient underwent coronary artery bypass grafting with LIMA to LAD and SVG to ramus and PDA with a successful recovery.

An aberrant origin of left main coronary artery from right coronary aortic sinus is a rare anomaly. The course of the anomalous LMCA can be of 4 types: Interarterial, Prepulmonic, Retroaortic and Subpulmonic.

Interarterial course that is between aorta and pulmonary artery is considered malignant and has been associated with ischemic events and sudden death.

106 INFILTRATIVE HEART DISEASE

V Tonthat, W Baumgartner, S Laura, LS Engel. *LSU Health Sciences Center, New Orleans, LA.*

10.1136/jim-2016-000393.106

Case Report Introduction: Amyloidosis is deposition of misfolded fibrils in the extracellular space of various organ systems. Cardiac involvement can lead to heart failure, small vessel disease, pericardial disease, conduction abnormalities, and arrhythmias.

Case A 67 year old woman with history of diabetes mellitus and hypertension, presented with chief complaint of chest pain and shortness of breath. She reported constant left-sided, non-exertional, dull chest pain. Review of systems was pertinent for three months of progressive paroxysmal nocturnal dyspnea, orthopnea, and dyspnea on exertion. She was tachycardic, hypoxic, and in respiratory distress at presentation. Physical exam was remarkable for bibasilar crackles and jugular venous distention. Electrocardiography showed low voltage normal sinus tachycardia, prolonged QT interval, non-specific T wave flattening laterally, and new Q-waves anteriorly. Troponin I level was >50.0 ng/ml and BNP of 1815 pg/ml. Chest X-ray revealed bilateral pulmonary edema. Echocardiography demonstrated normal left and right ventricular size and systolic function with bi-atrial enlargement, 'granular and sparkling' appearance of the myocardium. Diagnostic coronary angiography revealed non-obstructed coronary arteries. Infectious and autoimmune disorders were ruled out. Cardiac MRI showed delayed gadolinium enhancement in the anterolateral and inferolateral wall with biventricular hypertrophy consistent with infiltrative heart disease. After diuresis, the patient's symptoms improved and was discharged to have an outpatient fat pad biopsy to confirm suspected amyloidosis.

Discussion Primary amyloidosis (AL), Transthyretin (TTR) amyloidosis, and Senile amyloidosis are the most common of the 25 types of amyloid proteins to involve the heart. Many imaging studies are suggestive of amyloidosis, but a definitive diagnosis is only made by visualizing the amyloid fibrils within tissue. This can be accomplished via tissue

(i.e. fat pad or cardiac) biopsy with Congo-red staining or by visualizing the characteristic negative apple-green birefringence under a polarized light. Early recognition and diagnosis of this systemic disease is crucial to management. Treatment depends on the primary cause and often therapy is targeted at the complications associated with cardiac amyloidosis.

107 PATIENT FORAMEN OVALE: NOT ALWAYS CONGENITAL

SM Zaidi, G Murtaza, V Ladia. *East Tennessee State University, Johnson City, TN.*

10.1136/jim-2016-000393.107

Case Report Patent foramen ovale (PFO) is a connection between the right and left atrium of the heart and is described as purely a congenital phenomenon. We present a case of patient who developed a non-congenital, 'new' PFO in setting of infective endocarditis, leading to paradoxical stroke.

Our patient is a 25 year old female with history of IV drug abuse who presented to the ER with coccyx pain and fever. She was found to have MRSA bacteremia and started in IV antibiotics. A transthoracic echo (TTE) was done which visualized a 3.7 cm×1.32 cm suspicious lesion on her tricuspid valve with a PFO visualized. A transesophageal echo (TEE) was done which confirmed large vegetation on all three tricuspid valve leaflets and a large PFO with bi-directional flow again noted. She later developed left sided paresis and a CT head was obtained showing infarct involving the right anterior lentulostriate distribution, likely secondary to embolus from her heart vegetation.

Records from her last hospitalization a month ago, when she was admitted for MSSA bacteremia, were reviewed at which point she was evaluated with a TTE to rule out endocarditis. No evidence of endocarditis was seen on her previous echo and no PFO was visualized.

PFOs have great embryological significance, necessary for oxygenated blood to travel from right to left atrium during fetal development. Normally PFOs close at an early age, however can be present in up to 30% of the adult population due to improper closure. Most patients remain asymptomatic their entire lives, however, when present it can lead to paradoxical stroke, right-to-left shunt, air embolisms, atrial septal aneurysms, migraines and platypnea-orthodeoxia syndrome.

PFOs are readily diagnosed with use of a TTE or TEE with bubble study to visualize a right-to-left shunt, with higher sensitivity described with TEE. Since most patients with PFOs are asymptomatic, management of a incidentally detected PFO involves no treatment. However, management of PFOs involved in strokes is currently under review and can include closure of PFO and secondary stroke prevention medications.

Our review of literature did not reveal other cases of non-congenital PFOs. This case demonstrates an instance of a non-congenital PFO in setting of endocarditis and re-affirmation of a known phenomenon of a paradoxical stroke.

Clinical Epidemiology and Preventive Medicine

Joint Plenary Poster Session and Reception

4:30 PM

Saturday, February 11, 2017

108 WHEN A CANULA CAN CAUSE A CATASTROPHE: LEGIONELLA IN A LONG-TERM FACILITY

A Mirza,¹ M Habib,¹ K Williams,² C Stoughton,² T Vo,¹ RD Smaligan². ¹Texas Tech Univ HSC-Amarillo, Amarillo, TX; ²City of Amarillo Health Dept, Amarillo, TX.

10.1136/jim-2016-000393.108

Case Report An 86yo man with COPD and HTN was admitted from a long-term care facility (LTCF) with pneumonia. He was treated with antibiotics and survived. A urine antigen test was positive for Legionella and the local Health Department was notified. Their staff met with the LTCF immediately. Samples from sinks, water faucets and shower heads showed 11 out of 30 with viable *Legionella pneumophila* SG1. No new patients were admitted while the study was ongoing and a water system rx plan was started, first by superheating for hours, then hyperchlorination followed by placement of point of use filters. On review, 26 residents had respiratory sx's in the past 6 months: 1 tested pos for Legionella. Of concern was the fact that 2 roommates, whose room had a culture pos faucet, both developed pneumonia and were hospitalized. One was neg but the other passed away before samples could be collected. It should be noted that the sensitivity of the urine antigen test is 80%. Repeat sampling of water after rx showed 0 out of 30 pos but 2 weeks later 3 of 30 were once again pos. Water treatment was repeated. Careful analysis by health department staff revealed that the water reservoirs for humidifying oxygen were being filled with tap water which in retrospect may have been contaminated with the bacteria. Reservoirs were replaced and sterile water used from then on.

Discussion A recent environmental study of Legionella showed it to be present commonly in water samples across 68 locations in the USA. Controversy exists over whether Legionella in water systems correlates well with the incidence of Legionellosis. There is also disparity in guidelines about the CFU/ml permitted and the use of tap water vs sterile water for oxygen supply humidifiers. In the US, guidelines specific to LTCFs that provide recommendations regarding routine environmental testing for Legionella vary significantly across agencies. At the state level only Alabama, Maryland, and Texas provide guidelines regarding primary prevention. Hence, we suggest that further studies are warranted to determine the impact of routine

testing and implementation of control measures to reduce morbidity and mortality due to this almost ubiquitous bacteria.

109 ACUTE EXERTIONAL COMPARTMENT SYNDROME: A RARE DIAGNOSIS WITH POTENTIALLY DEVASTATING CONSEQUENCES

A Richardson, C Baldeo, E Bueno, P Reddy. University of Florida Jacksonville, Jacksonville, FL.

10.1136/jim-2016-000393.109

Case Report Acute compartment syndrome occurs from increased pressure within the fascial compartments of skeletal muscle that contain muscle and nerves. As a result of increased pressures within the closed fascial compartments, vascular compromise can occur. If left untreated, this results in permanent damage. We present a case of acute exertional compartment syndrome.

A 33 year old male presented from jail to the emergency department complaining of bilateral flank pain and dark colored urine of 8 hours duration. Since his recent incarceration he started a new workout routine and estimated he may have done over 100 squats continuously prior to symptom development. He developed intense pain in his thighs after exercising. Vitals on admission showed BP of 139/97 mmHg, heart rate of 94 bpm, and temperature of 98 F. Examination was significant for tenderness of bilateral thighs. Serum creatinine was noted to be 1.04 mg/dL, BUN 13 mg/dL, WBC 11.3 thou/mm³ and Hemoglobin of 12.8 g/dL. Urinalysis revealed red, turbid urine with 40RBCs. Lactic acid was 3.6 and CK 169,880. CK levels continued to increase and the patient's pain worsened. Distal pulses remained palpable, however bilateral lower extremity pain was noted to be out of proportion to the examination. Pressures within the muscle fascia of both thigh and right calf muscles were consistent with compartment syndrome. He was taken emergently to the operating room for bilateral thigh and right calf fasciotomy. Upon opening of fascia, edematous tissue and bulging muscles were noted with no muscle devitalization. He was transferred to the surgical ICU post op and fully recovered with no complications.

Compartment syndrome of the thigh remains an uncommon finding with few noted in literature. Acute exertional compartment syndrome is a rare presentation of acute compartment syndrome occurring after exertion without injury. Prompt diagnosis and fasciotomy is required to prevent permanent damage. Sequential physical examinations and obtaining regular CK levels can be helpful in triggering prompt management. As high intensity workouts increase in popularity, acute exertional compartment syndrome will likely become more prevalent.

Endocrinology and Metabolism Joint Plenary Poster Session and Reception 4:30 PM Saturday, February 11, 2017

110 SEVERE CARDIOVASCULAR AUTONOMIC NEUROPATHY AS A COMPLICATION OF POORLY CONTROLLED DIABETES MELLITUS

V Bazylevska, A Adiga, I Huizar. *TUHS, Lubbock, TX.*

10.1136/jim-2016-000393.110

Introduction Cardiovascular autonomic neuropathy (CVAN) is a condition resulting in autonomic dysregulation of cardiovascular system. The diagnosis presents a challenge mainly due to the absence of clearly defined diagnostic criteria. However, the CVAN appears to be of an extreme importance, since there's strong association of the condition with all-cause mortality, silent ischemia, adverse cardiovascular, cerebrovascular and renal outcomes.

Case report 47 year-old male presented to the emergency room (ER) with complains of dizziness and systolic blood pressure (BP) being in low 80s. Previously he was seen multiple times both in ER and urgent care clinic for both, significantly elevated and low BP, usually accompanied by chest pain.

The patient had past medical history of poorly controlled diabetes mellitus with the most recent HbA1c being 12.5%, complicated by severe peripheral neuropathy, erectile dysfunction and gastroparesis required gastric pacemaker implantation. In addition, he had history of morbid obesity, hypertension, percutaneous coronary intervention, heart failure with preserved ejection fraction and obstructive sleep apnea. Physical exam was significant for BP of 85/52. Initial labs were significant for glucose level of 572 with no signs of diabetic ketoacidosis. TSH level was normal.

Intravenous fluid administration led to increase in BP to 170/100 within 6 hours with subsequent its increase to 200/120. It had been hard to adjust his antihypertensive medication due to severe fluctuations in BP over the hospital stay. Since the patient was recently evaluated with echocardiographic, electrophysiologic studies and nuclear stress testing which yielded negative results, differential diagnosis was limited to diabetic autonomic neuropathy and pheochromocytoma. Plasma fractionated metanephrins were negative and CT scan of the abdomen did not demonstrate any adrenal masses. The patient refused MIBG scanning due to the need of abstinence from multiple medications. Autonomic testing was performed later, which demonstrated significant pan-autonomic dysfunction.

Conclusion This case report emphasizes the necessity of timely diagnosis and treatment of CVAN for both, quality of life and prognosis improvement.

111 PHEOCHROMOCYTOMA OF THE ORGAN OF ZUCKERLANDL

E Chang,¹ C Lee,² J Gimenez,³ LS Engel,¹ R McCarron¹. ¹LSU Health Sciences Center, New Orleans, LA; ²LSU Health Sciences Center, New Orleans, LA; ³Ochsner Medical Center, New Orleans, LA.

10.1136/jim-2016-000393.111

Introduction Pheochromocytomas (PCCs), or intra-adrenal paragangliomas (PGLs), are neuroendocrine tumors arising within the adrenal medulla. Extra-adrenal paragangliomas may arise in the sympathetic or parasympathetic paraganglia and more rarely in other organs. One of the most common extra-adrenal sites is in the organ of Zuckerkandl, a collection of chromaffin cells near the origin of the inferior mesenteric artery or near the aortic bifurcation. We present a case of a patient with resistant hypertension secondary to an extra-adrenal paraganglioma in the organ of Zuckerkandl.

Case A 43-year-old man with a history of depression, type 2 diabetes mellitus, and hypertension was sent to the Emergency Department by his primary care physician for severely elevated blood pressures. The patient also had diaphoresis, tachycardia, and a new, fine tremor of his left hand. Upon presentation, his blood pressure was 260/120 mmHg with a heart rate of 140 beats per minute. Plasma fractionated metanephrines sent on admission revealed significantly elevated levels of total plasma metanephrines (2558 pg/mL), free metanephrine (74 pg/ml) and free normetanephrine (2484 pg/mL). A I-123 metaiodobenzylguanidine (MIBG) scan showed abnormal uptake in the lower abdomen at the level of the aortic bifurcation. The patient was started on alpha-blockade, with subsequent addition of a beta-blocker prior to surgery. The patient underwent surgical removal of the tumor with pathology consistent with a paraganglioma.

Discussion Pheochromocytomas and paragangliomas are responsible for approximately 0.5% of cases of secondary hypertension. Many different biochemical markers have been used to aid in the diagnosis of PCC/PGL including plasma catecholamines, plasma metanephrines, urine fractionated metanephrines, urine catecholamines, total metanephrines and vanillylmandelic acid. Definitive management of a PCC and PGL involves surgical removal of the tumor. Finally, there should be a discussion with each patient to determine if he or she should undergo genetic testing, as studies demonstrate that approximately 25% of catecholamine producing PCCs and PGLs are due to heritable genetic mutations.

112 GALACTOSE SUPPLEMENTATION AS A NOVEL TREATMENT FOR DOLICHO-PHOSPHATE MANNOsylTRANSFERASE 2 DEFICIENCY

TF Fitzpatrick-Schmidt,^{1,2} E Morava-Kozicz,² S Wong². ¹Tulane University, New Orleans, LA; ²Tulane University School of Medicine, New Orleans, LA.

10.1136/jim-2016-000393.112

Purpose of Study Dolichyl-phosphate mannosyltransferase 2 (DPM2) deficiency is a subtype of congenital disorder of glycosylation (CDG; DPM2-CDG). DPM2 is a regulatory subunit of the dolichol-phosphate-mannose synthase (DPMS) complex, an important enzyme in N-linked glycosylation. DPM2 is required to stabilize the DPMS complex. To date, there are only three reported cases of DPM2-CDG. Patients present with delayed psychomotor development, progressive muscle weakness, epileptic seizures, and early mortality. DPM2-CDG is an untreatable, devastating disease. Previous studies have demonstrated the

benefits of monosaccharide supplementation for a few CDG subtypes, showing clinical improvement and rescue of cellular glycosylation; however, whether monosaccharide supplementation is beneficial to DPM2-CDG is unknown.

Methods Used To examine the effect of monosaccharide supplementation on cellular glycosylation, we cultured skin fibroblasts derived from a DPM2-CDG patient, with or without monosaccharide supplementation. D-mannose or D-galactose was added to the culture medium at 0 mM, 0.75 mM, 2 mM, or 5 mM. We used western blotting and immunohistochemistry to detect the protein expression of intracellular adhesion molecule 1 (ICAM-1), a validated marker of N-glycosylation. We also used quantitative RT-PCR to assess RNA expression in metabolic pathways that are immediately adjacent to DPM2.

Summary of Results ICAM-1 protein expression was diminished in untreated DPM2 deficient cells and showed improvement following supplementation with galactose, but not mannose. DPM2 deficient cells showed altered RNA expression at baseline and after galactose supplementation in the hexosamine biosynthetic pathway and unfolded protein response signaling.

Conclusions Our results suggest that D-galactose, but not D-mannose, improves cellular glycosylation in DPM2 deficient cells. Interestingly, aberrant RNA expression was observed in metabolic pathways upstream to DPM2. Furthermore, some of the genes appear to be responsive to galactose supplementation. Our preliminary *in vitro* findings suggest that galactose supplementation may be beneficial to patients with DPM2-CDG.

113 PAMIDRONATE USED AS A TREATMENT IN A PATIENT WITH CARBOMYL PHOSPHATE SYNTHETASE DEFICIENCY TYPE 1

C Foster, A Diaz-Thomas, H Al-Zubeidi. *University of Tennessee Health Science Center, Memphis, TN.*

10.1136/jim-2016-000393.113

Case Report Immobilization is an uncommon etiology of hypercalcemia associated with limited movement. It is described in patients who have increased bone turnover, often seen in adults after hip fracture, trauma or burn patients, and children with spinal cord injury and long bone fractures. It has been also described in patients who are non-weight bearing.

Case report A 15 month old developmentally delayed and hypotonic Caucasian female with a history of carbamoyl phosphate synthetase I (CPS I) deficiency presented with vomiting and a slow increase in her calcium over >6 months. Initial laboratory assessment included: calcium of 14.2 mg/dL and increased urine NTX with PTH, PTHrP, phosphorus, urine calcium/creatinine ratio and vitamin D being unremarkable, consistent with increased bone turnover. A renal ultrasound done during admission demonstrated nephrocalcinosis. and skeletal survey showed no evidence of rickets, skeletal deformity, or old/healing fractures. Family testing revealed normal parathyroid hormone, vitamin D, and calcium. On admission to the hospital, she was provided rehydration with ½ maintenance of 0.9% NaCl in addition to her home formula regimen, which was

increased to a full maintenance rate of D5 0.45% NaCl given her persistent hypercalcemia. Her metabolic formula had been fortified with calcium: the fortification was also decreased and finally discontinued. Lasix and calcitonin were both tried with limited success and numerous side effects. Physical therapy was consulted to assist with increasing movement and resisting gravity by chair-sitting. Despite these measures, she continued to have persistent hypercalcemia and emesis. Finally, a trial of 0.25 mg/kg of pamidronate intravenously decreased her serum calcium to 9.4 mg/dL after 2 days. Improvement in her bone turnover markers was noted. Emesis resolved and patient was discharged home. She is being maintained on scheduled pamidronate and physical therapy.

Conclusion Pamidronate infusion may be a tool that can be utilized to address hypercalcemia in patients with carbomyl phosphate synthetase deficiency type 1.

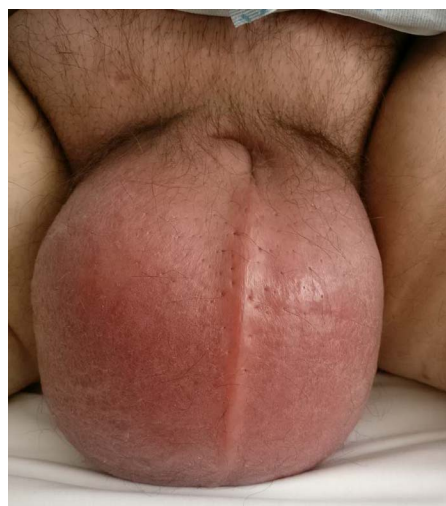
114 OBESITY AS A CAUSE OF MASSIVELY LOCALIZED SCROTAL LYMPHEDEMA

KR Green,¹ F Baidoun,¹ R Jacob,¹ L Knight². ¹UF Jacksonville, Jacksonville, FL; ²University of Florida College of Medicine, Gainesville, FL.

10.1136/jim-2016-000393.114

Case Report Massively localized lymphedema is an accumulation of protein-rich lymph fluid in the soft tissues of the scrotum. This rare condition is characterized by giant swelling, inflammation, and peau d'orange skin changes.

Case Report A 49 year old male with a history of diabetes mellitus, hypertension, and morbid obesity presented with seven weeks of scrotal swelling and erythema. Eight weeks prior he was admitted at an outside hospital for anasarca, which resolved with diuretics except for his scrotum. Antibiotics and diuretics on a subsequent admission had no improvement. He denied scrotal pain, dysuria, hematuria, penile discharge, penile lesions, sexual diseases, trauma, and recent travel.



Abstract 114 Figure 1

Exam revealed a massively enlarged non-tender scrotum, obscuring the penis with erythematous, mottled, and thickened skin. Infectious markers and chemistries including urinalysis and culture were unremarkable. Ultrasound showed normal vascular flow to both testes with scrotal edema and fluid accumulation in the subcutaneous tissue without hydrocele. CT revealed no evidence of abscess or necrotizing fasciitis; however, mild right inguinal lymphadenopathy was noted. Echocardiogram revealed no evidence of heart failure.

Conclusion Massively localized lymphedema is a rare manifestation of obesity. Diagnosis is clinical and can be confirmed with pathology. Definitive therapy is surgical; however, it is reserved for cases that cause functional limitations and recurrent infections.

115 UNTREATED HYPOTHYROIDISM RESULTING IN MYXEDEMA COMA AND HEART FAILURE

R Kamat, B Ford, E Sowell, LS Engel, R McCarron. *LSU Health Sciences Center, New Orleans, LA.*

10.1136/jim-2016-000393.115

Case Report Introduction: Myxedema Coma is a complication of severe hypothyroidism resulting in hypothermia, altered mental status, and multi-organ dysfunction.

Case A 69-year-old man with a past medical history of hypertension, hyperlipidemia and hypothyroidism presented to the Emergency Department (ED) with shortness of breath and palpitations. He reported a two-month history of worsening weakness and dyspnea, especially worsened by laying down. Family members at bedside reported a three-year history of noncompliance with medications and refusal to see his primary physician. They reported that in the past 3 days patient had become more somnolent and was no longer at his baseline mental status. On admission, the patient required a nonrebreather for O₂ saturations of 72%, pulse 107, respiratory rate 26, and blood pressure 168/95. A chest x-ray done in the ED was significant for cardiomegaly. A PE study was also done at that time which was negative for thromboembolism but consistent with acute systolic heart failure and bilateral pleural effusions. Echocardiogram obtained showing EF of 25%. The patient continued to become more lethargic and required BiPAP for his hypoxia. He was subsequently intubated for acute respiratory failure. Labs at that time were significant for a TSH of 97.24 uIU/mL and FT₄ of <0.4 ng/dL. The patient was started on high dose IV levothyroxine and glucocorticoids. After 2 days, he self-extubated and his mental status improved considerably. Repeat TSH and FT₄ levels showed improvement in thyroid function. However, a repeat echo showed no improvement in cardiac function. He was eventually discharged home with levothyroxine, heart failure medications, and close follow-up.

Discussion Myxedema coma is now a rare complication of severe hypothyroidism owing to improved diagnosis of thyroid deficiency in the outpatient setting. Common manifestations include cardiac dysfunction, hypothermia, altered mental status, and electrolyte disturbances. Aggressive therapy should be initiated with thyroid hormone and

corticosteroids, along with supportive measures for end organ dysfunction.

116 FIST BUMP: A CASE OF ABNORMAL PALMAR THICKENING

A Leonard, LS Engel. *LSU Health Sciences Center, New Orleans, LA.*

10.1136/jim-2016-000393.116

Case Report Case: A 58 year old woman with a history of poorly controlled type 2 Diabetes Mellitus (Hemoglobin A1c 12%), hypertension, ablated atrioventricular nodal reentry tachycardia, and osteoarthritis described an 8 month period of palm soreness and thickening during attendance at her primary care clinic. She reported palpable nodules, worse on her left palm and now progressing to right hand with tenderness at night with occasional 4th and 5th digit 'closing' on their own. The patient had no history of alcohol or tobacco use. Physical exam revealed nodule like thickening over the bilateral palmar aspect of the 4th and 5th digits with associated areas of erythema on the left palm. She did not have tenderness nor decreased range of motion or strength in intrinsic or extrinsic hand muscles. There was no other large joint involvement. Radiographs were unremarkable. An ultrasound of the palms showed diffuse plaque like thickening of palmar aponeurosis with focal irregular hyperechoic focus of nodularity near the ulnar aspect of the palm consistent with chronic nodular palmar fasciitis. A rheumatologic work up was negative. The patient was started on meloxicam and diclofenac gel with minor improvements. The nodules progressed and she had an increase in soreness over the lesions and was subsequently seen in Rheumatology and Hand clinic with the consensus that her Dupuytren's Disease with contractures was secondary to poorly controlled diabetes. The patient received bilateral steroid injections into the hands and regained better control of her diabetes resulting in overall slow improvement of her symptoms.

Discussion Dupuytren's Disease and associated contractures most often affect the 4th and 5th digits bilaterally. Contractures are often preceded by fibrosis of the palmar area with thickening and skin abnormalities and development of 'cords' that limit finger extension. Risk factors for this disease include alcohol or tobacco use, trauma, and diabetes. Palmar fasciitis, which can be confused with Dupuytren's disease, often involves all digits and is associated with underlying malignancy or polyarthritis type syndromes. Treatment focuses on supportive care with collagenase injections and surgical correction often required to relieve some disability.

117 ASPERGILLOSIS OF PITUITARY GLAND IN AN IMMUNOCOMPETENT PATIENT

MS Marangoz, DS Hsia, T deSilva. *Louisiana State University, New Orleans, LA.*

10.1136/jim-2016-000393.117

Introduction Sphenoidal aspergillosis is an unusual cause of sella turcica enlargement and is seen primarily in immuno-compromised patients. We present a 72-year-old

immuno-competent male who had intact pituitary function following a transsphenoidal surgery (TSS) where pathology showed aspergillus species in the pituitary gland.

Case His past medical history was significant for type 2 diabetes, hypertension, hyperlipidemia, and chronic kidney disease stage 3. He presented with severe headache, vomiting and eye pain with sudden onset and constant pain behind his left eye upon awakening in the morning. He denied change in vision or photophobia. His family history was significant for lung cancer in his brother. He denied smoking, alcohol, or illicit drug use.

On exam he was alert, oriented to person, place, and time. Heart exam showed regular rate and rhythm, with a 2/6 systolic murmur. Neurological exam revealed intact cranial nerves II to XII without a visual field defect.

Labs were significant for creatinine 2.54 mg/dl and glucose 218 mg/dl. Head CT revealed a mass lesion in the left sphenoid sinus, eroding the anterior floor of the pituitary sella. On CT it measured 12x12x17 mm, while on MRI it was noted to be 20x20x25 mm. The lesion partially surrounded the left internal carotid artery and had a small tail that extended near or into the left optic foramen.

Labs were significant for: ACTH 40 pg/ml (N:7–69), LH 7 mIU/ml (N 2–12), FSH 7.4 mIU/ml (N 3.0–5.5), Prolactin 16.6 ng/ml (N 1–18), IGF 86 ng/ml (N 36–215 ng/ml), testosterone 29 ng/dl (N 175–781), TSH 1.70 uIU/ml (N 0.5–5).

He underwent elective TSS by neurosurgery and ENT without complications (Diabetes insipidus, CSF leakage etc.).

The pathology report showed: fragmented pauciseptate hyphae of very narrow diameter, thin walls and containing calcium oxalate crystals consistent with *Aspergillus* species with PAS and GMS stains. Specimens were noted to include infarcted pituitary adenoma tissue with cells expressing prolactin and FSH.

No hormonal replacement was necessary and he was referred to infectious disease clinic for follow up for aspergillus infection.

Conclusion This case demonstrates an unusual case of Aspergillosis presenting as a pituitary mass. It highlights the fact that immuno-competence should not preclude consideration of this diagnosis.

118 A PARATHYROID ADENOMA MASQUERADING AS A THYROID NODULE

F Mushtaq,¹ L Melendez². ¹LSUHSC-New Orleans, Metairie, LA; ²University Medical Center, New Orleans, LA.

10.1136/jim-2016-000393.118

Case Report Parathyroid adenomas are difficult to visualize and diagnose. High index of suspicion is needed when suspecting hypercalcemia due to parathyroid pathology

Case description A 48 year old female was referred to endocrinology for evaluation of hypercalcemia. Initial laboratory data revealed parathyroid hormone (PTH) 181 pg/ml (12–65 pg/ml) calcium 10.5 mg/dl (8.4–10.3 mg/dl) for normal albumin, 24 hour urine calcium 1824 mg/24 hrs, phosphorus 2.5 mg/dl (2.5–4.7 mg/dl), 25 hydroxy vitamin D 6.3 ng/ml (30–100 ng/ml) and normal bone

density. Sestamibi single-photon emission computed tomography (SPECT) parathyroid scan showed no parathyroid adenoma. Thyroid ultrasound showed 1.2 cm hypoechoic well vascularized inferior right thyroid nodule. Fine needle aspiration (FNA) of this nodule showed atypia of undetermined significance and cytology with nuclear enlargement, focal presence of crowded cellular aggregates with absent colloid. During her clinical course, vitamin D was replaced with repeat laboratory data showing 25 hydroxy vitamin D level 31 ng/ml, serum calcium 11.1 mg/dl, 24 hr urine calcium 519 mg/24 hrs and PTH level 258 pg/ml. Repeat FNA of the right thyroid nodule with PTH washout of aspirate fluid was 2270 pg/ml. Cytology showed granular chromatin and crisscrossing capillaries of some cell groups, findings which are associated, but not specific for parathyroid lesions.

Discussion 99mTc-sestamibi is taken up by the parathyroid tissue where it's retained in oxyphil cells. A negative scan occurs in 12–25% of patients and does not rule out parathyroid disease¹. FNAs of the parathyroid can be confused with the thyroid because of overlap in cytomorphologic features. A combination of cytological parameters should be used as no one single feature is diagnostic². Two studies of cytological evaluation of parathyroid lesions showed scattered naked nuclei, loose clusters, fibrovascular core, and a papillary or follicular pattern that was easily confused with thyroid like lesions³.

REFERENCES

- 1 Lal A. The negative sestamibi scan; is minimally invasive parathyroidectomy still possible? *Ann Surg Oncol* 2007;14:2363
- 2 Absher KJ. Parathyroid cytology: avoiding diagnostic pitfalls. *Head Neck* 2002;24:157–64
- 3 Ileyeong Heo. Fine Needle Aspiration Cytology of Parathyroid Lesions. *Korean J Pathol* 2013;47:466–471

119 SEVERE AND RECURRENT HYPOGLYCEMIA IN A MIDDLE-AGED MALE ON NO GLUCOSE LOWERING MEDICATIONS

A Ogunsakin,¹ O Siddiqui,² H Steinberg¹. ¹University of Tennessee Health Science Center, Memphis, TN; ²University of Tennessee, Memphis, TN.

10.1136/jim-2016-000393.119

Background Severe hypoglycemia can result in neuronal dysfunction and death. It is mostly associated with insulin and/or sulfonylurea use. However, severe hypoglycemia has also been reported in patients with ESRD and weight loss

Case Presentation A 43 year old male was brought to the emergency department by EMS with loss of consciousness and serum glucose level of 30 mg/dL. He received multiple boluses of dextrose and was started on i.v. dextrose infusion and subcutaneous octreotide to maintain blood glucose levels above 60 mg/dL, with associated improvement in his mentation. Two hours prior to presentation he had consumed a high carbohydrate meal. In the past three months, he had experienced other episodes of hypoglycemia requiring treatment with dextrose infusion; these incidents also had occurred 2–4 hours after meal. History was significant for ESRD due to uncontrolled hypertension. At age 25, he was diagnosed with T2DM. He was on insulin for almost a year. He subsequently lost 200 lbs, by

lifestyle modification and no longer required any diabetic medications.

On Physical examination he had stable vitals with a BMI 38.2. Review of his medications did not show any culprit drugs. Insulin and C-peptide levels were 164.9 mcU/mL and 23.3 ng/dL respectively. TSH level was normal at 0.9 mU/L. A sulfonylurea screen was negative.

Hypoglycemia resolved over 24 hours in response to octreotide and dextrose. A 72 hr fast was attempted but he was unable to fast for longer than 42 hours. He did not develop hypoglycemia and had an appropriate reduction in insulin. Anti-insulin antibodies were negative. Adrenal insufficiency was excluded with ACTH stimulation test.

Discussion Severe hypoglycemia is life-threatening and may be due to an insulinoma which was ruled out with good certainty in this patient. Etiologies such as adrenal insufficiency were excluded which made non-pancreatogenous hypoglycemic syndrome (NIPHS) a likely diagnosis. His postprandial symptoms and lack of recurrence of hypoglycemia with fasting support our hypothesis of NIPHS, which has been reported in patients after bariatric surgery/excessive weight loss.

Conclusion In patients with severe and recurrent hypoglycemia, NIPHS should be considered.

120 SEPSIS INDUCED MYXEDEMA COMA WITH DIABETIC KETOACIDOSIS

S Palumbo, LS Engel, N Masri. *LSU Health Sciences Center, New Orleans, LA.*

10.1136/jim-2016-000393.120

Case Report Introduction: Myxedema coma, a decompensated state of hypothyroidism, is characterized by decreased metabolic activity resulting in hypothermia, hypotension, bradycardia, and impaired mental state. The Mortality rate approaches 30%. We present a unique case of sepsis induced myxedema coma with superimposed diabetic ketoacidosis.

Case A forty-three year old African American woman with a history of neonatal meningitis with cerebral palsy, seizures, and intellectual disability in addition to insulin dependent diabetes mellitus and hypothyroidism presented with a one day course of altered mental status. Two weeks prior to presentation, the patient ran out of her medications and developed progressive periorbital and lower extremity edema, constipation, dry skin, and severe menstrual bleeding. On initial evaluation, blood pressure was 82/43 mmHg, heart rate 61 bpm, and temperature 86.8 °F. The thyroid gland was diffusely enlarged and the patient was emergently intubated due to airway compromise. Labs were significant for TSH of 112.9, free T4 <0.40 ng/dL, free T3 <1.0 ng/dL and glucose of 1133 mg/dl with hemoglobin A1c of 16.4%. The patient was placed on a norepinephrine infusion for blood pressure support and admitted to the ICU. Her treatment included IV replacement of levothyroxine (T4) and triiodothyronine (T3), stress dose glucocorticoids, insulin infusion, and empiric antibiotics. She rapidly improved and was extubated and off pressor support by day three. Blood cultures grew *Streptococcus anginosus* (poor dentition was the suspected source) and antibiotics were deescalated to penicillin. The patient

developed pulmonary edema after aggressive intravenous fluids and an echocardiogram revealed acute combined systolic (EF 20–25%) and diastolic heart failure secondary to a myocardial infiltrative process consistent with myxematous changes. The patient required intermittent furosemide. A repeat echocardiogram one week later showed a normalized ejection fraction. Endocrinology tailored her outpatient treatment regimen for oral levothyroxine and subcutaneous insulin.

Discussion Based on our patient's rapid improvement, it is evident that prompt repletion of T3 and T4 with additional supportive care in the case of concomitant processes can rapidly reverse end organ dysfunction in the case of myxedema coma.

121 PITUITARY HYPERPLASIA SECONDARY TO PRIMARY HYPOTHYROIDISM

SK Scott, A Kaulfers. *University of South Alabama Children's and Women's Hospital, Mobile, AL.*

10.1136/jim-2016-000393.121

Background Uncontrolled or undiagnosed primary hypothyroidism can cause the pituitary to produce large quantities of TSH, resulting in hypertrophy of the pituitary, mimicking a pituitary macroadenoma. This can also result in deficient or excess secretion of other pituitary hormones due to mass effect, necessitating additional testing of all pituitary hormones. The pituitary should return to normal size with medication compliance.

Objective Make primary care physicians aware that enlargement of the pituitary gland is one of the consequences of uncontrolled primary hypothyroidism.

Case Description 13 year old African American male with a 5 year history of hypothyroidism, admitted with loss of consciousness and seizure-like activity, with prolonged altered mental status. He reports a 1 month history of gradually worsening vision. He has a long history of non-compliance with his L-thyroxine, and admits that he has not taken any medication in over a month.

Urine drug screen, electroencephalogram, electrocardiogram, complete metabolic panel, complete blood count with differential, lactic acid, and chest x-ray were normal. TSH was very high at >150.00 microIU/mL (range 0.34–4.82) and Free T4 was very low at 0.36 ng/dL (range 0.77–1.61). MRI of brain showed a 1.4×2×1.4 cm pituitary mass that was completely filling the sella with extension into the cavernous sinuses, with displacement of the carotid arteries, and deviation of the infundibulum.

ACTH was high at 62 pg/mL (range 6–55) and prolactin was high at 63.7 ng/mL (range 2.1–17.7). Cortisol, FSH, IGF BP3, IGF-1, LH, and testosterone were normal.

He was re-started on 150 mg L-thyroxine daily and will be closely monitored by endocrinology and neurosurgery.

Results It was determined that the enlarged pituitary gland was causing the altered mental status and vision problems. Lab work showed that he did not have a pituitary tumor. Prolactin was elevated as expected with high TSH.

Conclusion Uncontrolled primary hypothyroidism should be considered in the differential diagnosis of pituitary masses. Correct diagnosis is of vital importance.

Multidisciplinary approach is essential in the cases of pituitary masses to avoid delays in diagnosis and prevent unnecessary surgery.

122 AN INTERESTING CASE OF AMIODARONE INDUCED THYROTOXICOSIS

LN Stemboroski, J Trabanco, M Gutierrez, R Kunjal, J House. *University of Florida College of Medicine, Jacksonville, FL.*

10.1136/jim-2016-000393.122

Case Report The use of amiodarone, an iodine rich antiarrhythmic drug, can cause thyroid dysfunction in 15–20% of cases. Complications include iodine induced thyrotoxicosis (AIT) or hypothyroidism. There are two types of AIT, an iodine-induced hyperthyroidism (type 1) and destructive thyroiditis (type 2). Mixed or indefinite forms can occur. Type 1 AIT is more common in patients with pre-existing thyroid disease. AIT is a diagnostic and therapeutic challenge, it is important to establish the correct diagnosis because the management is specific to each subtype.

A 61 year old male presented to the Emergency Department with complaints of shortness of breath and cough for two weeks. He has a PMH significant for CAD, ischemic heart failure, monomorphic ventricular tachycardia on amiodarone and AICD placement. He endorsed history of unintended 40 pound weight loss and problems with his short term memory and concentration. Physical exam was significant for temporal wasting and brisk DTRs. The thyroid gland was normal size, non-tender, no nodules nor bruit appreciated. Echocardiogram revealed severe systolic dysfunction and he was admitted for decompensated heart failure. TSH was less than 0.01 and Free T3 and T4 were highly elevated. Thyroid stimulating immunoglobulin, thyroid peroxidase antibody, and thyrotropin receptor antibody were all within normal limits. Endocrinology was consulted, recommending a thyroid iodine uptake scan and ultrasound, which showed very low uptake and no hypervascularity or nodules on Doppler. He was diagnosed with Amiodarone Induced Thyroiditis type II and started on prednisone 40 mg daily.

It is imperative to differentiate between type 1 and type 2 AIT, a careful history and physical examination should be performed. An iodine-131 uptake test and color flow Doppler sonography should be performed, this is a useful tool for early diagnosis. Absent hypervascularity is seen on ultrasound and low to absent uptake is found in Type 2 AIT. This type is caused by a direct toxic effect of amiodarone. The thyrotoxicosis is a destructive thyroiditis where excess preformed T3 and T4 are released into the circulation. Amiodarone should be discontinued if possible. Type 2 AIT is treated with glucocorticoids, whereas type 1 is treated with antithyroid therapy.

123 RARE COMPLICATIONS OF UNCONTROLLED DIABETES MELLITUS

A Thomas, R Kunjal, K Rizg, KR Green, B Lyons, W Aung, N Guzman. *University of Florida Health, Jacksonville, FL.*

10.1136/jim-2016-000393.123

Case Report The vascular complications of Diabetes Mellitus (DM) are well known. However, there are less common, potentially fatal associations to keep in mind. Here, we discuss two such cases.

A 59-year old obese female with IDDM presented with a constant, vague left-sided flank pain and hematuria for three days. She denied fever, nausea, vomiting, or dysuria. Vital signs were unremarkable. Her physical exam was notable for left flank tenderness, multiple ulcerations over yellow-brown crusted plaques on her right anterior shin, and a superficial ulcer on her left heel. She stated she was diagnosed with necrobiosis lipoidica diabetorum (NLD) years ago at an outside hospital. Lab studies revealed blood glucose of 176 and Hba1c of 8.4%. Urine analysis showed 179 WBC's, 82RBC's, occasional bacteria and nitrites.

A non-contrast CT of the abdomen and pelvis was obtained to rule out acute pyelonephritis or nephrolithiasis. CT revealed extensive bladder wall gas. A foley was placed to decompress the bladder and she was started on empiric Vancomycin and Piperacillin-tazobactam. Her symptoms resolved by day 2 and the foley was removed. Urine culture grew mixed flora and she was switched to ciprofloxacin twice daily dosing for 14 days for complicated cystitis.

NLD is a chronic granulomatous dermatologic lesion. It's etiology is unclear but seems to be related to diabetic microangiopathy. Diagnosis is made by biopsy and management is with tighter glycemic control and wound care with topical or intralesional corticosteroids or immunomodulation. Complications can include ulceration and, rarely, squamous cell carcinoma.

Emphysematous cystitis (EC) is an infection of the bladder involving gas-forming bacteria or fungi. DM, among other immunosuppressed states, is one of its major risk factors. EC has a non-specific presentation, varying from asymptomatic to septic shock. It is often found incidentally on imaging during investigation for other pathologies. Management includes antibiotics and bladder drainage. If not treated immediately, the infection may ascend the urinary tract and cause emphysematous pyelonephritis, which carries a much higher morbidity and mortality. For this reason, physicians must consider EC within their differentials in diabetic patients presenting with UTI symptoms.

124 INCREASING ENDOCRINOLOGY REFERRALS FOR PEDIATRIC GENDER DYSPHORIA

LK Tumblin, M Sayles, D Bowlby, A Blue. *Medical University of South Carolina, Charleston, SC.*

10.1136/jim-2016-000393.124

Purpose of Study There is an increase in societal recognition of transgender people. Onset of puberty can increase dysphoria in children with gender dysphoria (GD). Pubertal suppression (PS) therapy is considered at the start of puberty to limit secondary sexual characteristics prior to initiating cross-gender sex steroids (SS).

Methods Used We described patients referred for evaluation of GD to the Pediatric Endocrinology clinic at MUSC. Data was collected on patients with initial visits between 2010 and 2016 through a retrospective chart review.

Summary of Results Measures of characterizing patients included gender, age, Tanner stage, and psychiatric history. Of the 39 patients, 9 had initial visits in 2014, 17 in 2015, 11 in 2016. The natal male: female ration is 1:1.8 with males presenting at an average age of 11.7 years (4–17 years) and Tanner stage 2.9 (1–5) and females average age 14.9 years (10–18 years) and Tanner stage 4.56 (1–5). With regard to endocrine treatment, 46% no medication, 8% PS only, 18% SS only, 28% combination PS/SS. The average age of starting endocrine therapy was 15.2 years (10–18). 69% of the patients reported psychiatric diagnoses: anxiety 33%, depression 38%, ADHD 15%, self-mutilation 18%, suicidal ideation/attempt 13%, insomnia 5%, bipolar 5%.

Conclusions Recently, GD referrals have increased, the majority being females however males present at a younger age. Half of the patients chose endocrine therapy. The majority had co-morbid psychiatric disorders. Increased community awareness of transgender issues in pediatrics will hopefully result in more referral at younger ages allowing consideration of endocrine therapy thus potentially improving clinical outcomes and increasing mental health support.

125 GALACTOSE SUPPLEMENTATION IN TMEM165-CDG PATIENTS RESCUES THE GLYCOSYLATION DEFECTS

TE Gadomski, S Wong, E Morava-Kozicz. *Tulane University School of Medicine, New Orleans, LA.*

10.1136/jim-2016-000393.125

Purpose of Study TMEM165 deficiency, a type of congenital disorder of glycosylation (CDG), is a severe multi-system disease that manifests with metabolic, endocrine and skeletal involvement. The clinical features of this disease are secondary to abnormal glycosylation, which, in this CDG, results from impaired Golgi manganese homeostasis and consequent impaired function of galactosyl transferases in the Golgi system. It has been previously demonstrated that the observed N-glycosylation defect can be overcome by in vitro galactose supplementation in TMEM165 knock out cells. We wanted to test the efficacy of galactose treatment in patients with TMEM165-CDG.

Methods Used Participants in this observational pilot study received oral galactose supplementation over 18 weeks. D-Galactose intake was increased over the study period as follows: weeks 0–6: 0.5 g/kg per day, weeks 7–12: 1.0 g/kg per day, weeks 13–18: 1.5 g/kg per day. Maximum daily intake was 50 g for any participant. Blood analysis was performed every 6 weeks to assess glycosylation and other biochemical parameters (endocrine and liver function, creatine kinase, thyroid and growth hormones, and coagulation and anticoagulation factors). Urinary galactose levels were measured as a safety parameter.

Summary of Results Treatment of our patients with oral galactose was well tolerated with high patient compliance. No galactosuria occurred with any dose of galactose. Galactose supplementation improved several lab results in our patients, namely coagulation parameters as well as IGF1 and IGFBP3 in Patient 1. Consistent with these observations, serum N-glycan analysis by mass spectrometry showed improved galactosylation in patients during galactose therapy.

Conclusions The effects of D-galactose supplementation were prospectively evaluated in TMEM165-CDG patients. We demonstrated that oral galactose supplementation improved biochemical and clinical parameters, including a significant increase in galactosylated transferrin isoforms, endocrine function and coagulation parameters. We recommend the use of oral D-galactose therapy in TMEM165-CDG patients.

126 INVOKAMET INDUCED KETOACIDOSIS

SM Zaidi, F Tawadros, M Jbara, G Murtaza, D Ginn. *East Tennessee State University, Johnson City, TN.*

10.1136/jim-2016-000393.126

Case Report Invokana (Canagliflozin) and Invokamet (Canagliflozin+metformin) are newer oral antidiabetic medications for treatment of patients with type II diabetes (DM2). The mechanism of action is inhibition of sodium-glucose co-transporter 2 protein (SGLT2), which reduces renal glucose reabsorption, thus reducing blood glucose levels. We present a case of Invokamet induced diabetic ketoacidosis (DKA).

Our patient is a 47 year old male with morbid obesity and recently diagnosed DM2 who presented to ED with complaint of 2 day history of shortness of breath along with severe nausea and vomiting. He had been started on Invokamet for glycemic control a week prior, after noting a hemoglobin A1c of 11%.

On exam he was in mild respiratory distress, tachycardic and demonstrated sluggish response to conversation.

He was noted to have a blood glucose level of 292 mg/dl, anion gap of 38 with a bicarbonate of 3 mmol/L and lactate level of 2.1 mmol/L. ABG showed pH of 7.1, pCO₂ of 7.1 mmHg with pO₂ of 189 mmHg. Moderate acetone levels were noted in blood. No obvious signs of infection on imaging or urine analysis were seen and his other lab work was unremarkable.

He improved markedly with IV insulin and fluid resuscitation. On follow up testing, he was noted to have a negative Glutamic acid decarboxylase (GAD65) antibody and negative pancreatic islet cell antibody.

Our case represents one of case series that have been reported across the country for Invokamet induced ketoacidosis. In May 2015 FDA issued a warning that (SGLT2) inhibitors may lead to ketoacidosis. Janssen Research & Development performed an analysis of all events of metabolic acidosis using the FDA Adverse Event Reporting System (FAERS) from March 2013 to June 2014 using data from 17,596 patients, and concluded that DKA and related events occurred at a low frequency in the Canagliflozin type II diabetes program, with an incidence consistent with limited existing observational data in the general population with type 2 diabetes.

With continuity of presentation of similar cases and the seriousness of presentation, further independent studies needs to be done, to determine the risk of Ketoacidosis associated with (SGLT2) inhibitors and whether there are specific risk factors that should be included in the contraindications list of the drug information.

Gastroenterology

Joint Plenary Poster Session and Reception

4:00 PM

Saturday, February 11, 2017

127 GASTRIC ANTRAL VASCULAR ECTASIA PRESENTS AS A POLYPOID MASS IN A CIRRHOTIC: A CASE REPORT

H Catherine, E Fontenot, LS Engel, S Landreneau. *LSU Health Sciences Center, New Orleans, LA.*

10.1136/jim-2016-000393.127

Case Report CASE: A 76 year old man with alcoholic cirrhosis was referred to the emergency room for microcytic anemia without overt signs of gastrointestinal bleeding. He noted mild fatigue and dyspnea with exertion without chest pain. He has a history of small esophageal varices without bleeding noted on EGD two years ago. His medical history includes diabetes, chronic kidney disease, hypertension, and hypercholesterolemia. On physical exam there was an early systolic murmur with the remainder being normal including normal vitals. Laboratory evaluation showed iron deficiency anemia (Hgb 6.1 mg/dL, MCV 70, Ferritin 17, Fe Sat 5%), but otherwise normal labs including baseline creatinine. An abdominal ultrasound showed a nodular liver without ascites. He was admitted, transfused, and EGD the following day showing linear erythema and enlarged folds in the gastric antrum, a polypoid fold/mass at the pylorus that was not bleeding, as well as small esophageal varices without stigmata of bleeding. A colonoscopy was unremarkable. An outpatient EUS showing spongy expansion of the mucosa and submucosa of the antrum with sonographically normal muscularis propria. Endoscopic biopsies were taken, which revealed vascular dilatation with fibrin thrombi consistent with GAVE. The lesion was ablated with argon plasma coagulation, and he was discharged with plans to repeat EGD in six weeks.

Discussion Gastric antral vascular ectasia (GAVE) accounts for 4% of non-variceal upper gastrointestinal bleeding (GIB). About 30% have cirrhosis and portal hypertension. GAVE is diagnosed endoscopically and confirmed by biopsy in difficult cases to help distinguish from portal hypertensive gastropathy, which is important for management decisions. Endoscopic ultrasound (EUS) may provide clarification when the endoscopic appearance resembles high-risk structures unsafe for direct biopsy in patients with known portal hypertension. EUS can also ensure complete therapy after ablation.

128 PANCREATIC ARTERIOVENOUS MALFORMATION WITH HEPATITIS C

H Catherine, L Murphy, H De Jesus, B Spieler, S Cajigas-Loyola, LS Engel. *LSU Health Sciences Center, New Orleans, LA.*

10.1136/jim-2016-000393.128

Case Report CASE: A 37 year old man with untreated hypertension, tobacco use, and remote intranasal cocaine

use presented to the emergency department with subjective fevers, productive cough, nasal congestion, and body aches. He was hypertensive, had a microcytic anemia and was found to be Hepatitis C positive on screening test. He was non-toxic appearing, diagnosed with a viral infection, and discharged with a follow up the hepatitis clinic for treatment. Screening ultrasonography for liver fibrosis staging revealed F0 to F1 indicating absent to mild fibrosis, no lesions concerning for hepatocellular carcinoma, and an incidental finding of clustered serpiginous low level echo structures with both arterial and venous flow in the head of the pancreas. A triple phase computed tomography (CT) was obtained for further investigation and showed a pancreatic arteriovenous malformation.

Discussion Pancreatic arteriovenous malformations (AVM) are rare. They are worked up with ultrasonography and then CT or magnetic resonance imaging. They should be characterized using with classification systems such as the International Society for the Study of Vascular Anomalies. Acutely, interventional or surgical procedures can be considered. But asymptomatic cases can be managed with treating comorbidities to reduce risk, in this case those include controlling hypertension and treating the Hepatitis C to prevent fibrosis and portal hypertension that can lead to bleeding and enlargement of the AVM.

The mechanisms of gastrointestinal bleeding includes duodenal ulcers due to local mucosal ischemic, pancreatic or biliary ductal bleeding through the ampulla of Vater, eroded vessels in the gastrointestinal tract wall caused by pancreatic AVMs, or from gastroesophageal varices due to portal hypertension caused by the pancreatic AVM. While this patient is asymptomatic without abdominal pain or overt GIB, he has a significant chronic microcytic anemia that may be indication his AVM is already causing bleeding. This requires further workup and close monitoring.

129 A RARE CAUSE OF ABDOMINAL PAIN

E Dauchy, M Modica, LS Engel, N Masri. *LSU Health Sciences Center, New Orleans, LA.*

10.1136/jim-2016-000393.129

Case Report Case A 54 year old woman with hypothyroidism presented with right flank pain that began acutely one week prior to presentation. She was told initially she had a urinary tract infection and treatment resulted in mild symptomatic improvement. The pain returned and she presented to another Emergency Department (ED) and was told the pain was due to constipation. She returned to the ED the next day when her pain worsened and her labs were notable for WBC of 19,000/uL, BUN/Cr of 28/0.75 mg/dL, AST of 31 U/L, ALT of 92 U/L and total bilirubin of 0.6 mg/dL. RUQ ultrasound was notable for dilation of the common bile duct. Given concern for choledocholithiasis, she was started on cefepime and metronidazole. MRCP demonstrated a distended gallbladder without stones and a small amount of pericholecystic fluid. Also noted were two areas of increased signal in the right kidney, concerning for neoplasia or infarction. Contrast abdominal Computed tomography showed a moderate size area of hypodensity, consistent with renal infarct. Workup

for embolic source of the infarction was unrevealing. Renal artery angiogram demonstrated a spontaneous dissection of the superior branch of the right renal artery. PCI was not performed due to risk of jeopardizing the other vessels and so she was managed medically with rivaroxaban along with hydrochlorothiazide and metoprolol succinate to keep her systolic blood pressure below 140 mmHg. The morning after the procedure, the patient told the treatment team that her grandson liked to jump from a height and she would catch him on her right side. This was felt to be a likely etiology of her spontaneous dissection. At the time of discharge, her pain was improved and repeat angiogram performed eight weeks later noted healing of the dissection.

Discussion Spontaneous renal artery dissection is a rare cause of abdominal pain and often presents a diagnostic and therapeutic challenge. This case highlights the importance of considering alternate etiologies of localized abdominal pain when other common pathologies have been excluded.

130 DEFINING NORMAL PANCREATIC DUCT SIZE BY ENDOSCOPIC ULTRASOUND IN THE ELDERLY POPULATION

Z Dickson,² S Duncan,¹ C Tombazzi¹. ¹University of Tennessee Health Science Center, Germantown, TN; ²University of Tennessee Health Science Center, Memphis, TN.

10.1136/jim-2016-000393.130

Purpose of Study With increasing availability and utilization of advanced imaging such as computed tomography and magnetic resonance imaging, gastroenterologists are tasked with the management and treatment of asymptomatic pancreatic cysts. The American Gastroenterology Association has determined that a patient must have two of three characteristics in order to proceed with endoscopic ultrasound: cyst size >3 cm, dilated pancreatic duct, and solid component of the cyst. What is unknown is what is considered a normal pancreatic duct in the elderly population. With increasing availability and utilization of advanced imaging such as computed tomography and magnetic resonance imaging, gastroenterologists are tasked with the management and treatment of asymptomatic pancreatic cysts. The American Gastroenterology Association has determined that a patient must have two of three characteristics in order to proceed with endoscopic ultrasound: cyst size >3 cm, dilated pancreatic duct, and solid component of the cyst. What is unknown is what is considered a normal pancreatic duct in the elderly population.

Methods Used 127 consecutive patients referred for EUS were included. One endoscopist performed all procedures and PD size in the body was obtained.

Summary of Results The average age in our cohort was 63.3 years and average pancreatic duct size was 1.8 mm in the body. See attached table for breakdown by age.

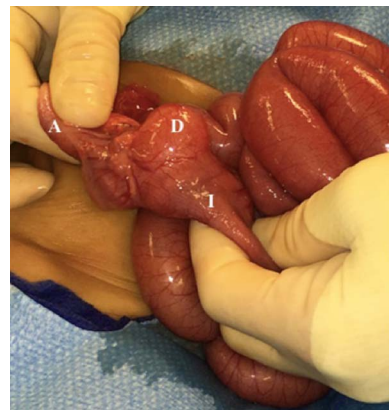Conclusions Our study demonstrated that there was a correlation between increasing age and increasing pancreatic duct diameter. The average pancreatic duct diameter in our population was much lower than what is considered the upper limit of normal for patients with pancreatic cyst.

131 FOUR MONTH-OLD INFANT WITH TERMINAL ILEUM DUPLICATION CYST

A Foldes. *UTSW, Dallas, TX.*

10.1136/jim-2016-000393.131

Case Report Enteric duplication cysts are rare, and are found more often in children than adults. There is much variation among characteristics of these cysts. They are usually diagnosed after associated serious complications, such as ileus, small bowel obstruction, intussusception, bowel rupture, hemorrhage, or pancreatitis. Here we describe an infant recently placed into Child Protective Services (CPS) custody, presenting with an acute onset of vomiting. After extensive workup, a terminal ileum duplication cyst was found and resected on exploratory laparotomy. The differential diagnoses are broad in any vomiting infant, but duplication cysts are not usually on the initial list of potential diagnoses. This case report briefly reviews the histology, suspected etiology, presentation, and treatment of duplication cysts.



Abstract 131 Figure 1 Terminal ileum duplication cyst at the level of the ileocecal valve. A, appendix. D, duplication cyst. I, ileum. Photo courtesy of Dr. Steve Megison.

132 THE UNEXPECTED BLEED: A CASE OF COLONOSCOPY-INDUCED SPLENIC HEMATOMA

J Gabriel, S Bhogal, A Kapila. *East Tennessee State University/Quillen College of Medicine, Johnson City, TN.*

10.1136/jim-2016-000393.132

Case Report Even the most common complications associated with colonoscopies are quite uncommon. This includes perforation and hemorrhage, occurring in only up to 2.67% and 0.72% of patients, respectively. Even less apparent, splenic hematoma can often occur unrecognized. Despite its rarity, this case shows the inevitable need for splenic injury to be considered due to its potential for detrimental outcomes.

A 64-year-old female presented with left upper quadrant abdominal and chest pain 30 minutes after a colonoscopy. Symptoms were lethargy, weakness, and light-headedness.

Medical history included hypertension, type 2 diabetes mellitus, and coronary artery disease. Her exam was significant for hypotension and abdominal tenderness in the left quadrants. CBC revealed normocytic anemia and mild thrombocytopenia. A focused assessment with sonography for trauma showed a peri-splenic stripe with peri-hepatic and cystic fluid collections. This prompted further imaging with computed tomography, which was positive for a large peri-splenic hematoma with hemorrhage extending throughout the left upper quadrant, liver, and pelvis. However, there were no active extravasation of arterial contrast. Without any indications for trauma and due to its temporal association with the procedure, a diagnosis of colonoscopy-induced splenic hematoma was made. Treatment was initiated with aggressive fluid resuscitation and blood transfusions. This conservative management was further supported by the surgical team and the patient's symptoms and cell counts gradually improved, requiring no further intervention.

This case highlights the importance of considering the unusual when faced with complications of a commonly performed procedure. Post-colonoscopy splenic injury has only been reported in a few cases since the 1970's. It is thought to be due to splenocolic ligament traction, adhesions, instrument looping, difficult intubation, and lesions at the splenic flexure. Conservative management can be tried for hemodynamically stable patients, but splenectomy is the definitive treatment for those who are unstable. With the increasing number of colonoscopies performed for the aging population, recognition of this complication is crucial in the prevention of further morbidity and mortality.

133 AN INTRIGUING CASE OF MICROCYTIC ANEMIA IN A PEDIATRIC PATIENT: COLLAGENOUS GASTRITIS

R Herdes, R Arrouk, M Stark. *Louisiana State University, New Orleans, LA.*

10.1136/jim-2016-000393.133

Case Report Collagenous gastritis is an extremely rare disease characterized by the presence of a thickened subepithelial collagen band, leading to the entrapment of capillaries and inflammatory cells within the gastric lamina propria. Affected individuals can present with a variety of symptoms, most often anemia, abdominal pain, or diarrhea. Pediatric patients predominantly present with nodular gastric mucosa on EGD secondary to edema. Anemia is the result of hemorrhage from dilated capillaries entrapped in the abnormal collagenous matrix. There is a suspected association between collagenous gastritis and autoimmune disorders. Given the rarity of collagenous gastritis, no standard treatment plan has been developed, although most case reports have utilized proton pump inhibitors with iron supplementation.

We describe the case of a 15-year-old male who presented for two months of intermittent abdominal pain and one month of increasing fatigue and pallor. He was found to have a severe microcytic anemia secondary to iron deficiency. EGD revealed diffuse gastric nodularity with associated erythema. Histopathology of the mucosa demonstrated subepithelial collagen with lymphocytic

infiltration. Trichrome stain confirmed the diagnosis of collagenous gastritis. Microcytic anemia was treated acutely with blood products and iron supplementation. Patient was treated outpatient with 8 weeks of proton pump inhibitor. He was monitored closely with repeat EGD and colonoscopy.

This case represents a unique etiology of microcytic, iron-deficiency anemia. While extremely rare, recognition of nodular gastric mucosa in a pediatric patient with abdominal pain and/or anemia, in the absence of *Helicobacter pylori* infection, should prompt consideration of collagenous gastritis. Patients found to have collagenous gastritis on pathology should receive a thorough work-up for autoimmune disorders and should be followed up closely with gastroenterology for repeat EGD and surveillance colonoscopy.

134 CHRONIC ABDOMINAL WALL PAIN: AN EASY DIAGNOSIS THAT SAVES UNNECESSARY EXPENSES

DF Hidalgo, M Zhang, J Phemister, J Swenson, M Young. *East Tennessee State University, Johnson City, TN.*

10.1136/jim-2016-000393.134

Case Report Chronic Abdominal Wall Pain (CAWP) is a condition where the pain originates from the abdominal wall itself (somatic pain) rather than from viscera underneath the wall (visceral pain).

The most common cause of CAWP is anterior cutaneous nerve entrapment syndrome (ACNES), first described in 1971(1). The cutaneous branches of sensory nerves (T7-T12) go through the posterior rectus sheath, passing through a fibrous ring. Normally, fat in the neurovascular bundle permits the nerve to slide unimpeded within the fibrous ring (2). Entrapment of the nerve can be caused by intra or extra abdominal pressure or localized scarring.

We report the case of a 52-year-old male presented with right upper quadrant (RUQ) pain for 4 days, 8/10, sharp, non-radiated and aggravated by palpation. Physical exam unremarkable, except for the pain described above. An abdominal ultrasound did not reveal gallbladder abnormalities. He was sent home and an outpatient hepatobiliary scintigraphy (HIDA scan) showed suspicious for common bile duct obstruction. He was sent to the Emergency Room again. A second physical exam showed the same picture than the one 2 days ago, with positive Carnett sign. Due to the abnormal HIDA scan, a magnetic resonance cholangiopancreatography was done which was normal. A solution of xylocaine with triamcinolone was injected at the site of the pain, relieving the pain and confirming the diagnosis.

ACNES is the most common cause of CAWP. It is diagnosed with physical exam (Carnett sign), where the leg-raising test is performed and the abdominal pain tenderness should remain the same or get worse to be considered positive, suggesting a somatic type of pain. Carnett sign has a sensitivity of 78% and specificity of 88%, combined with diagnostic criteria they reach 85% and 97% respectively for the diagnosis of this condition. (3)

Any clinician should be suspicious of this entity as it is an easy diagnosis and saves a lot of unnecessary expenses for patients and hospitals. A positive response (decrease of

pain of more than 50%) after an anesthetic injection is consistent with the diagnosis of nerve entrapment and therapeutic at the same time.

135 NOT YOUR TYPICAL VARICEAL BLEED

M Malik, E Huang, M Nazim, RD Smalligan, A Omer. *Texas Tech Univ HSC Amarillo, Amarillo, TX.*

10.1136/jim-2016-000393.135

Case Report Ectopic varices resulting from portal hypertension are uncommon, but like esophageal varices can be a life threatening condition if they bleed spontaneously. Bleeding abdominal wall varices are not much of a diagnostic challenge but they still lack an ideal therapeutic approach due to the rarity of this condition.

48 year old male presented to the emergency room (ER) with bleeding from his abdomen for one day. He had a history of heavy alcohol consumption, cirrhosis, diverticulitis, perforated colon requiring partial colectomy and diverting colostomy which was eventually reversed. After the colostomy reversal, he noticed a single 'blood blister' formation at the previous ostomy site. He had presented to the ER after waking up in a pool of blood and noticing active bleeding from that blister. On arrival, his vital signs were within normal limits. On examination, he was not in any distress. Cardiopulmonary exam was unremarkable. Several spider angiomas were noted on chest. No abdominal distention, shifting dullness or fluid thrill was appreciated but a single angiomatous lesion measuring 3 mm at the site of previous ostomy was actively oozing blood. On investigations, he had hemoglobin of 12.5 mg/dl, platelets 50,000 INR 1.29 and creatinine 1.2. An esophagogastroduodenoscopy (EGD) done 5 months earlier had shown Barrett's Esophagus but no gastroesophageal varices. CT scan revealed advanced cirrhosis with an abdominal wall varix corresponding to the site of the bleeding. On further inquiry, patient admitted to probing his blister recently. The patient underwent exploratory laparotomy wherein the feeding vein as well as several other surrounding small veins were clamped. Patient had a benign hospital course afterwards and was discharged in a stable condition.

Ectopic variceal bleeding accounts for 1–5% of all variceal bleeding, carrying up to 40% mortality risk for the initial hemorrhage. These varices can be around the small intestine, colon, ovaries, peritoneum, etc. Bleeding abdominal wall varices can be managed empirically by octreotide and nonsurgically by embolization and sclerotherapy. Our case was managed by surgically clamping the bleeding vessel. Regardless of the treatment modality chosen, the most important aspect of management is to prevent exsanguination and to keep the patient hemodynamically stable.

136 THROMBOTIC STORM IN ULCERATIVE COLITIS: A CASE REPORT

J Mefferd, D Gilliam, M Nowicki. *University of Mississippi Medical Center, Jackson, MS.*

10.1136/jim-2016-000393.136

Case Report Ulcerative Colitis (UC) is an idiopathic process that has been rarely associated with thrombotic

events, most notably in women. Though commonly diagnosed in adolescence, thrombotic events have been reported more often in adults. This case details a non-fatal event of thrombotic storm in UC. A fourteen year-old male with attention deficit hyperactivity disorder on methylphenidate, presented to clinic with complaints of crampy abdominal pain, diarrhea, and rectal bleeding. The differential diagnosis included inflammatory bowel disease (IBD), infectious enterocolitis, and celiac disease. Stool studies were negative. Colonoscopy showed underlying UC, with significant bleeding and friability. The procedure was aborted due to concern for bowel perforation. He was started on mesalamine, metronidazole, prednisone, and esomeprazole for treatment of severe UC. After two months of persistent symptoms he was started on infliximab therapy, but did not tolerate the medication and was changed to adalimumab. Three weeks later he presented to the pediatric emergency room with altered mental status, seizure-like activity, right-sided weakness, and left-sided facial droop. Imaging revealed thrombi in the left internal carotid artery, left middle cerebral artery, and left ventricle. Anti-phospholipid panel, lupus anticoagulant, anti-thrombin III, and anti-factor Xa were all negative. Aggressive anticoagulation was initiated, and patient had no further progression of thrombi, but persistent gastrointestinal bleeding led to colectomy. Infrequently reported in the literature, thrombotic embolic cases associated with the use of adalimumab in UC have been reported. Even more uncommon are cases of thrombotic embolic events associated with male children afflicted with UC. This case highlights the need for awareness of the risk of thrombotic events in IBD and with adalimumab treatment, and the need for prophylactic anticoagulation when appropriate, as the incidence of thrombotic events increases with hospitalization and more severe disease. On follow-up this patient has persistent right-sided hemiparesis despite extensive rehabilitation. While his UC symptoms are quiescent following colectomy, he remains on anticoagulant therapy.

137 SOLITARY RECTAL ULCER SYNDROME AND RECTAL PROLAPSE PRESENT WITH MULTIPLE RECTAL POLYPS

T Mingbunjerdasuk, S Suchartlikitwong, A Rakvit. *Texas Tech University Health Sciences Center School of Medicine, Lubbock, TX.*

10.1136/jim-2016-000393.137

Case Report A 40-year-old Hispanic woman with history of discoid lupus erythematosus presented with hematochezia. Her maternal aunt had history of colon cancer. Patient underwent colonoscopy which showed a diffuse nodular with white plaquish rectal mucosa and multiple sessile polyps in the rectum. Pathology is compatible with solitary rectal ulcer syndrome and mucosal prolapse.

Solitary rectal ulcer syndrome (SRUS) is an uncommon benign rectal disorder that usually presents with hematochezia. Endoscopic findings vary from mucosal erythema, ulceration, or mass lesions which can be similar to inflammatory bowel disease and malignancy. Pathology is necessary to make a diagnosis. It is associated with rectal prolapse. Treatments are bowel regimen with laxatives in mild case and surgery in severe case.

138 AN UNUSUAL CASE OF SMALL BOWEL MESENTERIC HYDATID CYST DISEASE

T Nguyen,¹ JP Garrido,¹ RD Smalligan,¹ D Graham². ¹Texas Tech Univ HSC Amarillo, Garland, TX; ²Hospital Vozandes del Oriente, Shell, Ecuador.

10.1136/jim-2016-000393.138

Case Report A 24yo Ecuadorian woman presented with a one-year history of constant mid-abdominal pain, worsening in the previous 4 months, accompanied by anorexia and a 10-lb. weight loss. On exam she was thin, had no adenopathy, but had a palpable, mobile mass in the mid-abdomen. Ultrasound showed two complex masses (6x4 cm and 3x2 cm). Labs were unrevealing. At exploratory lap 2 white masses were found embedded in the ileal mesentery. Soft, rubbery nodes were noted throughout the mesentery. The liver and remainder of the abdomen were free of gross disease. Pathology showed viable hydatid cysts, though the mesenteric nodes were simply hyperplastic. The patient recovered well and was treated with albendazole for 50 days. Ultrasound 8 mo later showed no recurrence.

Discussion Hydatid disease or cystic echinococcosis is caused by the tapeworm *Echinococcus granulosus* which has worldwide distribution with intermediate hosts being sheep, pigs and cattle. The liver is the most common site of cysts (70%) followed by the lungs (25%). Up to 1/3 of cases have multiple cysts. Any organ can be affected but it rarely presents as a primary mesenteric cyst. While hydatid diseases are initially asymptomatic, growing cysts can have mass effects and obstruct blood or lymphatic flow. Cyst rupture can cause anaphylaxis and secondary seeding. The rare times when hydatid cysts have been seen in the mesentery they have usually been due to inoculation from spontaneous rupture of nearby cysts, or trauma or iatrogenic. In our case there was no evidence of the disease in other organs. Primary and isolated small bowel mesenteric hydatid cyst disease seems to be quite rare. The weight loss and generalized malaise of the patient along with widespread intra-abdominal adenopathy made metastatic carcinoma a concern. Treatment options for hydatid disease include surgery, percutaneous management of hepatic lesions, pharmacotherapy or observation. In this case, due to the anatomical location of the disease, surgery (for definitive diagnosis and symptomatic relief) and adjunctive drug therapy were chosen and effective. The ideal duration of adjunctive drug therapy is not well defined. Follow-up ultrasound or CT is recommended for 3 years after treatment due to the possibility of recurrence.

139 COMPARED TO SOY OIL-BASED LIPID EMULSION, THE USE OF FISH OIL-BASED LIPID EMULSION MAY REDUCE THE RATE OF BLOODSTREAM INFECTIONS IN INFANTS WITH INTESTINAL FAILURE ASSOCIATED LIVER DISEASE

MH Premkumar, J Hagan, CR Mahesh, A O'Donnell, AR Arunachalam. *Baylor College of Medicine, Bellaire, TX.*

10.1136/jim-2016-000393.139

Purpose of Study The use of Fish Oil-based Lipid Emulsion (FOLE; Omegaven) has been shown to reverse

Intestinal Failure Associated Liver Disease (IFALD) seen with the use of Soy Oil-based Lipid Emulsion (SOLE; Intralipid). Blood stream infections (BSI) are common in patients with Intestinal Failure (IF). It is not known whether FOLE alters the rate of BSI in infants with IFALD compared to SOLE.

Methods Used Infants enrolled in the compassionate use protocol to receive FOLE in the treatment of IFALD between January 2014 and September 2015 were prospectively included. BSI was defined as a positive blood culture treated with antibiotics for ≥ 5 days. Random-effects Poisson regression models were used to examine both the bivariate association of treatment (FOLE or SOLE) with BSI rate and the multivariate association after adjusting for other risk factors for BSI.

Summary of Results 51 patients met study inclusion criteria, 34 (67%) of whom had at least one BSI. In the FOLE group, there were 37 BSIs over 4639 patient-days, compared to 26 BSIs over 2033 patient-days while on SOLE (BSI rate of 8 vs. 12.8 per 1000 patient-days, $p=0.089$), yielding a marginally lower BSI rate during FOLE treatment. After controlling for treatment dose, maximum conjugated bilirubin, birthweight (BW), and the type of intestinal stoma, patients had a significantly lower BSI rate while on FOLE ($p<0.001$). Subgroup analysis performed only considering times when both treatment doses were 1 g/Kg/day showed a significantly lower BSI rate during FOLE treatment compared to during SOLE treatment (8 vs 19.6 per 1000 patient days, $p=0.005$).

Conclusions In infants with IFALD, treatment with FOLE was associated with a significantly lower rate of BSI compared to the treatment with SOLE controlling for the dose of lipid, severity of liver disease, BW, and the surgical history. This decrease in the rate of BSI with FOLE treatment remained significant even when both treatments were given at low doses. This suggests that in addition to the well-known benefit of resolution of cholestasis, the use of FOLE in IFALD may reduce the rate of BSI, an effect never reported in the literature before.

140 OLD DISEASE IN NEW LOOKS: A CASE OF LUETIC HEPATITIS IN AN ASYMPTOMATIC NEUROSYPHILIS PATIENT

A Qasim, N Prabha, A Islam. *Texas Tech Univ HSC Amarillo, Amarillo, TX.*

10.1136/jim-2016-000393.140

Case Report 50 y old, Caucasian, homosexual male with no past medical history, presented with abdominal pain and new onset of non-pruritic skin rash. He is sexually active with one male partner for last 2 y. On exam, BP 134/80, HR 88, O2 sat 96% on RA. Had an elevated, non-tender, maculopapular rash involving chest, abdomen, extremities, including palms. No genital lesions or lymphadenopathy. Neuro exam: unremarkable. Abdomen was tender. Chest and cardiac exam: normal. Lab work: Alk phosph 975, ALT 71, AST 46, T.bil 1.2. US and CT abdomen showed Cholelithiasis, right hepatic 1.2 cm echogenic/hypodense lesion. MRCP: T2 weighted hyper intense foci in liver, no duct obstruction. HIV Ab, hepatitis panel -negative, but

positive RPR (titer 1:512) -confirmed by Treponemal test 'Treponemal Pallidum Particle-Agglutination Assay' TPPA. CSF: WBC count 1–2, glucose 140, total protein elevation 114. CSF VDRL was reactive. Following cholecystectomy, liver biopsy reported non-specific but confirmed hepatic involvement of Syphilis. With the above, immediate treatment was started with iv Benzathine penicillin, public health informed and patient counseled.

Discussion Syphilis is an STD caused by spirochete *Treponema pallidum*. Annual incidence rate increased from 2.9–6.3 cases per 100,000 (2005–2014) in the US. Serologic testing for syphilis include both non-treponemal (VDRL, RPR or TRUST) and treponemal tests (FTA-ABS, MH-TP, TPPA, TP-EIA, CIA). Neurosyphilis is confirmed by high wbc and protein in CSF and a reactive CSF-VDRL with/without clinical manifestations (asymptomatic neurosyphilis-as above). Leucic hepatitis is diagnosed by cholestatic picture on lab work and by biopsy.

Our case is unique: no reported cases of secondary syphilis with either luetic hepatitis or neurosyphilis in a non-HIV/viral hepatitis patient without primary disease. Emphasis should be made on considering Luetic hepatitis in patients with risky sexual behavior, skin rash and cholestasis. CSF should be checked to confirm asymptomatic neurosyphilis in every serologically confirmed syphilitic patient. Early treatment has proven to definitely decrease progression into serious disease.

141 METASTATIC ANAL CUTANEOUS MELANOMA MASQUERADING AS THROMBOSED HEMORRHOIDS

C Saraceni, W Chastant, M Spera, LS Engel, D Raines. *LSU Health Sciences Center, New Orleans, LA.*

10.1136/jim-2016-000393.141

Case Report Introduction: Anorectal melanoma is a mucosal melanoma, and is a rare form of this malignancy than the more common cutaneous melanoma: making up only 2.3% of all melanomas. Due to their anatomic location and lack of readily discernible signs and symptoms, they are frequently misdiagnosed as benign polyps or hemorrhoids.

Case A 48 year old man with no significant past medical history presented to the Emergency Department with a complaint of a bleeding anal mass. The patient first noticed the anal mass 8 months prior to presentation. The mass was initially reducible, however it had grown in size and was now non-reducible. It had become malodorous, oozy, and occasionally bled. The mass was associated with constipation, rectal pain, and bleeding with bowel movements. The perianal exam demonstrated a large 11 cm fungating, hyperpigmented mass draining serosanguinous fluid. Colonoscopy was performed and appeared normal to the cecum. The retroflexed view of the distal rectum and anal verge was normal and no anal or rectal abnormalities were noted. Hemorrhoidectomy surgery was performed to remove the mass. Histopathologic evaluation revealed malignant melanoma with positive margins. Immunostaining was performed and specimens were positive for S100, Mart-1, HMB-45. Computed tomography of

his abdomen and pelvis with IV Contrast revealed multiple pelvic lymph nodes and masses concerning for metastatic disease. Ultrasound guided fine needle aspiration and core biopsy of 2 separate right inguinal lymph nodes showed no definitive evidence of malignancy. A Chemotherapy regimen of novolumab and ipilimumab was initiated.

Discussion The initial evaluation of patients with AM should include a rectal examination, rectal ultrasound, and CT and/or PET imaging to assess for distant metastases. AM is excluded from the AJCC staging system for anal cancer. However, diagnosis remains difficult and is usually made after treatment for benign disease (ie hemorrhoidectomy), therefore many present with late stage disease with poor prognosis.

142 REFRACTORY TIPS-INDUCED HEMOLYSIS

X Solis, B Rosales, A Rakvit. *TTUHSC, Lubbock, TX.*

10.1136/jim-2016-000393.142

Case Report Hyperbilirubinemia after creation of transjugular intrahepatic portosystemic shunts (TIPS) has been attributed to hemolysis and portal diversion, but the causes and natural history of this condition remain unknown. TIPS-associated hemolysis may be asymptomatic or may be severe enough to present with severe anemia and high-output heart failure. This type of anemia is predominantly normocytic, with anisocytosis present. Patient with TIPS hemolysis have been known by previous studies to carry a worse prognosis.

Our case presents a 76 yo F with a history of Hepatitis C cirrhosis acquired via blood transfusions in 1982. The Hepatitis C was successfully treated with antiviral therapy.

However, the cirrhosis progressed and she developed decompensation in the form of hepatic hydrothorax, ascites, and LE edema. She continued to require regular paracentesis for refractory ascites, despite remaining compliant with fluid restriction, Lasix, and spironolactone.

She underwent TIPS placement on 8/9/16. Post-procedure the patient became transfusion dependent, with pre-TIPS hemoglobin was noted to be 11 mg/dl. 10 days later the patient's hemoglobin dropped to 8.5 mg/dl and hematocrit to 24.3%, RDW was 17.3%, total bilirubin rose to 5.0, indirect bilirubin 3.9, and direct bilirubin 1.1, lactate dehydrogenase 230, and haptoglobin <15, indicative of hemolysis. Resolution of TIPS-induced hemolysis was not observed in this patient and she remains transfusion dependent. Her bilirubin and INR continued to increase. She didn't want to proceed with liver transplant and was placed in palliative care.

TIPS-associated hemolysis is a phenomenon that can be observed in approximately 10% of TIPS patients. Resolution of hemolysis is usually observed within 12–15 weeks post TIPS placement, but a small percentage of these patients may never have resolution of hemolytic anemia. Treatment options for refractory TIPS-hemolysis can include extreme measures such as orthotopic liver transplant.

143 NISSEN FUNDOPLICATION AFTER FAILED JEJUNOSTOMY TUBE PLACEMENT IN REFRACTORY GERD

S Suchartlikitwong, T Mingbunjerdasuk, A Rakvit. *Texas Tech University School of Medicine, Lubbock, TX.*

10.1136/jim-2016-000393.143

Case Report Proton-pump inhibitors (PPIs) are the first-line treatment for gastroesophageal reflux disease (GERD). Up to 30% of patients with GERD are resistant or partial responded to PPIs¹. Several mechanisms are proposed to explain this condition including slow gastric emptying². Jejunostomy tube (J-Tube) placement in patient who has gastroparesis has highly successful response. The following case is a patient who failed J-Tube placement and needed fundoplication afterward.

History A 70-year-old Caucasian female has had GERD and hiatal hernia for many years. Her past medical history includes epilepsy, mild mental retardation, cerebrovascular disease, hypertension and hyperlipidemia. She has a PEG tube due to risk of aspiration. She was diagnosed with Barrett's esophagus in 2009, and underwent 3 radiofrequency ablations. She has been on high dose PPI (esomeprazole 40 mg twice daily) and carafate. Despite these treatments, the Barrett's esophagus was not entirely resolved and she later developed severe esophagitis (LA classification grade D³ esophagitis). Gastroparesis was suspected. However, gastric emptying study was not done due to mental status and risk of aspiration. She underwent J-tube placement and was exclusively fed through J-tube. Nine months after J-tube placement, EGD was performed and showed minimal improvement of esophagitis. She proceeded to have Nissen fundoplication. Follow-up EGD in 4 months post-operation showed healed esophagus.

Discussion Jejunostomy feeding is one of choices to treat refractory GERD, especially in patients who have component of gastroparesis. Theoretically, jejunostomy will bypass food directly into intestine and gastric pylorus helps to prevent food travelling backward into stomach. However, this patient failed medical treatment and J-tube placement and needed fundoplication to lessen gastroesophageal reflux and heal esophagitis.

REFERENCES

- 1 Sifrim D, Zerbib F. Diagnosis and management of patients with reflux symptoms refractory to proton pump inhibitors. *Gut*. 2012;61:1340–1354.
- 2 Fass R, Gasiorowska A. Refractory GERD: what is it? *Current gastroenterology reports* 2008;10:252–257.
- 3 Sami SS, Rangunath K. The Los Angeles Classification of Gastroesophageal Reflux Disease. *Video Journal and Encyclopedia of GI Endoscopy* 1:103–104.

144 RARE DIFFERENTIAL DIAGNOSIS FOR A COMMON PRESENTATION

E Turse, JZ Whatley, AM Parker, P Hosseini-Carroll, NK Gupta, WM Meeks. *University of Mississippi Medical Center, Jackson, MS.*

10.1136/jim-2016-000393.144

Case Report With the increasing prevalence of atherosclerosis, peripheral artery disease (PAD), and aortic vascular diseases surgical interventions such as aorto-bifemoral

bypass are becoming more common. Rarely, in 0.36%-1.6%, aortoenteric fistulas can develop following bypass leading to hematemesis or hematochezia.

A 41-year-old female with diverticulosis, and PAD with prior aorto-bifemoral bypass complicated by methicillin resistant *Staphylococcal aureus* infections, complained of a one day history of hematochezia. Physical exam was notable for large midline scar, left brachial peripherally inserted central catheter and hematochezia on rectal exam. Computed tomography angiogram of her abdomen and pelvis demonstrated diverticulosis and a 9-millimeter iliopsoas abscess. Prior to admission, her hemoglobin and hematocrit (H&H) were 8.5/26.9 which decreased to 7.6/24.6 with a mean corpuscular volume 94.6.

During endoscopic evaluation, a foreign body was found in the second portion of the duodenum. This was the patient's aorto-bifemoral artery graft causing a secondary aortoenteric fistula. She was transferred to the intensive care unit and vascular surgery took the patient for aorto-iliac bypass and excision of her infected graft. During this operation, a four-centimeter erosion of the duodenum with bile staining on the aortic graft was seen confirming secondary aorto-enteric fistula. Unfortunately, due to the patient's significant PAD, she had a complicated hospital course prior to discharge.

While hematochezia from diverticular bleeding is extremely common, other differential diagnoses must be considered in patients who have had vascular procedures such as aorto-bifemoral bypass. Having a broad differential of diagnoses including secondary aortoenteric fistulas in these patients can allow swift endoscopic evaluation in appropriate settings such as the operation theater. Doing so will allow for safe revision and a decrease in the morbidity and mortality (13%-86%) associated with such findings. Interestingly, such fistulas are usually found in the third or fourth portion of the duodenum and typically present with hematemesis while our patient's was in the second portion and presented with hematochezia.

145 ETHANOL LOCK FREQUENCY AND LINE OCCLUSION RATES IN PEDIATRIC INTESTINAL FAILURE

C Wallace, T Woodfin, L Wilkinson, T Jackson, I Aban, R Dimmitt, C Martin, D Galloway. *University of Alabama - Birmingham, Birmingham, AL.*

10.1136/jim-2016-000393.145

Study Purpose To investigate how the frequency of ethanol lock usage influences the rate of line occlusion and central line associated bloodstream infections (CLABSI's) in children with intestinal failure (IF)

Methods This was a retrospective chart review cohort study in children with IF at Children's of Alabama hospital at the University of Alabama at Birmingham. Two cohorts of ethanol lock usage were compared (≤ 3 days weekly AND > 3 days weekly). Study variables recorded were number of days of ethanol lock usage, number of CLABSI's, number of line occlusions. Rates were calculated per 1000 catheter days and comparisons were made using Wilcoxon signed-rank test.

Results There were 15 subjects in the first cohort (≤ 3 days weekly) and 33 subjects in the second cohort (> 3 days

weekly). Line occlusion events were more common in the second cohort (4.33 vs 0.22, $p=0.003$) while there was no difference in CLABSI rate among cohorts (3.48 vs 3.92, $p=0.548$)

Conclusions Line occlusion events occurred less frequently among our cohort when ethanol locks were used for ≤ 3 days weekly. Frequency of ethanol lock usage did not impact the rate of CLABSI in our population. Larger prospective studies are needed in order to better understand the potential impact of ethanol locks on line occlusion in the pediatric IF population.

146 SPLENIC VEIN THROMBOSIS IN A YOUNG MALE WITH ALCOHOL DEPENDANCE

DF Hidalgo, C Onweni, M Zhang, J Phemister, M Srinath, M Young. *East Tennessee State University, Johnson City, TN.*

10.1136/jim-2016-000393.146

Case Report Splenic vein thrombosis is a complication most commonly associated to recurrent pancreatitis, resulting in left-sided portal hypertension and isolated fundal varices formation. Hemorrhaging from gastric varices is low but it is associated with higher morbidity and mortality rates than hemorrhage from esophageal varices (1); this is why is it important to identify and diagnose splenic vein thrombosis, in order to treat and prevent the complications listed above.

Splenectomy is probably not indicated until a hemorrhage occurs (2). It has been reported that gastrointestinal bleed from gastric varices is a rare complication (3). But when present, splenectomy should be performed as fundal varices disappeared after splenectomy (3).

The purpose of this report, is to review practice guidelines - if available, and the applicability to our patient.

We report the case of a 28-year-old alcoholic man with multiple admissions for alcohol detoxification and pancreatitis. His other medical history includes erosive gastritis and hepatitis C. He has been vomiting red blood for the last five days, with chronic upper abdominal pain and dark stools. Abdominal Computerized tomography showed chronically thrombosed/atrophied splenic vein with prominent gastro splenic and gastro esophageal varices. An Esophagogastroduodenoscopy showed severe esophagitis, isolated gastric varices and mild portal gastropathy.

Wedged hepatic venous pressure of 12 and a calculated hepatic venous pressure gradient of 5 were found. (N:5–10) With this values portal hypertension was ruled out.

Splenic Vein Thrombosis is not uncommon in patients with recurrent or chronic pancreatitis. Of these, 53% of cases have been associated with gastric varices, and among them, only 12% will ultimately bleed.

Since the chief complaint of our patient was dark stool for months and EGD showed gastric varices, splenectomy was recommended (4). But due to patient recurrent admission for alcohol detoxification, surgery and interventional radiologist team decided that splenic artery embolization would be a more tolerable procedure for him.

147 PSEUDOMELANOSIS DUODENI: RELATION WITH END STAGE RENAL DISEASE AND USE OF ANTI-HYPERTENSIVE MEDICATIONS

M Zhang,¹ DF Hidalgo,¹ J Phemister,² M Srinath,² J Swenson,² M Young². ¹East Tennessee State University, Johnson City, TN; ²ETSU, Johnson City, TN.

10.1136/jim-2016-000393.147

Case Report Pseudomelanosis duodeni (PD) is a rare condition where the duodenum has a dark speckled appearance seen on esophagogastroduodenoscopy (EGD). We report a 71-year-old male with history of iron deficiency anemia, stage 4 chronic kidney disease, hypertension presented to the hospital with symptomatic anemia, shortness of breath, and abdominal pain. EGD was done, which showed erosive gastritis, large duodenal diverticulum, and discoloration with dark pigmented speckles on the duodenal mucosa. Random duodenal bulb biopsies were taken. Histopathology report showed presence of patchy aggregates of macrophages containing granular brown to black pigments within the superficial lamina propria consistent with the diagnosis of PD. Prussian blue stain was negative for iron deposition, although iron stain was positive in some reported PD cases. A case series done in 2008, 17 adult patients who were histologically diagnosed with PD, iron stain was entirely positive only in 18 % of patient, which may suggest a multifactorial cause of substance deposition (Giusto D et al. 2008; 40:165–167). It must be differentiated from melanosis coli that occurs mainly in the colon and is associated with chronic laxative use. This is supported by the patient we report who did not have a history of chronic laxative use. Hemochromatosis would be another major differential if iron stain is positive. PD has been mostly reported to be an incidental finding on EGD which has association with the use of anti-hypertensive medications, iron supplements, chronic kidney disease and anemia.

148 FUNDIC GLAND POLYPOSIS: RELATION TO CHRONIC ANTACID USE AND RISKS OF CANCER

M Zhang, DF Hidalgo, J Phemister, M Srinath, M Young. *East Tennessee State University, Johnson City, TN.*

10.1136/jim-2016-000393.148

Case Report Fundic gland polyposis (FGP) is a rare condition that consists of multiple polypoid projections in the fundus or body of the stomach seen on esophagogastroduodenoscopy (EGD). We report a 58 year old male with history of iron deficiency anemia, gastroesophageal reflux disease (GERD), Barrett's esophagus presented with chronic symptoms of acid burn and epigastric pain which responded to chronic use of proton pump inhibitor (PPI). EGD showed prominent gastric folds and revealed multiple fundic gland polyps. Biopsies were taken and histology confirmed the diagnosis. Colonoscopy showed few transverse colon polyps which turned out to be tubular adenomas. Most FGPs occur sporadically. Sometimes the

condition is associated with chronic use of PPI or polyposis syndromes. Studies have shown that long term use of PPI was associated with a fourfold increased incidence of fundic gland polyps (Jalving M et al. 2006;24(9):1341). Fundic gland polyps occur in 20 to 100 percent of patients with FAP and 11 percent of patients with MAP (Vogt S et al. 2009; 137(6):1976). Although gastric and hyperplastic adenomas are known to be associated with *Helicobacter Pylori* (*H. pylori*) infection, patients with active *H. pylori* infections were being reported to have regression of fundic gland polyps. The possibility of a familial polyposis syndrome should be considered in patients with >20 polyps, young age of onset or concurrent small bowel polyps, and screening colonoscopy should also be performed.

Global Health

Joint Plenary Poster Session and Reception

4:30 PM

Saturday, February 11, 2017

149 WHEN CULTURE AND LANGUAGE BARRIERS CAN BE BLINDING

CM Young, MB Bhatia, L Scott, RD Smalligan. *Texas Tech Univ HSC Amarillo, Amarillo, TX.*

10.1136/jim-2016-000393.149

Case A 21 yo Burmese woman immigrated from a refugee camp and presented with worsening vision. She had PMH of recently treated leprosy and afterward developed erythema nodosum leprosa (ENL) type 2. The patient spoke some English and worked at a local factory. Meds: 1 yr of prednisone 40 mg qd; methotrexate 2.5 mg 8 tabs qwk; folic acid 1 mg. PE: multiple tender, erythematous nodules on face and extremities; visual acuity: blind OD and 20/50 OS with EOMI and neuro exam otherwise nl. Repeated attempts at weaning steroids failed. Pt was hospitalized for sepsis-like flares 3 times in a year. Physicians documented 'no visual problems' at these visits. With an interpreter it was found she had been losing vision for months but culture and communication barriers likely interfered with relaying this. In conjunction with National Hansen's Disease program she had an ophthalmology evaluation and was dx with severe glaucoma related to high dose steroids. Further questioning via interpreter revealed a visit to an eye doctor some time before where further workup was recommended but not done due to cost and distance.

Discussion This heartbreaking case is presented to illustrate several important points. First, ENL can cause life-threatening illness that mimics sepsis and painful skin lesions as seen in our patient. Treatment is high dose steroids with taper as able using steroid sparing agents. Though uncommon, ENL can also cause severe eye problems including iritis and iridocyclitis thus questions about visual acuity and vision testing should be done routinely in these patients. Next, even in medical conditions that are known to cause eye problems, other etiologies need to be considered when problems arise. In this case, none of the known eye conditions occurred, but a known possible side

effect of high dose steroids was the cause: glaucoma. Treatment was started right after diagnosis and her left visual acuity has stabilized but the prognosis of the right eye is poor. Third, it is imperative to obtain proper interpreters for refugees who speak marginal English. This patient was pleasant and agreeable at visits and seemed to understand, but apparently was not understanding questions being asked during regular appointments. Obtaining better history via an interpreter may save someone's vision or life.

Health Care Research and Quality Improvement

Joint Plenary Poster Session and Reception

4:30 PM

Saturday, February 11, 2017

150 QUALITY IMPROVEMENT INITIATIVE TO REDUCE SEPSIS EVALUATION AND ANTIBIOTIC UTILIZATION RATES IN HEALTHY NEWBORN INFANTS

J Bhat, R Gulati, O Jha, R Bhat, K Peevy, M Zayek. *USA, Mobile, Alabama, Mobile, AL.*

10.1136/jim-2016-000393.150

Purpose of Study Over the past decade, the incidence of early onset sepsis (EOS) has been declining, but the sepsis evaluation rate (SER) and the antibiotic utilization rate (AUR) for suspected EOS are still high. The Kaiser neonatal sepsis calculator has been proven to limit unnecessary work-ups and to safely reduce the empirical use of antibiotics. Our objective is to reduce SER and AUR by 20% from the baseline values of 24% and 6% respectively, by January 2017, among well appearing infants who were ≥ 34 w gestation age admitted to newborn nursery (NBN). The goal will be achieved by implementation of the Kaiser Sepsis Score (KSS) with cut-off values established at our institution.

Methods Used We are planning multiple PDSA cycles to achieve our goal. During the first PDSA cycle, we prospectively collected data on all the newborn infants admitted to NBN starting from June 1st 2016 to August 31st 2016, to determine our baseline AUR and SER. We calculated but did not clinically apply KSS on all infants who underwent a sepsis evaluation to determine our center specific cut-off scores and to determine the magnitude of reduction in the SER and AUR that could be safely achieved by using KSS cut-off values. Training for nurses and house staff for optimal utilization of the sepsis algorithm was initiated, and data collection was begun after implementation of the KSS protocol. The SER and AUR rates were compared

Summary of Results During the PDSA cycle 1, 126 (24%) out of 530 well appearing newborn infants admitted to NBN were evaluated for EOS. Empirical antibiotic treatment was initiated in 32 (6%) newborn infants. None had blood culture proven EOS, however nine infants (2%) received a prolonged duration (5–7 days) of antibiotics for suspected clinical sepsis. By using the Kaiser Incidence of EOS and applying the center specific KSS cut-off values of

0.05 to initiate an evaluation and 0.3 for empiric antibiotic therapy, we could have reduced SER by 50% and AUR by 19%. Data collection after the implementation of the algorithm is ongoing.

Conclusions Implementation of the Kaiser sepsis calculator using center-specific KSS cut-off scores for both evaluation and treatment is useful in reducing the SER and AUR in our newborn nursery.

151 DO CAREGIVERS UNDERSTAND THE TRIAGE PROCESS?

MG Brennard, K Monroe. *University of Alabama at Birmingham, Birmingham, AL.*

10.1136/jim-2016-000393.151

Purpose of Study Triage is a quick evaluation of patients to help determine how urgently they should be seen by a provider in the emergency department (ED). Caregivers have demonstrated appropriate self-triage for their children, however, there is no information on whether educating about triage might improve caregivers' experience in the pediatric ED. We set out to compare the caregivers' triage scores with nurse-assigned triage scores, as well as the caregivers' score for common chief complaints both before and after a scripted educational intervention.

Methods Used This study utilized a prospective, convenience sample of caregivers presenting to an academic pediatric ED. Caregivers were surveyed to evaluate their agreement with the triage score and test their implementation of the triage score for common complaints. Emergency Severity Index (ESI) is used in our institution for objective triage. Our study included patients with ESI 2–5 with any chief complaint in an English-speaking family. Caregivers excluded if the patient was ESI 1, non-English-speaking, or transported by ambulance from another facility. **Week 1:** Caregivers experienced triage as usual in our ED prior to completing the survey. **Week 2:** After triage score was assigned, research staff read a card with scripted information about our triage process and then provided that card to each caregiver prior to the survey.

Summary of Results The average age and gender of the caregivers tested was 34 years with 91% female, and a large majority were the patient's mother (82%). Caregivers who received verbal education about the triage process and given that text on a card had over 3 times the odds of agreement with the staff-assigned triage score compared to caregivers that had not received the card (OR=3.2, 95% CI 1.5–7.3). Our current data suggests that almost 30% of the total caregivers recorded the correct triage category for 5 out of the 7 common complaints.

Conclusions Triage in the ED can be a confusing process. Preliminary data suggests that providing verbal and written text about the triage process to caregivers may contribute to more agreement with the triage score given by nurses. Future study will include analysis of the caregivers' knowledge of assigning the correct triage category with and without this additional triage education.

152 CHARACTERISTICS OF PATIENTS WITH CHRONIC OBSTRUCTIVE PULMONARY DISEASE WHO ARE READMITTED WITHIN 30 DAYS FOLLOWING AN ACUTE EXACERBATION

AC Castillo, H Edriss, K Selvan, K Nugent. *Texas Tech University Health Sciences Center, Lubbock, TX.*

10.1136/jim-2016-000393.152

Purpose of Study The Hospital Readmissions Reduction Program targets Medicare patients with congestive heart failure, acute myocardial infarction, pneumonia, and COPD and penalizes hospitals which have an increased 30-day readmission rate. Approximately 20% of patients with acute exacerbations of COPD are readmitted within 30 days. Analysis of these readmissions can help hospitals and clinicians identify patients at risk for readmission and identify possible deficiencies in the patient care.

Methods Used We retrospectively reviewed medical records of patients with acute exacerbations of COPD who were readmitted to the hospital within 30 days of discharge. We collected information on patient demographics, on comorbidity, on laboratory and radiographic information, and on management; based on record review we identified the clinical diagnosis which best explained the readmission.

Summary of Results We identified 27 admission-readmission hospitalization events in 16 patients with acute exacerbations of COPD between 1/1/2011 and 12/31/2015. The mean age was 73.4 ± 6.9 ; 66.7% were men. These patients had frequent comorbidities, including CAD (40.7%), HTN (96.3%), DM (33.3%), and CKD (25.9%). The initial chest x-rays were clear in 81.5%, showed infiltrates in 11.1%, and showed cardiomegaly in 14.8%. Nineteen percent of the admissions required mechanical ventilation. The length of stay for the index hospitalization was 4.7 ± 2.5 days; 92.6% of patients were discharged home. Most patients (61.5%) were readmitted with an acute exacerbation of COPD within with an average interval of 15 ± 8.4 day since discharge. Following the second hospitalization more patients (25.9%) were discharged to nursing facilities. These patients had a mean of 2.7 ± 1.9 hospitalizations for all causes during the 12 months prior to their index admission.

Conclusions Patients with acute exacerbations of COPD who require readmission within 30 days are older, have frequent comorbidity, have short lengths of stay during the index admission, and are discharged home following hospitalization. The time interval before readmission provides adequate time for clinic follow-up. These patients are easily identified by their past history of frequent admissions.

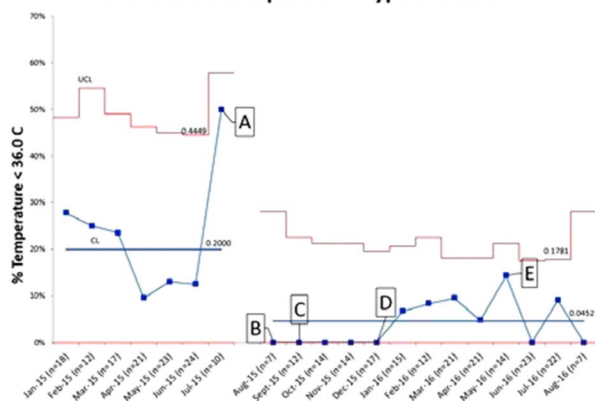
153 MULTIDISCIPLINARY TEAM CREATION AND AUDITING IMPROVE NEONATAL POSTOPERATIVE HYPOTHERMIA

C Day, C Heine, S Meany, J Ross. *Medical University of South Carolina, Charleston, SC.*

10.1136/jim-2016-000393.153

Purpose of Study Neonates, especially those requiring surgery, are at increased risk of hypothermia. Our NICU

Neonatal Postoperative Hypothermia



Abstract 153 Figure 1

had an average incidence of postoperative hypothermia of 23%. We aimed through a multidisciplinary team and auditing to decrease our postoperative hypothermia $<36^{\circ}\text{C}$ to $<10\%$.

Methods Used Process mapping of the perioperative course resulted in a key driver diagram, with primary drivers: education, patients, equipment, environment, time, and leadership. PDSA cycles were initiated sequentially (Figure 1), including creation of a multidisciplinary team (A), education (B), a comprehensive audit (C-D), and a log sheet (E).

Summary of Results 36 charts were audited. 0% had postoperative temperatures $<36^{\circ}\text{C}$; however, 6 were $<36.5^{\circ}\text{C}$. Of those, 5 had GAs less than the median (35 3/7 wks), 1 had a PMA at time of surgery less than the median (38 3/7 wks), and 1 had a wt at time of surgery less than the median (2.94 kg). Following the audit, there was an increase in postoperative hypothermia to $>10\%$, prompting initiation of the next PDSA cycle (revised log sheet). Since initiation, rates of hypothermia have remained $<10\%$.

Conclusions We saw a significant decrease in postoperative hypothermia during the audit but then an increase to $>10\%$ following the audit, likely secondary to decreased focus in the absence of significant culture change. A subsequent PDSA cycle with initiation of a log sheet once again achieved our primary outcome measure.

154 NEONATAL INTENSIVE CARE UTILIZATION IN KENTUCKY: IMPACT OF NEONATAL ABSTINENCE SYNDROME

S. Duncan. Univ Louisville, Louisville, KY

10.1136/jim-2016-000393.154

Purpose of Study Kentucky is at the epicenter of the opioid epidemic. Annual cases of Neonatal Abstinence Syndrome (NAS) continue to rise. Recent publications have suggested an ever-increasing utilization of neonatal intensive care (NICU) across all weight ranges. We hypothesized that NAS significantly impacts the utilization of neonatal intensive care.

Methods Used Kentucky Annual Hospital Utilization and Services Reports were accessed from 2000–2015. Births, Level II NICU Days, Level III NICU Days and Total NICU Days were recorded, along with the annual number of NAS cases. Regression analysis was performed.

Summary of Results Total NICU Patient Days increased annually during the period of 2000–2015 ($R^2=0.93$, $p<0.001$). The number of births did not demonstrate a linear increase. NAS cases increased from 19 in 2000, to 1,234 in 2015 ($R^2=0.84$, $p<0.001$). Regression analysis of Total Births and NAS demonstrated a significant effect of NAS on Total NICU Patient Days (Adj $R^2=0.84$, $p<0.001$).

Data for Level II and Level III Patient Days was not recorded until 2005. Level II Days increased annually ($R^2=0.89$, $p<0.001$), whereas Level III Patient Days did not demonstrate an annual trend. The individual contribution of Level II Days to Total NICU Days was significant ($R^2=0.92$, $p<0.001$). Regression modeling of Total Births and NAS on Level II Days revealed the influence of NAS (Adj $R^2=0.7$, $p<0.05$).

Conclusions State and regional level data may reveal trends in NICU utilization over time. This data demonstrates a rise in Level II NICU days as contributor to overall NICU utilization, primarily as a result of NAS. Further study is suggested to assess the influence of NAS and related factors on NICU utilization.

155 FALSE POSITIVE ELEVATION IN SERUM β -HCG LEVELS IN TRAZADONE OVERDOSE

E Juarez Ramirez Tello,¹ A Adiga,¹ K Nugent². ¹Texas Tech Health Science Center, Lubbock, TX; ²Texas Tech University, Lubbock, TX.

10.1136/jim-2016-000393.155

Case Report 51 years-old lady with history of bipolar disorder was admitted to the hospital after a suicide attempt. She had ingested unknown amount of trazadone few hours prior to hospitalization. Her blood pressure was 96/60 mm Hg, heart rate was 48/min, respiratory rate 16/min and she was afebrile. Her systemic examination did not reveal any specific findings. Her laboratory evaluation showed hemoglobin 14.3 g/dl, WBC count was 6.87 cells/cumm, 215 cells/cumm, complete metabolic profile was normal except for anion-gap of 17. Her urine drug screen was positive for amphetamines. Her blood alcohol, salicylate and acetaminophen levels were negative. Her serum β -HCG was positive, on quantification repeated twice showed levels of 8 MIU/m and 6 MIU/ml (normal 5 MIU/ml). To confirm the laboratory findings she underwent transvaginal ultrasound which did not show any evidence of pregnancy.

Trazadone is the 6th commonly prescribed psychiatric medication with almost 19 million prescription every year, is used as an antidepressant, anti-anxiety and hypnotic medication acts by serotonin reuptake inhibition and antagonist activity, its metabolite chlorophenylpiperazine can cause false positive urine amphetamine tests, which is seen in our patient. Several anti-anxiety medications like diazepam, alprazolam, azapirones and hydroxyzine are known to cause a rise in β -hCG level. Antipsychotics associated with

rise in β -hCG are droperidol, chlorpromazine, clozapine, trifluorpromazine, thiorodazine. Antiepileptic drugs and some anti-parkinson medications like bromocriptine and benztropine can also determine a rise of the hCG level in urine. A large cohort study which studied the effects of antidepressants on hormone levels revealed that antidepressant exposure affects mean levels of inhibin, β -hCG, and estriol. The literature regarding trazadone in particular causing a rise in HCG level is limited. The mechanism underlying this elevation is thought to be interference with the invitro immunoassay. False positive β -HCG levels associated with these medications needs confirmation with transvaginal ultrasound.

Rarely trazadone and other antidepressants are known to interfere with invitro immunoassays leading to false positive results.

156 EFFECT OF REGIONAL CME ON PROVIDER ACCESS TO PEDIATRIC DIDACTICS AND REFERRAL RATES TO A SUB-SPECIALTY MEDICAL HOME AMONG MILITARY TREATMENT FACILITIES: A QUALITY IMPROVEMENT INITIATIVE

SM Marchegiani,^{2,1} JE Emerick,^{1,3} MG Elrod,² C Sullivan,^{3,1} RE Gardner,¹ TC Newton,^{1,3} J Venrick.³ ¹Walter Reed National Military Medical Center, Silver Spring, MD; ²Naval Medical Center Portsmouth, Portsmouth, VA; ³Uniformed Services University of the Health Sciences, Bethesda, MD.

10.1136/jim-2016-000393.156

Purpose of Study Active duty, contract and government service providers caring for patients in military treatment facilities (MTFs) have variable access to pediatric continuing medical education (CME) due to clinic demands, Department of Defense (DoD) budgeting and varied GME proximity. As a quality improvement (QI) project we created a symposium to increase pediatric CME by 6.5 hours for MTF providers in the National Capital Region (NCR) at no-cost to the DoD. A second project aim assessed provision of CME on sub-specialty referral rates to the NCR sub-specialty medical home.

Methods Used Pre-participation surveys were sent by electronic mail to pediatric and family medicine MTF providers before each symposium. The survey was also included in the on-site symposium evaluation. Surveys assessed current MTF access to pediatric CME, conference attendance, demographics and desired provider topics. Impact of the QI activity on sub-specialty referral rates was evaluated by the mean change in sub-specialty referral numbers from six and three months prior to each symposium to the numbers three and six months after using one sample t-tests.

Summary of Results National conference attendance among 65 survey respondents was 34%. Over 60% of respondents reported <10 hours of pediatric CME each year at their MTF. Regional symposium attendance resulted in a 65% access increase to pediatric CME for this demographic. An increase of 76 (SD 108.7, $p=.009$) and 65 (SD 98, $p=.009$) referrals at six months was observed in 2015 and 2016, respectively. An increasing trend for sub-specialty referrals was also observed for each year at 3

months. Referral increases were not influenced by the sub-specialty topics presented.

Conclusions These data indicate that regional didactic quality improvement initiatives can significantly increase access to pediatric CME for MTF providers and affect sub-specialty referral rates to a military medical home. Referral patterns suggest access to pediatric CME alone is sufficient to improve regional patient recapture.

157 USE OF AN ONLINE IMMUNIZATION REGISTRY IN THE PEDIATRIC EMERGENCY DEPARTMENT TO CONFIRM TETANUS VACCINATIONS AS UP TO DATE WITH INJURIES REQUIRING TETANUS VACCINATION IN CHILDREN WHO PRESENT TO THE EMERGENCY DEPARTMENT

J McCall, C Zeretzke. University of Florida, Gainesville, FL.

10.1136/jim-2016-000393.157

Purpose of Study This study was designed to retrospectively review patients who received tetanus vaccination in the Emergency Department and compare with data from a statewide database on vaccination status (FL SHOTS) to determine if vaccination was indicated at the time of presentation to the emergency department.

Methods Used We retrospectively reviewed all pediatric patients who received a tetanus vaccine in the Gainesville and Jacksonville University of Florida Emergency Departments from January 2011 to May 2015. The FL SHOTS database was accessed to determine vaccination status of the patients prior to the vaccine administration.

Summary of Results So far, the data of 100 pediatric patients who received the tetanus vaccine in the ED have been reviewed. In this group of patients, 15% of the children received the vaccine despite at least one source stating that they were already up to date. Two percent of patients receiving the vaccine were previously up to date per both sources.

Conclusions We will continue to move forward with this study. There are 455 patient charts collected for review in total. Once the data is finalized, we will review those patients who received the vaccine unnecessarily to discover what factors led to the vaccine administration. This may include the non-utilization of FL SHOTS at the time of administration. If the data hold true at the end of the study, implementing a more complete system of reviewing vaccination status prior to administration of the tetanus vaccine could save up to 15% of related costs in our ED settings.

158 ENHANCING THE REACH OUT AND READ PROGRAM AT A RESIDENT PRACTICE CLINIC

K McKnight,¹ M Hare,^{1,2} J Yaun^{1,2}. ¹University of Tennessee Health Science Center, Memphis, TN; ²Le Bonheur Children's Hospital, Memphis, TN.

10.1136/jim-2016-000393.158

Purpose of Study Early language development is correlated with school performance. By age 4, low income children hear up to 30 million fewer words than their more affluent peers. The Reach Out and Read (ROR) program is

a primary care based literacy intervention that provides books to children. ROR leverages well visits as an opportunity to provide books for children ages 6 months to 5 years, to discuss the importance of reading to children, and to model how to read aloud to young children. The ULPS General Pediatrics Clinic is a resident practice clinic at the University of Tennessee Health Science Center that serves a low income population and has been involved with ROR for almost 2 years. The purpose of this project was to enhance the ULPS ROR through creating a literacy rich waiting room, providing residents education on the importance of ROR, and ensuring a steady income of books for the program.

Methods Used Information was provided to prospective waiting room volunteer readers through flyers and a hospital website. Residents were evaluated using tests administered during orientation and then a year later to assess retention of information. Residents were educated about ROR and early literacy through orientation, clinic didactic sessions, and attending teaching and modeling. A Prescription to Read pad, Dolly Parton Imagination Library sign-ups, and a pop up library were set up in the waiting room to help children have access to more books.

Summary of Results The number of volunteers now totals 7 with more inquiries. The results of the resident tests yielded an increase in the average number of questions correct from 4.56 (SD=1.95) to 7.44 (SD=1.71) with a p value of 0.0054. Efforts continue to help increase the availability of books.

Conclusions With the appropriate publicity, volunteers can be acquired to read in the waiting room. Flyers and a website connected to the local hospital help with advertisement. Residents learn both through lectures during orientation and through ROR in the clinic, improving their awareness and understanding of the Reach Out and Read program. Contacting local programs that provide free books to children is a great way to ensure continuation of the program.

159 PHYSICIAN ELECTRONIC MEDICAL RECORD USE AND PATIENT SATISFACTION IN THE PEDIATRIC EMERGENCY DEPARTMENT

JS Montgomery,^{1,2} J Niemyer,^{1,2} M Bell,² L Crawley,² R Dick^{1,2}. ¹University of Arkansas for Medical Sciences, Little Rock, AR; ²Arkansas Children's Hospital, Little Rock, AR.

10.1136/jim-2016-000393.159

Purpose of Study Physician-patient communication is essential to providing good patient care by facilitating rapport and education of patients and families. Electronic Medical Records (EMR) have added a new component in the exam room that could have an impact on communication between the Licensed Independent Practitioner (LIP) and patients. Prior research in adult medicine has demonstrated less interaction but little impact on patient satisfaction although very little research has been done in the Pediatric population. The purpose of this study is to investigate the effects of LIP use of EMR in the exam room on patient and family satisfaction, and an understanding of their care in the Pediatric Emergency Department (PED).

Methods Used This study was conducted as a survey administered to parents and guardians of patients in the PED at Arkansas Children's Hospital. The survey consisted of questions designed to assess how patients and families felt about the interaction with LIPs and the level of interest/care during the history and physical examination, and to determine if these factors were affected by LIP use of EMRs while in the exam room. Answers to the questions were on a scale of 1–10 and the survey was administered once the PED visit was complete. Surveys were done in RedCap database.

Summary of Results Data was collected from 143 patient families. Electronic devices were used in the exam room by 28.7% of LIPs. The use of these devices had no significant difference (t-value 0.286) on patient and family overall satisfaction.

Conclusions The use of EMR by LIPs in the exam room had no effect on patient and family satisfaction with their care in this study.

160 WALKING AWAY FROM READMISSIONS

LE Muncy,¹ C Colombo,¹ P Tipler,^{2,1} D Cook¹. ¹Dwight D. Eisenhower Army Medical Center, Grovetown, GA; ²Augusta University, Augusta, GA.

10.1136/jim-2016-000393.160

Purpose of Study Studies have demonstrated that acute admissions often lead to hospital acquired deconditioning, resulting in the need for rehab, and increasing recurrent hospital admissions. Our hospital has successfully implemented multiple interventions to decrease hospital acquired deconditioning. However, a measure to quantitate levels of mobility and to encourage ambulation throughout the hospital stay was not in place.

Methods Used A retrospective chart review of 84 patients admitted for COPD or heart failure from 01 January 2015 through 31 December 2015 was performed to determine if ambulation occurred using physical therapy, nursing, and provider progress notes. Exclusion criteria consisted of inability to walk, ICU admission, acute coronary syndrome, as well as patients transferred from outside hospitals. Subsequently, red hearts were placed every 10 feet on the floors of patient wards. Staff was notified of the placement of the hearts, and encouraged to have their patients walk daily. To assist with data collection, a daily ambulation note was created in our electronic health record. Starting July 01, 2016, charts are being reviewed to determine distance walked and readmission rates using the same inclusion and exclusion criteria as above.

Summary of Results Retrospective results prior to intervention indicate that of the 47 heart failure admissions included, 35% of the ambulated patients were readmitted in 30 days, and 56% of the non ambulated patients were readmitted. Of the COPD admissions, 7% of the patients that were ambulated were readmitted within 30 days, and 21% who were not ambulated were readmitted. After intervention, early results indicate there is a decrease in readmission rates for COPD and heart failure, as ambulation rates increase.

Conclusions Readmissions are a common occurrence in patients diagnosed with COPD and heart failure. With

readmissions impacting reimbursement, measures to prevent readmission may not only improve reimbursement, but may also increase patient satisfaction and decrease morbidity as a whole. This initial data suggests implementing a simple ambulation protocol may be a cost effective way to improve readmission rates for hospitals, as well as functional status and satisfaction with patients.

161 EFFECT OF VENTILATOR ROUNDS ON RESPIRATORY OUTCOMES IN VLBW INFANTS IN A LEVEL IV NICU

T Nguyen, A Blood, Y Nicolau. *Loma Linda University, Loma Linda, CA.*

10.1136/jim-2016-000393.161

Purpose of Study Risk of chronic lung disease (CLD) is directly proportional to the number of days on invasive mechanical ventilation (IMV). Non-invasive modes of respiratory support in very low birth weight (VLBW) infants have decreased the incidence of CLD in many centers. California Perinatal Quality Care Collaborative (CPQCC) data shows that CLD rates in the 84-bed level IV NICU of Loma Linda University Children's Hospital were higher than those at comparable NICUs. To address the issue and decrease the use of IMV, weekly ventilator rounds were instituted for one year in 2013 to discuss and evaluate all babies on IMV. The purpose of this study was to evaluate the effect of weekly ventilator rounds on the use of IMV, post-delivery-room bubble CPAP (bCPAP), postnatal steroids and incidence of CLD.

Methods Used Inborn babies <30 weeks' gestation and weighing 401–1500 g were placed on bCPAP immediately after birth to increase post-delivery-room bCPAP usage. Babies who failed bCPAP and required intubation had chest x-rays, blood gases, ductus arteriosus status, caffeine usage, mode of ventilation, baseline oxygen requirement, and diuretic usage reviewed and discussed with the primary care team weekly. The objectives were to allow permissive hypercapnea, encourage active ventilator weaning, and ensure extubation occurred within 24 h after babies were deemed extubatable. Babies who remained intubated >2 weeks and had failed prior extubation and/or still required >40% FiO₂ were eligible for postnatal steroids. CPQCC outcomes for 2013 were compared to the two years prior to initiation of ventilator rounds (2011 and 2012) and to the year after it was stopped (2014).

Summary of Results Ventilator rounds in 2013 was associated with a 14.5% increase in the use of postnatal steroids, 11% increase in post-delivery-room bCPAP, and 9.5% decrease in the rate of CLD when compared to 2011–2012. Termination of ventilator rounds in 2014 was associated with a 22% decrease in the use of postnatal steroids, 6% decrease in post-delivery-room bCPAP, and 9% increase in the rate of CLD.

Conclusions Weekly ventilator rounds in 2013 decreased the overall CLD rate in babies who weigh <1,500 grams when compared to 2011 & 2012. When ventilator rounds were discontinued, BPD rates increased back to percentages comparable to 2011 & 2012.

162 CLINICAL EFFECTIVENESS OF CASE MANAGEMENT FOR REDUCING HOSPITAL READMISSIONS

E Price-Haywood,² J Harden-Barrios,² H Petersen,¹ M Roberts,³ N Markward². ¹Lovelace Respiratory Research Institute, Albuquerque, NM; ²Ochsner Clinic Foundation, New Orleans, LA; ³UNM College of Pharmacy, Albuquerque, NM.

10.1136/jim-2016-000393.162

Purpose of Study We evaluated the effectiveness of an outpatient case management program (OPCM) to reduce hospital readmissions.

Methods Used We conducted a retrospective observational study of Medicare Advantage (MA) patients hospitalized in a large integrated delivery system between 2013 and 2016. Cases were defined as patients flagged as discharge risk with index inpatient visit (IP) within 90 days prior to OPCM acceptance and enrolled in MA at least 90 days pre- and 1 day post-OPCM assessment date. Controls were defined as having no OPCM exposure, index IP primary diagnosis among top case IP diagnoses, and enrolled in MA at least 90 days pre- and 1 day post-index IP. We generated propensity scores using gender, race, zip code poverty level, index length of stay, index IP diagnosis, select co-morbidities (COPD, CHF, MI, Diabetes, Renal Failure), presence of pre-index IP/SNF/Home Health events, and total pre-index ED visits. We used inverse probability treatment weighting to reduce study group differences in case-mix. We used multiple logistic regression to examine the relationship between OPCM exposure and 90-day readmissions (mean OPCM enrollment, 72 days).

Summary of Results Among 52,928 patients, 1385 met inclusion criteria (231 cases; 1151 controls). Most patients were white (82%), elderly (mean age, SD: 78 [9.9]), with Charlson score 3.7 and were admitted with respiratory disorders during the index IP (54%). Black race (OR, 95%CI: 1.7 [1.19–2.45]), male gender (1.3 [1.03–1.68]), pre-index IP events (1.78, [1.30, 2.44]), and Charlson score (1.08 [1.03–1.13]) were associated with increased odds of 90-day readmission. Pre-index ED visits trended towards increased odds. The model-adjusted impact of OPCM was neutral.

Conclusions Program review revealed that most OPCM referrals originated in primary care rather than inpatient services. Programs intended to reduce utilization such as hospitalizations should enroll patients from service centers of interest thereby optimizing use of committed resources.

163 IMPROVING THE EDUCATIONAL EXPERIENCE FOR RESIDENTS ON THE MOTHER BABY UNIT

S Reed, J Nortman, B Drabu, B Roebuck. *University of Oklahoma, Tuttle, OK.*

10.1136/jim-2016-000393.163

Purpose of Study The goal of this quality improvement project was to implement changes to the Mother Baby Unit (MBU) rotation to make the experience more educational for residents and to help them feel more prepared for resuscitations and newborn care in their future practice.

Abstract 163 Table 1

	Resident Responsibilities					Educational Experience				Team Communication	
	Q2	Q7	Q9	Q10	Q11	Q5	Q6	Q8	Q12	Q3	Q4
Pre-Orientation Mean	4.6	6.3	7.0	4.1	4.2	6.0	6.1	5.8	7.0	3.7	7.9
Post-Orientation Mean	7.3	8.9	9.0	6.6	6.6	9.0	8.5	8.2	9.1	6.1	9.1
Δ	2.7	2.6	2.9	2.5	2.4	3.0	2.4	2.4	2.1	2.4	1.2
T-test Score	-3.2	-3.2	-3.5	-2.2	-2.6	-4.1	-3.2	-3.2	-2.8	-2.5	-1.8
p-value	0.002	0.002	0.0008	0.02	0.008	0.0002	0.002	0.001	0.004	0.009	0.045

Q, question; Δ, difference between pre- and post-orientation means

Methods Used MBU attendings implemented a new orientation, which included a handout outlining the MBU rotation, introducing nursing leadership to the team, and discussing resuscitations and newborn care resources. Pre- and post-orientation pediatric and med-peds residents were given the opportunity to complete a 12-question survey to assess their experience on the MBU rotation. There were 20 pre-orientation residents and 11 post-orientation residents included in this study.

Summary of Results The initial survey question (Q1) showed that all residents felt an MBU orientation would be beneficial with an average score of 9.3/10. Post-orientation residents felt more prepared to provide newborn care, to lead newborn resuscitations, and had an overall better educational experience than pre-orientation residents. Comments revealed that several areas, such as interactions with nursing staff and balancing time between deliveries and newborn care, still need further improvement.

Conclusions Overall, the handout and orientation with an MBU attending significantly improved the rotation. Residents felt more prepared to perform their responsibilities on the service and more confident in leading resuscitations and providing newborn care.

MBU Survey Results for Pre- and Post-Orientation Residents

164 LSU INTERNAL MEDICINE IMPACT ON ED THROUGHPUT

M Rolfsen, LS Engel, S Sanne. *LSU Health Sciences Center, New Orleans, LA.*

10.1136/jim-2016-000393.164

Purpose of Study Emergency Department (ED) overcrowding has been shown to compromise various domains of quality, notably timeliness and safety. Furthermore, ED throughput has become an important metric in hospital reviews and insurance compensation. The Center for Medicare and Medicaid Services (CMS) now routinely tracks and publicly reports ED throughput measures. Various methods have previously been proposed to decrease this time, including hospitalist phone consultation and resident education and feedback.

Methods Used In a 235 bed urban hospital, we measured the time between consultation to the Internal Medicine team and the decision to admit, with a goal of 45 minutes. Prior to this study, residents would receive consultations from the ED and would conduct a full evaluation before an

admission. Our intervention was to allow residents to conduct an abbreviated evaluation in the ED and subsequently a full evaluation after an admission occurred. Residents recorded the consult and admit times, as well as reasons for any delays.

Summary of Results We tracked 2596 patients over a 12-month period beginning Aug 1st 2015. Our average time from consultation to admission was 49.9 minutes with a median of 40 minutes. Most recorded delays fell into the following categories: labs; separate consultations; multiple simultaneous admits; incomplete work-up or complicated admit; floor work or resident check out.

Conclusions ED throughput is a major focus area for patients and hospitals. CMS now tracks and reports throughput data. Improving ED throughput by an academic hospitalist service may prove to be a challenge, however we have been able to demonstrate the ability to admit patients in a timely manner while preserving the educational goals of the admitting teams.

165 QUALITY IMPROVEMENT FOR UTI MANAGEMENT

MH Roy, E Klepper, M Bolton, J Kuznetsova, J Meche, J Bentley, DM Mathews. *Our Lady of the Lake, Baton Rouge, LA.*

10.1136/jim-2016-000393.165

Purpose of Study The goals of our QI collaborative thru the Value in Inpatient Pediatrics network were to increase duration of antibiotic treatment to between 7 and 14 days for >95%; decrease the use of IV antibiotics after discharge to <5%; increase percent of diagnostic urine cultures obtained via catheter/suprapubic aspiration PA to >95%; increase overall percent of abnormal urinalysis used for diagnosis of urinary tract infections (UTIs) to 95%; increase percent of diagnostic urine cultures made using a culture with greater than 50 K CFU of a single uropathogen to >95%; decrease the rate of voiding cystourethrogram obtained without abnormal ultrasound to <5%; increase rate of renal ultrasound in patients diagnosed with first time UTI to >90%, decrease the prescription of prophylactic antibiotics at discharge to <5%.

Methods Used Our institution recently completed an 18 month quality improvement (QI) project in collaboration with over 30 hospitals in order to improve adherence to the existing AAP guidelines. Resource utilization in terms of antibiotics selection, laboratory testing, medication utilization, and radiology studies were being collected and

compared. We collected 9 months of retrospective data as baseline performance. We then began providing education on the guidelines to the Pediatric residents and faculty, including the Pediatric ER. Data were collected on project measures for a total of 4 three month periods retrospectively.

Summary of Results We have remained at goal throughout all 7 cycles for appropriate: use of prophylactic antibiotics, rate of voiding cystourethrogram without abnormal renal ultrasound, duration of antibiotic therapy, as well as transition to enteral antibiotics. There has been improvement in appropriate urine collection methods and using specific diagnostic criteria to correctly diagnose UTI via urinalysis. We continue to note fluctuation in the rate of renal ultrasound in first time UTI.

Conclusions By reviewing our data, we have been able to better identify areas of weakness in regards to adherence to AAP guidelines. We continue to make educational interventions in order to meet the above stated goals. Our data thus far show that we met or exceeded the project goals for nearly all parameters. Through continued collaborative educational efforts, we can better promote guideline adherence.

166 THE FEASIBILITY OF USING TELEMEDICINE TO PROVIDE TERTIARY PEDIATRIC OBESITY CARE

R Sadeghian,¹ R Gooch,² D Preud'homme,¹ L Phelps¹. ¹University of South Alabama, Mobile, AL; ²Northwell Hofstra School of Medicine, Lake Success, NY.

10.1136/jim-2016-000393.166

Purpose of Study Although Telemedicine implementation in tertiary care has been tried, the satisfaction and outcome data is limited due to small sample sizes and the variation of methods and personnel by which the telemedicine technology is delivered and participants assessed. Our objective was to determine the feasibility of using telemedicine to deliver Pediatric tertiary obesity care and to evaluate Patient/MD/Staff satisfaction.

Methods Used We used a commercially available telemedicine system by JEMS technology to conduct a prospective study where a sample of 30 patients were evaluated by a specialist physician using telemedicine technology from Feb 2016 through Aug 2016. Inclusion criteria included children aged 10–18 years of age and a BMI greater than 95%. A qualitative assessment of the patient/MD/staff perceptions of telemedicine use were assessed through a 5 point Likert scale. We used descriptive statistics to describe responses.

Summary of Results 27 telemedicine consultations performed to completion. Technology error troubleshooting was the most common cause of incomplete sessions and technology dissatisfaction. MD/staff/patient responders agreed that the use of telemedicine is an appropriate and effective use of the clinician's skillset and time ($\geq 96\%$), and can avoid patient travel from an underserved area to a tertiary care clinic ($\geq 95\%$). All responders were comfortable and satisfied using the Telemedicine equipment ($\geq 85\%$). MD and patients agreed that the telemedicine

equipment helped the patient avoid a face-to-face visit ($\geq 90\%$). Patients felt the technology was effective in the management of their visit ($\geq 93\%$).

Conclusions We successfully delivered tertiary obesity care through the use of telemedicine equipment in different clinical situations associated with Pediatric Obesity. Wireless internet connectivity and adequate training of personnel to use the equipment are important aspects of successfully completing telemedicine sessions with patient, staff and physician satisfaction. Access to pediatric tertiary obesity care is a major barrier specifically for low socioeconomic populations, in our opinion telemedicine represents a realistic and cost-effective modality to provide well-received specialty care for the obese pediatric population.

167 MEDICAL STUDENTS ENHANCE FOLLOW-UP FOR DISCHARGED HOSPITAL PATIENTS

SD Schlessinger, B Bunol, J Fowler, T Goodfellow, H Lambert, J Sivils. University of Mississippi Medical Center, Jackson, MS.

10.1136/jim-2016-000393.167

Purpose of Study In 11/ 2015, CMS published a proposed final rule for the *Improving Medicare Post-Acute Care Transformation* (IMPACT) act. IMPACT requires hospitals improve inpatient (inpt) discharge (d/c), including follow-up (f/u) appointments (appts) for all pts d/c'd to home. Although currently unable to track, hospital leaders estimate fewer than 40% of d/c'd pts leave our hospital with a date/time for f/u appt. We asked M1 medical students (M1s) to evaluate our barriers in assigning appts and to propose improvements.

Methods Used Five M1s participated in a summer 2016 work project evaluating hospital appt processes for d/c'd pts. M1s completed Institute for Healthcare Improvement basic certification, reviewed CMS guidelines, discharge best practice documents, and hospital policies. They subsequently interviewed residents, faculty, floor nurses, coordinated care specialists, d/c nurses, NPs, pts, unit clerks, administrators, and schedulers.

Summary of Results Existing hospital f/u appt policies for MDs, schedulers (SDS), and clerks were poorly aligned. Appt orders could not be placed outside the full d/c order set; once placed, d/c occurs within 90 minutes, despite appt assignments taking up to 5 hours to complete. SDS were attempting to call pts in rooms long after d/c, unaware of a hospital d/c lounge where some pts wait. Three categories of pts were identified that did not ever receive appts at d/c: pts without resources not assigned f/u appts until completion of financial counseling (may take weeks to complete), pts following up outside our hospital system, and pts the SDS cannot reach by phone at home in the three days following d/c. No f/u appts could be scheduled on week-ends or holidays. The M1 report has led to a number of changes in our processes with more to come: a hospital f/u appt order is separate from the D/C order set and allows f/u to be scheduled as early as the first day of hospitalization, indigent pts receive f/u appts with financial counseling at time of f/u, unit clerks now work with pts to schedule f/u appts outside of our health system prior to

d/c, and MDs are being trained to enter f/u appt orders at least 24 hrs before d/c and by noon on Friday for week-end d/c.

Conclusions M-1s can assist in improving timely assignment of f/u apps for d/c'd hospital patients.

168 **COMPARING A NASAL IRRIGATION DEVICE TO A NASAL SUCTIONING DEVICE IN THE PEDIATRIC EMERGENCY DEPARTMENT: ARE THEY EQUAL?**

BS Shihabuddin. *OUHSC, Oklahoma City, OK.*

10.1136/jim-2016-000393.168

Purpose of Study The objective of our study was to compare a nasal irrigation device (Schnozzle, Splash Medical Devices LLC, Atlanta, GA) to a nasal suctioning device (BBG Nasal Aspirator, Children's Medical Ventures LLC, Monroeville, PA). Our hypothesis was that the Schnozzle was non-inferior to the nasal aspirator in emergency department length of stay (LOS) and the rate of return to the pediatric emergency department (PED) within 72 hours of the first visit with the same complaints. We also compared the vital signs before and after the device use. Nursing staff was also asked to rate their satisfaction with either device.

Methods Used This was a retrospective study of patients who presented to an academic pediatric emergency department between December 1, 2015 and January 30, 2016. The study was conducted in two steps followed by non-inferiority analysis on the LOS and the rate of return to the PED. Data on patients who presented between December 1, 2015 and December 31, 2015 and had a documented nasal suctioning performed using the BBG device was collected and then the standardized difference was determined and the sample size was calculated. We determined the non-inferiority limit to be 60 minutes. From that we determined the sample size of 18 patients per group. Data on patients who presented between January 1, 2016 and January 30, 2016 who had a documented nasal irrigation performed using the Schnozzle was collected and the final analysis was performed. All included patients were diagnosed with either bronchiolitis or upper respiratory tract infection. Seventy patients were included in the final analysis, 35 in the suction group and 35 in the Schnozzle group. Nursing staff feedback was elicited by a single question survey.

Summary of Results There was no statistically significant difference in the vital signs of both groups before and after the use of either device. The Schnozzle was non-inferior to the BBG in total LOS. We could not comment on the return rate to the PED, as there were no return visits for the BBG group. Nursing staff preferred the Schnozzle [77.8% (95%CI=45.3–93.7)].

Conclusions The Schnozzle is non-inferior to the BBG nasal aspirator in length of stay in the pediatric emergency department when used in patients with bronchiolitis and upper respiratory infections. Nursing staff was more satisfied with the Schnozzle.

169 **UTILIZATION OF INTERMEDIARY UNITS FOR CHILDREN ADMITTED WITH UNINTENTIONAL POISONINGS**

C Smola, CL Wu, CM Pruitt, M Nichols. *UAB, Birmingham, AL.*

10.1136/jim-2016-000393.169

Purpose of Study Unintentional poisonings represent a large number of admissions to intermediary (IU) or intensive care (ICU) units. There is a potential for significant utilization of hospital resources, but limited data exists on admission practices by providers. We aimed to describe hospital resource utilization and outcomes of children admitted following unintentional poisoning.

Methods Used In this retrospective, single-center cohort study at a quaternary-care children's hospital, children aged <6 years were evaluated who presented to the emergency department (ED) with unintentional poisoning during a 5-year period. Children admitted to the ICU or discharged from the ED were excluded. Primary outcome was ED disposition (IU versus acute care bed admission), with secondary outcomes of length of stay (LOS) and escalation of care. Covariates included standard demographics, ED medical interventions and diagnostics (supplemental fluids, oxygenation, laboratory tests, telemetry, electrocardiography (ECG), urine drug screen (UDS), and neuroimaging), presence of altered mental status (AMS), certainty of ingestion (COI), provider training level (fellow, attending, toxicologist), and drug class. Multivariate logistic regression was performed with SAS 9.4.

Summary of Results Four hundred and two admissions occurred during the 5-year period with 80.6% admitted to the IU. There were no escalations of care or difference in LOS. Laboratory tests, telemetry, ECG, UDS, AMS, provider training level, and CNS and cardiac drugs, were all associated with inpatient disposition in bivariate analysis. After adjusting for patient age, provider training level, and COI, patients with AMS were significantly more likely to be admitted to the IU (aOR 3.65, 95%CI 1.71–7.82). Exposures to cardiac drugs were more likely to be admitted to the IU (aOR 3.65, 95%CI 1.71–7.82). Poisonings with metabolic or caustic exposures were more likely to be admitted to acute care beds (aOR 2.80, 95%CI 1.17–6.66, $p=0.02$; aOR 53.95, 95%CI 5.35–543.65, $p<0.01$, respectively).

Conclusions Significant use of hospital resources were committed to patients with unintentional poisonings. Children presenting with AMS and poisonings of certain drug classes were significantly associated with a higher level of inpatient care. Future studies may help standardize patient care to minimize resource utilization.

170 **FULL BODY SKIN EXAMINATION AMONG DERMATOLOGISTS: A PILOT STUDY TO UNDERSTAND PRACTICE PATTERNS AND BARRIERS**

JE Turrentine, T Wyatt, K Braun. *Augusta University, Augusta, GA.*

10.1136/jim-2016-000393.170

Purpose of Study Full body skin examination (FBSE) is an important measure to identify skin cancers. Up to 45% of

melanomas are found 'incidentally' on exam, and most melanomas are detected in areas normally covered by clothing. However, according to some studies, dermatologists perform FBSE for only a fraction of visits. Current literature is sparse regarding barriers to FBSE and often fails to define what specific body areas are examined. This study examines dermatologists' typical practice patterns and perceived barriers to the FBSE, as a way to explore potential interventions that will improve examination practices.

Methods Used Using published FBSE literature, a 14-item survey was developed to assess: 1) practitioner demographic information, 2) body sites examined in patients with and without a history of skin cancer, and 3) perceived barriers to performing FBSE. Surveys were administered to 100 dermatologists at a regional dermatological society meeting.

Summary of Results Fifty-one (51%) attendees completed at least part of the survey, and forty-five (45%) attendees completed the entire survey. Participants included 32 (63%) females and 19 (37%) males; practice types included 42 (82%) in private practice, 7 in academics (14%), and 2 in a combination (4%). Only 30/51 (59%) participants reported offering FBSE to new patients with a history of skin cancer. Among high risk patients with a history of melanoma, 48/48 (100%) dermatologists reported routinely examining the face, abdomen, chest, back, and arms, but other areas were examined less consistently: scalp=47/48 (98%), legs=47/48 (98%), breasts=43/48 (90%), genitals=26/48 (54%), buttocks=45/48 (94%), perianal area=30/48 (62%), feet=47/48 (98%), conjunctiva=33/48 (69%), and oral mucosa=21/48 (44%). The most cited barrier to FBSE was 'patient does not want exam' (21/45 [47%] cited this as 'very much' a barrier); other prominent barriers were 'lack of time' and 'embarrassment of patient.'

Conclusions Several body sites are inconsistently examined by dermatologists during FBSE even in high risk patients. Further study is warranted to understand the patient-related factors that are cited as major barriers to FBSE, as a means to develop patient-directed interventions that may improve the quality of FBSE.

Hematology and Oncology

Joint Plenary Poster Session and Reception

4:30 PM

Saturday, February 11, 2017

171 CMV INFECTION-INDUCED LIFE THREATENING ACUTE HEMOLYSIS, PANCYTOPENIA AND CRITICAL B12 DEFICIENCY IN AN IMMUNOCOMPETENT HOST

H Alshammaa, O Salh, A Islam. *Texas Tech Univ HSC Amarillo, Amarillo, TX.*

10.1136/jim-2016-000393.171

Case Report Cytomegalovirus (CMV) is a common viral infection presents with different clinical manifestations. Acute hemolysis secondary to CMV is very rare in immunocompetent adult with unclear mechanism and associated vitamin B12 deficiency due to rapid hemolysis and ineffective erythropoiesis is also rare. We report an immunocompetent adult patient presented with critical

pancytopenia and severe B12 deficiency due to CMV induced hemolysis.

A 40 years old female presented with progressive jaundice, dyspnea and fatigue. She had weight loss, spiking fever, chills and many episodes of vomiting of three weeks duration. Past history is only significant of Methamphetamine use. PE: A&O, pale, tachypnea and icterus. Mild hepatosplenomegaly and aortopulmonary adenopathy on CT scan. Lab studies: Hb 2.7, platelets 34,000, WBC 3.700 with ANC of 1600. MCV 122. T Bil. 6.7, D Bil 1.6, Haptoglobin 7 and LDH 2600. Serum folate 15.6 ug/L but serum B12 was less than 50 ng/L. Methylmalanoic acid and homocysteine were 12815 and 127.9 respectively. Iron studies normal with mild transaminitis and normal creatinine. Peripheral blood exam: severe pancytopenia without nucleated RBC or blast cells. Bone marrow aspirate showed hypercellular BM with increased myeloid and erythroid hematopoieses. Flow cytometry showed non-specific 5% myeloblast. Cold agglutinin Antibodies positive (1:128 titer) with direct antiglobulin test (DAT) positive for both IgG and C3 indicating autoimmune mixed hemolytic anemia. Acute hepatitis and HIV panel was negative but CMV IgG and IgM was positive consistent with acute CMV infection.

Discussion Cold agglutinin disease (due to infection or neoplastic growth) is rare, affects usually females in the seventh decade of life. Unlike that in children, CMV infection-induced acute hemolysis is very rare in healthy adult. Our case was healthy adult presented with acute mixed cold and warm agglutinin mediated hemolysis with critical pancytopenia due to CMV infection. The investigation of acute CMV infection is required in case of acute autoimmune hemolysis in healthy adult. B12 deficiency can be due to rapid hemolysis. Supportive therapy is the best approach so far especially in immunocompetent host, role of steroid and antiviral agents still controversial.

172 ORBITAL CARCINOID METASTASIS

KC Arthur, D Hamilton. *University of Mississippi Medical Center, Jackson, MS.*

10.1136/jim-2016-000393.172

Case Report Orbital Carcinoid Metastasis is a rare occurrence, accounting for 5% of choroidal metastases. In most cases, the primary tumor is already known and is of bronchial or gastrointestinal origin. The most common sites of metastases are bone, liver, and lymph nodes. Spread to the eye is thought to occur hematogenously. The largest case series consists of 13 patients. Of the case reports available, the 10 year survival rate of patients with orbital metastasis is 38%, which is similar to survival for systemic metastasis. Treatment usually consists of radiotherapy and/or chemotherapy.

We present an 86 year old male with a history of carcinoid of the ileum and prostate cancer s/p radical prostatectomy who presented to the ophthalmologist with complaints of fluctuating proptosis and diplopia of unknown duration. He had been followed for a right retro-orbital mass for approximately 40 years that was thought to be secondary to an orbital varix. He was diagnosed with carcinoid of the terminal ileum in 2010 found on CT scan

after complaints of abdominal pain and underwent an ileocecectomy. Pathology of the ileal carcinoid was low grade, negative margins, invaded the lamina propria and focally involved the muscularis propria. Perineural and lymphovascular invasion were present and 4/6 lymph nodes had tumor deposits. He was pathologically classified as T3N1M1 at the time of diagnosis, and 5-HIAA was not elevated at the time. Treatment was not initiated as he was asymptomatic and his carcinoid markers were within normal limits.

MRI showed right proptosis secondary to a 2.7×2.5×1.9 well-circumscribed, enhancing retrobulbar mass. He underwent a right orbitotomy, and pathology revealed a low grade neuroendocrine tumor, carcinoid. The tissue was strongly positive for broad spectrum keratin, CD56, Synaptophysin, and Chromogranin. He remains asymptomatic and does not demonstrate diarrhea, flushing, or wheeze. Chromogranin A was elevated at 1930 ng/mL. A CT scan of the chest, abdomen, and pelvis and an octreotide scan are being used to determine the course of treatment.

We present a rare case of orbital carcinoid metastasis, which presented as a retro-orbital mass present for 40 years as ileal carcinoid.

173 GASTROINTESTINAL ANGIOEDEMA AND THE PRESENCE OF LUPUS ANTICOAGULANT: UNRELATED SYMPTOMS OF A SINGLE UNDERLYING DISORDER

JH Atkins, H Iqid, E Cobos, S Radhi. *Texas Tech Health Sciences Center, Lubbock, TX.*

10.1136/jim-2016-000393.173

Case Report A 70-year-old female presented with a 2-year history of cyclical abdominal pain and intermittent watery diarrhea. Initial testing revealed mild anemia and a prolonged PTT due to the presence of lupus anticoagulant. Imaging was unremarkable except for splenomegaly. GI evaluation including a colonoscopy, and testing for porphyria, carcinoid, and food allergies were negative. Testing for C1 esterase inhibitor and C4 titers revealed low levels that supported the diagnosis of acquired angioedema (GI tract) from C1 esterase inhibitor deficiency (C1INH-AAE). The co-occurrence of lupus anticoagulant and C1INH-AAE, as well as splenomegaly, prompted a search for an underlying lymphoid disorder hence a peripheral smear was reviewed followed by flow cytometry that showed atypical clonal lymphocytes. A bone marrow biopsy done also showed aggregates of mature clonal B cells. A final diagnosis of small lymphocytic leukemia (SLL) was made for which she was treated with chemotherapy. With treatment of SLL, her abdominal pain, diarrhea, splenomegaly, and prolonged PTT resolved along with normalization of C1 esterase inhibitor activity. She continues to live without symptoms 20 years after treatment.

C1INH-AAE is a rare syndrome of recurrent angioedema that can involve the airways, GI tract, and the skin (without urticaria). The underlying mechanism is the presence of an auto-antibody against the C1 esterase inhibitor leading to overproduction of bradykinin. Importantly, C1INH-AAE is associated with an underlying lymphoid malignancy in

about 35% of patients.

The presence of lupus anticoagulant can rarely be associated with a lymphoid malignancy. In our patient, the concern for a malignancy was high since she has C1INH-AAE, lupus anticoagulant, and splenomegaly. It is possible that the patient's B cells produced an antibody against C1 esterase inhibitor that is also a lupus anticoagulant thereby producing symptoms that initially defied a unifying diagnosis.

C1INH-AAE and lupus anticoagulant are rare autoimmune manifestations of lymphoid malignancies. It is interesting to note both were the presenting issues in a patient who was eventually diagnosed with SLL.

174 RENAL CELL CARCINOMA WITH PARANEOPLASTIC POLYNEUROPATHY

J Bennett, JC Henegan. *UMMC, Brandon, MS.*

10.1136/jim-2016-000393.174

Case Report Paraneoplastic neuropathy is associated with various hematologic and solid tumor malignancies. It is most commonly seen in small cell lung cancer, but can also be associated with prostate, breast, pancreatic, ovarian cancer and multiple myeloma. It is rarely associated with renal cell carcinoma (RCC). We describe a case report of a patient with relapsed RCC and an associated paraneoplastic primary demyelinating sensorimotor polyneuropathy.

A seventy-year-old female with a history of stage III (pT3pN0M0) papillary RCC resected two years prior presented with new symptoms of 'numbness, weakness' and 'pain' in her hands and toes beginning about three months earlier, and now progressed to her wrists and ankles. She described sensations of 'sand' in her shoes and difficulty manipulating objects with her hands. Neurologic examination revealed impaired vibration testing distally and wide-based, unsteady gait. CT Chest Abdomen Pelvis with contrast showed new mediastinal lymphadenopathy. A subsequent lymph node biopsy was consistent with relapsed papillary RCC. MRI imaging of the brain and spine revealed no mass lesions. Electromyography resulted in electrodiagnostic evidence of sensorimotor polyneuropathy with secondary axonal changes. SPEP, TSH, and vitamin B12 tests were normal and no other causes including viral illness, diabetes, nor medication side-effects were identified. Cerebrospinal fluid showed nonspecific abnormalities including increased IgG index and oligoclonal bands. Serum paraneoplastic antibody testing was negative.

RCC has been associated with different paraneoplastic syndromes, but rarely with paraneoplastic polyneuropathy. We describe a patient who developed symptoms resulting from paraneoplastic polyneuropathy that progressively worsened months prior to finding a relapse of her RCC. Allen et al described a patient with papillary RCC complicated by paraneoplastic neuropathy, with a similar EMG pattern and negative serum paraneoplastic antibody testing. At present the patient is on a trial of immunotherapy for her demyelinating polyneuropathy and on oral chemotherapy for her renal cell carcinoma. If she has no improvement in her symptoms after an appropriate amount of time then the plan is for her to undergo a metastatectomy, as previous

reports indicate that removing all visible disease can lead to a resolution of symptoms.

175 TAILORED TREATMENTS IN NON SMALL CELL LUNG CANCER IN THE TARGETED THERAPY ERA

R Bijjula, R Khalaf, D Jaishankar. *East Tennessee State University, Johnson City, TN.*

10.1136/jim-2016-000393.175

Case Report The prognosis of stage IV Non small cell lung cancer (NSCLC) is dismal with a 5 year survival rate of 1%. Palliative treatment options include cytotoxic chemotherapy, targeted agents (EGFR, ALK and ROS inhibitors) and immunotherapy. We describe one such patient with this incurable disease, who is now alive and well 70 months after diagnosis, receiving a series of effective treatments sequentially. A 68-year-old male was admitted for evaluation of dyspnea. Imaging demonstrated moderate right pleural effusion. Thoracentesis revealed TTF-1 positive adenocarcinoma of lung on cytology. ALK rearrangement was detected. Patient declined upfront ALK directed targeted therapy. He was initially treated with carboplatin, paclitaxel and bevacizumab for 6 cycles followed by bevacizumab maintenance which was discontinued due to toxicity. He was then switched to maintenance Pemetrexed and successfully received 40 cycles over a period of 37 months with stable disease status being maintained all through. He finally developed progressive disease with rib and cervical vertebral metastases for which he received palliative radiation therapy. He then commenced targeted therapy with Crizotinib (1st gen ALK inhibitor) which he continued with dose modifications (due to toxicity) for a period of 12 months. He was finally intolerant of Crizotinib and was switched to Certinib which he has now successfully continued for 14 months albeit with dose reductions (from 750 mg to 450 mg). He is clinically stable with an good performance status (ECOG 1) and radiographic resolution of his bony lesions on targeted therapy. His recent scan in 9/2016 revealed no evidence of metabolically active disease. He has a loculated pleural effusion that has been stable for 5 years without requiring any therapeutic thoracentesis. Stage IV NSCLC carries an abysmal prognosis with the most recent SEER data from 2007 reporting median survival time of 6 months for untreated patients and 12 months with treatment. The primary aim is palliative, with an effort to prolong survival, while maintaining quality of life. Treatment choices are tailored based on histologic and molecular features. Targeted agents, usually the first line of treatment (with molecular abnormalities) have dramatic benefits as highlighted in this case.

176 RECURRENT BREAST CANCER: ENOUGH TO BREAK YOUR HEART?

R Bijjula, D Jaishankar, K Chakraborty. *East Tennessee State University, Johnson City, TN.*

10.1136/jim-2016-000393.176

Case Report Stress Cardiomyopathy(SC) or Apical Ballooning syndrome (takotsubo cardiomyopathy) is a unique reversible cardiomyopathy that is frequently precipitated by a stressful event. It is more prevalent in postmenopausal women and characterized by transient regional systolic dysfunction of the left ventricle resembling MI, with normal coronary vasculature.

A 54-year old lady with recurrent breast cancer [hormone receptor(HR) negative and HER 2 positive] was found to have an impaired ejection fraction(EF). She had dyspnea on exertion. An echocardiogram revealed a substantial drop in EF to 45% compared to 60% two years ago. Physical examination was unremarkable overall. Medical history was relevant for sick sinus syndrome with pacemaker placement, previous breast cancer (HR positive and HER2 negative) and bilateral mastectomy. She previously declined adjuvant chemotherapy and endocrine treatment. The impaired EF was a deterrent to pursue HER 2 directed agents which can further impair the EF. Left heart catheterization showed no atherosclerotic disease but revealed arteries with quick taper from mid to distal vessel suggestive of SC. Renin- angiotensin system(RAS) antagonist and beta blocker(BB) therapy was initiated. This led to improvement in the EF to 55% in two months while receiving concomitant HER2 targeted therapy. She successfully completed systemic therapy with preserved EF despite cardio toxic medications. Her impaired EF was secondary to SC precipitated by the diagnosis of recurrent breast cancer.

The etiology of SC is broad including emotional (28%) and physical (36%) stress and another 28% with no apparent cause. Common symptoms include chest pain, dyspnea or syncope (76%, 46%, and 8% respectively). Diagnostic studies reveal transient left ventricular dysfunction in the absence of obstructive coronary artery disease and/or new EKG abnormalities (ST segment elevation 44%-100%, ST segment depression 7.7%). Etiology of SC involves catecholamine induced microvascular dysfunction leading to myocardial stunning. Conservative management and resolution of physical and emotional triggers results in improvement. Chronic BB therapy along with blockade of the RAS is effective. Recovery could take 1–4 weeks. Clinicians need to be cognizant about this entity considering it can mimic MI/CHF.

177 SMALL LYMPHOCYTIC LYMPHOMA WITH EXTREME PLASMACYTIC DIFFERENTIATION

C Capra,¹ JL Frost². ¹University of Mississippi Medical Center, Jackson, MS; ²GV (Sonny) Montgomery VA Medical Center, Jackson, MS.

10.1136/jim-2016-000393.177

Introduction Differentiating between lymphoplasmacytic lymphoma (LPL) and other indolent, small B-cell lymphomas can be challenging but is clinically relevant due to different therapeutic strategies.

Case presentation A 64 year-old male presented with fatigue, weight loss, neuropathy, and frequent falls. He also had recent epistaxis requiring blood transfusion. Exam demonstrated pallor, left axillary and bilateral inguinal lymphadenopathy, and diminished sensation in his feet. His

white blood count (WBC) was 7,400 cells/cmm with a normal differential. Hemoglobin was 10.1 g/dL and platelet count was 226 thousand/cmm. Total protein was 11.2 g/dL and serum protein electrophoresis revealed an abnormal band as an IgM kappa measuring 3.19 g/dL. Quantitative immunoglobulin M (IgM) was measured at 4,742 mg/dL. Computed tomography (CT) scan revealed extensive lymphadenopathy. Flow cytometry of the bone marrow aspirate revealed a clonal B-cell population that stained positive for CD5 and CD23, as well as a discrete population of plasma cells that were positive for CD45 and CD19. Testing for MYD88 L265P mutation was negative and chromosome analysis revealed a trisomy 12 and a 13 q deletion. After two cycles of Bortezomib, Cyclophosphamide, and Dexamethasone for WM the IgM increased to 5,930 mg/dL necessitating a change to Fludarabine, Cyclophosphamide, and Rituximab to treat CLL/SLL.

Discussion Some degree of plasmacytic differentiation is well known in CLL/SLL, however, there usually is not frank differentiation into plasma cells. Recent studies have suggested that the MYD88 mutation is present in more than 90% of WM cases. In this case, the predominant features were attributable to a paraproteinemia, however, the bone marrow findings were unexpected and suggested CLL/SLL with extreme plasmacytic differentiation. Though the 13 q deletion and trisomy 12 are not specific for CLL, they occur with only 10% and 5% frequency, respectively, in LPL. As our patient did not respond to standard therapy for WM, the decision was made to change to a regimen more directed toward CLL/SLL.

178 METASTATIC NEUROENDOCRINE TUMOR CHARACTERIZED BY GENERALIZED SUBCUTANEOUS NODULES

C Castillo Latorre, I Valle, K Torres, N Cruz. *San Juan City Hospital, San Juan, PR.*

10.1136/jim-2016-000393.178

Case Report Once a Neuroendocrine tumor has metastasized, it can release a large number of hormones leading to distinct symptoms. However, not all of them will be functional, nor present themselves clinically as subcutaneous nodules. Subcutaneous metastasis may be the presenting symptom in many cases with underlying malignancies such as, breast, lung, colon, pancreatic and ovarian cancer, but also in melanoma. However, this is a rare site of metastasis for neuroendocrine tumors. We present the case of a 72 year-old female patient with a 40 pack year smoking history, who came to our institution, with the complain of asymptomatic generalized cutaneous and subcutaneous nodules measuring 1 cm to 5 cm since one month of evolution. Progression of nodules from chest, axilla, cervical and lower abdomen were observed, without involvement of the lower extremities. A Head CT scan showed a hyperdense millimeter foci located in the right caudate nucleus. Thorax CT scan showed multiple bilateral breast nodules or masses as well as innumerable diffuse bilateral chest wall

subcutaneous nodules, left lower lobe pulmonary nodule with mild mediastinal and hilar lymphadenopathy. Abdomen and pelvis CT scan showed diffuse bilateral subcutaneous soft tissue nodules, lobulated bilateral adrenal and renal masses with small nodules on the pancreatic body and tail. A subsequent fine needle biopsy was performed, in the most prominent subcutaneous nodule located in the submandibular and cervical area showing a metastatic neuroendocrine carcinoma. In view of these imaging studies suggesting multiple metastatic sites and a biopsy showing a neuroendocrine carcinoma, the most common site of investigation is the lung, however there is no significant focus of lung origin to suggest it. Consequently, making this case an even rare presentation and opening a path of possibilities of investigation.

179 DIAGNOSTIC AND MANAGEMENT DILEMMAS OF A RARE CASE OF HYPERCALCEMIA OF MALIGNANCY CAUSING RECURRENT NECROTIZING PANCREATITIS WITH DIFFICULT TO CHARACTERIZE FLUID COLLECTIONS

H Catherine, K Ellard, E Lindsey, H De Jesus, E Wallace, B Spielier, S Landreneau, LS Engel, S Walvekar. *LSU Health Sciences Center, New Orleans, LA.*

10.1136/jim-2016-000393.179

Case Report CASE: A 38 year old man recently diagnosed with small cell lung cancer by biopsy discovered during an initial workup for acute pancreatitis attributed to hypercalcemia of malignancy presented with worsening necrotizing pancreatitis on computed tomography (CT) due to recurrent hypercalcemia. Readmission prevented initiation of outpatient chemotherapy. The CT also showed a 4 cm collection in the neck with compression and a splenic vein thrombosis and a few smaller fluid collections around the tail, as well as acute edematous inflammation. He was treated with seven days of ciprofloxacin and metronidazole and Calcium was controlled with fluids. Another week later, chemotherapy was again delayed by readmission for recurrent pancreatitis with a calcium of 11.0 mg/dL, which remained elevated despite fluids. Given the persistent hypercalcemia in the setting of recurrent pancreatitis, zoledronic acid was initiated despite his poor oral hygiene putting him at higher risk of jaw osteonecrosis. An attempt to endoscopically place a pancreatic duct stent to drain the fluid collections failed and endoscopic ultrasound demonstrated imaging more consistent with necrosis. Inpatient chemotherapy was initiated to prevent further delay in treatment. Because the fluid collections couldn't be drained and surgical intervention with active malignancy was not ideal, conservative management was elected.

Discussion Paraneoplastic hypercalcemia from lung cancer is a rare etiology of pancreatitis, with the usual etiologies being gallstones and alcohol. This case demonstrates the importance and challenges of characterizing local complications of pancreatitis such as fluid collections, for which the Revised Atlanta classification provides guidance based on radiologic findings.

180 HYPOKALEMIA AND METABOLIC ALKALOSIS IN METASTATIC PANCREATIC NEUROENDOCRINE TUMOR

H Catherine, B Mock, A Richard, V Losada, LS Engel, S Sanne, S Guillory.
LSU Health Sciences Center, New Orleans, LA.

10.1136/jim-2016-000393.180

Case Report A 40 year old man with hypertension and unspecified heart failure, on high dose furosemide, presented with weakness, lower extremity swelling, abdominal pain, and refractory hypokalemia. Metastatic liver and spinal disease of unknown origin with suspicion for pancreatic primary was discovered one month prior. At the time of admission he was found to have a profound metabolic alkalosis with a pH of 7.62 and his potassium was 2.2 mmol/L. Furosemide was discontinued and he was started on acetazolamide, intravenous fluids and oral potassium. His refractory hypokalemia was determined to be secondary to ectopic adrenocorticotropin hormone (ACTH) production and excess mineralocorticoid content. Daily oral ketoconazole was added to reduce mineralocorticoid effects, and dose titrated based on 24-hr urine studies. Echocardiogram revealed normal cardiac function and lower extremity, scrotal, and abdominal swelling was attributed to compression of the venous return by tumor. Results of the biopsy showed grade 3 pancreatic neuroendocrine tumor with an-cytokeratin positive, synaptophysin positive, and 5–10% Ki-67 positive. He was transferred to the oncology service for initiation of chemotherapy with etoposide and cisplatin. He subsequently developed sepsis secondary to polymicrobial bacteremia including methicillin resistant staph aureus treated with vancomycin and ciprofloxacin. A pathological fracture of the spine progressed to paralysis below the T8 level with preserved touch, pain, and temperature sensation. Neurosurgical intervention was not pursued due to pancytopenia following his first cycle of chemotherapy. Palliative radiation provided pain relief but not return of function. Imaging showed progression of disease with pulmonary nodules and bilateral adrenal metastasis after the first round of therapy and he elected to be discharged with hospice.

Discussion This case represents an uncommon presentation of an uncommon neoplasm, pancreatic neuroendocrine tumors (PNETs). The secondary hypercortisolism can explain the refractory hypokalemia and metabolic alkalosis, as well as contribute to both his immunocompromised state and additional demineralization of his metastases-riddled bones.

181 T CELL LYMPHOBLASTIC LYMPHOMA PRESENTED WITH PERICARDIAL EFFUSION

P Chariyawong,¹ T Nantsupawat,² I Warrach,¹ N Nair¹. ¹Texas Tech University Health Sciences Center, Lubbock, TX; ²University of Minnesota, Minneapolis, MN.

10.1136/jim-2016-000393.181

Introduction T cell lymphoblastic lymphoma is a rare subtype of non-Hodgkin lymphoma accounted for 2% of adult cases.¹ Heart involvement is usually a late manifestation. Presentation with pericardial effusion is unusual.

Diagnosis can be challenging due to difficulty in distinguishing malignant cells from reactive lymphoid cells.¹ Case Patient is 40 year-old male presented with pleuritic chest pain. Echocardiography showed pericardial effusion. Pericardiocentesis was done. Patient was treated as viral infection because blood cultures were positive for Coxsackie virus B. Colchicine and indomethacin produced only transient relief. Bilateral pleural and pericardial effusions were removed subsequently via pericardial window with biopsy performed. Pathology of pericardium showed fibrotic tissue with lymphohistiocytic infiltrate, favoring a reactive etiology. Patient had recurrent pleural and pericardial effusions complicated by atrial fibrillation which required ablation. Due to no clinical improvement despite appropriate medical management, CT chest was considered which revealed soft tissue mass infiltrating the mediastinum and bilateral axillary adenopathy suggestive of malignancy. Lymph node biopsy confirmed the diagnosis of T cell lymphoblastic lymphoma. Immunostaining were positive for CD3, CD5, CD7, TdT and CD79a. Patient was treated with chemotherapy, CEOP regimen and subsequently changed to hyperCVAD regimen due to progression of the disease.

Discussion Pericardial effusion secondary to mediastinal lymphoma usually occurs later along the course of the disease. This patient presented with rare manifestation of pericardial effusion. Diagnosis was challenging. Initial pathology report of pericardial tissue showed reactive lymphohistiocyte infiltrate with no evidence of malignancy. Without immunostaining, reactive lymphoid cells may be difficult to distinguish from malignant cells.¹ This case illustrates that immunostaining should be performed to unmask the diagnosis of malignancy if treatment appears refractory.

REFERENCE

- 1 He XL, Yu F, Guo T, et al. T-cell lymphoblastic lymphoma presenting with pleural effusion: A case report. *Respir Med Case Rep* 2014;12:55–8.

182 METASTATIC OVARIAN CANCER PROVEN OTHERWISE – AN OCCULT GOBLET CELL APPENDICEAL CARCINOID

P Chariyawong, R Yendala, S Hosford, S Radhi. Texas Tech University Health Sciences Center, Lubbock, TX.

10.1136/jim-2016-000393.182

Case Report Neoplasms of appendix are rare in only 1% of all appendectomy specimens. Goblet cell carcinoid is an extremely rare type, showing features of both adenocarcinoma and carcinoids with small nests of signet ring-like cells resembling normal intestinal goblet cells but with atypia.

A 54 year-old Hispanic woman presented with abdominal bloating for 6 months and a 40-pound weight loss. Gynecologic exam showed solid slightly mobile mass with nodularity in adnexa, confirmed on the CT abdomen/pelvis as a large pelvic mass with minimal ascites. Negative colposcopy and endometrial biopsy were noted with high CA 125 at 400 and CEA at 8 followed by negative EGD and Colonoscopy. She was presumed to have ovarian cancer and subsequently underwent staging laparotomy involving

total abdominal hysterectomy, bilateral salpingo-oophorectomy, radical pelvic dissection and appendectomy. The frozen section revealed a signet ring mucinous adenocarcinoma suggestive of a metastatic GI cancer at which time a thorough intra-op GI exploration was undertaken including cholecystectomy and liver resection with no obvious primary source identified. Optimal debulking to 1–2 mm tumor size was accomplished but significant residual tumor was inevitable due to peritoneal carcinomatosis. The final pathology was positive for chromogranin, synaptophysin and CK 20 involving all pelvic sites consistent with metastatic goblet cell carcinoid tumor of appendix. She is currently on FOLFOX chemoregimen with no evidence of residual disease or recurrence clinically and radiographically for 6 months.

Goblet cell carcinoid typically presents as acute appendicitis due to luminal obstruction but has a potential to spread intraperitoneally. Prognosis ranges between malignant carcinoids and adenocarcinoma. Aggressive debulking of intraabdominal metastases with or without heated intraperitoneal chemotherapy can prolong survival. Systemic chemotherapy is less defined with FOLFOX being the most commonly utilized. In women, these adenocarcinoids can mimic ovarian cancer and we intend to increase awareness of this rare presentation with a crucial role for multidisciplinary surgical approach in determining outcome.

183 **MULTIPLE MYELOMA PRESENTING AS ACUTE LIVER FAILURE SECONDARY TO EXTRA MEDULLARY HEPATIC PLASMA CELL INFILTRATION**

S Choksi, A Omer. *Texas Tech Univ HSC Amarillo, Amarillo, TX.*

10.1136/jim-2016-000393.183

Case Report A 59 year-old Hispanic female with a remote history of breast cancer presented with signs and symptoms of liver failure. Initial evaluation revealed pancytopenia, elevated serum total protein with a low albumin level, and a high serum calcium level. Serum and urine protein electrophoresis with immunofixation was highly suggestive of multiple myeloma (MM) with an IgA monoclonal protein and lambda light chain specificity. Diagnostic imaging suggested hepatocellular dysfunction. Histopathology of bone marrow displayed 90% plasma cell infiltrate; of which 16% were lambda restricted plasma cells. Liver biopsy revealed the same type of cells infiltrating the liver sinusoids. The patient was started on dexamethasone and bortezomib and was scheduled to follow up with oncology clinic for the completion of her chemotherapy.

MM has been publicized in the literature to have plasma cell infiltration involving extramedullary organs; however, this usually happens as a later manifestation. Interestingly our patient presented initially with clinical manifestations of liver failure secondary to MM with liver sinusoidal infiltration with plasma cells.

184 **ESOPHAGEAL CARCINOMA WITH RARE DISTANT METASTASIS**

E Dauchy, L Nunez, LS Engel. *LSU Health Sciences Center, New Orleans, LA.*

10.1136/jim-2016-000393.184

Case Report Case: A 56 year old African American man with a past medical history of hypertension and tobacco use presented to the emergency department with chronic low back pain that gradually worsened over three months prior to presentation. He went to an urgent care clinic when the pain began to radiate down his bilateral lower extremities and was told he had 'bone disease.' He reported lack of appetite and an unintentional 15 pound weight loss over three months. He was afebrile on presentation and labs were notable for a WBC count of 17,300/UL and serum calcium of 11.6 mg/dL. Imaging of the lumbar spine had findings consistent with destruction of the L4 vertebral body and advanced lytic lesions of L5/S1. Computed tomography of the abdomen and pelvis was notable for diffuse thickening of the distal esophagus with significant lymphadenopathy around the lesser curvature of the stomach. Also present was a hypodense lesion on the right psoas with surrounding contrast enhancement, for which he was started on empiric vancomycin. GI was consulted for EGD and biopsy of the esophageal mass, while Interventional Radiology was consulted to biopsy the right psoas lesion to rule out infectious etiology. EGD was notable for a friable, fungating near-obstructive circumferential mass at least 8 cm long from which biopsies were obtained. He was maintained on a clear liquid diet while awaiting palliative esophageal stent placement and final pathology to determine course of treatment. Radiation Oncology was consulted for palliative therapy directed at the bone lesions. After the first cycle of XRT, the patient went into cardiac arrest and resuscitation efforts were unsuccessful. Esophageal biopsies resulted as poorly differentiated squamous cell carcinoma and the psoas lesion biopsy was consistent with metastatic squamous cell carcinoma.

Discussion We present a rare case of esophageal carcinoma with skeletal muscle metastasis (SMM). Little is known about the outcome of patients with SMM as most available evidence is found in anecdotal case reports. This case serves as a reminder that distant metastatic disease can present in any location and rare sites must also be considered.

185 **PARANEOPLASTIC LEUKOCYTOSIS IN RENAL CELL CARCINOMA**

RE Gavidia Quezada, H Igid, E Juarez Ramirez Tello, S Radhi. *Texas Tech Health and Science Center, Lubbock, TX.*

10.1136/jim-2016-000393.185

Case Report A 79-year-old male presented to the hospital for a 2-week history dyspnea, cough, fever, and unintentional weight loss. His WBC count was elevated at 40,000. Imaging studies revealed multiple (>30) scattered subcentimeter nodules on both lungs as well as a right renal mass. Extensive work up done did not reveal any source of infection. Biopsies of his right renal mass and lung masses were done and confirmed the diagnosis of metastatic renal cell carcinoma (RCC). Despite empiric antibiotic therapy, his WBC count continued to rise to 78,000 in 2 weeks. A peripheral smear was reviewed followed by a bone marrow biopsy that both showed neutrophilia without any evidence of malignancy. Serology for GM-CSF and IL-6 were noted to be elevated which supported the diagnosis of

paraneoplastic leukocytosis and fever from RCC. Notably, he had recent hospitalizations for a hip fracture as well as skin infection that was adequately treated with antibiotics. During that time, his WBC count ranged between 18,000 to 30,000.

RCC may present with local symptoms of abdominal pain, mass, and hematuria, or incidentally found on imaging studies done for other reasons. However, in about 20% of cases, it presents with seemingly unrelated symptoms due to paraneoplastic syndromes of which hypertension (renin), hypercalcemia (PTHrP), polycythemia (erythropoietin), and Cushing syndrome (ACTH) are more common. In very rare occasions, patients may also present with persistent leukocytosis and fever and hence often mistaken to have an underlying infection. In these cases, leukocytosis persists despite antibiotics and paraneoplastic syndrome should be entertained. Elevated levels of GM-CSF, G-CSF, and IL-6 support the diagnosis of paraneoplastic cause of leukocytosis. Improvement of leukocytosis is expected with treatment of RCC. Unfortunately, patients with RCC presenting with leukocytosis have poorer prognosis as demonstrated in this case, where his functional status progressively declined that he elected for hospice care.

Paraneoplastic syndrome should be considered as a cause of persistent leukocytosis and fever in a patient with underlying malignancy especially if no obvious underlying infection is identified.

186 CIPROFLOXACIN INDUCED THROMBOTIC THROMBOCYTOPENIC PURPURA

U Giri, N Jain, A Vaughn, C Sands. *University of Tennessee Health Science Center, Memphis, TN.*

10.1136/jim-2016-000393.186

Introduction Thrombotic thrombocytopenia purpura (TTP) is a potentially fatal condition characterized by microangiopathic hemolytic anemia and thrombocytopenia and maybe accompanied by renal failure, fever and neurological symptoms. We report a rare case of ciprofloxacin induced TTP successfully treated with plasma exchange and steroids

Case description A 50-year-old African American woman presented with abdominal pain of one-week duration. She had completed a course of ciprofloxacin for urinary tract infection prior to this. Physical examination was unremarkable except for diffuse abdominal tenderness. Lab tests showed hemoglobin 9.4 g/dL, WBC 8,600/mm³, platelet count 21,000/mm³ (decreased from 225,000/mm³) and numerous schistocytes on peripheral smear. Other relevant lab findings included total bilirubin 2.2 mg/dL, creatinine 2.1 mg/dL (baseline 1.1 mg/dL), LDH 934 U/L, haptoglobin <8 mg/dL, reticulocyte 4.4%, PT-INR 1.1, APTT 30.5 s, and fibrinogen 354 mg/dL. Lipase, ALT, AST, and ALP were normal. Though initial abdominal imaging showed gallbladder sludge and wall thickening, a HIDA scan performed later ruled out acute cholecystitis. The above findings were suggestive of TTP and intravenous steroids and plasma exchange was initiated.

Direct antiglobulin test, HIV screen and hepatitis panel were negative, blood culture showed no growth, and complement levels were normal. Antinuclear antibody (ANA) titer was positive (ANA index 1.6) without any mucocutaneous or joint manifestations and negative extractable nuclear antigen profile. ADAMTS13 sent prior to treatment was later reported as <3, with elevated ADAMTS13 inhibitor confirming the diagnosis of acquired TTP. The patient improved after four sessions of plasmapheresis, with platelet count 210,000/mm³ and LDH 230 U/L on discharge. With a score of 6 on the Naranjo Adverse Drug Reaction Probability Scale, this was a probable adverse drug reaction to ciprofloxacin.

Discussion Drug induced TTP or thrombotic microangiopathy is due to the formation of drug dependent antibodies (immune mediated) or direct tissue toxicity (toxicity mediated). Physicians must be aware of this rare adverse reaction to ciprofloxacin, one of the most widely used antibiotics, for early diagnosis and prompt initiation of treatment.

187 VERTEBRAL COMPRESSION FRACTURES AS A UNIQUE PRESENTATION OF ACUTE LYMPHOCYTIC LEUKEMIA IN A 3-YEAR-OLD MALE

KM Gleditsch, R Gardner. *Louisiana State University Health Science Center, New Orleans, LA.*

10.1136/jim-2016-000393.187

Case Report Acute lymphoblastic leukemia of the precursor B cell lineage is the most common malignancy of children. The symptomatology at presentation classically includes generalizable symptoms of fever, leg pain, bruising and fatigue. We present the case here of a 3 year old male who initially presented to his pediatrician with none of the classic complaints. This patient initially presented to his pediatrician after a trip to Mexico with his family during which he fell on his coccyx and immediately began complaining of low back pain. He presented to his pediatrician several times with this complaint and otherwise asymptomatic before a diagnosis was reached. The severity of his back pain prompted an MRI which showed numerous lumbar vertebral compression fractures. A CBC was then obtained which showed leukocytosis and a significant blast cell population. Flow cytometry on peripheral blood and bone marrow confirmed the diagnosis of Precursor B Cell ALL. The patient was promptly started on chemotherapy and his back pain resolved within 3 weeks.

188 THREE STRIKES BUT NOT OUT

JA Groot, SJ Groot, A Wood, S Nadesan. *Texas Tech Univ HSC Amarillo, Amarillo, TX.*

10.1136/jim-2016-000393.188

Case Report A 71-year-old male patient presented to the hospital complaining of fatigue and constipation. He was noted to have a hemoglobin of 6.4 g/dL, MCV of 94, corrected reticulocyte count of 5.3%, leukopenia of 3.4, LDH of 442 U/L, and total bilirubin of 3.9 with an indirect of

3.6. He had a vitamin B12 level of 137 pg/mL and positive intrinsic factor antibody test indicative of pernicious anemia. He also had a low Ferritin level of 23 ng/mL with no stainable iron on a bone marrow biopsy suggesting iron deficiency anemia. Upper endoscopy revealed arteriovenous malformations (AVM) in the trachea and stomach. The patient had direct and indirect Coombs positivity (anti-IgG, anti-C3B, and anti-C3D) along with elevated indirect bilirubin, LDH, and splenomegaly (17 cm) with a reticulocyte count of 14% indicating hemolytic anemia. The iron deficiency and pernicious anemia were corrected with iron and vitamin B12 supplementation as demonstrated by a corrected reticulocyte count of 4.86% six days after initiation. Hemolysis continued despite steroid therapy. A splenectomy was performed with anemia resolution. Current hemoglobin is 13.6, MCV 102, corrected reticulocyte count of 2.16% and a bilirubin of 1.0.

Discussion The most common form of anemia is iron deficiency anemia resulting from decreased iron stores, with a prevalence of 5% in men and 14% in women. Iron deficiency anemia can be asymptomatic or may present with exertional dyspnea, dizziness, fatigue and conjunctival pallor. Pernicious anemia is a macrocytic, megaloblastic anemia caused by a deficiency in the vitamin B12 stores of the body due to an autoantibody against intrinsic factor and/or gastric parietal cells. It has a prevalence of 0.1% in the general population and 1.9% in those over 60. Autoimmune hemolytic anemia may be primary-idiopathic, with an incidence of 0.8% per year, or secondary caused by an underlying condition such as autoimmune disease, infection, or drugs. This case is unique as the patient had anemia from three causes- iron deficiency secondary to AVM, pernicious anemia, and autoimmune hemolytic anemia. This case should remind physicians that a normal MCV can be composed of macrocytic and microcytic red cells from concurrent anemias.

189 DOUBLE TROUBLE

SJ Groot, JA Groot, A Wood, S Nadesan. *Texas Tech Univ HSC Amarillo, Amarillo, TX.*

10.1136/jim-2016-000393.189

Case Report A 57-year-old female presented with a history of ductal carcinoma in situ of the left breast and a low to mild dysplastic mixed tubular adenomatous and hyperplastic polyp of the ascending colon at age 56. A family pedigree revealed breast cancer in two sisters at ages 40 and 43, two paternal aunts at ages 55 and 69 and paternal grandmother at age 69. Her father at age 57 and grandfather at age 68 had prostate cancer. The sister with breast cancer had colon cancer at age 45 as did her paternal uncle at age 55. Her father also had a glioblastoma at age 62. A paternal uncle had kidney cancer at age 64. Cancer gene assessment revealed a heterozygous 5'UTR_Ex1Del in the BRCA2 gene and a heterozygous c.251-2A>T mutation in the PMS2 gene. BRCA2 gene mutation is associated with hereditary breast and ovarian cancer. PMS2 gene mutation is associated with Lynch syndrome (hereditary non-polyposis colon cancer) causing polyposis and colorectal cancer. Patient underwent a hysterectomy, bilateral

salpingo-oophorectomy, segmental resection of the colon and is being closely monitored.

Discussion Breast and colon cancers are the second and third leading causes of cancer death in women. A hereditary etiology in cohorts with multiple cancers needs to be investigated. BRCA2 is a tumor suppressor gene. Its protein product repairs DNA and prevents rapid and uncontrolled cell division. BRCA2 gene mutation carries a lifetime risk of 45% for developing breast cancer and 11–17% for ovarian cancer. Its estimated prevalence is 1–3%. It is associated with breast, ovarian, prostate, pancreatic, male breast cancers and melanoma. Lynch syndrome is a genetic predisposition due to mutations in the MLH1, MSH2, MSH6, and PMS2 genes which govern DNA mismatch repair. Lynch syndrome carries a lifetime risk of 52–82% for developing colorectal cancer, 25–60% for endometrial cancer, 6–13% for gastric cancer and 4–12% for ovarian cancer. Lynch syndrome can cause colorectal, endometrial, biliary tract, ovarian, gastric, upper urinary tract and brain cancers. The prevalence of Lynch syndrome is estimated to be 1 in 440. This case is unique for the presence of concurrent mutations of the BRCA2 and PMS2 genes and emphasizes the need for cancer gene panels using next generation sequencing technology to reveal simultaneous mutations in multiple genes.

190 GASTROINTESTINAL TUMOR PRESENTING AS INFERIOR VENA CAVA SYNDROME

M Gutierrez, B Lyons, W Aung. *University of Florida-Jacksonville, Jacksonville, FL.*

10.1136/jim-2016-000393.190

Case Report Patient is a 67 y/o male with history of Legal blindness, Hepatitis C, drug and tobacco abuse who came in of complaining of worsening bilateral lower extremity swelling of 3 weeks duration. Patient denied any other associated symptoms. Physical examination of the abdomen revealed a poor-defined, hard, immobile mass in the right upper and lower quadrant for which an abdominal CT scan was ordered and revealed a 13x15 cm large mesenteric mass encasing adjacent bowel loops and exhibiting compression of nearby organs. The mass' extension into the IVC was presumed to be the possible cause of the patient's complaint as the cardiac echo revealed a preserved ejection fraction. Noteworthy on laboratory results were an elevated INR of 1.4 as well as an elevated CEA tumor marker at 4.04. AFP and CA 19-9 were negative. The results of an initial biopsy of the mass were inconclusive. Repeat biopsy results showed histologically mixed epithelioid and spindle cells and immunohistochemistry was CD117-positive suggestive of gastrointestinal stromal tumor (GIST). The tumor was classified as stage IIIB (T4n0m0) per abdominal CT findings. Due to the high degree of disease advancement, the tumor was deemed unresectable and the patient was started on Gleevec 400 mg QD for palliative therapy vs neo-adjuvant therapy with plans for follow up abdominal CT scan in 3 months to reassess for any tumor regression for possible resection. However, patient was lost to follow up.

Discussion GIST are the most common types of mesenchymal neoplasms that affect any portion of the GI tract although overall, they only constitute about 1% of primary GI cancers. The majority of cases are usually sporadic in origin. GISTs are identified by a mutation in the KIT (CD117) in >90% of cases. Features of the tumor can vary depending on the size and organ of origin which in this case, caused vena cava compression presenting as the unusual initial manifestation. Inferior vena cava syndrome (IVCS) could occur as a result of IVC obstruction or thrombosis and present with nonspecific symptoms including peripheral edema. In this particular case, it was the initial feature of an underlying undiagnosed malignancy.

Conclusion We recommend workup for underlying malignancy in patients showing symptoms of IVCS once other differential diagnoses have been ruled out.

191 LESSON IN RESILIENCE FROM THE HEART OF A CHAMPION: A CASE OF METASTATIC MELANOMA OF THE HEART DIAGNOSED ANTEMORTEM

D Hansen, N Sheehan. *University of Mississippi Medical Center, Jackson, MS.*

10.1136/jim-2016-000393.191

Introduction Malignant melanoma has an unpredictable clinical behavior with metastases in unusual sites. Melanoma has a great propensity for cardiac involvement but it is typically diagnosed via autopsy postmortem given its non-specific clinical symptoms. Only 5 other cases of antemortem metastatic melanoma of the heart have been described in the literature. Here, we report a case of a patient with metastatic melanoma of the heart diagnosed antemortem.

Case Report A 64-year-old white man with history of coronary artery disease and left shoulder melanoma presented with shortness of breath and dizziness. Patient was found to have a non ST elevation myocardial infarction. Cardiac catheterization revealed no stenotic lesions while echocardiogram demonstrated a large right atrial echodensity concerning for a myxoma. Computed tomography of the chest, abdomen and pelvis demonstrated a 4.5 centimeter lobulated mass in the right atrium consistent with a myxoma rather than metastatic disease.

Patient had a previous history of left shoulder melanoma diagnosed approximately 10 years ago. He underwent a wide local excision but did not receive systemic chemotherapy. Physical examination revealed a large well-healed left shoulder scar approximately 2×4 cm.

Patient underwent resection of the right atrial mass with reconstruction of the right atrium and superior vena cava to right atrial bypass. Pathology revealed metastatic melanoma with positive resection margins and lymphovascular invasion. BRAF mutation was not detected. Positron emission tomography demonstrated no other evidence of disease. Patient is currently receiving immunotherapy with nivolumab and ipilimumab and is tolerating it well.

Discussion Metastatic melanoma of the heart is rarely identified antemortem as it is clinically silent or masked by symptoms of other visceral metastases. The presence of

cardiac metastases should be investigated with routine echocardiogram even in the absence of symptoms due to significant impact on survival. Systemic chemotherapy has been used without much success for cardiac melanoma. Advent of immunotherapy is very promising but no data or clinical trials are currently available for management of metastatic melanoma of the heart, hence posing a treatment dilemma.

192 A RARE CASE OF PRIMARY RENAL CARCINOID TUMOR

D Hansen, J Eubanks. *University of Mississippi Medical Center, Jackson, MS.*

10.1136/jim-2016-000393.192

Introduction Primary renal carcinoids are exceedingly rare tumors consisting of neuroendocrine cells. Carcinoid tumors most commonly occur in the gastrointestinal tract and lungs, and less frequently in the genitourinary system. Pathogenesis of renal carcinoid is unclear as neuroendocrine cells are not found in the renal parenchyma. Owing to rarity of this malignancy, clinical course of this disease and appropriate management are not well established.

Here, we report a rare case of a patient with renal carcinoid diagnosed following right radical nephrectomy.

Case Report Patient is a 55-year-old man who presented with right flank pain, chronic diarrhea and a 10-pound weight loss. A renal mass was visualized on abdominal ultrasonography. Subsequent computed tomography of the abdomen demonstrated a 2.2×1.7×1.6 centimeter lesion at the lower pole of the right kidney. Cystoscopy and retrograde pyelogram demonstrated no involvement of the collecting system. Patient declined biopsy of the lesion and instead underwent a right radical nephrectomy. Originally, the neoplasm was felt to represent a urothelial carcinoma, however, upon review at Mayo Clinic, pathology returned as a renal carcinoid with lymphovascular invasion, low Ki 67 proliferative index and 2 mitoses/10 high power field.

Serum chromogranin A and 24-hour urine 5-hydroxyindoleacetic acid levels were within normal limits. Octreotide scan demonstrated no scintigraphic evidence of recurrent or residual disease. Patient's diarrhea resolved and without evidence of flushing or wheezing. He was placed on observation and has not required any adjuvant therapy.

Discussion Primary renal carcinoids are extremely rare indolent neuroendocrine tumors. They typically pose diagnostic dilemmas because of their rarity, similar presentation with other renal tumors and minimal clinician awareness. Conventional imaging lacks sensitivity in detecting carcinoid tumors so somatostatin receptor scintigraphy should complement computed tomography and magnetic resonance imaging when searching for either occult or metastatic disease. Surgical resection of the kidney is the treatment of choice for localized primary renal carcinoid, however, there is a paucity of data in regards to treatment of metastatic disease with novel agents. Long term follow-up is necessary due to risk of recurrence.

193 PROTHROMBIN TIME TO ASSESS RIVAROXABAN EFFECT

S Hebert, B Boulmay, S Subbiah, P Rigby. *Louisiana State University Health Sciences Center, Section of Hematology & Oncology, New Orleans, LA.*

10.1136/jim-2016-000393.193

Introduction Rivaroxaban (R) is frequently prescribed for multiple indications. Monitoring of drug effect is not required, but reproducible measurement is not readily available for complications.

Case presentation A 59 year old male with a past medical history of hepatitis C and pulmonary embolism treated with R, presented to the emergency department (ED) due to breathlessness. R compliance was unclear. Prothrombin time (PT) measured at 20 seconds (s). During admission, he was treated for heart failure and pneumonia; R was resumed at 20 mg daily without PT monitoring. One day after discharge, the patient re-presented to the ED after fall. PT measured at 117 s; R was held. Readmission day 2, the PT was 155 s. Vitamin (v) K 5 mg orally and 10 mg IV were administered 9 hours later. Prothrombin complex concentrate (PCC) 3000 units was then administered, PT was 49 s. PT was trended for 4 days after PCC and was 17 s, near previous baseline.

Discussion Quantification of anticoagulation is not readily available for R. R has been observed to dose-dependently increase PT, though measurement is unreliable per individual patient and between laboratories. Variability of sensitivity of reagents used between labs for PT make measurement inconsistent between labs; inter-lab variability is not corrected with use of INR, which is specific for vK antagonist (VKA) only. Unlike VKAs, the effect of R on the PT is short-lived and dependent on dose timing and drug absorption. Studies suggest chromogenic anti-factor Xa (AXA) measurement may be useful in high risk patients to assess anti-coagulation effect. Individualized correlation of AXA and PT, both R dose dependent, may allow utilizing PT for rapid assessment over long periods. Expression of PT in plasma concentration of R may overcome reagent variability and correlate AXA with PT. Though PCC is typically used to reverse VKA anticoagulation, the above case resulted in significant improvement of measured PT. Patients with Child-Pugh A/B hepatic dysfunction have decreased clearance of R, which can lead to excessive anticoagulation and further prolongation of PT; R is not generally recommended. If anticoagulation is necessary and limited to R in these patients, a combination of AXA and PT may be an option for therapeutic monitoring.

194 A RARE CASE OF EXTENSIVE MYCOSIS FUNGOIDES WITH LARGE CELL TRANSFORMATION

J Hsu, V Herrin. *University of Mississippi, Jackson, MS.*

10.1136/jim-2016-000393.194

Case Report Mycosis fungoides is the most common subtype of cutaneous T cell lymphoma that presents with potential patches, plaques, tumors, and erythroderma that may involve the blood, nodes, and viscera. The incidence is six cases per million per year with large cell transformation

representing 20–50% of these cases. Mycosis fungoides typically has an indolent course but has been shown to have a poorer prognosis with extracutaneous manifestations and large cell transformation.

We present a 42 year old Black male with history of hypertension who presented one year prior to a local dermatologist with a small lesion on his left forearm that was present for seven years. Patient underwent a biopsy revealing stage 2A cutaneous T-cell lymphoma. Patient did not undergo local therapy for over one year secondary to lack of finances and developed progressive disease.

Patient was seen as an emergent referral from Dermatology after being seen in the emergency department for lower extremity cellulitis with diffuse erythroderma, tumors, plaques, alopecia, and patches involving >80% of the skin. Patient had a CT CAP showing multifocal areas of skin thickening and nodularity with extensive bilateral axillary, inguinal, iliac chain adenopathy with a 5.6×4.4 cm lobulated hypodensity in the superior spleen. Multiple skin biopsies revealed sheets of atypical lymphoid cells with expression of CD3/CD4, with elevated CD4:CD8 ratio with loss of CD7/CD8/PAX5/CD30 expression with >25% of cells representing large cell transformation.

Patient had a WBC of 4.8 with 70% neutrophils, 6% lymphocytes, 11% eosinophils, and 4% basophils with a normocytic anemia with hemoglobin of 10.6 and platelets of 281. Peripheral blood flow cytometry showed few aberrant T-cells CD3+, CD4+, CD7- with 111 cells/cmm showing a CD4:CD8 ratio of 4.91. The patient did not meet diagnostic criteria of Sezary syndrome with absolute Sezary count of <1000 cells/cmm and CD4:CD8 ratio of <10.

Due to the extensive cutaneous disease with visceral involvement and large cell transformation, our patient was treated with R-EPOCH – rituximab, etoposide, prednisone, vincristine, cyclophosphamide, and doxorubicin.

Mycosis fungoides with large cell transformation is a rare condition that can present as diffuse dramatic cutaneous manifestations if neglected.

195 ADULT BRAIN METASTASIS FROM A CHILDHOOD ORGAN

TR Jackson, N Jain, U Giri, G Phelps. *University of Tennessee Health Science Center, Georgetown, TN.*

10.1136/jim-2016-000393.195

Introduction Thymus gland normally atrophies after puberty. Although thymic cancer can present with local compression and paraneoplastic syndromes, brain metastases are less commonly reported. We report a case of ataxia from squamous cell cancer of thymus with cerebral metastasis.

Case Description A 68-year-old Caucasian man with no pertinent medical history, presented with difficulty walking and swaying to right for one month. He denied weakness, sensory disturbances or change in bowel or bladder habits. Physical and system based examinations were unremarkable except for ataxia. Brain MRI showed a 4.6 cm×4 cm×2.5 cm mass with cystic and solid components, and

surrounding vasogenic edema in the left cingulate gyrus. CT of chest, abdomen and pelvis revealed a 3.5×3.8 cm soft tissue mass in the anterior superior mediastinum. CT guided core biopsy of the mediastinal mass and histopathologic examination showed a poorly differentiated squamous cell carcinoma of thymus. Immuno-histochemical staining was positive for pankeratin, CD117 (C-kit) and CK-5/6. He underwent left parieto-occipital craniotomy and mass resection. Histopathologic examination showed poorly differentiated metastatic non-small cell carcinoma with staining positive for C-kit and squamous cell markers p40 and CK5/6, similar to the mediastinal mass, confirming brain metastasis from thymic carcinoma. The patient is currently receiving inpatient rehabilitation for post-operative residual right sided weakness. Further treatment with chemotherapy or radiotherapy would be decided based on his functional recovery and performance status.

Discussion Thymomas are uncommon epithelial tumors that rarely metastasize to lung, bone, kidney or liver. They may be found incidentally on imaging or present with dyspnea, chest pain or cough symptoms. Masaoka staging for thymoma is an anatomical system based on the degree of invasion, while the WHO system is based on histologic features. There is no definite consensus on management of these tumors. Although metastasis to the brain suggests a poor prognosis, survival may be improved with resection of the mass followed by multimodality treatment.

196 HEMOPHAGOCYtic LYMPHOHISTIOCYTOSIS IN A INTRAVASCULAR LARGE B CELL LYMPHOMA. A RARE PRESENTATION OF A UNCOMMON FORM OF LYMPHOMA

E Juarez Ramirez Tello,¹ H Igid,² A Fuller,² M Lacy,² S Radhi². ¹Texas Tech Health Science Center, Lubbock, TX; ²Texas Tech University, Lubbock, TX.

10.1136/jim-2016-000393.196

Case Report A 75-year-old Caucasian male presented with weakness, fever of up to 103°F, failure to thrive, and altered mentation. He was initially hypotensive; physical examination revealed generalized weakness but otherwise unremarkable. He was empirically treated with antibiotics but despite an extensive evaluation, no source of infection was identified and his fever persisted. Initial imaging studies did not show any abnormalities. His course was notable for refractory anemia and thrombocytopenia that required repeated transfusion of blood products. A bone marrow biopsy done revealed no gross microscopic abnormalities, however, his ferritin levels were noted to have markedly increased and with further lab testing, the diagnosis of hemophagocytic lymphohistiocytosis (HLH) was made. A liver biopsy done to investigate liver failure revealing striking sinusoidal clusters of large neoplastic B cells. With these pathologic findings, additional staining of his initial bone marrow biopsy was performed which then highlighted large B cells with similar pattern of involvement as in the liver. Based on these findings, a diagnosis of intravascular large B cell lymphoma (IVLBCL) was finally made.

IVLBCL is a rare and very aggressive form of large B cell lymphoma characterized by neoplastic B cells proliferating

within small vessels that can involve any organ but spares the lymph nodes. It most commonly presents with fever and altered mentation but in rare occasions, can also present with HLH. Interestingly, the co-occurrence of HLH and IVLBCL is well described in Asian patients which occurs in 59% of cases but is rarely seen in Caucasian patients where only very few cases have been reported.

There should be a high index of suspicion for IVLBCL in a patient presenting with altered mentation, fever, and HLH with no obvious underlying cause despite an extensive evaluation. Arguably, early diagnosis may make a difference in survival if therapy is initiated. Unfortunately, in this case, the patient expired while awaiting final pathologic confirmation.

197 METASTATIC CARCINOID TUMOR DEBUTATING WITH SEVERE DOUBLE VALVULAR DISEASE

E Juarez Ramirez Tello,¹ A Adiga,¹ K Nugent². ¹Texas Tech Health Science Center, Lubbock, TX; ²Texas Tech University, Health Science Center, Lubbock, TX.

10.1136/jim-2016-000393.197

Case Report 27 year old female with right upper quadrant (RUQ) abdominal pain, fatigue, fever, diarrhea, nausea, vomiting. Dyspnea, anxiety, palpitations, diaphoresis, facial flushing present. Exam with 3/6 LLSB Systolic murmur, lower extremity pitting edema, tenderness to palpation to RUQ. Lab results with Elevated D-Dimer (647), total bilirubin 1.5, direct Bilirubin 0.3, white cell count 15 K/μl, high ESR and CRP. Abdominal ultrasound showed multiple complex cyst on liver with target appearance. Stool ova and parasite, echinococcus, entamoeba negative. 24 h Urine 5-HIAA and chromogranin A. Patient started on octreotide therapy, symptoms improved significantly. Ultrasound guided liver biopsy confirmed diagnosis of Carcinoid tumor. Diagnostic protocol failed to identified primary tumor, capsule endoscopy showed highly suspicious mass in the ileo cecal valve. TTE showed abnormal ventricular septal motion LVEF 55%, right ventricular enlargement. Mildly thickened tricuspid aortic valve, mild aortic valve regurgitation, mildly thickened mitral valve, mild mitral regurgitation. Thickened pulmonary- valve, -annulus. Increased systolic Doppler flow velocities across the pulmonary valve. Pulmonary valve systolic mean gradient 12 mmHg. Severe tricuspid valve regurgitation. Incomplete tricuspid valve coaptation. Tricuspid valves thickened and immobile. Severe tricuspid valve regurgitation. Tricuspid valve diastolic mean gradient 4 mmHg. Patient started on Lanerotide 30 mg IM monthly and referred to Mayo Clinic for further treatment.

Carcinoid tumor, has an incident of 1.2 to 2.1 per 100 k people, mean age of 55 to 60 years. Only 20% presenting heart involvement, left side cardiac involvement occurs in less than 10%. However when the primary tumor stems from a pulmonary bronchus it may result in involvement of the left-side heart valves. The presence on both vales is associated with a severe and poorly controlled disease.

4% of cases have metastatic disease in valves and 3.8% myocardial involvement. In this case, early presentation

(age 27 with no history, severe pulmonary tricuspid mitral disease) prompts to expect higher index of suspicion to diagnose and start early treatment in younger age group.

198 CHRONIC MYELOGENOUS LEUKEMIA BCR/ABL POSITIVE COMPLICATING A PREGNANCY

E Juarez Ramirez Tello,¹ A Sultan,¹ S Khan,² L Tijani,² K Nugent². ¹Texas Tech Health Science Center, Lubbock, TX; ²Texas Tech University, Lubbock, TX.

10.1136/jim-2016-000393.198

Case Report 25 year old female presented to emergency room for abdominal pain and two months of amenorrhea. Pregnancy test positive, physical exam showed large abdominal mass in upper left quadrant. Ultrasound shows hepatosplenomegaly, spleen measuring 27 cm longitudinally. White cell count (WBC) of 242 K/ul. Bone marrow biopsy revealed changes consistent with chronic myeloid leukemia (CML) with no significant increase in the blast population CD34 & CD117, mild fibrosis (1/4) and small polyclonal B-cell lymphoid population. Flow cytometric analysis showed majority of cells mature granulocytes with small blast population (<2%). FISH study confirmed BCR/ABL translocation 100%. Interferon- α (INF α) started at 6 MM unit/m², and was adjusted according tolerance. At week 18 hemoglobin (Hb) of 6.4 g/dl, with elevated indirect bilirubin and lactic dehydrogenase concerning for cold agglutinin disease, tested positive on both warm IgG and complement positive on Coombs test. INF α therapy stopped, patient started on folate and steroids. Received blood transfusion after been premeditated with IVIG with good response. Patient discharged on INF- α 3 MM unit/day. Prednisone dose continued to be tapered. Oncology recommended induction of labor at week 34. Two days after delivery patient started on Hydroxiurea and Allopurinol for cytoreduction. WBC was 70 k/ul, after 24 hours WBC decreased to 68 k/ul. Patient discharged 5 days post delivery, with no complains and started Desatinib. Two weeks after adding Desatinib her WBC decreased to 22 K/ul with Hb of 12.4 g/dl, after 4 weeks WBC at 8 K/ul and Hb 11 g/dl.

The coincidence of CML and pregnancy is uncommon in part because CML occurs mostly in older age groups with a median age of 57 to 60 years. The management of CML during pregnancy is problematic due to side effects of the therapy to mother and fetus. Pregnant patients with CML are at risk of leukostasis, as well as placental insufficiency with risk for low birth weight, prematurity and increased mortality. Successful treatments case reports are needed to provide alternative safe and effective therapeutical options.

199 SYMPTOMATIC SMOLDERING WALDENSTROM MACROGLOBULINEMIA

E Juarez Ramirez Tello,¹ A Sultan,¹ M Shanshall,² S Awasthi². ¹Texas Tech Health Science Center, Lubbock, TX; ²TTUHSC, Lubbock, TX.

10.1136/jim-2016-000393.199

Case Report 80 year old man with hypertension, atrial fibrillation/flutter S/P cardiac resynchronization device, present fatigue, headache and decreased vision. Exam

Figure 1.

Test	May/19 th /2016	July/21 th /2016	July/26 th /2016	August/2 nd /2016
White cell count (K/ul)	8.27	7.39	7.23	8.1
Red blood cell (M/ul)	5.35	5.56	5.67	5.37
Platelets (K/ul)	230	223	221	225
Creatinine (mg/dl)	1.3	1.1		1.1
EGFR	53.2	64.4		64.4
Total protein (g/dl)	8.7	8.2	8.7, 8.6	8.7
Albumin (g/dl)	3.7	3.6	3.5	3.3
Alpha 1 fraction (%)	4	4.4		4.5
Alpha 1 (g/dl)	0.34	0.36		0.39
Alpha 2 fraction (%)	11.6	11.8		10.6
Alpha 2 (g/dl)	0.91	0.97		1.01
Beta 1 fraction (%)	5.5	5.6		6.0
Beta 1 (g/dl)	0.47	0.46		0.52
Beta 2 fraction (%)	9.5	3.9		4.0
Beta 2 (g/dl)	0.82	0.32		0.35
Gamma fraction (%)	30.2	32.9		32.3
Gamma (g/dl)	2.6	2.7		2.81
M spike (%)	26.0	27		25.8
M spike (g/dl)	2.24	2.21		2.24
Serum protein electrophoresis	M spike	M spike		M spike
Serum immunofixation		IgM and Lambda paraproteins		IgM and Lambda paraproteins
IgG		555 (L)		527 (L)
IgA		78		74
IgM		3,802		3,604
Flow cytometry			96 Viability	
Multiple myeloma markers			CD10, CD19, CD20, CD38, CD45, CD56, Kappa and Lambda chains (intracellular)	
Bone marrow biopsy report			5% Plasma Cells	
Beta-2-Microglobulin, Serum		2.8		
Free Kappa light chain		13.8		15.49
Free Lambda light chain		55.53		61.10
Kappa/Lambda free		0.25 (L)		0.25
Serum Viscosity		2.4		
NM Chromosome/Genetic report (FISH)				Negative for Multiple Myeloma

(L) Lower than normal values. Red color represent higher than normal values

Abstract 199 Figure 1

remarkable for lower extremity edema, abdominal distention, no hepatosplenomegaly was noted.

Initial work up revealed hyponatremia; hearth failure treatment was optimized with no symptoms relieve, implantable device malfunction was ruled out, however symptoms persisted. Initial work up revealed WBC 5.4 g/dl, Hb 15.7 g/dl, platelets 221 K/ul, total protein to 8.7 g/dl. Serum protein electrophoresis was ordered which revealed IgM of 3,802 mg/dl, patient referred to Hematology clinic where further work up (fig.1) that was consistent with smoldering waldenstrom macroglobulinemia (SMW).

SWM is a rare poorly described asymptomatic disorder characterized by the presence of a serum IgM value ≥ 3 g/dL and/or $\geq 10\%$ bone marrow lymphoplasmacytic infiltration of the bone marrow but no evidence of end-organ damage, such as symptomatic anemia, hyperviscosity, lymphadenopathy or hepatosplenomegaly. It is believed to affect 20% of patients diagnosed with MGUS with a higher rate of progression to WM up to 12% per year with a median progression time of 4.6 years, this patients should be closely monitored every 3 to 4 months; high risk patients may benefit of low toxicity treatment. This case represent an unusual presentation of a rare condition, high index of suspicion is needed ensure timely treatment.

200 A MIXED LINEAGE CRISIS

SM LeTellier. University of Mississippi Medical Center, Brandon, MS.

10.1136/jim-2016-000393.200

Case Report 67 year old male diagnosed with accelerated phase CML in 6/2015 with two blast populations on bone marrow biopsy represented by 7% myeloid blast and 6%

lymphoid blast. Patient was initially managed with dasatinib. Unfortunately he was noncompliant and lost to follow up. He represented with blurry vision and headaches in 10/2015 and found to have a leukocyte count of 739,000. The patient underwent leukopheresis times two for symptomatic leukostasis. Peripheral blood flow cytometry was consistent with CML with AML blast crisis with 46% myeloid blast. Chromosome analysis was consistent with clonal evolution with 2 clonal mutations. The patient underwent induction with 7+3. His day 14 bone marrow was positive for residual leukemia. However, flow cytometry now revealed a blast population consistent with precursor T cell ALL with 90% blast. He was re-induced with a SWOG 8417 ALL protocol, received seven prophylactic lumbar punctures all of which were negative, and was maintained on dasatinib. Regrettably during the course of his two inductions his performance status decreased considerably. He received two further doses of vincristine as part of ALL maintenance which were poorly tolerated. He re-admitted in 2/2016 for a febrile syndrome and diffuse rash. A skin biopsy was consistent with neutrophilic eccrine hidradenitis secondary to dasatinib which was subsequently held. His rash resolved with time and he was changed to ponatinib the same month. He has tolerated ponatinib well and achieved a complete hematologic response. Further maintenance and consolidation for both AML and ALL have been held secondary to poor tolerance and poor performance status. Serial measurements of his BCR-ABL IS percentile have revealed a gradual decrease in size of his clone to 20% after seven months of therapy. The patients performance status continues to improve significantly on single agent therapy.

201 ANGIOSARCOMA OF THE SCALP WITH METASTASES PRESENTING AS BILATERAL PNEUMOTHORACES

E Long, JL Frost. *University of Mississippi Medical Center, Jackson, MS.*

10.1136/jim-2016-000393.201

Introduction Angiosarcoma is a malignant neoplasm derived from the endothelium of blood or lymphatic vessels. It is a rare neoplasm accounting for 2% of soft-tissue sarcomas. Though angiosarcomas can arise from the liver, breast, and heart, approximately 60% of angiosarcomas are cutaneous. The scalp itself has been estimated as the primary site for 35% of all angiosarcomas. Angiosarcomas of the scalp frequently metastasize to the lungs; pneumothorax can be either the first sign of metastasis, or the event leading to discovery of the primary lesion. We describe a patient with angiosarcoma of the scalp who underwent resection for cure, only to present later with bilateral pneumothoraces demonstrating metastasis. This is a classic but rare metastatic pattern.

Case Report A 76-year-old male presented for dermatologic evaluation with a lesion on the right frontal scalp spanning 6.3 cm. Biopsy revealed cutaneous angiosarcoma. The patient underwent a PET-CT showing 2 subcentimeter nodular opacities in the lungs which were not FDG-avid. He subsequently underwent a wide local excision of the scalp and plans were made for adjuvant concurrent chemoradiation.

Some time later, the patient presented to the hospital with shortness of breath and was found to have bilateral pneumothoraces, necessitating bilateral chest tube placement. Pleural fluid cytology and lung biopsy demonstrated metastasis of the angiosarcoma to the lungs as the cause of the pneumothoraces.

Discussion Angiosarcoma of the scalp has an affinity for pulmonary metastasis. Angiosarcoma of the scalp resulting in pneumothorax has been well reported. In approximately half of the reported cases, the primary lesion was not discovered until suggested by the pneumothorax; in the others, the diagnosis of cutaneous angiosarcoma was known beforehand. Staging PET frequently misses metastatic lesions of cutaneous angiosarcoma, as they are not necessarily FDG-avid. However, they can have characteristic cystic morphology. Therefore, it is important to be aware of the propensity of scalp angiosarcoma to metastasize to the lung, and to carefully investigate any lung imaging.

202 A NOVEL APPROACH TO THE TREATMENT OF SEVERE RECURRENT EPISTAXIS SECONDARY TO HEREDITARY HEMORRHAGIC TELANGIECTASIA

AL Marle,¹ AS Delmas,¹ RT McGary,¹ FC Moore,² LE Muncy¹. ¹Dwight D. Eisenhower Army Medical Center, Fort Gordon, GA; ²Arizona College of Osteopathic Medicine, Glendale, AZ.

10.1136/jim-2016-000393.202

Case Report Hereditary hemorrhagic telangiectasia (HHT) is a genetic disorder which causes mucocutaneous telangiectasias, gastrointestinal bleeding, and epistaxis. We report the first case of long term, low dose bevacizumab therapy used to treat severe recurrent bleeding from HHT.

A 49 year old gentleman presented with recurrent epistaxis causing severe symptomatic anemia. He endorsed progressively worsening epistaxis now occurring daily, lasting up to 40 minutes each occurrence. Symptoms were refractory to multiple attempts of cauterization and laser operative management over the course of 10 years. Due to lifestyle limitations resulting from this severe spontaneous bleeding, treatment with bevacizumab was initiated. The initial dosing regimen was two milligrams per kilogram every three weeks. However, when arthralgias developed this was tapered to one and a half milligrams per kilogram every four weeks. After one year of treatment, the patient reported a dramatic decrease in epistaxis with occurrences lasting only seconds, twice per week. As a result of this effective form of spontaneous hemorrhage control, the patient was no longer iron deficient and iron replacement therapy was discontinued.

Bevacizumab is a novel, off label treatment for epistaxis secondary to HHT, however the ideal dosing regimen is under investigation. Patients with HHT have abnormally elevated levels of vascular endothelial growth factor (VEGF) which inappropriately stimulates angiogenesis. The proposed mechanism of bevacizumab is inhibition of VEGF which stops defective angiogenesis. To our knowledge this is the only reported case of long term, low dose bevacizumab therapy used to suppress chronic epistaxis secondary to HHT. This case supports long-term treatment of

epistaxis secondary to HHT with low dose bevacizumab, which is more cost-effective and may have less toxicity than standard dose treatment.

203 A RARE CASE OF THERAPY RELATED CHRONIC MYELO MONOCYTIC LEUKEMIA

N Moka,¹ C Stanfill,² K Chakraborty,¹ D Jaishankar¹. ¹East Tennessee State University, Johnson City, TN; ²East Tennessee State University, Johnson City, TN.

10.1136/jim-2016-000393.203

Case Report Chronic myelomonocytic leukemia (CMML) is characterized by persistent peripheral blood monocytosis $>1.0 \times 10^9/\text{UL}$, bone marrow blasts $<20\%$ and dysplastic hematopoiesis. Therapy related, t-CMML accounts for less than 5% of CMML and is noted in patients who received cytotoxic chemotherapy or radiation. We describe a case of t-CMML in a patient with a history of follicular lymphoma. An 82-year-old female presented with dyspnea and worsening fatigue. History indicated stage IIE, grade III follicular Non Hodgkin's lymphoma treated with multi agent chemo immunotherapy R-CHOP five years ago. Exam revealed pallor and petechiae/ecchymoses. No palpable adenopathy or hepatosplenomegaly noted. Anemia (7.9 g/dL) and thrombocytopenia (61 K/uL) on CBC. Peripheral blood smear notable for monocytosis (15%) and promonocytes. Hypercellular (80%) bone marrow with increased blasts (6%) and promonocytes (7%) consistent with CMML-type 2. FISH analysis revealed 5 q deletion (8.2%) and increased chromosome 11 signals suggesting disruption of the MLL gene. The patient's symptoms worsened with increasing leukocytosis, acute renal failure, transfusion dependence, and severe hypoxia. Not being a stem cell transplant candidate, hypomethylating agents were being discussed but patient opted for best supportive care and succumbed to t-CMML within sixty days of diagnosis. t-CMML is a well described yet rare entity that occurs 5–7 years after cytotoxic chemotherapy (alkylating agents vs topoisomerase inhibitors). While it may be associated with high-risk cytogenetics that portend poor prognosis compared to de novo CMML, no specific molecular abnormality is pathognomonic. Treatment of t-CMML is challenging and spans best supportive care vs hydroxyurea vs hypomethylating agents (Azacitidine/Decitabine) vs immunomodulatory drugs (thalidomide/lenalidomide) vs induction chemotherapy. Data on t-CMML treatment is limited to case reports with few systematic reviews. While therapy related acute myeloid leukemia is well established, we propose that this rare disease be recognized as a new entity of therapy-related myeloid neoplasms. Our case serves to educate the clinician and highlight the importance of CMML with poor prognosis.

204 ETOPOSIDE AND CYTARABINE (EC): AN EFFECTIVE NON ANTHRACYCLINE INDUCTION REGIMEN FOR THE 1ST LINE TREATMENT OF ACUTE MYELOID LEUKEMIA

N Moka, R Khalaf, K Chakraborty, D Jaishankar. East Tennessee State University, Johnson City, TN.

10.1136/jim-2016-000393.204

Case Report Acute Myeloid Leukemia (AML) is characterized by a clonal proliferation of myeloid precursors with a reduced capacity to differentiate into more mature cellular elements. Anthracyclines are a mainstay in the treatment of acute myeloid leukemia. We report a case of complete remission with a non-anthracycline regimen with Etoposide and Cytarabine (abbreviated Mitoxantrone Etoposide Cytarabine -MEC regimen). A 41-year-old male with a history of ischemic cardiomyopathy (ejection fraction 20–30%) was diagnosed with AML with favorable cytogenetics (inversion 16). At diagnosis he was noted to have tricuspid valve endocarditis with pacemaker lead vegetations. After pacemaker lead removal and a protracted course of antibiotics he received induction therapy with a non anthracycline regimen Etoposide-Cytarabine without the anthracycline Mitoxantrone (abbreviated MEC regimen). He was noted to have significant cyto-reduction but had persistent (6.6%) blasts after 1st induction leading to a 2nd induction course which did result in morphological and molecular remission. Patient received 2 cycles of high dose cytarabine consolidation (HiDAC) and has remained in remission for five years. AML is increasingly becoming a disease of the elderly and the infirm. Aggressive therapy in those patients is challenging. Available treatments in elderly patients are low dose cytarabine or hypomethylating agents decitabine/azacitidine as single agents. MEC is a regimen that has been used in the relapsed setting as a pre transplant induction regimen but is rarely used upfront especially without mitoxantrone. Etoposide has been studied in the refractory disease setting. We propose the addition of etoposide to cytarabine in the first line setting in patients who are not candidates for anthracycline based induction regimens. This may be more effective than currently available options for patients with co-morbidities. No head to head studies exist to compare these regimens. Further work needs to be done to validate this approach. A systematic literature search indicates only two other anecdotal case reports of first line induction therapy with the agents discussed in this case.

205 LIPEMIC BLOOD: A SIDE EFFECT OF HIGH DOSE CYTARABINE

S Ozair, EC Quintin, M Loch. Louisiana State University Health Sciences Center, River Ridge, LA.

10.1136/jim-2016-000393.205

Case Report A 53 year old female with no known past medical history was diagnosed with acute leukemia with myeloid and T-cell differentiation when she presented to the ED for bleeding hemorrhoids. She had more phenotypically myeloid features and was treated with induction therapy (cytarabine 200 mg/m² for 7 days and daunorubicin 90 mg/m² for 3 days) with good response (52% to 1% blasts by bone marrow and flow studies). She proceeded to consolidation therapy with high dose cytarabine 3 g/m² given twice a day on days 1, 3 and 5. Her lipid profile upon initial admission revealed: Cholesterol 105 mg/dL, Triglycerides 151 mg/dL, HDL 23 mg/dL, and LDL 52 mg/dL.

Four weeks after starting high dose cytarabine (HiDAC), her blood was noted to be lipemic in appearance. Repeat

lipid profile showed elevated cholesterol (487 mg/dL) and Triglycerides (2937 mg/dL). She denied any dietary changes, and was started on rosuvastatin and gemfibrozil therapy. After a week of therapy she had improvement in her lipid profile (Cholesterol 309 mg/dL, Triglycerides 867 mg/dL, HDL 25 mg/dL).

Three weeks after cycle 2 of HiDAC, she was again noted to have high cholesterol (346 mg/dL) and triglycerides (2882 mg/dL) despite adherence to medications and without dietary changes. She finished her third cycle of consolidation therapy and continued to have a lipemic appearance to her blood.

Cytarabine is an antimetabolite that inhibits DNA synthesis. It is known to affect liver and pancreatic function. This patient had grade II hyperbilirubinemia after cycle 3 of HiDAC in the setting of neutropenic fever which subsequently resolved. Additional serologic and radiologic evaluation failed to reveal any other abnormalities of her liver or pancreas.

Hyperlipidemia is not a known complication of cytarabine. However, in our patient, high dose cytarabine appeared to be the most likely explanation of her elevated cholesterol and triglyceride levels. Her hemoglobin A1c on initial presentation was 4.6% and rose to 7.1% with steroids that were given concurrently with chemotherapy. Long acting insulin was added to maintain good control of her serum glucose levels. The patient's lipemic blood was an interesting finding, as there are no reported cases of an association between elevated cholesterol and triglyceride levels with HiDAC treatment.

206 ANGIO IMMUNOBLASTIC T CELL LYMPHOMA A LESSER KNOWN EBSTEIN BARR VIRUS ASSOCIATED LYMPHOMA

ND Patel, E Cook, K Chakraborty, D Jaishankar. *East Tennessee State University, Johnson City, TN.*

10.1136/jim-2016-000393.206

Case Report Angio immunoblastic T-cell lymphoma (AITL) accounts for 2% of Non Hodgkin's lymphoma and may present with generalized lymphadenopathy, fevers, weight loss, rash, hypergammaglobulinemia and positive Coombs test. The disease is derived from follicular helper T-cells. A 67-year-old male with a history of prostate cancer, developed fatigue, axillary and cervical lymphadenopathy along with drenching night sweats. On exam he had prominent left supraclavicular and bilateral axillary lymphadenopathy. An initial excision lymph node biopsy was non diagnostic but a small atypical CD10 positive T-cell population raised the possibility of AITL. No overt T-cell atypia, loss of T cell antigens or clonal T-cell receptor gene rearrangement was noted. Flow cytometry revealed mixed population of T cells (49%) and B cells (47%). Scattered small EBV positive cells were noted. Upon clinical progression, a repeat lymph node biopsy was suspicious for evolving lymphoproliferative disease. A diagnosis of AITL was made based on architectural distortion, increase in para cortical T-cells, with follicular helper T-cell phenotype (CD10+, CD279+, CXCL13+) and increased EBV positive cells. Patient received 6 cycles of CHOP

(cyclophosphamide, doxorubicin, vincristine, prednisone) chemotherapy and achieved complete response clinically and radiographically. He then underwent high dose chemotherapy with autologous stem cell transplant as consolidation. AITL accounts for 18% of peripheral T-cell lymphoma in the West. Patients present with advanced-stage disease, systemic symptoms, and autoimmune manifestations. AITL is characterized by malignant T cells in a background of polyclonal plasma cells, eosinophils, histiocytes, B cells and Epstein-Barr virus (EBV) amongst follicular dendritic cells. Docking simulations suggest loss of GTPase activity in the RHOA Gly17Val mutant. The prognosis of AITL is poor with median survival less than 3 years. Optimal management is not well defined. Outcomes with anthracycline-based chemotherapy are suboptimal. A minority of patients achieve long-term disease control following stem cell transplantation while the majority progress over time. This case highlights the complexities and conundrums of diagnosis and treatment of AITL.

207 PLASMA CELL LEUKEMIA: A RARE VARIANT OF MULTIPLE MYELOMA

T Poosarla,¹ JC Henegan,¹ A Reddy.² ¹University of Mississippi, Flowood, MS; ²University of Mississippi Medical Center, Jackson, MS.

10.1136/jim-2016-000393.207

Case Report Plasma cell leukemia (PCL) is a very aggressive and rare variant of multiple myeloma. It is defined by the presence of malignant plasma cells in the peripheral blood and bone marrow. Here we share a case where a patient with primary PCL and poor cytogenetics treated with doxorubicin, cyclophosphamide, etoposide, cisplatin, and bortezomib (VD PACE).

51 year old African American female with history of seizures and hypertension presented with fever, chest pain, and cough. On admission, she reported fatigue, generalized weakness, and decreased appetite. Physical exam was notable for rhonchi in the right lower lobe. Chest x-ray showed right lower lobe pneumonia. Her labs demonstrated a white blood cell count of 25TH/cmm, hemoglobin 8.4 g/dL, and platelet count of 50TH/cmm. Her total protein was 9.8 g/dL with an albumin of 3.6 g/dL and globulin gap of 6.2 g/dL. Peripheral smear contained macrocytic RBC's with rouleaux formation, and numerous plasmacytoid lymphocytes. Flow cytometry demonstrated an abnormal plasmacytic cell population. Serum protein electrophoresis showed an abnormal discrete band characterized as IgG lambda free light chain. Bone marrow biopsy revealed a hypercellular marrow with >90% plasma cells. Cytogenetic testing on the abnormal cell population demonstrated a monosomy 13, deletion 17 p, and 1 q21 amplification.

She was treated with VD PACE. Her first cycle was complicated by febrile neutropenia and pneumonia. She received 2 more cycles, which was tolerated well. She is currently in complete remission by serological criteria with no M spike, and normal lambda free light chains. She is in stringing complete remission by peripheral blood criteria by no plasma cells on her follow-up flow cytometry.

Primary PCL occurs without an antecedent diagnosis of multiple myeloma, whereas secondary PCL arises from the transformation of preexisting multiple myeloma. Primary PCL accounts for 1%-4% of multiple myeloma. It has extremely poor prognosis with median overall survival of 7 months. Induction with Bortezomib based chemotherapy regimens have shown to improve overall survival and progression free survival when followed by autologous stem cell transplant (Auto-SCT). Our patient is currently in complete remission and is being evaluated for Auto-SCT.

208 UNRAVELING THE TRAVELING PHLEBOTOMIST

L Puttock, L Harper, L Roan, LS Engel, C Sanders. *LSU Health Sciences Center, New Orleans, LA.*

10.1136/jim-2016-000393.208

Case Report Introduction: Anemia is commonly encountered in all clinical settings with roughly 24.8% of our world population having anemia according to the 2008 World Health Organization database.

Case A 29 year old African American woman with an unconfirmed medical history significant for Sickle Cell Anemia (HbSS), NSTEMI, Wolf Parkinson White status post multiple ablations and pacemaker placement, seizure disorder, multiple DVTs, anxiety, and obesity presented to the Emergency Department with a one week of hemoptysis, intermittent right sided shoulder pain, and right sided intermittent chest pain. The chest pain intensified three hours prior to presentation without relief from nitroglycerin or home sickle cell pain regimen. Vital signs were unremarkable. On exam, a loud S2 was auscultated along with tenderness to her lower abdominal quadrants with no guarding or rebound. EKG was notable for ventricular-paced rhythm and CT imaging was negative for pulmonary embolism and an intra-abdominal process. Labs revealed hemoglobin 9.9 gm/dL, hematocrit 32.9%, MCV 70.6, reticulocyte percentage 1.8%, reticulocyte index 0.9, RDW 16.4, iron 17 micrograms/dL, Transferrin 304 micrograms/dL, TIBC 395 micrograms/dL, Iron Saturation 4%, and Ferritin 3.9 ng/mL. Hemoglobin electrophoresis resulted with HgbA 97.8% and HgbA2 2.2%. Throughout her hospitalization, the patient refused multiple interventions including telemetry and blood draws, along with persistent requests to escalate her pain regimen. Records from outside hospitals documented recurrent anemia despite iron supplementation, drug seeking behavior, and history of leaving against medical advice. She was diagnosed with hemoglobin Munchausen's in the setting of iron deficiency anemia (IDA), possibly explained by self-bloodletting as a trained phlebotomist.

Discussion Hemoglobin Munchausen syndrome is a factitious disorder where patients fabricate complaints of sickle cell anemia and are found to have a normal hemoglobin electrophoresis. Dr. Jean Bernard, a French Hematologist, described Lasthénie de Ferjol in 1967, a syndrome of recurrent IDA provoked by repeated episodes of self-induced bloodletting. Lasthénie de Ferjol Syndrome is a rare illness that presents a challenge to diagnose and should be considered in young women with a healthcare background and severe IDA.

209 WHERE CAN'T KAPOSI GO? A CASE REPORT ON KAPOSI SARCOMA WITH MULTIPLE ORGAN INVOLVEMENT

EC Quintin, JN Slim, TM Reske. *LSUHSC New Orleans, New Orleans, LA.*

10.1136/jim-2016-000393.209

Case Report HIV associated Kaposi sarcoma (KS) is an AIDS defining malignancy triggered by co-infection of human herpes virus. Its incidence has substantially declined since the advent of antiretroviral therapy; however, can still be found in non-adherent patients. These lesions are classically found on skin and mucosal surfaces but can occur in the viscera and bone marrow. We present a case of KS with multi-organ involvement.

40 yo Caucasian male with HIV, non-adherent to HAART (CD4 count 2), presents to emergency room with progressive weakness with non-bloody diarrhea over 3 days. Patient's PE was significant for multiple red-purple skin lesions as well as violaceous gingival lesions. Patient previously presented at an outside facility and underwent a BM biopsy at that time for evaluation for pancytopenia. Results showed mildly decreased bone marrow cellularity with erythrodysplasia and mild fibrosis without any infiltrative processes. His initial peripheral blood: WBC 2.4, ANC 990, H/H 5.2/17.0, Plt 170. Parvovirus IgG was high at 6.7 but parvo PCR negative. Negative histo, crypto, CMV workup. Skin biopsy confirmed diagnosis of Kaposi sarcoma. Bone marrow was repeated for other infectious or malignant etiologies. Results showed trilineage hematopoiesis but with 20% bone marrow involvement of Kaposi sarcoma, positive for HHV8 by IHC stains. At that time, colonoscopy deferred due to patient's neutropenia and lack of overt GI bleeding. Patient was discharged with plans for close follow up but returned with complaints of frank blood per rectum. Urgent colonoscopy was unable to be performed due to attenuation of the anal sphincter with black adherent material in the rectum. EGD showed normal mucosa. Given patient's proclivity to bleed, doxorubicin was initiated in order to attempt to control the presumed bleeding from GI involvement of his KS despite his WBC 1.6, ANC 700. HAART therapy was continued. The first cycle grossly improved his mouth and skin lesions and lengthened time between transfusions. He continued to improve and was able to be discharged. While our patient manifested some of the more common locations (gingival, skin and presumed gastrointestinal tract), marrow involvement with Kaposi should be considered in high risk populations.

210 CORRECTING A COUGH WITH CHEMO: A CASE REPORT OF LUNG INFILTRATION BY CLL

EC Quintin, S Subbiah. *LSUHSC New Orleans, New Orleans, LA.*

10.1136/jim-2016-000393.210

Case Report Chronic lymphocytic leukemia is a chronic B cell lymphoproliferative disorder that accumulates nonfunctioning lymphocytes. Occasionally, it is known to infiltrate into solid organs in addition to the bone marrow. We

present a case of CLL with pulmonary involvement that necessitated treatment.

54 yo AAF with known trisomy 12 CLL on no treatment presents to her physician's office for persistent cough of approximately 2 weeks despite symptomatic management with over the counter medications. Labs indicated a stable leukocytosis (17–19 k) consistent with her CLL. She denies any acid reflux symptoms or feeling ill. CXR at that time did not show any acute process. She feels slightly short of breath, but denies any effect on her usual activities. She was given a 5-day course of antibiotics and recommended a daily antihistamine.

Patient then presented to the ED one week later with complaints an enlarged cervical lymph node that accompanies her cough. She reports finishing her antibiotic course and is adherent with her daily antihistamine. She does report night sweats 3–4 times in the past week; denies any fevers or weight loss. Her ED labs show a stable leukocytosis without bands or blasts, no anemia or thrombocytopenia. Her new CXR shows a possible left upper lobe atelectasis; her CT scan that shows a soft tissue density concerning for obstructive neoplasm. Pulmonology performed a bronchoscopy which showed fragments of bronchial mucosa infiltrated with small lymphocytic lymphoma. Flow cytometry of a fresh specimen also demonstrated involvement of her known disease.

Given her symptomatic CLL, patient opted for therapy with Bendamustine and Rituximab. After 2 of her 3 planned cycles, her WBC is 6 k and continues to have a normal H/H and platelet count. Most importantly to her, she reports that her cough has completely subsided. She is awaiting a restaging scan to determine if there is radiographical evidence of regression, but given her symptom improvement, we feel that her disease is much better controlled.

Leukemic pulmonary infiltrate is a known complication in patients with CLL. It is important to obtain a thorough history and physical in patients with CLL as their disease can theoretically infiltrate any organ. Treatment may be necessary to help alleviate their burden, both hematologically and symptomatically.

211 NOT YOUR ORDINARY COAGULAPATHY

L Raney, R Gardner. *LSUHSC, New Orleans, LA.*

10.1136/jim-2016-000393.211

Case Report When evaluating for effective coagulation, platelet number and function, the presence of coagulation factors, and integrity of collagen must be assessed. We present an interesting case of a 12 yo female with a history of autism who presented with progressive fatigue and worsened gingival bleeding that was not due to your typical coagulopathy. These symptoms were found 4 months ago when K.H's dentist diagnosed her with gingivitis. The symptoms slowly progressed to developing petechia and bruising on her lower extremities. On initial presentation, she was awake and alert, non-toxic appearing, and very tired. Her gums were very inflamed and covered in dried blood. She had no palpable lymph adenopathy or hepatosplenomegaly. She had a III/VI SEM on auscultation. Her

legs and back were covered in petechia and purpura were found in bilateral popliteal fossas. Initial labs were remarkable for a hemoglobin of 3.1, normal MCV of 85, elevated reticulocyte count of 16.7%, and elevated RBC distribution width of 18.8. Her white blood cell and platelet count were normal, and she was diagnosed with a severe normocytic anemia for which we began an extensive work up to determine the etiology. A destructive process was ruled out with a negative coombs test and a normal RBC enzyme assay. Normal WBC and platelet counts and a responsive reticulocyte count ruled out marrow failure. The etiology was due to blood loss for which we performed a bleeding work up. Her platelet count and function are normal. She had a mildly prolonged PT 15.4, but normal INR and PTT. She has no prior history of abnormal bleeding hemophilia is unlikely, however we sent for factor levels to verify. The degree of anemia didn't correlate with the mildly prolonged PT, so we investigated collagen integrity. We discovered that as a result of her autism, K.H has a very limited diet where she avoided almost all meat, vegetables, and fruits. As a result she was profoundly deficient in vitamin C and vitamin K leading to a scurvy-like picture of gingival oozing and petechia that lead to a severe anemia. She was also found to be iron and folate deficient. She was transfused to normal hemoglobin and supplemented with iron, vitamin C and K, and folate. Upon follow up here gingivitis, oozing and petechia resolved, her hemoglobin remains normal, and her vitamin deficiencies are responding to therapy.

212 COMPLETE RESPONSE OF THYMIC SEMINOMA TREATED WITH CISPLATIN-ETOPOSIDE DOUBLET

D Reddy, S Kassaby, K Chakraborty, D Jaishankar. *Quillen COM, Johnson City, TN.*

10.1136/jim-2016-000393.212

Case Report Anterior mediastinal masses are uncommon in clinical practice, and the differential diagnosis includes lymphoma, thymoma and rarely germ cell tumors. We describe a unique case of primary mediastinal thymic seminoma with an excellent response to chemotherapy.

A 50-year-old Oriental male with a history of hypertension presented with intermittent substernal chest pain radiating to the left shoulder and neck. Exam was unremarkable and he was hospitalized for a possible acute coronary syndrome. Cardiac catheterization demonstrated minimal disease but a subsequent CT scan noted a 6.2×4.2 cm anterior mediastinal mass. CT guided biopsy revealed tumor cells with clear cytoplasm (CD117+) nested between fibrous stroma with abundant lymphocytes. The lymphocytes were positive for CD3 and CD5 (T cells) and scattered CD20 (B cells). The morphologic and immunophenotypic characteristics were consistent with thymic seminoma. Labs revealed a normal AFP and beta HCG with an elevated LDH. No testicular mass or abdominal lymphadenopathy was appreciated clinically or radiographically. The patient was treated with Cisplatin and Etoposide for 4 cycles (Bleomycin was omitted to avoid pulmonary toxicity given his age). He tolerated chemotherapy well and follow up scans established a complete response.

Germ cell tumors such as primary mediastinal thymic seminomas are morphologically indistinguishable from testicular seminomas and affect males in their second/third decades of life. Extra gonadal germ cell tumors (no evidence of primary tumor in the testes) are rare while extra gonadal pure seminomas are even rarer. Mediastinal thymic seminomas develop at the juncture of the innominate vein and the superior vena cava. The exact mechanism of their origin remains unknown but are considered to develop from failed migration of primitive germ cells from the endoderm of the yolk sac to the scrotum during embryogenesis. Surgery and radiation play a small role as outcomes are superior with intensive cisplatin-based combination chemotherapy which provide remission rates over 90% with a 5-year overall survival rate over 80%. Our case serves to educate that thymic seminoma should be considered as a rare but curable differential diagnosis for an anterior mediastinal mass.

213 CELLULAR REGULATION AND MODULATION OF IMMUNE THROMBOCYTOPENIA: MIXED MYELOID DERIVED SUPPRESSOR CELLS AND LYMPHOCYTES NICHE

KN Rezkallah, S Subbiah, TM Reske, P Rigby. *LSU Health Sciences Center, New Orleans, LA.*

10.1136/jim-2016-000393.213

Purpose of Study Understanding the cellular immune regulatory aspect of ITP which involves cross connected interactive cells, i.e. MDSCs, Tregs, NK cells, memory cells, and stem cells.

Methods Used Literature about MDSCs, Tregs, other lymphocytes, and ITP was researched and reviewed.

Summary of Results Myeloid derived suppressor cells (MDSCs) are heterogeneous immature cells, they have the ability to suppress T cell responses through the interferon (IFN)- γ -dependent nitric oxide production or the Th2 mediated interleukin (IL) 4/IL-13-dependent Arginase-1 (Arg-1) pathway. Hou et al showed that numbers and suppressive functions of MDSCs were impaired in the peripheral blood of patients with ITP compared with healthy control patients and improved by treatment with dexamethasone.

Tregs are CD4T cells with high expression of CD25 and expression of transcription factor fork head boxP3 (Foxp3), many studies showed that the percentage of Treg cells was significantly decreased or altered in ITP patients. Tregs run their suppressive functions through contact and cytokine dependent suppression. Several distinct mechanisms are proposed for the mechanisms of immune suppression of effector T cells by Tregs.

There are several reports of different number of natural killer (NK) cells that were nevertheless functionally defective in peripheral blood from ITP patients. Some studies suggested the mechanism of interaction between MDSCs, Tregs and other lymphocytes but the exact mechanism is still unclear. The role of these cells in increased production of autoimmune antibodies in the elderly is not studied yet.

Conclusions Multiple cells are involved in immune modulation: MDSCs in addition to, Tregs, and also involved are NK cells, stem cells, and memory cells. These cells cross connect, forming a niche in clusters or nests of cells, to provide action regarding modulation of the autoimmune mechanism of immune thrombocytopenia (ITP), different studies of each type of these cells separately then further comprehensive studies examining these cells together are needed to understand cross talk to each other.

214 SORE THROAT AND DYSPHAGIA: AN ATYPICAL PRESENTATION OF AGGRESSIVE BURKITT'S LYMPHOMA

C Rivera-Franceschini,¹ L Figueroa-Jimenez². ¹San Juan City Hospital, Ponce, PR; ²San Juan City Hospital, San Juan, PR.

10.1136/jim-2016-000393.214

Case Report Burkitt's lymphoma (BL) is a highly aggressive non-Hodgkin's Lymphoma (NHL). This lymphoma results from germinal or post germinal center B cells. It is characterized by translocation and deregulation of c-MYC gene on chromosome 8. They present with rapidly growing tumor masses. There are three subtypes: endemic, sporadic, and immunodeficiency-associated. The sporadic variant is seen in the United States and Western Europe. Sporadic BL are typically seen in adults less than 35 years of age and compose less than one percent of adults' NHL. We present a case of a 54-year-old man with type 2 diabetes mellitus, hypertension and dyslipidemia who complains of dry cough of one-year duration. Now presenting with sore throat and dysphagia. Patient went to his primary care physician where he was found with a right asymmetric swollen palatine tonsil. No lymphadenopathy, fever, exudate, weight loss, night sweats or any other constitutional symptom. Physical exam was remarkable for the right swollen and erythematous palatine tonsil. Initially, patient was prescribed antibiotics but symptoms persisted. Patient was evaluated by an otolaryngologist who identified an ulcerated lesion on the right palatine tonsil and a biopsy was performed. On the pathology report the lesion was CD3, BCL-6, CD10, CD-20, PAX-5, MIB-1/Ki-67 and C-MYC positive. Morphologic, immunohistochemical features and cytogenetic/FISH studies (demonstrating t(8;14) in 55/100 nuclei) are supportive of the diagnosis of BL. PET CT scan showed an isolated hypermetabolic right tonsillar mass suggestive of lymphoma. Patient underwent chemotherapy with Hyper-CVAD and rituximab. This treatment was chosen because the addition of rituximab improves survival without adding toxicity. The patient is currently asymptomatic. Even though our patient had a tonsillar presentation, sporadic BL usually has an abdominal, lymphatic or medullary involvement rather than head and neck involvement. The diagnosis is based on the pathologic evaluation of the biopsy. Recognition of a unilateral palatine enlargement with a low centor score should prompt early lesion biopsy. It is imperative to initiate treatment as early as possible since advanced stage of BL is associated with worse prognosis.

215 **NEUROENDOCRINE LUNG CANCER AND TRACHEOBRONCHOPATHIA OSTEOCHONDROPLASTICA: TWO RARE ENTITIES**

C Rivera-Franceschini,² E Calderón-Alicea,^{1,2} W Cáceres-Perkins^{1,2}. ¹VA Caribbean Healthcare System, San Juan, PR; ²San Juan City Hospital, San Juan, PR.

10.1136/jim-2016-000393.215

Case Report Tracheobronchopathia osteochondroplastica (TO) is a rare benign condition of multiple osseous and cartilaginous nodular lesions that affects the large airways and the submucosa of the trachea and main bronchi. Patients can have bronchial obstruction, hemoptysis and cough for which it can be easily mistaken with advanced lung cancer. A 77-year-old Hispanic male with past medical history of hypertension, prostate cancer, hypercholesterolemia, COPD, diverticulosis, and renal cell carcinoma presented with a non-calcified nodular lesion in the lingula identified incidentally on a surveillance CT scan. A Chest angiography revealed a spiculated mass in the lingula with small nodularities and linear stranding adjacent to it. A fiberoptic bronchoscopy showed multiple nodule like lesions in the upper areas of the right upper, right middle entrance and basal segment of the right lung. The same occurred for the left upper lung, lingula, and left lower lobe entrance. The lesions did not follow a specific distribution but they were interpreted as suspicious for metastatic disease. A biopsy guided by Chest CT scan unveiled an intermediate grade neuroendocrine carcinoma (atypical carcinoid) positive for chromogranin and synaptophysin with a low Ki-67 (3%). The patient was not considered a surgical candidate as for 'metastatic disease'. To better characterize the pulmonary lesions, the patient underwent a second bronchoscopy with impression not of metastatic disease but of TO with a lymph node that was not invading the junction of the airways. The patient was taken for robotic assisted left upper lobe lobectomy with mediastinal lymph node dissection with a final pathological diagnosis of a moderately differentiated neuroendocrine tumor (atypical carcinoid) stage T2N2M0. TO could be mistaken for metastatic nodules by radiographic and bronchoscopic appearance. Understanding the presentation of this rare benign condition permitted a curative management to his localized lung cancer. Identification of TO by a physician is essential in order to perform the correct management and follow up.

216 **ERADICATE ANTI-EIGHT**

S Sanders, G Browne, T Kazecki, EC Quintin, LS Engel, M Loch. *LSU Health Sciences Center, New Orleans, LA.*

10.1136/jim-2016-000393.216

Case Report Case: An 82 y/o woman with history of hypertension, polymyalgia rheumatica, and acquired Factor VIII presented with a painful large thigh hematoma. She was diagnosed with an acquired Factor VIII deficiency 6 months prior after being hospitalized for a complicated spontaneous retroperitoneal hematoma with subsequent abscess formation associated with an isolated elevation of

aPTT. She presented 6 months after that hospitalization with a right thigh hematoma that was treated with steroids and discontinuing apixiban that she was on for PE/DVT. One week later, she was readmitted for worsening hematoma. Imaging showed a stable hematoma with active extravasation which was treated with high dose steroids. Her hemoglobin was 10.6 g/dL on admit (baseline 13 g/dL), but dropped to <8 g/dL with a Factor VIII inhibitor level of 26.9 BU. She was started on recombinant activated factor VII (rFVIIa) every three hours (5 doses total) and began weekly rituximab secondary to steroid refractory inhibitor levels. The patient received 2 doses of rituximab during hospitalization, 1 unit of blood (discharge Hg 8.7 g/dL) and completed the remainder 2 infusions of rituximab after discharge. Factor VIII activity, Factor VIII inhibitor levels, and aPTT trended. Measurements were initially erratic in the acute phase likely due to inconsistent lab draws, but overall trend demonstrated improvement (Figure 1).

Discussion Acquired hemophilia A is a rare autoimmune disease caused by immunoglobulin G antibodies directed against factor VIII, which neutralize its coagulant function. Treatment involves (1) bypassing agents like recombinant activated factor VII (rFVIIa) or plasma-derived activated prothrombin complex concentrate (aPCC) to control bleeding and (2) immunosuppressant therapy to eradicate the inhibitor. First line treatment consists of steroid therapy, with or without cyclophosphamide. However, due to the toxicity of regimens involving cyclophosphamide, other regimens, like the above use of rituximab, may be preferred.

217 **NOT YOUR COMMON EYE DISORDER**

EB Saul, S Elkins. *University of Mississippi Medical Center, Madison, MS.*

10.1136/jim-2016-000393.217

Introduction Follicular lymphoma (FL) is the second most common type of the non-Hodgkin lymphomas (NHL). Painless generalized lymphadenopathy and bone marrow involvement is commonly present at diagnosis. Follicular lymphoma may arise as primary tumors in extranodal sites, such as the gastrointestinal tract, skin, breast, and testis. The ocular adnexal region (ie, orbit, eyelids, conjunctiva, lacrimal gland and lacrimal sac) is regarded as the extranodal region. Ocular adnexal lymphoma (OAL) is rare with an incidence of 0.2 per 100,000 persons/year.

Case A 56 year old Asian male presented with pain, swelling and irritation of his left eye for a month's duration. Review of systems was negative including visual changes, weight loss, fevers, night sweats, and lymphadenopathy. He takes no medications and has no past medical history. His family history was pertinent for glaucoma. Slip lamp exam performed by ophthalmology revealed left caruncular enlargement with redness and chemosis extending inferior and superior to it into the fornix. A biopsy of the left caruncular and conjunctival mass was performed. Pathology revealed conjunctival and squamous mucosa with underlying closely-packed lymphoid follicles composed of mostly small lymphocytes with scattered centroblasts. Immunostains were positive for CD10, CD20, BCL2, and

BCL6 diagnostic for a low-grade follicular lymphoma. FISH was positive for IGH-BCL2 translocation. A full workup was done by hematology. CT of the chest, abdomen, and pelvis revealed no active lymphoma. MRI brain/orbits was normal except for some nonspecific supratentorial white matter changes. Radiation therapy was recommended though he chose close observation given potential toxicities associated with radiation.

Discussion Non-Hodgkin lymphoma of the orbit and ocular adnexa are common primary orbital malignancies. Low-grade lymphomas include the extra-nodal marginal zone and follicular lymphomas. High-grade lymphomas include diffuse large B-cell lymphoma. Diagnosis is made by excisional biopsy with pathological examination of the malignant cells. Treatment depends on the stage and could include radiation therapy, chemotherapy and/or excision. Unfortunately, vision-threatening toxicities and frequent relapses can occur. Early diagnosis is essential as it provides more favorable long-term disease free survival.

218 BURKITT'S LYMPHOMA: NEW HEADACHE AND ACUTE PARALYSIS

JN Slim, M Loch. *LSU Health Sciences New Orleans, New Orleans, LA.*

10.1136/jim-2016-000393.218

Introduction Burkitt's lymphoma is an aggressive B-cell lymphoma that typically presents with extranodal tumor sites. Here we discuss an unusual presentation of immunodeficiency-associated Burkitt's lymphoma.

Case Report A 29 year old HIV positive, transgender on hormone therapy male to female; initially presented with new onset left-sided headaches and was diagnosed with complex migraine after a negative CT head. In a few days she re-presented with worsening headaches, facial numbness and testicular pain with swelling. MRI/MRA head and face demonstrated extra-axial mass not appreciated on previous CT.

Acutely, left lower extremity paralysis developed. MRI spine noted two compressive masses: L5-S1 and paraspinal soft tissue masses most severe from T3 to T5. Hemilaminotomy to T2-6 and laminectomy T9-10 was performed.

Pathology demonstrated a high grade B cell lymphoma with morphologic and immunophenotypic features (CD10+, BCL-2-, markedly elevated Ki-67 proliferative index) suggestive of Burkitt lymphoma. Treatment for aggressive B-cell lymphoma with R-EPOCH and intrathecal chemotherapy was initiated and our patient recovered the use of her lower extremities.

Discussion Typically, Burkitt lymphoma will present with abdominal masses, evidence of tumor lysis syndrome and elevated LDH. Initial biopsies show B cell lymphomas with CD10+ IHC and high proliferation indices (Ki67>90%). Burkitt's lymphoma has demonstrated a 39% 2-year OS with CHOP therapy, traditional treatment for diffuse large B-cell lymphoma, compared to 70%-80% with more aggressive multi-agent regimens.

Conclusion The doubling time of Burkitt lymphoma is 24-48 hours and early recognition and treatment is imperative. Cytogenetic and FISH studies are not immediately available at most medical facilities and in the setting of 25 hour doubling time; therapy must be considered. Our case demonstrates this importance as she presented with two areas of cord compression and rapid onset paraplegia with multiple additional tumor sites. In the case of cord compression, emergent neurosurgical consultation is paramount, followed by subsequent medical treatment.

219 MISTAKEN IDENTITY: WILM'S TUMOR IN AN ADULT

JN Slim, M Loch. *LSU Health Sciences New Orleans, New Orleans, LA.*

10.1136/jim-2016-000393.219

Introduction Wilm's tumor, while the most common renal tumor in young children, is rare in adults comprising about 3% of reported cases. Preoperative diagnosis is difficult, as there are no specific radiographic findings or tumor markers to distinguish it from more common renal tumors.

Case presentation A 37 year old Honduran woman presented in her home country with abdominal pain and right flank mass and treated with excision, nephrectomy and adrenalectomy. In our clinic, 3 months later she reported recurrent abdominal pain and CT demonstrated an 8 cm mass in the right adrenal fossa. Her pathology was reported as carcinosarcoma of the adrenal gland and the original tissue block was re-examined. Local experts reported nephroblastoma, with mixed blastematos and epithelial components, favorable histology. Biopsy of recurrent mass did not demonstrate malignant cells.

Our patient's tumor had spread beyond the kidney and could not be completely surgically removed; but had not spread to other organs such as lung, liver or bone and we considered her a stage III. Chemotherapy protocol DD4A was started in a neoadjuvant fashion. This protocol was shown, in children, by the National Wilms Tumor Study-5 to have 4-year event-free survival and overall survival estimates of 75% and 86%⁴.

Repeat imaging after 6 weeks of therapy demonstrated further progression. This is atypical of favorable histology prompting biopsy of new growth; which was consistent with Wilm's tumor not meeting criteria for anaplastic or unfavorable histology. A protocol for anaplastic Wilm's tumor was started with significant reduction in tumor burden noted after cycle 2.

Discussion Wilms' tumor in adults is exceedingly rare and has a diverse histological presentation. In the absence of appropriate post-operative chemotherapy and radiation; treatment based on histology was pursued. Response to anaplastic protocols with minimal response to DD4A would suggest a more aggressive approach initially would be warranted for future cases.

Conclusion We present an unusual case of a rare adult tumor. In especially rare malignancies, treatment must be based on case reports or more common tumor protocols. We feel this case demonstrates the importance of an aggressive team approach to coordinate timely and appropriate patient care.

220 DIFFERENTIAL DIAGNOSES OF PENILE LESIONS: A CASE OF PENILE CARCINOMA

SE Smith, EC Quintin, A Garcia. *LSUHSC New Orleans, New Orleans, LA.*

10.1136/jim-2016-000393.220

Case Report Penile cancer (PC) is a rare malignancy, typically presenting as a painless lump or ulcer on the penis. PC accounts for less than 1% of male cancers in the United States. It is more commonly seen in older men. Risk factors include genital warts and phimosis, infection with HPV or HIV and smoking.

A 56 yo male presented with complaint of cauliflower-appearing penile lesion (PL) present for 3 weeks. Patient notes a lump on the side of shaft but denied issues with voiding, erection, dysuria, hesitancy, hematuria, or weak stream. Patient denied pain but did report blood spots on his underwear throughout the day. Physical exam revealed uncircumcised penis with an easily retractable foreskin. Hard, red, velvety lesion was present on entire dorsal glans. Mass involved left side of foreskin with no shaft lesion. Punch biopsy showed an invasive, moderately differentiated squamous cell carcinoma of the penis. Patient subsequently underwent partial penectomy with plans for neoadjuvant chemotherapy prior to lymph node dissection.

Primary care physicians may frequently encounter patients with PLs. Presentation on physical exam is key when discerning possible etiologies. Differential diagnoses for PLs are grouped into infectious and non-infectious. Due to the variable plaque and ulcer appearance for PC, both infectious and noninfectious causes should be considered on the differential diagnosis. Lichen sclerosus and psoriasis are benign inflammatory/papulosquamous lesions while HSV, syphilis, and candidiasis are common infectious lesions that can visually mimic ulcers/plaques of PC. Giant condylomas from HPV infection appear similar to PC with irregular surface margins and exophytic nature of the warts. While most benign lesions can be managed with observation and/or topical corticosteroids, biopsy of malignant lesions is essential in obtaining the proper diagnosis and optimal treatment plan. Surgery is the primary treatment of PC while chemotherapy is used in locally advanced and metastatic disease. The prognosis of early PC is excellent with survival rates above 90%. However, the prognosis of locally advanced PC is poor. Therefore early diagnosis is imperative and PC should be considered in the differential diagnosis of penile lesions.

221 AML OR A SARCOMA? WHAT COULD BE THIS RETROPERITONEAL MASS

A Sultan,¹ S Khan,¹ L DCunha,² H Igid,¹ N DCunha¹. ¹Texas Tech University Health Sciences Center, Lubbock, TX; ²Texas Tech University, Lubbock, TX.

10.1136/jim-2016-000393.221

Case Report Retroperitoneal sarcomas are rare neoplasms. Diagnosis is often challenging and imaging alone cannot be used for grading hence histology is vital for the diagnosis.

37 years old male presented for the evaluation of low back pain of 2 months duration. He was working as a construction worker and he thought he overworked at his job.

Patient's low back pain progressively got worse and a CT scan was done and was told he has a mass in his abdomen. Patient underwent a CT guided retroperitoneal mass biopsy and pathology report showed malignant neoplasm and specimen was sent to a higher level of care center for consultation and the report showed morphologic and immunophenotypic findings are consistent with a myeloid sarcoma; additional clinical correlation with a bone marrow biopsy is recommended for possible diagnosis of acute myelogenous leukemia.

Hence, patient underwent a bone marrow biopsy and pathology report showed normocellular marrow with megakaryocytic hyperplasia; there is no morphologic or immunophenotypic evidence of acute leukemia, flow cytometric analysis revealed no significant immunophenotypic abnormalities; cytogenetics reported normal FISH result for the AML panel probe set and normal male karyotype. Lab results showed no mutation for FLT3 ITD, FLT3 TKD mutation, CEBPA mutation, OR c-kit mutation. Additionally, BCR-ABL interpretation: p190 and p210: not detected; NPM mutation: not detected.

CT abdomen/pelvis showed retroperitoneal mass, several small retroperitoneal lymph nodes around the aorta and IVC; group of matted retroperitoneal lymph nodes measuring 4.2×1.8×3 cm in size extending from level of L2-L3 down to lower border of L3.

Abdominal ultrasound showed retroperitoneal mass just anterior the lower portion of the abdominal aorta above the aortic bifurcation primary or metastatic mass versus lymphadenopathy; left renal agenesis; hepatomegaly.

Patient was started on induction chemotherapy with ARA-C 100 mg/m² IV and Daunorubicin 90 mg/m² IV. Patient also received 2 cycles of consolidation therapy with high dose cytarabine 3 gm/m² IV.

Surgery is the definitive treatment for retroperitoneal sarcomas. Chemotherapy and radiation therapy are of minimal benefit when used alone.

222 INTRACRANIAL TUMORS AS A STROKE MIMIC: A CASE REPORT

S Sunkara,¹ J Patil,² JP Garrido,¹ RD Smalligan,¹ R Bharadwaj¹. ¹Texas Tech Univ HSC-Amarillo, Amarillo, TX; ²Baylor College of Medicine, Houston, TX.

10.1136/jim-2016-000393.222

Case Report Patients with acute neurological deficits are often diagnosed with stroke. However, there are lesions referred to as 'stroke mimics', that account for 3–13% of misdiagnosed strokes¹. In 3–5% of cases of intracranial tumors, patients have a stroke-like presentation.¹ In many reported cases, gliomas have acute onset of stroke-like symptoms, and image manifestations similar to an acute stroke¹. The misdiagnosis of cerebral gliomas may delay treatment and result in irreparable damage. We present a case of suspected glioblastoma multiforme in a 93 year-old man that initially presented with stroke-like symptoms.

A 93 year-old male with a past medical history of hypertension and BPH, presented to the clinic setting with drooling and slight left facial droop. He was recently given tamsulosin for BPH, so it was discontinued and symptoms improved. The patient returned 2 months later, after

discontinuing his antihypertensives, with systolic pressures up to 180, pancytopenia and a PSA of 13.26. He denied seeing a specialist. Five days later, the patient had left facial drooping and slurred speech. MRI without contrast showed a 1.5 cm round area with local mass effect but no midline shift, suggestive of sub-acute infarct. The patient was diagnosed with a subacute ischemic stroke, prescribed aspirin and sent to a retirement community for therapy. Ten weeks later, the he was unable to stand, had left-sided weakness, facial droop with excessive salivation, and lost 12 lbs in two weeks. Five days later, he was admitted to the hospital due to rapidly progressive symptoms, pancytopenia and elevated PSA. MRI showed a 2.8 cm ring-enhancing lesion in the right parietal lobe. The lesion was thought to be glioblastoma multiforme and the patient was admitted to hospice without additional testing.

Distinguishing between ischemic stroke and intracranial mass is important as workup and treatment varies significantly between the two. Perfusion weighted imaging (PWI), functional MRI (fMRI), and diffusion tensor imaging (DTI) have all been recent inclusions in the imaging tool box that may help in differentiation.¹ It is important to recognize that additional imaging can be helpful in early diagnosis that will direct treatment and decrease morbidity and mortality.

223 WHERE DID THE PLATELETS GO? A CASE OF DRUG-INDUCED IMMUNOLOGIC THROMBOCYTOPENIA

T Tarro, E Oltmann, LS Engel, S Kamboj. *LSU Health Sciences Center, New Orleans, LA.*

10.1136/jim-2016-000393.223

Case Report Introduction: Drug-Induced Immunologic Thrombocytopenia (DITP) is a relatively common and sometimes serious clinical disorder characterized by drug-dependent antibodies that are specific for the drug structure and bind tightly to platelets and cause their destruction. Clinically, patients present with moderate to severe thrombocytopenia and spontaneous bleeding varying from simple ecchymoses, petechiae, and mucosal bleeding to life-threatening spontaneous intracranial hemorrhage. Hundreds of drugs have been implicated in the pathogenesis of DITP, and sulfonamides are most often associated with this condition.

Case A 29 year old man with no significant past medical history presented with a severe rash×1 day. About 1 week prior to presentation, the patient began experiencing upper respiratory symptoms including maxillary sinus pain, post-nasal drip, congestion, rhinorrhea, and a non-productive cough. He was evaluated by his primary care physician 3 days prior to presentation and had labs drawn and was started on a 10-day course of Trimethoprim-Sulfamethoxazole (TMP-SMX). Platelet count prior to initiation of TMP-SMX was 140×10⁹/L. The evening prior to presentation, the patient began experiencing flu-like symptoms including fevers, chills, malaise, and myalgias. He then developed a petechial rash on his trunk and

extremities. Platelet count on hospital admission was 1×10⁹/L. The patient also had a normocytic anemia with a hemoglobin of 13.7 g/dL and a hematocrit of 39.8 %. HIV and acute hepatitis panel were negative. Haptoglobin was normal and lactate dehydrogenase was only slightly elevated. During the patient's hospital course, TMP-SMX was discontinued upon admission and he was treated with IVIG×1 infusion and corticosteroids×5 days. The platelet count recovered to 128×10⁹/L at time of hospital discharge.

Discussion In DITP, the platelet count generally falls rapidly within 2–3 days of taking a drug which has been taken previously, or greater than 7 days after starting a new drug. Rapid identification and removal of the offending drug is imperative to prevent clinically significant bleeding.

224 PRECURSOR B LYMPHOBLASTIC LYMPHOMA: PRESENTATION OF CHEST PAIN

S Vazquez Diaz, R Sadeghian, B Lockwood, F Wilson, M Petty, T Kulkarni. *University of South Alabama, Mobile, AL.*

10.1136/jim-2016-000393.224

Case Report 13 year old male with no significant past medical history presented with complaints of intermittent chest pain for 6 months, which had been treated as musculoskeletal pain. 10 days prior to admission a painful lump was noticed on his left upper back and chest pain became more frequent. Pain was accompanied by dyspnea, but he had no fever, weight loss or other symptoms.

Physical examination revealed markedly decreased breath sounds on the left, a 6x6 cm soft, tender mass over left scapular area and left axillary lymphadenopathy. Laboratory studies obtained showed a WBC of 13.8, ESR 47, CRP 9.6, LDH 345.

CT showed numerous soft tissue masses throughout the chest, abdomen and pelvis with the largest in the left upper lung measuring 9.9×9.1×8.6 cm with lymph node involvement; lytic lesions in proximal left femur and body of manubrium; loculated, left pleural effusion with subtotal collapse of the left lung; hepatomegaly; bilateral kidney masses and small bowel masses.

Biopsy of left axillary lymph node revealed diffuse sheets of monotonous small round blue malignant cells. By flow cytometry approximately 80% blasts, and 8% lymphocytes were detected. The blasts represented precursor B-cells with expression of CD45 (dim), CD10, CD19, CD20 (small subset), CD22 (dim), CD79a, HLA-DR, TdT, and Kappa surface light chains (dim). The findings were consistent with precursor B lymphoblastic leukemia/lymphoma. Bone marrow biopsy did not showed evidence of leukemia or lymphoma, and hence this represented precursor B lymphoblastic lymphoma. Patient was started on AALL1131 protocol with monitor in PICU for the first 4 days of treatment due to concern for tumor lysis syndrome. Patient was discharged home after being treated for 2 weeks and being followed up in the USS Hope for consolidation therapy.

225 DENOSUMAB ASSOCIATED SEVERE HYPOCALCEMIA IN A PATIENT WITH CHRONIC KIDNEY DISEASEMH Williams, RA Williams, S Salim, N Sheehan. *UMMC, Jackson, MS.*

10.1136/jim-2016-000393.225

Case Report Denosumab is a monoclonal antibody against receptor activator of nuclear factor kappa B ligand (RANKL). Denosumab reduces the risk of skeletal-related events, including spinal cord compression, pathologic fracture, and hypercalcemia of malignancy, in patients with bone metastases. Hypocalcemia is a known side effect of denosumab, occurring in an estimated 8–14% of patients. Here we present an asymptomatic patient with severe hypocalcemia who was treated with denosumab one month prior.

A 70 year old white male with hypertension, chronic kidney disease (CKD) stage V, and metastatic adenocarcinoma of the lung presented from oncology clinic for severe hypocalcemia. The patient reported fatigue and a poor appetite, but had no other complaints. Exam revealed a thin, ill-appearing male with dry skin and mucous membranes. Laboratory findings revealed a serum calcium of 3.6 mg/dL (corrected to 4.6 mg/dL), ionized calcium of 0.62 mmol/L, creatinine of 4.2 mg/dL, an elevated parathyroid hormone of 401.9 pg/mL, and a low serum 25-OH vitamin D of 17 ng/mL. Electrocardiogram showed a prolonged corrected QT (QTc) interval of 512 ms. The patient was treated with a total of 8 g of intravenous calcium gluconate, followed by a 10 g infusion of calcium gluconate given over 10 hours. Once his ionized calcium was greater than 1.0 mmol/L, he was transitioned to oral calcium supplementation, along with calcitriol. His severe hypocalcemia was thought to be secondary to denosumab, of which he received a single dose approximately one month prior to presentation, with secondary hyperparathyroidism from CKD also contributing. The patient was discharged on oral calcium carbonate with continued close monitoring of serum calcium.

With denosumab use, frequent monitoring of calcium levels and aggressive replacement of calcium and calcitriol is necessary to prevent hypocalcemia. Renal impairment does not affect the pharmacokinetics of denosumab, and therefore, does not necessitate dose adjustment of the drug. However, patients with CKD stages IV and V need to be monitored more closely, as they experience higher rates of hypocalcemia. This case demonstrates the importance of being aware of the adverse side effects of denosumab and monitoring for them regularly, as even patients at risk of life-threatening arrhythmias may be asymptomatic.

226 DON'T ALWAYS TAKE CANCER AT FACE VALUE: MULTIPLE PRIMARIES IN AN AIDS PATIENTRA Williams, MH Williams, N Wright, D Hansen, J Sheppard. *UMMC, Jackson, MS.*

10.1136/jim-2016-000393.226

Case Report Diffuse large B cell lymphoma (DLBCL) is an aggressive malignancy that is considered an acquired immune deficiency syndrome (AIDS) defining illness. It

typically involves the lymph nodes, but can involve other sites such as the liver and lungs. Basal cell carcinomas (BCC) can metastasize rarely to similar sites, especially with extensive locally invasive lesions. Here, we present an AIDS patient with multiple potential sources of diffuse lesions and hypercalcemia.

A 67 year old white male with human immunodeficiency virus (HIV), untreated for the past five years, presented with weakness, malaise, and a 25 pound weight loss. He had been feeling weak for the past six months, worsening in severity to the point that he could no longer stand. He had a previous history of BCC resected from his left cheek two years prior. Over the past year, the lesion had returned and was enlarging in size. On exam, he had a 7×7 cm crusted facial lesion which extended from the left zygomatic bone to the posterior ear. It had eroded to muscle and had associated necrosis of the ear. He exhibited left facial nerve palsy and diffuse weakness. Viral load was over 4 million with a CD4 count of 67. His corrected serum calcium was 14.2 mg/dL, with an elevated 1,25 dihydroxyvitamin D level of 81 pg/mL. Imaging revealed invasion of the mass into local muscular and glandular structures. He had lymphadenopathy of the neck, abdomen, and thorax, as well as multiple pulmonary, hepatic and splenic masses concerning for metastatic disease. His facial lesion was biopsied, with pathology consistent with BCC. Right groin lymph node biopsy was indeterminate. Subsequent transbronchial biopsy of the right lower lobe of the lung revealed high grade DLBCL. This patient was deemed a poor chemotherapy candidate and opted to pursue hospice care.

Although BCC can metastasize to liver, lungs, and lymph nodes in rare instances, there are other possible sources for disseminated lesions in an untreated AIDS patient, including a second primary malignancy. DLBCL is considered an AIDS-defining illness and should be in the differential for patients presenting with diffuse disease. In this case, the elevated 1,25 dihydroxyvitamin D level also helped to support the diagnosis, since it is observed in lymphomas and few other malignancies.

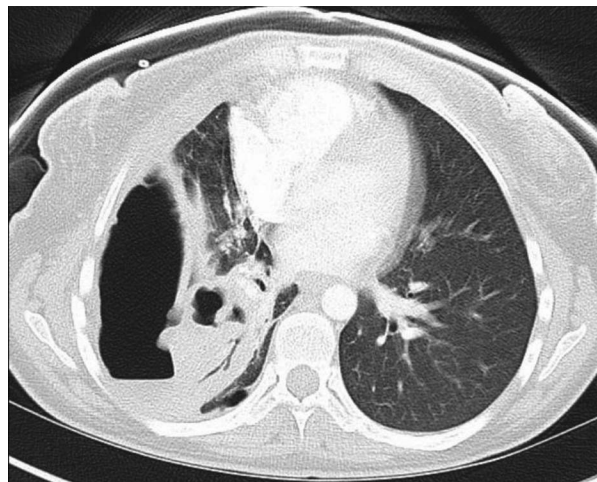
**Infectious Disease, HIV, and AIDS
Joint Plenary Poster Session and Reception
4:30 PM
Saturday, February 11, 2017**

227 RHODOCOCCUS EQUI: A RARE CAUSE OF LUNG ABSCESSF Ayoade, J King. *Louisiana State University Health Science Center, Shreveport, LA.*

10.1136/jim-2016-000393.227

Case Report A 30 year old woman with human immunodeficiency virus (HIV) disease presented with chest pain, cough and dyspnea of two weeks' duration. Her HIV viral load was 158,371 copies/ml and CD4+ lymphocyte count was 20 cells/ μ L.

Chest CT scan showed a large cavitary lung abscess and hydropneumothorax (Fig. 1). One of three sputum samples



Abstract 227 Figure 1 Chest CT showing hydropneumothorax and a 15cm×8 cm cavitary lung lesion and abscess.

was acid fast bacilli (AFB) positive but mycobacterial culture was negative. Cultures of the blood, sputum and pleural fluid were initially read as growing *Nocardia* spp. but later confirmed as *Rhodococcus equi*.

Based on susceptibility results, she was treated with intravenous linezolid, imipenem and rifampin for two weeks, followed by oral moxifloxacin, clarithromycin and rifampin for six months. Antiretroviral therapy was started after two weeks. She recovered and continued to do well one year later.

Discussion *Rhodococcus equi* is a rare, weakly acid fast, gram positive coccobacillus that could be easily confused with nocardia or mycobacteria¹.

The organism however is relatively easy to grow on routine blood cultures. Diagnosis is easily clinched with good clinical suspicion and communication with the microbiology laboratory.

Multiple antibiotics is often needed and should be continued until immune reconstitution occurs.

In summary, *Rhodococcus equi* should be included in the differential diagnosis of cavitary lung disease in the HIV patient but can be easily microbiologically confused with other pathogens.

REFERENCE

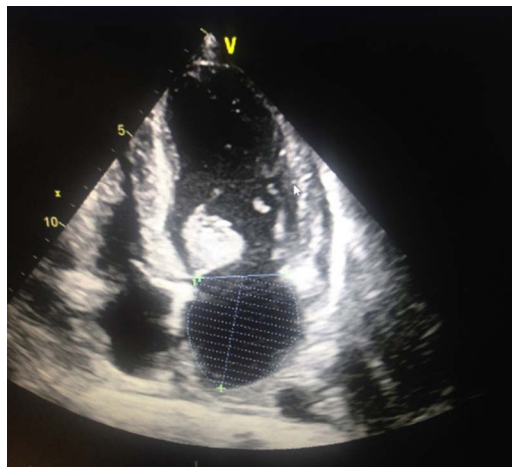
- 1 Weinstock DM, Brown AE, *Rhodococcus equi*: An Emerging Pathogen, *Clin Infect Dis* 2002;34:1379–1385.

228 ABIOTROPHIA DEFECTIVA ENDOCARDITIS WITH MULTIPLE SEPTIC EMBOLI

F Ayoade,^{1,2} S Singireddy,^{1,2} V Mekala,^{2,1} S Dauenhauer,^{2,1} R Washburn^{2,1}. ¹Louisiana State University Health Science Center, Shreveport, LA; ²Overton Brooks VA Medical Center, Shreveport, LA.

10.1136/jim-2016-000393.228

Case Report *Abiotrophia defectiva* is a nutritionally variant streptococcus, usually found as normal flora of the human upper airway, gastrointestinal and urogenital tracts. It can cause endocarditis, often associated with emboli,



Abstract 228 Figure 1 Large mitral valve vegetation on echocardiogram.

surgical interventions and higher mortality compared to other streptococcal isolates.¹

Case Presentation A 31 year old man with recent intravenous drug abuse presented with two months of fatigue, weight loss, fever, dyspnea and abdominal pain. Physical findings included a grade 3/6 apical systolic murmur and diminished left radial artery pulse. Echocardiogram showed 1.5–2.5 cm mitral valve vegetation (Figure 1) associated with severe mitral regurgitation.

Doppler ultrasound of the left arm showed left brachial artery embolus. Abdominal CT scan revealed large infarcts in the spleen and both kidneys. Blood cultures grew Gram positive cocci in chains in 5 of 6 bottles, identified on VITEK 2 as *A. defectiva*.

The patient was treated with intravenous penicillin G and gentamicin for six weeks, as well as mitral valve repair and left brachial artery balloon embolectomy. He made a full recovery.

Discussion and Conclusion This case highlights the aggressive nature of *Abiotrophia defectiva* endocarditis and the fact that combined medical and surgical therapy may be necessary for a successful outcome.

REFERENCE

- 1 Lin CH, Hsu RB. *Am J Med Sci* 2007;334:235–239.

229 CLOSTRIDIUM SEPTICUM SEPTIC ARTHRITIS OF BILATERAL PROSTHETIC KNEE JOINTS

F Ayoade,^{1,2} R Penn,^{2,1} V Mekala,^{2,1} R Washburn^{2,1}. ¹Louisiana State University Health Science Center, Shreveport, LA; ²Overton Brooks VA Medical Center, Shreveport, LA.

10.1136/jim-2016-000393.229

Case Report Septic arthritis due to *Clostridium septicum* is a rare, devastating condition with high mortality. To our knowledge, this is the first reported case of simultaneous polyarticular prosthetic knee joint infection caused by this pathogen

Case Presentation A 79-year-old man with bilateral prosthetic knee joints presented with three days of knee pain

and swelling associated with fever and vomiting. Past medical history included radiation proctitis from recently treated prostate cancer. His evaluation showed sepsis and septic arthritis in both knees. Colonoscopy revealed no evidence of colorectal neoplasm and blood tests showed no indication of leukemia. Gram positive bacilli identified as *C. septicum* were isolated from blood and both knee joints. He received arthroscopic debridement, synovectomy and open polyethylene exchange of both knees followed by eight weeks of IV penicillin G and metronidazole. He retained both prosthetic knees and is doing well on suppressive oral penicillin VK.

Discussion *Clostridium septicum* is an aerotolerant Gram-positive, gas-producing bacillus. Virulence is linked to α -toxin, a lecithinase that causes hemolysis and myonecrosis.¹ The infection is associated with leukemia and underlying colonic malignancy in up to 30%-50% of patients.¹ Tumor necrosis and anaerobic glycolysis promote a hypoxic and acidic environment favoring the germination of clostridial spores.² Even though our patient did not have colorectal or hematological malignancy, we postulate that radiation proctitis, recent colonoscopy and gastrointestinal mucosal barrier breakdown provided a milieu favoring the growth and dissemination of *C. septicum*.

Conclusion We conclude that mucosal barrier damage and other non malignant factors could be important in the pathogenesis of *Clostridium septicum*. This case underscores the severity and virulence of this infection and the need for source control followed by penicillin therapy.

REFERENCES

- Kornbluth A, Danzig J, Bernstein L. *Clostridium septicum* infection and associated malignancy. Report of 2 cases and review of the literature. *Medicine* 1989;68:30-37.
- Alpern RJ, Dowell VR. *Clostridium septicum* infections and malignancy. *JAMA* 1969;209:385-388.

230 PURULENT PERICARDITIS DUE TO AN INFECTED PACEMAKER LEAD

T Backes, LS Engel. *LSU Health Sciences Center, New Orleans, LA.*

10.1136/jim-2016-000393.230

Case Report Introduction: Intravenous drug users have a substantially increased risk of infective endocarditis, especially in the setting of implanted cardiac devices. Purulent pericarditis is a rare occurrence that can occur iatrogenically or through direct or hematogenous spread.

Case description A 75 year old man with a past medical history of hepatitis C, IV drug abuse, and sick sinus syndrome status post pacemaker was brought in by EMS with a chief complaint of diaphoresis and chest pain. Initial EKG revealed atrial fibrillation with ST elevations in multiple leads. The patient underwent urgent left heart catheterization which revealed nonobstructive CAD. A bedside echo was significant for a pericardial effusion and a pacemaker lead vegetation. CT of the chest revealed extension of the ventricular pacemaker lead through the anterior right ventricular wall and pericardium and into the pleural cavity. Cardiothoracic surgery performed a pacemaker removal as well as pericardial window due to early tamponade; approximately 900 mL of purulent fluid was

drained from the pericardial space. Initial blood culture grew MSSA. He was also found to have multiple other foci of infection including a left-sided pleural effusion and a perihepatic fluid collection, both of which were drained and also grew out MSSA. The patient initially improved on antibiotics after his pacemaker removal and drainage of the infected fluid collections. However, several days after the pacemaker removal he gradually became more bradycardic; due to his multiple comorbidities and active infection, he was not a candidate for a replacement implanted pacemaker. He became profoundly bradycardic and hypotensive overnight and died despite the use of multiple pressors to maintain his blood pressure as well as transcutaneous pacing to maintain his heart rate.

Discussion Purulent pericarditis has become a relatively uncommon occurrence since the development of effective antibiotics. This case illustrates a rare example of purulent pericarditis and cardiac tamponade secondary to the extension of an infected pacemaker wire through the pericardium and into the thoracic cavity. The presence of multiple other infected fluid collections in this case also illustrates the need to thoroughly assess for secondary foci of infection in cases of bacterial endocarditis.

231 MYCOBACTERIUM HECKESHORNENSE INFECTION MIMICKING METASTATIC DISEASE

K Chohonis,¹ S Burkett,¹ T Calvano.² ¹Eisenhower Army Medical Center, Fort Gordon, GA; ²Brooke Army Medical Center, San Antonio, TX.

10.1136/jim-2016-000393.231

Case Report *Mycobacterium heckeshornense* is a recently identified species of non-tuberculous mycobacteria (NTM) which is becoming recognized as an emerging pathogen in both immunocompromised and immunocompetent patients. We describe a rare case of *Mycobacterium heckeshornense* infection mimicking metastatic disease. A 56 year-old African-American man presented to the Emergency Department with one day of fever, somnolence, and dyspnea in the setting of several weeks of cognitive decline. Neuroimaging, cerebral spinal fluid analysis, and electroencephalogram testing were negative for intracranial mass or hemorrhage, meningoencephalitis, or seizure. Computed tomography of the chest with intravenous contrast revealed multiple, lower lung field predominant, spiculated pulmonary nodules, splenomegaly, and a 4 cm right adrenal mass, which were metabolically active on 18F-FDG positron emission tomography. Endoscopic ultrasound biopsy of the right adrenal gland revealed normal adrenal tissue. A percutaneous fine needle aspiration biopsy of a left lower lobe pulmonary nodule revealed granulomatous inflammation, without evidence of malignancy. A bronchoscopy with bronchoalveolar lavage (BAL) to the left lower lobe was AFB stain negative without evidence of malignant cells. During this time, the patient's cognitive and functional status continued to rapidly deteriorate. He developed renal failure with bland urine sediment, normal renal duplex ultrasound, and negative serologies. The patient's family deferred hemodialysis and the patient passed away six weeks from his initial presentation. Post-mortem, the BAL and fine needle aspiration AFB cultures revealed

growth. Mycobacterial DNA probe testing was negative for *Mycobacterium tuberculosis*. DNA sequencing was most similar to *Mycobacterium heckeshornense*. Only 12 cases of *M. heckeshornense* infection have been reported in humans since its initial description in 2000. We present a unique case *M. heckeshornense* infection with presumed multi-organ involvement in an immunocompetent patient. This case highlights the pathogenicity of this emerging non-tuberculous mycobacterium and stresses the importance of obtaining an accurate diagnosis based on molecular biology methods.

232 PERI-PROSTHETIC TIBIAL OSTEOMYELITIS CAUSED BY STAPHYLOCOCCUS SCIURI

TS Dhami,^{1,2} T Naguib^{1,2}. ¹Texas Tech University of Health Sciences, Amarillo, TX; ²VA Hospital, Amarillo, TX.

10.1136/jim-2016-000393.232

Introduction *Staphylococcus sciuri* is a multi-drug resistant coagulase negative pathogen of emerging importance. Despite being frequently isolated from animals, *S. sciuri* was reported in human cases of infective endocarditis, urinary and wound infections, but not in osteomyelitis as a single pathogen.

Case Report 77 year-old diabetic gentleman, who had inter-fragmentary fixation of a right tibial pilon fracture 5 years earlier, presented with pain, redness, and swelling of the right ankle without precipitating injury. Lab revealed leukocytes of 12.1 K/uL, ESR 76 mm/Hr, CRP 7.37, and procalcitonin <0.05. Radiographs revealed healed tibial pilon fracture with advanced traumatic arthritis and hardware of 2 screws. No gas was seen. Preoperative wound cultures revealed the growth of *Serratia marcescens*. Hardware removal and drainage of the intramedullary canal and debridement of the right distal tibia were performed and vacuum was applied. Pathology showed acute and chronic osteomyelitis. Cultures revealed moderate growth of *S. sciuri* that was resistant to clindamycin, oxacillin, and vancomycin, but sensitive to tetracycline and TMP/SMZ. Due to acute kidney injury, he was treated with a combination of oral levofloxacin and intravenous vancomycin for 6 weeks. Long-term follow-up revealed resolution.

Discussion The majority of periprosthetic joint infection is caused by *Staphylococci*, both coagulase positive and negative. *S. sciuri*, a coagulase negative organism, has been implicated with other organisms in the pathogenesis of osteomyelitis. However, its pathogenic ability has been substantiated by our report as it has been isolated as a single organism. The organism is capable of rapid conversion from a state of methicillin sensitivity to that of resistance. It is important to note that the gene *mecA* homologue ubiquitous in the antibiotic susceptible animal species of *S. sciuri* may be an evolutionary precursor of the methicillin resistance gene *mecA* of the pathogenic strain of *S. aureus*.

Conclusion *S. sciuri* is capable of causing periprosthetic osteomyelitis as a single agent. Clinicians should consider the organism in this clinical scenario, especially in view of its multidrug-resistance potential.

233 A CASE OF CULTURE-NEGATIVE AORTIC VALVE ENDOCARDITIS IN A PATIENT WITH SICKLE CELL DISEASE

B Ford, R Kamat, SJ Beck, LS Engel, B DeBoisblanc. *LSU Health Sciences Center, New Orleans, LA.*

10.1136/jim-2016-000393.233

Case Report Introduction: Culture negative endocarditis is defined as endocarditis without identified etiology after three consecutive blood cultures and seven days of incubation. Work-up is generally warranted to determine if the endocarditis has a noninfectious source.

Case A 45 year-old incarcerated man with a past medical history of sickle cell disease and chronic venous stasis ulcers presented with two days of shortness of breath, chest pain, and subjective fevers/chills. He reported that his chest pain was sharper than the usual pain he experienced with his sickle cell crises. He also noted that he had been regularly treated with antibiotics for acute chest syndrome and his venous stasis ulcers. On admission, the patient was found to be severely anemic and required BiPAP for his respiratory distress. He was emergently intubated and initial chest radiograph showed diffuse opacities which were concerning for acute chest syndrome vs. pulmonary edema. He was admitted to the ICU for further management and placed on broad spectrum antibiotics. He received blood transfusion and a transthoracic echocardiogram showed a large pedunculated mass on the aortic valve extending into the left ventricular outflow tract, and a subsequent Trans-esophageal echocardiogram showed flail cusps of aortic valve with a large vegetation and high risk of embolization. An abdominal ultrasound also revealed acalculous cholecystitis. The patient had a cholecystostomy tube placed for gallbladder drainage and received dialysis for worsening kidney failure. Upon improvement in his multi-organ dysfunction he underwent prosthetic aortic valve replacement as well as laparoscopic cholecystectomy. Pathologic evaluation failed to demonstrate an infectious etiology.

Discussion In the developing world, zoonotic and fungal infections are major contributors to culture negative endocarditis. Overuse of antibiotics can also lead to issues with identification. This patient was on chronic antibiotics, likely owing to his lack of positive culture results. If valve replacement is performed histopathological testing can be helpful, however pathology was negative for this patient for both gallbladder and aortic valve specimens.

234 AFRICAN TICK BITE FEVER IN A TRAVELER – DIAGNOSTIC CHALLENGE

D Gebremariam, K Nugent. *Department of Internal Medicine, Texas Tech University Health Sciences Center, Lubbock, Texas.*

10.1136/jim-2016-000393.234

Introduction African tick bite fever is an emerging infectious disease transmitted by ticks. It is mainly found in Africa, but sometimes found in Americas and Caribbean. African tick bite fever is caused by two species of rickettsia, ‘*Rickettsia africae*’ and ‘*Rickettsia parkeri*’. The bacteria

reside in salivary glands of the tick and are transmitted to the host during a blood meal. Hardly any cases are reported within Africa itself. Most cases are travelers that have gone to endemic countries.

Case presentation A 41 year old woman was admitted for fever of 102 F, chills and skin rashes of five days after returning from a hunting trip to South Africa. Patient reported tick bites while out in the wilderness. On exam she had an eschar in the left popliteal region. A clinical diagnosis of African TBF was made, doxycycline started and she improved. Investigations include PCR for malaria, hepatitis panel, influenza A & B, HIV and syphilis screening and outside labs done for rickettsiae (done only for RMSF), typhus, malaria and Q-fever were all negative. Given the high clinical likelihood of African TBF, diagnostic challenges were patient's presentation in the acute phase where serological tests could be negative and unavailability of specific tests for African TBF.

Discussion The classical clinical triad of fever, eschar and rash occurs in 50 to 75 % of cases of TBF. An eschar, as in this patient, is very strong sign of african TBF. There is a need to test for acute and convalescent phase antibodies since they usually are released after a few weeks of tick bite. Our patient presented in the acute phase and even if specific tests were done to detect antibodies against 'Rickettsiae africae' the tests would have likely been negative. The preferred diagnostic technique is a skin biopsy from the eschar with PCR or immunohistochemical detection of bacteria, which presented a diagnostic challenge since the organism is rare in the USA and lab facilities did not perform the test presenting a diagnostic challenge. Our case demonstrates the importance of clinical diagnosis of acute febrile illnesses in travelers and appropriate early treatment to prevent more serious outcomes.

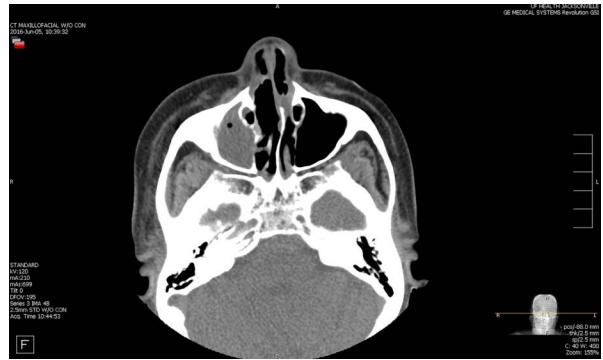235 INVASIVE ETHMO-MAXILO-ORBITAL MUCORMYCOSIS

J Greco, P Staiano, P Patel, J Ruiz, C Palacio. *UF Jacksonville, Jacksonville, FL.*

10.1136/jim-2016-000393.235

Case Report Our patient is a 53 year old female with past medical history of poorly controlled IDDM, COPD, anemia, right AKA, and a long history of non-adherence with medications who presented to the emergency room for headaches, nausea, facial numbness and swelling, eye pain and blurry vision. She was initially admitted for hypertensive emergency requiring nicardipine infusion and DKA requiring insulin ggt. Initially there was some concern for stroke, neurology was consulted but CT head was negative for acute findings. She was diagnosed with right maxillary sinusitis and the patient was started on Augmentin. Patient stated she saw her PCP approximately a month ago for concern of sinus infection and stated she received antibiotics.

She admitted to non-adherence of her insulin and BP meds. She was drowsy during physical exam and endorsed eye pain with nausea. She had no other acute complaints at that time. Further imaging was done via CT of the Maxillofacial sinus and there was opacification of the right sinus with invasion of sphenoid, maxillary, ethmoid bones.



Abstract 235 Figure 1

The patient's findings were consistent with mucormycosis and debridement x2 was done and sent for culture that was positive for bacterial (VRE, CNSA, *Corynebacterium*) and multifungal (mucor, rhizopus).

She was started on Daptomycin, Amphotericin and Caspofungin. The infection was found to have infiltrated the optic nerve and medial rectus on MRI. Ultimately she lost her vision and developed blindness to even light perception. The patient also developed renal failure and had to initiate dialysis. CK was monitored bi-weekly. She eventually developed an elevated CK of 9000 and switched to zyvox from daptomycin. Ultimately, the patient was not compliant with her IV anti-fungal and stated she wanted to be on a long-term oral medication she could take from home. The patient was discharged on isavuconazonium after first being loaded with it.

236 STREPTOCOCCUS PYOGENES AN UNCOMMON CAUSE OF COMMUNITY ACQUIRED PNEUMONIA

KR Green,¹ B Lyons,¹ C Horn,¹ U Wardan². ¹*UF Jacksonville, Jacksonville, FL;* ²*Des Moines College of Medicine, Des Moines, IA.*

10.1136/jim-2016-000393.236

Introduction Historically streptococcus pyogenes was a common cause of community acquired pneumonia, however since the antibiotic era, cases are usually limited to post viral infections. It is characterized by chills, fevers, cough productive of blood tinged sputum, and pleurisy.

Case Report A 19-year-old female with a history of depression presented to the emergency department with 3 weeks of coryzal symptoms and a rapidly progressive cough with rust colored sputum. She denied gross hemoptysis, but noted red streaking in her sputum. She had fever, chills, night sweats and a 15 pound weight loss in two months. She had no history of immunodeficiency and denied risk factors for tuberculosis infection.

On presentation she was afebrile, tachycardic and normotensive. Laboratory studies were remarkable for anion gap metabolic acidosis, leukocytosis of 30.9 with 20 percent bands. Sputum for acid fast bacilli and sputum culture were initially negative. Respiratory viral panel was positive for rhinovirus. HIV was negative. Chest X-ray revealed a right midlung cavitary lesion and she was started on broad spectrum antibiotics. CT revealed a 6 by 3.8 by

4.6 cm right upper lobe/right middle lobe pulmonary abscess/pneumonia and a moderate pleural effusion. Pleural fluid evaluation was consistent with empyema. Five days after admission, the respiratory culture grew *S. pyogenes*. VATS was performed and revealed pleural rind with extensive empyema involving the upper, middle and lower lobes with adjacent abscess formation in the middle and upper lobes. A chest tube was placed and removed when drainage ceased. She was discharged on a course of augmentin. Thirty-eight days after discharge an initial acid fast bacilli culture with stain, which originally revealed no evidence of acid fast bacilli on smear grew *Mycobacterium gordonae*. However, the patient was lost to follow up.

Conclusion *S. pyogenes* pneumonia is a rare cause of CAP but is seen in immunocompromised persons or after viral infection, as in this case. Invasive *S. pyogenes* pneumonias carry a mortality of approximately 38 percent if left untreated. *Mycobacterium gordonae* is typically considered non-pathogenic unless the patient has other unexplained pulmonary symptoms and can contribute to mortality as in this case.

237 RECRUDESCENCE OF MALARIAL INFECTION IN A RECENTLY-IMMIGRATED PEDIATRIC PATIENT

R Herdes, S Graebert, M Shapiro, RE Begue. LSU, New Orleans, LA.

10.1136/jim-2016-000393.237

Case Report Malaria is a parasitic infection of the bloodstream and liver, caused by *Plasmodium spp* and transmitted by *Anopheles* mosquito vectors. Incubation period is usually two weeks with commencement of symptoms occurring around 14 days after infection. Typical clinical presentation includes fever, malaise, and vomiting with associated anemia, thrombocytopenia, and parasitemia. *Plasmodium vivax* and *Plasmodium ovale*, both which are prominent in Sub-Saharan Africa are known to have relapsing infections secondary to residual latent hypnozoites in the liver. Infection recrudescence in patients secondary to dormant liver forms with recent travel to endemic areas should be considered in all pediatric patients with recurrent malarial symptoms.

We present the case of a 5-year-old male with intermittent fevers, vomiting, and lethargy. Family had recently emigrated from Mauritania (western North Africa) and parents reported a prior history of malaria infection with treatment (unknown medication) prior to resettlement. Physical exam was remarkable for hepatomegaly and dehydration. Labs demonstrated thrombocytopenia and peripheral blood smear showed ring forms within erythrocytes. Abdominal ultrasound showed hepatosplenomegaly. Patient was diagnosed with quinine-resistant malaria and was treated with three days of atovaquone-proguanil (malarone). After good clinical response, one month after discharge, patient's symptoms recurred and required a second 3-day course of malarone, followed by 14 days of primaquine for eradication of dormant liver forms. Follow-up peripheral blood smear one month after primaquine course showed no evidence of parasites.

This case highlights important points in the management of malaria. One, that it should be suspected on any patient with fever and history of recent residence in endemic areas, regardless of history of treatment. Two, that rapid tests (like peripheral smear) may allow prompt diagnosis for clinical decisions but does not speciate *Plasmodium spp*. And three, that in case of initial response and later relapse malaria species with liver dormant forms (*P. vivax* and *P. ovale*) must be suspected and additional treatment with primaquine (after testing for G6PD deficiency) should be administered for eradication of malaria.

238 A RARE CASE OF WEST NILE VIRUS ENCEPHALITIS

C Horn, P Patel, JM Hernandez-Jimenez, F Baidoun. UF-COM, Jacksonville, FL.

10.1136/jim-2016-000393.238

Case Report 80 year old male presented to the ED with altered mental status for the past 48 hours per family. He had a history of coronary artery disease, diabetes, hypertension. Patient was brought to the hospital by his children who stated he had a normal baseline mentation. On exam, he was febrile at 102.1F, awake, alert however unable to respond to commands, rest of exam was within normal limits. Initial labs showed moderate leukocytosis and lactic acidosis. Initial imaging of head showed no acute changes. Lumbar puncture was performed and initial cell count showed elevated WBCs concerning for meningitis versus encephalitis. Patient was admitted to ICU for severe sepsis, pan-cultures were obtained and he was started on broad spectrum antibiotics. Course was complicated by type II NSTEMI in setting of sepsis. Patient then had a PEA arrest requiring CPR and endotracheal intubation. Blood and urine culture showed no growth. Cerebrospinal fluid serology positive for West Nile Virus(WMV) IgM. Patient was diagnosed with WNV encephalitis. After extensive discussion with family, patient's status was changed to DNR and was terminally weaned from ventilator.

WNV is transmitted by the *Culex* mosquito in summer to early fall and is more common in the Mid-West and Western US. West Nile fever, which occurs in roughly 25% of infected individuals, and is characterized by headaches, malaise, rashes and myalgias. Neuroinvasive disease can include WNV-associated paralysis, meningitis and encephalitis. WNV encephalitis (WNE) is one of the most common, if not the most common, causes of endemic viral-related encephalitis in the United States, is much more common in the elderly and has been associated with diabetes and alcoholism. Less than 1% of individuals infected with WNV develop neuroinvasive disease, although it carries with it a fatality rate of 10–20%. WNE is characterized by altered mental status, depressed levels of consciousness, focal neural deficits, personality changes, extrapyramidal symptoms, Parkinsonism and myoclonus. Respiratory failure and cardiac arrhythmias have been shown to be more common in WNE as compared to other WNV infections. CSF IgM antibodies remain the preferred method of diagnosis above serology. Diagnostic imaging of the brain is usually normal. Treatment of WNE is supportive.

239 PSEUDOMONAS PUTIDA INFECTION IN IMMUNOCOMPROMISED PATIENTS, A DEATH SENTENCE?

M Ibrahim, F Tawadros. *Quillen College of Medicine/ETSU, Johnson City, TN.*

10.1136/jim-2016-000393.239

Introduction *Pseudomonas* species, *Putida* is an uncommon cause of skin and soft tissue infections. We present a case where *Pseudomonas Putida* cellulitis was linked again with a very poor prognosis in ESRD patients

Case presentation A 64 year old African American male with PMH of ESRD presented to the ED after he missed his last three hemodialysis sessions with altered mental status in addition to worsening shortness of breath over the previous 2 weeks and bilateral shin oozing skin ulcers with pus drainage which was sent for bacterial culture. Initially, the patient was normotensive, but was fluid overloaded. Potassium was 5.9 mEq/L and blood urea nitrogen was 159. White blood cell count was 15.9/mm³. Patient was emergently dialyzed and started on vancomycin and zosyn for treatment of complicated severe cellulitis. Wound culture revealed mixed growth of *Pseudomonas Putida* in addition to *Enterococcus Faecalis*. Sensitivity results showed significant resistance of *Pseudomonas Putida* to piperacillin /tazobactam. As a result, piperacillin /tazobactam was discontinued and meropenem was started. However, the patient's clinical condition continued to deteriorate and died after he developed a septic shock.

Discussion Clinical data on *Pseudomonas Putida* infections are lacking owing to the rarity. Many strains of *Pseudomonas Putida* are usually sensitive to antimicrobial agents such as carbapenems and fluoroquinolones, in recent years the emergence of resistance to them has been a growing concern. In 2012, Kim et al¹ studied 18 cases of *Pseudomonas Putida* infections and reported increased mortality rates compared to previous studies. Most patients with infections due to *Pseudomonas* have a mucocutaneous defect or underlying compromised immunity. In our case patient had ESRD which put him in an immunocompromised state in addition to his multiple comorbidities

Summary Clinicians should be aware of high susceptibility of patients with ESRD to opportunistic organisms like *Pseudomonas Putida*, as this bacterium responds very well to treatment and have good prognosis with early initiation of proper antibiotics.

REFERENCE

- 1 Kim SE, et al. Nosocomial *Pseudomonas Putida* Bacteremia: High Rates of Carbapenem Resistance and Mortality. *Chonnam Med J* 2012;48:91–5

240 PASTEREULLA MULTOCIDA MENINGITIS LEADS TO DISSEMINATED INTRAVASCULAR COAGULATION AND MULTI-ORGAN FAILURE

E Juarez Ramirez Tello,² A Adiga,¹ K Nugent,² RE Gavidia Quezada¹. ¹Texas Tech Health Science Center, Lubbock, TX; ²Texas Tech University, Lubbock, TX.

10.1136/jim-2016-000393.240

Case Report 70 year old female with history of myelodysplastic syndrome, congestive heart failure, coronary artery

disease, hypothyroidism, diabetes type 2 admitted to intensive care due to generalized weakness, resting dyspnea and abdominal pain. Afebrile bradycardia and hypotensive with decreased breath sound and basilar crackles bilaterally present. Within hours patient developed lethargy and respiratory acidosis requiring intubation and pressor medications. Lab results remarkable for hyper-ammonia, azotemia, anemia, positive for opiates, normal lactate. EEG showed generalized slowing, no epileptiform waves. Patient started on midodrine, ammonia level, mental status, azotemia improved. Intravenous pressor medications started to extubate 48 hours later. After extubation patient agitated, unable to follow commands, with persistent CO₂ retention despite continue BiPAP mask. Three days later patient still unresponsive. Brain MRI unremarkable. Lumbar puncture obtained, patient improved for 24 hours but later deteriorated. Severely elevated liver enzymes and decreased fibrinogen pointing to diffuse intravascular coagulation (DIC). Autoimmune hepatitis ruled out, patient diagnosed with shock liver and multi-organ dysfunction. CSF culture positive for *Pastereulla multocida* (PM). Antibiotics adjusted appropriately. After twelve days family decided for comfort care, patient was extubated and finally died.

Gram-negative organisms is low frequent cause of community-acquired meningitis, accounting for 3.6% of cases in the US, affecting elderly patients with other chronic debilitating conditions.

PM is uncommon among gram-negative etiologic causes, mainly reported on neonates. With 48 cases in both and immunocompromised adults, 26% had recent history of neurosurgery.

PM exists as a commensal in upper respiratory tracts of livestock and domestic pet species, especially cats and dogs. Infection in humans associated with animal bites, scratches and licks.

Wound, deep tissue, and other disseminating infections may also develop, including endocarditis or meningitis, associated with bacteremia, sepsis, septic shock, and disseminated intravascular coagulation as in our case.

241 EYE ON LYME: A RARE CASE OF OPTIC NEURITIS FROM LYME DISEASE

RM Khan, U Masood, B Madhira, H Ghonim, A Ewida. *SUNY Upstate Medical University, Fayetteville, NY.*

10.1136/jim-2016-000393.241

Case Report Optic nerve involvement is a rare complication of Lyme Disease (LD) with only a few reported cases in literature. While abrupt disease of LD most commonly presents with meningitis, facial nerve palsy, radiculoneuritis or focal encephalitis¹, here we highlight the rare occurrence of Optic Neuritis in a patient with LD.

A 31 year old female presented with 3 weeks of headaches, right eye pain and vision loss. One month prior, patient was in the Dominican Republic where she reports being bit by 'insects' and having a week of flu-like symptoms that resolved on their own. Since then, she had fatigue and progression of her chief complaints. She denied any family history of multiple sclerosis or similar symptoms in the past. On physical examination, she had nuchal

rigidity, photophobia, decreased visual acuity (20/400 right eye), and pain on right eye abduction. The remainder of her neurological, fundoscopic, motor, and sensory exam was unremarkable.

On magnetic resonance imaging (MRI) Orbit of Face, she had enlargement of right optic nerve consistent with Optic Neuritis. MRI Thoracic spine showed no demyelinating lesions. Lumbar puncture showed glucose 43 (low), protein 242 (high) and WBC 72 (high) - consistent with bacterial meningitis. Infectious work-up of cerebrospinal fluid (CSF) for HSV, AFB, VDRL, Enterovirus and fungal cultures were negative. CSF Lyme IgG and IgM were negative with DNA PCR negative for *Borrelia burgdorferi*. However, Serum Immunoblot assay for Lyme IgM antibodies was positive with reactive bands p23 and p41. All other serum work-up for HIV, AFB, HAV, HBV, HSV, HLTV1-HLTV2, RPR, VDRL and Treponemal Ab were negative thus pointing toward the one positive finding as the likely cause of her meningitis and Optic Neuritis. Patient was immediately started on Ceftriaxone after which her right eye symptoms as well as general well-being significantly improved.

Given that it is such a rare occurrence, the purpose of this case is to bring awareness to the fact that LD can manifest as Optic Neuritis. Not only that, a swift diagnosis can lead to treatment in a timely manner resulting in complete resolution of symptoms and favorable patient outcomes.

REFERENCE

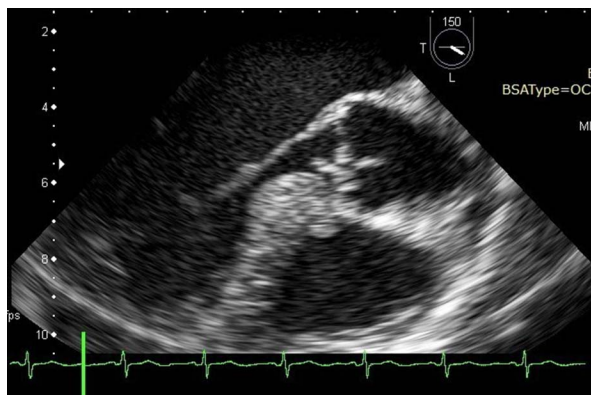
- 1 Burakgazi AZ, et al. Unusual Presentation of Unilateral Isolated Probably Lyme Optic Neuritis. 2016

242 MYSTERIOUS CASE OF *ERYSIPELOTHRIX RHUSIOPATHIAE* ENDOCARDITIS

D Layman, V Baselski, M Land, S Cross. *University of Tennessee Health Sciences Center, Memphis, TN.*

10.1136/jim-2016-000393.242

Case Report *Erysipelothrix rhusiopathiae* is a non-spore-forming, gram positive bacillus. Infections in humans occur mainly due to occupational exposure with animals. Systemic infection caused by *E. rhusiopathiae* is rare. We present a case of *Erysipelothrix rhusiopathiae* endocarditis with no identifiable source of infection. A 60-year-old male presented with chills and dyspnea. He was febrile on presentation and hypoxemic. Physical exam was unremarkable. The patient was admitted for respiratory failure. Initial TTE demonstrated severe aortic regurgitation. Blood cultures on admission were positive for gram positive bacilli initially suspicious for *Lactobacillus spp.* Further evaluation with TEE revealed a 9.8 by 3 mm aortic valve vegetation. By day four of the patient's hospital stay the initial blood cultures were reported as *Erysipelothrix rhusiopathiae*. Antibiotic therapy was changed to ampicillin. Blood cultures cleared by hospital day 6. Cardiology did not feel that surgical intervention was indicated. The patient remained stable and completed 6 weeks of IV antibiotic therapy. Follow up TTE near the end of therapy showed thickened aortic valve with moderate aortic regurgitation. He was discharged in good condition at the



Abstract 242 Figure 1

completion of 6 weeks of treatment. *E. rhusiopathiae* is a rare cause of endocarditis which can cause extensive valve destruction and mycotic aneurysms. Mortality is high and valve replacement is commonly indicated. We present a case of successfully medically treated *E. rhusiopathiae* endocarditis with no identifiable source of infection.

243 DISSEMINATED CRYPTOCOCCUS IN A PATIENT WITH HIV/AIDS

S Lillis, LS Engel. *LSU Health Sciences Center, New Orleans, LA.*

10.1136/jim-2016-000393.243

Case Report A 42 year old African American man with a past medical history of HIV off HAART for almost two years, neurosyphilis treated in 2010, hypertension and type 2 diabetes mellitus presented to the ED with a two week history of neck pain and left lateral back pain, malaise, poor appetite, ten pound weight loss and vomiting. Vital signs at the time of admission were unremarkable. Physical exam findings included point tenderness along the C6 spinous process, and a 1 centimeter smooth, firm, umbilicated nodule in the right groin. Initial labs revealed a CD4 count of 29 cells/microL. Computed tomography of the chest showed multiple cavitory lesions in the right lower lobe, multiple enlarged right hilar lymph nodes, and multiple lesions in the spleen. Pathological exam from a CT guided lung biopsy was consistent with fungal infection. Serum Cryptococcus titer was elevated at 1:512. The patient was diagnosed with disseminated Cryptococcus and started on induction therapy with amphotericin B liposomal and flucytosine. Induction therapy was extended for two more weeks after lumbar puncture did not show clearance at day fourteen. Lumbar punctures were performed as needed for symptoms of elevated intracranial pressure. A lumbar drain was placed by neurosurgery on hospital day sixteen and removed on hospital day thirty after drainage decreased. The patient completed twenty-eight days of amphotericin B liposomal and flucytosine and was then transitioned to daily fluconazole. On hospital day thirty-four, patient had worsening headache, nausea, and vomiting. Lumbar puncture revealed an opening pressure of 54 mmHg. Neurosurgery placed a lumbar peritoneal drain on hospital day thirty-five with resolution of symptoms.

The patient had an uncomplicated post-operative course and was discharged home on daily fluconazole.

Discussion Disseminated *Cryptococcus neoformans* is an opportunistic infection seen in patients with untreated AIDS. Patients with high fungal burdens often have elevation of the intracranial pressure. Aggressive management of intracranial pressure leads to decreased mortality. A permanent ventriculoperitoneal shunt or lumboperitoneal shunt (as was used in this patient) can be placed after induction therapy is completed in patients with continued lumbar puncture requirements.

244 THE GREAT IMITATOR – AN UNUSUAL PRESENTATION OF SECONDARY SYPHILIS

M Mahoney, A Omer. *Texas Tech Univ HSC Amarillo, Amarillo, TX.*

10.1136/jim-2016-000393.244

Case Report A 50-year-old Caucasian, homosexual male with a history of diabetes presented to the ED with epigastric abdominal pain. He also had a diffuse maculopapular rash involving most of his body, including the palms and soles. Associated symptoms were numerous, but included intermittent dizziness and weakness, subjective fevers, and weight loss. The patient claimed to have had negative HIV and syphilis tests within the last month and to have been sexually active with only one partner for the last two years. On admission, CT showed a stone lodged in the gallbladder neck. LFTs were elevated, with alkaline phosphatase in the 900s and mild elevations in AST and ALT. With the suspicion of cholecystitis, a cholecystectomy was planned. However, the patient was retested for syphilis in the meantime and found to have a positive RPR and positive Treponemal antibodies. A liver biopsy showed portal hepatitis, fibrosis and inflammation. These findings indicated syphilitic hepatitis—an alternative explanation for his pain. A CSF sample also taken during this time returned with a positive VRDL test. The patient was placed on IV penicillin for neurosyphilis and syphilitic hepatitis, after which his symptoms gradually improved.

Discussion Syphilis rates have increased in recent years, from 2.1 per 100,000 in 2001 to 6.3 per 100,000 in 2014. Rates are significantly higher for the MSM population than

for other demographic groups. Syphilis, known as ‘The Great Imitator,’ can be difficult to diagnose. Here, it presented as abdominal pain that mimicked cholecystitis. While this presentation was unusual, syphilis was caught in this patient primarily because of his characteristic rash. Suspicion of syphilis in vulnerable populations, especially the MSM population, must remain high to avoid missing this easily treatable disease.

245 SHOULDER PAIN ON STEROIDS!

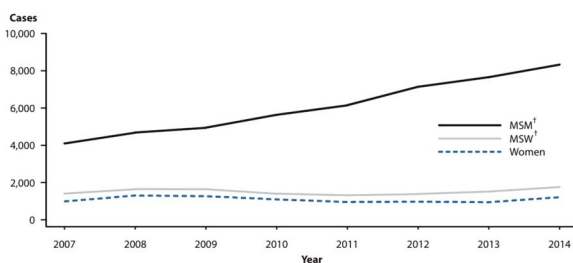
M McLain, RD Smalligan, S Alexander, B Khandheria. *Texas Tech Univ HSC-Amarillo, Amarillo, TX.*

10.1136/jim-2016-000393.245

Case Report An 82-year-old Mexican-American woman with a PMH of ESRD on hemodialysis, HTN and AF presented with pain and swelling in her shoulder over 8 months despite conservative treatment of her rotator cuff tear. She received intra-articular injections of steroids on at least 2 occasions but had paradoxical worsening of her symptoms. She denied any systemic symptoms. On exam she was afebrile, no adenopathy, lungs: clear, heart irregular and joints normal except for right shoulder that was swollen and tender but not red or warm. CBC was normal. At this point her shoulder was aspirated and fluid sent for stains and cultures. Gram stain was negative however within 2 weeks *Mycobacterium tuberculosis* was growing in culture. She was referred to the health dept. where she denied recent travel, TB contacts, cough or other symptoms concerning for pulmonary TB and her CXR was negative. She was started on standard directly observed treatment with INH, rifampin, pyrazinamide and ethambutol (renally adjusted). Within two weeks the swelling and pain in her shoulder had subsided significantly and appeared almost normal.

Discussion Tuberculosis of the shoulder is a rare form of extrapulmonary TB and can mimic Poncet’s disease (reactive arthritis accompanying TB). Tuberculous arthritis most often affects the hip or knee, but can occur in any joint. Symptoms of tuberculous arthritis are exactly as seen in our patient and include joint effusion, pain, and decreased range of motion. If left untreated, there is potential for permanent joint destruction and deformity. Skeletal/joint TB occurs in 1–3% of patients with TB and typically occurs from hematogenous seeding, often after trauma to the area. Reactivation of latent TB may occur in immunocompromised patients with renal failure, diabetes mellitus, HIV, malnutrition, or advanced age. The diagnosis of skeletal TB and tuberculous arthritis is often delayed because of lack of fever and other systemic TB symptoms, resulting in ineffective and often counterproductive treatments as seen in our case with the corticosteroid injections. Although rare, clinicians need to keep tuberculous arthritis in their differential diagnosis in patients with known immunocompromising conditions that present with monoarticular arthritis, especially if they do not respond promptly to standard treatments.

Figure 32. Primary and Secondary Syphilis — Reported Cases by Sex and Sexual Behavior, 27 Areas*, 2007–2014



* 27 states reported sex of partner data for ≥70% of reported cases of primary and secondary syphilis for each year during 2007–2014.
 † MSM = men who have sex with men; MSW = men who have sex with women only.

Abstract 244 Figure 1

246 CANCELLED

247 A RARE CASE OF CLOSTRIDIUM PARAPUTRIFICUM EMPYEMA IN A PATIENT WITH BILATERAL PULMONARY EMBOLI

LE Muncy, R Deen, D Davis K. Dwight. *Eisenhower Army Medical Center, Ft. Gordon, GA.*

10.1136/jim-2016-000393.247

Case Report Empyemas are a frequent occurrence, most commonly caused by streptococcus and staphylococcus species. Clostridium rarely causes empyema but is associated with violation of thoracic cavity, pulmonary infections, or tissue necrosis. We present a case of *Clostridium paraputrificum* empyema in the setting of bilateral pulmonary emboli.

A 57 year-old man with a history of a whipple procedure, diabetes, malnutrition, and no recent antibiotic exposure presented with dyspnea. He had been admitted a week prior for anasarca secondary to hypoalbuminemia, which was treated with an increase in pancreatic enzymes and diuretics. He subsequently developed progressive dyspnea on exertion, with a new oxygen requirement, and an exam consistent with a pleural effusion. CT imaging of the chest demonstrated a moderate size loculated effusion and bilateral pulmonary emboli. Thoracentesis revealed an exudative effusion with an LDH of >700. Cultures of pleural fluid recovered gram positive rods identified as *Clostridium paraputrificum*. Ampicillin/sulbactam was started and a chest tube was placed. Due to incomplete drainage tPA was initiated. After minimal improvement he underwent a VATS decortication and pleurodesis. He improved and was discharged on oral antibiotics and continued oral anticoagulation for the pulmonary emboli. He remained symptom free upon follow up four weeks later.

This is the only reported case of *C. paraputrificum* empyema. There is one other case of a lung infection caused by *C. paraputrificum* in the literature, in a malnourished male with a history of alcohol abuse. Infection generally occurs in immunocompromised patients or patients with intra-abdominal necrosis. As with empyema from more common organisms, treatment is with tube thoracostomy and directed antibiotics. Our patient was evaluated for malignancy, without any positive findings to suggest this as a factor. We hypothesize that localized pulmonary necrosis developed due to decreased vascular supply from his bilateral pulmonary emboli, which combined with immunocompromise from severe malnutrition resulted in this unusual localized abscess/empyema.

248 EMPHYSEMATOUS PYELONEPHRITIS: CONSERVATIVE MANAGEMENT VS NEPHRECTOMY

G Murtaza, A Emmanuel, N Mungo, SM Zaidi, K Bajaj. *East Tennessee state University, Johnson City, TN.*

10.1136/jim-2016-000393.248

Case Report Emphysematous pyelonephritis is a severe gas-forming infection of renal parenchyma. Here we present an interesting case of EPN, which was initially managed medically but had a favorable outcome with nephrectomy in the end.

A 58 year old male with a history of diabetes mellitus and renal calculi presented to the ER with a 1 week history of progressively worsening right flank pain, vomiting, high grade fever and chills. Physical examination showed significant abdominal distention, diffuse tenderness with hypoactive bowel sounds. Laboratory tests revealed wbc count 21000/mm³, platelet 270000/mm³, serum creatinine 3.41 and serum glucose 280 mg/dl. Abdominal CT showed large amount of gas within collecting system in right kidney. Urology recommended placement of nephrostomy drain with antibiotics and deferred any surgical intervention. Over the next couple of days patient continued to develop progressive abdominal distention due to significant ileus. Hospital course was further complicated by development of acute deep venous thrombosis, renal failure, refractory ascites and ileus. Urologist were still against nephrectomy despite the fact that patient did not respond to appropriate antibiotics based on cultures for several weeks. Palliative medicine was suggested however the family requested full treatment. This facilitated the switch in treatment strategy from medical management to surgery. Ultimately patient underwent radical nephrectomy. His post-operative course was complicated by acute peritonitis with formation of abscess and had repeat explorative laparotomy with right hemicolectomy. He gradually recovered from multi organ failure after couple of weeks and was discharged to rehab facility in stable condition.

Controversies exist surrounding the appropriate management of this life-threatening condition with advocates for both medical managements alone and percutaneous drainage combined with nephrectomy. Delay in this decision-making complicated the hospital course. Failure to promptly switch treatment strategy from percutaneous drainage to nephrectomy resulted in a nearly fatal hospital course. Regardless of whether a clinician ends up deciding medical or surgical management, surgical options should not be delayed in appropriate clinical scenario.

249 CUTANEOUS HISTOPLASMOSIS MASQUERADING AS RECURRENT ABSCESSSES

G Nelson, J Ruiz, M Gutierrez, C Isache. *University of Florida, Jacksonville, FL.*

10.1136/jim-2016-000393.249

Case Report A 38 year-old African-American male presented with complaint of a neck mass for one week. His past medical history included HIV (diagnosed 16 years prior, current CD4 of 22), diabetes and recurrent skin abscesses. He also had been evaluated 9 years prior for dry cough and intermittent fevers with diffuse pulmonary infiltrates on chest x-ray, unresponsive to antibiotics. Over the next several years he developed a series of skin 'boils' on the periorbital area, back, legs and penis. He sought medical attention several times and repeatedly failed antibiotics plus incision and drainage. On this admission he presented with complaint of a neck mass that was 5x7 cm.

Review of systems was notable for aching neck pain, mild subjective fevers and malaise. Patient was seen in clinic one week prior with same complaint and sent home with clindamycin but continued to worsen. Multiple scarified lesions were noted throughout the skin. Bedside ultrasound showed no drainable abscess. CT of the neck revealed anterior left neck edema and heterogeneous enhancement related to superficial phlegmonous changes anterior to the thyroid cartilage. Tissue biopsy demonstrated fungal organisms histologically consistent with *Histoplasma* plus positive PAS and GMS stains. Patient was started on itraconazole 200 mg bid. Histoplasmosis is an opportunistic fungal infection caused by inhalation of *Histoplasma capsulatum*. It is most prevalent in the Mississippi and Ohio River Valley in bat and bird dropping contaminated soil. Though typically indolent, immunocompromised individuals are at risk of dissemination to blood and bone marrow, with multisystem involvement or rapidly progressive sepsis. Cutaneous histoplasmosis is very rare; 10–20% of AIDS patients with disseminated histoplasmosis present with papules, pustules, plaques, ulcers and rarely erythema nodosum. This atypical dermatologic manifestation of a large neck mass deviated from usual lesions. Treatment options for disseminated histoplasmosis include itraconazole and amphotericin B for mild and severe cases. The aberrant presentation described in this case posed a diagnostic challenge leaving the patient misdiagnosed for years. Therefore, it is important to carry a high index of suspicion in AIDS patients with nonspecific skin lesions who fail multiple antibiotic therapies.

250 OCCULT EPIDURAL ABSCESS PRESENTING AS FEVER OF UNKNOWN ORIGIN

L Nuss, B Casey, A Prudhomme, D Leblanc. *LSUHSC New Orleans, New Orleans, LA.*

10.1136/jim-2016-000393.250

Case Report Fever of unknown origin (FUO) has been classically defined as a temperature above 38.3°C (101°F) for at least three weeks with no diagnosis after one week of hospital investigation. In pediatrics, these parameters have not been strictly applied, and FUO is a broad diagnosis. The causes generally fall into the categories of infection, malignancy, inflammatory disorders, and miscellaneous. For clinical purposes, we can describe pediatric FUO as a fever persisting longer than one might expect an acute self-limiting illness to last without an apparent diagnosis, after a careful history, physical examination, and laboratory assessment. Even as diagnostic technology advances, many cases of FUO continue to elude the clinician.

Here we report a previously healthy 11 year old female who presented with malaise and fevers despite a course of oral antibiotics for 9 days and then continuation of fevers for nearly 3 weeks. Initial laboratory findings showed elevated platelets and serum C-reactive protein. Abdominal CT was significant for splenic lesions concerning for infection versus malignancy. An extensive infectious work-up continued to be negative, so an oncologic investigation was initiated, including PET scan and splenic biopsy. Ultimately, due to increasingly frequent febrile headaches, an MRI of

the head and sinuses was obtained revealing a large frontal epidural abscess as well as an associated left frontal subgaleal abscess, likely secondary to pan-sinusitis. Otolaryngology and neurosurgery drained and cultured the abscesses, revealing Group C streptococcus and *Prevotella buccae*, colonizers of the upper respiratory tract and oral cavity respectively. The patient was started on IV antibiotics and treated for 4–6 weeks. Complete resolution of the fever was achieved on post-operative day 5, the patient's headaches resolved, and inflammatory markers trended downward.

Fever of unknown origin is a challenging syndrome as by definition it has remained unexplained after baseline tests and examinations. Even as medical science and testing grows more sophisticated, the fundamental skills of conducting a physical exam and obtaining a thorough history often remain the key to discovering the underlying diagnosis. As in this case, new symptoms may appear or become more prominent, leading to the root source of fevers.

251 CORTICOSTEROID TREATMENT FOR PROLONGED FEVER IN HEPATOSPLENIC CAT-SCRATCH DISEASE: A CASE STUDY

A Phan, LA Castagnini. *Baylor College of Medicine, San Antonio, TX.*

10.1136/jim-2016-000393.251

Case Report Hepatosplenic cat-scratch disease (CSD) may cause prolonged fever. We present a 4 year old boy referred to the Infectious Diseases clinic with a 60-day history of daily fevers up to 103°F associated with malaise, loss of appetite and occasional abdominal pain. He also had left sided cervical lymphadenopathy a few weeks into his illness, for which he was seen at an emergency room where he was diagnosed with lymphadenitis by neck computerized tomography. He was prescribed amoxicillin for 10 days with no change. His social history was remarkable for a 10-week exposure to a new kitten. Physical exam was notable only for a left-sided submaxillary non-tender, firm and mobile lymph node of 1 cm diameter, without any overlying erythema or fluctuance. Further workup included *Bartonella henselae* antibody serum titers revealing IgG 1:1024, and IgM 1:128, consistent with CSD. Abdominal ultrasound (US) revealed multiple discrete low-echogenic round lesions throughout the liver. A 14-day course of sulfamethoxazole 12.5 mg/kg/dose-trimethoprim 2.5 mg/kg/dose twice a day and rifampin 7.5 mg/kg/dose twice a day was prescribed.

After 12 days of initial antibiotic course, the patient continued to have daily fevers, decreased appetite and fatigue. He was prescribed an additional 10 days of rifampin, and 10 days of azithromycin 5 mg/kg/day. After 24 days, the patient continued to have daily fevers. On day 86 of fever, repeat abdominal US revealed interval increase in size and number of liver lesions and multiple splenic hypoechoic lesions with minimal splenomegaly.

Given persistent fever for 94 days despite multiple antibiotic regimens, the patient was trialed on a tapered oral prednisolone course for 9 days, starting at 1 mg/kg/dose twice daily. On day 4 of steroids, there was complete deferescence. His appetite and energy level also returned to

normal. Six weeks after completion of therapy, the family reported no recurrence of symptoms. Our case illustrates the potential benefit of corticosteroids for pediatric patients with hepatosplenic CSD and prolonged fever. A trial of oral corticosteroids should be considered in patients with systemic involvement and prolonged fever secondary to CSD.

252 CAMPLYLOBACTER JEJUNI – A GREAT MIMICKER

C Pirtle, H Catherine, LS Engel, S Walvekar. *LSU Health Sciences Center, New Orleans, LA.*

10.1136/jim-2016-000393.252

Case Report A 46-year-old man with a history of Hepatitis C presented complaining of severe right sided abdominal pain and non-bloody vomiting for three days. He reported three weeks of subjective fever and chills and two weeks of liquid tan stools with mucus and small amount of red blood mixed in about five-six times a day. He denied recent antibiotics, camping, travel, sick contacts, or a history of abdominal surgeries. Of note, he owns five Pitbull dogs and a bearded dragon lizard. He had right lower quadrant abdominal pain with tenderness on exam and an elevated lactic acid. A Computed Tomography scan of his abdomen revealed mild dilated bowel loops with air fluid levels in the ileum and jejunum which was concerning for ileus versus a small bowel obstruction. Surgery recommended conservative management with fluids and bowel rest. The primary team empirically began antibiotics (Ciprofloxacin and Metronidazole) however by day three the patient did not have any symptomatic relief. Stools studies were positive for *Campylobacter jejuni* antigen, all other stool cultures were negative with negative blood cultures. He did not improve and Infectious Disease recommended switching to azithromycin. After 3 days significant improvement in symptoms was noted and was discharged thereafter.

Discussion *Campylobacter* is the most common bacterial cause of diarrheal illness. In 2012, the Foodborne Diseases Active Surveillance Network (FoodNet) estimated the incidence to be 14.3 cases per 100,000 population. Our patient had a classic but rarer presentation of pseudoappendicitis caused by *Campylobacter jejuni* infection with fever, vomiting, diarrhea, and abdominal pain in the right iliac fossa mimicking acute appendicitis. His history of Hepatitis C in the setting of pet food handling put him at a higher risk than the general population for *Campylobacter* infection. This case also demonstrates the importance of recognizing this bacteria's increasing resistance to fluoroquinolones. In 2014, the rate of resistance in the US was 20 to 27%. There is only a 5% resistance to macrolides to which this patient responded well.

253 A TRANSFUSION-ASSOCIATED CASE OF BABESIOSIS

R Washburn,^{1,2} M Ong,² D Nanchahal,² J Todd,² J Cotellingham,² H Rafeek^{1,2}. ¹Overton Brooks VA Medical Center, Shreveport, LA; ²LSU Health Sciences Center, Shreveport, LA.

10.1136/jim-2016-000393.253

Case Report A 28-year-old male was admitted with hemolytic anemia refractory to prednisone, rituximab and intravenous immunoglobulin. Past medical history included motor vehicle accident seven months before presentation, requiring splenectomy and multiple blood transfusions. There was no history of overseas travel. Significant exam findings included normal vital signs and the presence of icterus but no organomegaly or rash. Abnormal lab results included hemoglobin 6.9 mg/dL, MCV 132 fL, positive direct antiglobulin test, AST 107 U/mL, total bilirubin 6.5 mg/dL and positive anti-*Babesia* IgG 1:80. Peripheral blood smear showed multiple intracellular ring forms, consistent with babesiosis. Parasitic index was 10%.

Clinical course Immunosuppressive agents were discontinued and therapy was initiated with intravenous quinidine and oral clindamycin. When the parasitic index decreased to less than 1%, treatment was transitioned to oral atovaquone and azithromycin. After six weeks, parasitemia had completely resolved, and therapy was discontinued.

Discussion and Conclusion Babesiosis is a tick-borne illness that causes hemolytic anemia and is transmissible by blood transfusions. This case highlights the fact that careful peripheral blood smear examination is crucial for diagnosis and therapy.

254 UNIQUE COMPLICATIONS OF LEGIONELLA: WHY NOT CATCH 'EM ALL?

D Robbins, J Baxter, T Kazecki, B Mathew, LS Engel, D Janz. *LSU Health Sciences Center, New Orleans, LA.*

10.1136/jim-2016-000393.254

Case Report Case: A 27-year old African American man without previous medical history presented to the Emergency Department with altered mental status, GI symptoms and fever. One week prior, he was diagnosed with viral gastroenteritis and treated with supportive care. At the time of admission, he was febrile to 104.5 °F. Initial labs were significant for leukocytosis, AKI with creatinine to 2.05 mg/dL, hypokalemia, hyponatremia, and mild anemia; initial qSOFA and SOFA scores were 2 and 3, respectively. Chest roentgenogram was suggestive of right lower lobe pneumonia. Shortly after admit he developed acute hypoxic respiratory failure requiring intubation and subsequent severe ARDS. Urine antigen testing was positive for *Legionella* and he was treated with a 14-day course of levofloxacin. The patient was also diagnosed with rhabdomyolysis (CK of 47,628 U/L), acute kidney injury requiring continuous renal replacement therapy, and status epilepticus related to metabolic disturbances. His hospitalization was complicated by an ileus and subsequent GI bleed secondary to an NG tube that had ulcerated into his stomach. After a 3-week ICU stay, the patient was diagnosed with pancreatitis (lipase 1208 U/L) followed by a diagnosis of acalculous cholecystitis requiring cholecystostomy tube placement by IR. He was eventually discharged but required intense rehabilitation.

Discussion *Legionella* are aerobic, Gram-negative bacilli and infections with this organism have tripled within the past 15 years largely due to improved diagnosis, increased flooding and rainfall. The most common risk factors are

exposure to cigarette smoking, chronic lung disease and post-transplant patients, neither of which fit our patient profile. A Unique constellation of laboratory findings include: renal and hepatic dysfunction, hyponatremia, rhabdomyolysis, various rashes, pancreatitis, neuropathy, and glomerular disease. Other complications include: DIC, sinusitis, perirectal abscess, pyelonephritis and pericarditis/endocarditis. All patients suspected of having Legionaire's disease should have urinary antigen testing, and should be treated with levofloxacin or azithromycin.

255 A CASE OF NOT-SO-SPONTANEOUS, SPONTANEOUS BACTERIAL PERITONITIS

S Sanders, M Oglesbee, LS Engel, A Garcia. *LSU Health Sciences Center, New Orleans, LA.*

10.1136/jim-2016-000393.255

Case Report The diagnosis of spontaneous bacterial peritonitis (SBP) requires the exclusion of secondary causes of infection. The presence of a foreign body should be classified as secondary or iatrogenic, rather than spontaneous. In the cases of secondary or iatrogenic bacterial peritonitis, guideline coverage for SBP is often times inadequate.

Case A 36-year-old woman with history of metastatic ER +/PR+/HER2- invasive ductal carcinoma presented with abdominal pain and fever. Imaging studies revealed right breast mass, hepatic and pulmonary lesions and ascites. The patient was started on weekly carboplatin/ paclitaxel, as well as endocrine therapy with exemestane and leuprolide. Jaundice and abnormal liver function tests resolved after 4 weeks of treatment. A Jackson-Pratt drain was placed for intermittent peritoneal drainage. The patient had daily large volume ascites drained from the JP drain, but diagnosis of SBP necessitated drain removal and she was placed on prophylactic ciprofloxacin. Later, a tunneled peritoneal catheter was placed, but the patient re-presented with similar symptoms. Peritoneal fluid analysis revealed 218 polymorphonuclear leukocytes and she was started on cefoxitin for spontaneous bacterial peritonitis. Peritoneal culture grew an acid fast bacilli, group IV rapid grower. Her tunneled catheter was removed and she was empirically started on levofloxacin, azithromycin, and doxycycline. The ascitic culture resulted with *Mycobacterium abscessus* and the same rapid-grower was isolated from culture of the catheter tip. Repeat scans show marked improvement in liver and lung metastasis.

Discussion This case highlights a patient with an advanced chemo-sensitive cancer who achieved significant and durable response with chemotherapy but had a course complicated by iatrogenic bacterial peritonitis mistaken for SBP. Guideline antibiotic regimens for SBP are often inadequate to cover the infections encountered in iatrogenic bacterial peritonitis. Our patient's organism, *Mycobacterium abscessus*, belongs to the group of rapidly growing nontuberculous mycobacteria (NTM) that comprise a significant portion of skin and catheter-related infections. Treatment regimens are not well-established, but usually consist of multi-drug long-term antibiotics and catheter removal.

256 PNEUMOCYSTIC PNEUMONIA COMPLICATED BY BILATERAL PNEUMOTHORACES AND MALABSORPTION OF UNKNOWN ETIOLOGY

AJ Shah, W Javaid. *State University of New York Upstate Medical Center, Syracuse, NY.*

10.1136/jim-2016-000393.256

Case Report *Pneumocystis jirovecii* pneumonia (PCP) is the most common opportunistic respiratory infection in patients infected with AIDS. Since the advent of antiretroviral therapy, there has been a dramatic decrease in pneumocystis pneumonia from 29.9 per 1000 person years between 1994 to 1997 to 3.9 per 1000 person years between 2003 to 2007. We present an unusual case of a patient with recurrent PCP infection who developed a 1970s presentation of PCP with multiple pneumothoraces. **Case** 49 year old male with past medical history of AIDS presented to the emergency department with respiratory failure, productive cough, fevers, chills, and night sweats secondary to pneumonia. Patient had a history of multiple pneumocystic pneumonias in the past 16 months, totally 7 admissions. Patient was initially diagnosed with HIV in 2007 with an initial CD4 count of 23 when he presented with weight loss, diarrhea, and rash. Of note, patient had multiple bi-directional endoscopies with normal biopsies and negative infectious work-up over previous 16 months and has had multiple prior genotypes/phenotypes that have not shown any evidence of resistance to anti-retrovirals.

While on IV Bactrim and prednisone taper of 21 days, patient developed sudden shortness of breath and chest pain. Patient developed a right sided pneumothorax that required two right sided chest tubes for re-expansion. However, days later, patient developed left sided apical pneumothorax that did not require a chest tube. Later in his admission, patient underwent VATS procedure (pleurodesis) to fix his pneumothorax as it was not improving with chest tubes.

Discussion This is a classic presentation in the 1970s but with the advent of prophylaxis and antiretroviral therapy, these presentations are rare. There have been only three reported case series of patients with pneumothoraces in HIV infected patients. Of these presentations, many undergo VATS procedure as did our patient. The pleurodesis helped resolve the pneumothorax. Of note, mortality rate of these patients is 31% compared to 6% in those who don't have pneumothorax.

257 SEVERE CASE OF PYODERMA GANGRENOSUM WITH UNDERLYING PSEUDOMONAL INFECTION

AJ Shah, U Masood, F Ramsey. *State University of New York Upstate Medical Center, Syracuse, NY.*

10.1136/jim-2016-000393.257

Case Report Pyoderma Gangrenosum (PG) is a rare neutrophilic dermatosis that presents as an inflammatory and ulcerative disorder of the skin. The incidence of PG is 3 to 10 cases per million people per year. It more commonly

occurs in women with an average age onset between 40 and 60 years. More than half of the patients have an associated underlying systemic disease such as inflammatory bowel disease. We present a case of a male with severe PG of the lower extremity without any associated systemic illness.

Our patient is a 63 year old male with a past medical history significant for hypertension and anemia who presented to the ED after having a low blood pressure and diaphoresis at his PCP's office. His vitals on admission were only significant for a low grade fever. On physical exam, the patient had a 16×18 cm lower extremity wound on right lower extremity medial to ankle and two smaller ulcers on his inner thigh of his right leg measuring 8×10 cm and 1.5×1 cm, with pus like discharge beneath necrotic tissue. It was discovered that patient's wounds were a progression of a simple wound due to multiple surgical debridement of the involved tissue by his outpatient wound care. During the hospital course, extensive work up to rule out autoimmune, inflammatory and hematological etiologies was found to be negative. As the patient was suspected to have an underlying infection due to the fever, a wound culture performed on admission yielded *Pseudomonas Aeurogenosa*. He was treated with surgical debridement, course of IV Ceftazidime per wound culture sensitivities, steroids, and dapsone. Despite these interventions, patient's wound continued to worsen in size. He was discharged with IV antibiotics and steroid course. Upon follow up, patient continued to have extensive, enlarging PG with persistent pseudomonas infection.

Pyoderma gangrenosum is a disease that is not very well understood. What makes our case interesting is the idiopathic etiology, worsening of the wound, and persistent infection despite a commonly practiced mode of debridement for necrotic skin infections. The outcome was less than favorable as the choice of debridement of necrotic tissue in order to alleviate the pseudomonal infection led to worsening of the PG. This phenomenon can be explained by pathergy.

258 RHINO-ORBITAL MUCORMYCOSIS PRESENTING IN A DIABETIC PATIENT WITH DIABETIC KETOACIDOSIS

Shah Stuart, Richardson Aaron, Baidoun Firas, Isache Carmen, G Jeffrey, DO House, Parmar Kamalpreet, Gopinath Arun. *University of Florida College of Medicine Jacksonville*

10.1136/jim-2016-000393.258

Case Report Rhino-Orbital Mucormycosis (ROM) is a rare, aggressive and invasive fungal infection that commonly involves the paranasal sinuses but can include the eyes, brain, skin and lungs. It has an overall prevalence 0.15% in diabetics with an increased incidence in persons whose diabetes is poorly controlled. It can also be seen in the immunosuppressed as well. Mortality rate is noted to be as high as 50% even in patients who receive proper antifungal treatment depending on the extent of involvement.

The patient is a 53-year-old female with past medical history significant for hypertension, diabetes mellitus type 2, chronic obstructive pulmonary disease, anemia and right above knee amputation who presents with complaints of

headache, nausea, right facial numbness and right eye blurry vision. Blood pressure was 201/88 and physical exam notable for right sided facial swelling with decreased sensation of the right maxilla and chin. Initial laboratory studies were significant for leukocytosis, hyperglycemia, high anion gap metabolic acidosis and acute kidney injury. The patient was admitted for hypertensive emergency and diabetic ketoacidosis. Initial Computer tomography (CT) of the sinuses showed paranasal sinus disease and Otolaryngology was consulted. Follow up CT of the maxillofacial skeleton, paranasal sinuses, orbits, skull base and portions of the temporal bones showed invasive fungal sinusitis of the right orbit. The patient underwent immediate debridement and pathology specimens obtained showed fungal hyphae invading the mucosa and blood vessels. Infectious Disease was consulted and the patient was started on Lipophilic Amphotericin B and Caspofungin with improvement in her symptoms.

ROM presenting symptoms include facial swelling and discomfort, fever, nasal congestion, vision loss, headaches and ophthalmoplegia. Due to the aggressive nature and high mortality rate of this disease it is imperative that in the setting of high clinical suspicion early detection, surgical excision and debridement along with proper antifungal therapy occur in a timely manner as this is essential for survival of this deadly infection.

259 METHICILLIN RESISTANT STAPHYLOCOCCUS AUREUS BACTEREMIA LEADING TO EMPYEMA NECESSITANS AND PERINEPHRIC ABSCESS IN A DIABETIC WITH LINGERING HEEL ULCER

S Siddiqui, JA Groot, JW Turner, J Abbey, A Omer. *Texas Tech University Health Sciences Center-Amarillo, Amarillo, TX.*

10.1136/jim-2016-000393.259

Case Report A 57 year-old male with a past medical history of hypertension and diabetes mellitus presented to the emergency department with a chronic right heel ulcer, and new onset right chest wall swelling. Prior cultures of the ulcer grew MRSA. On admission, vitals revealed tachycardia with HR 110, low grade fever of 99.6 and mild hypoxia with saturation 91% on room air, BP was in normal limits. There was active foul smelling purulent drainage from the heel ulcer. A soft, non-erythematous, fluctuant, 10x10 cm mass was noted on the right chest. Otherwise all other physical exam findings were normal. Diagnostic data showed a WBC count of 17.3, creatinine 1.4, and glucose 569. MRI of the right foot displayed diffuse soft tissue swelling around the heel. CT thorax revealed a cavitary lesion in the right upper lung lobe expanding through the anterior chest wall into the pectoralis musculature with regions of gas, and in the abdomen a complex subcapsular fluid collection was detected adjacent to the left kidney. Cultures of the blood, urine, and heel wound grew MRSA. The patient clinically improved subsequent to combination therapy with daptomycin and surgical intervention.

Discussion Empyema necessitans is a rare complication in which an empyema crosses the parietal pleura into the chest wall forming a subcutaneous abscess. Most reported

cases are related to *Mycobacterium tuberculosis*, *Actinomyces* or *Streptococcus* species. Only a few cases due to MRSA have been reported. Perinephric abscess can also occur through local or hematogenous spread. We report an unusual case of MRSA bacteremia from a chronic heel ulcer leading to empyema necessitans and a perinephric abscess. Though presentation in empyema necessitans often includes symptoms such as pleuritic pain, cough and an enlarging chest mass, it can also be asymptomatic. Our patient expressed no pulmonary complaints, and his chest mass was as an incidental finding on examination for evaluation of his heel ulcer. With the increasing prevalence of diabetes, our case should prompt physicians to consider empyema necessitans, in their differential for patients with a diabetic foot ulcer and MRSA bacteremia.

260 JAW-DROPPING NEUROSYPHILIS

D Smith, V Serven, LS Engel. *LSU Health Sciences Center, New Orleans, LA.*

10.1136/jim-2016-000393.260

Case Report Introduction: Neurosyphilis can present with a wide variety of non-specific neurological symptoms which can be difficult to detect in patients with previous neurological deficits. Here we present a case of man with a history of stroke who presented with acute neurological deficits and was later diagnosed with neurosyphilis.

Case A 73 year old man with a history of stroke with unknown baseline deficits presented with a complaint of being unable to close his mouth, speak, or swallow. Neurological examination revealed an acute inability to protrude the tongue, a diminished gag reflex, and a chronic left lateral gaze palsy. The patient's other cranial nerves were intact including a symmetrical face and intact facial sensation. Further neurological exam revealed left sided upper and lower extremity weakness that the patient asserts were residual from his previous stroke. No other abnormalities were noted. Initial CT was negative for hemorrhage, and an MRI was unable to be obtained secondary to the patient's pacemaker. A pharyngeal endoscopy showed no mechanical reason for the patient's deficits. He was empirically started on vancomycin, ceftriaxone, and ampicillin. The patient's diagnosis was unclear until an RPR ordered two days after presentation resulted reactive, and a subsequent VDRL resulted 1:2. The diagnosis of neurosyphilis was made with a positive CSF VDRL. The patient had no previous record treatment for syphilis, and he denied having risky behaviors in the past. By the end of his 2nd week of penicillin therapy, the patient had improvement in his symptoms, and he was able to close his mouth for a few seconds at a time.

Discussion Cranial nerve deficits are one of the many non-specific symptoms that can occur with neurosyphilis. Here we present a case with unusual findings made vaguer by the patient's inability to communicate and previous history of stroke. The case also highlights the importance of syphilis screening with RPR in patients with unexplained neurologic deficits.

261 TUBERCULOUS MENINGITIS: EARLY IDENTIFICATION PIVOTAL FOR SURVIVAL

AL Torres. *San Juan City Hospital, Carolina, PR.*

10.1136/jim-2016-000393.261

Case Report Tuberculous Meningitis (TBM) is an uncommon yet a highly devastating manifestation of tuberculosis. It accounts for approximately 1% of all cases of TB and carries a high mortality and distressing level of neurological morbidity. Due to its relative rarity, TBM remains a formidable diagnostic challenge.

A 38 year old male with history of HIV, on antiretroviral therapy for three months, was brought to the Urgency Room with complaints of altered mental status. For the past month patient had been complaining of fever, chills, night sweats with associated headaches, myalgias, and forgetfulness. Initial evaluation remarkable for an agitated, partially oriented male with no evident neurologic deficit or nuchal rigidity; responded to simple verbal commands and cranial nerves were intact. Forty-eight hours after hospital admission, patient's clinical status deteriorated, developing right-sided hemiparesis and respiratory distress requiring endotracheal intubation for mechanical ventilation. Laboratory work-up remarkable for serum sodium level of 124, cerebrospinal Fluid (CSF) analysis yielding elevated protein and white blood count, low glucose, and negative cryptococcal antigen and acid fast bacilli; VDRL reactive and toxoplasma IgG Anti body positive. CXR with no evidence of infiltrates or cavitations. Brain MRI positive for leptomeningeal enhancement along the posterior fossa and bilateral occipital lobes. In addition, a subtle cortical enhancement along the right temporal occipital region, as well as a focus of received diffusion along the medial aspect of the left deep gray matter nuclei observed. Based on neuroimaging and results of CSF the decision to start a four drug regimen, in addition to corticosteroids for tuberculosis was made. Subsequently the diagnosis of TBM was confirmed with three positive acid fast bacilli sputum culture. After a month and a half of in patient treatment, patient was successfully discharged home on antituberculous drugs and extensive physical rehabilitation.

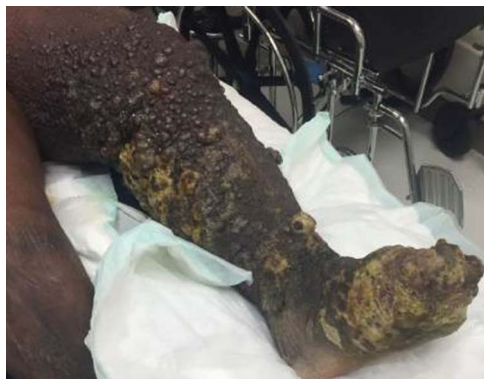This case illustrates that high degree of suspicion must be maintained since, the diagnosis of TBM can be challenging. In such cases neuroimaging and CSF collection can aid in early diagnosis. Empiric therapy should be initiated as early as possible, if suspected, in order to reduce morbidity and mortality.

262 KS IN MS

E Turse, K Pippin, RA Williams, SM LeTellier, Z Henson, JB Brock, R Webb. *University of Mississippi Medical Center, Jackson, MS.*

10.1136/jim-2016-000393.262

Case Report 39-year-old black female with acquired immunodeficiency syndrome (AIDS), non-compliant with antiretroviral therapy (ART), presented with 6 months of



Abstract 262 Figure 1

left leg lymphedema with progressive nodules and lichenification despite empiric treatments for cellulitis. No history of sex, travel, or drug use. Left lower extremity was edematous with large nodules, maceration and necrosis. Closer evaluation revealed maggots in the toe webbing and plantar surface. She was initiated on broad-spectrum antibiotics. Punch biopsy from an outside hospital was consistent with Kaposi Sarcoma (KS), with immunoreactivity for human herpesvirus 8 (HHV8). Due to superimposed infection, she completed a course of antibiotics prior to consideration of chemotherapy. She was also started on ART, *Mycobacterium* and *Pneumocystis* prophylaxis but refused chemotherapy. With worsening necrosis, she was readmitted for antibiotics and debridement. Core needle biopsy of her left groin lymph nodes, thigh, tibia, and foot were consistent with KS. Given the extent of disease and clinical decline she was put on hospice and died from metastatic KS.

KS is the most common AIDS-associated neoplasm caused by HHV8. KS-AIDS is seen almost exclusively in men who have sex with men (MSM). The annual incidence of KS has declined over the last few decades to 2–6 per 10,000 in the US population. This patient's presentation is unique. There is a 10–15:1 ratio between MSM and women with KS and KS is rare in American Blacks. Lastly, patients with KS-AIDS usually die from associated opportunistic infections or gastrointestinal KS, not from metastatic KS.

263 A DELAYED RECOGNITION OF DISSEMINATED SALMONELLA ENTERICA INFECTION

M Varghese,¹ S Baer,^{2,1} A Poursina,¹ R Colombo¹. ¹Augusta University Medical Center, Augusta, GA; ²Augusta VA, Augusta, GA.

10.1136/jim-2016-000393.263

Case Report *Salmonella enterica* species are a rare cause of osteomyelitis in humans. We present the case of a 71 year old man with delayed recognition of disseminated *Salmonella enterica* infection. The patient initially presented to a local community hospital with 1 week history of abdominal pain and fevers. He had no dysuria, nausea, or vomiting. Urine cultures were obtained which showed gram negative rods and he was discharged home the next day after intravenous fluids. He did not get any outpatient

antibiotics. Urine culture finalized as *Salmonella enterica* species after discharge. He returned to the same hospital 4 days later with fevers and persistent abdominal pain. Blood cultures were positive for *Salmonella* species; he was sent home 2 days later with unknown oral antibiotics. The patient presented again 4 days later with lower extremity weakness and severe back pain. He was found to have L2-L3 discitis-osteomyelitis, epidural abscess, and psoas abscess; he was transferred to a tertiary academic medical center for neurosurgical evaluation. Psoas abscess cultures grew *Salmonella enterica* species. Blood cultures obtained during latter admission remained negative. He was discharged home on IV ceftriaxone to which the organism was susceptible *in vitro*. He was readmitted 2 weeks later with fevers and hypotension. Workup revealed persistent L2-L3 discitis-osteomyelitis, epidural abscess, and a new prostate abscess. No new organisms were identified. Sub-speciation of the *Salmonella enterica*, as well as investigation for a possible occult immune defect contributing to the infection severity, is underway. This case illustrates a delayed diagnosis of *Salmonella* bacteremia with subsequent complications that has been refractory to appropriate therapy. It highlights the importance of early recognition of the positive cultures for unexpected or uncommon pathogens, especially when from a sterile site, to avoid additional morbidity for patients.

264 A TALE OF TWO STAPHYS: MRSA AND MSSA BACTEREMIA

S Werner, LS Engel. LSU Health Sciences Center, New Orleans, LA.

10.1136/jim-2016-000393.264

Case Report Introduction: Staphylococcus Aureus skin infections are common in intravenous drug users (IVDU), which can lead to more serious infections like bacteremia.

Case A 36 year old man with a history of bipolar disorder and IVDU presented with 5 days of pleuritic left sided chest pain, and left arm swelling. The reported that he had a negative Computed tomography - PE study at an outside facility the day his symptoms started. He admitted to subjective fever, chills, nausea and shortness of breath, but denied vomiting, abdominal pain and sick contacts. He admitted to cocaine use 12 hours prior to arrival. The patient's temperature was 101.2 oF, heart rate was 126 beats/min, blood pressure was 153/82 and respiratory rate was 22 per minute. He had regular heart rate, without murmurs or rubs. Lungs were clear to auscultation, though his left chest wall was tender with palpation. His left arm was erythematous and swollen proximal to the antecubital region without fluctuance noted. Laboratory studies showed a white blood cell count of 11,400 cells/ul, with 21% bandemia. Troponin and EKG findings were unremarkable. Chest X-ray was without focal infiltrate or atelectasis. Repeat CT-PE study demonstrated multiple nodules throughout both lung fields concerning for septic emboli. Blood cultures grew methicillin-resistant Staphylococcus Aureus (MRSA) and methicillin-sensitive Staphylococcus Aureus (MSSA). An ultrasound of the left arm revealed an abscess and linear foreign body, which was explored with incision and drainage. Cultures from the abscess grew both

MRSA and MSSA. There was no evidence of endocarditis on echocardiogram. Our infectious disease consultant recommended treatment with intravenous Oxacillin and Vancomycin for 4–6 weeks. The patient was transferred to long term acute care facility for antibiotic therapy.

Discussion IVDU are at risk for skin infections and other complications. Staphylococcus Aureus infections are common in this population, though infection with multiple strains is rare. Patients with septic emboli and possible infective endocarditis should be treated with 4–6 weeks of antibiotic therapy.

265 A CRAWLING FUNGUS: CANDIDA IN UNEXPECTED PLACES

V Zayas, S Giles, J Matos, I Ortiz, E Acosta, G Gonzalez. VA Caribbean Healthcare System, Bayamon, PR.

10.1136/jim-2016-000393.265

Case Report *Candida spp.* is a yeast-like fungus that is abundant in nature. *Candida* infective endocarditis (CIE) accounts for only 1 to 2% of all cases of infective endocarditis (IE). From 1996–2003 there was a threefold increase in the number of hospitalizations associated with cardiac device infections.

A 60-year-old male with past medical history of Diabetes mellitus type 2, Hypertension, Chronic Kidney Disease stage IV, Coronary Artery Disease and Congestive Heart Failure, status post Cardiac Resynchronization Therapy Device placement presented with progressive edema and shortness of breath. He was admitted to Internal Medicine ward for further management, where he developed fever, tachycardia and dyspnea. Blood cultures grew yeast, so he was started on Fluconazole. Subsequent blood cultures continued to grow yeast, which revealed *Candida tropicalis*. Given persistence of Candidemia, Fluconazole was discontinued and Micafungin was begun. A transesophageal revealed a large echogenic lesion attached to the right atrial pacemaker wire, prolapsing into the right ventricle during diastole. Ophthalmology service evaluated patient and stated that no evidence of fungal retinopathy was observed. Still, the patient continued with candidemia, so Micafungin was discontinued and he was started on high dose Caspofungin. After antifungal was adjusted, blood cultures came back negative for fungal or bacterial organisms. Patient was not considered a candidate for surgery due to multiple comorbidities that were mentioned above.

Endocarditis by *Candida spp.* associated with implantable cardiac devices has been described very little in literature due to the fact that, before the discovery of antifungals, all patients died and *Candida* endocarditis was diagnosed post mortem. This case is of clinical significance because the patient presented with clinical picture of acutely decompensated heart failure, which was falsely attributed to two common causes, medication/diet non-compliance, when in fact, it was the CIE that decompensated the CHF. To our knowledge, this is the 20th case

described in literature that *Candida spp.* has infected an implanted cardiac device and 3rd case due to *Candida tropicalis*.

Medical Education, Medical Ethics, and Advocacy Joint Plenary Poster Session and Reception 4:30 PM Saturday, February 11, 2017

266 IDENTIFICATION OF LEARNING GAPS IN THE TREATMENT OF CHILDREN WITH AUTISM SPECTRUM DISORDER WHO PRESENT WITH ACUTE ILLNESSES

KP Austriaco, M Kong. University of Alabama at Birmingham, Birmingham, AL.

10.1136/jim-2016-000393.266

Purpose of Study Autism spectrum disorder (ASD) is a developmental disorder that is characterized by deficits in communication, difficulties in social situations, and repetitive motions. Because of this characteristic triad commonly associated with ASD, it can make it difficult for health care professionals to assess or treat a child who presents to the clinic or emergency room with an acute illness. The primary aim of this study was to find learning gaps that were present between medical students, pediatric interns, residents, and fellows through the use of an online survey platform.

Methods Used A 23 question survey was utilized and dispersed to medical students, pediatric residents, interns, and fellows who are currently receiving training at the University of Alabama at Birmingham, AL. Questions included frequency of interaction between participants and children with ASD, their perceived baseline knowledge of ASD and sensory regulation, and the format that they believe would be best to learn about children with ASD.

Summary of Results Results show that as the education level increases, the likelihood of encountering a child in a clinical setting increases and those with higher educational levels have at least some knowledge of ASD. However, even at higher levels of training, responses show that pediatric interns, residents, and fellows felt inadequately educated, and were unfamiliar with sensory dysregulation that may be present with children with ASD. Most students across all educational levels felt that they should have more training and education regarding ASD children, especially when they present with an acute illness.

Conclusions The findings of this survey suggest that medical students across all training levels perceived a lack of knowledge regarding ASD and the associated issues with sensory regulation. Even at the highest level of pediatric training, fellows similarly reported a perceived lack of knowledge. Most of the trainees reported the need for increased education and training in relation to communication during treatment of children with ASD in general, as well as when they present with an acute illness.

Neurology and Neurobiology Joint Plenary Poster Session and Reception 4:30 PM Saturday, February 11, 2017

267 LOCKED IN SYNDROME: AN UNFORTUNATE ISCHEMIC EVENT

H Catherine, H Chau, LS Engel, J Amoss. *LSU Health Sciences Center, New Orleans, LA.*

10.1136/jim-2016-000393.267

Case Report A 69 year old man with past medical history of acute vertebrobasilar stroke six months prior requiring angiogram with stent placement, paroxysmal atrial fibrillation, and hypertension presented to the emergency department after being found unresponsive in bed. Upon arrival to the ED, patient had a GCS score of 3 and was intubated. He had a 50 pack-year smoking history. His medication regimen included clopidogrel 75 mg daily, hydrochlorothiazide 12.5 mg daily, warfarin 5 mg daily, diltiazem 240 mg daily, amiodarone 200 mg daily and pravastatin 40 mg daily. The rest of his history was non-contributory. His temperature was 99.9 degrees Fahrenheit and he was tachycardic with a systolic blood pressure in the 140s. He was unresponsive to painful stimuli. There was no trauma noted. Pupils were 3 mm and equal with sluggish response to light. Exam was otherwise unremarkable. Magnetic resonance imaging and angiography showed a bilateral pontine infarct with vertebral artery occlusion. Over the next three days, he was able to communicate by blinking his eyes and was diagnosed with locked-in syndrome. At the time of discharge he had control of vertical eye gaze, eye opening, and slight movement of the right toes.

Discussion This is a rare case of cerebrovascular accident in the brainstem causing near complete paralysis and inability to speak with retained consciousness and sensation. It is termed locked in syndrome (LIS) and results from bilateral brainstem lesions with the most common being in the ventral pons. Due to sparing of the supranuclear ocular motor pathways, blinking and eye movements commonly remain intact. While some will regain some minor motor function over time, most have a poor prognosis. Early revascularization is optimal when possible.

268 AN UNUSUAL CASE OF ENCEPHALOPATHY

R Dhoot, K Pabba, R Razi, RD Smalligan, K Cutts. *Texas Tech Univ HSC Amarillo, Amarillo, TX.*

10.1136/jim-2016-000393.268

Case Report A 57 y/o woman with a past medical history of heavy alcohol abuse presented to the ER with altered mental status and possible seizure activity. She had been discharged one week prior after improving from confusion secondary to beer potomania and a prolonged postictal state. On this admission, she had many features initially suggestive of a persistent vegetative state. She showed some slight improvement but was still unaware of her

surroundings, had a waxing and waning sensorium, did not follow commands and babbled fluent but nonsensical speech. The most striking feature of her neurologic exam was episodic left sided myoclonic jerks. HEENT, cardiac, lung, abdomen and skin findings were normal. EEG showed encephalopathy with generalized diffuse slow waves but no evidence of epileptic activity. MRI showed no signs of ischemia, hemorrhage or edema suggestive of viral encephalitis. LP and CSF cultures were negative. Serum IgG and IgM for West Nile and HIV and NMDA antibody were negative. There was no acute improvement in mental status or myoclonus after trials of thiamine, phenytoin, levetiracetam, valproate, or a 24 hour burst suppression coma. She was discharged to a longterm care facility with lorazepam, valproate, and pregabalin. Subsequent follow-up months later showed complete resolution of myoclonus and the patient was speaking short sentences though not carrying on intelligent conversation. She still required total care and feedings through a g-tube.

Discussion This patient's presentation illustrates a case of Lance Adams Syndrome (LAS) initially masquerading as alcohol withdrawal seizures. Though some element of irreversible Wernicke's encephalopathy may be present making this case a multi-factorial encephalopathy, it did not completely explain this patient's range of symptoms, especially her persistent myoclonus. Clinically, patients with LAS demonstrate, intention tremor, dysmetria, dysarthria, ataxia and generalized myoclonus. Purkinje cells in the cerebellum are particularly susceptible to hypoxic insults. LAS is also thought to be related to loss of serotonin in the inferior olive nucleus and deregulation of GABA's action in suppressing post-hypoxic myoclonus. LAS can be improved with early treatment, with 50% of patients respond to clonazepam, sodium valproate, and piracetam.

269 CEREBRAL VENOUS THROMBOSIS

J Doan, LS Engel. *LSU Health Sciences Center, New Orleans, LA.*

10.1136/jim-2016-000393.269

Case Report Introduction: Cerebral venous thrombosis is a rare, but serious condition and may be seen by internists due to its variable presentation.

Case A previously healthy 34 year old woman presented to the Emergency Department due to sudden onset aphasia. She was experiencing significant stress the week prior and took clonazepam for anxiety the night before presentation. She went to bed that evening without any symptoms, but awoke the next morning with new onset expressive aphasia. She had been taking oral contraceptives and had never smoked tobacco. There was no family history of stroke, thrombosis, or malignancy. On physical exam, she had severe expressive aphasia. The neurological exam was limited as she could only follow simple commands. Otherwise, there were no other focal neurological deficits. A stat Computed tomography (CT) scan of her head revealed multiple parenchymal hemorrhages, the largest involving the right frontal and left parietal lobe as well as gray/white hemorrhages. Neurosurgery was consulted; emergent cerebral angiography revealed a superior sagittal sinus thrombosis. She was started on intravenous heparin

and 3% saline for increased cerebral edema seen on repeat imaging. The following day of her hospitalization, she experienced seizure-like activity and was started on levetiracetam. An EEG showed possible epileptiform activity in the right parietal region. She had another seizure a few days later and was started on lacosamide. Stat CT of the head was largely unchanged and repeat EEG showed resolution of epileptiform activity. She was bridged to warfarin and later switched to apixaban. Hypercoagulable studies, including APLS, anti-cardiolipin, Jak2 V617F, prothrombin III, factor V Leiden, protein C and S, and G20210A were all negative. Due to her negative hypercoagulable workup, her thrombosis was thought to be due to use of oral contraceptives. She was discharged to inpatient rehab with gradual improvement of speech near baseline.

Discussion Cerebral venous thrombosis is associated with hypercoagulable states, including oral contraceptives, malignancy, and pregnancy. The main treatment is anticoagulation. This form of thrombosis is rare, but associated with good outcomes.

270 WHY DO I ASPIRATE? A UNIQUE CASE OF AMYOTROPHIC LATERAL SCLEROSIS

ES Josan, T Bhandari, A Mahajan, S Bhogal. *East Tennessee State University, Johnson City, TN.*

10.1136/jim-2016-000393.270

Introduction Amyotrophic lateral sclerosis (ALS) is a degenerative disease that affects both upper & lower motor neurons. It causes motor as well as fronto-temporal dysfunction, dysphagia & ultimately death. We present a case of a patient who was being treated for recurrent episode of aspiration pneumonia which was secondary to evolving ALS

Case Description A 67 year old male with history of dysphagia was being admitted with recurrent episodes of bilateral aspiration pneumonia. Over a course of 5 months, he had developed progressive dyspnea limiting his daily activities. Neurological exam revealed grade 3/5 muscular weakness & uniformly brisk reflexes in all extremities. Sensory, coordination, bladder & bowel function were intact. Cranial nerve exam were grossly normal except tongue fasciculation & partial dysphonia. Spirometry showed mixed obstructive & restrictive pattern. Other etiologies of motor involvement such as structural defects of brain/spine, B12 deficiency, paraneoplastic syndrome, myasthenia gravis, Lambert-eaten syndrome & endocrinal dysfunction were ruled out systematically. Nerve conduction studies revealed reduced compound muscle action potentials in the upper & lower limb. There were no evident post-exercise facilitations & conduction block or dispersion. Sensory nerve action potential amplitudes were preserved. He met the El Escorial criteria for ALS. Riluzole therapy was initiated & he was symptomatically managed for dysphagia which halted symptom progression.

Discussion ALS is an important differential for respiratory failure in setting of motor dysfunction. Recurrent idiopathic aspiration pneumonia should trigger neurological

evaluation. Bulbar & muscular system pathology leads to dysphagia which results in aspiration & malnutrition. Respiratory failure is common & accounts for significant morbidity & mortality (about 73%) with median survival time from symptom onset to death in 3–5 years. Early recognition with quantification of risk for aspiration & appropriate intervention is essential to improve quality of life. Serial pulmonary function testing & noninvasive ventilator support can be used for monitoring as well as management. Aspiration precautions also help to reduce the incident rate.

271 CHECK MY EYES TO MAKE THE DIAGNOSIS: A CASE OF STEELE RICHARDSON OLSZEWSKI SYNDROME

SE Koshy, R Bharadwaj, RD Smalligan. *Texas Tech Univ HSC-Amarillo, Amarillo, TX.*

10.1136/jim-2016-000393.271

Case Report An 84-year-old man presented with inability to look up or down. For several years, he had been slowly deteriorating, experiencing slurred speech, difficulty focusing, memory loss, a shuffling gait, and falls. He was also more emotional with laughing and crying episodes. Neurological exam revealed a central preference of gaze bilaterally with very limited vertical eye movements but good lateral eye movements and other cranial nerves intact. He had a masklike facies, slow speech, a festinating gait but no tremors and otherwise nonfocal exam. MRI of the brain showed generalized atrophy. Supranuclear palsy was diagnosed in consultation with neurology. Trials of carbidopa-levodopa and transdermal rotigotine failed to produce any significant improvement and the patient progressed over a few months to require total care.

Discussion Progressive supranuclear palsy (PSP), also known as Steele Richardson Olszewski syndrome, is an uncommon, atypical parkinsonian disorder which occurs in approximately 6 per 100,000 population. Gait disturbance resulting in falls is the most common initial feature. The hallmark of PSP is supranuclear ophthalmoparesis or plegia, but it can take as long as 10 years to develop. Other clinical features include pseudobulbar palsy and frontal cognitive abnormalities. Possible late stage manifestations are swallowing difficulties, complete ophthalmoplegia, and immobility. PSP is often confused with Parkinson's Disease. However, in PSP patients, a resting 'pill rolling' tremor is rare, rigidity is usually more pronounced in the neck than the limbs, unsteady gait appears earlier in the course, and there is minimal response to levodopa. Our patient did not have the typical PSP MRI finding of midbrain atrophy; however, the diagnosis of PSP is currently based on clinical features. Although it generally has a poor prognosis, a multidisciplinary approach including speech therapy, occupational therapy, and physical therapy is recommended. Our patient eventually required home hospice care. This case illustrates the importance of diagnosing PSP in distinction to Parkinson's since it allows the patient and family to receive more accurate advice regarding the prognosis and palliative treatment options.

272 JUST A PUFF OF SMOKE

A Leonard, LS Engel. *LSU Health Sciences Center, New Orleans, LA.*

10.1136/jim-2016-000393.272

Case Report A 44 year old woman with a history of stroke s/p aneurysm clipping, seizure, and substance abuse was brought to the hospital after a family member received a call from her friend saying she was acting unusual and may have had a seizure. At her baseline, she needed modest assistance in daily activities after her CVA and conversed without issue. Her mother died of a stroke. On exam the patient was afebrile, normotensive with mild tachycardia to 110. The patient moved all her extremities but was lethargic, agitated, responded to pain, did not follow commands and moaned nonsensical speech. Labs were unrevealing with mild leukocytosis (WBC: $11.7 \times 10^9/L$), normal metabolic panel, ammonia, glucose, and a negative urine toxicology. Initial computed tomography (CT) of her head demonstrated atrophy with large area of encephalomalacia in Left middle cerebral artery (MCA) area. Repeat CT, 1 day later showed edema and sulcal effacement in the right occipital, posterior, temporal, and posterior parietal lobes with evolving infarct in right posterior cerebral artery (PCA) and right MCA territories. CT angiogram showed occlusion of the clinoid segments of both internal carotid arteries, consistent with Moyamoya pattern of collateral flow. Neurosurgery was consulted and recommended cerebral bypass. The patient was unable to consent for surgery and her family refused surgery. The patient received supportive therapy with minimal improvements. She was accepted to inpatient stroke rehab upon discharge.

Discussion Moyamoya disease is a rare vascular condition which leads to progressive stenosis of the internal carotid arteries through wall thickening of the associated arteries which leads to progressive strokes and the development of collateral vessels. Moyamoya is a Japanese term for a 'puff of smoke' which describes the appearance on imaging of the small collateral vessels that develop around the progressively blocked arteries. There is a hereditary association and our patient's mother likely had the disease as well. The prognosis is poor and the disease will lead to a cognitive decline with associated CVAs. Treatment includes cerebral revascularization or bypass. The case highlights the need for early diagnosis, as our patient was too debilitated to make medical decisions for treatment at the time of her diagnosis.

273 NEW ONSET IDIOPATHIC GENERALIZED EPILEPSY INDUCED BY PHOTIC STIMULATION DIAGNOSED IN A 66 YEAR OLD FEMALE

O Moore, I Farooqui, S Krishnaiengar. *UF Health Jacksonville, Jacksonville, FL.*

10.1136/jim-2016-000393.273

Case Report Idiopathic generalized epilepsy (IGE) is a well documented seizure subtype presenting clinically as an absence, myoclonic, or generalized tonic-clonic seizure event. Electroencephalography characteristically reveals patterns of diffuse, bilateral synchronous neuronal electrical

discharges. Most commonly described in child and adolescent patients, the recognition of a possible adult onset variant is beginning to gain recognition. A current literature review found 23 such adult onset IGE cases presenting after the age of 40. Here we present a case of new onset IGE in a 66 year old female with electrographic general spike and wave discharges induced by 14Hz photic strobe stimulation. The patient had no prior history of staring or seizure-like events, and no active intoxication or substance abuse withdrawal. The contributing factor of urinary tract infection with mild leukocytosis did exist.

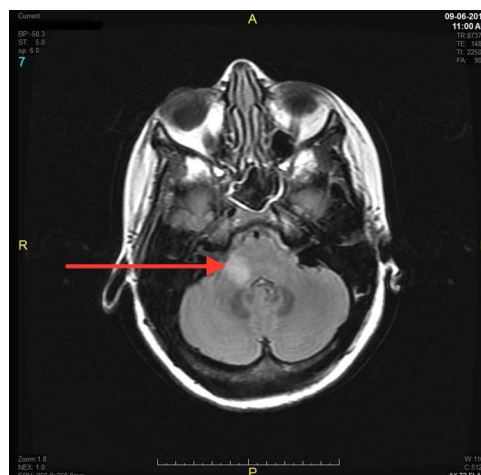274 SUBSTANCE ABUSE INDUCED CNS DEMYELINATION OR MULTIPLE SCLEROSIS?: A DIAGNOSTIC DILEMMA

K Opoku, JW Turner, C Prasad, M Malik, RD Smalligan, R Chandra. *Texas Tech Univ HSC Amarillo, Amarillo, TX.*

10.1136/jim-2016-000393.274

Case Report A 23-year-old lady with no PMH other than methamphetamine and marijuana abuse came with sudden onset of right facial paresthesias, impaired right hearing and unsteady gait for a week prior to admission. On exam, vitals stable, no fever. Mentation intact. She had a central nystagmus, diminished sensation of right face, right sensorineural hearing loss and right cerebellar signs consistent with right pons lesion. (Fig 1. Red Arrow) Also lesions in subcortical, periventricular & corpus callosum. Toxicology positive for methamphetamine and marijuana. LP had normal WBC, RBC, glucose and protein. CSF myelin basic protein was high. CSF had one oligoclonal band. Given the onset of the illness right after substance abuse, a concern was raised for drug induced vasospastic CNS microangiopathy/demyelination mimicking Multiple Sclerosis (MS)

Discussion Literature describes CNS microangiopathic and demyelinating effects of Methamphetamine as well as microangiopathy of cannabis. MRI lesions from these can mimic MS. White matter changes in methamphetamine users are seen in frontal, periventricular and corpus callosum regions. Hence location of MRI lesions cannot distinguish these from MS. Oligoclonal bands are seen in 85–95



Abstract 274 Figure 1

% of MS patients, but are of limited distinguishing ability due to poor specificity for MS. These elevate in any breakdown of blood brain barrier. With millions using drugs, physicians should know about substance abuse mimicking MS both in symptoms and brain imaging. Diagnosis of MS should not be made in isolation from the substance abuse history. This has therapeutic implications for patients prescribed prolonged expensive MS therapies. From a probability standpoint also, substance abuse is more common than MS. It is also possible that methamphetamine and cannabis play a role as a trigger factor for developing MS.

275 TRANSVERSE MYELITIS ASSOCIATED WITH POSITIVE MUMPS SEROLOGY

F Sakho. *UF HEALTH JACKSONVILLE, Jacksonville, FL.*

10.1136/jim-2016-000393.275

Purpose of Study TM is an acute, immune mediated inflammatory myelopathy. Post-infectious process, autoimmunity, vaccinations maybe involved in the pathogenesis, still, 50% of cases are idiopathic. Mumps viremia declined sharply almost 90% since the implementation of the MMR vaccine (live attenuated)

The primary purpose of this study was to investigate the frequency of association between transverse myelitis (TM) and positive mumps serology.

Methods Used A literature review from 1957–2011 was conducted via Pubmed. Search terms were ‘transverse myelitis’, ‘mumps’, and ‘vaccination’. English publications were evaluated. We included cases of TM with positive Mumps serology. Other demyelinating disorders were excluded.

Summary of Results Twenty two articles were reviewed and eleven cases matched our inclusion criteria; predominantly children except for 3 adults. Eight cases (72.7%) were post-immunization and three cases were post-infectious. One case involved the cervical cord the remainder were thoracic levels. Recovery varied between a fatality and resolution of symptoms within 2 weeks. Our case involved a 18-year-old presenting with precipitous quadriplegia and respiratory failure, found to have increased T2 signal from C1 to C5 on MRI. Serologic findings were positive for Mumps IgM and IgG. He did not improve despite IV Methylprednisolone, IVIG and plasma exchange.

Conclusions This reports serves to alert healthcare providers regarding the overlooked association between Mumps viremia and TM. Mumps infections are considered benign with the most common neurologic complication being aseptic meningitis. As demonstrated by this review, occasionally it causes more severe sequela such as TM.

276 THROMBOTIC THROMBOCYTOPENIC PURPURA INDUCED ISCHEMIC STROKE

P Staiano, J Greco, J Ruiz, P Patel. *UF Health Jacksonville, Jacksonville, FL.*

10.1136/jim-2016-000393.276

Case Report 56 y/o F with no PMH except TTP in 2001 requiring plasmapheresis, presented to the ED after

awakening with left side facial droop, left hand dysmetria, and unstable gait. Last known normal was 2230 the night prior. Aside from smoking, she had no other risk factors for stroke. Family history was positive for her mother having a stroke in her 50's. Lab work up at the time was significant for platelet count of 54 with no schistocytes. Physical exam was pertinent for a left facial droop, slurred speech and dysarthria, end point dysmetria on the left, positive Hoffman bilaterally, 5/5 strength except 4-/5 left iliopsoas and triceps, and pronator drift on left. She was found to have a large right MCA infarct with occlusion of M1 segment as well as a left cerebellar infarct. Pt was aspirin loaded, started on high intensity statin, and transferred to neuro floor. During her stay, she had a Tmax of 100.4, otherwise hospital course was unremarkable. She recovered nicely during initial stay, regaining strength in her left arm to 4+/5 and improvement in speech, and was discharged with plan for home physical therapy.

Subsequently she was readmitted 2 days later for worsening weakness and balance. Repeat CT head showed continued evolution of right MCA infarct, MRI brain suggested new infarction superimposed on previous infarct. Platelets upon readmission were 53 with few schistocytes. TTP was suspected as etiology for her stroke (ADAMSTS13 <10 and LDH 664), and Hem/Onc was consulted. Pt was started on prednisone 60 mg and plasmapheresis was initiated. Her functionality and ADLs improved significantly with plasmapheresis. After 3 sessions, platelets improved into 400's, and her strength and ambulation improved as well. After completion of plasmapheresis, she was transferred to rehab center for continued physical therapy. Her expected prognosis of recovery is good.

277 ACUTE RESPIRATORY FAILURE IN A PATIENT WITH A NEW DIAGNOSIS OF AMYOTROPHIC LATERAL SCLEROSIS

T Tarro, C Saraceni, L Puttock, L Roan, LS Engel. *LSU Health Sciences Center, New Orleans, LA.*

10.1136/jim-2016-000393.277

Introduction Amyotrophic Lateral Sclerosis (ALS) is an idiopathic disorder of both upper motor neurons and lower motor neurons in the motor cortex of the brain, brainstem, and spinal cord. The diagnosis is made clinically as there is no definitive test to establish a diagnosis. ALS can present with severe respiratory insufficiency requiring emergency mechanical ventilation. However, respiratory symptoms are regarded as an uncommon presenting feature of ALS.

Case A 42 year old man with a history of benign prostatic hyperplasia presented with a 2 week course of worsening shortness of breath. The patient also complained of generalized weakness, twitches in his bilateral extremities, a weak, non-productive cough, dysphonia, difficulty swallowing his food, and an 80 lb weight loss in the past 4–5 months. Physical exam on presentation was significant for diminished muscle bulk throughout, more pronounced around the bilateral shoulder girdles, proximal bilateral upper extremities, and pectoral muscles. Upper extremity and lower extremity muscle strength was 4/5 bilaterally.

Fasciculations were present in all 4 extremities and more prominent in the bilateral triceps, forearms, and anterior thighs. Hyperreflexia was exhibited in the bilateral triceps, biceps, brachioradialis, and patella tendons. Arterial blood gas on admit showed a pH of 7.26, a pCO₂ of 88, a pO₂ of 116, and a bicarbonate of 39.5 on a venturi mask of 40% FiO₂. Negative inspiratory force (NIF) was negative 10 cm H₂O. The patient required immediate intubation and mechanical ventilation. Electromyography results were consistent with ALS. The patient was extubated to bi-level non-invasive positive pressure ventilation (NIPPV) and NIF remained greater than negative 60 cm H₂O. The patient was discharged with bi-level NIPPV.

Discussion ALS has a median survival of about 32 months from the onset of symptoms. Respiratory muscle involvement is a recognized, but often late complication of ALS. The presence of impaired respiratory function is a negative prognostic factor in ALS. Bi-level NIPPV improves the prognosis of individuals with ALS with significant respiratory insufficiency.

278 INCREASED INTESTINAL PERMEABILITY IN THE MICE WITH DEFICIENT CATECHOL-O-METHYLTRANSFERASE

G Wang, X Wang, L Yang, NG Verne, Q Zhou. *Tulane University, New Orleans, LA.*

10.1136/jim-2016-000393.278

Purpose of Study Catecholaminergic system is consisted in dopaminergic and adrenergic families that play important roles in modulation of intestinal functions. It is well known that catechol-o-methyltransferase (COMT) can degrade dopamine (DA), epinephrine and norepinephrine (NE) to remove their functional effects. We have found digestive function disorders in patients who have low colonic COMT. So far, the pathogenic mechanism is not clear.

Methods Used In order to measure intestinal permeability and secretion, an Ussing chamber system was used for recording ion transport rate cross intestinal epithelium in both normal mice and those deficient in COMT

Summary of Results The results showed that electrical field stimulation (EFS)-evoked net changes of short-circuit current (ΔI_{sc}) of 1.52 ± 0.35 times (n=16) that was higher in ileal preparations of COMT (-/-) (n=12) than COMT (+/+) (n=15) female mice. The change in ΔI_{sc} has not significant in COMT (-/-, n=10) and (+/+, n=12) male mice. In order to detect dopaminergic functional changes in the ileal permeability and secretion, dopamine (DA, 10 μ M), quinpirole (10 μ M, a D2 receptor agonist), and A68930 (5 μ M, a D1 receptor agonist) were applied respectively in compartment of serosal side. Quinpirole did not alter background I_{sc} , A68930 and dopamine suppressed I_{sc} (A68930: $\Delta I_{sc} = -9.31 \pm 2.05$ and DA: $\Delta I_{sc} = -14.31 \pm 4.05$ in male WT mice (n=17). In female mice, quinpirole, A68930 and DA all have suppressing effects in wild type animals (n=9), but quinpirole-evoked suppression is significantly decreased in COMT knockout female animals (n=10). Norepinephrine (NE, 5 μ M) and foemoterol (10 μ M), a β_2 adrenergic agonist, enhanced ΔI_{sc} in all preparations from mice (WT: 10 male and 9 female; KO: 11 male and 10 female. Effects of foemoterol are more

marketable in COMT KO animals, and the adrenergic augment effects can be inhibited by the neuronal blocker, tetrodotoxin (TTX, 1 μ M).

Conclusions The results implicate that dopaminergic and adrenergic stimulating effects in ileal mucosal permeability and secretion are enhanced in COMT KO mice. Dopaminergic effects may be mediated by dopamine 2 receptor and adrenergic effects are mediated by adrenergic β_2 receptors, in which these ligand responses all are due to neurogenic effects.

Pediatric Clinical Case Joint Plenary Poster Session and Reception 4:30 PM Saturday, February 11, 2017

279 CHOLEDOCHOLITHIASIS AFTER *STREPTOCOCCUS PNEUMONIAE* ASSOCIATED HEMOLYTIC UREMIC SYNDROME TREATED WITH CEFTRIAXONE: WHAT'S TO BLAME?

C Abrams,^{1,2} B Bagga,^{1,2} D Hijano^{3,1,2}. ¹University of Tennessee Health Science Center, Memphis, TN; ²Lebonheur Children's Hospital, Memphis, TN; ³St. Jude Children's Research Hospital, Memphis, TN.

10.1136/jim-2016-000393.279

Case Report A 3-year-old previously healthy boy presented to an outside hospital with six days of upper respiratory symptoms, fever and fatigue, which acutely worsened into respiratory distress. Imaging at presentation revealed complicated right lower lobe pneumonia with small effusion. Labs revealed anemia (Hb 4.0 g/dL), thrombocytopenia (Platelets 3,000/mcL), and renal insufficiency (Cr 2.1 mg/dL). He was diagnosed with *Streptococcus pneumoniae* associated HUS (SP-HUS) after blood culture returned positive to *S. pneumoniae*. After initial stabilization, he continued to be febrile and was noted to have an empyema requiring video-assisted thoracoscopic surgery and chest tube drainage. He received a total of 21 days of cephalosporins, with majority of therapy being ceftriaxone (16 days) for his severe invasive pneumococcal disease. As he was approaching discharge, on hospital day 25, he developed symptoms of acute abdomen and was found to have developed cholelithiasis with multiple stones in the distal common bile duct. Given lack of improvement with medical treatment, he underwent cholecystectomy with intraoperative cholangiogram and transduodenal sphincterotomy. Although HUS associated with invasive pneumococcal disease is a well-known clinical entity, our case brings to light the unique clinical complication of cholelithiasis after therapy for SP-HUS. The development of cholelithiasis in our case could certainly be multifactorial. Cholelithiasis can be seen in patients with SP-HUS and ceftriaxone use separately, but symptomatic gallbladder disease requiring intervention is unusual in both cases. Given that cephalosporin use is often the mainstay treatment of *S. pneumoniae* infections; this highlights the importance of judicious use of cephalosporins in this setting while carefully monitoring for complications, given that there may be an increased predisposition of cholelithiasis in this unique clinical setting.

280 NEUROLOGICAL SEQUEL FOLLOWING HSV ENCEPHALITIS. A POSSIBLE CASE OF KLUVER-BUCY SYNDROME

A Ali Ibrahim,¹ T Sexton^{1,2}. ¹USA Children and Women's, Mobile, AL; ²Singing River Hospital, Pascagoula, MS.

10.1136/jim-2016-000393.280

Case Report To our knowledge, this is the first possible case of Kluver-Bucy syndrome following HSV encephalitis in the pediatric age group of the United States. We describe an 8 year old girl who was noted to have hyperphagia, hyperorality, hypersexuality exhibited by placing hands in genitals, along with irritability 1 month following initial HSV infection.

281 QUIT PLAYING GAMES WITH MY HEART!

SS Bagwell, C Campbell. *University of Alabama at Birmingham, Birmingham, AL.*

10.1136/jim-2016-000393.281

Case Report A 13 year old male with Carpenter's syndrome presented after cardiac arrest while playing video games at an arcade. Cardiopulmonary resuscitation was started immediately, and he was defibrillated four times. Upon presentation to the hospital, he was in normal sinus rhythm but noted to have frequent runs of polymorphic ventricular tachycardia triggered by extreme emotion. Physical exam was significant for global developmental delay, dysmorphic facies, frontal bossing, and bilateral syndactyly in upper and lower extremities. Echocardiogram had normal cardiac structure and function. He was diagnosed with catecholaminergic polymorphic ventricular tachycardia and had a left sympathetic denervation (sympathectomy). Post operatively, he had decreased ectopy on telemetry and was discharged home on nadolol and flecainide.

Catecholaminergic polymorphic ventricular tachycardia (CPVT) is a genetic disorder causing life threatening arrhythmias in response to surges in sympathetic activity. Typical presentation is syncope during emotional or physical stress in childhood. Family history may be significant for sudden cardiac death. Sixty percent of patients have mutations in the cardiac ryanodine receptor gene (AD) or calsequestrin 2 gene (AR). Historically the typical treatment was ICD placement coupled with anti-arrhythmic medications, however sympathectomy has become a more widely used option. It addresses the underlying pathology and decreases arrhythmias through reductions in preganglionic intracardiac noradrenaline release. Patients are also counseled to avoid strenuous exercise and competitive sports.

Carpenter's syndrome is a rare autosomal recessive disorder also known as acrocephalopolysyndactyly type II. There are approximately only 300 cases in the United States. It is characterized by brachycephaly due to craniosynostosis, syndactyly, polydactyly, intellectual disability, and congenital heart disease. Treatment is usually focused on correcting skull malformations through multiple operations during infancy. Interestingly, there is no known genetic relation between CPVT and Carpenter's syndrome.

282 NOW WHAT!? FEVER AND LABORATORY ABNORMALITIES FOLLOWING A COMPLICATED HOSPITAL COURSE

J Banales, LA Castagnini. *Baylor College of Medicine- San Antonio, San Antonio, TX.*

10.1136/jim-2016-000393.282

Case Report IB is an 8-year-old girl with a history of intellectual disability and minimal, non-verbal communication who was transferred to the Children's Hospital of San Antonio for 3 days of fever and refusal to bear weight. A right psoas abscess was discovered on MRI for which she was taken to the OR for incision and drainage. She would continue to have a prolonged hospital course marked by surgical wound infection, multiple trips to the OR for washouts and debridements, and treatment with several IV antibiotics. On hospital day #34, the patient acutely developed a puzzling combination of fever, irritability, leukopenia, thrombocytopenia, and transaminitis. This case provides an example of a previously documented but lesser-known side effect from prolonged use of piperacillin-tazobactam characterized by the same constellation of fever and laboratory abnormalities seen in our patient with or without rash. This adverse reaction is rapidly reversed by discontinuation of the drug. While rash did not occur in our patient, our suspicions were further confirmed when, after having the above features for 6 days, the patient had a return to clinical and laboratory baseline within 24–48 hours of discontinuing piperacillin-tazobactam as the sole intervention and was able to be discharged home a few days later. Given the common use of this antibiotic in patients with complex infectious disease, this case is important as an increased awareness of this constellation of symptoms is essential in preventing patient harm, unnecessary evaluation, and increased healthcare costs.

283 CONGENITAL SYPHILIS- THE GREAT PRETENDER STRIKES BACK

W Bemby, M Anderson, SL Nelson. *Tulane University School of Medicine, New Orleans, LA.*

10.1136/jim-2016-000393.283

Case Report A one month eight-day old female presented to the emergency department for acute onset right upper extremity swelling and decreased movement. She was born at term to a healthy mother who obtained early prenatal care. Prenatal laboratory data was negative, including RPR, which was obtained on three separate occasions. Pregnancy was complicated by non-reassuring fetal heart tones, requiring emergent cesarean section.

On the morning of admission, the patient was noted to have no flexion of the right elbow. Her only other symptoms were reappearance of rhinorrhea/congestion that had resolved from a previous hospitalization 2 weeks prior for RSV.

ED workup revealed: ESR 101, CRP 7.5, AST 54, Alkaline phosphatase 571. Radiographic imaging demonstrated diffuse periosteal reaction of the long bones and MRI showed non-specific bilateral diffuse subcortical

edema. There was initial concern for osteomyelitis versus leukemia; therefore, the patient was admitted and started on empiric antibiotics. Physical exam showed rash, nasal congestion and rhinorrhea, weakness and poor movement of the right arm, and edema. Constellation of findings led to subsequent obtainment of a serum RPR which was reactive with a positive titer at 1:512. Antibiotics were discontinued and the patient was started on IV Penicillin G Potassium.

The patient's mother was re-tested as well as the father and both were found to have a reactive RPR with positive titers and were treated for syphilis. After initiation of treatment, the patient was noted to be much more alert with increased movement of her right arm.

Congenital syphilis is caused by an in utero infection with the organism *Treponema pallidum*. Clinical manifestations are divided into early congenital syphilis at two years of age and less and late congenital syphilis in older children. Diagnosis is via nontreponemal antibody tests such as the VDRL and the RPR. A treponemal antibody test (MHA-TP or FTA-Abs) is used as a specific confirmatory test. The treatment regimen for congenital syphilis is aqueous crystalline penicillin G 200,000–300,000 units/kg/day IV for ten days. Syphilis should continue to remain at the top of the list of differential diagnoses in both children and adults for clinicians.

284 CYTOMEGALOVIRUS ASSOCIATED DUODENAL ULCER AND DUODENITIS IN AN IMMUNOCOMPETENT PEDIATRIC PATIENT

R Bernard, J Kuznetsova, E Klepper, G Aljomah. *LOL Children's Hospital, Baton Rouge, LA.*

10.1136/jim-2016-000393.284

Case Report Cytomegalovirus (CMV) is a herpes virus that lies latent in immunocompetent hosts. However, the virus can reactivate and cause gastrointestinal (GI) complications in immunocompromised patients. CMV gastrointestinal infections of the lower GI tract usually involve the colon, while the esophagus and stomach are the most commonly affected of the upper GI tract. CMV duodenitis is a rare occurrence, especially in an immunocompetent host. Scant literature exists for such cases. Here we present a case of an otherwise immunocompetent pediatric patient with poor weight gain found to have CMV duodenitis.

A thirteen-month-old Vietnamese female with a history of atopic dermatitis presented to the Emergency Department with a febrile seizure. She was admitted for poor weight gain as her height and weight were in the first and fifth percentile for her age, respectively. Initial work up was remarkable only for a slight elevation in her ALT of 48. She consistently refused oral intake and after several days of inadequate weight gain despite a high calorie diet via nasogastric tube, the patient underwent an EGD. The EGD demonstrated a duodenal ulcer and she was started on sucralfate and omeprazole. During a repeat evaluation of labs, she was found to have a more significant transaminitis. Pathology from the EGD specimen biopsies later showed viral inclusion bodies consistent with CMV duodenitis. Ultimately, immune deficiency was eliminated from the

differential diagnosis due to a negative HIV PCR and normal IgA and IgG levels. Her IgE levels were mildly elevated likely due to her atopy. The patient's viral load at 1080 IU/mL was followed via PCR and resolved with treatment consisting of IV ganciclovir and oral valganciclovir. Post antiviral treatment, the patient's liver enzymes also normalized. The patient was discharged home demonstrating adequate weight gain via g-tube feeds after CMV and ulcer treatment were initiated.

CMV infection can cause extensive tissue invasion and end organ damage. Timely proton pump inhibitor and antiviral treatment in patients can help reduce morbidity. Although rare, pediatricians should have a heightened clinical suspicion for CMV in immunocompetent pediatric patients presenting with poor weight gain.

285 NOVEL MANIFESTATION OF 16P11.2 MICRODELETION SYNDROME WITH ATYPICAL CYANOTIC BREATH HOLDING SPELLS IN INFANCY

J Bhat, P Maertens, J Martinez. *USA, Mobile, Alabama, Mobile, AL.*

10.1136/jim-2016-000393.285

Case Report A 4 month old caucasian male infant was referred to the pediatric in-patient facility for evaluation and management of recurrent episodes of seizure like activities. Infant was born to a G₂P₁ mother after an uncomplicated pregnancy and delivery at 37 weeks gestation age. Mother reported that each episode started with an inconsolable cry, followed by gasping for breath and respiratory pause during exhaling phase. The episodes were associated with cyanosis. Mother also reported dystonic posturing of extremities and trunk. The event was terminated after few seconds of apnea with deep inhalation and gradual return to normal coloration. After each episode, he remained mildly dazed and irritable for 10–15 minutes. Infant started to have these episodes starting from the postnatal age of 1 month, but recently the episodes became more severe and more frequent. Two weeks prior to the current admission, comprehensive in-patient evaluations for gastroesophageal reflux disorder, inborn errors of metabolism, continuous video EEG, and brain MRI were performed and they were normal. Due to high clinical suspicion for seizures, therapeutic trial with Levetiracetam was initiated with no response. During the current admission, physical exam was notable for mild global developmental delay, macrocephaly and soft facial dysmorphism. 2D- echocardiogram, EKG and iron deficiency work -up were also normal. Video EEG was repeated and showed dysrhythmia independently or towards the end of events. Microarray CGH revealed 16p11.2 micro-deletion. A clinical diagnosis of cyanotic type of Breath Holding Spells (BHS) was made in spite of early presentation. Mother was reassured and advised for close follow-up. The infant had less frequent episodes of BHS in spite of discontinuation of antiepileptic drug.

In conclusion, BHS can present with diverse manifestations and high degree of suspicion is required along with exclusion of other important differential diagnoses before arriving at the final diagnosis. We are reporting this index case with an early onset of cyanotic type of BHS as a novel

manifestation in infants with 16p11.2 deletion syndrome. Furthermore this case highlights the importance of CGH microarray technology in the early diagnosis of neurodevelopmental disorders.

286 **PAROXYSMAL EPISODES OF GENERALIZED DYSTONIA MANIFESTING WITH RECURRENT EPISODES OF SEVERE APNEA IN A NEWBORN INFANT WITH UNDERLYING NEUROLOGICAL INJURY**

J Bhat, O Jha. *USA, Mobile, Alabama, Mobile, AL.*

10.1136/jim-2016-000393.286

Case Report A 37 weeks gestational age, African American male infant with prenatal diagnosis of lumbosacral Myelomeningocele and Arnold-Chiari malformation type 2 with hydrocephalus was born to a 22 years old G2P0 mother by a scheduled cesarean section. He underwent Myelomeningocele repair along with Arnold-Chiari malformation decompression with Ventriculo-Peritoneal shunt placement on postnatal day 2. A day after the procedure, he was successfully extubated. He had benign postnatal course until postnatal day 14, when he started to develop recurrent and severe apneic episodes. Some of the episodes were associated with severe hypoxemia and/or severe bradycardia. He was started on nasal continuous positive airway pressure (CPAP) with no benefits. Frequency and severity of the episodes gradually worsened, resulting in almost 15–20 episodes per day and majority of them required positive pressure ventilation with bag and mask to abort the episodes and revive him. Continuous video EEG was performed multiple times and it did not show any electrographic evidence of seizures during these episodes. Even therapeutic trial with antiepileptic medications yielded no benefits. Repeat brain imaging, upper airway flexible bronchoscopy, esophageal impedance study, and genetic work up congenital hypoventilation syndrome did not yield any etiological clues for these episodes. It was observed by the bedside nurses that, each time before the episodes infant developed dystonic posturing of his trunk and extremities for a very short duration followed by the development of apneic episodes. Hence dystonia was thought to be an etiology for these episodes and hence therapeutic trial with Benzatropine was started with moderate response. Infant was switched over to Baclofen, which resulted in the complete resolution of episodes.

In conclusion, paroxysmal episodes of dystonia can occur in infants with underlying brain injury without any apparent triggers. Dystonic episodes can result in dystonic closure of upper airway and spasmodic contractions of diaphragm and other respiratory muscles resulting in severe apneic episodes. Baclofen being a muscle relaxant prevented the dystonic muscle spasms and thus prevented the apneic episodes.

287 **RHABDOMYOSARCOMA MISDIAGNOSED AS AN ABSCESS**

MS Bouquet, R Bernard, N Evans. *Our Lady of the Lake, Baton Rouge, LA.*

10.1136/jim-2016-000393.287

Case Report The differential diagnosis of a retropharyngeal mass is broad including both infectious and non-infectious etiologies. Here we describe a pediatric patient who was found to have a malignant lesion after presenting with a persistent retropharyngeal mass initially thought to be an abscess.

A 9 year-old female presented to the emergency department (ED) after presumed failed outpatient treatment of a peritonsillar abscess. She presented to her pediatrician two days prior with left sided odynophagia, otalgia and tonsillar enlargement on exam. After worsening pain and new onset hoarseness despite use of antibiotics, she presented to the ED. Lab work was negative. Computed Topography (CT) of the neck with contrast was read as a left peritonsillar abscess. She was admitted for intravenous antibiotics and otolaryngology (ENT) was consulted. Upon reviewing the CT, ENT noted an ill-defined large retropharyngeal mass with associated bony displacement and erosion more concerning for malignancy. Pathology from the CT guided needle biopsy showed a small blue cell tumor consistent with an embryonal rhabdomyosarcoma. Oncology work-up was negative and the patient was transported to St Jude for treatment.

Unknown to pediatrician, five months prior she had a similar presentation with fever and headache in which she was diagnosed with influenza after a normal CT of the head at an outside hospital. The patient was later contacted by the radiologist who was concerned about a dilated internal jugular vein seen on CT and requested further imaging. A subsequent Magnetic Resonance Angiogram/Venogram was performed at our hospital and showed normal vasculature but demonstrated a solid lesion in left parapharyngeal space with the appearance of a schwannoma. A malignant lesion could not be ruled out. The patient was referred to oncology where the decision was made to repeat imaging a month later, but patient was lost to follow-up.

Rhabdomyosarcoma of the neck can present in a similar manner to a retropharyngeal abscess. Both infectious and non-infectious differentials should be considered. A complete medical history must be obtained and medical records reviewed to determine diagnosis. Close communication between healthcare providers and families is necessary to improve compliance with follow-up and prevent delays in diagnosis.

288 **THE VAGUE PRESENTATION OF INFANT BOTULISM**

RC Calderone, L Davis, J Crout. *The University of Mississippi Medical Center, Jackson, MS.*

10.1136/jim-2016-000393.288

Case Report A previously healthy 3-month-old white female presented to clinic with poor feeding and lethargy for 2 days. Her pediatrician was concerned for dehydration and admitted her for IV fluids. Review of symptoms was otherwise negative. Vital signs were normal and physical exam showed a lethargic infant without focal findings. Admission labs were within normal limits

Hospital Course Day 2 AM: Constipation reported and abdominal XR demonstrated dilated loops of bowel.

Subsequent abdominal ultrasound returned normal.

Day 2 PM: Feeding and muscle tone worsened, and patient pooling secretions. Sluggishly reactive pupils and diminished reflexes noted. Discovered a possible exposure to raw honey and excavation near her home.

Day 3: EMG and Nerve conduction studies suggestive of a neuromuscular junction transmission defect. IV Botulism Immune Globulin (BabyBIG®) requested from the California Department of Public Health.

Day 4: BabyBIG® given.

Day 6: Muscle tone and feeding begin to improve.

Day 10: Discharged home with parents.

Discussion Clostridia spp. are spore-forming, anaerobic, gram-positive bacilli found in soil and marine sediments. Spores can colonize and germinate into bacilli in infants' large intestines, producing botulinum neurotoxin.

Botulinum toxin binds at the neuromuscular junction, producing a flaccid motor paralysis that begins with the bulbar musculature.

Common presentations include constipation, poor feeding, weak suck, hypophonic cry, increased drooling, hypotonia, ptosis, dilated and/or sluggishly reactive pupils, disconjugate gaze, blunted facial expression, poor head control, and lethargy.

In 2014, 128 cases of infant botulism were reported in the U.S. Two infant deaths have been reported since 2001.

BabyBIG® is human-derived botulism antitoxin approved for treatment of infant botulism. Its use significantly reduces length of hospital stay and associated costs.

Conclusion Infant botulism should be considered in infants with symptoms of constipation, poor feeding, decreased tone, and weak cry. The decision to treat should be based on clinical presentation and not delayed for confirmatory laboratory testing.

Hospital care, anticipated complications, post-discharge care, and parental support are available through The Infant Botulism Treatment and Prevention Program.

289 INTERMITTENT MAPLE SYRUP URINE DISEASE MASQUERADING AS NEW ONSET DIABETES IN THE PEDIATRIC INTENSIVE CARE UNIT

M Carpenter, BL Willen, B Merritt. *University of South Alabama, Mobile, AL.*

10.1136/jim-2016-000393.289

Case Report Acidosis, hyperglycemia, and the presence of ketone bodies classically identify diabetic ketoacidosis (DKA). This disease process is well known to Pediatric Emergency Departments and Intensive Care Units alike. These findings can be present in other diseases but DKA is an emergency situation requiring prompt action. We present an unusual case of a six-year-old African American female who was admitted with a presumptive diagnosis of DKA but had inconsistencies prompting a more thorough workup.

Our patient is a previously healthy six-year-old African American female who presented with lethargy and altered mental status. Her mother reported that the patient experienced nausea, vomiting, and abdominal pain with over the last day along with polydipsia and oliguria.

She was neurologically altered and mainly exhibited symptoms of severe dehydration with tacky mucous

membranes, tachycardia, and delayed capillary refill. Laboratory evaluation revealed a blood glucose of 295, a pH of 7.1, bicarbonate of 8, and positive acetone. Unconventionally her hemoglobin A1C was 5.2% with no glucosuria. She was given a fluid bolus and admitted for further management.

Initially, she was started on 10% dextrose fluids as well as an insulin drip. Her glucose normalized after the initial fluid resuscitation and the acidosis continued to correct as she was continued on insulin and dextrose supplementation. While this was not DKA, the etiology further eluded us until the following morning. Her mother remembered an abnormal newborn screen concerning for maple syrup urine disease (MSUD), though confirmatory testing for MSUD was negative after birth.

She spent 24 hours on insulin and dextrose and fully recovered after fluid resuscitation over two days. Serum and urine amino acids consistent with MSUD were elevated from our institution while the same testing from the metabolic geneticist were normal two days later. There is a narrow window for detecting a disease such as this and clinical suspicion should prompt investigation. Though the testing will not make an immediate impact, planning and consultation with a metabolic specialist for 'sick days' with special diets and protocols will hopefully prevent further admissions to the hospital for this patient.

290 CORTICOSTEROID ADJUNCTIVE THERAPY IN GUILLAIN BARRE SYNDROME, A CASE REPORT

T Chatmethakul, N Hidalgo, O Sanchez. *University of South Alabama, Mobile, AL.*

10.1136/jim-2016-000393.290

Case Report Since era of Polio vaccine, Guillain-Barre Syndrome (GBS) has become the most common cause of acute flaccid paralysis in healthy children. Acute inflammatory demyelinating polyradiculopathy (AIDP) is the most common form of GBS. Classic presentation begins with paresthesia followed by legs weakness and ascend to involve the arm and muscle of respiration. Improvement mostly occurs within 14 days after initiation of IVIG therapy starting in arms downwards to legs. Corticosteroids as an adjunct therapy have been used in severe cases. It has also been shown to hasten recovery in animal model of GBS; however, there are limited data in human and the benefit remains controversial. We report a case of Severe GBS with successful clinical recovery when Corticosteroids was used adjunctively to IVIG.

An 8 years old African American male presented with paresthesia and acute weakness in upper and lower extremities following Mycoplasma pneumonia and eventually progressed to respiratory failure required mechanical ventilation. Investigations showed elevated CSF protein with normal white cell count and contrast enhancement of the spinal nerve root on MRI consistent with GBS. He was treated with 2 sequential IVIG infusion. At day 10 after IVIG treatment his muscular strength in bilateral legs showed remarkable improvement followed by improvement in his vital capacity and was able to be weaned off of mechanical ventilation 12 days after treatment; however, his

motor power of bilateral arms remained unresponsive representing atypical recovery pattern. Repeat investigations showed persistent increase in CSF protein and enhancement in C-spine area. Corticosteroids was then started as an adjunctive therapy. 8 days after he showed significant improvement in his upper extremities motor power and has been subsequently weaned off of corticosteroids.

Intravenous Immunoglobulin has been proven most effective in treating Guillan Barre Syndrome. However, the role of corticosteroids in GBS remains unclear secondary to limited data especially in pediatric populations. Our case represent a successful case of Corticosteroids as an adjunctive therapy for Severe GBS with atypical recovery pattern in pediatric patient.

291 IDIOPATHIC VENTRICULAR TACHYCARDIA IN TERM NEWBORN

T Chatmethaku¹, S Suntratonpipat,² T Pirunnet,² R Connelly¹. ¹University of South Alabama, Mobile, AL; ²Phramongkutklao Hospital, Bangkok, Thailand.

10.1136/jim-2016-000393.291

Case Report It was reported that 1%-3% of fetal tachyarrhythmia was detectable antenatally and 0.8% persisted into neonatal period. Ventricular tachycardia is a less common arrhythmia and less understood. Some cases have been reported to associate with progression to ventricular fibrillation and death. However, idiopathic ventricular tachycardia which is a rare benign forms of ventricular tachycardia contains an excellent outcome in healthy newborns with structurally normal heart.

A 40-week GA neonate born to a primigravida 29 years old healthy mother with no history of maternal drug use, family history of cardiac illness related to long QT syndrome, arrhythmia or sudden cardiac death presented with fetal tachyarrhythmia. Antenatal and Perinatal course were unremarkable except for fetal ultrasonography that showed tachycardia with heart rate of 200–220 bpm. At birth, her maximum heart rate were 200 bpm during crying and 160 bpm during sleeping. A 12-lead ECG showed left bundle branch block with fusion beats that is suppressed during exertive movements. Other blood and radiographic investigations were unremarkable. An echocardiography showed structurally normal heart with normal ventricular function. Patient remained hemodynamically stable throughout hospital stay and required no intervention in conversion of cardiac rhythm. Normal sinus rhythm resumed at day 7 of life.

Accelerated ventricular rhythm can be distinguished from other malignant forms of VT due to its slower rate and absence of symptoms. It is usually suppressed by exertion, whereas VT from other causes may persist or progress into ventricular fibrillation during exercise. The mechanism is unknown and may include abnormal automaticity. Our case was an asymptomatic neonate born with accelerated ventricular rhythm and the investigations showed idiopathic caused whose ECG eventually resumed normal sinus rhythm spontaneously. We conclude that asymptomatic newborns with frequent monomorphic ventricular and considered healthy on the basis of noninvasive cardiologic evaluation have a good long-term prognosis.

292 PHEOCHROMOCYTOMA PRESENTING IN CARDIOGENIC SHOCK

S Avula, C Mironovici, EN Chiccarelli. Louisiana State University, River Ridge, LA.

10.1136/jim-2016-000393.292

Case Report A 12-year-old female presented with a one day history of vomiting and fatigue. She developed tachycardia, hypotension, altered mental status and respiratory distress in the emergency department. Echocardiogram on admission showed severely depressed left ventricular systolic function with an ejection fraction (EF) of <10%. She required extracorporeal membrane oxygenation (ECMO) and ventilator support for four days for hemodynamic stabilization. Paroxysmal hypertension was subsequently noted with labile systolic blood pressures between 90–280 mmHg, which raised suspicion for pheochromocytoma. Abdominal computed tomography showed a 7 cm×5 cm×5 cm retroperitoneal mass anterior to the left kidney. Predominantly normetanephrine-secreting pheochromocytoma was diagnosed based on biochemical studies. It was considered the reason for cardiogenic shock due to catecholaminergic cardiomyopathy. Full alpha and beta blockade allowed for recovery of normal cardiac function prior to surgical resection with an EF of 79%. Pheochromocytoma was histologically confirmed to be adrenal in origin.

Pheochromocytoma is a catecholamine producing neuroendocrine tumor that can be adrenal or extra-adrenal in origin. It classically presents with sustained hypertension, headaches, palpitations and excessive sweating. Cardiac manifestations are rare. Life-threatening dysrhythmias, cardiomyopathies, myocardial infarction and cardiogenic shock have mostly been reported in the adult literature. Acute cardiac complications may be misleading and hinder early diagnosis and treatment of the underlying extracardiac disease. Clinicians must be cognizant of multi-system involvement on initial assessment of cardiogenic shock. Pheochromocytoma should be part of the differential diagnosis as its manifestations are highly variable. Screening by obtaining urinary catecholamines is simple and noninvasive when there is clinical suspicion.

293 THYMUS ENLARGEMENT IN AN INFANT WITH NON-IGE MEDIATED COW'S MILK/SOY PROTEIN ALLERGY: A CASE REPORT

GP Contreras Yametti, A Ali Ibrahim. University of South Alabama Children & Women Hospital, Mobile, AL

10.1136/jim-2016-000393.293

Case Report Diagnosis and management of cow's milk protein allergy in infancy can be challenging for general pediatricians. Its pathophysiology encompasses an IgE and/or non-IgE mediated response that can present with a broad spectrum of symptoms and signs that range from mild to severe dermatologic, gastrointestinal, and respiratory manifestations. We describe a case of a 5-month old infant with severe milk protein allergy who presented with sudden and rapidly progressive thymic enlargement associated with chest wall deformity, tracheomalacia, and

stridor. The clinical symptoms improved significantly after allergen elimination from the diet, including regression of the thymus and correction of the chest wall deformity raising the question of a possible association between milk protein allergy and thymic hyperplasia. The thymus provides a specialized and architecturally organized environment for the development of mature T cells through its positive and negative selection. Non-IgE manifestations of cow's milk protein allergy are known to be caused by Type IV hypersensitivity reactions mediated by TH1 cells and cytotoxic T cells. Hence, true thymic hyperplasia could possibly be related to non-IgE responses to cow's milk/soy proteins. We hypothesize that removing these allergens from our patient's diet resulted in suppression of non-IgE mediated allergic responses, with subsequent changes in the thymus size.

294 CHILDHOOD INTERSTITIAL LUNG DISEASE

K Cooper, L Finley, MH Roy, E Hauck. *Our Lady of the Lake, Baton Rouge, LA.*

10.1136/jim-2016-000393.294

Case Report Childhood interstitial lung disease (chILD) is rare and incidence has been hard to determine due to lack of consensus on qualifications. It is primarily seen in infancy, but there are small subgroups of young children and adolescents that will develop one of these rare diseases. ChILDs are a group of disorders that share the pathophysiologic feature of structural remodeling of the distal airspaces. This is believed to be the consequence of persistent inflammation or remodeling with fibrosis after injury. A high index of suspicion is necessary to pursue the diagnosis because of its rarity.

Our patient is a 10 year old female who had been seen as an outpatient for 4 weeks of increased work of breathing and cough not associated with fever. Initial chest X-ray showed bilateral infiltrates. She received a course of Azithromycin without improvement. Repeat chest X-ray showed worsening bilateral infiltrates, she was then given rocephin. Subsequently, she presented to the ED breathing 48–65 breaths/minute with oxygen saturations as low as 70%. Her exam findings were pertinent for decreased air movement bilaterally with coarse breath sounds throughout and clubbing of her fingernails. Evaluation revealed a normal CBC, elevated CRP, negative sweat test and extensive negative infectious disease work up. CT scan showed diffuse honeycombing in the lungs. She underwent a bronchoalveolar lavage and lung biopsy, neither yielding a definitive diagnosis. She was started on steroids and continues to undergo evaluation by her rheumatologist and pulmonologist. Months later she continues to require supplemental oxygen and have significant dyspnea on exertion.

ChILDs are often a diagnosis of exclusion, and biopsy is often delayed until after common causes of respiratory insufficiency are ruled out, such as infectious or inflammatory. The onset is insidious and most caregivers may not recognize initial subacute symptoms. Many children will have tachypnea or shortness of breath, cough that is dry and non-productive, poor weight gain, hemoptysis, chest pain, fever, and wheezing, making the diagnosis quite hard

because many common pediatric conditions can cause this same array of symptoms. Prognosis has great variability depending upon the patient, their family history, time of diagnosis, and response to treatment.

295 LEUKEMIA MASQUERADING AS JUVENILE IDIOPATHIC ARTHRITIS

M Davie, S Alvarez. *LSUHSC, Shreveport, LA.*

10.1136/jim-2016-000393.295

Case Report A 3-year-old male with a 4 month history of joint pain and swelling was hospitalized for evaluation of recurrent, symmetric joint pain and swelling. Starting in December 2015, he developed pain in his shoulders and elbows. His pediatrician started the initial rheumatologic work up including ANA and rheumatoid factor which were negative. He was referred to pediatric rheumatology due to concerns for Juvenile Idiopathic Arthritis (JIA); however, no definitive diagnosis could be made. Additional work up during the admission included peripheral blood flow cytometry which was negative and MRI of the swollen left knee which showed only a small joint effusion. He was started on high dose anti-inflammatories which initially greatly improved his pain. He was then discharged but ultimately re-admitted two weeks later for reoccurrence of his pain and inability to walk. During the second admission, a bone marrow aspiration revealed extensive focal necrosis and infiltration with blasts. Diagnosis of B cell acute lymphoblastic leukemia was made and chemotherapy was started.

296 DON'T FORGET THE TONGUE

J Dean. *University of Alabama at Birmingham, Homewood, AL.*

10.1136/jim-2016-000393.296

Case Report Introduction: Brief Resolved Unexplained Events (BRUE) account for nearly 1% of emergency room visits for patients <1 year old. In approximately 50% of cases, no clear etiology of the event is discovered. However, a thorough physical exam can reveal clues to an undiagnosed genetic syndrome.

Case Presentation: The patient is a 2-month-old previously healthy male who was admitted for overnight polysomnography due to concern for apnea. One month prior to admission, the patient had experienced an episode of apnea with associated hypotonia at home that resolved with stimulation. The patient was admitted to an outside hospital due to the brief resolved unexplained event (BRUE). No clear etiology of the event was discovered prior to discharge. At discharge follow-up, the primary pediatrician referred patient for an overnight polysomnography. When patient presented for the study, he was noted to have macroglossia and an umbilical hernia. These physical exam findings prompted molecular testing for Beckwith-Wiedemann syndrome. Overnight polysomnography revealed significant obstructive sleep apnea with associated hypoxemia and molecular testing returned positive for Beckwith-Wiedemann syndrome.

Discussion Beckwith-Wiedemann syndrome (BWS) is a rare genetic disorder characterized by distinctive physical exam

findings. These findings may include macroglossia, umbilical hernia, hemihyperplasia, vascular lesions and particular facial findings. Patients with BWS are at an increased risk for sleep disordered breathing, embryonal tumors and renal abnormalities. Early identification is imperative so these life-threatening complications can be routinely monitored. A diagnosis can be confirmed with molecular testing for atypical methylation at 11 p15 or a pathogenic variant in *CDKN1C*.

Conclusion: A thorough physical exam must be performed on all infants who present due to a BRUE. Subtle physical exam findings could reveal both the etiology of the event, as well as an underlying genetic disorder. A timely diagnosis will aid in both the management of the presenting BRUE and prevent other complications from arising in the future. A thorough physical exam can keep rare syndromes from going undiagnosed.

297 FEMUR MASS IN A PATIENT WITH HIV AND POOR MEDICATION COMPLIANCE

L Finley, R Dickman, E Klepper, J Deyo. *Our Lady of the Lake Children's Hospital, Baton Rouge, LA.*

10.1136/jim-2016-000393.297

Case Report Burkitt's lymphoma was first reported in Eastern Africa as childhood facial tumor and subsequently identified as a non-Hodgkin's type lymphoma. Since the emergence of the Human Immunodeficiency Virus (HIV) infection, an association has been noted between Burkitt's lymphoma and HIV. Three subtypes now identified; endemic, sporadic or AIDS related. In United States, sporadic and immunosuppression-related cases have been reported. Patients usually present with an abdominal mass and generalized 'B symptoms'. We present a patient with a history of congenital HIV infection and poor medication compliance, who developed Burkitt's lymphoma.

The patient presented with fever, abdominal pain and right thigh pain affecting his gait. Work-up showed mild elevation of ESR and CRP. Plain films and a CT scan demonstrated a small fibrous cortical defect. An MRI was suggestive of a Brodie's abscess (subacute osteomyelitis). Incision and drainage of the lesion returned a small amount of seropurulent material, which was negative for infection or malignancy. The patient was discharged with four weeks of Clindamycin. Two months later the patient returned with worsening leg swelling and pain. Re-evaluation with MRI demonstrated pronounced periostitis, a large abscess and cortical erosion. Pathology showed malignancy and extensive necrosis. The patient was subsequently diagnosed with Burkitt's non-Hodgkin's lymphoma. Following referral to Pediatric Oncology, he began chemotherapy using a standard regimen for his disease. He was maintained on HIV medical therapy simultaneously in conjunction with Pediatric Infectious disease. He has since completed treatment for his cancer and at last evaluation had no evidence of disease.

As our case illustrates, it is important to consider the immunosuppressed status of a patient with HIV as well as medication compliance when evaluating vague complaints. Although Burkitt's lymphoma can present with lytic lesions, this is an uncommon initial finding. Presentation

may be subtle and there are reports of Burkitt's lymphoma masquerading as an abscess. In our patient, the ultimate diagnosis was possibly masked by the radiographic interpretation. Thus, when considering more common diagnoses such as infection, malignancies must also be considered in the immunocompromised patient.

298 JEJUNAL CYSTIC LYMPHANGIOMA: AN UNUSUAL CAUSE OF SMALL BOWEL OBSTRUCTION IN A PEDIATRIC PATIENT

MN Frascogna,¹ B Dillard,¹ B Berch,¹ M Maready². ¹University of Mississippi Medical Center, Jackson, MS; ²Akron Children's Hospital, Akron, OH.

10.1136/jim-2016-000393.298

Case Report Abdominal pain and constipation are common presenting complaints to the emergency department in the pediatric age group, the majority of which have a non-emergent etiology. We present the case of a young child with common presenting complaints but with an unusual cause of bowel obstruction.

A 3-year old female with no significant past medical history presented to the emergency department (ED) with constipation and intermittent vomiting. She was well until two weeks prior to presentation, at which time she stopped having bowel movements and developed abdominal pain, distention, and non-bloody, non-bilious emesis. She was seen at an outside ED where she was diagnosed with constipation by abdominal x-ray and was treated with an enema and oral polyethylene glycol. Her symptoms persisted, and she was seen by her primary care provider who increased her bowel regimen. She had no improvement and developed bilious emesis at which time she presented to the pediatric ED.

On arrival, she was noted to be pale and lethargic. She was afebrile, tachycardic, and had a normal blood pressure for age. Examination was significant for marked abdominal distention without a discreet palpable mass. Plain abdominal x-rays demonstrated air fluid levels and a complete paucity of gas in the right mid and lower abdomen. Laboratory studies were significant for metabolic acidosis and anemia. An abdominal computerized tomography (CT) scan with intravenous contrast showed a large (17.2-cm X 8.8-cm X 21-cm) multi-septated fluid-filled structure which consumed the majority of the abdominal cavity. She was taken for exploratory laparotomy where a large section of mid-jejunum was noted to be significantly dilated with profound lymphatic congestion and contain several large cystic structures. The area containing the cystic structures was excised and an anastomosis performed. The patient had an uneventful post-operative course with return of normal bowel function and was discharged on post-operative day five. A diagnosis of jejunal cystic lymphangioma was made on pathologic review.

299 UNUSUAL PRESENTATION OF HENOCCH SCHONLEIN PURPURA (HSP)

MC Gaston. *LSU Health Sciences Center, New Orleans, LA.*

10.1136/jim-2016-000393.299

Introduction HSP is a relatively common vasculitis that initially manifests with purpuric skin lesions in up to 75% of cases. As the disease progresses, multiple systems can be

affected, resulting in abdominal pain, gastrointestinal bleeding, nephropathy, and arthralgias, among other manifestations.

Case A 12-year-old male with no past medical history presented with a 1–2 week history of abdominal pain and, beginning 2 days prior, bloody stools. WBC count was 28,000 on day 1. Patient was having ~20 episodes of grossly bloody diarrhea daily, though hemoglobin, hematocrit, and platelet count remained normal. Initially, the medical team's differential diagnosis was topped by infectious gastroenteritis followed by IBD, and patient was started on broad-spectrum antimicrobial therapy. On day 3, the patient developed a purpuric rash on his face and genitals, though his platelet count and coagulation studies remained normal. Labs were also notable for persistent hypoalbuminemia, hematuria, proteinuria, and hypocomplementemia. He was hypertensive, with systolic pressures in 130 s, despite adequate analgesia. Endoscopy revealed diffuse inflammation of the small intestines. Tissue biopsies taken for culture, in addition to blood and stool cultures, remained negative. Stool studies to assess for infection were also negative, though stool calprotectin level was elevated. On day 4, patient's rash spread to include lesions on trunk and lower extremities, and he began to complain of arthralgias. As patient remained without improvement despite broad-spectrum antibiotic therapy, the medical team began to look to HSP as a more likely diagnosis. Solumedrol was added to his treatment regimen. This addition was followed by rapid improvement in patient's condition, which continued despite discontinuation of antibiotics. Skin biopsies revealed a leukocytoclastic vasculitis, consistent with HSP.

Discussion The rash of HSP tends to affect the lower extremities and generally appears prior to development of additional manifestations. The disease's abdominal symptoms are generally confined to abdominal pain, and rarely is hemorrhage seen. The development of the HSP's characteristic tetrad - palpable purpura, arthralgia, abdominal pain, and renal disease - in uncharacteristic order and level of severity can complicate diagnosis.

300 UNUSUAL PRESENTATION OF HENOC SCHONLEIN PURPURA (HSP)

MC Gaston. *LSU Health Sciences Center, New Orleans, LA.*

10.1136/jim-2016-000393.300

Introduction HSP is a relatively common vasculitis that initially manifests with purpuric skin lesions in up to 75% of cases. As the disease progresses, multiple systems can be affected, resulting in abdominal pain, gastrointestinal bleeding, nephropathy, and arthralgias.

Case: A 12-year-old boy with no past medical history presented with a 1–2 week course of abdominal pain and, beginning 2 days prior, bloody stools. WBC count was 28,000 cells/ul on day 1. The patient was having ~20 episodes of grossly bloody diarrhea daily, though hemoglobin, hematocrit, and platelet count were unremarkable. Initially, the medical team's differential diagnosis was topped by infectious gastroenteritis followed by IBD, and the patient was started on broad-spectrum antimicrobial therapy. On day 3, the patient developed a purpuric rash on his face

and genitals, though his platelet count and coagulation studies remained normal. Labs were also notable for persistent hypoalbuminemia, hematuria, proteinuria, and hypocomplementemia. He was hypertensive, with systolic pressures in 130 s, despite adequate analgesia. Endoscopy revealed diffuse inflammation of the small intestines. Tissue biopsies taken for culture, in addition to blood and stool cultures, remained negative. Stool studies to assess for infection were also negative, though stool calprotectin level was elevated. On day 4, the patient's rash spread to include lesions on trunk and lower extremities, and he began to complain of arthralgias. The patient failed to improve despite broad-spectrum antibiotic therapy and the medical team began to look to HSP as a more likely diagnosis. Solumedrol was added to his treatment regimen. This addition was followed by rapid improvement in patient's condition, which continued despite discontinuation of antibiotics. Skin biopsies revealed a leukocytoclastic vasculitis, consistent with HSP.

Discussion The rash of HSP tends to affect the lower extremities and generally appears prior to development of additional manifestations. The disease's abdominal symptoms are generally confined to abdominal pain, and rarely is hemorrhage seen. The development of the HSP's characteristic tetrad - palpable purpura, arthralgia, abdominal pain, and renal disease - in uncharacteristic order and level of severity can complicate diagnosis.

301 ALTERED MENTAL STATUS PRESENTING TO THE PEDIATRIC EMERGENCY DEPARTMENT

Sara Williams, Neal Sankhla, Pallavi Ghosh, P Ghosh, S Williams, N Sankhla. *University of Alabama at Birmingham, Birmingham, AL.*

10.1136/jim-2016-000393.301

Introduction Pediatric stroke is relatively uncommon in apparently healthy children and when it occurs can cause significant morbidity and mortality.

Case Presentation Our patient is an 8 year old, previously healthy Caucasian female who presented with altered mental status. Parents described sudden onset of intermittent left sided facial twitching, left arm trembling, and flexion of her left leg with inability to talk and walk while coming down a slide on an inflatable playground. When EMS arrived, her eyes were deviated to the left and she had two episodes of emesis with intermittent apnea and bradycardia during transport.

No history of trauma, headache, URI symptoms, fever, vomiting or weakness. No exposure or access to medications. Review of systems was otherwise negative.

In the Emergency department, she was afebrile and her vital signs were stable. Initial exam revealed a somnolent but intermittently agitated girl with intact cranial nerves, withdrawing all extremities to pain, reflexes 1+ and non-focal symmetric neuro exam.

Differential included head injury, status epilepticus, stroke, ingestion, meningitis, electrolyte imbalance, intracranial mass or bleed.

Labs/ Images: Head CT obtained was normal. CBC, CMP, ammonia, urine, urine drug screen, aspirin level, acetaminophen level and alcohol level were within normal

limits. EKG with normal sinus rhythm.

ED course: Pt continued to be altered so lumbar puncture was performed and viral PCRs sent. Subsequent exams revealed that patient was aphasic, had nasolabial flattening on the right and weakness of her right upper extremity. Emergent MRI/ MRA of the brain obtained six hours later showed acute infarct of left middle cerebral artery territory. Patient was immediately taken to interventional radiology for partial thrombectomy.

Conclusion What initially appeared to be probable post-ictal behavior was actually consistent with a left MCA stroke. Patients like this one pose a difficult challenge in diagnosing stroke in a timely manner. Due to their non-specific presentations and the rarity of stroke in pediatric population we are now developing a stroke protocol in conjunction with neurology to use in the emergency department at Children's of Alabama.

302 NARCOLEPSY: NOT JUST FOR ADULTS

C Glendye, E Livingston, K Schneider. *University of Mississippi Medical Center, Madison, MS.*

10.1136/jim-2016-000393.302

Objectives Recognize the signs and symptoms of childhood narcolepsy

Background Narcolepsy is a chronic disorder affecting the sleep-wake cycle. Symptoms of childhood onset narcolepsy differ from those symptoms seen in adults. Young children can have symptoms ranging from inattentiveness, emotional lability, cataplexy, sleep paralysis, and hypnagogic hallucinations. Studies have shown a strong association between hypocretin deficiency and childhood narcolepsy. Hypocretin is thought to be deficient due to hypothalamic dysfunction. Due to the variability in presentation, narcolepsy is often misdiagnosed for other more common childhood disorders

Case Description We present a previously healthy 5 year old female with hypersomnia, unstable gait, slurred speech, and hallucinations. She presented after syncopal episode during a dance recital. Mom noted that her eyes were open but she wouldn't talk; afterwards she was confused with slurred speech. Mom reported fatigue and excessive sleepiness over the past few weeks with weight gain. Blood work, CSF studies, and MRI brain were within normal limits. EEG displayed mild diffuse slowing with no epileptiform activity. It was presumed that the patient had autoimmune encephalitis. She was started on high-dose steroids and IVIG with improving symptoms. A few weeks later, she was readmitted with excessive daytime sleepiness and vivid hallucinations. Physical exam revealed intermittent tongue protrusion and ptosis consistent with facies cataleptica. It was felt that she likely had a sleep disorder and a working diagnosis of narcolepsy was established. She was started long-acting methylphenidate with improvement in her sleepiness but with worsening of her hallucinations to the point of acute psychosis necessitating stimulant discontinuation. She was referred to Sleep Medicine for sleep study and Multiple Sleep Latency Test (MSLT). Results were negative but limited due to lack of patient

cooperation. HLA testing and CSF hypocretin were sent, and both were consistent with a diagnosis of narcolepsy (HLA DQ1B 0602 positive and hypocretin-1 0 pg/mL, respectively).

Conclusion As with our patient, childhood narcolepsy is often misdiagnosed. A negative MSLT does not rule out narcolepsy, and a diagnosis can be made if there is significant clinical history with collaborating lab findings.

303 A CASE OF MENINGITIS SECONDARY TO SALMONELLA PARATYPHI B VARIANT

KB Grizzle, N Samuy. *Children's of Alabama, University of Alabama at Birmingham, Birmingham, AL.*

10.1136/jim-2016-000393.303

Case Report: Learning points 1. Recognize Salmonella as a rare cause of meningitis.

2. Discuss management and sequelae of Salmonella meningitis

Case Presentation A 3 month-old male presented to the emergency department with decreased oral intake and fever. He went into status epilepticus, leading to respiratory failure and subsequent intubation. A full septic workup was obtained and he was started on broad-spectrum antimicrobials prior to admission to the ICU. His CSF and blood cultures grew Salmonella, identified as paratyphi B variant. He was taken to the OR by neurosurgery on hospital day 11 and again on hospital day 15 for craniotomy with evacuation of subdural empyema. Head imaging also revealed multiple intraparenchymal abscesses not large enough to warrant drainage. He was initially treated with ceftriaxone and gentamicin. CSF culture cleared after 10 days, at which time gentamicin was discontinued. Ceftriaxone was continued, and a 14-day course of ciprofloxacin was added for augmented coverage. His seizures were difficult to control and required high doses of anti-epileptic medications, including 48 hours on a midazolam drip. He was extubated on hospital day 37. MRI obtained at 8 weeks of antibiotic therapy showed persistent, though improved, brain abscesses. Swallow study revealed aspiration with all consistencies, necessitating g-tube placement. At the time of discharge, he was stable on phenobarbital, levetiracetam, and lacosamide. He was discharged on home ceftriaxone monotherapy, which was discontinued after repeat MRI obtained at 12 weeks of therapy was reassuring. Of note, complete immune work up was normal.

Discussion Salmonella is an uncommon cause of bacterial meningitis, accounting for <1% of cases in developed countries. However, it remains an important cause of bacterial meningitis in the developing world. When it occurs, there is high potential for significant morbidity and mortality. Acute complications include seizures, hydrocephalus, empyema, and intracranial abscesses. Long-term sequelae include intellectual disability, language and motor delay, epilepsy, hearing loss, microcephaly, and hydrocephalus. Antibiotic therapy generally includes a third-generation cephalosporin with or without a fluoroquinolone, but also depends on pathogen susceptibility.

304 HASHIMOTO'S ENCEPHALOPATHY-WHEN TO CONSIDER?

S Gu, D Singh, J El-Dahr, SL Nelson. *Tulane University, New Orleans, LA.*

10.1136/jim-2016-000393.304

Case Report A 14-year-old previously healthy female transferred to our PICU from her local hospital where she presented in possible status epilepticus following 6 weeks of increasing clumsiness and falls, and changes in vision and behavior. Her past medical history included only a history of menstrual migraines, and her family history was remarkable for systemic lupus erythematosus and Hashimoto's thyroiditis in her maternal grandmother and Crohn's disease in her mother. Evaluation by another emergency room several weeks prior after her first unusual fall demonstrated normal blood work and head CT, and she was diagnosed with concussion. Outpatient neurology and cardiology work up with MRI/MRA brain, EEG, echocardiogram, and EKG were normal. On the day of admission, patient had returned to school in a wheelchair, given parental concern for falling, and had an episode of tonic-clonic activity with persistent rigidity and posturing concerning for status epilepticus.

Work-up included brain/spine MRI, MRV, MRA, EEG, LP, blood and urine studies for ingestion, genetic, metabolic, and autoimmune causes. All imaging was unremarkable and most of serum studies were negative, with the exception of elevated anti-TPO and anti-thyroglobulin antibodies with normal TSH and free T4, suggestive of Hashimoto's Encephalopathy. Treatment with high-dose corticosteroids followed by plasmapheresis and then rituximab resulted in complete resolution of signs and symptoms at 4 week follow up.

Hashimoto's Encephalopathy, otherwise known as steroid-responsive encephalopathy associated with autoimmune thyroiditis (SREAT), is a heterogeneous collection of clinical symptoms, categorized by otherwise normal labs but high titers of serum anti-thyroid antibodies and is seemingly responsive to corticosteroid therapy. First described in 1966 by Lord Brian et al., SREAT is likely under-diagnosed, especially in the pediatric population, given its sub-acute presentation, frequent normal imaging and standard serum studies, clinical overlap with other conditions, and relative novelty of SREAT as a diagnosis. Therefore, Hashimoto's Encephalopathy and acquisition of anti-thyroid antibodies should be considered in patients with either personal or family history of autoimmune conditions who present with altered mental status or abnormal movements with otherwise negative work-up.

305 NOVEL USE OF SIROLIMUS IN THE TREATMENT OF BLUE RUBBER BLEB NEVUS SYNDROME IN A PEDIATRIC PATIENT

CA Harkey, B Googe, B Herrington. *University of Mississippi Medical Center, Jackson, MS.*

10.1136/jim-2016-000393.305

Case Report Blue Rubber Bleb Nevus Syndrome (BRBNS) is a rare vascular disorder characterized by classic blue to black venous malformations visible on the skin, mucosa, and gastrointestinal tract. Complications of BRBNS include

symptomatic mass compression of surrounding joints and soft tissue and iron deficiency anemia due to GI bleeding. We present the fourth known case of BRBNS in the literature successfully managed with Sirolimus.

A 6-year-old male with a history of BRBNS was referred to our pediatric hematology clinic for severe iron deficiency anemia secondary to blood loss from intestinal vascular blebs. He had limited response to sclerotherapy, and despite multiple surgeries to remove intestinal lesions, the patient was dependent on chronic blood transfusions to maintain hemoglobin levels greater than 10. Over the course of several years, he developed blebs in his shoulders, hip and back leading to increased pain and decreased range of motion (ROM). His symptoms progressed to the point he became non-ambulatory and wheelchair dependent. With limited response to traditional therapy, he was started on oral sirolimus. Within months, the patient began to see great improvement. His pain resolved and his ROM improved. Most significantly, his hemoglobin stabilized to above 13, and he has not required blood transfusions in over two years. Currently, the patient no longer requires the use of the wheelchair, and his only complaint is occasional aphthous ulcers. His sirolimus level is monitored frequently, along with his cholesterol, both of which have remained within normal limits.

Sirolimus, an immunosuppressant with antiangiogenic properties, has been successfully used off-label to treat three reported cases of BRBNS worldwide. Sirolimus is thought to inhibit mTOR, a tyrosine-kinase mediated pathway which upregulates the production of vascular endothelial growth factor (VEGF). This inhibition of mTOR leads to decreased production of VEGF, and theoretically, a decrease in the development of vascular malformations found in BRBNS. Although evidence is limited, we have shown sirolimus to be an effective therapy for our patient with BRBNS. Additional research should be conducted to replicate its efficacy for widespread use for BRBNS resistant to traditional treatment modalities.

306 5 YEAR OLD WITH FEVER AND LEFT PAINFUL NECK MASS

K Herring, R Eubanks. *University of MS Medical Center, Madison, MS.*

10.1136/jim-2016-000393.306

Case Report A 5 yo AAM presents with a 4 day history of odynophagia, neck swelling and fever to 103. After one day of cefdinir with worsening throat and neck pain, he was taken to an OSH where labs demonstrated leukocytosis and mild transaminitis. Rapid strep, mono - negative. Neck x-ray with prevertebral soft tissue fullness. Received clindamycin and ceftriaxone, then transferred to our ED. Exam demonstrated neck stiffness, swelling and tenderness below the left angle of the mandible with bilateral lymphadenopathy. CT neck showed large retropharyngeal fluid collection from C1 to C7. Portable laryngoscopy showed mildly increased adenoids with mild edema at nasopharyngeal and posterior pharyngeal wall. Pt then admitted, continuing ceftriaxone and clindamycin. The following day, a formal I&D resulted in minimal purulent drainage. On the third day, he developed an erythematous maculopapular rash on

bilateral LE with mild excoriation. Cracking on his lips, tongue erythema, and mild bilateral pedal edema without apparent tenderness noted. At this point with seven days fever, he was diagnosed with Kawasaki Disease(KD). The day following IVIG and aspirin, fevers resolved with dramatic clinical improvement. An echocardiogram showed no aneurysms.

The differential for fever with a painful left neck mass is vast, including retropharyngeal abscess, neoplasm, infectious lymphadenitis and KD. KD is a multisystem vasculitis affecting small and medium sized arteries with an uncertain cause. KD is a diagnosis of exclusion and diagnostic criteria for typical KD include: fever for >5 days, oral cavity changes, polymorphous rash, conjunctival injection, cervical lymphadenopathy and edema/desquamation of the hands and feet.

Literature review supports common presentations of KD involving the criteria above. However, there are reports of rarer presentations with retropharyngeal fluid collections unresponsive to antibiotics, later diagnosed as KD.

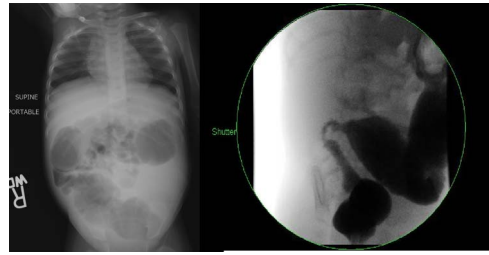
Delayed treatment increases risk of complications including the worrisome coronary artery aneurysms (CAA). IVIG during the first 10 days of illness reduces prevalence of CAAs fivefold. It is imperative for providers to be able to quickly assess and correctly diagnose KD in order to hasten therapy. KD should be considered in children who present with multiple days of high fever and retropharyngeal fluid collections.

307 A CURIOUS CASE OF CONSTIPATION AT THE CELLULAR LEVEL

MR Hincapie. *University of Florida - Jacksonville, Orange Park, FL.*

10.1136/jim-2016-000393.307

Case Report JB is a 12 month old premature small-for-gestational age infant admitted for abdominal distension and constipation. This was her very first episode of abdominal distension. Her mother took her to the local emergency room six days prior for constipation and was given stool softener and prune juice regimen. She then had several episodes of non bloody, non mucus diarrhea, decreased oral intake, and a rectal temperature of 100.4F. She was rehydrated; labs and an Abdominal Xray were obtained. Plain films showed grossly dilated loops of bowel with increased gas and large air fluid levels concerning for obstruction. NGT decompression was attempted without success. She was transferred to the local children's hospital on maintenance fluids and empiric antibiotics. Pediatric surgery and gastroenterology were involved and due to concern for obstruction, a barium enema was conducted which showed a transition zone suggestive of possible Hirschsprung Disease (HD) or congenital stricture. Rectal biopsy confirmed aganglionosis of the colon. Pediatric surgery provided a regimen of daily rectal irrigations and stool softener until surgery due to concern for enterocolitis or the risk of toxic megacolon. A dietician was also closely involved to optimize feeding until the colectomy with leveling colostomy was completed. Sequential full thickness rectal biopsies during her successful colectomy noted ganglion cells in the proximal sigmoid colon.



Abstract 307 Figure 1

This clinical case raises several questions on the late diagnosis of Hirschsprung Disease. Her first bowel movement was within 48 hours of life, and she had a chronic history of mild constipation. Given her lack of severe clinical symptoms until one year of life, her disease process could have been overlooked. The clinical breakdown of constipation or diarrhea in a case of HD may help illustrate that that the underlying clinical process may in fact be atypical as seen in this case.

308 A SEVERE CASE OF LOXOSCELISM

SC Hutchins, K Schneider. *University of Mississippi Medical Center, Madison, MS.*

10.1136/jim-2016-000393.308

Case Report In the United States, the most common and dangerous spider bite is from the *Loxosceles reclusa*, known as the brown recluse spider. Most bites will heal without medical treatment, though in severe cases, necrotic lesions and systemic symptoms can accompany envenomation. The systemic effects from a brown recluse spider bite are collectively referred to as Loxoscelism and may include fever, myalgias/arthralgias, nausea and vomiting, thrombocytopenia, hemolytic anemia, and acute renal failure. Loxoscelism reportedly occurs in 16% of brown recluse spider bites, and children tend to have more severe systemic symptoms and higher incidences of hematological complications.

We present a 13 year old male with a worsening left shoulder lesion and concern for sepsis. He reported an encounter with a spider the previous morning. Symptoms began with a painful erythematous lesion on his left scapula that progressively worsened. The lesion grew in size with a darkened center, which developed into an eschar. He also developed fever, vomiting, and fatigue, as well as a diffuse erythematous rash on his trunk and extremities. Upon arrival to our institution, the patient was noted to be in compensated shock with a severe hemolytic anemia (hemoglobin of 4.1). On exam, he had scleral icterus, a diffuse maculopapular rash over his trunk and bilateral upper and lower extremities, and a left shoulder lesion 3×4–5 cm in diameter with large eschar, central necrosis, and surrounding erythema. He was given fluid resuscitation and blood transfusions, and he underwent wound debridement with wound vacuum placement. Due to his history and presenting signs and symptoms, he was diagnosed with vasculocutaneous loxoscelism.

Given their nonspecific appearance, it is difficult to definitively diagnose a spider bite unless a spider was seen inflicting the bite or the spider is collected and positively identified. However, in the setting of a characteristic skin lesion and/or systemic symptoms with exclusion of other etiologies, the diagnosis of a spider bite can be definitively made. Systemic symptoms and severe acute hemolysis in an indigenous region without another identifiable cause may point to Loxoscelism. Once the diagnosis is made, treatment should be supportive with fluid resuscitation and blood products as needed to maintain hemodynamic stability.

309 RARE CASE OF PASTEURILLA MENINGITIS

MM Ibrahim,¹ R Evans,^{1,2} JJ Burns¹. ¹University of Florida at Sacred Heart Hospital, Pensacola, FL; ²Mayo Clinic, Rochester, MN.

10.1136/jim-2016-000393.309

Case Report A 5-week-old female infant was admitted with a two day history of lethargy, decreased oral intake, irritability and one day history of fever with maximum of 102F. There was no history of vomiting, diarrhea or rash. Examination on admission was significant for a bulging anterior fontanelle, mild lethargy, good cry and no focal neurologic deficits. She was born full term without any complications and had no known infectious exposure. She lived at home with her parents and two dogs. CBC showed a WBC of 10,600, with 57.9% neutrophils, 15% bands, CRP was 6.6 mg/dl. Examination of CSF was cloudy with WBC of 14,998, with 90% neutrophils, 90 RBC's, protein of 277, a glucose of 21. Empiric treatment with broad spectrum antibiotics including Ampicillin, Gentamicin, Vancomycin and Ceftriaxone was started initially upon admission. After identification of beta-lactamase negative Ampicillin-sensitive *Pasteurella Multocida* on both CSF and blood culture, Ampicillin was chosen for treatment for a duration of 21 days. The infant became afebrile within 48 hours of intravenous ampicillin therapy, with the CRP trending down. Head ultrasound was obtained initially to evaluate for brain abscess and was found to be negative. Upon completion of antibiotic therapy, a MRI of brain was obtained and leptomenigeal thickening was noted, a consequence of the meningitis and unconvincing.

Social history revealed that the mother had two dogs, both of which had direct contact with the infant by licks on face. No bites or scratches reported. It is hypothesized these exposures led to the infections.

Discussion *Pasteurella Multocida* meningitis is a rare clinical occurrence mainly seen in extremely young or old age. Most of the reported cases in infants have had exposure to pets. The mortality can be as high as 25%. Usually the bacteria are beta-lactamase negative, and treatment with ampicillin should be sufficient. Thorough history taking including animal exposures is vital while evaluating a neonate/infant with fever. This report also emphasizes that infants younger than 3 months of age are at an increased risk for opportunistic infections and should be kept away from direct contact with pets.

310 TREATMENT OF ATYPICAL HEMOLYTIC UREMIC SYNDROME WITH EARLY Eculizumab INFUSION

SR Induru,¹ S Poore,¹ D Feig². ¹University of Alabama, Birmingham, AL; ²Children's of Alabama, Birmingham, AL.

10.1136/jim-2016-000393.310

Presentation A 14 month-old boy presented with a 10 day history of fever, rhinorrhea, conjunctivitis and otalgia. He received 7 days of amoxicillin followed by 3 days of cefdinir without improvement. He had decreased oral intake, increased fussiness, and anuria for >18 hr at the time of presentation. His initial evaluation revealed a listless, pale child with diffuse abdominal tenderness and tachycardia. Laboratory values included Hgb 8.4 gm/L, platelet count 50,000/mcL, BUN 86 mg/dL, Cr 2.4 mg/dL. Blood smear revealed schistocytes. Anemia secondary to hemolysis, thrombocytopenia, and AKI were consistent with the diagnosis of HUS, but lack of diarrheal prodrome raised concern for atypical mechanisms including complement dysregulation or bacterial neuraminidase mediated process.

Clinical Course and Management Initial management included stabilization of intravascular volume, correction of acidemia, and avoidance of iatrogenic volume overload and electrolyte disturbance. On hospital day two, patient required a transfusion of pRBCs for ongoing hemolysis, Hgb/Hct to 5.9/17.6. Sodium bicarbonate infusion of 2 mEq/kg was administered to mitigate risk of hyperkalemia and a mid-transfusion Lasix infusion of 1 mg/kg for volume and K+ control. The patient tolerated this transfusion without complication. He had continued hemolysis and oliguria so he was treated with eculizumab and started on meningococcal prophylaxis. He had genetic and serologic testing for complement dysregulation. He was discharged home 5 days after the infusion with stable H/H, improved thrombocytopenia, and PO fluid management.

Discussion In sharing this case, our primary goal is to encourage pediatric practitioners to consider aHUS in cases without diarrheal prodromes and consider early intervention with eculizumab therapy. Our clinical suspicion for diagnosis of aHUS was supported by his age, clinical course, and the tolerance of blood products. With these factors in mind, the decision to infuse eculizumab was made in conjunction with tight fluid and electrolyte management to prevent the acute need for dialysis, plasmapheresis, or additional transfusions in the setting of atypical HUS.

311 ASSOCIATION OF AUTOIMMUNE HEPATITIS TYPE 1 IN A CHILD WITH EVANS SYNDROME

C Jarasvaraparn, H Imran, A Siddiqui, F Wilson, D Gremse. *Univeristy of South Alabama, Mobile, AL.*

10.1136/jim-2016-000393.311

Background Autoimmune hepatitis (AIH) is a progressive liver disease that is often associated with other autoimmune disorders. Evans syndrome (ES) is a rare autoimmune disorder, which is associated with immune thrombocytopenia and autoimmune hemolytic anemia.

AIH is often associated with other autoimmune disorders such as systemic lupus erythematosus, Sjögren's syndrome, and ulcerative colitis. We report a 2-year-old-female with past medical history of ES who presented with jaundice and significant transaminitis due to AIH.

Case presentation A 2-year-old African American female, previously healthy, presented with epistaxis and easy bruising for 2 months. Her liver and spleen were unremarkable. Her laboratory test showed hemoglobin 10 g/dl, hematocrit 30%, white blood cell 14800 cells/ μ l, platelet 61,000 cells/ μ l, Reticulocyte count 8.08%, and the viral panels were negative. At the time ES was diagnosed, her evaluation included a negative anti-nuclear antibody, positive warm autoantibody, positive Coombs test, positive platelet antibody and positive anti-C3. Her diagnosis of ES was confirmed by the presence of autoimmune anemia and thrombocytopenia with positive Coombs test. After treatment with one dose of intravenous immunoglobulin and prednisone. Her hemoglobin improved from 8.4 to 10.9 g/dL. While receiving no medications 11 months later, she developed increasing jaundice and pruritus. Abdominal ultrasound showed hepatosplenomegaly. Her laboratory demonstrated aspartate aminotransferase 692 IU/L, alanine transaminase 544 IU/L, albumin 1.9 g/dl, total bilirubin 10.2 mg/dl and direct bilirubin 8.8 mg/dl. Moreover, her laboratory tests showed positive anti-nuclear antibody, positive smooth muscle antibody, positive F actin antibody, and elevated total serum IgG. Anti-liver-kidney-microsome antibody, anti-HAV-IgM, HBsAg, anti-HBc, and anti-HCV were all negative. Liver biopsy revealed mild cholestasis (canalicular and hepatocytic), interface hepatitis with hepatocytic mixed inflammatory infiltrates. She was diagnosed with Type 1 AIH and received prednisolone, azathioprine and ursodiol.

Discussion We conclude that evaluation for ES as an associated autoimmune condition should be considered in children with a combination AIH, anemia and thrombocytopenia.

312 CAVERNOUS MALFORMATION AS A UNIQUE MIMICKER OF TRANSVERSE MYELITIS

R Kamat, R Herdes, M Lemoine, W Lindsey, G Duhon. *Louisiana State University Health Sciences Center, New Orleans, LA.*

10.1136/jim-2016-000393.312

Case Report Transverse Myelitis is a rare neuroinflammatory disorder associated with acute sensory/motor loss and autonomic dysfunction. Cerebral vascular malformations are a rare cause of similar symptoms secondary to hemorrhage of the spinal cord.

Case A 16-year-old male with no significant history was transferred from outside hospital for rapid-onset descending paralysis for one day. Patient reported he was playing football and complained of right-sided shoulder pain and numbness which progressed to loss of motor function and sensation on the right side of his body. He denied any history of trauma. Patient's sensory and motor dysfunction quickly advanced to include the left side. A lumbar puncture and CT scan of brain and spinal cord were inconclusive. A subsequent MRI of spinal cord without gadolinium

contrast revealed spinal cord edema from C1-T1 as well as an undetermined lesion at C5-C6. Patient transferred emergently for suspected transverse myelitis and need for plasmapheresis. Upon arrival, vital signs were stable. Physical exam was notable for absent strength in upper and lower extremities. Sensation was intact from T4 and above, but was found to be unequal in bilateral upper extremities. Proprioception remained intact. Imaging was reviewed with radiology who believed that the lesion at C5-C6 may be a mass. Decision to undergo plasma exchange was deferred until further imaging was done with contrast. Patient was given high dose glucocorticoids and repeat MRI revealed a cavernous malformation of the spinal cord with hemorrhage and surrounding cord compression. Patient underwent angiography and arterial embolization. Postoperatively he recovered sensation but continued to have reduced function of bilateral upper and lower extremities with plans to transfer to neurorehabilitation unit.

Discussion In a patient with acute paralysis, prompt action is required to prevent permanent loss of motor function. While rare, cerebral vascular malformations including cavernous malformation with associated hemorrhage should be considered for acute sensory and motor loss with MRI findings. This case represents a unique differential diagnosis for a pediatric patient with acute descending paralysis and sensory loss.

313 MISPLACEMENT OF A PERIPHERALLY INSERTED CENTRAL VENOUS CATHETER INTO AN ARTERY IN A NEONATE

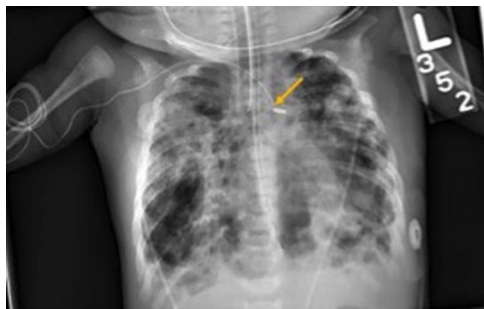R Kesman, MH Premkumar. *Baylor College of Medicine, Bellaire, TX.*

10.1136/jim-2016-000393.313

Case Report Vascular access in the care of a neonate is vital but has significant risks. We report an inadvertent placement of a peripherally inserted central venous catheter (PICC) into an artery in a neonate.

History Baby Girl A born at an outside hospital at 27 weeks with bronchopulmonary dysplasia was transferred to our hospital on day 165 following a complication with gastrostomy. On arrival, a PICC inserted into the right antecubital vein was noted with good distal perfusion. Chest x-ray showed the tip of the PICC on the left of midline raising suspicion for a misplaced PICC into the brachial artery. Echocardiogram showed the PICC in the right innominate artery. The PICC was removed immediately, and no complications were noted.

Discussion Intra-arterial misplacement of a PICC is a recognized risk of PICC placement. The incidence of misplacement of a PICC into an artery in neonates is unknown. Bright red blood during insertion, changes in distal perfusion, the tip of PICC in an abnormal position should all raise suspicion of misplacement into an artery. High oxygen content in a blood gas drawn from the PICC, waveforms on a transducer can strengthen the suspicion of misplacement. However, confirmatory tests include either a Doppler ultrasound or an Echocardiogram. An intra-arterially misplaced PICC should be removed immediately, and complications such as arterial vasospasm,



Abstract 313 Figure 1

thrombosis, distal ischemia, gangrene should be looked for and treated.

Conclusion Inadvertent insertion of a PICC into an artery is rare but can be associated with serious adverse effects including gangrene and death. Keen observation and a high degree of suspicion followed by a timely intervention can minimize the injury in such a situation.

314 UNUSUAL PRESENTATION OF A PRESUMED USUAL CLINICAL CONDITION

B Kola. *Texas Tech University Health Sciences, Odessa, TX.*

10.1136/jim-2016-000393.314

Case Report A seven day old female infant was seen in the pediatric clinic with history of recurrent right eye discharge and redness that started 4 days after delivery. No other associated symptoms or signs were noted at the time of presentation. On exam the infant was happy with epiphora, conjunctival injection and normal red reflex. No significant perinatal history and no known sick contacts. She was started on topical eye ointment for 7 days but no change in symptoms. She was referred to ophthalmologist, who started her on topical antibiotics. Later that week the infant developed periorbital swelling and corneal haziness and a corneal scar. At this point she was re-evaluated by ophthalmologist who started her on systemic acyclovir (after obtaining cultures) for possible Herpes Simplex virus (HSV) kerato-conjunctivitis. The only possible source was the father who had fever blisters.

Objective To encourage clinicians to have high index of suspicion and make close follow up so timely referral can be made and severe complications prevented.

Results Her further investigations after treatment were negative and she had significant improvement. She continued on acyclovir for one year. Currently she has acquired heterochromia (right eye- brown, Cylindrical axis +3.0 and 0 spherical, left eye: Hazel) and on corrective glasses.

Conclusion Neonatal conjunctivitis is common ocular disease in newborns after vaginal delivery and mostly benign¹. Investigations and treatment should be based on the history and clinical presentation. Causes vary from chemical to infectious origin and most cases of viral and bacterial conjunctivitis are self-limited². Response to treatment must be promptly evaluated and referral to ophthalmologist is mandated². This case is unique in the way it presented and resulted in a corneal scar as herpetic

conjunctivitis normally presents with vesicles around the eyelid and primary HSV blepharo-conjunctivitis has good outcome with non-scarring.³

REFERENCES

- 1 Neonatal Conjunctivitis Leading to Neonatal Sepsis - A Case Report. Dey AC, etal
- 2 Acute infectious conjunctivitis in childhood. Rupesh Chawla, MD, etal
- 3 Treatment of Herpes Simplex Virus Infections in Pediatric Patients: Current Status and Future Needs. SH James and RJ Whitley. *Clin Pharm Ther.*2010;88: 720-724.

315 ALTERED MENTAL STATUS CAUSED BY LEUKOCYTOSIS

A Kulkarni, CM Pruitt. *University of Alabama at Birmingham, Birmingham, AL.*

10.1136/jim-2016-000393.315

Introduction Leukocytosis is an increase in white blood cell proliferation, often due to an infectious cause. The clinical presentation of acute leukocytosis is quite variable, and is often related to the etiology of the reaction.

Case A 2 year old female presented to the emergency department with 2 days of altered mental status. She had been excessively sleepy and difficult to wake up, but had no antecedent infectious symptoms. Physical examination revealed a sleeping child who would only arouse with significant physical stimulation. She would cry, say a few words, and then fall back asleep. Vital signs and other examination findings were normal. Laboratory evaluation revealed an elevated white blood cell count (34,000 cells/microL), and marked increases in uric acid (13.1 mg/dL), alkaline phosphatase (4437 IU/L), and lactate dehydrogenase (952 U/L). Hematocrit and platelet counts were normal, and she lacked signs of malignancy on peripheral blood smear. She was treated with allopurinol and alkalinized intravenous fluids. Her mental status normalized within 24 hours, laboratory values improved, and therapies were stopped by hospital day 2.

Discussion This child was likely obtunded due to hyperuricemia secondary to rapid cell turnover from leukocytosis. This case demonstrates the importance of a broad differential diagnosis for altered mental status in pediatric patients. Hyperuricemia is an uncommon cause of altered mental status in children, but should be considered, especially if other causes are unapparent.

316 SPONTANEOUS PNEUMOMEDIASTINUM IN A PEDIATRIC PATIENT

E Landry, P Redmond, B Dillard. *University of Mississippi Medical Center, Jackson, MS.*

10.1136/jim-2016-000393.316

Case Report Chest pain and shortness of breath (SOB) are common presenting symptoms in the Pediatric Emergency Room. Given the potential serious conditions underlying such symptoms, a thorough evaluation of each patient is warranted. In this case, we present a child suffering from seemingly benign symptoms such as cough and rhinorrhea, who, after a few episodes of emesis, developed chest pain and SOB.

A six year old female presented to with a two to three day history of cough and rhinorrhea, and three mild episodes of non-bloody, non-bilious post-tussive emesis. Shortly after her third episode of emesis she developed pain in her chest, anterior neck, and shortness of breath prompting a visit to the ER. Upon arrival, she was noted to have retractions, nasal flaring, and respiratory distress out of proportion to her history. Tachycardia in the 150 s was noted. She required placement on nasal cannula oxygen and lab studies were obtained. Chest x-ray showed mediastinal air. Subsequent CT scan of the chest with PO contrast showed a significant pneumomediastinum with compression of the right ventricle, questionable contrast extravasation at the gastroesophageal junction, and patchy opacities in the left upper lobe concerning for pneumonia. Subsequent esophagram ruled out esophageal perforation. She was admitted to the PICU for further management where oxygen via nasal canula was able to be weaned by day two and serial CXRs showed progressive improvement in the pneumomediastinum. She was discharged home on hospital day four.

Spontaneous pneumomediastinum (SPM), although rare, is an important diagnosis on the differential of a patient with cough and SOB. Often caused by asthma exacerbations, more benign triggers associated with Valsalva such as cough and mild emesis may also cause SPM. Clinical findings such as chest pain, cough, dyspnea, distended neck veins, and subcutaneous emphysema should point the physician towards this more serious etiology. A thorough evaluation with close attention to the exam of the precordial area and a chest X-ray should be performed. Although treatment is often supportive, potential complications include tension pneumothorax, pseudotamponade, pneumopericardium, laryngeal compression, and gas embolism.

317 A UNIQUE CASE OF NECROTIZING PNEUMONIA WITH ASSOCIATED SEPSIS IN A PEDIATRIC PATIENT

M Lemoine, R Herdes, W Lindsey, R Kamat, J Storm, R Monier, N Godiwala. Louisiana State University Health Sciences Center, New Orleans, LA.

10.1136/jim-2016-000393.317

Introduction *Chromobacterium violaceum* is a gram-negative bacillus found in water and soil of tropical and subtropical climates. Although a rare cause of infection in humans, it has been reported to cause sepsis, abscesses, and metastatic lesions. It is known to be multi-drug resistant with high mortality and has been associated with chronic granulomatous disease (CGD) and G6PD deficiency. Pediatric cases represent a small percentage of known *C. violaceum* infections worldwide.

Case We present the unique case of septic shock and cardiopulmonary arrest secondary to *C. violaceum* necrotizing pneumonia in a pediatric patient. A previously healthy six-year-old female presented with a two day history of abdominal pain, fever and anorexia. Abdominal CT was performed due to concern for appendicitis and revealed a necrotizing right lower lobe pneumonia. She was started on broad-spectrum antibiotics; however, she continued to develop worsening bilateral pleural effusions and hypoxic respiratory failure. During intubation, she suffered a

cardiopulmonary arrest with subsequent high ventilatory and inotropic support and ultimately required veno-arterial extracorporeal membrane oxygenation. Her subsequent endotracheal culture was found to be positive for *C. violaceum*, and meropenem and ciprofloxacin were added to her antibiotic regimen. Infection in our patient was believed to have resulted from exposure to contaminated water or soil near the family's home in South Louisiana. Initial work-up for CGD was preliminarily positive. Due to frequent blood product transfusions while on ECMO, G6PD deficiency evaluation was postponed. Patient eventually decannulated off ECMO and extubated with plans to complete a prolonged antimicrobial course.

Conclusion To our knowledge, this case represents the first presentation of necrotizing pneumonia secondary to *C. violaceum* in a pediatric patient. While an extremely rare cause of infection in children, consideration of the pathogen in tropical and subtropical areas is crucial for successful prevention of progressive multi-organ failure and mortality. Patients with *C. violaceum* infection should be evaluated for immune-deficiencies, including both CGD and G6PD deficiency.

318 UNILATERAL PAIN AND WEAKNESS IN PATIENT WITH PRESUMED GUILLAIN-BARRÉ SYNDROME

A Magliolo, D Buie, D McCall. Children's of Alabama Birmingham, Birmingham, AL.

10.1136/jim-2016-000393.318

Summary of Case Patient is a 4 year old healthy male who presented to our hospital from an outside hospital with right leg pain. The patient was admitted to the outside hospital after 5 antecedent days of URI symptoms, fever, headaches, and right leg pain with refusal to bear weight. At the outside facility he was started on Rocephin because of his fever and a CT scan that showed sinusitis. His admission labs showed a normal CBC, CK, and urinalysis. His inflammatory markers continued to increase. Vancomycin was subsequently added as fever persisted since admission. Three days after admission, a lumbar puncture was obtained, but patient had been heavily pretreated with broad spectrum antibiotics; the results showed pleocytosis with white count of 156. His right leg pain persisted in right hip and knee; he continued to refuse to bear weight. Upon arrival to CoA, his previous scans, in addition to a non-contrast thigh MRI (which included bilateral hips per reports) were evaluated by orthopedics with no evidence of a septic joint. His physical exam upon admission was indicative of a pretreated meningitis with improvement of inflammatory markers; his hip pain and refusal to bear weight continued after his other symptoms improved. As pain continued in right hip and knee, inflammatory markers continued to downtrend. More imaging was obtained, including a repeat hip ultrasound and pelvis MRI, which did not show any effusion or signal abnormalities in the muscle or joint spaces. Ultimately, an MRI showed leptomeningeal enhancement involving the spinal cord, conus and cauda equinae, indicative of Guillain-Barré syndrome with unusual clinical manifestations of unilateral weakness and pain. He was treated with 1 g/kg of IVIG twice over two days

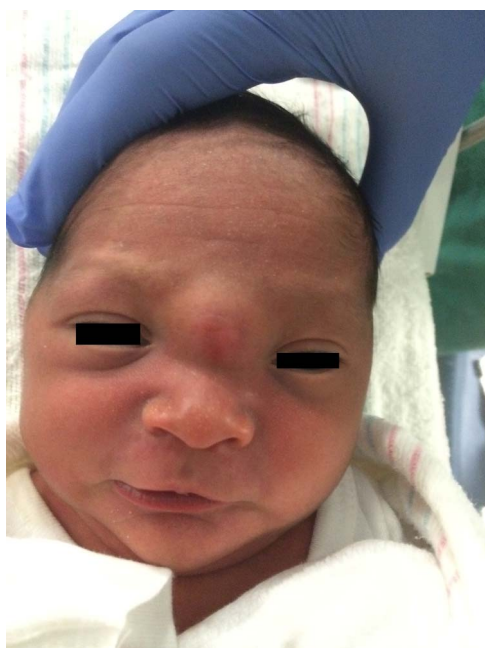Conclusions There was a delay in treating this patient's underlying neurological disease process as his presentation was unusual for this illness. Broadening the differential and honing in on physical exam findings could elucidate the causes of broadly defined weakness and pain.

319 NEWBORN WITH A GLABELLAR MASS

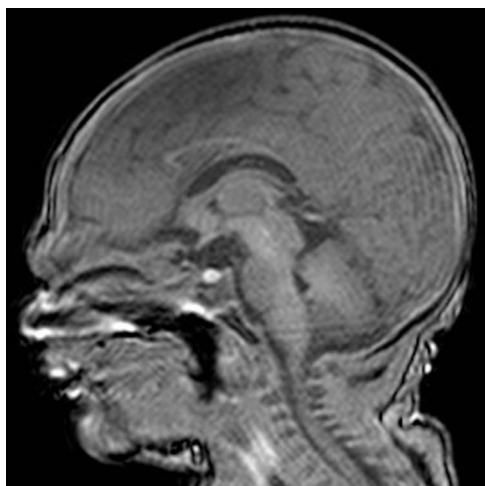L Maldonado. *University of South Florida, Tampa, FL.*

10.1136/jim-2016-000393.319

Case Report A 2-day old male newborn has a mass over the glabellar region. He is full term and his weight and head circumference are adequate for gestational age. There were no prenatal screens or sonograms performed during gestation. Delivery was precipitous, but not traumatic.



Abstract 319 Figure 1



Abstract 319 Figure 2

Apgars were 9/9. A 2.5 by 2 cm mass is noted over the glabella and bridge of the nose. It is soft, fluctuant, and does not transilluminate. The skin overlying the mass is reddish in color. (Fig 1). A bony defect is not palpable. His head is normocephalic with an open and flat anterior fontanelle and a 2 mm split of the sagittal suture. The remainder of his physical examination is within normal limits. MRI findings are consistent with a frontonasal encephalocele. (Fig 2)

320 TRANSLOCATION ASSOCIATED RENAL CELL CARCINOMA AS A SECONDARY MALIGNANCY IN A PEDIATRIC PATIENT PREVIOUSLY TREATED WITH ALLOGENEIC STEM CELL TRANSPLANT FOR PHILADELPHIA CHROMOSOME POSITIVE ACUTE LYMPHOBLASTIC LEUKEMIA

H Menghani,¹ M Stark,² D Aviles,¹ M Haymon,³ L Yu¹. ¹Louisiana State University Health Sciences Center, New Orleans, LA; ²Louisiana State University Health Sciences Center, New Orleans, LA; ³Children's Hospital New Orleans, New Orleans, LA.

10.1136/jim-2016-000393.320

Background Renal cell carcinoma (RCC) is infrequent in children and only accounts for 2–5 % of pediatric renal masses. Translocation associated RCC is the most common form of pediatric RCC. Here we present an exceptional observation of an 8 year old boy with translocation associated RCC who had a previous history of allogeneic stem cell transplant (SCT) for Philadelphia Chromosome positive (Ph+ve) Acute lymphoblastic leukemia (ALL) at 2 years of age.

Case An 8 year old male with Ph+ve ALL diagnosed at the age of 2 years was treated with chemotherapy and allogeneic SCT. Conditioning regimen was myeloablative consisting of total body irradiation, thiotepa and cyclophosphamide. Post-transplant course was complicated by Veno-Occlusive disease of the liver with hepatorenal syndrome. He developed nephrotic range proteinuria necessitating a renal biopsy which showed residual left renal scarring on the lower pole. Due to this finding, patient was followed with yearly renal ultrasound. Ultrasound at 6 years post-transplant revealed an incidental finding of 1.5 cm solid mass on upper pole of right kidney that was confirmed on contrast enhanced CT angiogram. CT of chest, rest of abdomen and pelvis were normal. Patient underwent partial nephrectomy of right upper lobe with lymph node sampling. Pathology of the lesion revealed signet ring like cells having clear cytoplasm with eccentric nuclei interspersed in normal renal polygonal cells. This sample was positive for Xp11.23 translocation (TFE3 expression) confirming the diagnosis of Xp11.23 translocation associated RCC Stage T1A.

Conclusion Children who survive cancer are >20 fold-increased risk of developing another malignancy. Still, RCC occurring as a secondary malignancy is uncommon. Cytotoxic chemotherapy may predispose to the development of translocation associated RCC. Our patient had a localized tumor with no lymph node involvement and underwent nephron sparing surgery. He is doing well 3 months post-surgery with no complications.

321 MASSIVE SPLEEN THAT STAYS

B Mitchell, RC Calderone, S Phillips, S Majumdar. *University of MS Medical Center, Madison, MS.*

10.1136/jim-2016-000393.321

Introduction Gaucher's disease (GD), the most common lysosomal storage disorder, is an autosomal recessive disorder caused by lack of glucocerebrosidase. The annual incidence is 1/60,000, but may be 1/1,000 in Ashkenazi Jews. Deficiency in glucocerebrosidase leads to accumulation of beta-glucocerebrosidase in liver, spleen, and bone marrow.

Case 5-year-old black female with history of iron deficiency anemia presented with history of subjective fever, headache, and significant splenomegaly on exam. Review of symptoms positive for upper respiratory symptoms weeks' prior. She denied animal exposure, rash, travel, or sick contacts. No family history. Her vital signs were normal and laboratory evaluation significant for anemia (hemoglobin of 9). Initial workup directed towards infectious and oncologic causes. Monospot, CMV and EBV IgM negative. CT chest, abdomen, and pelvis showed hepatomegaly and massive splenomegaly. Bone marrow biopsy revealed Gaucher cells and no evidence of malignancy.

Further workup showed undetectable beta-glucosidase level, elevated angiotensin converting enzyme, chitotriosidase and tartrate resistant acid phosphatase; consistent with GD Type I. She was scheduled for outpatient chemoport for imiglucerase enzyme replacement and discharged with orthotic spleen guard.

Discussion GD Type 1 comprises 90% of cases, has a good prognosis and associated with organomegaly, pain, osteonecrosis, pathological fractures, and cytopenia. Type 2 characterized by early onset, progressive brainstem dysfunction, organomegaly and death before age 2. Type 3 characterized by progressive encephalopathy and systemic manifestations seen in type 1. Enzyme therapy is available for type 1 and 3 only. Without treatment type 3 leads to death within a few years. Fetal form manifests with decreased or absence of fetal movements or anasarca. Differential diagnoses include other lysosomal storage disorders or malignancy. Surgical intervention is not recommended due to complications of asplenia and subsequent increased deposition in other organs, leading to bone and liver complications and risk of related malignancies. Enzyme therapy should decrease the size of spleen.

Conclusion GD should be considered in patients of any age with mild anemia and hepatosplenomegaly and can be diagnosed by careful interpretation of bone marrow aspirate smear.

322 EVALUATION OF OUTCOMES FOR EXTENDED INTERVAL GENTAMICIN DOSING IN CHILDREN WITH TULAREMIA

JJ Mott,¹ N Harik,³ W Linam,^{2,1} C McMinn,¹ H Maples^{1,2}. ¹University of Arkansas for Medical Sciences, Little Rock, AR; ²Arkansas Children's Hospital, Little Rock, AR; ³Children's National Medical Center, Washington, DC.

10.1136/jim-2016-000393.322

Purpose of Study Gentamicin at a dose of 5 mg/kg/day, divided 2 or 3 times daily, is the current treatment of choice for pediatric tularemia. Extended interval (EI) aminoglycoside dosing provides increased peaks, better post antibiotic effect, renal protective qualities, and improved convenience. Therefore, health care providers are considering EI dosing to treat tularemia. There is no literature regarding EI gentamicin dosing to treat pediatric tularemia. The aim of this retrospective chart review was to evaluate outcomes of children with tularemia treated with EI gentamicin.

Methods Used Patients <18 years of age with tularemia treated with EI gentamicin at Arkansas Children's Hospital (ACH) were identified retrospectively and their medical records reviewed. Patient outcomes were determined from review of physicians' and pharmacists' progress notes. Renal function and readmissions were also evaluated. For the purpose of this case review, all analysis is descriptive and qualitative.

Summary of Results Between 2011 and 2016, six patients (ages 4–9) diagnosed with tularemia were treated with EI gentamicin (5–7 mg/kg/day once daily). Length of therapy varied from 9 to 14 days. All 6 patients presented with painful adenopathy, and 4 patients were febrile. Renal function and gentamicin levels were monitored closely. No substantial increase in serum creatinine (>0.1 mg/dL) was seen during any EI gentamicin course. Only 4 patients had peak concentrations of gentamicin recorded, these ranged from 14–22 mcg/dL, with an average half-life of 2.5 hours providing significant non-detectable renal protective time. All patients had improvement in symptoms after their course of EI gentamicin and none were re-admitted or had recurring tularemia symptoms.

Conclusions This is the first case series supporting EI gentamicin for the treatment of pediatric tularemia. Six patients treated with EI gentamicin had no renal toxicity and no recurrence of infection. Further study is warranted to confirm these findings.

323 NOVEL MUTATION DETECTED BY WHOLE EXOME SEQUENCING IN A PATIENT WITH SATB2-ASSOCIATED SYNDROME

N Nasomyont, J Martinez. *University of South Alabama, Mobile, AL.*

10.1136/jim-2016-000393.323

Case Report The *SATB2*-associated syndrome is characterized by intellectual disability, severe language impairment, osteopenia, and craniofacial dysmorphism including micrognathia, downslanting palpebral fissures, cleft palate and crowded teeth. Initial communications referred to patients with chromosomal microdeletions in the 2q32-q33 genomic region including the *SATB2* and other contiguous genes. With the increasing utilization of whole exome sequencing (WES) in genetic diagnosis, particularly in children with developmental delay, several *SATB2* mutations have been reported in children with the characteristic manifestations of this condition, previously referred as Glass syndrome following the initial report of an affected child with a 2q32 microdeletion by Glass et al. Since then, few patients identified by WES were found to have private de

novo mutations with little phenotypic variation. We present a newly described de novo *SATB2* pathogenic variant in a 30-month-old Caucasian male with global developmental delay, severe language impairment, universal hypotonia, autism spectrum disorder (ASD), and normal palate. He was also identified as having significant sensory processing disorder including auditory and oral aversion to some food textures. He has soft dysmorphic facial features including a broad forehead, strabismus and long eyebrows, eversion of the lower lip, but he has normal primary dentition without teeth crowding and with a normal palate. A brain MRI and an echocardiogram were reported as normal. He is small with an OFC of 49 cm (25th centile), height 86 cm (5th centile) and weight 10.8 Kg (below 5th centile), but growing at a normal growth rate for age. He has no associated anomalies and is otherwise healthy. The CGH-SNP microarray and DNA analysis for fragile X syndrome were negative but a whole exome sequencing study identified a novel de-novo missense mutation in the *SATB2* gene (c.1696-1G>A; p.E566K). To our knowledge, this is the first case report of E566K variant in the *SATB2* gene as a pathogenic variant associated with *SATB2*-associated syndrome. Our patient offers a unique opportunity to expand our understanding of the phenotypical manifestations of the *SATB2*-associated syndrome and highlights the diagnostic value of WES in children with ASD and other neurodevelopmental disabilities.

324 MYELOPROLIFERATIVE FORM (PDGFRB -PLATELET DERIVED GROWTH FACTOR RECEPTOR B VARIANT) OF HYPEREOSINOPHILIC SYNDROME WITH EOSINOPHILIC GASTRITIS

VH Nayak,^{1,2} JJ Burns^{2,1}. ¹sacred Heart Children Hospital, Pensacola, FL; ²University of Florida, Gainesville, FL.

10.1136/jim-2016-000393.324

Case Report 16 year old female presented to ED, while she was on a band trip, with abdominal pain over umbilicus for 2 days without any history of vomiting or fever or change in the pattern of stools. She was evaluated in the ED for concerns of appendicitis but the workup was negative. Her CBC at that time showed WBC of 15,000 with 42% eosinophils. She was diagnosed to have hyper eosinophilia, was started on albendazole for 2 weeks and was instructed to follow up with her PCP. Her subsequent labs done at 2 weeks, 2 month and at 5 months, following the ED visit are as follows, wbc 12.2 with 45% eosinophils, 14.3 with 43% eosinophils and 17.2 with 34% eosinophils, respectively. No history of any weight loss or any worms in her stool or any recent travel. As she had persistent eosinophilia and intermittent abdominal pain, she was referred to our hospital for further management. Her physical examination was unremarkable. Her labs during hospitalization are as follows WBC count was 17200 with 34% eosinophils. CRP, ESR, IgE levels, Stool OP were negative. Parasitic workup for trichinella, toxocara, strongyloides, ascaris and entamoeba, all were negative. ECHO, CKMB and troponin levels were normal. CT chest, abdomen and pelvis for occult malignancy was negative. A bone marrow

aspirate and biopsy was performed, which showed marked eosinophilia in the absence of blasts. Cytogenetic studies showed a translocation between chromosomes 1, 5, and 14. FISH studies were positive for PDGFRB (5 q33.1) consistent with myeloproliferative variant of HES. Flow cytometry was normal. She was started on Imatinib and her eosinophil counts returned to normal in a month. She continues to take Imatinib, is on close follow up and her eosinophil counts are within normal limits.

325 ADRENOLEUKODYSTROPHY – CONSIDER IN BOYS WITH ACADEMIC FAILURE

SL Nelson. Tulane University School of Medicine, Metairie, LA.

10.1136/jim-2016-000393.325

Case Report A 13-year-old male presented to clinic for evaluation of a recent episode of status epilepticus and academic decline. He was born term without complications, and his development was normal. He had a past history of 10 febrile seizures between the ages of 3 and 6 years old, and another 'febrile seizure' at 9 years old. Also at 9-years-old he was diagnosed with possible PANDAS due to recurrent strep infections and anxiety, and the following year he had a choking episode and was unable to eat solid foods for 6 months due to anxiety. At 11-years-old he was diagnosed with ADHD due to academic difficulties and worsening behavior. Over the next two years his academic performance deteriorated, and by the time he presented for evaluation he was failing all of his classes. Over this same time period he was noted to become aggressive and impulsive. On exam he was immature for age, with brisk reflexes including crossed adductors and clonus.

A recent head CT showed nonspecific white matter hypodensities, so a brain MRI was performed, demonstrating symmetrical increased fluid in the bilateral white matter tracts with sparing of the U fibers consistent with a leukodystrophy. Testing of very long chain fatty acid (VLCFAs) found C26:0 and C24/22 and C26/22 ratios were higher than normal, consistent with a defect in peroxisomal fatty acid oxidation. Genetic testing of the ABCD1 gene found a known pathogenic mutation (c1999C>G, p.H667D, exon 10, hemizygous).

X-linked Adrenoleukodystrophy is caused by mutations in the adenosine triphosphate binding cassette (ABC), subfamily D, member 1 gene (ABCD1 gene), which helps form the channel through which VLCFAs move into the peroxisome for beta-oxidation and breakdown.

Abnormalities primarily affect the CNS (demyelination of white matter tracts), adrenal cortex, and testes. Males often present with learning difficulties and behavior problems and are initially diagnosed with ADHD. This is then followed by neurologic decline to include increasing cognitive/behavioral abnormalities and then later vision loss and spastic quadriplegia. Treatment is hematopoietic cell transplantation during the early stages, while the patient still has mild neurological symptoms. This can both significantly improve five-year survival, as well as slow neurological deterioration/progression.

326 RESPONSE TO ENZYME REPLACEMENT THERAPYT Nguyen, S Avula, M Marble, C Lijje. *LSUHSC- NO, New Orleans, LA.*

10.1136/jim-2016-000393.326

Case Report Pompe disease (PD), an autosomal recessive condition also known as glycogen storage disease II, is caused by the absence or deficiency of the lysosomal enzyme acid alpha glucosidase (GAA). Classic infantile PD, the most severe form with predominantly cardiac involvement, has been considered uniformly lethal within months before enzyme replacement therapy (ERT) became available. LV mass index and ejection fraction have been suggested as proof for ERT efficacy.

A 3-months female patient presented with increased work of breathing, poor feeding, and worsening skeletal muscle tone. Echocardiography revealed severe hypertrophic cardiomyopathy. The PR interval was shortened. Ejection fraction was mildly impaired. Speckle tracking global longitudinal strain (GLS) was highly abnormal. Classic infantile PD was suspected and confirmed by gene sequence analysis, which revealed a homozygous splice site mutation in the GAA gene. GAA activity level with acarbose was 1.74 nmol/hr/mg protein (normal ≥ 5.98). ERT was started at 20 mg/kg as biweekly infusions. The treatment was well tolerated other than initial atrial bigeminy, which was hemodynamically insignificant. Over time, the patient's breathing pattern normalized. She started to gain weight. Her muscle tone improved significantly. All echocardiographic parameters improved dramatically. While LV mass index decreased by 85%, EF improved by only 14%. Lateral mitral valve Tissue Doppler E/E' ratio and GLS, however, recovered by 75% and 71%, respectively. The segmental strain pattern is now synchronous. After 1.5 years of ERT, the patient is asymptomatic with normal muscle tone and no significant residual cardiac morphological or functional abnormality.

Speckle tracking based strain analysis, ideally complemented by a combination of LV diastolic function parameters, may be more sensitive to assess initial functional cardiac compromise and monitor response to ERT than ejection fraction.

327 A RARE CASE OF PRADER-WILLI SYNDROMEPatel Akshar, Patel Bharat. *Bay Area Heart Center, Webster, TX*

10.1136/jim-2016-000393.327

Case Report AP is a 22 year old Indian boy who comes to our religious congregation who has morbidly severe mental retardation, obesity and hypogonadism. A review of medical records from his parents revealed that patient has a deletion of chromosome number 15 on genetic testing.

The family is receiving medical support from Prader-Willi syndrome association in Florida. Review of literature revealed that Prader-Willi syndrome is very rare.

328 A TICK FOUND IN THE NICK OF TIMEF Patel,¹ AC Kiefer,^{1,2} P Edwards,^{1,2} E Dayyat,^{1,2} D Hijano,^{1,2,3} B Bagga^{1,2}. ¹University of Tennessee Health Sciences Center, Memphis, TN; ²LeBonheur Children's Hospital, Memphis, TN; ³St. Jude Children's Research Hospital, Memphis, TN.

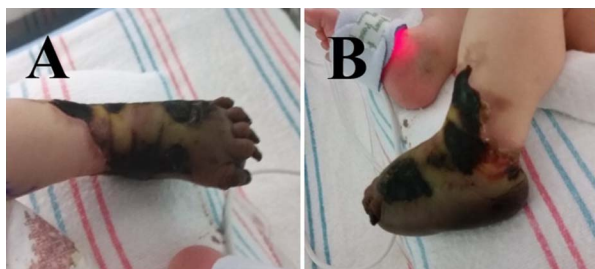10.1136/jim-2016-000393.328

Case Report A previously healthy two-year old girl from rural Mississippi presented with an acute onset of bilateral lower extremity weakness and unsteady gait. The day before admission, the patient was reportedly playing in a wooded area around her house and was at her baseline. Review of systems was otherwise negative. On physical exam, the patient had bilateral lower extremities weakness with areflexia. She was otherwise well looking with stable vitals. A work up to look for a multitude of possible infectious and noninfectious etiologies was initiated. Labs including complete metabolic panel, complete blood count, urinalysis, cerebrospinal fluid analysis, creatinine kinase, and urine drug screen did not reveal any obvious abnormalities. Radiographs of lower extremities and computer tomography of the brain were unremarkable. An engorged tick was found in the auricular canal on the second day of hospitalization and was promptly removed, with a rapid resolution of symptoms within the next 24–48 hrs suggesting that this was a case of tick paralysis. Tick paralysis is a rare form of flaccid paralysis caused by an attached tick. Unlike other tick-borne illnesses, tick paralysis is not infectious in etiology. The toxins released from the engorged tick are thought to be responsible for the symptoms, but the exact mechanism is unclear. The clinical presentation can be variable, with the most common symptoms being ascending weakness, paresthesia, and hyporeflexia. Our case was unique in that our patient also presented with ataxia. Because of the variation in presentation, the diagnosis can be challenging and is often delayed, resulting in an aggressive pursuit for alternative causes of acute ascending paralysis. Our case highlights the importance of a good physical exam in children presenting with ataxia and acute flaccid paralysis in tick endemic areas of the country. A high degree of suspicion, thorough physical exam and prompt removal may alleviate the symptoms and also save the patient from unnecessary diagnostic and therapeutic interventions.

329 CASE REPORT: ACQUIRED VERSUS CONGENITAL NEONATAL PURPURA FULMINANSMJ Patel, TO Findley, D Brown, A Duncan. *McGovern Medical School at UT Health, Houston, TX.*

10.1136/jim-2016-000393.329

Case Report Neonatal Purpura Fulminans (PF) is a life-threatening disorder caused by congenital or acquired deficiencies of protein C (PC) or S. The condition presents as a cutaneous manifestation of disseminated intravascular



Abstract 329 Figure 1

coagulation characterized by rapid onset of purpuric lesions within hours of birth and progression to irreversible necrosis of the skin. Diagnosis and targeted treatment are time-sensitive to prevent significant morbidity and mortality but can be difficult in the acute setting due to the turnaround time of confirmatory genetic testing. In this report, we describe a case of PF in a newborn with culture-negative sepsis and undetectable PC levels at birth. The patient developed left leg ischemia with extensive arterial thromboses in the first hours of life. Despite treatment with fresh frozen plasma and PC concentrate, the lesion progressed to hemorrhagic necrosis requiring amputation via left ankle disarticulation (Fig 1). Given the severity of presentation, genetic testing of the *PROC* gene for congenital PC deficiency was obtained in the patient but returned as normal. PC levels collected from both parents were also normal. The patient was weaned off of PC therapy as endogenous PC levels normalized, confirming a transient deficiency. This case highlights the course of PF in the setting of acquired PC deficiency secondary to severe culture-negative sepsis in a neonate, which is rarely described in the literature. In addition, there has been limited study of treatment with PC concentrate in the neonate, emphasizing the need for more studies on efficacy and goals of therapy.

Evolution of purpura fulminans in the left leg by day of life 20. A, Extensive ischemia with hemorrhagic necrosis. B, Extent of cutaneous infarction in the distal leg.

330 THERMAL ESOPHAGEAL INJURY FOLLOWING INGESTION OF BOILING MUSHROOM WATER

A Prevost,¹ E Klepper,¹ E McDonough,¹ A Talley². ¹Our Lady of the Lake Children's Hospital, Baton Rouge, LA; ²LSU Health Sciences Center, New Orleans, LA.

10.1136/jim-2016-000393.330

Case Report Thermal esophageal and gastric damage due to ingestion of hot liquids is not well studied or reported in pediatrics. Limited case reports exist in the literature, though this could be an underestimate due to under reporting. All cases reported have been accidental ingestions of hot food or liquid. The majority of cases presented with chest pain, dysphagia and odynophagia. Variable histologic findings were reported as well. No definitive management guidelines exist. Our case provides a complete report of the acute assessment and management of an obvious thermal esophageal injury and may contribute to what is known about this presentation.

A 16-year-old male presented to the emergency department with odynophagia, dysphagia, and hematemesis following ingestion of 'nearly boiling' mushroom tea. Symptoms began immediately after ingestion. He was started on intravenous ondansetron, pantoprazole, ketorolac, maintenance IV fluids, and a clear liquid diet. At sixty hours post-ingestion, an esophagogastroduodenoscopy (EGD) performed revealed blistering and edema of the soft palate and epiglottis, diffuse and circumferential erythema of the entire esophagus with an exudate likely to be desquamated mucosa, and linear erythema of the body and fundus of the stomach. Oral sucralfate suspension and an oral rinse containing magnesium hydroxide, viscous lidocaine, and diphenhydramine were begun for symptomatic treatment. Supplemental peripheral parenteral nutrition was also initiated. Three days post-ingestion, his diet was advanced to a soft diet. An EGD one month post-ingestion was normal showing no residual effects from the injury. At this time the pantoprazole was weaned and restrictions to his diet were lifted.

Without extensive studies on the varying presentations and complications of thermal esophageal injuries, a conservative management approach is needed. Clinicians should be aware of the small but real risk of a patient eventually developing a stricture. In order to better standardize care in these rare injuries, the development of a clinical care algorithm may be beneficial to provide clinicians with a guide for management based on outcomes of previously reported cases. Our suggested approach is attached.

331 LEAD ASTRAY: NONACCIDENTAL CHILDHOOD LEAD POISONING BY A MOTHER WITH LEAD NITRATE

L Quang. Oklahoma University Health Sciences Center, Oklahoma City, OK.

10.1136/jim-2016-000393.331

Case Report A 22-mo, medically complex, technology-dependent child with CHARGE Syndrome transfers to our clinic with severe, chronic lead poisoning since the age of 5 mos. The child's family had just moved to our region, & her first venous blood lead level (BLL) was 52 mcg/dL. In our clinic, the mother described a PMHx significant for a genetic work-up at the previous Children's Hospital confirming CHARGE Syndrome with a positive CHD7 gene mutation test at 4-mos. At 5 mos, the child presented with a 3-day history of cyanosis, seizures, lethargy, & an elevated BLL of 135 mcg/dL. Ultimately, no source for the lead poisoning was ever identified in the previous family residence. The child required monthly hospitalizations at the previous Children's Hospital for I.V. chelation therapy between 5–19 months of age for repeated, unexplained high BLLs. Physical examination in our clinic was significant for dysmorphic features consistent with CHARGE Syndrome. Neurologically, she was hypotonic & unable to regain an upright sitting position after the physical examination. Developmentally, she was at 6 months for gross motor skills & <6 months for fine motor, language, & personal-social skills. Her tracheotomy, CVC, & g-tube sites were clean, dry, & intact. We reviewed over 10,000 pages of medical charts from the previous Children's Hospital, & we concluded that this child's chronic lead

positioning was nonaccidental, as her severe cognitive & motor developmental delays (including her inability to swallow/exclusive g-tube feeds) precluded her from environmental childhood lead poisoning. Furthermore, no residential lead hazards were ever identified. Child Protective Services & local law enforcement were notified. They found a bag of lead nitrate in the mother's backpack & several bottles of lead nitrate at the high school science classroom where the mother had taught. The child had a large total body burden of lead, as evidenced by an elevated zinc protoporphyrin & copious radiopacities in her stomach confirmed to be lead by scanning electron microscopy/energy dispersive x-ray spectroscopy of biopsies (Figures 1–2). The patient responded well to lead chelation therapy & novel bisphosphonate therapy to reduce bone lead resorption. The mother was found guilty at trial and is serving a 30-year prison sentence.

332 EXTREME HYPERKALEMIA IN A PREVIOUSLY HEALTHY INFANT

P Redmond, C Faulk, B Dillard. *University of Mississippi Medical Center, Jackson, MS.*

10.1136/jim-2016-000393.332

Case Report Respiratory failure and cardiovascular collapse are not uncommon presentations to the pediatric emergency room. As such, it is important for caregivers to always consider the 'H's and T's' in their assessment of such a patient. In this case we present a previously healthy neonate with acute cardiovascular collapse due to an unexpected cause.

A five week old male presented in respiratory failure as a transfer from a tertiary care facility. He had worsening lethargy and fever prompting a work up during which he suffered an episode of ventricular tachycardia and PEA. Once in our unit, he was noted to have an abnormal tracing on his cardiac monitor, prompting a 12-lead EKG which showed a very wide complex rhythm at a slowed rate. Arterial blood gas showed pH of 6.98, sodium of 119, and a potassium of 10.4 mmol/L. He was treated with IV bicarb, calcium chloride and sent to the PICU. Initial suspicion of congenital adrenal hyperplasia. Hydrocortisone was

initiated. Initial chemistry was notable for acute kidney injury with creatinine of 4.25. An abdominal mass was palpated. Therefore a renal ultrasound was obtained revealing bilateral grade four hydronephrosis and cortical cysts. Further history from mother revealed oligohydramnios during pregnancy and decreased urine output over the prior weeks. Following stabilization a voiding cystourethrogram was obtained which confirmed posterior urethral valves.

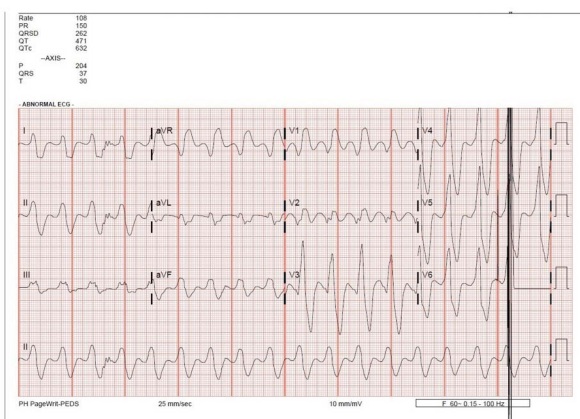All CAH labs returned negative and patient's initial electrolyte disturbances were attributed to his acute kidney injury from his PUVs. His electrolytes corrected following vesicostomy and the patient clinically improved.

333 METHYLENETETRAHYDROFOLATE REDUCTASE DEFICIENCY PRESENTING AS SHOCK IN THE PEDIATRIC INTENSIVE CARE UNIT

RP Richter, N Tofil.

10.1136/jim-2016-000393.333

Case Report While evaluation and management of shock is basic for the pediatric intensivist, awareness of abnormal presentations of rare diseases is important to highlight. We report a case of infantile methylenetetrahydrofolate reductase (MTHFR) deficiency presenting as shock. A 2 month old ex-41 week female with a 2 week history of poor oral intake, coughing and gagging during feeds, and decreased motor activity was intubated at a local emergency department for apnea and shock. She was transferred to the pediatric intensive care unit after infectious work-up and broad spectrum antibiotic administration. Head CT revealed a small brain with periventricular calcifications, thus an evaluation for perinatal infections was initiated, which was negative. Sepsis evaluation was negative, thus antibiotics were discontinued. As two maternal first cousins once removed died within the first year of life, metabolic and genetics screening tests were sent that revealed an elevated homocysteine level and low-normal methionine level. A presumptive diagnosis of MTHFR deficiency was made, and the patient was started on betaine. Her alertness and motor tone improved over the next two weeks. She was extubated after 15 days and weaned to room air by the time of discharge 36 days after her initial presentation. After 31 days of treatment, the homocysteine level decreased to an undetectable level, and the methionine level increased to normal. MTHFR deficiency was confirmed with gene sequencing, revealing two novel mutations in gene hotspots associated with other variants known to cause MTHFR deficiency: c.1151T>G (variant of uncertain significance) and c.1154delC (likely pathogenic) in exon 7 of the MTHFR gene. Infantile MTHFR deficiency usually presents as seizures, encephalopathy, or developmental delay. The patient likely presented in shock secondary to respiratory failure and hypovolemia from inadequate oral intake due to neuromuscular weakness. Betaine treats MTHFR deficiency by lowering toxic homocysteine levels through conversion to methionine using betaine-homocysteine methyltransferase. This case also presents two novel gene mutations associated with MTHFR deficiency.



Abstract 332 Figure 1

334 RADIOGRAPHIC AND GENOMIC FINDINGS IN A CONSANGUINOUS ZELLWEGER PATIENT

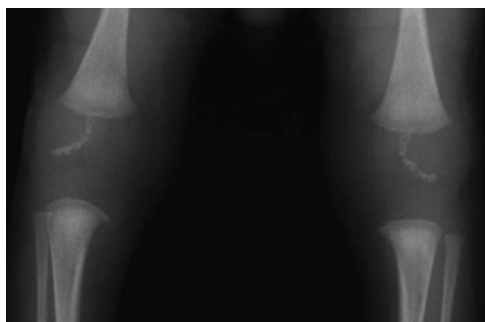E Rife, SL Nelson, H Andersson, A Dunbar. *Tulane University, Metairie, LA.*

10.1136/jim-2016-000393.334

Case Report A 6-day-old (former 34 week) male with no prenatal care was transferred to the NICU for further workup and evaluation of dysmorphic features in the setting of possible consanguinity. Initial physical examination revealed a large anterior fontanelle with a prominent forehead, widely separated sutures, flattened facies, a broad nasal bridge, hepatomegaly, and generalized hypotonia.

Initial laboratory workup, including newborn screen, was unrevealing. Plain radiographs of the extremities were grossly abnormal with stippled scimitar-shaped chondral calcifications in the patellar region, suggestive of Zellweger Syndrome. Further clinical workup to support the diagnosis was subsequently performed. Testing of very long chain fatty acids demonstrated elevated C26:0 and C26:1 as well as elevated ratios of C24/C22 and C26/C22 consistent with a defect in peroxisomal fatty acid oxidation. SNP microarray analysis found multiple regions with loss of heterozygosity indicating consanguinity. Whole exome sequencing detected a mutation in the PEX 26 gene which is vital for peroxisome membrane protein import and assembly and closely associated with Zellweger Syndrome.

Zellweger syndrome (ZS) is a peroxisome biogenesis disorder caused by mutations in PEX genes which encode proteins involved in peroxisome assembly and function. Peroxisomal disruption/dysfunction can cause severe abnormalities in brain development and nerve myelination, as well as abnormal formation of the liver, kidneys, and bones. The prognosis for infants diagnosed with ZS is poor, and most do not survive their first year of life. Current treatment modalities for manifestations of ZS focus on symptomatic and supportive care only.



Abstract 334 Figure 1 Stippled chondral calcifications in the patellar regions

335 ACUTE LEFT-SIDED WEAKNESS

MH Roy, E Klepper, DM Mathews, C Hollman. *Our Lady of the Lake, Baton Rouge, LA.*

10.1136/jim-2016-000393.335

Case Report Pediatric stroke (PS) is an acute neurologic deficit resulting from an ischemic or hemorrhagic cerebral

vascular event. Incidence of PS is 2–8/100,000 children/year. PS has a variable etiology, all with potentially significant morbidity and mortality. The most common predisposing factors for PS are congenital and acquired heart disease, hematologic and metabolic disorders, vascular disorders, and infectious etiologies.

A 10-month-old male with a history of exposure to methamphetamine and recent treatment for otitis media presented to an emergency room with suspected seizures. The patient was evaluated with a head CT, spinal tap, urinalysis and drug screen, CBC and viral respiratory screen, all of which were normal. An outpatient electroencephalogram was scheduled and the patient was prescribed levetiracetam.

The next day he presented to our ED with continued abnormal movements and new-onset left sided weakness. Exam revealed an alert, irritable infant with a normal cranial nerve exam, decreased strength and tone, and hyperreflexia of his left upper and lower extremities. He had clonus at the ankle and a positive Babinski on the left. An MRI of the brain demonstrated an ischemic stroke in the right hemisphere of the basal ganglia and parietal periventricular white matter. EEG showed suppression of sleep spindles over the right hemisphere and no epileptiform abnormalities. Coagulopathy work-up was significant only for a prolonged partial thromboplastin. Pediatric neurology recommended increasing levetiracetam and beginning aspirin. He was readmitted the following day for increased abnormal movements. Repeat MRI and exam remained unchanged. The episodes were consistent with hemiballismus with posturing of the left side. The patient was started on clonazepam and the episodes resolved.

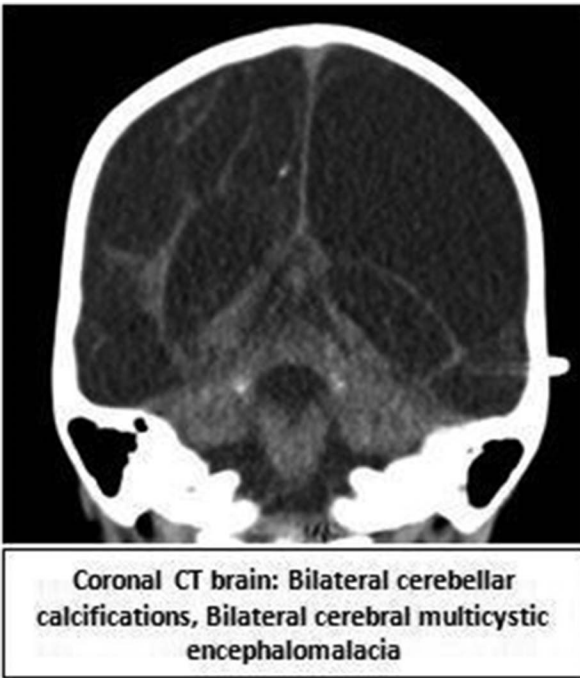
While the etiology of stroke is known in half of all affected children, fifty percent of PS cases occur in children with no known risk factors. Clinical presentation varies among age groups. Studies have shown a significant association between methamphetamine use and cerebrovascular complications in adults, but it is not known if there is an association between methamphetamine exposure and stroke in the pediatric population. This case suggests the possible existence of such an association and indicates a direction for future research.

336 HERPES SIMPLEX ENCEPHALITIS (HSE) WITH CEREBELLAR CALCIFICATION – A FIRST CASE REPORT

A Sabapathy, P Maertens. *University of South Alabama, Mobile, AL.*

10.1136/jim-2016-000393.336

Case Report A 19 day-old boy born via vaginal delivery at 37 weeks was admitted to PICU for lethargy, poor feeding, episodes of posturing and stiffening for 1 week. Prenatal history was uneventful except for limited prenatal care, unknown GBS and herpes status. Serum, CSF HSV PCR, HSV surface cultures were all positive for HSV 2. Infant's serum Toxoplasma and urine CMV were negative. Newborn screening was normal. The child was treated 21 days with parenteral acyclovir. Repeat CSF PCR was negative for HSV. Patient was discharged with suppressive dose of oral acyclovir for a total of 6 months. He was readmitted at 7 months of age for concerns of lethargy and seizures.



Abstract 336 Figure 1

Initial Cranial ultrasound showed diffuse cerebral edema, liquefaction/necrosis of left cerebral hemisphere, midbrain, thalamus with ventriculomegaly and possible right cerebellar calcification. MRI brain at 2 months showed bilateral cerebral multicystic encephalomalacia with bilateral basal ganglia calcification and suspected right cerebellar calcification. CT brain at 7 months showed cerebral multicystic encephalomalacia with bilateral basal ganglia and now bilateral cerebellar calcification.

Discussion Cerebellar calcifications have been seen in infants with congenital CMV, toxoplasmosis, HIV, early onset MELAS and cerebellar tumors. Only limited number of cases illustrating CT findings in neonates affected with HSE have been reported. Here, we report a case of neonatal HSE with cerebellar calcification, which has never been reported.

337 IMPORTANCE OF CULTURAL COMPETENCY IN DIAGNOSING RARE MEDICAL EVENTS

R Sadeghian,¹ R Gooch,² O Sanchez,¹ B Merritt,¹ S Falkos,¹ H Custodio,¹ A Jackson Jr.³ ¹University of South Alabama, Mobile, AL; ²Northwell Hofstra School of Medicine, Lake Success, NY; ³Auburn University, Auburn, AL.

10.1136/jim-2016-000393.337

Case Report A previously healthy 1-month-old Asian female infant presented to a community hospital in acute respiratory failure. The child was born full term via spontaneous vaginal delivery with no complications. HPI included less oral intake, spitting after feeds, and decreased activity for 3 days. The baby was taken to her pediatrician for evaluation of these symptoms, where she was diagnosed with a viral illness. On the day of admission, the infant started to have intermittent shortness of breath, gasping

and perioral cyanosis. She required intubation upon arrival to the ED. Patient received one dose of Vancomycin and Ceftriaxone for suspected sepsis prior to transfer to a tertiary care children's hospital. Laboratory, culture and radiological exams showed no abnormalities. She completed a 7 day course of antibiotic treatment. During the PICU stay, her physical exam demonstrated a poor cough, limited movement, poor tone, no gag reflex upon suctioning and unresponsiveness to painful stimuli. Fatigability test was positive. Constipation was reported. With further questioning, the mother stated that they had been using honey as part of a cultural remedy to remove 'white patches' off her tongue for the past few weeks. This had been used in every generation of infants from the mother's great grandmother to herself. Over that time to a few days prior to admission, the child had a weak cry, poor sucking, decreased neck/head tone, decreasing swallowing, increased drooling, and slight downward gaze. Given the clinical scenario, we obtained stool for *Clostridium botulinum*, and patient received BABYBIG® 50 mg/kg/dose. Stool samples were submitted for laboratory confirmation to Alabama Department of Public Health and *Clostridium botulinum* type A neurotoxin genes were detected. After administration of the human-specific botulinum immunoglobulin, the patient improved clinically over a period of 2 weeks and was ultimately extubated. This case report suggests the importance and recognition of cultural influences on infant feeding practices by primary care physicians. Trust building and education at well child visits are effective strategies to promote healthy infant feeding.

338 OBESITY, HYPOTHYROIDISM, SLIPPED CAPITAL FEMORAL EPIPHYSIS: JUST A WEIGHTY CONNECTION?

A Salih, K Bowlware. *The University of Oklahoma Health Sciences Center, Oklahoma City, OK.*

10.1136/jim-2016-000393.338

Case Report Case Presentation: A 13-year old obese male presented with 3 months of leg pain and weakness. His parents noted he was having difficulty climbing stairs, which progressed to difficulty walking. Dull pains began in his left thigh and spread to include the right pelvic region. By the time of presentation, the patient developed a limp and required a cane. His lower extremities were progressively edematous. A diffuse, erythematous, papular rash including his palms preceded his leg pain and weakness. On exam, he had decreased range of motion in his left hip and weakness in his quadriceps.

Thyroid studies were remarkable for Thyroid Stimulating Hormone of 278 micro International Units per milliliter and free T4 of 0.4 nanograms per deciliter. Hip films were consistent with a left sided slipped capital femoral epiphysis (SCFE). The patient was started on levothyroxine therapy and taken to surgery for pinning. The contralateral hip was asymptomatic and given the patient's chronic hypothyroid state, prophylactic repair of the contralateral hip was not performed at the same time to avoid a prolonged surgery and subsequent prolonged healing state associated with hypothyroidism. One month later, the right hip was

prophylactically repaired and found to have a grade 1 SCFE.

Discussion SCFE occurs when the proximal femoral physis is unable to resist the load placed on it causing a portion of the proximal femur to anterolaterally and superiorly displace. It has been recognized that multiple endocrinopathies, particularly hypothyroidism, may play a role in the development of SCFE. It is postulated that hypothyroidism increases the risk for SCFE through abnormal growth and mineralization of the cartilage. Up to 90% of SCFE patients with a height <10 percentile (indicating possible growth hormone deficiency) were found to have an underlying endocrinopathy. Bilateral hip involvement occurs in up to 60% of patients with identified unilateral SCFE and risk is noted to reach 100% in patients with a co-existing endocrinopathy.

Conclusion Thyroid studies are an important diagnostic tool in the evaluation of SCFE. Presence of hypothyroidism may predispose patients to SCFE, increase likelihood for contralateral hip involvement, and is associated with a delayed healing state.

339 DRESSED IN DISGUISE

A Salih, R May, R Welliver. *University of Oklahoma Health Sciences Center, Oklahoma City, OK.*

10.1136/jim-2016-000393.339

Case Report Case Presentation: A 12-year-old healthy female presented with six-weeks of increasing pain in her left tibia and difficulty ambulating. She denied recent trauma. Labs revealed only mild leukopenia. MRI displayed an edematous, heterogenous tibial lesion in the left mid-distal diaphyseal region with periosteal reaction. Tibial biopsy was without evidence of malignancy. A lesion Gram stain demonstrated Gram-positive cocci, however cultures remained negative. She was started on vancomycin for presumptive osteomyelitis. Shortly after, she developed fevers, malaise, further leukopenia and significant neutropenia. Infectious workup was negative. Coverage was empirically broadened with ceftazidime. Vancomycin was held to exclude its contribution to neutropenia.

Following count recovery, the decision was made to re-start vancomycin alone and monitor labs while outpatient. She experienced an erythematous, pruritic rash, which resolved with diphenhydramine pre-treatment. Fevers returned and vancomycin was discontinued. Ceftazidime was re-started, however fevers persisted and neutropenia worsened. A bone marrow aspirate and biopsy were unremarkable. Increases in inflammatory markers, liver enzymes and significant eosinophilia ensued. Antibiotics were withheld and her laboratory values and symptoms improved.

Discussion An active, infectious etiology was questioned given incomplete supportive findings. Lesion bone cultures were negative and this was an unusual location for osteomyelitis, the diaphysis rather than the usual metaphysis. Rash, eosinophilia, elevated liver enzymes, and systemic symptoms, in relation to vancomycin use is consistent with DRESS Syndrome.

Conclusion The presence of leukopenia, seemingly inexplicable fevers and an unclear initial diagnosis for bone pain added a dimension of complexity to arriving to this diagnosis. Although DRESS is rare, the use of vancomycin, an oft-implicated inciting drug, is increasingly common. This case serves to heighten prompt recognition of this serious diagnosis with vancomycin use and other drugs known to commonly trigger DRESS syndrome, including anti-epileptics and sulfa-containing drugs.

340 DEADLY SKIN LESIONS: WHEN ARE 'MOSQUITO BITES' WORTHY OF CONCERN?

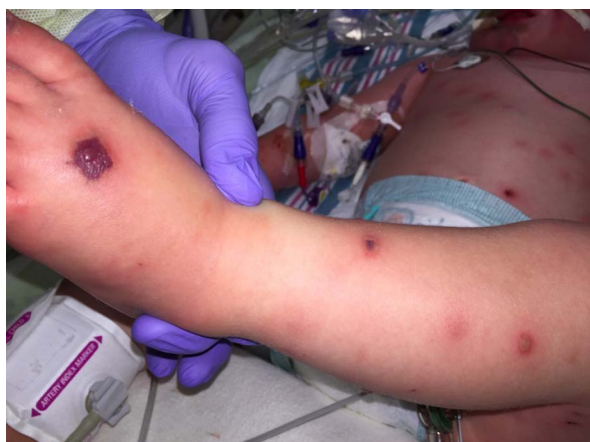JJ Sarandria, A Mirza. *University of Florida- Jacksonville, Jacksonville, FL.*

10.1136/jim-2016-000393.340

Purpose of Study This clinical case report highlights pediatric skin lesions that should raise concern for deadly underlying infectious processes.

Methods Used We present a 16-month-old boy who was transferred to our facility for 3 days of lethargy, emesis, diarrhea, and fever. The week prior, he had finished a 7-day course of amoxicillin for febrile otitis media, but his fever returned and his blood culture grew gram negative rods. On examination, he was tachycardic to 170 beats per minute, lethargic, and had scattered blanching purpuric skin lesions on his extremities that his mother believed were mosquito bites.

Summary of Results Labs revealed a leukocytosis with left shift, thrombocytopenia, and both blood and CSF cultures positive for *Pseudomonas aeruginosa*. Despite an aggressive antibiotic regimen with gentamicin and ceftazidime, he rapidly deteriorated. The skin lesions evolved over the next 72 hours into necrotic ulcerations with erythematous halos, identified as ecthyma gangrenosum. He rapidly developed disseminated intravascular coagulation and respiratory failure. Imaging revealed multiple cerebral, cerebellar, and brainstem infarcts with herniation. His mother reported a number of infections over the last year, including recurrent otitis media, coxsackie infection, and skin abscesses. An immunodeficiency workup including viral infection, immunoglobulin subclasses, T cell subsets, flow cytometry, and neutrophil oxidation testing were all normal.



Abstract 340 Figure 1

Conclusions Ecthyma gangrenosum is a harrowing skin finding in children with pseudomonas bacteremia. Early identification of these lesions aids in timely initiation of appropriate and potentially life-saving antibiotic coverage.

341 DYSTONIA AS A SIDE EFFECT OF RANITIDINE

CW Schlappi. *University of Alabama Birmingham, Birmingham, AL.*

10.1136/jim-2016-000393.341

Case Report A 40 day old male presented to the emergency department with concern for acute onset of altered mental status and abnormal movements. The mother describes the patient in his usual state of health when she laid him down for a nap at roughly 1100 that day. The mother went to wake the patient from napping after she noted him to be asleep for much longer than usual. When mother picked the child up, she appreciated that his arms were extended, his back was arched continually, and he was not tracking as usual. He would not take his bottle. This fact along with the patient's abnormal tone prompted the family to bring the patient to be evaluated. The patient was full term and had been healthy with good weight gain. Of note, the patient had been diagnosed with gastroesophageal reflux disease and was started on ranitidine two weeks prior to presentation. The exam was consistent with what the family had described with a hyperextended back, extended elbows, and abducted shoulders. He was able to track and was gazing around the room. He had no rhythmic jerking appreciable. The patient's vital signs were stable with heart rate of 110, blood pressure of 83/53, temperature of 97.1 F. The differential was broad and included seizure, sepsis, non-accidental trauma, Sandier syndrome, ingestion, and dystonia. He had multiple labs and imaging obtained which including a blood gas, CMP, CBC, urinalysis, urine drugs screen, urine and blood cultures along with a head CT without contrast. All of these evaluations were roughly normal. One dose of Benadryl was trialed, and the patient's tone improved greatly but he was not back to baseline. Further workup included an EEG which was suggestive of no epileptiform activity. He was continued on Benadryl during the hospitalization and returned to baseline. With all of the lab findings and imaging studies, stable vital signs, and response to Benadryl, the diagnosis was determined to be dystonia from ranitidine. He was discharged home on omeprazole for GERD.

Discussion Ranitidine is a very common medication used in the treatment of GERD. This is a very safe medication, but there are always possible side effect profiles to any prescription drug. Although few case reports exist, dystonia is a documented side effect of this medication that providers should be made aware of.

342 DISSEMINATED HAEMOPHILUS INFLUENZAE TYPE A INFECTION IN UNDIAGNOSED ASPLENIA

EO Schmit,¹ A Headrick,² D Kimberlin¹. ¹University of Alabama at Birmingham, Birmingham, AL; ²University of Alabama School of Medicine, Birmingham, AL.

10.1136/jim-2016-000393.342

Case Report A 4 year-old previously healthy African-American female presented with 2 days of headache and abdominal pain, which progressed to emesis, disorientation, and altered mental status. In the ED she was in septic shock, with WBC count 30,600 per μ L, platelets 52,000 per μ L, INR 2.1, and CRP 36.56 μ g/dL. Exam demonstrated abdominal guarding and meningismus. Head CT was normal, but abdominal CT revealed heterotaxy, intestinal non-rotation, and asplenia that was previously undiagnosed. Blood cultures grew *H. flu* type a (Hia). Lumbar puncture was delayed due to DIC and obtained 3 days into admission. CSF was notable for 5360 WBC/uL, glucose <20 mg/dL, and protein 227 mg/dL, with negative Gram stain and culture, likely from antibiotic pre-treatment. She was initially treated with vancomycin, ceftriaxone, and metronidazole but was changed to ampicillin when her Hia susceptibilities resulted. Her course was complicated by a septic vs. reactive left hip and left ankle with negative joint fluid cultures. Fever persisted for 16 days, and subsequent workup for complications included an echocardiogram which revealed a new moderate mitral regurgitation. She was ultimately treated with 28 days of parenteral antibiotic therapy for presumed bacterial endocarditis in the setting of disseminated Hia infection. She was discharged home on prophylactic penicillin VK and with appropriate immunizations for an asplenic patient.

Discussion *Haemophilus influenzae* can be subdivided into six encapsulated strains (serotypes A-F) and non-typeable *H. flu*. After introduction of the *H. flu* serotype b vaccine in 1990, the incidence of invasive Hib infection among children decreased dramatically. Hia is the next most virulent serotype, and although its pathogenicity is similar to Hib it more commonly causes sepsis and pneumonia with a lower incidence of meningitis. Although Hia infection is very uncommon, multiple studies have found a disproportionately increased incidence of invasive Hia infections in indigenous peoples throughout North America, including Native Americans and aboriginal peoples. Our patient is not of Native American descent, and represents an unusual case of Hia meningitis with disseminated infection.

343 AN UNUSUAL COMPLICATION OF INFLUENZA

MJ Sims, A McFarlin. *LSU-HSC, Metairie, LA.*

10.1136/jim-2016-000393.343

Case Report Every year, influenza affects thousands of children. While most children have mild disease managed with only symptomatic treatment, some require hospitalization. An even fewer number develop complications that require further medical attention.

A six-year-old previously healthy girl presented to the Emergency Department with right-sided chest wall and shoulder pain. Six days prior, she was seen at an urgent care for fever and cough, where she was diagnosed with influenza and treated with oseltamivir. In the ED, exam was benign, except for tenderness along the right pectoralis with decreased shoulder range of motion. A chest x-ray showed a right middle lobe pneumonia. She was discharged with amoxicillin-clavulanic acid.

Four days later, she returned with persistent fever,

worsened chest pain, and chest wall swelling. On exam, the patient had a three centimeter, exquisitely tender, focal swelling of the right anterior chest without erythema or drainage. CRP and ESR were elevated; CBC and differential were normal. Chest CT revealed a large sub-muscular abscess in the right anterior chest wall without signs of pneumonia. Surgeons drained the abscess; cultures grew MRSA. The patient was discharged on clindamycin after a two day hospitalization and made a full recovery.

While post-influenza abscesses are described in the literature, they are certainly among the least common complications and are typically described as pyomyositis. This patient, however, had no signs of myositis; total CK was normal and abscess was described as deep to, not within, the pectoralis muscle. It is unclear whether this abscess was secondary to direct local spread of bacteria across the pleura or hematogenous seeding. Regardless, given that the patient was previously healthy without history of local trauma or immune compromise, one can assume that this deep space abscess was an unusual, and not previously described, sequella of influenza.

344 OVARIAN MUCINOUS CYSTADENOMA IN AN ADOLESCENT

C Smith, C Antunez, N Evans, E Klepper. *Our Lady of the Lake Children's Hospital, Baton Rouge, LA.*

10.1136/jim-2016-000393.344

Case Report Ovarian mucinous cystadenoma arises from the ovarian surface epithelium. These tumors are normally benign with only 10% having a malignant component. They are the most common mucinous ovarian tumors and account for 20–25% of all benign ovarian tumors. The peak incidence occurs between the third and fifth decade. They are rare among adolescents but have been documented. The most common presenting symptoms are due to mass effect and include abdominal pain, increased abdominal girth, and persistent abdominal bloating. We describe a case of an adolescent female with an ovarian mucinous cystadenoma.

A 12-year-old female with a history of generalized anxiety disorder and chronic constipation presented to our hospital for evaluation of abdominal distension that was first noted 4 weeks prior. Abdominal films showed a non-specific bowel gas pattern with moderate stool in the colon and no appreciable abdominal mass. On physical exam, the patient's abdomen was noted to be soft, non-tender but diffusely distended. She was discharged with polyethylene glycol and PCP follow-up. The patient returned to our hospital four days later due to worsening abdominal distension. Repeat abdominal x-ray showed moderate gas in small intestine and descending colon, but appeared gasless in-between. Contrast abdominal CT showed a 22×14×31 cm cystic mass possibly of ovarian origin. All tumor markers were within normal limits. Pediatric surgery performed an exploratory laparotomy which revealed 4 kilogram right-sided ovarian mass. Initial pathology and fluid cytology were consistent with mucinous cystadenoma.

The patient did well post-operatively and was discharged home with oncology follow-up to review final pathology.

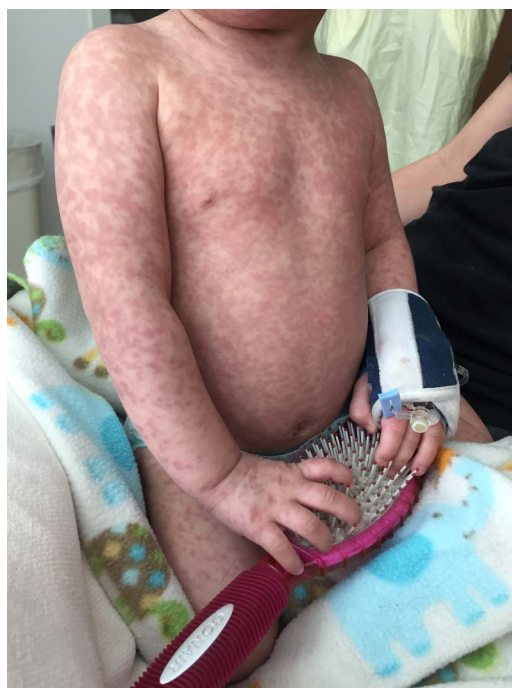Increased abdominal girth in an adolescent female is typically gastrointestinal in origin but gynecologic causes must also be considered. Most ovarian masses are physiologic; however, neoplasms do occur. Primary imaging studies should include transabdominal or transvaginal ultrasonography. MRI or CT with PO and IV contrast can provide further clarification for indeterminate lesions. Observation is the preferred treatment for functional ovarian cyst while neoplasms are treated with resection. For mucinous cystadenoma, resection is curative and does not increase the risk of future ovarian malignancy.

345 VACCINE-INDUCED MEASLES IN AN IMMUNOCOMPETENT 13-MONTH OLD PATIENT

SB Sood, K Suthar, K Mather. *The University of Oklahoma School of Community Medicine, Tulsa, OK.*

10.1136/jim-2016-000393.345

Case Report We describe a case of vaccine-induced measles, positive by polymerase chain reaction (PCR) and IgM, in a 13-month-old immunocompetent male who developed prodromal symptoms seven days after receiving his first dose of the Measles Mumps and Rubella (MMR) vaccine. The patient had neither an identified exposure to a measles case nor travel outside of his residence in Oklahoma and therefore the first dose of the attenuated MMR vaccine is the only known source leading to his acute measles illness. Four reports exist regarding vaccine-associated measles in children and there is an overall low risk of transmission from vaccine-associated measles. This case has important implications for reviewing



Abstract 345 Figure 1

public health interventions to determine epidemiological links in geographical areas with low incidence of measles and also highlights the importance of vaccine safety and monitoring.

346 TERM NEONATE WITH BILATERAL UPPER LIMB HYPOTONIA

A Taneja, K makker, R Alissa, C Arango. *UF College of Medicine Jacksonville, Jacksonville, FL.*

10.1136/jim-2016-000393.346

Case Report A full term infant is born to a 21 yr. old. G3P2003 mother with inadequate prenatal care. Maternal prenatal labs including human immunodeficiency virus (HIV), Hepatitis B, Rapid plasma reagin (RPR), group B streptococcus (GBS) and blood type are unknown but drawn and pending. Baby is born by an uneventful but precipitous spontaneous vaginal delivery.

In the first 12 hrs. after birth baby shows signs of hypothermia, tachypnea, hypotonia of both upper limbs, high pitched cry and increased irritability and tenderness even on gentle handling of the upper extremities. Neurological exam further reveals weak palmar grasp, delayed and incomplete Moro reflex bilaterally and inability to elicit active wrist extension bilaterally. Rest of the neurological exam is benign with normal generalized activity and normal lower limb tone and reflexes. There is no reported shoulder dystocia or birth trauma or difficult extraction

Chest X-ray reveals minimal interstitial fluid in the lung fields and no clavicle fractures.

Maternal HIV, Hepatitis B and GBS were negative . RPR in mom is reported positive at 1:32. TPA (Treponema pallidum agglutination) to confirm the positive RPR was sent and was pending at the time of initial work up on the baby.

Initial sepsis screen including CBC and blood culture was sent on the newborn along with liver function tests, hepatitis C antibody and RPR. Blood culture was negative and the liver function tests were within normal limits.

RPR on the neonate was eventually reported positive (1:16) and CSF VDRL was also positive at 1:1. Neonate's FTA-ABS was also positive. Maternal TPA also came back to be positive by day of life 3 thus confirming the diagnosis to be of untreated maternal syphilis and congenital neonatal neurosyphilis with bilateral upper extremity weakness likely secondary to pseudo paresis or palsy from syphilis.

Crystalline penicillin was given for possible neonatal syphilis.

Further work up of the neonate included an ophthalmologic assessment and long bone X-rays. X-rays showed serrated appearance at the distal metaphyses with faint lucent metaphyseal bands likely indicating syphilitic changes in bilateral femur. Ophthalmologic assessment was normal

After the initial symptoms baby had no more issues during the hospital stay for treatment for congenital neurosyphilis.

347 SYMPTOMATIC VARIATION OF CMV INFECTION IN A TWIN GESTATION

H VanderVelde. *University of Florida-Jacksonville, Jacksonville, FL.*

10.1136/jim-2016-000393.347

Case Report Dichorionic/diamniotic twins were born at 33 weeks of gestation to a 23 year old gravida 4, para 3 mother. Her pregnancy was complicated by polysubstance abuse, hepatitis C infection, late prenatal care, and bipolar disorder. The mother experienced preterm labor and twin neonates were delivered via urgent C-section due to malpresentation and vaginal bleeding. At birth, twin A had diffuse purpuric rash consistent with 'blueberry muffin' appearance, hepatosplenomegaly, and jaundice. There was suspicion for CMV infection which was later confirmed by CMV PCR. She was also noted to have thrombocytopenia ($35,000$ platelets/ mm^3) on initial CBC. Twin B had no such rash, and no signs of hepatosplenomegaly or jaundice. She became thrombocytopenic during her hospital course ($44,000$ platelets/ mm^3). CMV PCR returned positive on Twin B as well. Both twins were started on valganciclovir; Twin A's treatment course was complicated by severe neutropenia. Head ultrasound and brain MRI were performed on both twins; twin A had multiple intracranial calcifications including cerebellar calcification and mineralizing vasculopathy and twin B had only mild punctate periventricular calcifications.

CMV is the most common congenital viral infection, with most infections being asymptomatic. Whether symptomatic or asymptomatic at birth, the disease can come with devastating long-term sequelae. This case demonstrates the clinical variability of symptoms between twins. There have been few reports of similar occurrences.

The reasons for varying clinical manifestations in twins with CMV infection are not completely understood. Analyzing symptomatic variation in twins allows for a greater understanding of this common disease and provides insight into how and why clinical variability occurs in genetically similar individuals.

348 HELP! I CAN'T GET UP – HYPOKALEMIC PERIODIC PARALYSIS

B Wagner, E Klepper, K Iheagwara. *Our Lady of the Lake, Baton Rouge, LA.*

10.1136/jim-2016-000393.348

Case Report Hypokalemic periodic paralysis (HPP) disorder is a rare neuromuscular disorder affecting an estimated 1 in 100,000 individuals. It is characterized by acute episodes of painless, generalized weakness with preservation of consciousness and respiration during periods of hypokalemia. HPP first presents in adolescence and ultimately develops into a progressive proximal muscle myopathy during the sixth decade of life. Episodes of HPP are exacerbated with fasting, high carbohydrate meals, and strenuous exercise. Most cases are inherited but there are acquired forms as well. We present a teenager with initial symptoms secondary to viral illness who was ultimately diagnosed with HPP.

A 17-year old male presented with headache, fever, and acute onset of quadriparesis. Several days prior he was seen with complaint of headache, dizziness, and neck pain. He was diagnosed with migraine after normal head CT and discharged home. He returned for reevaluation due to persistent pain and new fever. During the encounter, CSF studies were unremarkable and CBC indicated viral process. He

was subsequently discharged home. Later that evening, he developed profound bilateral upper and lower extremity weakness and was found by family on the floor, unable to move. During the final visit, labs demonstrated hypokalemia of 2.0 with otherwise normal labs and EKG. With slow replenishment of potassium the patient's quadriplegia resolved. He was discharged home with acetazolamide for prophylactic therapy.

HPP is caused by genetic mutations affecting the alpha-1 subunit of dihydropyridine-sensitive calcium channels in skeletal muscle. Clinical penetrance of the disorder varies per mutation and is documented to have almost three to four times more clinical expression in males. HPP therapy includes abstaining from exacerbating factors and prophylactic medications aimed to prevent hypokalemia. Acute attacks of HPP are best treated with oral potassium supplements. HPP episodes decrease in frequency prior to the sixth decade of life. However, most patients develop a progressive proximal myopathy. This myopathy affects muscles of proximal upper and lower extremities as well as the pelvic girdle, with severity ranging from mild to severe. Clinicians should have high suspicion for HPP in the setting of acute apparent paralysis and hypokalemia.

349 HSV ENCEPHALITIS: WHERE'S THE HERPES?

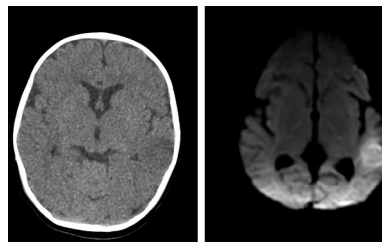
R Ward. *University of Florida - Jacksonville, Jacksonville, FL.*

10.1136/jim-2016-000393.349

Case Report An otherwise healthy 3 month old male presents with seizure-like episodes after 4 days of URI symptoms. While in the emergency room, he was noted to have 3 events in which he turned his head to the left, flexed his arms, and was non-responsive. The episodes lasted less than 1 minute before he returned to baseline. Mom noted he had 2 such events at home, but thought it was because of breathing difficulty from his cold. His only symptoms up to this point were runny nose and cough for 4 days with 2 episodes of vomiting the night before presentation. No fever, diarrhea, or rash.

Emergency department labwork, including urine drug screen, UA, CMP, CRP, CBC, and EKG, were all within normal limits. Head CT showed focal area of hypodensity in the left lateral temporal lobe most suggestive of ischemia and MRI was recommended. LP showed slight turbidity, RBC 2650, glucose 45, and protein 25. He was started empirically on acyclovir and admitted for further evaluation.

EEG confirmed subclinical seizures and levetiracetam was started. MRI brain showed an area of restricted perfusion/hyperintensity in the left superior temporal gyrus, suggestive of stroke. His brain was otherwise unremarkable, with normal MRA and MRV studies. Clinically the child was back to baseline with no residual weakness by the next day. CSF culture and gram stain, herpes simplex PCR, enterovirus PCR, and herpes nucleic acid amplification were all negative. Despite lack of microbiological evidence of herpes, it was decided that he would should continue acyclovir for the full course. Finally, on day 7 of admission, serologies for HSV IgG antibodies returned positive for



Abstract 349 Figure 1

HSV type II. He was discharged home on levetiracetam and with a PICC line to finish a 21-day course of acyclovir.

350 HYPOXIC ZEBRAFISH AND INOSITOL

S Williams. *UAB, Birmingham, AL.*

10.1136/jim-2016-000393.350

Purpose of Study The brain is highly sensitive to oxidative stress during periods of hypoxia. Modeling hypoxic brain injury in animals is a challenge for researchers. The zebrafish offers a feasible inexpensive system that can be used for these brain injury studies. There is little research on oxygen and oxidative stress in embryonic Zebrafish development and potential agents that may be neuroprotective. Inositol is of particular interest because of its presence in foods and its pivotal role in neural signaling. Furthermore, inositol can be used as a vitamin supplement but it is not an essential vitamin. It has also been found that inositol can be a key regulator in brain and bone development.

Methods Used We hypothesize that nitrogen will deplete oxygen causing a hypoxic state in Zebrafish embryos and induce brain injury. However, embryos pre exposed to inositol in vitro will be protected from brain injury and have a higher percentage survival rate. In this study, embryonic Zebrafish were exposed to waterborne concentrations of inositol prior to 8 minutes of nitrogen bubbling.

Summary of Results As a result, inositol pretreated embryos survived at a higher percentage rate after 20 minutes of injury and completely recovered after 24 hours of injury.

Conclusions These findings could suggest that inositol is neuroprotective in Zebrafish embryos and may need to be studied in a larger animal model.

351 URETERAL STENOSIS OF THE TRANSPLANT KIDNEY DUE TO BK POLYOMA VIRUS NEPHROPATHY (BKVN) IN A PATIENT WITH BILATERAL WILMS TUMOR AND EPIDERMOLYTIC HYPERKERATOSIS

R Propper, L Kidd, A Paramesh, I YOSYPYV. *Tulane University School of Medicine, New Orleans, LA.*

10.1136/jim-2016-000393.351

Case Report A 13 year old Africa American with history of bilateral Wilms tumor resulting in ESRD s/p kidney transplant 3 months prior to presentation, LVH secondary to hypertension, and epidermolytic hyperkeratosis was

found to have plasma creatinine of 3.3 mg/dL (baseline creatinine of 0.9 mg/dL), hyperkalemia (6.5 mmol/L) and severe metabolic acidosis at routine clinic visit that necessitated acute hemodialysis. Ultrasound of the transplant kidney showed severe hydronephrosis with good blood flow. A foley catheter was placed to decompress the bladder. Nephrostogram revealed long ureteral stricture and prompted placement of nephrostomy tube with subsequent resolution of hydronephrosis. In situ hybridization of transplant kidney biopsy specimen showed presence of BKV and absence of graft rejection or interstitial nephritis. Plasma BKV qPCR showed viral load of 6 million copies/ml. Immunosuppressive therapy was modified by replacing mycophenolate mofetil with Leflunomide. Subsequently, ureteral stenosis was repaired by Boari flap procedure. These interventions resulted in normalization of graft function and resolution of BKV viremia. This case illustrates a need for high index of suspicion for BKVN causing ureteral stenosis which presents with signs of urinary tract obstruction and reduced graft function. Management includes reduction of immunosuppression, initiation of specific antiviral therapy and surgical relief of obstruction.

Perinatal Medicine

Joint Plenary Poster Session and Reception

4:30 PM

Saturday, February 11, 2017

352 MATERNAL OPIATE AND TOBACCO USE: EFFECTS ON INTERMITTENT HYPOXEMIA IN PRETERM INFANTS

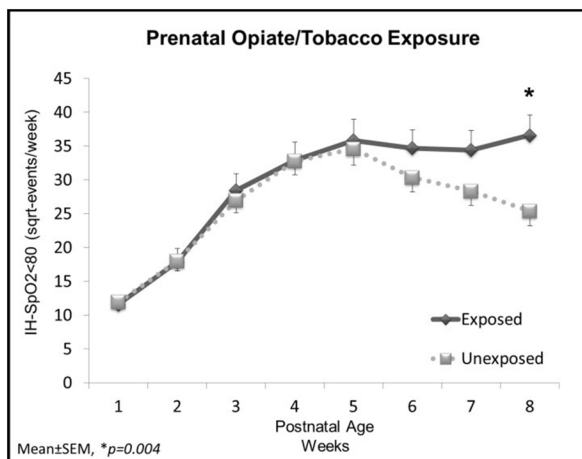
EG Abu Jawdeh,¹ A Pant,¹ D Mamilla,² A Gabrani,³ P Westgate,¹ A Patwardhan,¹ J Bauer,¹ H Bada,¹ P Giannone¹. ¹University of Kentucky, Lexington, KY; ²Wayne State Univeristy, Lexington, MI; ³CHOP, Philadelphia, PA.

10.1136/jim-2016-000393.352

Purpose of Study Maternal substance use during pregnancy may be associated with cardiopulmonary instability in infants. Intermittent hypoxemia (IH) is episodic drops in oxygen saturation. Preterm infants have rising IH frequency, peaking at 4–5 wks postnatal age where IH plateaus (5–8 wks). We tested the hypothesis that preterm infants with prenatal opiate/tobacco exposure have higher IH frequency during first 8 wks of life.

Methods Used Oxygen saturation (SpO₂) was continuously monitored using pulseoximeters with 2 s averaging/1 Hz sampling rate. Infants with gestational age (GA) ≤ 29 wks were included. Novel software was used to analyze SpO₂ data. Prenatal opiate/tobacco exposure was collected from records/toxicology screens. Primary outcome (IH-SpO₂ < 80) defined as drop in SpO₂ < 80% (4–180 s). We adjusted for GA, birthweight, gender, and Apgar scores.

Summary of Results Total of 88 infants ≤ 29 wks GA were enrolled. Analyzable data was present for 73 patients (29 opiate and/or tobacco exposed, 44 unexposed). There was higher IH-SpO₂ < 80 in exposed group beyond the 4–5 wk peak that was significant at 8 wks, $p=0.004$ (figure). Difference persisted after adjustment, $p=0.02$.



Abstract 352 Figure 1

Conclusions This pilot project shows prenatal opiate/tobacco exposure may contribute to increased IH and subsequent morbidities. A larger cohort aimed at understanding these relationships may have a direct impact on management of preterm infants.

Gerber Foundation

353 DOES DONOR HUMAN MILK IMPACT NEONATAL ABSTINENCE SYNDROME?

C Alexander, P Radmacher, LA Devlin. University of Louisville, Louisville, KY.

10.1136/jim-2016-000393.353

Purpose of Study Neonatal Abstinence Syndrome (NAS) is a drug withdrawal syndrome that occurs primarily after antenatal exposure to opiates. Symptoms may be present at birth, but often peak at 48–72 hours after delivery. The onset of symptoms is affected by the half-life of the opiate used during pregnancy in combination with maternal and infant metabolism. One of the postnatal challenges for infants with NAS is feeding intolerance. The use of mother's own milk has been reported to improve NAS scores and/or reduce the duration of pharmacologic treatment when compared to formula feeding. However, the AAP considers the unsupervised use of opiates during pregnancy in conjunction with marijuana, cocaine, methamphetamines, and other street drugs to be a contraindication for breastfeeding. We hypothesized that donor human milk may have similar efficacy to mother's own milk for infants with NAS who are unable to breastfeed.

Methods Used The University of Louisville Institutional Review Board approved this study. Following maternal consent, infants with NAS who required pharmacologic treatment were fed only donor human milk (Co-op donor milk, Medolac Laboratories, Lake Oswego, OR) for a period of 2 weeks once initial withdrawal symptoms were stabilized on morphine. Finnegan scores were assessed per hospital protocol and oral morphine dosing was per a standardized NAS protocol. Twelve infants were enrolled in the study and 9 infants completed at least 7 days of exclusive donor milk feedings. The infants in the study who

completed at least 7 days of treatment were then matched one to one with historic control infants who were primarily formula fed. Total Finnegan scores, GI sub-scores, total length of treatment, and need for adjuvant pharmacologic therapy were compared.

Summary of Results Median Finnegan scores and median GI sub-scores were compared and were not statistically different between the study and control groups. The duration of pharmacologic therapy and need for more than one drug to control symptoms were also not statistically significant between the groups.

Conclusions The present pilot study suggests that feeding with donor human milk is comparable to formula feeding and may not hold the same efficacy as mother's own milk for infants with NAS. However, this study was limited by a small number of patients.

354 NOVEL GENETIC MUTATION OF MICROVILLUS INCLUSION DISEASE-LIKE PHENOTYPE

JD Antonishek, V Shiu, CL Blanco, N Mittal. *University of Texas Health Science Center San Antonio, San Antonio, TX.*

10.1136/jim-2016-000393.354

Introduction Microvillus Inclusion Disease (MVID) was first described in 1978 with presentation of severe watery diarrhea with only slight response to bowel rest, failure to thrive, and metabolic acidosis. Mutations in the *Myo5B* gene have been identified as causative for MVID. Recently, a second gene was identified (*STX3*) with only two reported cases in the literature and phenotype limited to intestinal disease. We report a third patient with the novel *STX3* mutation with MVID-like phenotype and neurological involvement.

Case Report A term male was born via C-section with apgar scores 7/9. The pregnancy had been complicated by consanguinity, polyhydramnios, pre-eclampsia, and chorioamnionitis. Exam was remarkable for abdominal distension. X-rays, contrast enema and abdominal ultrasound were unremarkable. The patient passed meconium and feeds were advanced. On routine lab monitoring, the patient had severe metabolic acidosis (HCO_3^- 12 mEq/L and anion gap of 14 mEq/L). He was made NPO and total parenteral nutrition (TPN) was initiated. Acidosis corrected with TPN and feeds were resumed. Once at full feeds the patient became severely acidotic, feeds were held and TPN initiated. This cycle recurred despite multiple changes in enteral nutrition. His clinical course was remarkable for emesis, mild diarrhea (mucoid string-like stool or crystals scattered throughout yellow gelatinous stool), and abnormal neurological exam (nystagmus, staring spells, and hyper/hypotonia). GI series, metabolic and cystic fibrosis work-up, and stool studies were all normal. Esophagogastroduodenoscopy/sigmoidoscopy revealed features of MVID which was confirmed by biopsy. Whole exome sequencing was positive for a homozygous gene mutation at *STX3*.

Discussion This case demonstrates a unique presentation of MVID in a patient with a rare genotype. Unlike the typical presentation, our patient never demonstrated severe, watery diarrhea yet wasn't able to tolerate enteral

nutrition. Furthermore, neurological findings have never been described in MVID with this novel mutation. It is important to consider MVID in the differential of an infant with abnormal stools, metabolic acidosis, and neurologic symptoms, and to consider intestinal biopsy and genetic testing for this condition.

355 ARE WE WHAT WE EAT? MICROBIOME OF HUMAN MILK AND COLONIZATION OF NEONATAL GUT

M Assad, E Brownell, M Caimano, J Hagadorn, J Trzaski, A Matson. *Connecticut Children's Medical Center, Hartford, CT.*

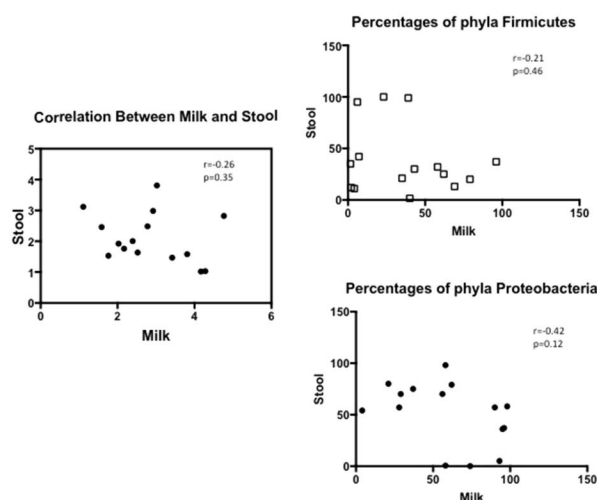
10.1136/jim-2016-000393.355

Purpose of Study Preterm human milk (HM) contains commensal bacteria, many of which are thought to originate via the entero-mammary pathway. Following birth, HM feeding critically influences neonatal gut flora; however, to date no study has evaluated the role of HM microbiome in facilitating this process.

To evaluate the relationship between preterm HM microbiome and neonatal gut microbiome.

Methods Used Twenty-four hour pooled preterm HM samples were collected on postnatal weeks 1–4; these samples were matched with infants' corresponding stool samples to evaluate associations. All samples were subjected to 16S rRNA microbial analysis. The resultant data were assessed using Pearson's correlation and Kruskal-Wallis. Significance was defined as $P \leq 0.05$.

Summary of Results An adequate 16S product was detected in 15/21 (71%) paired HM/stool samples. *Proteobacteria* and *Firmicutes* were the most highly represented phyla in both HM and stool samples. Alpha diversity, as reflected by the Simpson Diversity Index (SDI), did not significantly change in either HM or stool samples during the intervals studied. There were no significant correlations between the percentages of *Proteobacteria* ($r = -0.42$; $P = 0.12$) or *Firmicutes* ($r = -0.21$; $P = 0.46$), or in the SDI ($r = -0.26$, $P = 0.35$) between the matched HM/stool samples.



Abstract 355 Figure 1

Conclusions In our sample, the presence of 2 major phyla in HM are not associated with colonization patterns in the neonatal gut. Additional factors such as antibiotics, antacids, HM oligosaccharides, and gestational age will be addressed in future analyses. The immunologic properties of HM regulating colonization of the neonatal gut warrants further research.

356 REDUCING SEVERE INTRAVENTRICULAR HEMORRHAGE IN EXTREME PREMATURITY: QUALITY IMPROVEMENT INITIATIVE

A Patra, P Bhandary, M Hanna, E Abu Jawdeh, G Barber, L Subedi, A Carpenter, S Haynes, P Giannone. *Kentucky Children's Hospital, University of Kentucky, Lexington, KY.*

10.1136/jim-2016-000393.356

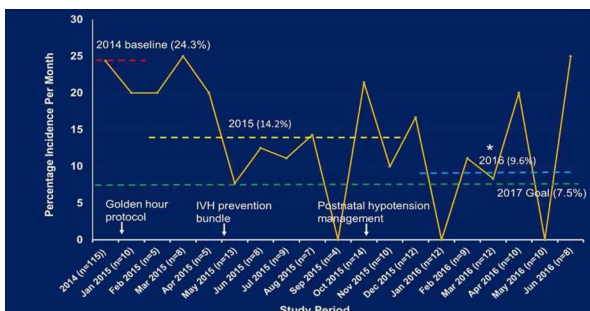
Purpose of Study Severe Intraventricular hemorrhage (SIVH) is a major cause of neurodevelopmental impairment in extreme prematurity. Our SIVH incidence in 2014 was significantly higher than mean incidence in Vermont Oxford Network registry despite adequate compliance with antenatal steroids and magnesium sulfate administration. We aimed to reduce SIVH incidence by 50% by modifying risk factors in postnatal care.

Methods Used We instituted evidence based guidelines to control SIVH risk factors between Jan-Oct 2015 for 2 years. A) Golden hour protocol for timely and effective stabilization in first hour of life. B) IVH prevention bundle implementing volume targeted ventilation, blood gas management, minimizing handling/pain and optimal head positioning C) Management of hypotension allowing 'permissive' hypotension, avoiding volume bolus and promoting early infusion of dopamine.

Tiny baby checklist developed to review protocol adherence and Plan-Do-Study-Act cycle changes. SIVH recorded on day of life 7 cranial ultrasound. SIVH incidence in retrospective cohort of infants (Jan-Dec 2014) compared with a prospective cohort after protocol implementation.

Summary of Results SIVH incidence was 24.3% (n=115) in 2014. Initiation of standardized protocols led to decrease in SIVH to 14.2% (n=112) in 2015 (p=0.065). Significant decrease in SIVH incidence noted in 2016 to 9.6% (n=61), data analyzed until June 2016 compared to 2014 (*p=0.026, Fisher's exact test)

Conclusions SIVH reduction in extreme prematurity can be achieved using standardized clinical protocols and quality improvement measures.



Abstract 356 Figure 1

357 HIGHEST OXYGENATION INDEX IN FIRST 48 HOURS PREDICTS OUTCOME IN LEFT-SIDED CONGENITAL DIAPHRAGMATIC HERNIA

AS Bruns,^{1,2} P Lau,¹ G Dhillon,^{1,2} JA Kailin,^{1,2} GB Mallory,^{1,2} P Lohmann,^{1,2} O Olutoye,^{1,2} R Ruano,³ CJ Fernandes^{1,2}. ¹Baylor College of Medicine, Houston, TX; ²Texas Children's Hospital, Houston, TX; ³Mayo Clinic, Rochester, MN.

10.1136/jim-2016-000393.357

Purpose of Study To assess predictive value of oxygenation index (OI) on pulmonary morbidity and mortality in left-sided congenital diaphragmatic hernia (CDH) patients.

Methods Used Medical records of all inborn infants with a prenatal diagnosis of isolated left-sided CDH treated at this tertiary referral center from January 2012 to April 2016 were reviewed. The highest OI values in the first 48 hours of life were calculated and compared to survival at 6 months along with pulmonary discharge parameters. Pulmonary parameters included respiratory support and medications for pulmonary hypertension at discharge and length of stay (LOS).

Summary of Results Of 40 patients, 16% of patients died prior to discharge. 32% of patients were discharged on pulmonary medications. Higher OI in the first 48 hours of life exhibited a statistically significant correlation with LOS (p=0.020) with predicted LOS increasing by 1.2 days for every one-unit increase in OI. Respiratory support status at discharge was assigned a score (RSS) (1-no support, 2-nasal cannula, 3-ventilator, 4-death). There was a highly significant association with a higher OI and RSS (SCC=0.752, p<0.001), even after adjusting for 5 minute APGAR and gestational age (OR=1.09, 95% CI 1.04–1.14, p<0.001). A higher OI was also associated with significantly higher odds of death after adjusting for 5 minute APGAR & gestational age (aOR=1.06, 95% CI:1.02–1.11, p=0.008).

Conclusions Higher OI values in left-sided CDH patients during the first 48 hours of life are associated with mortality and respiratory morbidity including length of hospital stay, respiratory medications and respiratory support at discharge.

358 SUBSTANCE ABUSE DURING PREGNANCY IS ASSOCIATED WITH INCREASED INCIDENCE OF GASTROSCHISIS: AN ANALYSIS OF THE NATIONAL KIDS' INPATIENT DATABASE

J Desai, J Patel, M Patel. *University of Mississippi Medical Center, Jackson, MS.*

10.1136/jim-2016-000393.358

Purpose of Study So far the only strong evidence based risk factor identified for gastroschisis is a young maternal age. There is still a need for large population based studies to identify risk factors associated with gastroschisis.

Aims: (1) Describe the prevalence trend for congenital abdominal wall defect. (2) Study the association of gastroschisis and omphalocele with maternal substance abuse.

Methods Used We accessed the national multicenter Kids' Inpatient Database (KID) Healthcare Cost and Utilization Project (HCUP) including admissions at age≤30 days with

Abstract 358 Table 1 Relationship of Maternal Substance Abuse with Abdominal Wall Defects

		Maternal Substance Abuse		Statistical Values		
		Yes	No	p value	Unadjusted OR (95% CI)	Adjusted OR (95% CI)*
Abdominal Wall Defect	Yes	333 (2.5%)	13136 (97.5%)	0.000	2.4 (2.22–2.76)	2.7 (2.30–3.22)
	No	135948 (1.0%)	13318710 (99.0%)			
For Year 2012 Only						
Gastroschisis	Yes	115 (4.4%)	2496 (95.6%)	0.000	3.1 (2.55–3.81)	3.0 (2.50–3.79)
	No	56283 (1.4%)	3875461 (98.36%)			
Omphalocele	Yes	21 (2.6%)	802 (97.4%)	0.012	1.8 (1.17–2.97)	1.12 (0.98–2.94)
	No	56378 (1.4%)	3877155 (98.6%)			

* Adjusted for Sex, Race, Geographic location of hospital (Northeast, Midwest, South, West), Size of hospital (Small, Medium, Large), Teaching status of hospital (Rural, Urban non-teaching, Urban teaching) via Binary logistic regression analysis.

ICD-9 codes of congenital abdominal wall defects (756.70–756.79) during years of 2003, 2006, 2009 and 2012. We used only year 2012 for maternal substance abuse analysis. Weight based analysis was performed using complex sample function of SPSS 22.0.

Summary of Results Prevalence of congenital abdominal wall defects is increasing with the rate of 8.6, 9.8, 10.6 and 10.7 per 10,000 neonatal admissions during years of 2003, 2006, 2009 and 2012 respectively. For year 2012, total 823 cases of omphalocele and 2610 cases of gastroschisis were included in further analysis (Table 1). Cocaine exposure was higher for omphalocele (25.0 % vs 9.2 %, $p=0.11$) but not statistically significant while opioid exposure was significantly higher for gastrochisis (80.2 % vs 62.8%, $p=0.004$).

Conclusions Incidence of abdominal wall defects is increasing. Maternal substance abuse is associated with higher abdominal wall defects in neonates. Gastroschisis has strong association with maternal substance abuse as compared to omphalocele. Possible association: opioids with gastroschisis and cocaine with omphalocele but these associations needs more evaluation.

359 DECREASING TOTAL DRUG EXPOSURE AND LENGTH OF STAY WHILE COMPLETING WITHDRAWAL FOR NEONATAL ABSTINENCE SYNDROME DURING THE NEONATAL HOSPITAL STAY

LA Devlin,¹ P Radmacher,¹ T Lau². ¹University of Louisville, Louisville, KY; ²University of Louisville, Louisville, KY.

10.1136/jim-2016-000393.359

Purpose of Study Neonatal Abstinence Syndrome (NAS), a rapidly growing public health concern, has considerably increased healthcare utilization and healthcare costs. In an effort to curtail costs, attempts have been made to complete withdrawal as an outpatient. This has led to prolonged exposure to medications which may negatively impact neurodevelopmental and behavioral outcomes. We hypothesized that the implementation of a modified NAS protocol would decrease total drug exposure and length of stay while allowing for complete acute drug withdrawal during the neonatal hospital stay.

Methods Used The University of Louisville Institutional Review Board approved this study. Data were derived from

medical records of term (≥ 37 0/7) infants with NAS treated with pharmacologic therapy in the University of Louisville Hospital NICU from 2005 to 2015. The pharmacologic protocol (P1) for infants treated between 2005 and March 2014 ($n=146$) dosed oral morphine every 4 hours and utilized phenobarbital as adjuvant therapy. Protocol 2 (P2) initiated after March 2014 ($n=44$) dosed morphine every 3 hours and used clonidine as adjuvant therapy. Charts were reviewed for demographics including sex, gestational age and birth weight. Maternal drug history and maternal and infant toxicology screens were recorded. The length of morphine therapy and need for adjuvant drug was noted. Length of stay was derived from admission and discharge dates.

Summary of Results The length of morphine therapy was decreased from 35 to 26.5 days; a 23.7% reduction (95% CI 12.5–33.3%) for infants treated with P2 vs P1 ($p<0.001$). The need for adjuvant pharmacologic therapy was decreased by 24% in patients treated with P2 vs P1 ($p=0.004$). The length of stay was decreased from 42 days to 33 days a 22.5% reduction (95% CI 12.4%–31.3%) for infants treated with P2 vs P1 ($p<0.001$). The decreased length of stay resulted in an average reduction of hospital charges by \$27,090 per patient in adjusted 2015 US Dollars.

Conclusions The present study demonstrates that total drug exposure and length of stay can be reduced while successfully completing acute withdrawal during the neonatal hospital stay.

360 POSTMENSTRUAL AGE FOR DISCHARGE READINESS IN VERY LOW BIRTH WEIGHT INFANTS

L DiAngelo, R Dhanireddy. University of Tennessee Health Science Center, Memphis, TN.

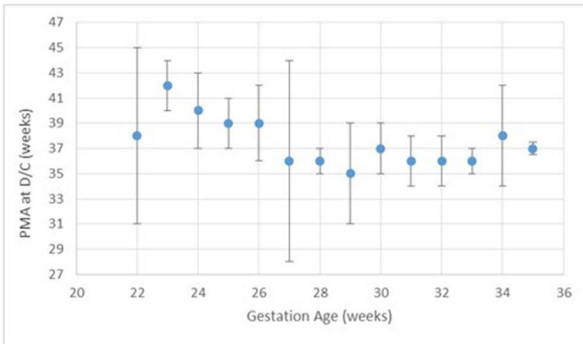
10.1136/jim-2016-000393.360

Purpose of Study To determine the postmenstrual age (PMA) at which very low birth weight (VLBW) infants, ≤ 1500 gms, will be off thermal support (incubator or warmer), take all enteral feeds via nipple feeding, and are discharged home.

Methods Used Medical records of 274 VLBW infants discharged home from the neonatal intensive care unit

Abstract 360 Table 1

Variable	PMA (wks)	Weight (gms)
All nipple feeds	36±2	1959±382
No thermal support	36±3	1976±272
Discharge home	38±3	2351±545



Abstract 360 Figure 1 GA vs. PMA at discharge in VLBW infants

between January 2014 and April 2016 were reviewed. The following data were collected: gestational age (GA), birth weight (BW), gender, antenatal steroid exposure, need for respiratory support, along with PMA at the time infant was off thermal support, was on full enteral feeds via nipple feeding, and discharged home. Data are presented as mean ±SD.

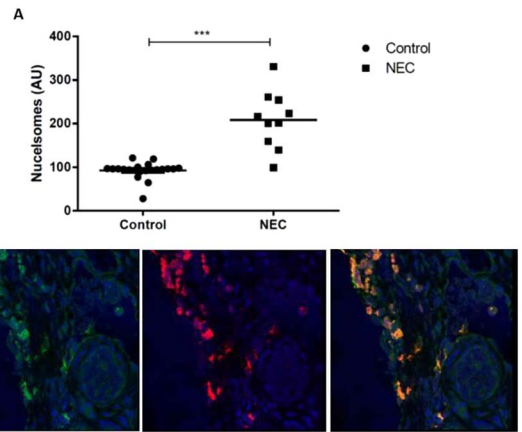
Summary of Results GA and BW were 29±3 wks and 1108±284 gms respectively. 237 (86%) were African American infants and 144 were male. Gender had no effect on PMA to full nipple feeds, coming off of thermal support, or discharge home. Infants who were exposed to antenatal steroids were off thermal support at a PMA of 36 ±2 wks compared to 37±2 wks non-exposed ($p<0.04$). Infants who were on any type of respiratory support were significantly delayed in time to full feeds (36±2 vs. 35±1 weeks; $p<0.03$) and discharge home (38±3 vs. 37±2 wks; $p=0$). GA significantly influenced PMA to full nipple feeds ($r -0.16$; $p<0.01$) and PMA to discharge ($r -0.33$; $p=0$). After controlling for GA, need for respiratory support was not significantly associated with PMA to full feeds and PMA to discharge.

Conclusions Our study provides guidance on expected PMA for discharge readiness in VLBW infants based on gestational age at birth.

361 CIRCULATING HISTONES AND NEUTROPHIL EXTRACELLULAR TRAPS IN NECROTIZING ENTEROCOLITIS

J Eckert,¹ H Chaaban,¹ M Escobedo,¹ F Lupu.² ¹OUHSC, Oklahoma City, OK; ²OMRF, Oklahoma City, OK.

10.1136/jim-2016-000393.361



Abstract 361 Figure 1

Purpose of Study NEC is characterized by inflammation and necrosis of the gut that can progress to SIRS, organ failure and death. Studies from our lab identified histones (his-DNA) as mediators and biomarkers in sepsis. High levels of his-DNA correlate with organ dysfunction and death in animals and humans with sepsis/SIRS. Histones release is either from apoptotic/necrotic cells, or from neutrophil extracellular traps (NETs). Based on neutrophil infiltration and intestinal necrosis that occur in NEC, we hypothesize that histones are released from NETs and/or damaged epithelium.

Methods Used His-DNA levels were measured in plasma of infants with NEC>stage 2 & compared to matched controls using Cell Death Detection ELISA (ROCHE). To determine if NET formation occur in intestinal tissue, double immunofluorescent staining for Cit-H4 (marker of NETs) and neutrophil elastase (NE) was performed on archived intestinal samples of NEC. Controls were samples from intestinal margins of infants <1 m who underwent surgery for atresia.

Summary of Results As shown in Figure A, his-DNA levels were significantly higher in NEC (n=11) compared to controls (n=22). In addition, levels were higher in non-survivors in the NEC group. Intestinal samples from infants with NEC revealed abundant NETs particularly in areas of necrosis, Figure B.

Conclusions We show that histones release and NET formation occur in infants with NEC. Since both NETs and histones contribute to SIRS and organ damage in many pathologies, further studies are needed to determine their role specifically in NEC.

362 THE ASSOCIATION BETWEEN FLUID INTAKE, POSTNATAL WEIGHT LOSS AND CHRONIC LUNG DISEASE IN ≤750 G BIRTH WEIGHT INFANTS

SM Goss, M Elkest, AJ Talati, M Elabadi. University of Tennessee Health Science Center, Memphis, TN.

10.1136/jim-2016-000393.362

Purpose of Study In infants ≤750 g birth weight (BW), an appropriate fluid intake and physiologic weight loss and

their relationship with chronic lung disease (CLD) are not well defined. We hypothesized that there is an association between increased fluid intakes in the first weeks of life, less weight loss, and an increased risk for the development of CLD. Our main objective was to describe the association between fluid intake in the first two weeks of life, percentage weight loss from birth weight, and the need of Oxygen at 36 weeks corrected gestational age (CGA).

Methods Used This was a retrospective chart review of infants with a birth weight ≤ 750 g that were discharged between January 2012 and May 2016. Infants that needed oxygen at 36 weeks CGA (OX36) were compared to those that were on room air (Air36). All total fluid intake included parenteral alimentation, drips, fluid boluses, feedings, and transfusions.

Summary of Results 61 infants, mean BW = 631 ± 102 g, were alive at 36 weeks CGA and 27/61 still required O₂. There was no difference in birth weight between groups. Air36 group had received on average 10 ml/kg/day less fluids than OX36 group during the first week of life, 139 ± 10 compared to 149 ± 17 ml/kg/day respectively, $p < 0.05$. They also had on average 3% more weight loss in this period and regained BW at DOL11 compared to the OX36 group which had a return to BW at DOL 8, $p < 0.05$. During first 11 days, an increase in weight loss by 1% from BW was associated with a 10% reduction to have an oxygen need at 36 weeks CGA, $p = 0.03$, OR = 1.105 95% CL 1.009–1.210.

Conclusions In infants with ≤ 750 g BW, maintaining all total fluid intake at < 140 ml/kg/day for the first 10 days was associated with a lower risk for developing CLD. Infants that developed an average physiologic weight loss of 3% during this 10 day period with a return to birth weight by DOL 11 also had a lower risk of CLD. We speculate that less water intake in the first 2 weeks of life may protect against other fluid dependent complications like patent ductus arteriosus and pulmonary edema and that in turn may lower the risk of developing CLD.

363 A SIMPLE INTERVENTION TO DECREASE TUBING FAT LOSSES IN CONTINUOUS FEEDS WITH HUMAN MILK

JM Hendrick, M Elabadi. *University of Tennessee Health Science Center, Memphis, TN.*

10.1136/jim-2016-000393.363

Purpose of Study Current literature suggests a significant amount of breast milk fat is lost due to tubing adsorption. Our hypothesis was residual milk in the feeding tubes can be given back to the infant to minimize these fat losses. Our objective was to compare fat content of delivered milk by two methods. For method 1, we gave residual BM left in feeding tube after continuous feeds back before analyzing fat content. For method 2, our current standard practice, we discarded BM left in tubing after continuous feeds were complete.

Methods Used For Method 1, the new method, 9 ml of fortified breast milk were prepared. One milliliter was used for baseline fat content, 2 ml were used to prime the pump tubing, and the last 6 ml were run at a rate of 2.67 ml/hr. At the end of the infusion, the 2 ml left in the tube were

pushed slowly into the collection cup with the rest of the breastmilk collected. For Method 2, our current standard practice, 12 ml of fortified breastmilk were prepared. One milliliter was used to measure baseline fat content, 2 ml were used to prime the pump tubing, and 8 ml were run at a rate of 2.67 ml/hr. The 1 ml left in the syringe and 2 ml left in the tubing were discarded. Ten runs of each method were performed. The change in fat content between the baseline breastmilk and the collected breastmilk were measured using the SpectraStar Human Milk analyzer.

Summary of Results With the new method, the mean drop in fat was $7.1 \pm 4.7\%$, compared to the traditional method where the mean drop in fat was $16.2 \pm 6.9\%$ with a $p = 0.0076$.

Conclusions Traditional infusion methods are associated with significant losses of fat. This simple intervention of preparing the exact amount or ordered milk and then infusing back the left over residual tubing milk will significantly decrease these fat losses.

364 A NEONATE WITH CONGENITAL FACIAL PALSY AND THROMBOCYTOPENIA

M Hills, J Patrick-Esteve. *Louisiana State University Health Science Center, Department of Pediatrics, Division of Neonatology, New Orleans, LA.*

10.1136/jim-2016-000393.364

Case Report Jacobsen syndrome, also known as 11 q terminal deletion disorder, is a rare disorder with a prevalence of approximately 1/1000 that is caused by partial deletion of the long arm of chromosome 11. The constellation of features seen in this syndrome include facial asymmetry, prenatal and postnatal growth difficulties, ear malformations, hearing impairment, immunodeficiency, multi-organ malformations, and thrombocytopenia, typically with large platelets.

We present a 35 week gestational age male with congenital unilateral right facial palsy and thrombocytopenia. The infant was born by vaginal delivery due to uncontrolled gestational diabetes, symmetrical intrauterine growth restriction, and concern for fetal well-being. Significant physical examination findings included dysmorphic right ear, asymmetric facies, and right lagophthalmos consistent with unilateral right facial palsy. Laboratory studies were significant for persistent thrombocytopenia of unclear etiology and a negative evaluation for congenital infection. Echocardiogram was notable for a small muscular ventricular septal defect and possible bicuspid aortic valve. Right hearing loss was confirmed by audiology evaluation. Given the multiple congenital anomalies and thrombocytopenia, Jacobsen Syndrome was suspected and results of testing are pending.

This case points out the importance of a careful and thorough physical exam on each newborn after delivery. Congenital facial paralysis is an uncommon condition that can preclude a number of issues for an affected neonate, including corneal abrasions and feeding difficulties. Although often caused by perinatal trauma, it is imperative to consider syndromic causes, such as Jacobsen Syndrome, based on pertinent physical examination and laboratory findings.

365 LACTIC ACIDOSIS AND METABOLIC ALKALOSIS IN THE SAME BABYP Jain, J Phillips. *University of Alabama at Birmingham, Birmingham, AL.*

10.1136/jim-2016-000393.365

Case Report This 33 week girl was born via C section for NRFHR to a 20 y/o P0000. Mom had PPRM and metabolic alkalosis with hypochloremia and hypokalemia due to 3 day h/o nausea and vomiting. Maternal labs showed a lactate of 4.7, HCO₃ 51, WBC 20 k and urinalysis with nitrites but negative culture. Mom had developmental delay, muscular dystrophy, short stature with balanced Robertsonian 13;14 translocation. Father had a h/o autism. Mom had a brief 20 second seizure with hypotension (BP 50/20) in the OR that resolved without intervention. Baby required bag and mask for 2 min after delivery. Apgars were 1 and 7. BW was 2.27 kg (68%), Length 45 cm (65%), HC 30 cm (36%). Exam showed hypotonia and a grade 1 systolic murmur. Abdomen was non-distended with prominent liver but no splenomegaly. Baby was admitted on room air but switched to NIPPV and then conventional ventilation due to frequent apnea. Initial ABG had a pH of 7.28, PCO₂ 68, HCO₃ 32 and lactic acid >15. Extensive w/u included serum AA, and acylcarnitine, urine OA, and ketones, lumbar puncture. Antibiotics and acyclovir were stopped after 2 days. Workup showed mild elevation of alanine and multiple other AA which were non-specific. Urine ketones were negative. Serum pyruvate was 0.72. Serum ammonia and LFTS were elevated and CK was 1311. Abdominal sonogram showed hepatomegaly. Echo was normal. Serial ABG showed elevated lactate levels which trended down to 1.9 by DOL 6. The HCO₃ trended down from 37 to normal and Cl increased from 79 to normal by DOL 3. Baby was weaned to room air by DOL 3. LFTS were normal by 2 weeks. Karyotype and array CGH showed balanced Robertsonian 13:14 translocation and deletion at 15 q 11.2 respectively.

This case is unique with both lactic acidosis and metabolic alkalosis in the same baby at birth. The high HCO₃ levels in baby could be due to maternal elevated HCO₃ levels. The perinatal insult could have caused lactic acidosis. The infant's liver dysfunction and hyperammonemia are consistent with a 'shock liver' pattern. The results of initial workup are nonspecific and likely secondary to liver dysfunction. The balanced Robertsonian 13;14 translocation is not likely to be of clinical significance. Deletion at 15 q11.2 has been reported in association with developmental delay, intellectual disability, ADHD, autism, seizures, and schizophrenia.

366 BRAIN ABNORMALITIES, LACTIC ACIDOSIS, AND HYPOTONIA IN A NEONATEN Kabani, J Phillips. *University of Alabama, Birmingham, AL.*

10.1136/jim-2016-000393.366

Case Report The differential diagnosis of lactic acidosis with hypotonia in an infant is broad and includes infection, cardiovascular abnormalities, and endocrine dysfunction.

When anatomic abnormalities are present, metabolic disorders should be considered.

A 2-d/o girl born at 34 +5/7 weeks was transferred due to persistent lactic acidosis. Prenatal history was significant for oligohydramnios, ventriculomegaly, and absent corpus callosum. APGARs were 5, 2, and 6; cord pH was 7.31. Baby was intubated at 8 minutes, given surfactant, and extubated to CPAP. ABG on arrival to our hospital had a pH of 7.18, HCO₃ of 13, and lactate of 18. She also had hypoglycemia. Metabolic acidosis was persistent, and she required a sodium bicarbonate drip. Exam showed peripheral and central hypotonia; she was nonspecifically dysmorphic. Infection and endocrinology work ups were negative. Head US showed cerebral dysgenesis with cobblestone lissencephaly, hypoplasia of the white matter, cerebellum and brain stem, and agenesis of the corpus callosum. Echo showed PDA. Her clinical picture was consistent with pyruvate dehydrogenase deficiency and this was confirmed by mitochondrial and genetic testing.

Pyruvate dehydrogenase deficiency is a rare x-linked autosomal or autosomal recessive metabolic condition depending on which gene is mutated. It is caused by deficiency of the cofactors in the pyruvate dehydrogenase complex which are necessary for converting pyruvate to acetyl-coA. This results in excess pyruvate, which is then converted to lactate, thus, causing a lactic acidosis. Pyruvate dehydrogenase deficiency often presents soon after birth, and many cases have brain abnormalities suspected prenatally. Diagnosis is made based on strong clinical suspicion and confirmed with molecular, genetic, mitochondrial, and biochemical studies and head imaging. Genetic and Metabolic specialists must be involved in the care, as close follow up is required. Treatment includes a ketogenic diet to lessen lactic acid accumulation, supplemental cofactors such as thiamine, lipoic acid, and carnitine, and long term oral citrate to help with the acidosis. Affected babies often have seizures, developmental delay, and have a poor prognosis. However, if caught and treated early, the neurodegeneration may be slowed.

367 ETIOLOGY OF HYDROPS FETALIS AND PREDICTORS OF SURVIVALL Key, AJ Talati. *University of Tennessee Health Science Center, Memphis, TN.*

10.1136/jim-2016-000393.367

Purpose of Study Hydrops Fetalis results in extravascular fluid accumulation in two or more body compartments prenatally, often leading to multi-organ failure and/or death. Immune hydrops fetalis has been almost eliminated following Rh alloimmunization treatment. We examined the cases of hydrops fetalis at our level 3 NICU from 1990–2015 and attempted to identify possible etiology and predictors of survival.

Methods Used A retrospective review of the charts of all infants born at Regional One Medical Center from January 1, 1990 to June 30, 2015 was employed. Infants were identified from a perinatal database. We recorded demographic and etiologic information and reviewed resuscitation records. T-test or chi squared tests were performed to detect the differences between alive and non-surviving infants.

Abstract 367 Table 1

N=62	All babies	Surviving (n=32)	Dead (n=30)	P value
EGA (weeks)	31.3±3.4	33±2.9	29.5±3.0	<0.0001
BW (grams)	1976±808	2207±750	1729±806	0.0185
African American	35 (57%)	18 (56%)	17 (53%)	0.9989
Males	33 (53%)	14 (44%)	19 (63%)	0.4076
LGA %	63.9	59.8	68.3	0.3663
APGAR 1 min (median)	2	3	1	0.00798
APGAR 5 min (median)	5	6	5	0.04006
Delivery Resuscitation (cc/thoracentesis)	14 (22.5%)	8 (25%)	6 (20%)	0.7080

Abstract 367 Table 2

	Total	Surviving	Dead	P value
Immune Hydrops	7 (11%)	5	2	0.2568
Chromosomal anomalies/ malformations	10 (16%)	4	6	0.4775
Renal	7 (11%)	3	4	0.6500
Infections	20 (32%)	10	10	0.8579
Hematologic (non-immune)	4 (6%)	1	3	0.2707
Idiopathic	10 (16%)	6	4	0.6126
Others	6 (9%)	3	3	0.9349

Summary of Results Of the >30,000 infants admitted to the NICU, 62 were identified as Hydrops Fetalis from the perinatal database. Of the 62 infants, 7 had a diagnosis of immune Hydrops Fetalis (11%). 32 (52%) babies survived to discharge. Table 1 shows the demographic differences between the two groups, while table 2 shows the etiologic differences.

Conclusions Mortality remains high in all cases of hydrops irrespective of the cause. Lower birthweight and lower gestational age were associated with higher mortality. Lower Apgar scores at 1 and 5 min also were associated with mortality. As expected, immune hydrops has become a rare cause of neonatal hydrops fetalis, while infections continued to be a major cause in our cohort.

368 EARLY POSTNATAL MALNUTRITION AND RISK FOR SPONTANEOUS INTESTINAL PERFORATION IN EXTREMELY LOW BIRTH WEIGHT INFANTS

A Klinger, M Zayek, R Bhat. *University of South Alabama, Mobile, AL.*

10.1136/jim-2016-000393.368

Purpose of Study Early postnatal malnutrition is an inevitable consequence of extreme prematurity as recommended dietary intake (RDI) are rarely met during the first postnatal week. Among extremely low birthweight (ELBW) infants, In addition to early energy deficits, catabolic state from clinical stress together may induce gut mucosal and submucosal changes with resultant increased risk for spontaneous intestinal perforation (SIP). Our objective was to

evaluate whether early postnatal malnutrition is associated with an increased risk for subsequent development of SIP in ELBW infants.

Methods Used In this single center, retrospective, case-control study, we included 33 ELBW infants, born from 2007 through 2012, who developed SIP after the first week of life. Each of these infants (case group) was matched for gestational age, birth weight and year of birth to a control infant who did not develop SIP (control group, n=33). Cumulative energy and nutritional deficits were calculated during first postnatal week after subtracting actual intake from recommended target. Data was analyzed by using repeated measures two-factor Analysis of Variance (ANOVA) and conditional logistic regression models.

Summary of Results Daily energy intake ($p<0.001$) and cumulative energy deficits ($p<0.001$) during first postnatal week were significantly different between cases and control groups (fig). In a stepwise multivariable conditional logistic regression model, after adjusting for all the covariates (5 minutes Apgar, SNAP-2 scores), increasing cumulative energy deficits during first postnatal week was independently associated with an increased risk of SIP (aOR 1.20, 95% CI 1.04–1.38, $p=0.01$).

Conclusions Our findings suggest that early postnatal energy deprivation may increase the risk for SIP in the ELBW infant. Further larger prospective cohort studies are warranted to validate our findings.

369 RESPIRATORY FAILURE IN AN INFANT WITH SPONDYLOEPIPHYSEAL DYSPLASIA CONGENITA

M Knecht, J Gallois, S Ollister. *LSUHSC-New Orleans, Metairie, LA.*

10.1136/jim-2016-000393.369

Case Report Spondyloepiphyseal dysplasia congenita (SEDC) is a skeletal dysplasia that specifically affects the bones of the spine and epiphyses of the long bones. It is caused by a mutation in the COL2A1 gene that encodes type 2 collagen and is inherited in an autosomal dominant pattern. Symptoms include short stature, cervical instability, scoliosis, joint abnormalities, cleft palate, vision problems, sensorineural hearing loss, and respiratory distress.

We present a female infant born at 37 weeks via C-section to a 23 year old G1P0 mother and unrelated father. Family history is significant for maternal diagnosis of SEDC; father was of normal height. At birth, infant had

a shortened torso and was <10% for length at birth. Infant demonstrated significant respiratory distress at birth requiring intubation with a video laryngoscope due to the presence of multiple craniofacial dysmorphisms including cleft palate, malar hypoplasia, micrognathia, retrognathia, and a small, very posterior bifid tongue. Based on these features, she was clinically diagnosed with SEDC. Initial chest radiography was consistent with respiratory distress syndrome, treated with surfactant. Patient developed significant pulmonary hypertension, which resolved with high frequency oscillatory ventilation and inhaled nitric oxide. She failed a controlled extubation on day of life (DOL) 15. A tracheostomy was placed on DOL 18. By DOL 54, infant was weaned to a tracheostomy collar, and no longer required mechanical ventilation.

Although respiratory distress is a feature of SEDC, respiratory failure requiring tracheostomy placement is rare. In these patients, respiratory failure may be due to small thorax with decreased thoracic volume, abnormal chest wall compliance, horizontal rib alignment resulting in decreased tidal volume, tracheomalacia, or cervical spine instability with compression of medulla/cervical spinal core. In our case, the patient's respiratory failure was complicated by upper airway obstruction (small posterior tongue, cleft palate, and micrognathia).

Respiratory difficulties can occur in children born with SEDC. These should be recognized early, and skilled physicians should be available at delivery for necessary interventions including difficult intubations and advanced ventilatory support.

370 IDENTIFICATION AND LOCALIZATION OF SURFACTANT PROTEIN A AND MRNA IN THE PERIVENTRICULAR REGION OF THE MOUSE BRAIN

EJ Marxen,^{1,4} PW Whitby,³ H Mussa,³ A Linens,² F Bhatti^{4,2,1}. ¹University of Oklahoma Health Sciences Center, Oklahoma City, OK; ²Dean McGee Eye Institute, Oklahoma City, OK; ³Phoenix Children's Hospital, Phoenix, AZ; ⁴OUHSC, Oklahoma City, OK.

10.1136/jim-2016-000393.370

Purpose of Study Surfactant Protein A (SP-A) associates with blood vessels in the retina; its up regulation accompanies pathological retinal neovascularization in preterm infants. Since the retina is an extension of the central nervous system, we hypothesize that SP-A is also present in blood vessels surrounding the blood brain barrier (BBB). Pre-term infants and neonates have a high likelihood of intraventricular hemorrhage (IVH) because of the intrinsic fragility of the germinal matrix vasculature; the disturbance in the cerebral blood flow predisposes pre-term infants and neonates to periventricular ischemia and leukomalacia. We hypothesize that SP-A co-localizes with blood vessels near the choroid plexus and germinal matrix in a manner similar to the distribution within the blood vessels of the retina. Our aims are to identify and localize SP-A protein and mRNA in the periventricular area of the mouse brain as well as determine if it associates with the neurovascular unit in the germinal matrix.

Methods Used After euthanization, whole brains were dissected from C57BL6/J mice at P22. The periventricular

area of the brain was identified and carefully excised. Protein expression was analyzed by Western Blot. mRNA expression was measured by PCR. Lungs of the mice were removed and processed for use as positive controls. Further confirmation via immunohistochemistry (IHC) was performed to ensure validity. Imaging via fluorescence microscopy of retinas was used as a guideline for IHC imaging of brains.

Summary of Results SP-A protein was identified via Western Blot. The experiment was repeated with multiple SP-A antibodies to confirm results. PCR also showed mRNA transcripts of SP-A.

Conclusions SP-A has been identified in the periventricular tissue of the brains of C57BL6/J mice. Due to the nature of the presence of SP-A in pathophysiologic retinal tissue, we believe that aberrant SP-A signaling may be an important factor in periventricular ischemia and IVH in preterm neonates.

371 SPONTANEOUS RESOLUTION OF AN INTRACRANIAL ARTERIOVENOUS MALFORMATION

J Miller, S Mohan. *Emory, Atlanta, GA.*

10.1136/jim-2016-000393.371

Introduction Vein of Galen Aneurysmal Malformation (VGAM) is rare despite being the most frequently detected prenatal cerebral arteriovenous malformation. Prenatal diagnosis of VGAM with cardiac involvement has been described in the literature and has a high rate of mortality and other adverse outcomes. This case highlights a rare phenomenon of spontaneous resolution of a prenatally diagnosed VGAM.

Case Presentation A 3rd trimester ultrasound on a 19 year old G2P0 revealed a cystic structure along the posterior section of the corpus callosum of the fetal brain, which was characterized by an elongated dilated vessel extending from the quadrigeminal plate cistern towards the occiput. Flow doppler demonstrated arterialized flow in the medial prosencephalic vein of Markowski. These findings were concerning for a VGAM. A fetal echocardiogram revealed cardiomegaly with tricuspid regurgitation. Following an uncomplicated birth of a female infant at 36 weeks and 5 days gestation, an echocardiogram demonstrated a patent ductus arteriosus and patent foramen ovale (PFO) with a structurally normal heart. Magnetic resonance imaging (MRI) of the brain on day 3 of life revealed a mural type median prosencephalic vein malformation consistent with VGAM associated with a mild mass effect, but otherwise normal appearance of the brain parenchyma. The NICU course was uneventful and the infant was discharged on day 5 of life with close follow up with cardiology and neurosurgery. An echocardiogram at 3 months of age demonstrated a PFO with normal biventricular function and normal right ventricular size. A cranial ultrasound at this time was normal. A brain MRI at 6 months of age was normal without evidence of a VGAM. There were no interventions performed by cardiology or neurosurgery from the time of diagnosis to spontaneous resolution.

Discussion Spontaneous resolution of a VGAM without medical intervention has not been reported. Counseling

families with a prenatal diagnosis of VGAM include discussion of medical management addressing common sequelae, such as seizures or high-output cardiac failure, and surgical interventions, including the standard of care vaso-occlusive therapies. Discussion of the possibility of resolution of a VGAM without intervention may be warranted as part of prenatal and postnatal counseling.

372 CRANIOFACIAL ENHANCER SEQUENCING IN NONSYNDROMIC CLEFT LIP AND PALATE

V Morris,¹ S Blanton,² S Hashmi,¹ J Hecht¹. ¹McGovern Medical School University of Texas Health, Houston, TX; ²University of Miami Miller School of Medicine, Miami, FL.

10.1136/jim-2016-000393.372

Purpose of Study Nonsyndromic cleft lip with or without cleft palate (NSCLP) is a common birth defect affecting more than 4,000 U.S. infants/year. NSCLP significantly impacts feeding, hearing, dentition and speech with financial costs of more than \$300,000. NSCLP is multifactorial, with genetic and environmental factors. Despite the use of varying approaches, only ~20% of the underlying genetic variation has been identified, primarily in exons. However, variation in noncoding regions, which can alter gene expression and developmental patterning, has been shown to be important. The goal of this study is to determine whether variation in craniofacial enhancer sequences contributes to NSCLP.

Methods Used Candidate enhancer regions were identified using the VISTA Enhancer Browser website (<http://enhancer.lbl.gov>). Filtering for expression patterns in blood vessels, somite, branchial arch, nose, facial mesenchyme, and mesenchyme from neural crest of transgenic mouse embryos identified 256 potential enhancers. Incorporating published data on patterning defects in knockout mice, deletion/duplication of craniofacial genes in animal models, and WES/WGS association reduced this to 20 enhancers. Custom probes were designed for each enhancer region using reference sequences. One affected individual from each of 288 multiplex families was sequenced using Illumina MiSeq targeted next-generation sequencing. Results were compared to an ethnically-matched 1000 Genomes Project control population (<http://www.internationalgenome.org>).

Summary of Results One enhancer, mm435, located in the 5' noncoding region of the ABCA4 gene, has been analyzed to date. This enhancer is of interest as a previous GWAS found significant association between ABCA4/ARHGAP29 (rs560426) and NSCLP. We found 29 single nucleotide polymorphisms (SNPs), with 2 SNPs trending towards association with NSCLP. Importantly, haplotype analysis identified a significantly associated haplotype ($p=0.004$) that included these SNPs. *In silico* analysis shows this haplotype removes a number of important DNA binding sites.

Conclusions These results provide support for noncoding enhancer sequence variation in the etiology of NSCLP. Analysis of remaining 19 enhancer sequences is ongoing.

373 EARLY CONTINUOUS RENAL REPLACEMENT THERAPY: IMPLEMENTING A PRACTICE CHANGE IN NEONATAL EXTRACORPOREAL LIFE SUPPORT

HJ Murphy,¹ JB Cahill,¹ K Twombly,¹ DJ Annibale,¹ J Kiger². ¹Medical University of South Carolina, Charleston, SC; ²University of Pittsburgh, Pittsburgh, PA.

10.1136/jim-2016-000393.373

Purpose of Study The optimal timing of continuous renal replacement therapy (CRRT) during neonatal extracorporeal life support (ECLS) is unknown. We implemented a practice change in mid-2011, initiating CRRT within 48 hours of cannulation, and hypothesized that early initiation improves fluid balance leading to shorter duration of ECLS and invasive ventilation with improved survival.

Methods Used We conducted a cohort study, retrospectively collecting data from the medical records of infants who received ECLS in a single neonatal intensive care unit 2007–2015. Comparisons were made between two groups: neonates who received ECLS prior to the practice change (Epoch 1; n=32) and neonates who received ECLS following the practice change (Epoch 2; n=31). Outcome measures included duration of ECLS, duration of invasive ventilation and survival. Standard parametric and non-parametric tests were performed as appropriate.

Summary of Results The epochs were similar when comparing birthweight, gestational age, ECLS mode, age at ECLS initiation, maximum percent weight change over first 7 days of ECLS and duration of CRRT; there was a significant gender difference (E1: 65% male, E2: 39% male; $p=0.03$).

Prior to the practice change, 12/32 (38%) infants received CRRT; 1/32 (3%) infant received early CRRT. Following the practice change, we successfully initiated early CRRT in 30/31 (97%) infants. Significant differences were noted when comparing age at CRRT initiation [E1: 201 hrs (IQR 87–234), E2: 48 hrs (IQR 24–78); $p<0.01$], weight at CRRT initiation [E1: 4133 gms (IQR 3726–4953), E2: 3190 gms (IQR 2801–3583); $p<0.01$] and time from cannulation to CRRT initiation [E1: 105 hrs (IQR 28–178), E2: 9 hrs (IQR 4–22); $p<0.01$]. Duration of ECLS, duration of ventilation and survival were similar between epochs.

Conclusions We successfully implemented a practice change, instituting CRRT within 48 hours of cannulation. In this study early CRRT was not associated with a shorter duration of ECLS or ventilation or improved survival, however these parameters were not negatively impacted suggesting early CRRT is safe in neonatal ECLS patients. Further investigation of fluid balance and nutrition delivery with ECLS and early CRRT is warranted.

374 SURVIVAL AND OUTCOMES OF TWIN BIRTHS AS IT RELATES TO BIRTH ORDER AT A LEVEL 3 NICU FROM 1989–2014

A Nasab, AJ Talati. *UTHSC, Memphis, TN.*

10.1136/jim-2016-000393.374

Purpose of Study National vital statistics data show multiple gestation rates are rising, especially twins. While some studies have explored the relationship between multiple gestations and outcomes, information on birth order and outcomes are lacking. We have hypothesized that the second-born twin would have a worse clinical outcome. We sought to evaluate the role of birth order as it relates to survival and outcomes.

Methods Used We reviewed our perinatal database from Nov 1989 through Oct 2014 at Regional One Health, a Level 3 NICU in Memphis, TN and identified all twin births. We excluded infants with missing data and incomplete pairs. Baseline characteristics of gestational age (GA) and race were similar between first-born and second-born twins. Demographic data and clinical outcomes were compared. Data were analyzed with t-test, Mann-Whitney or χ^2 analysis as applicable.

Summary of Results 32988 babies were admitted during the study period, of which 2826 were twins. After exclusion criteria were applied, 1190 pairs of twins (2380 infants) remained. Mean GA (32.3 vs 32.4 wks), birth-weight (1660 vs 1665 g), gender (51% vs 49% male), and IUGR status (22% vs 20%) were similar between the first and second twin respectively. The second twin had lower serum glucose (60 vs 46 mg/dL, $p=0.001$) and hematocrit (47 vs 46%, $p=.02$). Table shows other clinical outcomes.

Conclusions Survival did not differ based on birth order. The second twin was more likely to have low glucose levels on admission and higher incidence of PDA. Severe ROP was similar in both groups. The first born twin was more likely to have higher incidence of other morbidities. More investigation needs to be performed on possible confounding factors to understand these differences.

Comparison of Clinical Outcomes

Abstract 374 Table 1

Outcomes	Twin 1	Twin 2	p-value
1 Min Apgar Median (IQR)	6 (4–7)	7 (4–8)	$p<0.01$
5 Min Apgar Median (IQR)	8 (8–9)	8 (7–9)	$p=0.10$
RDS (%)	258 (21.7%)	213 (17.9%)	$p=0.02$
BPD (%)	161 (13.5%)	101 (8.5%)	$p<0.01$
PDA (%)	74 (6.2%)	171 (14.4%)	$p<0.01$
Severe IVH (%)	62 (5.2%)	38 (3.2%)	$p=0.01$
Severe ROP (%)	25 (2.1%)	30 (2.5%)	$p=0.50$
NEC (%)	87 (7.3%)	24 (2.0%)	$p<0.01$
Length of Stay (days) Median (IQR)	17 (10–34.75)	18 (10–36)	$p=0.03$
Survival (%)	1115 (93.7%)	1106 (92.9%)	$p=0.51$

375 MYO-INOSITOL AND FOLIC ACID AFFECT EXPRESSION PROFILES OF GENES REGULATED BY HUMAN HOMOLOG OF SPINA BIFIDA CAUSING GENE GRHL3

CM Nolan, H Northrup, K Au. *University of Texas Health Science Center Houston-McGovern Medical School, Houston, TX.*

10.1136/jim-2016-000393.375

Purpose of Study Disruption of the transcription factor grainyhead-like 3 (*Grhl3*) gene causes spina bifida (SB) in the curly tail (*ct*) mouse model. Myo-inositol rescued SB in *ct* mouse offspring. Folate-one-carbon metabolism (FOCM) in *ct* mouse cells was also altered. Few studies exist studying the role of human homolog *GRHL3* in causing human SB. We hypothesize that myo-inositol affects *GRHL3* expression and subsequently neural tube (NT) closure through altering expression of *GRHL3* target genes that are required in NT closure. We are using a human primary cell model to reveal how myo-inositol and folic acid affect *GRHL3* and *GRHL3* target genes expression.

Methods Used Human primary fibroblast cells were cultured in the absence or presence of different concentrations of folic acid or myo-inositol. DNAs, RNAs and proteins were extracted. Expression of *GRHL3* and related proteins were examined by Western Blotting. Gene expression profiles were examined by RNA-Seq to reveal expression of *GRHL3*, its target genes, and other genes. RNA-Seq results to be confirmed by quantitative RT-PCR.

Summary of Results Optimal cell growth was observed with 0–0.25 mM myo-inositol and 0–0.02 mM folic acid at 30 hours post-treatment. Protein analyses showed myo-inositol stimulated *GRHL3* expression. RNA-Seq data showed absence of myo-inositol affected expression of genes involved in cholesterol metabolism and genes involved in cell movement and wound healing. Absence of folic acid suppressed expression of multiple FOCM genes and many genes involved in cell growth and proliferation. Confirmation studies are ongoing.

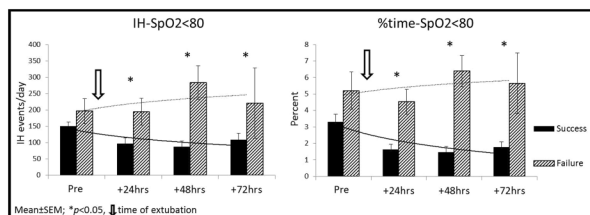
Conclusions This study in human cells demonstrated that myo-inositol altered expression of *GRHL3* and *GRHL3* target genes involved in cell movement, wound healing, and could potentially function in human NT closure. We also showed that folic acid affected expression of multiple FOCM genes and many genes involved in cell growth and proliferation. Our study results will provide valuable information to dissect nutrient-gene interaction mechanisms relevant to NT closure in humans in hopes of developing future knowledge-based intervention methods to reduce NT defects in pregnancy.

376 EXTUBATION FAILURE IN PRETERM INFANTS: A ROLE FOR MONITORING INTERMITTENT HYPOXEMIA

A Pant,¹ P Westgate,¹ TM Raffay,³ A Gabrani,² M Brasher,¹ P Giannone,¹ MD Cunningham,¹ EG Abu Jawdeh¹. ¹University of Kentucky, Lexington, KY; ²CHOP, Philadelphia, PA; ³Case Western Reserve University, Cleveland, OH.

10.1136/jim-2016-000393.376

Purpose of Study Mechanical ventilation (MV) in preterm infants is commonly associated with significant morbidities. In order to minimize days on MV, there is a practice shift



Abstract 376 Figure 1

towards early extubation to non-invasive strategies; however, the lack of clear clinical indications to predict successful extubation places infants at increased risk for complications. We assessed the role of intermittent hypoxemia (IH) monitoring as an indicator for extubation failure in preterm infants.

Methods Used We prospectively enrolled 88 infants ≤ 29 wks gestational age (GA) on MV. Oxygen saturation (SpO₂) was continuously recorded (2 s averaging, 1 Hz sampling) and analyzed with validated novel software. Respiratory support settings were retrospectively collected pre-/post-extubation. Failure was defined as reintubation within 72 hrs. Extubation events were grouped as success or failure. We compared IH measures between groups 24 hrs pre- up to 72 hrs post-extubation. IH measures defined as, IH-SpO₂<80: events/day with SpO₂<80% (4–180 s); %time-SpO₂<80: percent time with SpO₂<80%.

Summary of Results A total of 50 infants had 91 extubation events (64 success, 27 failure). Mean GA=26 wks(23–29) and BW=870 g(490–1385). Baseline respiratory settings did not vary between groups (all p =NS). IH measures did not significantly differ between groups 24 hrs pre-extubation; however, post-extubation IH measures were significantly higher in the failure compared to success group (figure).

Conclusions Although pre-extubation IH was not a statistically significant indicator of failure; increased IH post-extubation was associated with the need for reintubation in preterm infants. Improvements in clinicians' proactive monitoring of IH measures with subsequent adjustment of non-invasive support strategies post-extubation are imperative.

Gerber Foundation
Childrens Miracle Network

377 DECREASING PHLEBOTOMY IN PRETERM INFANTS BY SUCCESSFUL UTILIZATION OF CORD BLOOD FOR ADMISSION TESTING

P Bhandary, A Patra, M Hanna, E Abu Jawdeh, L McGee, S Haynes, P Giannone. *University of Kentucky, Lexington, KY.*

10.1136/jim-2016-000393.377

Purpose of Study Anemia is common in very low birth weight (VLBW) infants frequently requiring transfusions. Phlebotomy losses in the first day of life can result in up to 10% blood volume loss in these infants. Placental/cord blood (CB) is of fetal origin and can be used for initial laboratory studies thereby decreasing phlebotomy needs.

Various studies have demonstrated that hematocrit, platelet count and white blood cell count are comparable between blood obtained from neonate and CB. Additionally, when drawn from CB, a greater volume of blood can be obtained for blood culture improving sensitivity. Our aim was to achieve 80% successful utilization of CB for admissions tests in VLBW infants thereby decreasing phlebotomy and transfusion needs.

Methods Used Cord blood collection algorithm was developed, education and training were provided to all staff. Blood culture obtained from CB was compared with that obtained from neonates to estimate false positive rate. Blood transfusions during hospital stay and age at first transfusion was compared in study cohort (CB used) with similar VLBW infants where CB was not used.

Summary of Results Preliminary results from initial 6 months after implementation. Admission studies from cord blood were drawn successfully in 69% of these neonates ($n=71$). The collection technique used resulted in only one contaminated CB culture, thus providing useful/valid sampling in 98% of infants. In extremely low birth weight (ELBW) infants ($n=20$), when CB was used there was a trend towards decreased need for any transfusion during hospital stay (70% vs 90%, p =ns), when compared to CB not used. In addition, in ELBW infants when CB was used, there was a trend towards delayed need to first transfusion (Day 2.9 Vs Day 2, p =ns) when compared to CB not used.

Conclusions Neonatal admission studies can be successfully obtained from CB in majority of VLBW infants. Our CB collection resulted in valid blood culture samples in the vast majority of eligible infants. Encouraging trends with transfusion needs in ELBW infants need to be confirmed with continued utilization of CB for neonatal admission tests.

378 DOES ANTENATAL MAGNESIUM SULFATE INCREASE THE LIKELIHOOD OF A HEMODYNAMICALLY SIGNIFICANT PATENT DUCTUS ARTERIOSUS IN NEONATES?

A Qasim, S Jain, S Dasgupta. *University of Texas Medical Branch, Galveston, TX.*

10.1136/jim-2016-000393.378

Purpose of Study Antenatal magnesium sulphate (MgSO₄) is neuroprotective in premature infants (PI). Since influx of calcium secondary to high postnatal oxygen plays an important role in the constriction of the ductus arteriosus, antenatal MgSO₄ therapy should increase the risk of patent ductus arteriosus (PDA). We aim to investigate the role of antenatal MgSO₄ and risk of hemodynamically significant PDA (HsPDA) in PI.

Methods Used This is a prospective nested case control study. After IRB approval, PI (<32 weeks & <1500 grams) were recruited ($n=105$) in the study. All infants had ECHO (within 3 days) and blood sample drawn at the same time. Blood was centrifuged and plasma was saved at -80°C for NTproBNP measurement. Medical records of all infants and their mothers were collected from electronic medical records. HsPDA was defined as a PDA diameter>1.5 mm on day 3 of life. Babies were divided into two groups based

Abstract 378 Table 1. Baseline Characteristics

Characteristic	Antenatal Mg (N=95)	No Antenatal Mg (N=10)	p value
Birth weight (g)	1007±271	1030±329	0.81
Gestational age (weeks)	27.8±2.3	27.6±2.5	0.79
Race (%)			
- Hispanic	60	37.5	0.11
- Caucasian	30	30.2	
- African American	10	30.2	
- Asian	0	2.1	

on presence/absence of antenatal MgSO₄ use. We checked for difference in antenatal steroid use in the two groups and used logistic regression correcting for gestational age and birth weight. Other echocardiographic parameters (Ejection fraction [EF], Aortic root diameter and LA/Ao diameter) were also reviewed. Data was analyzed using SPSS 23.

Summary of Results Table 1 shows the baseline characteristics of the two groups (N=105). Pearson correlation analysis demonstrates a negative correlation between antenatal MgSO₄ use and the occurrence of a HsPDA in neonates ($r=-.364$ $p<0.001$) and regression model shows a negative linear relationship ($-.525$, $p<0.001$). There was no significant difference in the use of antenatal steroids between the two groups ($p=0.062$). However, EF, mean PDA diameter and mean LA/Ao were not significantly different ($p=0.383$, 0.063 and 0.103 respectively) in the two groups.

Conclusions Antenatal MgSO₄ use in PI is associated with a decreased likelihood HsPDA. in neonates.

379 MACROLIDES SUPPRESS LPS INDUCED INFLAMMATORY IN VITRO BRAIN INJURY MEDIATED BY MICROGLIA

S Ramarao, Y Pang, K Carter, AJ Bhatt. *University of Mississippi Medical Center, Jackson, MS.*

10.1136/jim-2016-000393.379

Purpose of Study There is a critical lack of knowledge for the prevention and treatment of inflammation induced brain injury in very low birth weight (VLBW) infants which causes significant neurodevelopment handicaps. Oligodendrocyte progenitor cell (OPC) is the major cellular target of brain damage in VLBW infant at the critical period of injury. Although Microglia protect brain from injury, their uncontrolled activation can cause damage to neighboring neurons and OPCs. Our previous in vitro studies have showed that the bacterial endotoxin lipopolysaccharide (LPS)-induced damage to OPCs was mediated by microglia. Macrolides inhibits inflammatory response from systemic immune cells, whether it also inhibit inflammatory response from immune cells from brain, namely microglia is not known. Our central hypothesize that Azithromycin (AZ), a macrolide reduces inflammatory injury to developing brain. The objectives of the current project were to investigate whether AZ inhibits

inflammatory cytokines release and OPC death by LPS activated microglia.

Methods Used Microglia and OPCs from the cortices of P1 rat brain were used. Microglia were activated by LPS treatment. There were four experimental groups: Group 1: Control (DMEM); 2: LPS; 3: AZ only; 4: AZ+LPS, pre-treatment with AZ for 1 h before LPS exposure. IL-1 β and IL-6 were measured in cell culture medium by ELISA (R&D System) following the manufacture's instruction. Microglia-conditioned medium (MDM) from all four groups were collected for the later experiments. OPC cultures divided into same four groups as above and treated similarly as microglia culture except the treatment with microglia-conditioned medium (MDM) with or without LPS and AZ exposure. Cell survival was measured using XTT assay.

Summary of Results AZ suppressed IL-1 β at 24 h and IL-6 at 24 and 48 h by LPS activated microglia (Two-way ANOVA, $P<0.05$, post hoc Holm-Sidak test, $n=4-5$). MDM following LPS treatment reduced the OPC survival as measured by XTT assay at 24 and 30 h compared to OPC survival following treatment with MDM from the control and AZ+LPS groups.

Conclusions Our findings suggest that AZ inhibits proinflammatory cytokines release and OPC death by LPS activated microglia.

380 SAVE MY NEURONS: VENTILATION IN THE PERIOPERATIVE PERIOD

S Ramarao, P Lowrey, L Schell, M Ellis, C Glendye, J Saucier, J Desai, M Famuyide. *University of Mississippi Medical Center, Jackson, MS.*

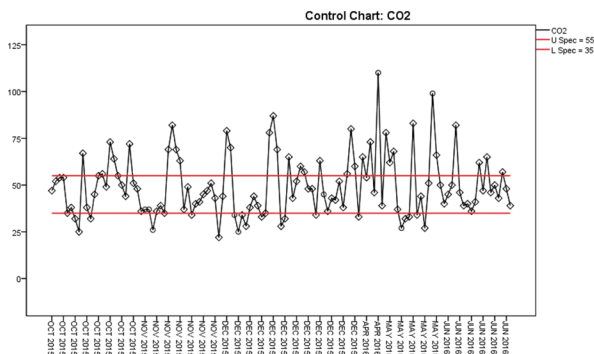
10.1136/jim-2016-000393.380

Purpose of Study Preterm infants experience complications during their hospital course, some of which require surgical intervention under general anesthesia. Both hypo- and hypercapnia are known to alter cerebral blood flow and cause neurotoxicity.

Methods Used As part of a multidisciplinary quality improvement (QI) initiative, we reviewed records of all infants in our level IV neonatal ICU who had surgery (excluding complex cardiac surgeries) during a 3-month period (Phase I). We standardized timing of post-operative blood gas collection and collected data over the next 3 months (Phase II). We defined desired range of pH as 7.25–7.45 and PCO₂ as 35–55. Process measures were tracked using Run Charts and Chi square test was used to evaluate for differences between the 2 phases.

Summary of Results Total of 79 and 41 infants present in phase I and II respectively. There was a significant difference in gestational ages (GA) between the 2 phases. Perioperative alkalosis was more common in infants with corrected GA >37 weeks (28% vs 14%, $p=0.000$), acidosis more common in the infants with corrected GA <37 weeks (39% vs 5.0%, $p=0.000$). Figure I shows the range of PCO₂ during phase I and II. No significant difference was noted between PCO₂ and pH levels between the 2 phases.

Conclusions Our findings suggest that impaired ventilation is a problem in the perioperative period. Bearing in mind



Abstract 380 Figure 1

the implication of impaired ventilation on the developing brain, we plan to explore if it is present during the entire surgical procedure or related to the transport process. Our QI efforts will include introducing interventions to ameliorate the problem.

381 SWALLOW/BREATH INTERACTIONS DURING NONNUTRITIVE SUCK IN TERM INFANTS

EW Reynolds,¹ R Charnigo,² D Grider². ¹University of Texas, Health Science Center @ Houston, Houston, TX; ²University of Kentucky, Lexington, KY.

10.1136/jim-2016-000393.381

Purpose of Study We have used our multi-channel graphical method to describe swallow-breath interaction (SwBr) and phase of respiration (POR) during nonnutritive suck (NNS) in preterm infants. We found 3 types of SwBr [Central Apnea (CA), Obstructive Apnea (OA) and Attenuated Respiration (AR)] and 5 types of POR [Beginning Expiration (BE), Mid-expiration (ME), End-expiration (EE), Mid-inspiration (MI) and Apnea (AP)].

The objective of this study is to describe SwBr and POR in term infants.

Methods Used 12 TRM infants were studied once during their initial hospitalization, yielding 94 swallows. Informed consent was obtained. Infants were fitted with a custom assembly of instruments to measure suckle and swallow pressures, nasal airflow and chest movement during 1-minute of NNS. Statistical analyses were performed with SAS. Results were compared to 16 low-risk preterm (LRP) infants from a previous study

Abstract 381 Table 1

	AR	OA	CA	BE	ME	EE	MI	AP
Term	74	20	5	41	19	24	5	10
LRPall	42*	34*	24*	20*	9*	46*	7	15
LRPearly	31*	41*	29*	9*	9	54*	9	16
LRPmid	49*	29	22*	30	8	33	5	17
LRPlate	79	16	5	47	10	42	0	0

*Indicates significantly different from TRM

Summary of Results: SwBr The Table shows the percentages for each SwBr for TRM and LRP babies. LRP babies were divided by post-menstrual age (PMA) [LRPearly (PMA<35 weeks), LRPmid (PMA: 35–39), LRPlate (PMA>39)]. TRM babies were significantly different from LRP babies and from LRPearly infants for all SwBr's and from LRPmid for AR and CA. There was no statistical difference between TRM and LRPmid babies for OA or between TRM babies and LRPlate babies for any SwBr

POR The Table shows the percentage of each type of POR for each group. Differences were noted between TRM and LRP for BE, ME and EE and between TRM and LRPearly for BE and EE. There were no differences between TRM and LRPmid or LRPlate for any POR. The percentages of ME, MI and AP for the LRP approach those of TRMs, but there is a lack of statistical power in these categories.

Conclusions We have described SwBr and POR during NNS for term babies. We have confirmed our speculation that SwBr and POR in LRP infants become more similar to term infants with age. Supported by NIH 5 K23 HD 050581.

382 PREDICTING MENTAL IMPAIRMENT AT 18 MONTHS OF AGE IN EXTREME LOW BIRTH WEIGHT INFANTS (ELBWI) AT THE TIME OF DISCHARGE FROM NICU

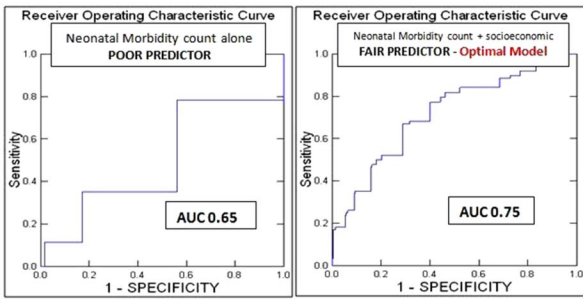
A Sabapathy, M Zayek. University of South Alabama, Mobile, AL.

10.1136/jim-2016-000393.382

Purpose of Study ELBWI are at risk for high adverse neurodevelopmental (ND) outcomes which include severe cognitive delay, psychomotor delay and language delay. As improved ND outcome is seen in ELBWI who receive early interventions, it is essential to detect at risk infants at very early age. Dr.Schmidt found that the higher the number of neonatal morbidities, the higher the risk for adverse ND outcomes. Our aim is to determine whether brain metrics can enhance the prediction of mental impairment at 18 months of age in ELBWI.

Methods Used We collected Bayley-III cognitive and language scores on 389 ELBWI (birth weight <1000 gms and gestation <28 wks, born in 2007–2012) who were assessed at 18–24 month of age (excluded: infants with chromosomal anomalies, hydrocephalus). First, we developed multivariate logistic regression models that included neonatal morbidities (white matter injury, chronic lung disease and Prethreshold retinopathy), head circumference at the time of discharge, maternal age, marital status and other basic demographics to assess the risk for mental impairment. Second, we added each of brain metrics findings separately into the model (midsagittal vermis area and corpus callosum surface area on 10–13 wks ultrasound, bifrontal and biparietal diameter on near-term MRI). To assess the accuracy of various logistic models, we compared their areas under the ROC curves (AUC) using Stata.

Summary of Results Optimal model which included factors such as male gender, IUGR, mother's age, marital status, socio economic status with morbidity count, improved significantly the predictability of a model containing only neonatal morbidities. Brain metrics did not improve model prediction.



Abstract 382 Figure 1

Conclusions Predicting mental impairment among ELBWI at the time of discharge remains a challenge. Focusing on socio-economic factors rather than brain metrics yield better predictive outcome.

383 THERAPEUTIC POTENTIAL OF MESENCHYMAL STROMAL CELLS FOR HYPOXIC ISCHEMIC ENCEPHALOPATHY: A SYSTEMATIC REVIEW OF PRECLINICAL STUDIES

A Moreira,¹ S Kahlenberg,¹ Y Alayli,¹ SB Mustafa,¹ P Hornsby,² SR Seidner¹. ¹UT Health Science Center-San Antonio, San Antonio, TX; ²UT Health Science Center, San Antonio, TX.

10.1136/jim-2016-000393.383

Purpose of Study Hypoxic ischemic encephalopathy (HIE) is a devastating condition with high mortality rates and significant long-term complications for infants who survive. Mesenchymal stromal cells (MSCs) have emerged as novel therapeutic agents shown to have promising results in experimental studies of HIE. The purpose of this systematic review is to assess the efficacy of exogenous administration of MSCs in animal models of HIE.

Methods Used Adhering to PRISMA guidelines, a systematic search of English articles was performed using MEDLINE, Web of Science, and Google Scholar. Search term items included mesenchymal stem/stromal cell, hypoxic ischemic encephalopathy, asphyxia, cerebral ischemia, and neonatology. We selected randomized and non-randomized studies that examined in vivo models of induced HIE. Data was collected on study specifics, MSC characteristics, and outcome measurements. Primary outcome was efficacy of MSC treatment, assessed by functional outcome and lesion size.

Summary of Results A total of 11 preclinical publications focusing on MSC therapy for HIE met our inclusion criteria. Nine of the studies (82%) induced HIE in rodents by ligating the common carotid artery followed by a period of hypoxic exposure. Seven (64%) studies derived their MSCs from rodent bone marrow, while the other investigators provided xenografts from human bone marrow or umbilical cord-derived MSCs. Range of MSC doses were between 0.25–3.5 ×10⁶ cells with 64% of the experiments transplanting the MSCs intranasally or intraventricular. The cylinder rearing test was the most common (73%) sensorimotor functional outcome performed in the first month

following the induction of HIE. All but one study demonstrated a marked reduction in asymmetrical paw preference after receiving MSC therapy. Lesional size was assessed, using neuroimaging or histologic evaluations, and showed a decreased area following MSC therapy.

Conclusions This review suggests a promising role for MSCs in preclinical studies of HIE. MSC treatment demonstrated improved functional and structural outcomes and encouraging for future translational studies.

384 A SYNDROME TO NOT OVERLOOK: JOUBERT SYNDROME

MC Steinhardt, C Mumphrey, M Marble, J Surcouf. *LSUHSC-NO, Metairie, LA.*

10.1136/jim-2016-000393.384

Background Joubert Syndrome is a rare brain malformation characterized by the absence or underdevelopment of the cerebellar vermis and molar tooth sign. Features include hyperpnea, hypotonia, and ataxia. Physical deformities include polydactyly, cleft lip/palate, and tongue abnormalities. Seizures, kidney and liver abnormalities may develop. Many cases are sporadic, while others are autosomal recessive.

We will present a case of an infant with the classical brain anomaly and features of Joubert Syndrome. This case should aid in the reminder that, although rare, should be included in the differential diagnosis, when the cerebellar vermis is absent in conjunction with other anomalies.

Case 34 2/7 WGA Male infant born via induced vaginal delivery to a 20 yo G2P1 after mother presented in preterm labor. Mother followed by MFM for prenatal diagnosis of Dandy Walker malformation and polydactyly. Amniocentesis had normal microarray, karyotype 46XY, negative for CMV and toxo, with normal AFP and AChE. Physical examination of the infant is striking for hypertelorism, large anterior and posterior fontanelle with widened sutures, flattened nasal bridge, 7 digits on right foot (pre and postaxial), 6 digits on left foot (preaxial) and bilateral hands (postaxial), as well as, increased tone in the lower extremities, decreased tone of the upper extremities, and hyperresponsive startle reflex. Infant had irregular respirations and apnea for which infant required non-invasive ventilation. Neuroimaging were consistent with absence of the vermis with cerebellar hypoplasia and enlargement of the posterior fossa consistent with Dandy-Walker malformation. Molar tooth sign of the superior cerebellar peduncles. Due to constellation of symptoms, Joubert Syndrome is suspected. Genetic confirmation pending.

Discussion Joubert syndrome has a pathognomonic molar tooth sign on neuroimaging. In addition, altered respiratory pattern, hypotonia, developmental delay, and ataxia are common neurological findings. Breathing dysregulations can be severe requiring assisted ventilation. This constellation of symptoms should prompt early neuroimaging and may help prevent morbidity and mortality related to breathing disturbances, and may initiate screening for other organ involvement.

385 THE PREVALENCE OF DONOR BREAST MILK USAGE IN THE NEONATAL INTENSIVE CARE UNIT

JL Steinkampf, S Ollister. *LSU, New Orleans, LA.*

10.1136/jim-2016-000393.385

Purpose of Study Prematurity carries with it the risk of multiple morbidities including sepsis, necrotizing enterocolitis, retinopathy of prematurity and long term developmental delay. Studies have demonstrated the reduction of these common morbidities for infants exposed to mother's own milk.

The American Academy of Pediatrics presented a policy statement in 2012 on Breastfeeding and the Use of Human Milk. The policy states that all preterm infants should receive human milk and that pasteurized human milk should be used if mother's own milk is unavailable or contraindicated.

Is donor breast milk (DBM) a new standard of care in the neonatal intensive care unit?

Methods Used A 12 question survey on the use and practices of DBM in training programs across the country. The survey was submitted to 97 academic NICUs based on the April 2012 directory of Section of Perinatal Pediatrics and results were collected from July through November 2015.

Summary of Results Survey response rate was 60.8% and 46 of the 59 (77.9%) NICUs reported the use of DBM in their NICU. The criteria for initiation and cessation of DBM varied among the respondents. 21 of the 59 respondents provided DBM to infants less than 32 weeks gestation or those weighing less than 1500 grams; other caveats included gastrointestinal anomalies, congenital heart defects, high risk or history of necrotizing enterocolitis. The discontinuation of DBM ranged from 32 to 44 weeks post conception age or a weight of 1500 to 2500 grams. While the inclusion and exclusion criteria for the use of DBM varied, some of the respondents considered medical and socioeconomic concerns, distribution of limited resources, the risk of exposure to infectious agents, and the possible discouragement in the supply of mother's own milk.

Conclusions Despite the endorsement from the AAP and WHO, the use of DBM is not universal and the qualifying criteria varies widely. Further research is ongoing to determine the benefit of DBM versus mother's own milk, exclusive breast milk feedings and identifying the infants who would benefit the most from this limited resource.

386 PLASMA BRAIN DERIVED NEUROTROPHIC FACTOR (BDNF) LEVELS IN INFANTS EXPOSED TO OPIATES IN UTERO AS A PREDICTOR OF THE SEVERITY OF NEONATAL ABSTINENCE SYNDROME (NAS)

L Subedi, H Huang, P Westgate, H Bada, A Pant, T Sithisarn. *University of Kentucky, Lexington, KY.*

10.1136/jim-2016-000393.386

Purpose of Study Past decade there has been a substantial increase in maternal opiate use leading to in utero exposure to opiates and increased incidence of NAS in infants. Previously animal model has shown that long-term

neurodevelopmental consequences of opiate exposure may be linked to low levels of BDNF. However, to date there has been no published study on the correlation of NAS/opiate exposure on the levels of BDNF in human infants. Our hypothesis was plasma BDNF levels correlate with the severity of NAS in infants who were exposed to opiates in utero. The severity of NAS was determined by the hospital length of stay (LOS), the numbers of medicine used to treat NAS and the NAS scores during first 48 hours after admission.

Methods Used This was a prospective cohort study. Infants ≥ 35 weeks of gestation admitted in Kentucky Children Hospital Level IV Neonatal Intensive Care Unit were enrolled. BDNF level was measured from blood samples within 48 hours of life from babies who were exposed and non-exposed to opiates using ELISA technique.

Summary of Results 53 infants were enrolled, 33 exposed and 20 non-exposed to opiates in utero which were grouped as NAS and non-NAS respectively. Mean BDNF level in NAS group was 242 ± 87 ng/ml and in non-NAS group was 215 ± 66 ng/ml, there was no statistically significant difference between the groups ($p=0.24$). There were no differences in BDNF levels between NAS infants that required one medication versus more than one medication (246 ± 83 vs 218 ± 106 ng/ml, $p=0.54$). There was no correlation between the BDNF levels and LOS ($p=0.85$). There was no correlation between BDNF levels and NAS scores ($p=0.09$) or how NAS scores changed in the first 48 hours ($p>0.05$).

Conclusions There were no differences in the BDNF levels between opiates exposed versus non-exposed infants. In addition, there were no correlations between plasma BDNF levels and the severity of NAS. The limitations of this study include small sample size and other confounders that may affect the BDNF levels such as tobacco use. The study is still ongoing.

387 BLOOD LACTATE LEVELS AS AN INDICATION OF SEVERITY OF HYPOXIC ISCHEMIC ENCEPHALOPATHY

L Subedi, MR Palla, P Westgate, H Bada, A Pant, MD Cunningham. *University of Kentucky, Lexington, KY.*

10.1136/jim-2016-000393.387

Purpose of Study Hypoxic ischemic encephalopathy (HIE) presents with a wide variety of clinical and neurologic abnormalities following an acute event prior to delivery. Therapeutic hypothermia (TH) initiated in the first 6 hours of life is associated with reduced mortality and improved short term neurodevelopmental outcomes. Different parameters have been used as criteria for TH including plasma lactate level (PLL). An initial PLL of ≥ 7.5 mmol/L has been reported to correlate with severity of HIE. The aim of this study was to determine if elevated PLL in the first hour of life were correlated with neurological injury as evidenced by abnormal electroencephalography (EEG) and abnormal brain magnetic resonance imaging (MRI) in our institution.

Methods Used This is a retrospective record review of infants with diagnosis of HIE from 2009 to 2016 and who were treated with whole body hypothermia. Our data as

collected included demographic characteristics, initial PLL, EEG and MRI findings. An indication of severity of HIE was an abnormal EEG (seizures), and an abnormal MRI (infarction and periventricular leukomalacia) and a Sarnat III score.

Summary of Results A total of 50 infants had HIE according to Sarnat criteria and were treated with whole body hypothermia. Mean gestational age and weight of the infants were 38.2 weeks and 3218 grams, respectively. An abnormal MRI was present in 27 infants, 18 had normal findings and 5 were not studied by MRI. Seizures were noted in 34 infants. The median interquartile range (IQR) PLL for infants with normal MRI was 10.6 (7.1, 13.0) mmol/L and 16.0 (8.4, 18) mmol/L in those with abnormal MRI ($p=0.01$) using non-parametric log rank test. Those with seizures had higher PLL, median (IQR) of 13.6 (8.7, 17.2), than those with no seizures, 10.6 (7.5, 13.0) mmol/L, this difference was a trend but not statistically significant. $P=0.11$.

Conclusions These findings support that PLL prior to hypothermia treatment as a useful indicator of severe neurologic injury following an HIE event.

388 RAF1 MUTATION CAUSING SEVERE BIVENTRICULAR HYPERTROPHY IN A PRETERM INFANT

DE Thompson, J Patrick, J Surcouf, D Rivera. *LSUHSC-New Orleans, New Orleans, LA.*

10.1136/jim-2016-000393.388

Case Report Noonan Syndrome (NS) is an autosomal dominant disorder characterized by short stature, distinctive facial features, short neck, congenital heart defects, pectus deformities and variable developmental delays. NS is genetically heterogeneous as the phenotype has been associated with mutations in several genes involved in the Ras/MAPK pathway. Among affected individuals, fifty percent harbor mutations in *PTPN11*, while only 3–17 percent have mutations in *RAF1*.

We present a 34 wga male infant born via emergency cesarean section due to fetal bradycardia. Physical examination revealed macrocephaly with frontal bossing, low set posteriorly rotated ears, sparse eyebrows and eyelashes, short nose with depressed nasal bridge and anteverted nares, lymphedema of hands and feet, and cryptorchidism. Echocardiogram revealed biventricular hypertrophy with suppressed cardiac function. Despite medical management, serial echocardiograms showed worsening hypertrophic cardiomyopathy and severe outflow tract obstruction. He was evaluated as a cardiac transplant candidate, but denied by two transplant centers due to his prematurity and prolonged need for mechanical ventilation. His complicated clinical course consisted of mechanical ventilation ultimately requiring tracheostomy, progressive hydrocephalus secondary to cerebral aqueductal stenosis requiring endoscopic fenestration of the third ventricle, bilateral moderate conductive hearing loss, and gastrostomy tube placement. Given the severe biventricular hypertrophy and dysmorphic features, a genetic etiology was suspected. Molecular testing identified a missense variant in *RAF1*: c.770 C>T

(p.S257L) associated with Noonan Syndrome. Due to his poor prognosis, he was ultimately discharged home from the hospital on a ventilator as a hospice candidate.

This mutation has been previously reported in the literature, most recently associated with the development of pulmonary arterial hypertension (PAH). The infant was monitored closely during hospitalization for the development of PAH. The infant also presented with progressive hydrocephalus due to aqueductal stenosis. This could be related to the NS phenotype or have a different etiology. More cases with this association are needed to confirm this finding.

389 THE EFFECT OF ORAL DEXTROSE GEL ADMINISTRATION ON NICU ADMISSION RATES IN NEONATES WITH HYPOGLYCEMIA

L Travers, C Dudek, R Baker, R Alissa, K Makker. *UF College of Medicine, Jacksonville, FL.*

10.1136/jim-2016-000393.389

Purpose of Study Neonatal hypoglycemia is a common medical problem in the newborn nursery and the neonatal intensive care unit (NICU) with significant medical and financial implications. High rates of NICU admissions result directly from the newborn nursery solely for the management of neonatal hypoglycemia.

Methods Used Currently feeding followed by intravenous (IV) dextrose (D10) as indicated is the standard approach to nursery management of hypoglycemia (AAP). Dextrose gel (40%) has been FDA approved for management of neonatal hypoglycemia. We conducted a comparison study of NICU admission rates in the setting of the previous neonatal hypoglycemia management protocol (AAP) for at risk infants (feed plus subsequent IV D10 and the new/study management protocol involving the use of oral dextrose gel intervention (feed+gel plus subsequent IV D10). The study was approved by institutional IRB. see SSPR methods file

Hypothesis: The use of dextrose gel in the management of neonatal hypoglycemia will decrease the rate NICU admissions for hypoglycemia

Primary Aim: To determine if the use of oral dextrose gel in the hospital reduced the need for IV placement/usage of D10 and subsequent NICU admissions for management of hypoglycemia.

Secondary Aim: To evaluate the effect of using dextrose gel on breastfeeding rates

Summary of Results The neonates analyzed under both protocols were not qualitatively different at baseline

NICU admissions decreased from 16% in the old protocol period to 6% in the new protocol period. The odds of NICU admission were 3 times higher for those managed by the old protocol compared to the new protocol (OR=3.03, 95%CI 1.08, 8.49) (see SSPR 1 file)

Breastfeeding rates increased from 21.1% (old protocol) to 36.9% (new protocol) in the two periods

Conclusions Oral glucose gel significantly and substantially reduced the number of NICU admissions. This simple non-invasive intervention has the potential to substantially reduce healthcare costs while improving patient outcomes.

390 OUTCOMES OF NEONATES WITH TRACHEOSTOMY SECONDARY TO BRONCHOPULMONARY DYSPLASIA

DA Vallarino, K Upadhyay, AJ Talati. *University of Tennessee, Memphis, TN.*

10.1136/jim-2016-000393.390

Purpose of Study Bronchopulmonary dysplasia (BPD) is a disease that can affect preterm neonates. Infants with severe BPD may develop pulmonary hypertension (PHN) and require chronic mechanical ventilation which for long term care may end up requiring a tracheostomy. The outcomes (short and long term) of these infants have not been studied well. We proposed to review survival and outcomes of infants requiring tracheostomy secondary to severe BPD in our NICU.

Methods Used We reviewed infants' charts who were diagnosed with BPD that underwent tracheostomy from January 2007 to May 2016 at our children's hospital NICU. Data were recorded from hospital stay as well as from follow up clinics. Institutional review board approval was obtained prior to beginning study.

Summary of Results 30 babies (27 during initial hospitalization and 3 subsequently) requiring tracheostomy were identified from our database. They had a median gestational age of 26 weeks (24–31 wks), mean birthweight of 742 gm (+262 gm) and 30% were SGA. 73% were males, 77% African American babies and 73% received antenatal steroids. All received surfactant (median 2 doses) and at least one course of postnatal steroids. Median FiO₂ during first 30 days was 0.40, at 36 weeks 0.30, and at time of tracheostomy placement 0.40. PHN was associated with 53% of the cases with 31% mortality. Median age of tracheostomy placement was 168 days (with median PMA 48 wk). 27% of infants required tracheostomy due to subglottic stenosis along with BPD. 80% of infants developed tracheitis after tracheostomy placement. G-tube was needed on 80% of these infants. 6/30 (26%) died prior to discharge. At 2 years followup 48% (11/23) were still mechanically ventilated and 26% (6/23) had been decannulated. 48% (11/23) had more than 3 subsequent hospitalizations.

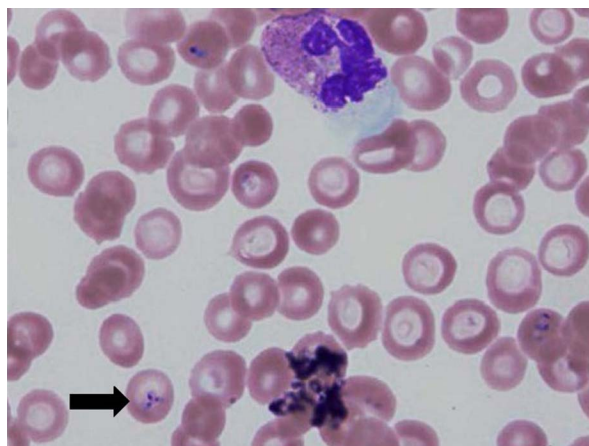
Conclusions In our cohort about two-thirds of infants with severe BPD and tracheostomy survived with need for prolonged home ventilation in almost half. They continue to have high morbidity and recurrent hospitalizations. Long term neurologic outcomes of these infants also need to be evaluated.

391 TICK TOCK: RACING THE CLOCK TO DIAGNOSE A PARASITIC INFECTION IN A NEONATE

K Vincent, EV Schulz, JE Squires, JB Cahill. *Medical University of South Carolina, Charleston, SC.*

10.1136/jim-2016-000393.391

Case Report: Introduction The bloodborne parasite *Babesia microti* is now the most common transfusion-transmitted infection across the USA and potentially fatal in the immunocompromised. Although the tick-borne transmission pattern primarily affects Northeastern states, we present a rare case of transfusion-associated *B. microti*



Abstract 391 Figure 1

diagnosed in a non-endemic state following an evaluation for neonatal hemophagocytic lymphohistiocytosis (HLH).

Case presentation A preterm infant with chronic lung disease and tracheoesophageal fistula (TEF) presented with fever, hepatosplenomegaly, elevated transaminases and coagulopathy. Multiple transfusions were required following TEF repair due to severe anemia and thrombocytopenia. Due to a concern for HLH, a diagnostic peripheral smear was performed (Figure). Donor blood subsequently tested positive for *B. microti*.

Management and Outcome Treatment included double-volume exchange transfusion and antimicrobials.

Discussion We document a case of transfusion-acquired babesiosis in a non-endemic state mimicking HLH. Although recent studies indicate donor testing is now available to detect *B. microti*, routine screening is not currently a standard practice.

Conclusion We argue donation algorithms should screen transfusions allocated to neonates for *Babesia*, due to their immunocompromised state.

392 PHACES SYNDROME

T Wang, J Phillips.

10.1136/jim-2016-000393.392

Case Report Introduction: Congenital sternal agenesis is a rare malformation and can be associated with other syndromes or a simple lone finding. However, all cases of congenital sternal agenesis require further workup to avoid significant sequelae. PHACES (posterior fossa anomalies, hemangioma, arterial lesions, cardiac abnormalities, eye anomalies, and sternal defects) syndrome is a recently described syndrome that should be considered in infants with sternal defects.

Case Presentation The patient was born full-term infant by spontaneous vaginal delivery and immediately noted to have an unfused anterior chest wall with absent sternum and partial cardiac exstrophy (both undiagnosed in utero). Due to concern for other possible anatomic abnormality and persistent respiratory distress, the patient was transferred to our referral hospital for further management.

Upon arrival, an ECHO, CT of chest and abdomen, and head ultrasound were obtained and reassuring for normal cardiac function, no diaphragmatic hernia or intraventricular hemorrhage. Genetics felt that the defect was an isolated finding and Plastics felt that surgery should be done at a later time. The patient was again evaluated at 10 weeks of age and noted to have multiple facial hemangiomas (which developed at 7 weeks of age). Genetics was reconsulted and recommended MRI/MRA of the head along with Dermatology and Ophthalmology consult. MRA showed right internal carotid artery stenosis while ophthalmology found possible right optic nerve compression. Due to these findings, the patient was diagnosed with PHACES syndrome.

Discussion PHACES syndrome is a relatively new diagnostic syndrome first described in 1996 and currently around 400 cases have been noted in the medical literature. Diagnosis of definite PHACES syndrome requires facial hemangiomas greater than 5 cm along with 1 major or 2 minor criteria. However, there is a wide range of possible anomalies and varying degrees of severity so all possible cases of PHACE require an ECHO, MRI/MRA, and ophthalmic exam. There remains no laboratory finding or known gene mutation to make the diagnosis.

Conclusion A wide differential remains for congenital sternal agenesis. Workup for possible syndromes is necessary considering life-long implications and early diagnosis is important for proper management. A video of the newborn infant will be shown.

393 COMPARING THE PROPERTIES OF HUMAN UMBILICAL CORD DERIVED MESENCHYMAL STROMAL CELLS FROM PRETERM VERSUS FULL TERM INFANTS

C Winter, S Balgi, SB Mustafa, L Winter, A Moreira. *UT Health Science Center-San Antonio, San Antonio, TX.*

10.1136/jim-2016-000393.393

Purpose of Study Mesenchymal stromal cells (MSCs) have recently shown promise as therapeutic agents in treating major morbidities associated with premature birth. Umbilical cord Wharton's jelly-derived MSCs (WJ-MSCs) are an ideal source for stromal cells due to their ease of isolation, ethical approval, and potential for autologous administration. However, there is minimal research evaluating functional differences in WJ-MSCs obtained from term versus preterm infants.

Methods Used WJ-MSCs were enzymatically digested from umbilical cord tissue from Term (gestational age ≥ 37 weeks, $n=3$) and Preterm (gestational age ≤ 32 weeks, $n=3$) neonates. Cells were characterized by: (1) surface antigen markers using flow cytometry, (2) ability to differentiate into adipogenic, chondrogenic, and osteogenic lineages following in vitro stimulation, (3) colony forming unit efficiency, (4) proliferation rates and, (5) cell motility assay.

Summary of Results WJ-MSCs were successfully isolated from both Preterm and Term groups. Cells adhered to plastic and displayed characteristic spindle-shaped morphology when cultured under standard conditions. WJ-MSCs from both groups expressed surface antigen markers CD73, CD90, and CD146 ($>95\pm$) and did not express

hematopoietic markers HLADR, CD79, or CD11b ($<5\%$). Preterm and Term cells were capable of differentiating into osteogenic, chondrogenic, and adipogenic lineages. There were no significant differences between the groups when evaluated by colony forming efficiency, proliferation rates, or cell motility.

Conclusions These preliminary findings suggest that WJ-MSCs derived from full term or preterm neonates have similar functional characteristics. Future studies will focus on the regenerative potential of WJ-MSCs from preterm and term infants following changes in the microenvironment (for example, oxygen tension).

394 TWO RARE CONDITIONS, ONE NEONATE

T Woodfin, A Hurst, J Philips. *UAB, Homewood, AL.*

10.1136/jim-2016-000393.394

Introduction Dysmorphic features often warrant a full genetic evaluation in the newborn. The evaluation should emphasize family history, clinical presentation, physical exam findings, and genetic testing. The importance of this stepwise approach is highlighted in a case where two rare conditions coincide.

Case Presentation The patient presented as a 3 day old male transferred from an outside hospital due to an increasing oxygen requirement and dysmorphic features including hypotonia, low set ears, pectus excavatum, wide spaced nipples, broad pear shaped nose, cryptorchidism and coarse hair. He was born via C-section due to preterm labor with breech presentation at 35.5 weeks gestation to a 36-year-old female with one prior spontaneous abortion. Family history was significant for a maternal uncle that died at 13 months old due to congenital anomalies. The family also reported they thought mother's brother had Menkes Disease, but the diagnosis was never confirmed. Head ultrasound prior to transfer showed agenesis of corpus callosum. Echo showed pulmonary HTN with large PFO vs ASD. Given the above presentation, a microarray was sent that showed 17 q21.31 deletion consistent with Koolen De Vriens Syndrome. Due to the unusual nature of patient's hair and family history, genetic testing for copper transport mutation was sent and was positive for Menkes Disease. The patient was started on Copper Histidine intramuscular injections BID.

Discussion Koolen De Vriens Syndrome (17 q21.31 deletion) is characterized by hypotonia, feeding difficulty, developmental delay, and characteristic facial features (broad/pear shaped nose). This occurs in 1 in 16,000 births. The prognosis is highly variable depending on presentation. Menkes disease is an X-linked recessive inherited disease that occurs in 1 in 100,000 births and is caused by a mutation in ATP7A (chromosome 13), which codes for a transport protein that mediates copper uptake from the intestine. Symptoms include unusual 'kinky' hair, growth retardation, bony abnormalities, severe neurologic impairment and seizures. The prognosis of Menkes is poor with death often occurring in the first decade of life.

Conclusion This case highlights the importance of a thorough evaluation, given that this patient had two rare conditions with very different natural histories and treatment courses.

Pulmonary and Critical Care Medicine
 Joint Plenary Poster Session and Reception
 4:30 PM
 Saturday, February 11, 2017

395 HIGHER TRIAGE TEMPERATURE IS ASSOCIATED WITH INITIALLY INAPPARENT SEPSIS IN THE EMERGENCY DEPARTMENT

MI Bender,² CE Lumb,² TA Edgij,² CM Pruitt¹. ¹University of Alabama at Birmingham, Birmingham, AL; ²University of Alabama School of Medicine, Birmingham, AL.

10.1136/jim-2016-000393.395

Purpose of Study The detection of pediatric sepsis is a challenge for the clinician. Little is known about children not initially thought to have sepsis in the emergency department (ED), but who go on to be diagnosed with sepsis-related illness. The purpose of our study was to investigate demographic and clinical data in children initially not suspected of having sepsis, but who ultimately receive a sepsis-related diagnosis.

Methods Used This is a sub-study of our single-center data within the Pediatric Septic Shock Collaborative, a quality improvement effort of the American Academy of Pediatrics for reliable triage identification and early goal-directed therapy for children with possible sepsis. Cross-sectional data over two years were analyzed for patients identified by our emergency department (ED) triage tool as having findings concerning for sepsis, and who ultimately had ICD-10 codes consistent with sepsis (determined *a priori*). Demographic and clinical data were compared between children for whom the treating physician treated as having potential sepsis vs. those for whom the sepsis pathway was stopped. Normally distributed data are presented as means with 95% confidence intervals (CI), and were compared with a two-tailed independent samples t-test, with $P < 0.05$ considered statistically significant.

Summary of Results One hundred ninety-three patients were treated for possible sepsis during the study period, with 90 (47%) of these having ED or inpatient diagnoses consistent with sepsis. Of this subgroup, physicians for 13 children ordered the sepsis protocol to be stopped. The patients who were treated for suspected sepsis had higher temperatures in triage (102.8, 95% CI 102.3–103.4) than those for whom the protocol was stopped (101.4, 95% CI 100.2–102.6) ($P = 0.03$). All other demographic and clinical data did not differ between these groups.

Conclusions For patients who have a positive triage screening for sepsis, but for whom the physician is less concerned, a higher triage temperature may indicate that suspicion should be heightened for this potentially life-threatening clinical entity.

396 RISK FACTORS PREDICTING READMISSION TO THE HOSPITAL IN PATIENTS WITH BRONCHIOLITIS

R Evans,¹ C Pham,¹ S Slagle,¹ R Amin,² JJ Burns¹. ¹University of Florida, Pensacola, FL; ²University of West Florida, Pensacola, FL.

10.1136/jim-2016-000393.396

Purpose of Study To demonstrate the relationship of demographic and clinical risk factors to hospital readmission rates for children with bronchiolitis.

Methods Used Upon IRB-approval, a retrospective chart review was completed on total of 234 patients under 2 years of age who were admitted from January 2010 to June 2015. Patient length of stay on first admission, tobacco exposure, breast feeding status, family history of asthma, daycare exposure, comorbidities (neurologic, infectious, genetic conditions), specific viral infection, use of Synagis, identification of virus, gestational age, chronologic age, insurance type, race, sex, and number of days symptomatic prior to initial admission were analyzed for relationship to readmission status.

Summary of Results Readmission with bronchiolitis occurred for 11% of 234 patients. Tobacco smoke exposure occurred in 38% of the 234 patients. Readmission was significantly increased in patients with tobacco smoke exposure (66.7%) vs. no smoke exposure (33.3%) (Chi-square $p = 0.002$). On logistic backward regression of all variables only tobacco smoke exposure was related to readmission (odds ratio 3.671, $p = 0.003$).

Conclusions Tobacco smoke exposure was the only identifiable risk factor among several for pediatric readmissions with bronchiolitis. Clinicians should educate parents and advocate avoidance of tobacco smoke in order to help reduce the rate of pediatric readmissions with bronchiolitis.

397 SINONASAL AND LARYNGEAL SARCOIDOSIS – UNCOMMON PRESENTATION AND OBSTACLES IN MANAGEMENT

P Chariyawong, H Edriss. Texas Tech University Health Sciences Center, Lubbock, TX.

10.1136/jim-2016-000393.397

Introduction Sarcoidosis is non-caseating granulomatous disorder of unknown etiology, it involves multiple organ system throughout the body. Estimated prevalence is 10 to 20 per 100,000 populations with higher incidence among African American people.¹ Common manifestations are bilateral hilar adenopathy, lung, skin, joint and eyes lesions. We report a rare case of sinonasal and laryngeal involvement.

Case A 55 year-old woman diagnosed cutaneous sarcoidosis by skin biopsy in 2004 and has been on oral corticosteroid since then. She presented with shortness of breath (SOB), hoarseness of voice and worsening of sinusitis. Patient reported history of chronic sinusitis for several years and she was diagnosed with allergic rhinitis at outside facility. Computed tomography (CT) of neck revealed bilateral maxillary, palate and floor of nose erosions suspicious for malignancy. Sinonasal sinus endoscopy showed bilateral narrow nasal vestibule with cobblestone mucosa. Biopsy from the right floor vestibule revealed a chronic non-caseating granulomatous inflammation. Patient also had bronchoscopy to evaluate for dysphonia and stridor which showed swollen epiglottis and vocal cords with a subglottic nodular lesion. Patient was treated with high dose systemic corticosteroid with difficulty tapering down due to persistent of respiratory symptoms. Once methotrexate IV and

hydroxychloroquine were added, her symptoms were improved.

Discussion Sinonasal and laryngeal involvement are both rare presentations of extra-pulmonary sarcoidosis with an incidence rate of 0.3–1%.² Sinonasal involvement may present with upper respiratory symptoms that mimics allergic symptoms such as our patient. In laryngeal form, patients present with dysphonia and SOB and it can progress to severe airway obstruction and potentially life threatening complications. Management of our patient was very challenging due to lack of response to prolonged therapy of systemic corticosteroid. She required methotrexate and hydroxychloroquine in addition to corticosteroid.

REFERENCES

- 1 Thomas KW, Hunninghake GW. Sarcoidosis. *JAMA* 2003;289:3300–3.
- 2 Mastan S, Advani R, Stobbs N, et al. A rare manifestation of a multisystemic disease: a case of vocal cord palsy secondary to sarcoidosis. *BMJ Case Rep* 2015 Apr 26; 2015.

398 SEVERE, LIFE-THREATENING PANCREATITIS AND SHOCK IN ADOLESCENT WITH AN INHERITED LIPODYSTROPHY

M Cotti-Rausch, A Brown, C Rutledge. *University of Alabama at Birmingham, Birmingham, AL.*

10.1136/jim-2016-000393.398

Case Report A 17 year-old female with partial familial lipodystrophy (PFL) and insulin-dependent diabetes presents with shock after a day of nausea, vomiting and abdominal pain. Workup at the referring hospital revealed metabolic acidosis, hyperglycemia, and ketonuria. She was placed on an insulin drip due to concern for diabetic ketoacidosis. On arrival to our facility, exam was significant for altered mental status, respiratory distress, and abdominal distension. She developed worsening shock and required intubation, ongoing fluid resuscitation, electrolyte replacement and antibiotics.

Her serum was grossly lipemic with markedly elevated lipase (3356) and triglycerides (6074), suggesting pancreatitis as the etiology of her septic shock. Other notable lab abnormalities included severe acidosis, profound hypocalcemia and hypoalbuminemia. She required greater than 15 L of isotonic fluids as well as inotropic support and shock-dose steroids. With ongoing resuscitation, she developed abdominal compartment syndrome requiring emergent bedside laparotomy with open abdomen.

The etiology of her pancreatitis was initially unclear; however, discussion with her family revealed that she had discontinued her NIH-directed medications two days prior to presentation. One of those was *Metreleptin*, an

experimental therapy for the metabolic derangements associated with PFL. Consultation with the prescribing NIH physician confirmed that abrupt discontinuation can result in life-threatening pancreatitis. Leptin was restarted, and over the following days she was weaned off inotropic support. Her abdomen was closed after five days, and she was extubated on day nine of admission. She was discharged home after 18 days in the hospital.

Acute pancreatitis is becoming an increasingly recognized disorder in pediatric patients. However, it remains a rare cause of severe septic shock, making early recognition and diagnosis imperative to appropriate management. This case illustrates the complex presentation, life-threatening complications and importance of a complete history in a pediatric patient with acute pancreatitis. Although the exact pathophysiology linking abrupt discontinuation of leptin therapy to pancreatitis is unclear, it is a recognized complication of this experimental treatment.

399 LABORATORY VALUES IN THE EMERGENCY DEPARTMENT DO NOT PREDICT PEDIATRIC SEPSIS

TA Edgil,² CE Lumb,² MI Bender,² CM Pruitt¹. ¹University of Alabama at Birmingham, Birmingham, AL; ²University of Alabama School of Medicine, Birmingham, AL.

10.1136/jim-2016-000393.399

Purpose of Study Reliable means of predicting pediatric sepsis are lacking for the clinician. While many clinical findings and laboratory values are thought to be associated with sepsis, data are conflicting as to their utility in children. The purpose of our study was to identify whether common laboratory tests reliably differentiate between pediatric septic shock and other closely related illnesses.

Methods Used Cross-sectional data over two years were analyzed for patients identified by our emergency department (ED) triage tool as having findings concerning for sepsis, and who were treated as such. Laboratory values were compared between children with ICD-10 codes consistent with sepsis (determined *a priori*) and those with alternative diagnoses. To minimize intrinsic bias, analyses were also performed for those subjects with only inpatient discharge codes (i.e. not ED codes) of sepsis. Normally distributed data were compared with an independent samples t-test, and non-parametric data were analyzed with a Mann-Whitney test. All tests were two-tailed, with P<0.05 considered statistically significant.

Summary of Results One hundred ninety-three patients were treated for possible sepsis during the study period, with 90 (47%) having either ED or inpatient diagnoses consistent with sepsis. White blood cell counts, absolute

Abstract 399 Table 1

	ICD-10 sepsis (n=90)	ICD-10 not sepsis (n=103)	P
WBC (cells/mcL) (median, IQR)	12,840 (5,680–21,430)	11,540 (9,080–15,930)	0.60
ANC (cells/mm3) (mean, 95% CI)	9,133 (3,420–15,380)	8,604 (4,630–11,250)	0.56
CRP (mg/L) (median, IQR)	5.93 (3.00–14.75)	3.90 (0.85–5.76)	0.02
Lactate (mmol/L) (mean, 95% CI)	2.9 (1.3–3.9)	2.6 (1.4–3.8)	0.41

WBC=white blood cell count; IQR=interquartile range; ANC=absolute neutrophil count; CRP=C-reactive protein

neutrophil counts, and lactate did not differ between those with sepsis diagnoses and those without. C-reactive protein (CRP) values were higher for those patients with diagnoses consistent with sepsis. However, when only considering inpatient diagnoses, CRP was not different between those with sepsis and those without (median 6.00 vs. 4.22 mg/L [$P=0.16$]).

Conclusions Laboratory values obtained in the ED for children with suspected sepsis do not predict ultimate diagnoses of sepsis. CRP may be the most promising laboratory test for future research.

400 JUST AN INTERN'S LUNG TUMOR?

C Pirtle, J Decuir, D Englert, LS Engel. *LSU Health Sciences Center, New Orleans, LA.*

10.1136/jim-2016-000393.400

Case Report INTRODUCTION: The recommended screening test for lung cancer is a Computed tomography (CT) scan of the chest. Chest radiograph, particularly the portable x-ray often taken on arrival to the Emergency Department provides major confounding factors such as artifact and bone shadows. We present a case that demonstrates an example how a boney shadow can sometimes turn out to be more clinically significant than anticipated.

Case A 79-year-old woman with a past medical history of type two diabetes mellitus, hypertension, kyphosis, COPD, and urinary incontinence presented with two weeks of worsening weakness and fatigue. She also had a non-productive cough associated with mild shortness of breath and chest pain. She denied recent illness, nasal congestion and sore throat. Single view chest X-ray was shot with suspicious lesion underlying the first rib. The nodule was seen but due to the position behind the radiographic shadow of the first rib, there was a possibility that this was an artifact. A chest CT scan was obtained and a 2.0 cm non-calcified soft tissue nodular mass abutting the adjacent pleura in the anterior subapical left upper lung field was demonstrated. A follow up PET CT characterized an avid left apical lung mass uptake in area of previously identified lung mass without metastasis. Due to the location of the mass, interventional radiology was unable to perform a biopsy. The patient received a left upper lung wedge resection and pathological examination revealed squamous cell carcinoma with clear margins.

Discussion This patient's course was complicated by the difficulty to detect and inability to biopsy the lung mass which ultimately required left upper lung resection. This patient was initially admitted for generalized fatigue and weakness with non-productive cough when incidentally a 2.0 cm non-calcified soft tissue nodule that was traced out behind the shadow of the 1st rib. This mass may have never been discovered in such an early stage if not for unrelated weakness and advance imaging modalities.

401 DROWNING WHILE BREATHING

MA Farinacci Vilaro, H Maldonado, L Gerena, K Rivera, M Yunes, M Rivera. *San Juan City Hospital, San Juan, PR.*

10.1136/jim-2016-000393.401

Case Report Hemoptysis is defined as bleeding originated from the lower respiratory tract that is usually self-limiting but in few cases can present as a serious life threatening disease due to the amount of blood loss. This is a challenging condition to treat, being asphyxiation the most common cause of death. Treatment options consist of conservative management with a mortality rate as high as 50% to 100%, or bronchial artery embolization, with lower mortality rate of 7.1% to 18.2%.

This is the case of a 76-year-old man with past medical history of bronchiectasis that presents to our institution with a history of hemoptysis for the last 2 years and associated fatigue. He refers usually has 1 episode of hemoptysis every morning when waking up of approximately 8 oz. He has been previously evaluated on multiple occasions with bronchoscopy, sputum studies and imaging studies with no definitive diagnosis besides bronchiectasis. He denies recurrent episodes of pneumonia or history of smoking but reports that he has been exposed to an unknown toxic substance at his previous workplace. Physical exam remarkable for inspiratory crackles at bases, decreased breath sound on left lobe and decreased breath sounds in right middle lobe. Chest CT scan shows patchy ground glass opacities superimposed on interstitial fibrosis, honeycombing and bronchiectasis within the upper and lower lungs bilaterally. CT angiography was performed that revealed arteriovenous malformation of the bronchial and pulmonary artery. Interventional Radiologist performed a successful embolization with complete resolution of patient's hemoptysis.

The significance of this case relies on the few cases that are diagnosed with bronchopulmonary arteriovenous malformation as in our case and corrects after arterial embolization giving the patient another living opportunity, taking in consideration the high mortality rates associated to this condition.

402 HIDDEN BEHIND THE EFFUSIONS LIES AN UNEXPECTED DIAGNOSIS

MA Farinacci Vilaro, M Cruz, M Yunes. *San Juan City Hospital, San Juan, PR.*

10.1136/jim-2016-000393.402

Case Report Angioimmunoblastic T cell lymphoma (AITL) a rare but distinct type of T cell lymphomas with aggressive course and high mortality. It accounts for approximately 1%- 2% of non-Hodgkin's lymphoma, with an annual incidence of 0.05 new cases per 100,000 people in US. It usually affects older adults; the median age is 60–65 yrs and some reports have noted a slight male predominance. AITL typically presents with generalized lymphadenopathy, hepatosplenomegaly, and constitutional symptoms of fever and weight loss. Pulmonary involvement along with ascites occurs in a 20% of patients.

Case of a 59yo female patient with past medical history of hypothyroidism and endometriosis; that was on her usual state of health until march/2016. She presents for evaluation with a chief complaint of fatigue, shortness of breath and dry cough, associated with generalized non itching urticarial rash, nonquantified fever, arthralgia, and approximately 10 pounds weight loss. Physical exam was

evident for the urticarial rash, generalized lymphadenopathy on the neck, axilla and groin, right hemithorax decreased breath sounds, dullness to percussion up to 2/3 and similar findings on the left pulmonary base. Patient was admitted for workup and treatment, thoracentesis was performed in 3 different occasions due to recurrence of pleural effusions and worsening of symptoms with patient being dependent of oxygen therapy. Patient was misdiagnosed with a viral infection and then with a rheumatologic disease in view that patient symptoms and pleural effusions responded significantly to steroids. After recurrence of pleural effusions, with results suggesting lymphoproliferative disorder, bone marrow biopsy was performed and diagnosis of AITL was done. After this findings patient was started on treatment and patient is doing well.

Among the 1–2% of patients with AITL only 20% developed pleural effusion, in our case the main presentation. This is an aggressive disease that has a high mortality. Spontaneous remission has been observed if patient is diagnosed and treated early, with a 3 years survival of up to 81% depending on the international prognostic index and progression free survival rate of 38%. Due to the aggressiveness of this condition physician should be aware of this rare entity.

403 ABRUPT CESSATION OF ISOPROTERENOL RESULTING IN HYPERKALEMIA IN A PACEMAKER-DEPENDENT PATIENT

S Henson, R Schwartz. *University of Oklahoma, Oklahoma City, OK.*

10.1136/jim-2016-000393.403

Case Report Severe hyperkalemia can result in a life-threatening arrhythmia and if not treated promptly may progress to cardiac arrest. Elevated potassium (K^+), characteristic ECG changes, and a known clinical etiology are generally taken together to make a timely diagnosis.

We report on a 17 year old male who underwent the Fontan procedure for double inlet left ventricle and levo-transposition of the great and became pacemaker dependent secondary to complete heart block. He presented to the emergency department with lightheadedness, bradycardia, and normal electrolytes. His pacemaker was found to be non-functional after interrogation. An isoproterenol infusion was started at 0.05 mcg/kg/min. During his pacemaker generator and pacing lead replacement isoproterenol was increased to 0.1 mcg/kg/min briefly and then stopped upon confirmation that the new pacing system was functional. Routine postoperative iSTAT K^+ from an arterial line was 7.4 mEq/dL. This value was thought to be erroneous since no immediate etiology for elevated K^+ was forthcoming and he was asymptomatic. Additionally, given the patient's pacemaker, assessing the T wave would not be possible. K^+ was confirmed to be >7 mEq/dL by repeat iSTAT and serum chemistry. K^+ normalized within the hour after treatment with aerosolized albuterol, furosemide and calcium chloride.

Beta-receptor agonists are known to cause intracellular shifting of K^+ through subsequent stimulation of active sodium-potassium transport across the cellular membrane.

While non-selective beta-blockers are known to result in an increase in potassium in the setting of a large K^+ load or exercise, severe hyperkalemia due to an abrupt withdrawal of a beta-agonist is not a well-known phenomenon.

A clinically stable patient without an obvious reason for severe, acute hyperkalemia, coupled with the absence of characteristic ECG changes due to a pacemaker resulted in a significant delay in the treatment of a potentially life-threatening condition. We hope that by presenting this case clinicians will become aware of the potential for significant hyperkalemia due to the abrupt cessation of potent beta-agonist infusions.

404 OBSTRUCTIVE SLEEP APNEA, ASTHMA AND CHRONIC OBSTRUCTIVE PULMONARY DISEASE- LONG-TERM OUTCOMES IN A COHORT OF 1,314 VETERANS

N Janocko,¹ M Ciavatta,² O Ioachimescu^{1,2}. ¹Emory University School of Medicine, Atlanta, GA; ²Atlanta VA Clinic, Decatur, GA.

10.1136/jim-2016-000393.404

Purpose of Study The long-term morbidity and mortality attributable to asthma, chronic obstructive pulmonary disease (COPD), obstructive sleep apnea (OSA) and their co-existence in various 'overlap' syndromes has not been fully evaluated.

Methods Used We performed an analysis on 1,314 patients enrolled at the Atlanta VA in the OLDOSA (Obstructive Lung Disease and Obstructive Sleep Apnea) cohort, which was started in 2008. We assessed long-term outcomes (morbidity and mortality) in relationship to existing diagnoses of asthma, COPD, OSA or a combination of these conditions.

Summary of Results 1,314 patients have been included in our analysis (mean age 66 years; 93% men; 59% Caucasians and 39% African Americans). Overall, we found a cumulative mortality rate of 52%, over a period of follow-up of approximately 8.5 years. Patients with COPD, asthma and OSA had cumulative mortality rates of 64%, 15% and 34%, respectively. Subjects with COPD and asthma, or COPD and OSA had mortality rates of 54% and 50%, respectively. Those who had all three diagnoses had a cumulative mortality rate of 33%. We adjusted various statistical models by using a well-established morbid load, i.e., Charlson Comorbidity Index (CBI). Patients with COPD had higher CBI (6.1%) vs subjects with asthma (4.5%) or OSA (4.9%). In patients with OSA who were using continuous positive airway pressure (CPAP), mortality rate was 23%, while in those not using CPAP therapy, mortality rate was 36% ($p=0.04^*$). Approximately 34%, 24% and 11% of patients with OSA had long-term outstanding, excellent and good compliance, respectively.

Conclusions We found that patients with a diagnosis of COPD had a higher mortality rate than asthma or OSA and this may be explained by a higher comorbid load, as measured by the Charlson Comorbidity Index. In subjects with a diagnosis of OSA, we found that those using CPAP therapy had a mortality rate that was lower than in those not using CPAP therapy.

405 TAT SIGNIFICANTLY IMPAIRS ANTIOXIDANT AND INNATE IMMUNE DEFENSES IN ALVEOLAR MACROPHAGES

A Kukoyi,¹ B Staitieh,¹ X Fan,¹ D Guidot^{1,2}. ¹Emory University, Atlanta, GA; ²Atlanta VA, Decatur, GA.

10.1136/jim-2016-000393.405

Purpose of Study Prior work from our group and others has demonstrated significant deficiencies in the alveolar macrophages of individuals living with HIV-1 infection, particularly in antioxidant defenses and innate immune function. Using an HIV-1 transgenic rat model, we have demonstrated that many of these impairments can be replicated through the actions of HIV-related viral proteins (such as Tat, Rev, Nef, and gp-120), that are present in the alveolar space. Given its known effects on other tissues, we focused on Tat as a potential mediator of alveolar macrophage impairment and undertook a series of experiments to determine the effects of Tat on Nrf2, the master transcription factor responsible for antioxidant defenses as well as a series of key innate immune effectors.

Methods Used NR8383 cells, a rat alveolar macrophage cell line, were treated with recombinant Tat protein (10, 50, and 100 ng/ml) for 24, 48, or 72 hrs. After the treatment period, antioxidant defenses were assessed by quantifying gene expression of Nrf2 and its downstream effectors NQO1 and GCLC, and innate immune function was assessed by quantifying gene expression of the innate immune effectors TNF- α and LL-37, by RT-PCR.

Summary of Results Tat significantly decreased gene expression of Nrf2, NQO1, and GCLC in NR8383 cells. The decrease was most pronounced 24 hrs after exposure to 50 ng/mL of Tat. A similar effect was noted with TNF- α , while LL-37 showed significant suppression with 50 ng/mL of Tat after 72 hrs of treatment.

Conclusions The HIV-related protein Tat significantly impairs both innate immune and antioxidant defenses in alveolar macrophages. The varied time points at which Tat maximally suppressed gene expression of the various targets studied suggests that multiple mechanisms are likely at work. Further experiments are necessary to determine the mechanisms through which Tat acts so that its harmful effects can be countered therapeutically in the future.

406 MEDIASTINAL MASS EFFECT MASQUERADING AS A PULMONARY EMBOLISM

W Li, D Sivalingham, A Sharma. *SUNY Upstate Medical University, Syracuse, NY.*

10.1136/jim-2016-000393.406

Case Report Pulmonary embolisms exist as one of the most over diagnosed and incorrectly diagnosed of conditions within critical and emergent settings. Because of the potential lethal course pulmonary embolisms follow within a short period of time, early diagnosis is crucial for initiation of life sustaining treatment and measures, however, over or misdiagnose carries arguably equal if not more devastating outcomes. Our patient was a 60 year-old male patient with a history of chronic obstructive pulmonary

disease, diastolic heart failure, Coronary Artery Disease and stage 4 lung carcinoma who presented with worsening generalized weakness, lightheadedness, and shortness of breath. With moderate pre-test probability per Well's criteria, initial chest radiography revealed pleural effusion more remarkable on the left concerning for an acute process with coinciding marked pro-BNP elevation and EKG findings of a new developing right bundle branch block suggestive for right ventricular strain. Subsequent CT Angiography was suspicious for a filling defect as evidenced by effacement of the left pulmonary artery. With physical exam findings significant for observed labored respirations along with decreased left-sided breath sounds, and given his active malignancy precipitating a hyper-coagulable state, pulmonary embolism remained high in the differential. Further discussion suggested a metastatic enlarging mediastinal mass secondary to primary lung carcinoma causing effacement of the left pulmonary artery proved more likely the etiology of the patient's symptomatology given his medical history. Delayed diagnosis however impeded initiation of emergent life-sustaining measures including urgent radiation therapy to downsize the aforementioned mass effect produced by the effacing mediastinal tumor. With completion of such urgent treatment by the radiation oncology service, the patient's symptoms improved markedly and was soon discharged. While pulmonary embolism is a life-threatening condition, over and misdiagnosis can delay proper management in certain instances. As a result, it is imperative that we take into consideration other differentials such as a metastatic mass effect in individuals with an oncological medical history suggestive of such in order to properly initiate life sustaining treatment.

407 TCA INDUCED LEFT BUNDLE BRANCH BLOCK

W Li, J Lamichhane, A Kahlon. *SUNY Upstate Medical University, Syracuse, NY.*

10.1136/jim-2016-000393.407

Case Report A 41 year-old Male with a history including alcohol abuse, diabetes mellitus type II, and major depressive disorder who was found unconscious by his estranged spouse with a suicide note and an empty bottle of amitriptyline. Found to have a novel left bundle branch block (LBBB), the patient also exhibited ventricular arrhythmias (tachycardia and fibrillation) necessitating unsynchronized defibrillation and intubation for hyperemic hypercarbic respiratory failure. Cycling cardiac enzymes (Troponin T and CK-MB) revealed values within normal limits and repeat EKGs exhibited a prolonged QT interval (541 msec) along with the LBBB (QRS 140 msec, Dominant S wave in V1, Broad monophonic R wave in leads I, aVL, V5-V6 and the absence of Q waves in the lateral leads) though without significant ST or T wave abnormalities signifying underlying heart disease. An echocardiogram confirmed the dysnergic septal motion consistent with the LBBB though displayed normal left ventricular systolic function and lacked other findings consistent with diminished cardiac function. Found to be in diabetic ketoacidosis (DKA) during this hospital course which resolved with medical management, his hospital course was otherwise complicated with a brief

psychiatric unit stay for suicidal ideations. Subsequent EKGs showed resolution of the LBBB and the patient was discharged upon psychiatric clearance. The significance of a LBBB finding ranges from benign to playing an integral factor in the risk/benefit assessment of using thrombolysis and can suggest underlying heart disease. Etiologies of LBBB include ischemic heart disease, hypertension, aortic stenosis, myocardial infarctions, and hyperemia to name a few with Digoxin toxicity being the most well known medication induced etiology. Toxicity with tricyclic antidepressants (TCA), while having documented risks of prolonged QT and widening QRS intervals due to anticholinergic properties, have few instances of LBBB in medical literature. The presence of a LBBB in individuals otherwise devoid of organic heart disease and no clinical presentation significant for electrolyte derangements, hemodynamic instability, organic or ischemic heart disease should hold medications such TCAs in the differential. The relevance of such can influence medical management and alter the course of a patient's medical care.

408 TARGETED THERAPEUTIC TIMES AND ASSOCIATION WITH HOSPITAL LENGTH OF STAY: DESCRIPTIVE STUDY OF A PEDIATRIC SEPSIS PROTOCOL

CE Lumb,² MI Bender,² TA Edgil,² CM Pruitt¹. ¹University of Alabama at Birmingham, Birmingham, AL; ²University of Alabama School of Medicine, Birmingham, AL.

10.1136/jim-2016-000393.408

Purpose of Study In pediatric sepsis, early recognition and goal-directed therapies are of utmost importance. We describe our local emergency department (ED) efforts for rapid identification and treatment of sepsis. We further sought whether timeliness of therapies was associated with decreased hospital length of stay (LOS) for these children.

Methods Used Cross-sectional data over two years were analyzed for patients identified by our ED triage tool as having findings concerning for sepsis, and who were treated as such. Process measures included first isotonic fluid bolus within 20 minutes of recognition; antibiotics within 60 minutes; and third fluid bolus (when needed) within 60 minutes. LOS was compared between patients receiving timely therapies and those who had delayed treatments with a two-tailed Mann-Whitney test, with $P < 0.05$ considered statistically significant. To control for severity of illness, additional analysis excluded children who received positive-pressure ventilation, pressor medications, or who were in the intensive care unit at any time during their hospital stay.

Summary of Results One hundred seventy-two patients received treatment for possible sepsis during the study period. Median minutes to therapies are as follows: first fluid bolus 21 (IQR 16–30); antibiotics 31 (IQR 19–63); and third fluid bolus 105 (IQR 60–148). Only 59 (34%) of the children had all of their interventions administered within the targeted timeframe. Median hospital LOS for patients receiving timely therapies was 110 hours (IQR 70–246) vs. 68 hours (IQR 43–134) for those whose interventions were delayed ($P = 0.002$). Excluding critically ill children, median LOS remained longer for those with timely

therapies (77 hours, IQR 61–157) vs. those with delayed treatment (59 hours, IQR 39–95) ($P = 0.002$).

Conclusions Few patients with possible sepsis receive therapies within targeted timeframes. Antibiotics may be over-prioritized by the bedside clinician. Hospital LOS is longer for children with timely therapies than those with delayed treatments, even when controlling for severity of illness. Other factors that contribute to LOS for children with possible sepsis deserve further exploration.

409 OVERNIGHT OXIMETRY IN BRONCHOPULMONARY DYSPLASIA

CN Martin,¹ L Stodghill,² D Lozano,¹ B Turner¹. ¹University of Alabama-Birmingham, Birmingham, AL; ²Children's of Alabama, Birmingham, AL.

10.1136/jim-2016-000393.409

Purpose of Study Bronchopulmonary dysplasia (BPD) is the leading respiratory diagnosis in premature infants, is often associated with other respiratory co-morbidities, including sleep-disordered breathing (SDB). Little data on the prevalence of SDB in BPD exists. We sought to evaluate the prevalence of SDB in the BPD population and to assess the overnight pulse oximetry as a screening tool for SDB in BPD.

Methods Used In this single-center, cross-sectional study we examined the charts of infants diagnosed with BPD in a quaternary-care children's hospital from August 2006 through March 2016. We defined infants who 'failed' overnight oximetry studies as those who spent $>2-5\%$ of the study time with O_2 saturation $<90\%$ or those infants with mean O_2 saturation $<95\%$. We also reviewed the overnight oximetry study for: mean O_2 saturation, lowest O_2 saturation, mean pulse rate, percent of total study time with O_2 saturation of 95–99%, 90–95%, and $<90\%$. We then identified infants who failed the overnight oximetry study that also had an overnight polysomnography study (PSG). The PSG was used to assess the apnea hypopnea index (AHI) and designation of obstructive or central apnea. Findings were then correlated with overnight oximetry results.

Summary of Results A total of 465 patients with BPD completed an overnight oximetry study. Sixty patients (13%) failed their overnight oximetry screening. Mean O_2 saturation was 92.5% (range: 86–96%) with a mean heart rate of 108 beats per minute (69–148 bpm). Mean low saturation was 73.5% (58%–91%). Twenty five of these patients underwent PSG, and 88% had an AHI >1 . Mean AHI of all PSGs was 6.3. No significant correlation between oximetry study and AHI exists.

Conclusions Our study demonstrates 13% of infants with BPD failed overnight oximetry study and over 35% of these infants failed their screening study with an abnormal AHI on PSG. Though not statistically significant, more impressive findings on overnight oximetry studies seem to occur in infants with a higher AHI on PSG. This study is limited by its retrospective nature and relatively few patients having undergone PSG. Based on these findings, we suggest care providers consider a PSG to assess for sleep disordered breathing as a possible cause for persistent O_2

requirement in BPD patients who fail overnight oximetry study.

410 ACTIVATION OF NRF2 ATTENUATES MIR-21 AND RESTORES SMAD7 EXPRESSION IN ALCOHOL-EXPOSED LUNG FIBROBLASTS

L Marts,¹ D Green,^{2,1} D Guidot,^{1,2} V Sueblinvong¹. ¹Emory University, Atlanta, GA; ²Atlanta VA, Decatur, GA.

10.1136/jim-2016-000393.410

Purpose of Study We previously determined that alcohol exposure inhibits Nrf2, the master transcription factor that activates anti-oxidant responses, and induces transforming growth factor- β 1 (TGF β 1) in the lung and in lung fibroblasts with pathophysiological consequences. Further, treatment with the Nrf2 activator sulforaphane attenuates alcohol-induced TGF β 1 expression in lung fibroblasts. However, the mechanisms by which alcohol and Nrf2 modulate TGF β 1 are unknown. Several microRNAs (miRs) have been shown to regulate gene expression through suppression of gene transcription and down-regulation of a target gene. miR-21 has been shown to target Smad7, a TGF β 1 inhibitor. We hypothesized that alcohol induces TGF β 1 expression through upregulation of miR-21 and subsequent suppression of Smad7 in lung fibroblasts. In addition, we predicted that activating Nrf2 with sulforaphane attenuates this effect through down-regulation of miR-21 expression, which in turn restores Smad7 expression.

Methods Used Mouse primary lung fibroblasts (PLFs) were cultured \pm alcohol (60 mM) \pm sulforaphane (5 mM). miR-21 expression was analyzed at 24 hours. In parallel, Smad7 gene and protein expression were analyzed at 24 and 72 hours, respectively. In parallel, 3T3 NIH lung fibroblasts were transfected with Nrf2 silencing RNA (or appropriate controls) and treated with sulforaphane. Smad7 gene expression was analyzed at 24 hours.

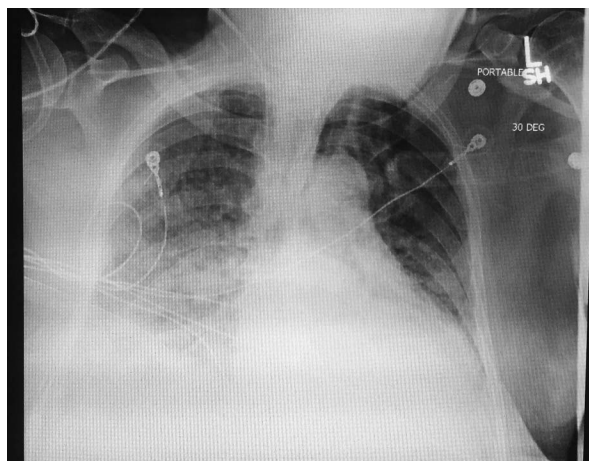
Summary of Results Alcohol exposure increased miR-21 expression in PLFs and decreased Smad7 gene and protein expression. In contrast, sulforaphane attenuated miR-21 expression and increased Smad7 expression in alcohol-treated cells. Interestingly, Nrf2 silencing inhibited the effect of sulforaphane on Smad7 gene expression.

Conclusions Alcohol inhibits Nrf2 activity and in parallel (or as a consequence) induces miR-21 and suppresses Smad7. We speculate this is at least one mechanism through which alcohol induces TGF β 1. It appears that alcohol-mediated induction of miR-21 and Smad7 is attenuated by sulforaphane via a Nrf2 signalling pathway. These findings provide a potential mechanism by which treatment with Nrf2 activators such as sulforaphane could limit injury and/or promote repair in the lungs of individuals with alcohol use disorders.

411 A UNIQUE CASE OF CHEST XRAY WHITE OUT

A McCarthy, K Esmail, V Seeram. University of Florida Jacksonville, Jacksonville Beach, FL.

10.1136/jim-2016-000393.411



Abstract 411 Figure 1

Case Report Acute respiratory distress and a CXR with unilateral white out has a broad differential. An accurate history and physical exam along with comparing to prior CXRs is critical. The patient is an 87 year old male being treated for a DVT with eliquis who developed acute respiratory distress during his admission. CXR showed right lung whiteout and the patient reported blood tinged sputum. As the patient continued to deteriorate he was transferred to MICU for hypoxic respiratory failure. Eliquis was discontinued given the report of hemoptysis. A fiberoptic bronchoscopy was done which revealed red cloudy fluid which did not clear with multiple lavages. Fluid analysis showed 35556 RBCs, sputum and lavage, gram stain and fungal cultures were all negative. Blood cultures were positive for haemophilus influenza. The patient was diagnosed with focal right lower lobe alveolar hemorrhage due to eliquis with concomitant pneumonia. Respiratory distress and a CXR with unilateral white out has a limited number of differentials. Determining tracheal position shortens the list of possible causes. When the trachea is pulled toward the opacified side the differential include total lung collapse, pneumonectomy, pulmonary agenesis and pulmonary hypoplasia. If the trachea is pushed away from the opacified side the differentials include pleural effusion, diaphragmatic hernia or a large pulmonary mass. When the trachea remains in a central position the choices include consolidation, pulmonary edema, ARDS, pleural mass, chest wall mass and alveolar hemorrhage. Evaluating for tracheal deviation along with taking an accurate history is essential when reviewing possible causes of CXR white out.

412 DAB CONCENTRATE: TWO CASES REPORTING THE EFFECTS OF MARIJUANA WAX

PR Sanchez, JF Cuevas, E Juarez Ramirez Tello. Texas Tech University Health Science Center, Lubbock, TX.

10.1136/jim-2016-000393.412

Case Report Dab concentrate also known butane hash oils (BHO) is an increasingly popular method of cannabis inhalation, though, little is known about the potential dangers associated with its use. BHO is made by extracting THC

from the cannabis flower via a method known as blasting. Data shows that this can potentiate psychotropic effects of marijuana about five-fold with concentrations of 23.7% to 75.9% compared to 3% to 6% of the usual marijuana flower. Moreover, many of these preparations have been contaminated with the compounds used to evaporate such as butane. We present two cases demonstrating the effects of dab concentrate inhalation. A 19-year-old Caucasian man with PMHx of well-controlled complex partial seizures admitted for altered mental status. On initial physical exam he was drowsy, had scleral injection, and showed diffuse abrasions and ecchymosis. All other systems were within normal limits. He later became combative. His renal function was impaired with BUN 24 mg/dL and sCr 2.6 mg/dL (baseline 1.1 mg/dL). CK was 28,323 IU/L and UDS was positive for cannabinoids. After 24 hours, patient experienced seizures, which were controlled. Renal function worsened to BUN 32 mg/dL, sCr 3.4 mg/dL and CK 38,000 U/L. He required intermittent hemodialysis, IV fluids, and sodium bicarbonate infusion. Additionally, a 57-year-old Caucasian man with PMHx of Hodgkin Lymphoma was admitted for seizures. He became combative and agitated requiring intubation. On initial exam patient was nonresponsive, intubated, had diffuse ecchymosis, and had left knee swelling. All other systems were normal. His renal function was BUN 16 mg/dL, sCr 0.9 mg/dL, and CK was 653 IU/L. UDS was positive for cannabinoids and benzodiazepines. Patient was later found with CK of 3,781 IU/L though renal function remained intact. He required aggressive IV fluids and sodium bicarbonate infusion with CK trending to 763 IU/L. Both patients were linked with the use of BHO prior to admission. This case introduces new information regarding the effects of dab concentrate particularly rhabdomyolysis with possible acute renal failure.

413 COMPARISON OF TRANSFUSION THRESHOLDS DURING NEONATAL ECMO

A Sawyer, L Wise, S Ghosh, J Bhatia, B Stansfield. *Medical College of Georgia at Augusta University, Augusta, GA.*

10.1136/jim-2016-000393.413

Purpose of Study Extracorporeal membrane oxygenation (ECMO) is an essential tool in the care of infants suffering from refractory hypoxic respiratory failure. Donor red blood cells (RBC) are required at the initiation of therapy and patients routinely experience bleeding and thrombotic complications that warrant additional transfusions. However, an agreement on RBC transfusion thresholds in the absence of other clinical indications has not been established. The objective of this study was to examine the effect of lowering the hematocrit threshold for transfusion on blood product utilization and patient outcomes.

Methods Used We reviewed the records of 72 neonates undergoing ECMO support for refractory hypoxic respiratory failure to compare outcomes before and after lowering the hematocrit transfusion threshold from 40% (n=37) to 35% (n=35) at a single tertiary neonatal intensive care unit. Demographic data, ECMO circuit and component lifespan, blood product utilization, measures of bleeding/

thrombosis, bleeding/thrombotic complications as reported to ELSO, and survival were compared between cohorts. SAS 9.4 was used to determine statistically significant differences between the two cohorts.

Summary of Results Patients who had a lower threshold for transfusion (HCT<35) had a lower mean hematocrit (38.3% vs. 41.4%, $p<0.0001$) and received less total RBC transfusion volume (10.4 vs. 13.3 ml/kg/day) while undergoing ECMO support. Also, patients in the HCT<35 cohort received fewer RBC transfusions ($p<0.001$). Survival off ECMO, survival to discharge, and complication rates were similar between the cohorts.

Conclusions A lower hematocrit threshold of 35% is associated with a reduction in red blood cell transfusion volume and does not appear to alter complication rates or patient outcomes for neonates receiving ECMO support for respiratory failure.

414 IATROGENIC BILATERAL PNEUMOTHORACES FOLLOWING ENDOBRONCHIAL ULTRASOUND GUIDED BIOPSY ON A MECHANICALLY VENTILATED PATIENT

SF Shah, G Nelson, A Richardson. *Harris C, Louis M, University of Florida College of Medicine Jacksonville, FL.*

10.1136/jim-2016-000393.414

Case Report Iatrogenic unilateral pneumothorax (PTX) following Endobronchial Ultrasound guided Transbronchial Needle Aspiration (EBUS-TBNA) is an infrequent (<4 percent) but established complication. Iatrogenic Bilateral pneumothoraces however are rare and often occur secondary to invasive cardiothoracic procedures through extensive mediastinal dissection. Bilateral pneumothoraces can result in significant morbidity and mortality from cardiovascular collapse if not identified and treated promptly.

A 67-year-old female with a past medical history of chronic obstructive pulmonary disease (COPD) and hypothyroidism presents in altered mental state requiring intubation and mechanical ventilation for airway protection. Computer tomography of the head revealed a cerebellar mass prompting further imaging of chest, abdomen and pelvis which identified bilateral multifocal nodular opacities in the lungs concerning for metastatic disease. The patient remained on mechanical ventilation owing to no improvement in mental status and chest radiograph (x-ray) done at that time was negative for PTX. EBUS-TBNA of subcarinal lymph nodes via left main stem bronchus and bronchoalveolar lavage (BAL) of the left lower lobe superior segment bronchus were performed. One-hour post procedure she was noted to be cyanotic and hypotensive with absent breath sounds bilaterally. A left chest tube was immediately placed and follow up chest x-ray showed a large right sided PTX with significant left chest wall and lower neck subcutaneous emphysema. A right apical chest tube was then placed and the patient was stabilized with resolution of her hypotension and hypoxia.

While not absolute contraindications it has been shown that performing a BAL or TBNA on mechanically ventilated patients is associated with an increased rate of PTX. It is believed that the combination of existing structural lung disease as well as iatrogenic injury in the setting of

mechanical ventilation resulted in the development of a communication between the left main stem bronchus and the pleural space between both hemithoraces resulting in bilateral pneumothoraces.

415 SEVERE SEPSIS AND PRE ECLAMPSIA; IS THERE ANY ASSOCIATION

A Sultan, PR Sanchez, S Copeland, R Alalawi. *Texas Tech University Health Sciences Center, Lubbock, TX.*

10.1136/jim-2016-000393.415

Case Report Maternal mortality in US has been increasing, as a result of complications, preeclampsia/ eclampsia, postpartum hemorrhage, sepsis, HELLP and complicated labor. Sepsis alone accounts for roughly 20% of cases.

33 years old F was transferred for evaluation of sepsis. She had uncomplicated C/S 2 wks prior to admission. She had initially presented with fever of 102.1, hypotension, diarrhea, nausea & vomiting. At the other facility, lactate was 3.5 despite fluids and antibiotics: vancomycin, flagyl. On admission, BP was 105/53 (MAP 65); HR 116; SpO₂ 95%, RR 33. Patient was alert, oriented with mild respiratory distress. Lung exam revealed diffuse rales, healed C/S scar, rest of exam was normal. Labs showed mild anemia, no leukocytosis, metabolic acidosis, acute kidney injury. Lactate remained stable, 3.3. U/A was normal and CXR revealed pulmonary edema. Stool revealed *C. difficile*. CT abd/pel showed lung opacities concerning for infection and changes in lower abdomen consistent with C/S. Echo showed EF of 30–35%, global hypokinesis. Patient was treated with vancomycin, meropenem with metronidazole, fluconazole, gentamicin added later. Within hours, patient developed acute hypoxemic respiratory failure warranting O₂ and eventually ET intubation. She remained hypotensive with refractory acidosis; requiring 3 vasopressors, bicarbonate infusion and CRRT within 12 hours. Given her depressed EF, cardiogenic shock was considered, thus Dobutamine was initiated. PA catheter pressure of 41/24 mmHg (wedge 12) raised concern for distributive shock. Serial ABGs trended pH from 7.1 to 6.8 despite maximal mechanical respiratory compensation. Multiple fluid challenges, albumin and blood products initially showed improvement in hemodynamics, but were detrimental to PA pressures. Ultimately, the family opted for DNR status and patient went into cardiac arrest. Later stool cultures grew *Salmonella* serotype Norwich, blood and urine cultures remained negative. Autopsy showed evidence of severe diffuse hypoxemia consistent with septic shock and periportal necrosis; the latter suggestive of preeclampsia and endotoxin effects. This case introduces an association between sepsis and preeclampsia in the postpartum patient that can help raise awareness of the leading causes of maternal mortality today.

416 A COMPLICATED ILLNESS SCRIPT

M Touchy, LS Engel. *LSU Health Sciences Center, New Orleans, LA.*

10.1136/jim-2016-000393.416

Case Report A 55 year old African American woman with past medical history of coronary artery disease with multiple myocardial infarcts with seven stents, heart failure, peripheral artery disease, type 2 diabetes mellitus (on metformin), hypertension, hyperlipidemia, and tobacco abuse was brought to emergency department by family members secondary to altered mental status for approximately one day. On week prior she was treated for flash pulmonary edema secondary to NSTEMI and underwent cardiac catheterization which revealed 50–70% in-stent re-stenosis, and a sub-total occlusion of the circumflex artery which was successfully intervened with balloon angioplasty. At time of admission, the patient was unable to communicate secondary to intubation. However, her family divulged that two days prior to admission, the patient began to experience progressively worsening hallucinations and vomiting. She was hypotensive with systolic pressures ranging from 60–70; temperature of 93 °F; BUN/Cr 77/10.1 mg/dL; potassium 8.2 mEq/L; bicarbonate of <5 mEq/L; anion gap 41; lactic acid 15 mmol/L; negative toxicology screen; BNP 4042 pg/ml; arterial blood gas with a pH of 6.8 and a pCO₂ of 23. The patient coded a total of four times, with each episode lasting no longer than five minutes before a pulse returned. She was transferred to ICU in critical condition on two vasoactive agents and a bicarb infusion; emergent CRRT was initiated for severe acidosis in setting of acute kidney injury. Over the next twelve hours, the patient was able to move all four extremities and follow simple commands; over the next two days, the patient's hemodynamic status, electrolytes, and acidosis and renal function improved. By hospital day four, she was extubated.

Discussion This is a great example of a complicated illness script with multiple organs involved, including lungs, kidneys, heart, and brain. Our working diagnosis was that the patient had incurred a kidney injury, possibly from recent coronary angiogram, which was further exacerbated by the patient's continued use of metformin, resulting in a severe lactic acidosis. This contributed to patient's hypotension and hemodynamic collapse.

Renal, Electrolyte and Hypertension Joint Plenary Poster Session and Reception 4:30 PM Saturday, February 11, 2017

417 A CASE OF RENOVASCULAR HYPERTENSION AND HYPERTENSIVE KIDNEY INJURY SECONDARY TO RENAL ARTERY STENOSIS

LA Vazquez-Moyet, G Brown, SA Morse, A Jaikishen. *LSU Health Sciences Center, New Orleans, LA.*

10.1136/jim-2016-000393.417

Introduction Renovascular hypertension (RVH) has numerous etiologies but renal artery stenosis (RAS) is the major cause. This is a case of severely uncontrolled blood pressure (BP) and acute renal failure related to RVH/RAS

Case Description A 73 year-old African American female with history of resistant hypertension, CKD4, type 2 diabetes and hyperlipidemia, with acute onset of generalized fatigue, presents to the ER with hypertensive urgency (230/

112 mmHg). Physical examination is unremarkable for abdominal bruits, lower extremity edema or heart murmurs. She was initially started on Hydralazine 10 mg IV bolus for two doses plus her home antihypertensive regimen (Labetolol 300 mg TID, and Doxazosin 8 mg, Norvasc 10 mg, Bumex 1 mg, and Losartan 100 mg QD). The next morning her blood pressure dropped to 152/67 mmHg and her creatinine rose from 2.2 to 3.0 mg/dL, presumably caused by the sudden drop of blood pressure. It was noted that a previous renal ultra-sound suggested renal artery stenosis of the right kidney as well as right renal enlargement compared to the left measuring 10.2 cm and 8.3 cm respectively. As a result, Losartan was withdrawn, Bumex was decreased to 0.5 mg/day and Aldactone 25 mg/day was added. Nuclear medicine lasix renogram showed a clearance of 40.3 mL/minute, with differential function of 80% in the right and 20% on the left kidney and no evidence of obstruction. During the next two days, her BPs were in the 130 s/60 s and creatinine beginning to plateau at 3.5 mg/dL. She was discharged on daily doses of Imdur 30 mg, Nefedipine 30 mg, Aldactone 25 mg, Labetolol 300 mg, Bumex 1 mg, and Doxazosin 8 mg.

Because of her shifting creatinine, further investigation of her bilateral renal artery stenosis had to be delayed as CT angiogram would expose her kidneys to nephrotoxic contrast. It was decided it was best she be followed as an outpatient as her AKI would likely resolve.

Discussion RAS is associated with poor prognosis in terms of decline of renal function and overall mortality. Once identified, the next step in management of RAS is unclear. However treatment approach should balance the risks and benefits of several modalities, ranging from medical therapy to surgical or endovascular repair

418 WEAKENING FROM COCAINE

S Butala. *Upstate Medical University, Syracuse, NY.*

10.1136/jim-2016-000393.418

Introduction Cocaine intoxication typically presents as a myriad of symptoms, including agitation, anxiety, seizures, hypertension, tachycardia, arrhythmias, diaphoresis, hyperthermia, increased muscle tone and rhabdomyolysis. The case below presents abnormal findings more related to the electrolyte abnormalities caused by cocaine

Case Presentation A 27-year-old male presented to the ED complaining of muscle pain and weakness. The patient reported muscle weakness starting six days prior to presentation. He states the weakness initially started in his right leg then progressed to involve his remaining limbs. He mentions over the last 2 days his weakness became so pronounced that it was causing him to limp. The day of admission, he noted he was unable to move his right hand. He denied any associated symptoms including fever, chills, nausea, diarrhea, abdominal pain or new rashes. Urine toxicology returned positive for cocaine. Motor strength was found to be 3/5 in upper and lower extremities bilaterally and +3 hyper-reflexia of biceps bilaterally. On labs, patient was found to have potassium 2.1 mmol/L. EKG was remarkable for significant QTc prolongation of 586 ms.

Discussion Hypokalemia is known to cause generalized weakness. The patient's severe hypokalemia was induced by an increase in adrenergic activity from cocaine. Cocaine inhibits the reuptake of norepinephrine simultaneously at the norepinephrine and dopamine transporters, which typically down regulate further release of the neurotransmitter. When a beta 2 receptor becomes activated it causes formation of cyclic AMP, which acts through protein kinase A to phosphorylate and activate the Na-K-ATPase pump, leading to an influx of potassium into cells resulting in hypokalemia. Cocaine will also block the inward flux of sodium during depolarization causing tetany.

Hypokalemia does not usually cause weakness until potassium drops below 2.5–3.0 meq/L, which will alter the action potential at the cell membrane. Frank rhabdomyolysis can present at a potassium of less than 2 meq/L. Substance abuse should always be considered in patient with weakness with known drug history and no alternative etiology.

419 OSMOLAR GAP: KEY TO EARLY TOXICITY DIAGNOSES

J Carlson, J Greco. *UF-Health, Jacksonville, FL.*

10.1136/jim-2016-000393.419

Case Report Ethylene glycol is a toxic substance used in various automobile products, most commonly anti-freeze. To those who ingest it, it has a sweet taste and, with enough intake, can give someone the 'buzz' they may be looking for. Accidental ingestions are common in children as anti-freeze products are laced with a fluorescein dye giving it a bright blue or green appearance resembling Kool-aid. Ethylene glycol toxicity is a challenging problem for physicians as patients can be asymptomatic for hours after initial ingestion and lab abnormalities we commonly associate with this ingestion (notably metabolic acidosis) may only manifest once damage has already occurred. To complicate the diagnosis further, altered mental status (AMS) is a prominent symptom, which may limit a patient's ability to give a proper history.

A 56-year-old male was brought into the ED for AMS by EMS after being found unconscious. Upon admission, the patient was slurring his words and smelled of alcohol, and a urine toxicology panel was positive for alcohol, benzodiazepines, and methadone. Workup revealed multiple lab abnormalities including a potassium of 7.7, a creatinine of 3.92, a creatine kinase (CK) of 133,960, a pH of 7.25, and an anion gap of 23 requiring admission to the ICU. The patient was given fomepizole and aggressive fluid resuscitation. Nephrology was consulted and calculated a serum osmolar gap of 30, which determined the need for dialysis and urine sediment analysis. This revealed calcium oxalate crystals, which is highly suggestive of ethylene glycol toxicity. Over the next week, the patient required multiple sessions of hemodialysis and a serum ethylene glycol level confirmed the diagnosis. After normalization of his labs, the patient was discharged in stable condition.

This case illustrates the importance of recognizing ethylene glycol intoxication early on as it can have permanent, detrimental effects if not treated in a timely fashion.

Relying on serum ethylene glycol levels can take days to yield results, and patients do not have this much time. When a patient comes in with AMS and a high CK, checking the osmolar gap is a quick and efficient way to narrow down the diagnosis and begin the appropriate management. It is imperative that pediatric and adult physicians in both the emergency and medicine fields keep ethylene glycol in their differential for AMS.

420 A REVERSIBLE FORM OF AKI FROM ANTIVIRAL THERAPY FOR HEPATITIS C

J Cho,^{1,2} P Fall,^{1,2} S Nahman^{1,2}. ¹Medical College of Georgia, Augusta, GA; ²Charlie Norwood VA Medical Center, Augusta, GA.

10.1136/jim-2016-000393.420

Case Report Antiviral therapy for hepatitis C virus (HCV) infection includes direct-acting antivirals (DAA) and multiple combinations of other drugs. AKI in HCV infected patients may be related to infection, progressive renal disease, or medications. We report a patient with AKI following therapy with DAA.

A 66 year old male with well controlled HIV, HCV infection (viral count 7 million), and mild CKD was treated with DAA (ombitasvir, paritaprevir, ritonavir, and dasabuvir) for 12 weeks. By week 12, the creatinine had risen from 1.2 to 1.7 mg/dl (table) and he was evaluated for AKI. The BP was 128/80 and he was euvolemic. The urinary sediment and renal ultrasound were negative. Seven weeks post therapy the creatinine returned to baseline. HCV viral count post treatment was <15.

It was theorized that the early rise in creatinine following institution of DAA, combined with the negative AKI evaluation and reversibility of the AKI, represented ritonavir inhibition of tubular secretion of creatinine. In CKD, tubular secretion of creatinine may account for up to 50% of the urine creatinine. Transporters involved with tubular creatinine secretion include OCT, OAT, and MATE. Ritonavir inhibits OAT1, OAT2, and MATE1. Dasabuvir is also a substrate of OCT. Similar mechanisms have been described for cimetidine, trimethoprim, and cobicistat.

Conclusion Inhibition of tubular secretion of creatinine by DAA may present as a reversible form of AKI. The changes appear to be of minor clinical significance and do not preclude continued therapy, however other causes of AKI must be excluded.

Abstract 420 Table 1

WEEKS	RELATION TO TREATMENT	CREATININE (GFR)
0	BASELINE	1.2 (73)
1	DAY 5 OF TREATMENT	1.5
12	LAST DAY OF TREATMENT	1.7 (48)
13	DAY 5 POST TREATMENT	1.4
19	7 WEEKS (DAY 49) POST TREATMENT	1.2
20	DAY 57 POST TREATMENT	1.2

421 STATIN-INDUCED RHABDOMYOLYSIS, COMPLICATED BY MORPHINE-INDUCED RESPIRATORY ACIDOSIS

SS Lock, MJ DelRosario, EA Aguilar, S Barry, AA Jack, E Reisin, SA Morse. LSU Health Sciences Center in New Orleans, New Orleans, LA.

10.1136/jim-2016-000393.421

Introduction Rhabdomyolysis is when damaged skeletal muscle rapidly breaks down. Patients may experience muscle aches, weakness, vomiting, irregular heartbeat, tea colored urine, and confusion. Protein myoglobin, a breakdown product, is toxic to the kidneys and may lead to kidney failure.

Method Our case is about a 58y/o Hispanic male with a history of HTN, DM-II, chronic back pain from osteoarthritis, CKD-III, dyslipidemia on statin therapy (Lipitor 40 mg daily), and rhabdomyolysis requiring dialysis who presented to the ER with the chief complaint of feeling weak. He reported generalized muscle aches for 2 weeks and stated that his back pain was worse today so he took 'a lot' of morphine. At the ER, patient was hypotensive, having SOB, AMS. He was placed on bipap, and given Narcan which improved his mental status. He was medically shifted for hyperkalemia, was given 4 liters of normal saline, and levophed drip for hypotension. On exam, he showed asterixis and was lethargic. He did not have an osmolol gap, so ingestions are less likely

Results Labs showed BUN 84, Cr 8.0 mg/dL, K 6.0 mEq/L, bicarb 14 mEq/L, CK 2600 IU/L. Lipitor was discontinued upon admission. Urine microscopy revealed muddy brown casts, no crystals, even though patient made >500 mL of urine since admission, his kidneys were unable to clear as he has not demonstrated improvement in labs. Because he had hyperkalemia refractory to medical shifting, asterixis, and acidemia (primary respiratory acidosis with a pure anion gap metabolic acidosis), the decision was made to dialyze him. We dialysed him for three days, after which his labs improved and he was discharged. Upon his outpatient follow up appointment, he is still off the statin and has not complained of muscle aches.

Conclusion In this case, rhabdomyolysis was life-threatening. The patient self-medicated his muscle aches with morphine, which caused his respiratory depression. This patient never had previous muscle aches quite like the ones he had while on the statin. Thus, we concluded that the statin was the culprit. Dialysis is a life-saving tool that nephrologists often use in kidney failure refractory to medical treatment.

422 TOGETHER IS NOT ALWAYS BETTER

L Puttock, LS Engel. LSU Health Sciences Center, New Orleans, LA.

10.1136/jim-2016-000393.422

Introduction Acute kidney injury in hospitalized patients can increase both morbidity and mortality.

Case A 40-year-old man with a history significant of hypertension, diabetes mellitus, heart failure with reduced ejection fraction, coronary artery disease, atrial fibrillation, stoke, and tobacco abuse presented to the Emergency Department with a three week course of progressive pain

and swelling in his left third digit. He had an incision and drainage and 14-day course of trimethoprim-sulfamethoxazole five weeks prior to presentation. Vitals were unremarkable. On exam, a black discoloration at the tip of his left third digit as well as swelling and tenderness to palpation from the palmar surface of the middle phalanx to the tip of the left third digit was noted. Labs were notable for CRP <0.5 mg/L, ESR 8 mm/hr, BUN 10 mg/dL, Cr 0.63 mg/dL, and WBC 7,500/ul. Exam and imaging were consistent with a left third digit felon abscess with osteomyelitis. He underwent incision and drainage and bone biopsy and vancomycin and piperacillin-tazobactam was started. On day five of antibiotic treatment, the bone biopsy culture grew MRSA and piperacillin-tazobactam was discontinued. On day six of antibiotic therapy, the patient developed an acute kidney injury with a BUN of 51 mg/dL and serum creatinine of 1.48 mg/dL. His urine urea nitrogen was 235 mg/dL, urine creatinine was 62.4 mg/dL and protein to creatinine ratio was 73. The etiology of his AKI was deemed intrinsic in setting of antibiotics given a borderline fractional excretion of urea of 37.2%. His renal function stabilized two days after piperacillin-tazobactam was discontinued and he gradually improved.

Discussion Utilization of vancomycin in combination with piperacillin-tazobactam for empiric antimicrobial therapy is on the rise. Multiple publications report an increased incidence of nephrotoxicity and acute kidney injury in patients treated concurrently with vancomycin and piperacillin-tazobactam compared to vancomycin monotherapy. This case highlights the importance of narrowing antibiotic coverage when possible and with vigilance for the complications that may result from the combination therapy of vancomycin and piperacillin-tazobactam.

423 CORRELATIONS BETWEEN MEASURED AND ESTIMATED GFR IN CHRONIC KIDNEY DISEASE PATIENTS

V Reddy, S Prabhakar. *TTUHSC, Lubbock, TX.*

10.1136/jim-2016-000393.423

Purpose of Study Current guidelines for clinical evaluation of chronic kidney disease (CKD) recommend use of glomerular filtration rate (GFR) as a measure of kidney function. Methods to accurately measure GFR in patients such as 24-hour creatinine clearance are cumbersome and impractical. Serum creatinine-based formulae, specifically MDRD and CKD-EPI equations, are the most accepted methods for estimating GFR (eGFR) and monitoring renal function. Still, skepticism prevails in the medical community in accepting the accuracy of these formulae in truly predicting the GFR.

Our aim is to examine the correlation between GFR, measured by a 24-hour creatinine clearance and eGFR using MDRD and CKD-EPI formulae, through a retrospective study of CKD patients seen at the Division of Nephrology and Hypertension at Texas Tech University Health Medical Center over the last 3 years.

Methods Used We collected data pertaining to kidney function from patients who had GFR both measured and

Abstract 423 Table 1

	Total	Sample Size (n=)	MDRD Accuracy	CKD-EPI Accuracy
		128	18.75%	19.53%
Gender	Female	71	23.94%	25.35%
	Male	57	12.28%	12.28%
CKD Stage	1	4	0%	0%
	2	15	20%	20%
	3	52	21.15%	17.30%
	4	42	16.67%	21.42%
	5	15	20%	26.67%
Diabetes?	yes	62	22.58%	20.97%
	no	66	15.15%	18.18%

calculated at the same period of time. We used the Bland and Altman recommendations for evaluating methods of clinical measurements. Accuracy was measured by analyzing % error of eGFR and by determining the percentage of data points with <15% deviation from the measured values.

Summary of Results The data is summarized in this table:
Conclusions We found an inaccuracy of eGFR calculated by both MDRD and CKD-EPI. Cause for the incongruence between estimated and measured GFR values is unclear. Data show that CKD-EPI is slightly more accurate than MDRD. There is a significant difference between MDRD and CKD-EPI in eGFR accuracy of diabetic v. non-diabetic patients. eGFR is a more accurate clinical assessment of GFR in patients with diabetes v. those without. These observations warrant large scale studies to review the validity of creatinine based formulae in measuring kidney function.

424 RENAL ENLARGEMENT IN END STAGE LIVER DISEASE

M Saad, WC O'Neill. *Emory University Hospital, Atlanta, GA.*

10.1136/jim-2016-000393.424

Purpose of Study Kidney function is often altered in end-stage liver disease (ESLD). While most attention has focused on renal impairment, we hypothesized that the kidneys may compensate for the decreased hepatic metabolic clearance by hypertrophy of renal tubules. This metabolic adaption will be reflected by an increase in renal parenchymal volume (RPV).

Methods Used To examine this hypothesis, RPV was measured in 24 patients with ESLD undergoing outpatient CT scans. ESLD was defined as advanced liver disease qualifying for transplant workup. Patients with known intrinsic renal disease, diabetes mellitus, kidney stones, proteinuria (100 mg/dl or more), or acute kidney injury were excluded. RPV was measured on outpatient non-contrast CT scans by measuring the cross-sectional area of the kidney, excluding cysts, sinus fat and vessels, on each transverse image and multiplying the sum by the slice interval, according to a published protocol. RPV was normalized to height or body surface area (BSA), and was compared to a control group

of 224 potential kidney donors. The study was powered to detect a 15% difference in RPV.

Summary of Results Mean age of the patients was 51 years (21–69), mean height was 168 cm, mean weight was 85 kg, and 14 were females. The mean creatinine was 0.83 mg/dL (0.42–1.54). Since RPV varies with gender independent of body size, males and females were analyzed separately. Although RPV correlates best with BSA, normalization to height was also performed to eliminate the bias related to the accumulation of extracellular fluid. In male ESKD patients, the mean RPV/BSA was 223 ± 21 ml/m² vs 195 ± 3 ml/m² in controls ($p=0.016$) and RPV/height was 269 ± 30 ml/m (mean+SE) vs 225 ± 4 ml/m in controls ($p=0.0057$). In female patients, the mean RPV/BSA was 223 ± 21 ml/m² vs 195 ± 3 ml/m² ($p=0.0019$) and RPV/height was 222 ± 8 ml/m vs 196 ± 3 ml/m ($p=0.0062$).

Conclusions Renal parenchymal volume was increased by 13–19% in ESKD, consistent with hypertrophy. Since lean body mass is likely decreased, and extracellular fluid increased compared to controls, the enlargement is probably even greater. Whether this is metabolic compensation for reduced hepatic clearance or a response to other alterations in ESKD will require further study.

425 MEMBRANOUS NEPHROPATHY IN A PEDIATRIC PATIENT WITH ASYMPTOMATIC PROTEINURIA

S Sharma,¹ L Kidd,² I YOSYPV¹. ¹Tulane University, Metairie, LA; ²Tulane University, New Orleans, LA.

10.1136/jim-2016-000393.425

Case Report A 10-year-old boy was found to have asymptomatic proteinuria during routine annual screening and was referred for further evaluation by a Pediatric Nephrologist. On presentation, he denied edema, gross hematuria, abdominal or back pain, rash, joint pain or warmth. Physical examination revealed a well-appearing child, with both stature and height-for-age at 25th percentile, manual BP of 114/72 mmHg (SBP- 90th percentile, DBP- 50th percentile) and otherwise was unremarkable. Laboratory findings showed urinalysis (UA) with 2+ protein, 6–10 RBCs; spot urine protein:creatinine ratio 1.8 mg/mg (normal <0.2); negative serum antinuclear antibodies, normal complements C3/C4 (122/17 mg/dL) albumin 3.3 g/dL, negative HepB and C serologies, and fasting cholesterol of 261 mg/dL. Renal ultrasound demonstrated structurally normal kidneys of normal size and increased medullary echogenicity. Spiral CT of abdomen/pelvis was obtained to rule-out nephrocalcinosis and demonstrated no abnormalities. Subsequent UAs demonstrated persistent significant proteinuria (protein:creatinine ratio >1.0 and <2.0 mg/mg). Renal biopsy was performed to evaluate for kidney disease as source of significant proteinuria and revealed thickened glomerular basement membranes (GBM) and GBM spikes on the Jones silver stain. EM and IF showed large subepithelial and membranous, but not mesangial, dense deposits consisting of IgG, IgG4 and C3, consistent with the stage III-IV idiopathic membranous nephropathy (IMN). Treatment with an ACE inhibitor along with a statin was initiated. This case demonstrates a rare cause of persistent proteinuria in a young

pediatric patient due to IMN and emphasizes a need for timely Nephrology referral for appropriate evaluation.

426 A RARE CASE OF LATE-ONSET RENAL VEIN THROMBOSIS IN A POST KIDNEY/PANCREAS TRANSPLANT RECIPIENT

RB Varedzis,¹ AA Jack,¹ J Garces². ¹LSU Health Sciences Center in New Orleans, New Orleans, LA; ²Ochsner Foundation, New Orleans, LA.

10.1136/jim-2016-000393.426

Introduction Late-onset renal vein thrombosis (RVT) is a rare post kidney transplant complication; even more so when the finding occurs in the setting of renal vein torsion. We present a case of RVT 6 months post kidney/pancreas transplant most likely caused by hilar vessel torsion. Our goal is to determine how frequently late onset RVT is encountered in transplant patients and whether this is a preventable complication.

Methods We describe a 44 year old female with CKD V, type 1 DM, 6 months post kidney/pancreas transplant from a deceased, CMV (+) donor; presented to ED with fever and allograft tenderness. Fluconazole/ceftriaxone and tacrolimus/steroids were initiated for suspected sepsis and acute cellular rejection, respectively. Diagnostic studies included serial renal dopplers and kidney biopsy. Ultimately, she developed acute RVT requiring surgical evaluation. We performed a literature review to identify the incidence and predisposing factors for late onset RVT in renal transplant patients.

Results Preliminary evaluation revealed AKI and subtherapeutic cyclosporine level with normal amylase/lipase. Initial renal allograft imaging demonstrated possible pyonephrosis with a patent renal vein. CMV PCR was minimally elevated and DSA was negative. Kidney biopsy performed on hospital day 4 demonstrated ATN, cortical necrosis, negative for C4d, thrombotic microangiopathy and pyelonephritis. Serial tacrolimus levels demonstrated an acute increase from 6.6 to 70.2 ng/mL within 3 days. Repeat doppler imaging hospital day 5 demonstrated RVT. The patient was taken for emergent surgical evaluation, the allograft was freely mobile but grossly mottled, nonviable and torsion was deemed the suspected cause. While RVT is a recognized early transplant complication it is very unlikely to occur several months out.

Conclusion Late-onset RVT is a very rare renal transplant complication and even more so when it is due to torsion of hilar vessels. This mechanism of injury is poorly understood and not well described in the literature. Given the significant likelihood of allograft demise, awareness of this potential complication is vital and investigation of possible contributing factors deserves closer attention.

427 A CASE OF METFORMIN INDUCED LACTIC ACIDOSIS

S Werner, LS Engel. LSU Health Sciences Center, New Orleans, LA.

10.1136/jim-2016-000393.427

Case Report Introduction: Metformin is a commonly used medication in the treatment of Type 2 Diabetes Mellitus

(T2DM). With an increasing prevalence in T2DM, Metformin is frequently used as a first line agent. Lactic acidosis is a rare, but known side effect of Metformin in the setting of worsening renal function.

Case A 72 year old African American man with a history of myocardial infarction s/p CABG, paroxysmal atrial fibrillation and Type 2 Diabetes Mellitus presented to the Emergency Department (ED) with abdominal pain for 1 day. The patient was noted to be altered, with Glasgow Coma Scale of 11 at presentation. He had a temperature of 91oF, blood pressure of 89/53, and heart rate of 18, with oxygen saturation of 95% on room air. Despite hydration with normal saline, he had persistent hypotension and norepinephrine was started. Broad spectrum antibiotics were initiated. Initial labs showed WBC count of 16,700 cells/ul without bacteremia. There was acute renal injury with creatinine of 10.1 mg/dl, Anion Gap Metabolic Acidosis AGMA with a pH of 6.8, Lactic Acid of 17.7 mmol/L and an Anion Gap of 25, with a Bicarbonate of 3 meq/L. His potassium was 7 meq/L. Chest X-ray and Urinary studies were unremarkable. Continuous Renal Replacement Therapy (CRRT) was initiated for his acute renal failure and lactic acidosis. The next morning, the AGMA corrected, Lactic Acid cleared, hyperkalemia resolved and Creatinine improved. The patient's mental status improved and he was able to report that he had been taking Metformin for his Diabetes. Metformin level was drawn, and resulted numerous days later as 33 mcg/mL. Blood and urine cultures were unremarkable. Chart review showed over the last two years, the patient had worsening GFR and Cr per outpatient laboratory data, but was maintained on his Metformin dose. The patient received hemodialysis until his Creatinine stabilized.

Discussion In the setting of worsening renal function, metformin has been known to cause Lactic Acidosis, causing significant anion gap acidosis and other critical illness.

110 mmol/L (141 mmol/L just 3 months prior). His metabolic panel showed low potassium (3.0 mmol/L), chloride (76 mmol/L), calcium (8.6 mg/dL), albumin (3.3 g/dL), phosphorus (1.2 mg/dL), and magnesium (1.2 mg/dL). BUN was 6 mg/dL and creatinine was 1.1 mg/dL. His serum osmolality was noted to be 251 mOsm/kg and his urine osmolality was 63 mOsm/kg. His urine otherwise showed sodium concentration of <10 mmol/L and potassium concentration of <20 mmol/L. Based on these results, it was presumed that his hyponatremia was due to inadequate solute intake (tea and toast diet) in addition to significant hypo-osmolar fluid intake or polydipsia. He received 1.5 liters of normal saline in the ER and was placed on water restriction. Repeat serum sodium three hours after the initial result was 115 mmol/L, and the decision was made not to initiate hypertonic saline. After 11 hours, and with no further intervention, his serum sodium had increased to 123 mmol/L. Because of the rapid correction, the decision was made to initiate D5W to re-dilute his serum, in hopes of preventing complications such as central pontine myelinolysis. The interesting aspect of this case is the lack of need to initiate hypertonic saline, and the rapidity with which he was able to auto-correct his hyponatremia with fluid restriction and minimal solute infusion alone.

428 AN INTERESTING CASE OF HYPONATREMIA REQUIRING D5W

F Yazdi, E Lindsey, SA Morse, LA Vazquez-Moyet. *LSUHSC-New Orleans, New Orleans, LA.*

10.1136/jim-2016-000393.428

Case Report A 42-year-old man presented with severe and symptomatic hyponatremia, for which our Nephrology service was consulted. His symptoms on presentation were limited to one day of nausea, vomiting, dizziness and weakness, which had progressively been getting worse. This constellation of symptoms had never occurred in his past, and he was normally otherwise a fully functional adult who felt well just two days prior. His past medical history included hypertension, for which he was taking Carvedilol; hyperlipidemia, managed with diet; depression and PTSD, treated with quetiapine, and alcohol abuse. His alcohol intake included daily consumption of 6–8 beers, but he quit drinking two months earlier. He did note an inconsistency in his diet, only eating one meal every two days. He also stated that his oral fluid intake was roughly 2–4 quarts of powerade and about 2–4 quarts of water daily. On presentation, it was discovered that his serum sodium was