

Cardiovascular club I

11:00 AM

Thursday, February 22, 2018

1 A POSSIBLE ROLE FOR GENETICS IN CARDIOVASCULAR DISEASE AMONG THE ACADIANS

AE Tedesco*, Z Haq, KL Di Losa, MJ Ali, P Gregory. *LSUHSC – New Orleans, New Orleans, LA*

10.1136/jim-2017-000697.1

Purpose of study It is well documented that the Louisiana Acadians ('Cajuns') experience a disproportionate risk for some genetic diseases due to a genetic founder effect. Furthermore, certain founder populations show a predisposition for developing heart disease. The current study was designed to determine both the population prevalence of cardiovascular disease in the Acadian region and to determine whether the prevalence of early cardiovascular disease is increased among the Cajun population.

Methods used We obtained descriptive information via the electronic medical record of 345 consecutive patients previously diagnosed with early onset (age <50) cardiovascular disease (CVD) who presented to University Hospital and Clinics Cardiology Clinic (June 2015–July 2016). The patients consisted of 184 African Americans (97 females and 87 males) and 161 Caucasians (74 females and 87 males). For this study, cardiovascular diseases included: coronary artery disease, HTN, myocardial infarction, and CHF. Demographics, vital signs, lipid panel results, medications, family history, date of CVD diagnosis, and past medical history were collected for all patients. The data on the (161) Caucasian patients were then stratified into either Cajun-identified or non-Cajun by comparing each patient's last name to a standardised list of most popular Cajun last names. Means for each variable between the two groups were compared using independent t-tests.

Summary of results The results of our analysis revealed that Cajun-identified patients were diagnosed with a CVD at a significantly younger age (40 ± 8 years) than were non-Cajun patients (44 ± 4 years, $p=0.03$). There were no significant differences between the Cajun-identified and non-Cajun groups with regard to BMI, blood pressure, HDL and LDL levels, family history of CVD, or smoking/alcohol use history. Cajun patients had lower triglyceride levels (184.6 ± 140.4) than non-Cajun whites (210.3 ± 153.1) although this was not statistically significant.

Conclusions Our results show that patients of Cajun ancestry were diagnosed with cardiovascular disease at a younger age than their non-Cajun counterparts. This intriguing finding suggests that genetic predisposition may contribute to environmental/behavioural factors in development of CVD. Further study is needed to determine the generalizability and the cause of this pathology.

2 STILL WITH HIGHER LDL LEVELS-HISPANICS IN PUERTO RICO SHOWS A LOWER CORONARY ARTERY DISEASE THAN THE USA-EXPLAINED BY GENETIC ADMIXTURE

¹JE Muñoz*, ¹P Elosegui, ¹C Melendez, ^{1,2}PI Altieri, ^{1,2}HL Banchs. ¹University of Puerto Rico, Medical Sciences Campus, San Juan, PR; ²Cardiovascular Centre of Puerto Rico and the Caribbean, San Juan, PR

10.1136/jim-2017-000697.2

Purpose of study Coronary artery disease (C.A.D.) is one of the highest causes of death in the world. The purpose of this study is to compare Puerto Rico (P.R.), Hispanic, U.S.A. country, with the U.S.A., in coronary artery disease.

Methods used Compare a population of Hispanics with the high LDL levels with normal total cholesterol and HDL in P.R. and the U.S.A. The study population was 1000 patients. The U.S.A. health statistics and P.R. Department of Health was used for comparison.

Summary of results Studying the lipid profile of Puerto Rico population, we found that the mean value of LDL lipoprotein is high (± 104 mg/dl) with similar cholesterol and HDL levels in both societies; still the coronary disease (CAD) incidence is lower than the U.S.A. (20%–30%). Investigators from the U.P.R. reported the genetic admixture of this Hispanic population. They reported the admixture consisted of 3 genes called protective against C.A.D.

Conclusions C.A.D. is an inflammatory process involving inflammation of the endothelial cells, macrophages and other cells. Probably, this admixture protects the endothelial cells against an aggressive inflammatory process and excessive oxidative stress. The observation of stitziel-Washington University which described ANGPTL3 gene which produces low cholesterol levels and absent plaques in the coronary arteries support our hypothesis.

3 OBESITY IS ASSOCIATED WITH AORTIC DILATION IN MARFAN'S SYNDROME

SD Grado*, C Watson, WF Campbell, S Kiparizoska, A Thibodeaux, C Richards, TA Skelton, MR McMullan, ME Hall. *University of Mississippi Medical Centre, Jackson, MS*

10.1136/jim-2017-000697.3

Purpose of study Marfan's Syndrome (MS), a connective tissue disorder characterised by a slender build and long limbs, is associated with aortopathy and aortic dissection. Obesity is associated with haemodynamic and metabolic abnormalities such as hypertension, hyperglycemia, inflammation and aortic stiffness that may adversely affect the aorta. We aimed to determine if obesity is associated with aortic dilation in MS patients living in an obese environment.

Methods used We retrospectively analysed anthropometric and echocardiographic data from 61 MS patients from the University of Mississippi Medical Centre from the past 5 years. Multivariable linear regression was used to assess the association of body mass index (BMI) with aortic root diameter measured on the parasternal long axis view at the sinuses of Valsalva on transthoracic echocardiogram.

Summary of results The mean BMI of our MS patients was higher compared with historically published data on MS patients (24.5 kg/m² vs 20.1 kg/m²). This corresponds with the high prevalence of overweight (BMI 25.0 to <30 kg/m²) and obesity (\geq BMI 30.0 kg/m²) in the state of Mississippi and suggests that it extends to the congenital heart population. Mean aortic root dimensions were increased in overweight (40.9 ± 5.1 mm) and obese MS patients (51.5 ± 12.0 mm) compared to normal weight (37.0 ± 6.8 mm) or underweight (38.1 ± 8.6 mm) patients. Aortic root diameter increased with increasing BMI, independent of age, sex, race, systolic blood pressure and height ($p=0.06$).

Conclusions Patients with MS tend to be tall and lean; however, in Mississippi, a state with high rates of obesity, they

have higher mean BMIs when compared to published data. Higher BMI was associated with larger aortic root diameters in our single-centre study. Further assessment of rates of aortic dilation in MS patients with differing BMIs is needed to determine if overweight and obesity exacerbate aortic dilation in MS.

4 BARRIERS TO EARLY CARDIAC CATHETERIZATION IN HIGH RISK NSTEMI PATIENTS

C Basman*, A Bhandary, J Daibes, P Sayegh, S Lebrun, N Coplan. *Lenox Hill Hospital, New York, NY*

10.1136/jim-2017-000697.4

Purpose of study The purpose of this study is to analyse barriers for patients with high risk NSTEMI to receive an early invasive treatment strategy.

Methods used We conducted a retrospective chart review designed to evaluate whether patients with high risk NSTEMI are receiving an early invasive (within 1 day of admission) or delayed invasive (1–3 days after admission) strategy.

Summary of results The study included 173 patients that presented to the Emergency Department with high risk NSTEMI. There were 46 patients (average age 64.5 years) in the delayed invasive arm, and 127 patients (average age 63.2 years) in the early invasive arm analysed. Patients receiving a delayed invasive strategy were more likely to have a history of atrial fibrillation (AF) and to be on anticoagulation (table 1). Patients admitted on weekend/holiday were more likely to have delayed invasive compared to patients admitted during the week (table 2).

Conclusions It is important to recognise barriers to prompt cardiac catheterization and to make hospital system adjustments for optimal treatment of patients with NSTEMI.

Abstract 4 Table 1 Chi square analysis; baseline features

Female Gender	19 (41%)	39 (31%)	0.2
Previous Myocardial Infarction	14 (30%)	44 (35%)	0.72
Previous Percutaneous Intervention	17 (36.5%)	40 (31.5%)	0.511
Previous CABG	7 (15%)	12 (9.5%)	0.21
History of Chronic Kidney Disease	11 (23.9%)	19 (15%)	0.13
History of Diabetes	14 (30%)	37 (29.1%)	0.86
History of Hypertension	30 (65%)	94 (74%)	0.49
Tobacco or Smoking History	18 (39%)	50 (39%)	1
History of Atrial Fibrillation (AF)	8 (17.4%)	7 (5.5%)	<0.05
History of Congestive Heart Failure	10 (21.7%)	14 (11%)	0.084
History of GI Bleed	1 (2%)	2 (1.5%)	0.72
Antiplatelet Therapy	28 (60.8%)	59 (46%)	0.123
Statin Therapy	21 (45.5%)	52 (41%)	0.65
Anticoagulation Therapy	8 (17.4%)	6 (4.7%)	0.13
Beta blockade Therapy	16 (34.7%)	30 (23.6%)	0.13
Temporal change in Troponins.	45 (97.8%)	123 (97%)	1

(Defined in as a value above the 99th percentile of the upper reference level. Additionally, evidence for a serial increase or decrease >20% is required.)

EKG Changes (ST Depressions)	12 (26%)	32 (25%)	0.88
GRACE score >140	10 (21.7%)	16 (12.6%)	0.055

Abstract 4 Table 2 Chi square analysis; patients admitted on a weekend/holiday versus weekday

Admitted on a Weekend or Holiday	20	24
Admitted on a Weekday	26	103

5 INTRAVENOUS IRON ADMINISTRATION REDUCES FIBROBLAST GROWTH FACTOR 23 LEVELS IN CHRONIC KIDNEY DISEASE

B Panwar*, O Gutierrez. *University of Alabama, Hoover, AL*

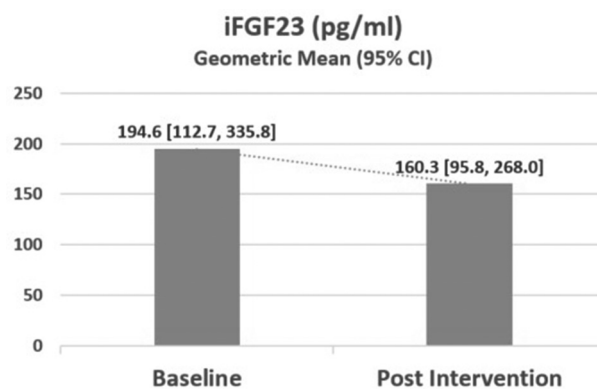
10.1136/jim-2017-000697.5

Purpose of study Higher fibroblast growth factor 23 (FGF23) is associated with higher risk of heart disease and mortality in chronic kidney disease (CKD). Recently, iron deficiency has been linked to elevated FGF23 levels. We examined whether treatment with intravenous iron reduces FGF23 in individuals with CKD.

Methods used 10 participants with stage 3/4 CKD (eGFR 15–59 ml/min) and scheduled to receive intravenous iron (Ferumoxylol) were enrolled in a single-arm study. The primary outcome variable was change in intact FGF23 (iFGF23) or c-terminal FGF23 (cFGF23) levels. Study samples were drawn at baseline and 2 weeks after iron administration. Paired t-test analysis was used to examine change in log transformed iFGF23 and cFGF23 over time.

Summary of results At baseline, mean estimated glomerular filtration rate, mean serum haemoglobin, mean serum ferritin, mean percent transferrin saturation and mean serum phosphorus were 29.5 (± 0.5) ml/min, 8.8 (± 1.5) g/dL, 54.8 (± 41.6) ng/ml, 14 (± 11.4)%, and 3.9 (± 0.5) mg/dL respectively. There was a significant reduction in mean serum iFGF23 concentration (17.7%) at 2 weeks post iron infusion (*two tailed* $p=0.022$). (Figure) There was no significant change in mean cFGF23 concentration.

Conclusions Intravenous iron administration significantly reduced serum iFGF23 levels among individuals with stage 3/4 CKD. Our findings suggest that optimising iron status in individuals with CKD could potentially decrease FGF23 concentration.



Abstract 5 Figure 1 There was no significant change in mean cFGF23 concentration

6 HIGH GRADE HEART BLOCK FOLLOWING ACCIDENTAL EXPOSURE TO ORGANOPHOSPHATE POISONING

GD Bedanie*, D Gbremariam, K Nugent. *Texas Tech University Health Centre, Lubbock, TX*

10.1136/jim-2017-000697.6

Introduction Organophosphates are potent cholinesterase inhibitors capable of causing severe cholinergic toxicity following cutaneous exposure, inhalation, or ingestion. Cardiac manifestations, such as sinus bradycardia, prolonged PR interval, and prolonged QTc, occasionally occur. Complete atrioventricular (AV) block has rarely been reported in this poisoning.

Case presentation A 45-year-old man was found unconscious and brought to our emergency centre as Level 1 trauma patient after his family found him on the floor. He was in respiratory arrest with an unknown mechanism and duration. His blood pressure and heart rate were normal. He had abrasions and bleeding from forehead. He was intubated and admitted to Surgical ICU under the trauma service. On the next day, his family reported that they are suspicious of exposure to an unknown chemical. Due to our suspicion of organophosphate exposure, laboratory test was done and showed a very low level of acetylcholine esterase. On the same day, he developed severe bradycardia with recurrent 3rd degree AV block. Cardiology was consulted, and the patient was treated with atropine.

Discussion Organophosphate exposure produces clinical manifestations due to cholinergic excess. It inhibits the acetylcholine esterase enzyme. Cardiac complications develops secondary to augmented vagal influence on the sinoatrial and AV nodes.

The presentation of our case was unusual and was misleading; he had no typical manifestations of organophosphate poisoning at presentation. Cardiac telemetry monitoring helped us detect recurrent 3rd degree AV block and severe bradycardia that developed 24 hour after exposure to organophosphate. It is rarely described in the literature and complete heart block has been reported in very small number of cases. Development of life threatening cardiac conduction abnormalities may not be early. Patients with suspected organophosphate exposure should be observed closely in an acute care setting with cardiac monitoring and access to atropine, oximes, and external pacing. Careful monitoring, early recognition of this complication, and appropriate management should decrease the mortality rate in these patients.

7 BORTEZOMIB IN THE MANAGEMENT OF CARDIAC AMYLOIDOSIS-A METAANALYSIS

JK Bissett. *CAVHS/UAMS, Little Rock, AR*

10.1136/jim-2017-000697.7

Purpose of study Cardiac amyloidosis is a devastating cardiomyopathy with poor prognosis. Median survival after the diagnosis is less than 6 months after diagnosis and one year mortality is 45% if no effective treatment can be offered. Bortezomib is a boronic acid derivative competitively bind to the proteasome S and has shown improvement in the survival of these patients. As cardiac amyloidosis is a rare disease, no large randomised clinical trials has been done to study the effectiveness of different therapies. Reported clinical experience is limited to retrospective studies. Recently there are abstracts reported different therapies on Bortezomib. The purpose of this study is to review the clinical use and effectiveness of Bortezomib in the management of cardiac amyloidosis.

Methods used Pubmed and Cochrane Evidence based medicine database search with keywords ‘ Bortezomib’ and ‘Cardiac Amyloidosis’ ‘systemic AL amyloidosis’ will be used. The listed reports/journal articles are reviewed, inclusion criteria:

1. Patient aged >18;
2. Study involve systemic amyloidosis AL type and Bortezomib used as an either a)induction agent; b) Part of the combination chemotherapy
3. Studies/reports listed clinical response and survival.

Relevant data are extracted and listed.

Summary of results There is a growing interest in the therapy of cardiac amyloidosis. There are more publications involving collaboration between centres and quality studies on the use of Bortezomib. Use of Bortezomib either along or more commonly, in combination with other chemotherapeutic agents such as dexamethasone, melphalan and cyclophosphamide show promise for patients with this devastating disease. The reported cardiac response rate varies from 19%–30%. In addition, Bortezomib used along or in combination with other chemotherapeutic agents improves survival. The studies so far are limited in terms of number of patients and further stratification of different risk groups. However, the results so far are promising.

Conclusions Bortezomib hold promise for cardiac AL amyloidosis. Further quality study is needed to characterise its use.

8 EFFECTS OF GLUCAGON IN THE CONDUCTION OF SYSTEM OF THE HEART-AND POSSIBLE USES IN THE CARDIOVASCULAR AND METABOLIC SYSTEM

¹H Nuñez*, ^{1,2}PI Altieri, ^{1,2}HL Banchs, ¹N Escobales. ¹University of Puerto Rico, Medical Sciences Campus, San Juan, PR; ²Cardiovascular Centre of Puerto Rico and the Caribbean, San Juan, PR

10.1136/jim-2017-000697.8

Purpose of study The role of glucagon in the conduction system is not clear at the present time, but its role in glycemic control is more known. We decide to clarify its electrophysiologic effects and define its possible use in close-loop bi hormonal systems-artificial pancreas.

Methods used His bundle studies were done to find the effect in 10 patients (P) in the sinus node, A-V node and ventricular conduction. B.S. levels were analysed prior and at the end of the study.

Summary of results Glucagon 5 mg was injected intravenously in an infusion which lasted 10 min. His bundle studies were done by standard techniques. Sinus node function was shortened by 16.6%, increased the atrioventricular conduction 12%, increased the heart rate by 17% (911 P<0.25). No effect in intraventricular conduction was found. The effect lasted 10 min. The baseline FBS was 90 mg/dl and at the end of the study 105 mg/dl. (N.S.).

Conclusions This shows that glucagon improves the sinus node and atrioventricular function, but not the intraventricular function. No other cardiac function was affected. Elevation of B.S. was observe, but not significant. We can conclude that the conduction system is improved by glucagon without other cardiac abnormalities. This shows that glucagon can be used in another compartment in the artificial pancreas to avoid hypoglycemia episodes, if any malfunction occurs in the device.

Adult clinical case symposium

12:00 PM

Thursday, February 22, 2018

9 PELVIC FLOOR MUSCLE EXERCISE-BASED BEHAVIOURAL THERAPY IMPROVES URINARY SYMPTOMS IN PARKINSON DISEASE

^{1,2}CP Vaughan*, ^{3,4}K Burgio, ^{3,4}P Goode, ²J Juncos, ^{1,2}L Muirhead, ^{3,4}G McGwin, ^{1,2}T Johnson. ¹Atlanta VA, Atlanta, GA; ²Emory University, Atlanta, GA; ³Birmingham VA, Birmingham, AL; ⁴University of Alabama at Birmingham, Birmingham, AL

10.1136/jim-2017-000697.9

Purpose of study Determine the efficacy of pelvic floor muscle-exercise based behavioural therapy (BET) for overactive bladder (OAB) in Parkinson disease (PD).

Methods used Randomised trial of BET compared to control (CON) conducted at two VA medical centres. Participants were diagnosed with PD by a movement disorders neurologist and had ≥ 4 episodes of weekly UI. BET included pelvic floor muscle exercises with urge suppression training, fluid modification, constipation management, and self-monitoring with a bladder diary. CON included a bladder diary and mirrored shape drawing. Outcomes were the International Consultation on Incontinence OAB questionnaire (range 0–16, higher = worse) and bladder diary-based weekly UI eight weeks post-randomization. Outcomes analysed using generalised linear models adjusted for baseline symptoms.

Summary of results 53 participants were randomised and 47 reported outcome data including 26 randomised to BET and 21 to CON (6 dropouts in CON). BET vs CON participants were similar with respect to age (71.0 \pm 6.1 vs 69.7 \pm 8.2 years), gender (70% vs 78% male), MDS-UPDRS part 3 motor score (25.6 \pm 13.4 vs 23.8 \pm 15.7), cognition (MoCA 23.5 \pm 3.1 vs 24.9 \pm 2.4), mean weekly UI episodes (13.8 \pm 9.8 vs 15.2 \pm 11.1) and OAB symptoms (8.9 \pm 2.4 vs 8.3 \pm 2.2). BET reported greater reduction in OAB symptoms compared to CON ((-3.1 \pm 2.8) vs (-1.7 \pm 2.2), $p=0.04$). Weekly UI reduction was similar between BET (-7.0 \pm 8.9) and CON (-4.8 \pm 12.7) ($p=0.5$). QOL and bother from OAB were significantly improved in BET ($p<0.0001$ for both) compared to baseline.

Conclusions Behavioural therapy improved overactive bladder symptoms in Parkinson disease. Bladder diary self-monitoring was associated with urinary incontinence reduction in both groups. Providers should consider behavioural therapy as initial therapy for overactive bladder symptoms in Parkinson disease.

10 RELIABILITY OF A NOVEL INDEX OF SENESCENT CELL ABUNDANCE IN HUMAN ADIPOSE TISSUE

¹L Raborn*, ²J Justice, ²H Gregory, ²B Nicklas, ²J Ding, ²S Kritchevsky, ²J Williamson. ¹LSUHSC – NO Medical School, New Orleans, LA; ²Wake Forest School of Medicine, Winston-Salem, NC

10.1136/jim-2017-000697.10

Purpose of study We sought to evaluate reliability of scoring senescent cell abundance by immunohistochemical [IHC] staining of p16^{INK4a} cells in adipose tissue.

Methods used Cells expressing p16^{INK4a} were identified by IHC staining of adipose tissues obtained from women who were older (69.8 \pm 7.1 years) and overweight/obese (BMI: 32.2 \pm 2.9 kg/m²). Fields were viewed at 20 \times magnification using OlyVIA pathology software; 15–20 fields per sample were chosen randomly, and images screen-captured for offline quantification. Two independent examiners reviewed each visual field and recorded total cells counted, and cells expressing Strong, Medium, or Weak intensity positive nuclear staining for p16^{INK4a}. Cell counts were compared between examiners, and inter-rater reliability was assessed by partial correlations adjusting for sample (r) and intra-class correlation coefficients (ICC) per sample.

Summary of results A total of 115 visual fields were analysed from 6 adipose tissue samples. Overall, an average of 38.0 \pm 27 cells were counted per visual field, and 6.6% \pm 5.1% p16^{INK4a} cells scored Strong (0.58 \pm 0.96 p16^{INK4a} cells per field) or Medium (1.78 \pm 1.5 p16^{INK4a} cells per field) signal intensity, and 14.7% \pm 8.8% p16^{INK4a} at any intensity. Significant differences between raters were observed in cell counts with Weak signal intensity (3.76 \pm 3.1 vs 1.83 \pm 1.2 counts per field, $p<0.05$), but not total cell counts, or Medium/Strong intensity cell counts ($p\geq 0.05$, all). Between-rater partial correlations for p16^{INK4a} counts per field were: Weak $r=0.61$; Medium $r=0.67$; Strong $r=0.83$ ($p<0.05$ all). Between-rater consistency was observed in: total cell counts per field (ICC=0.98), and p16^{INK4a} cell counts of Medium (ICC=0.89) or Strong (ICC=0.99) intensity ($p<0.05$ all), but not Weak (ICC=0.64, $p\geq 0.05$).

Conclusions Adipose tissue senescent cells that stain p16^{INK4a} with Medium or Strong signal intensity can be reliably identified and quantified between raters. This study provides evidence for the utility of the adipose tissue p16^{INK4a} cell abundance as a biomarker of cellular senescence in older adults.

11 INTRAEPIDERMAL BLISTERS VS RE-EPITHELIALIZATION OF SUBEPIDERMAL BLISTERS: THE SPECTRUM OF HISTOPATHOLOGIC FINDINGS IN BULLOUS PEMPFIGOID

BD Hodge*, R Brodell, J Mitchell, AB Googe, T Patel, J Schulmeier. University of Mississippi School of Medicine, Jackson, MS

10.1136/jim-2017-000697.11

Purpose of study To examine the incidence of re-epithelialization of subepidermal blisters causing the appearance of an intraepidermal blistering process leading to diagnostic challenges.

Methods used A search of positive immunofluorescence reports (2006–2015) confirming the presence of autoimmune subepidermal blistering was performed and then compared to hematoxylin and eosin (H and E) findings to identify cases of bullous pemphigoid. The presence of subepidermal blistering, intraepidermal blistering, absence of blistering reflecting urticarial and eczematous pemphigoid, and evidence of partial re-epithelialization were tabulated. Cases were not counted on a per-patient basis but rather per biopsy location; therefore, two biopsies from one patient were reported as two cases.

Summary of results 77 cases were identified as having both immunofluorescence and histopathologic features indicative of an autoimmune subepidermal blistering process. Of these cases, 43 showed dermal-epidermal blisters (55.84%), 12

showed features of urticarial or eczematous pemphigoid (15.58%), 12 showed at least focal intraepidermal blistering (15.58%), and 10 showed complete re-epithelialization producing the appearance of an intraepidermal blister (12.99%). A limitation of this study is the possibility that subepidermal autoimmune processes other than bullous pemphigoid (epidermolysis bullosa acquisita and cicatricial pemphigoid) could have been included in this analysis.

Conclusions Re-epithelialization of subepidermal blisters can pose diagnostic challenges as it leads the clinician to suspect an intraepidermal blistering process. By starting with immunofluorescent findings typical of pemphigoid and then reviewing H and E findings, it was determined that 55.84% of the time, histology demonstrated classic dermal-epidermal blistering. In 12.99% of specimens, however, histology showed complete re-epithelialization of the blister floor. Thus, the presence of an intraepidermal blister does not preclude the diagnosis of a sub-epidermal blistering process such as pemphigoid highlighting the importance of clinical-pathologic correlation. Biopsies taken of newer lesions are less likely to show this phenomenon.

12 LANGERHANS CELL HISTIOCYTOSIS WREAKS HAVOC ON THE HYPOTHALAMUS

C Bicknese*, M McLemore, A Ioachimescu. *Emory University School of Medicine, Atlanta, GA*

10.1136/jim-2017-000697.12

Case report A 23-year-old previously healthy man presented with polyuria, polydipsia of 10 month duration. One month prior to the endocrinology visit, a polyp was removed from the right ear canal after he complained of ear pain. Pathology revealed Langerhans cell histiocytosis (neoplastic cells stained for CD45, S100, CD1a, and vimentin). Other symptoms included fatigue and decreased libido. On physical exam, the 98 kg patient appeared euvoletic. Fluid balance was negative: intake 11.49/output 11.52 L. Laboratory studies confirmed diabetes insipidus: serum sodium 144 (136–145), urine osmolality 87 mOsm/kg (300–900 mOsm/kg), and central hypogonadism: undetectable testosterone (280–1,100 ng/dL), luteinizing hormone 1.0 mIU/mL (1.2–8.6 mIU/mL), follicle stimulating hormone 2.62 mIU/mL (1.2–19.2 mIU/mL). Prolactin was slightly elevated (17 ng/mL; 3–13 ng/mL), cortisol, thyroid and IGF-1 levels were normal. MRI of the brain showed mass-like enhancement of the hypothalamus and superior infundibulum, and enhancing lesions of right parietal calvarium and mastoids extending to the external auditory canal. PET scan did not reveal other lesions. Ophthalmology evaluation was normal. The patient received monthly cytarabine, oral desmopressin and transdermal testosterone. After 3 cycles of chemotherapy, brain MRI and PET scans showed improved appearance of hypothalamic and bone lesions.

Discussion LCH is a rare granulomatous disease characterised by abnormal expansion of dendritic cells. The estimated incidence is 3–5/million in children and 1–2/million in adults. Sites involved usually in adults are bones, lungs and skin. CNS-LCH is rare and usually associated with multisystem disease. Both anterior and posterior hypothalamic-pituitary axis

(HPA) can be involved and up to 30% of patients have diabetes insipidus. There is currently no standardised therapy for CNS-LCH. Some patients are conservatively monitored while other receive high-dose steroids, chemotherapy (vinblastine, etoposide, cytarabine) or radiation. While prospective studies are lacking, hypopituitarism persists in most cases after treatment.

Conclusion LCH should be considered in the differential diagnosis of diabetes insipidus and hypothalamic masses. Early diagnosis is important as LCH is a multisystem organ disease that may progress in absence of therapy.

13 TO DIAGNOSE IT, YOU NEED TO THINK OF IT

S Chalasani*, L Maher. *University of Mississippi, Jackson, MS*

10.1136/jim-2017-000697.13

Case report Immunoglobulin G4-related disease (IgG4-RD) is rare immune-mediated condition affecting multiple organs such as pancreas, kidney, lung, salivary glands, lymph nodes and skin with a characteristic lymphoplasmacytic infiltrate enriched in IgG4 positive plasma cells. It occurs mostly in older males with history of allergic diseases. Here we present a patient who had multiple hospitalizations with nonspecific symptoms and extensive work up.

A 64 year old male with past medical history of hypertension, dyslipidemia and diabetes comes for evaluation of 6 months history of nausea, vomiting, abdominal pain and weight loss. Patient had multiple hospitalizations and underwent an extensive work-up which showed hepatomegaly with a pancreatic mass and intrahepatic lesions as well as lymphadenopathy and an abnormal SPEP without a discrete monoclonal spike to point to multiple myeloma. He was seen in allergy clinic 8 months prior for evaluation of hives, rhinitis, and dyspnea. He was diagnosed with asthma and was started on Albuterol. His rheumatologic and infectious work up was negative. He had endoscopy and colonoscopy with biopsies which did not show any evidence of malignancy. He underwent right axillary lymph node biopsy that showed hyperplastic features with negative flow cytometry. Since he had elevated IgG and IgG4 level of 3360, a liver biopsy was performed that showed dense portal lymphoplasmacytic infiltrates with predominance of IgG4 plasma cells. A diagnosis of IgG4-related disease was made and he was started on high dose steroids with significant clinical improvement. In addition, he received 2 infusions of 1 gram Rituximab 2 weeks apart with plans to repeat imaging in future.

IgG4-related diseases is heterogeneous disorder involving multiple organs and presents with nonspecific symptoms. The gold standard for the diagnosis is dense lymphoplasmacytic infiltrates enriched in IgG4-positive plasma cells organised in a storiform pattern with fibrosis and obliterative phlebitis. Serologies are negative except for the elevated IgG4 (>135 mg/dL) seen in 60% to 70% of cases which can be a marker for a more aggressive disease course. Treatment includes immunosuppressive drugs; of these, rituximab appears to be most effective. Due to the rarity of the disease and nonspecific symptoms, a high index of suspicion is needed for early diagnosis and treatment.

14 A RARE VASCULAR CAUSE OF RECURRENT PNEUMONIA

MA Alawoki*, EK Addo-Yobo, B Boonpheng, N Kakkar, C Rosero, DM Pierce. *East Tennessee State University, Johnson City, TN*

10.1136/jim-2017-000697.14

Case report Pneumonia is the infection of the lung parenchyma that can be life-threatening if not managed appropriately. Most community acquired pneumonias have good prognosis, with majority recovering within a month. However, when it is recurrent in the same anatomical location, it is important to do further investigation to look for the cause. With this inquisitive clinical approach, an undiagnosed aberrant right subclavian artery (ARSA) was found to be the cause of recurrent pneumonia.

A sixty five year old female with a recent history of two episodes of right middle lobe(RML) pneumonia, within the previous five months, presented for a hospital follow up. Chest X-ray from both hospital visits suggested RML processes which resolved with levofloxacin. A detailed history during our encounter uncovered intermittent dysphagia to solids and liquids. The recurrent RML pneumonia and the remote history of dysphagia suggested significant pulmonary aspiration. A video fluoroscopy showed compression of the oesophagus. A CAT scan showed the presence of an ARSA that was compressing the upper oesophagus.

We discovered that an ARSA compressed the upper oesophagus, which caused recurrent aspiration pneumonia. ARSA is an uncommon congenital anatomical variant where the right subclavian artery comes directly off the aortic arch instead of the brachiocephalic trunk. It travels posterior to the oesophagus towards the right upper extremity; causing esophageal compression. If symptomatic, it will usually present in infants with respiratory symptoms or after decades as dysphagia along with chest pain, hoarseness or anorexia. Our patient had two upper endoscopies however no imaging study was done to evaluate for extrinsic esophageal compression. Despite the appropriate workup, vascular causes can be missed if not considered.

This case demonstrated a presentation of an ARSA compressing the upper oesophagus and causing dysphagia in a patient with recurrent RML pneumonia. Patients with recurrent pneumonia in the same anatomic location needs further workup and detailed questioning about dysphagia or aspiration events.

15 ACUTE CONFUSION AS A SEQUELA OF PEPTO-BISMOL TOXICITY

A Prystupa*, S Ahmed, RS Urban. *Texas Tech Univ HSC Amarillo, Amarillo, TX*

10.1136/jim-2017-000697.15

Case 61-year-old female with PMH of hypertension presented with acute confusion, hand tremors, and gait ataxia. Workup revealed negative RPR, normal TSH and Vitamin B12. Urine toxicology, blood alcohol, salicylate, and acetaminophen levels were negative. Lab work uncovered refractory hypokalemia and normal AG metabolic acidosis. Non-contrast head CT and brain MRI showed age-related atrophy, subacute/chronic bilateral thalamic enhancement and old basal ganglia lacunar infarctions. Family disclosed her overuse of Pepto-Bismol for dyspepsia. Bismuth toxicity was suspected due to progressive neurological decline, new onset RTA and history of Pepto-

Bismol use. High blood and urine bismuth level confirmed the diagnosis. Patient was treated conservatively with discontinuation of Pepto-Bismol and serial follow-up. At 4 weeks we detected resolution of tremor, gait ataxia, ankle clonus, and marked improvement of memory.

Impact Bismuth is a heavy metal and an active ingredient of a popular and usually safe OTC medication, Pepto-Bismol (bismuth subsalicylate). Its chronic use can lead to bismuth intoxication manifesting as memory change, confusion, depression, insomnia, ataxia, tremor, myoclonus, seizures and coma.

Discussion Acute or chronic ingestion of toxic dose of bismuth can lead to progressive confusion, myoclonus, lack of coordination, and speech disturbance. Bi binds to sulfhydryl groups, leading to white matter changes in CNS and proximal tubule damage in the kidney. Suggestive history, high blood and urine bismuth levels confirm the diagnosis of toxicity. Management is symptomatic with a gradual but unpredictable improvement after discontinuation of product. Extensive search for infectious and metabolic causes of encephalopathy was negative in our patient. The history of chronic bismuth use with high blood and urine levels and typical clinical findings with subsequent resolution of symptoms confirmed the diagnosis of bismuth encephalopathy. Our patient was treated conservatively and followed the typical course of Bi encephalopathy with gradual improvement at follow-up. More detailed labelling would increase awareness to avoid this potential toxicity. Bi toxicity should be considered in a patient presenting with suggestive history and symptoms.

16 RAPIDLY PROGRESSING HTLV-1 ASSOCIATED MYELOPATHY/TROPICAL SPASTIC PARAPARESIS PRESENTING AS BILATERAL LOWER EXTREMITY WEAKNESS

B Nguyen*, M Gutierrez, K Rizg, C Palacio, J Shah. *University of Florida College of Medicine, Jacksonville, FL*

10.1136/jim-2017-000697.16

Case report Patient is a 60 y/o African American male with a history of HTN and seizures who presented for a six-month history of bilateral lower extremity weakness that worsened to the point where he was unable to walk. Associated symptoms included upper extremity tremors, urinary retention and repeated falls. Remarkable labs included mildly elevated CK at 329, with negative RPR, Lyme, ANA, SSA/SSB, Aldolase, immunofixation, and HIV. MRI of neuro axis was done which showed no masses, no acute findings, and mild degenerative changes in C and L spine with minor disc bulging and mild neuro foraminal stenosis in L spine without any cord changes. Previous notes revealed an episode of uveitis in March 2015, but that there were no reported complaints of lower extremity weakness prior to the initial presentation. During outpatient Neurology follow-up, it was thought that his symptoms were consistent with a neurodegenerative process. Vitamin B12, Folate, MMA, Ceruloplasmin, and HTLV-1 were ordered and HTLV-1 was positive. He had multiple hospitalizations for progression of symptoms and was eventually diagnosed with TSP based on WHO criteria as lumbar puncture was deferred. He was sent to rehab for physical therapy but due to progression of disease leaving him mostly bedbound, he developed complications of sacral decubitus ulcers, recurrent UTI's and died secondary to sepsis only 14 months after onset of symptoms.

Human T-Lymphotropic virus 1 (HTLV-1) has been implicated in multiple diseases such as HTLV-1 associated myelopathy/tropical spastic paraparesis (TSP), an insidious disease with progression over 12–24 years. However, we report a case of TSP with rapid progression over 14 months, which contributed to his demise. Possibly, due to the rapid course, this patient did not have cord atrophy that is often seen on MRI of patients with severe, chronic TSP. CSF serology studies should be considered during initial admission as this may help to confirm the diagnosis and to identify markers of a more rapid course of TSP in the future. We suggest that if a rapid course of TSP is suspected, Psychiatry should be involved early on as patients can become demotivated and decompensate rapidly.

17 **LEFT VENTRICULAR NON-COMPACTION CARDIOMYOPATHY: CASE OF A RARE CONGENITAL DISORDER PRESENTING WITH MULTIPLE ORGAN FAILURE**

I Serrano, S Lulla, U Warden, B Al-Turk, S Maharaj. *University of Florida, Jacksonville, FL*

10.1136/jim-2017-000697.17

Case report A 42-year-old African American male with past medical history of chronic kidney disease and hypertension presented to the hospital with complaints of worsening dyspnea, cough and orthopnea for one month. On presentation, he was found to be volume overloaded with significant bilateral lower extremity oedema, rales and a pro-BNP of 11 500. A transthoracic echocardiogram revealed severe mitral regurgitation, an ejection fraction of 25%–30% and left ventricular enlargement with trabeculations consistent with non-compaction cardiomyopathy. After diuresis and optimisation of volume status, he underwent left heart catheterization with findings of non-obstructive coronary artery disease. Patient was initiated on goal directed medical therapy for heart failure and discharged. Months later an echocardiogram was repeated with no recovery in function. Medical therapy was optimised and a dual chamber-ICD was placed.

Two years later, the patient returned with complaints of dyspnea, palpitations, and oedema. He was found to be in atrial fibrillation with rapid ventricular response and decompensated heart failure. The morning after admission, the patient had a new onset seizure and shortly thereafter went into PEA arrest. Return of spontaneous circulation was achieved after 10 min and required endotracheal intubation. During hospital course the patient's renal function worsened with minimal urine output, eventually requiring hemodialysis. A repeat echocardiogram revealed a worsened ejection fraction of 10%–15%.

Discussion Left ventricular non-compaction (LVNC) is a rare congenital heart disorder that occurs in-utero due to arrest in the compaction of the developing myocardium, resulting in 'spongy' appearance of the left ventricle and thick myocardial wall. It is a genetic cardiomyopathy that presents with heart failure, ventricular arrhythmias, systemic embolism or sudden death. It has a prevalence of 0.01% to 1.3% on echocardiogram. This case presents a middle-age man who developed rapidly worsening of heart function, arrhythmias, renal failure, PEA arrest and hypoxic respiratory failure as subsequent complications from LVNC cardiomyopathy.

18 **SERIAL DILATION FOR COMPLICATED EXTRINSIC CERVICAL ESOPHAGEAL STRICTURES**

CC White. *Eisenhower Medical Centre, Evans, GA*

10.1136/jim-2017-000697.18

Purpose of study The unconventional use of serial mechanical dilations of extrinsic cervical esophageal strictures has been attempted with promising results.

Methods used Our patient is a 63 year old female with a history of stage 3 metastatic papillary thyroid carcinoma status post total thyroidectomy with selective right neck dissection who presented to our service with progressive dysphagia and hoarseness. Two years following her initial surgical management, she had recurrence of her disease requiring right radical neck dissection and radiation. She developed vocal cord paralysis and became tracheostomy dependent for more than seven years until a cordotomy was performed. She experienced persistent dysphagia and hoarseness following the placement of her tracheostomy. Despite maximal medical therapy, she often experienced food regurgitation requiring additional chewing to facilitate swallowing. She was evaluated with upper endoscopy, which revealed extrinsic esophageal strictures. ENT assessed for the patient for symptomatic relief and was deemed unable to provide any assistance because of her pathology. Both the aetiology and location of the stricture limited intra-lesional steroid therapy and stent placement. An upper endoscopy was performed and the stricture was bypassed utilising a specialised scope. A wire was placed and the stricture was dilated to an estimated of 10 mm. She has required 12 additional dilations at about 4 weeks interval over a year. The most recent dilation was 18 mm. As expected, there has been restenosis following each procedure and the strictures appeared more open and stable. Marked clinical improvement was noted with our therapy and there has been no suggestion of significant adverse effects.

Summary of results Progressive serial dilation is a safe and effective method of treatment for complex extrinsic cervical esophageal strictures not amenable to alternative therapies. There is minimal restenosis effect after dilation as the frequency of the dilations increases. The appropriate frequency of dilations is dependent on the patient's response to therapy. To date, progressive serial dilations appear safe and effective for severe, complex esophageal strictures.

Conclusions Progressive serial dilation is a safe and effective method of treatment for complex extrinsic cervical esophageal strictures not amenable to alternative therapies.

Neonatal case report symposium

12:00 PM

Thursday, February 22, 2018

19 **ACUTE ALCOHOL INTOXICATION AND WITHDRAWAL IN A PREMATURE INFANT**

MG Johnson*, ER Miller, AC Farris. *University of Louisville, Louisville, KY*

10.1136/jim-2017-000697.19

Case report Acute alcohol intoxication in an infant has rarely been reported, and the majority of reported cases have

involved exposure after delivery in term infants. Here we report a case of a preterm infant with acute alcohol intoxication at birth.

A male infant at 27 weeks gestation was admitted to the NICU for acute alcohol intoxication, metabolic acidosis and prematurity. The pregnancy was complicated by extensive maternal alcohol abuse and scant prenatal care. Maternal blood alcohol level was 382 mg/dL prior to delivery. The infant delivered precipitously prior to NICU team arrival and Apgar scores were 1, 5, and 7 at 1, 5, and 10 min. The infant was quickly intubated and transferred to the NICU while the mother was transferred to intensive care for acute alcohol withdrawal. On admission, the infant demonstrated severe anion gap metabolic acidosis with pH 7.00 and bicarbonate 7 mmol/L. The infant's blood alcohol level was 132 mg/dL at nine hours of life. Despite aggressive fluid resuscitation, sodium bicarbonate administration, and appropriate mechanical ventilation, the metabolic acidosis persisted with a lactic acid level of 16 mmol/L at thirteen hours of life. Liver dysfunction was noted with transaminitis and coagulopathy requiring cryoprecipitate and platelet transfusions. Lorazepam was initiated on day of life two for increased jitteriness and agitation presumed to be secondary to alcohol withdrawal and was continued for several days as the anion gap acidosis gradually resolved.

Ethanol freely crosses the placenta and is a well-known teratogen. Ethanol for umbilical cord care has been the most common reported source of acute infant intoxication, although there are also reports of ingestion related to child abuse. Only one case report from 1967 described an infant with acute alcohol intoxication immediately after birth, and no case reports were found describing acute intoxication in a premature infant. Infants with acute alcohol intoxication can present with a variety of symptoms including hypothermia, tachycardia, poor suck, lethargy, seizures and coma. Associated lab findings include anion gap metabolic acidosis and hypoglycemia. Therapy includes treatment of acidosis and electrolyte abnormalities and supportive care including antiepileptic medications and respiratory support as needed.

20 HEMATOCHESIA IN A NEONATE: THINK BEYOND NECROTIZING ENTEROCOLITIS

FJ Zaidi*, P Agarwal, D Macariola, S Hollinger. *East Tennessee State University, Johnson City, TN*

10.1136/jim-2017-000697.20

Case report A 37 week late preterm female born vaginally presented at 36 hours of life with neonatal abstinence syndrome. Delivery was uneventful. Maternal history was positive for hepatitis C, polysubstance abuse and poor prenatal care. Mother denied having any genital infection during her entire pregnancy. On admission, physical examination was unremarkable except for irritability and mildly increased tone. She was treated with morphine for a total of 10 days. Withdrawal symptoms resolved but she remained in NICU due to poor feeding. Patient required nutritional support but was otherwise doing well until day of life (DOL) 16, when she developed severe rectal bleeding associated with hypothermia and respiratory distress. She was initially placed on supplemental oxygen via nasal cannula but with increasing oxygen requirements she eventually needed to be on high frequency jet ventilation. The

patient was kept NPO and was started on Ampicillin and Gentamicin. Sepsis work up was obtained and infectious disease was consulted. Blood and urine cultures stayed negative throughout. CRP levels raised from <0.5 on admission to 45.0 mg/L. KUB, CXR and urinalysis were unremarkable. On DOL 17, the patient developed significant apnea, bradycardia, and hepatomegaly along with thrombocytopenia. She was treated with IV acyclovir and was transfused with platelets. Rectal bleeding worsened and was treated with fresh frozen plasma. AST and ALT were >2600 IU/L while platelet count dropped significantly from 253 000 to 14,000 K/uL. Haematology/Oncology was consulted who recommended parvovirus PCR, DIC panel and IVIG infusion. The patient progressively deteriorated, developed fulminant hepatitis, acute renal failure and disseminated intravascular coagulopathy. Despite assisted ventilation, vasopressor support, multiple blood products, and aggressive antiviral therapy, the patient passed away on DOL 19. The results of serum HSV DNA PCR came back positive post mortem.

Disseminated cases constitute only one quarter of HSV cases but have the highest mortality of 85% in untreated patients. In around 30% of cases, there are no cutaneous manifestations making an accurate diagnosis of HSV challenging. We report a neonate with rectal bleeding as the initial presenting symptom of disseminated HSV infection.

21 AN INFANT WITH CONGENITAL MYOTONIC DYSTROPHY PHENOTYPE

K Jeffries*, J Phillips. *University of Alabama, Birmingham, AL*

10.1136/jim-2017-000697.21

Introduction Congenital myotonic dystrophy (CMD) is a rare condition that presents with hypotonia and often respiratory distress. We present a severe case.

Case report This 2,130 g female infant was born at 34 weeks by Caesarian for NRFHT and polyhydramnios to a 28 y/o mother with a history of a prior 35 week infant who died shortly after birth from respiratory failure. The case infant was hypotonic with no respiratory effort at birth and was intubated and placed on a ventilator. Apgar scores were 1, 1, and 2 at 1, 5, and 10 min, respectively and were primarily due to profound hypotonia. Admission exam showed *Jeffries K* severe hypotonia and chest X-ray showed thin ribs. The mother has a positive family history for CMD, exhibits myotonic facies, and has difficulty releasing her hand after a handshake. However, array CGH was normal and karyotype revealed a balanced translocation between chromosomes 17q and 19q13. The infant failed numerous attempts at extubation and had severe feeding intolerance for which she received a tracheostomy and feeding gastrostomy. She has developed bronchopulmonary dysplasia, persistent patent ductus arteriosus with left-to-right shunt and right ventricular hypertrophy. At 6 months of age, she is tolerating 30 min trials of continuous positive airway pressure every 4 hours in an attempt to wean from the ventilator. She is on continuous gastrojejun tube feedings with OG tube clamping for one hour every four hours. Profound hypotonia persists.

Discussion CMD is a rare autosomal dominant genetic disorder with an incidence of about 1 in 45 to 50 thousand live births. Inheritance is almost always from an affected mother although parental inheritance has been documented. The

aetiology is an unstable CTG repeat in an untranslated region of the dystrophin myotonic protein kinase (DMPK) gene. These repeats in the mRNA inhibit proper splicing and result in disease. The more CTG repeats there are, the more severe the disease. Infants with greater than 1000 repeats manifest disease in the newborn period while individuals with fewer repeats have onset later in life.

Conclusion All infants presenting with hypotonia in the newborn period should have a family history taken and be evaluated for the possibility of this disease.

22 A RARE CASE OF COMBINED GENETIC SYNDROMES MOWAT WILSON AND MBD5 NEURODEVELOPMENTAL DISORDER

B Gavan, T Chatmethakul, J Martinez, F Eyal. *University of South Alabama, Mobile, AL*

10.1136/jim-2017-000697.22

Introduction Mowat Wilson Syndrome (MWS) is the result of pathogenic variants and deletions of the ZEB2 gene 2q22.2 characterised by microcephaly, mental retardation, distinct facial features with or without Hirschsprungs disease. MBD5 neurodevelopmental disorder is characterised by significantly below average intellectual functioning associated with impairments in adaptive behaviour.

We report a female newborn that presented with a phenotypic presentation of MWS who had a large deletion at chromosome 2q.22.2.

Case Our patient is an African American female infant born to a 29 years old Gravida 2 Para 1 mother with a past medical history of sarcoidosis. Prenatal history was significant for idiopathic polyhydramnios but otherwise unremarkable with no maternal medication exposure during prenatal period. There was no family history of mental retardation, consanguineous marriage or congenital anomalies. Patient was born at gestational age of 37 weeks by caesarean section secondary to previous maternal caesarean section with no complications.

At birth, patient was noted to be symmetrically SGA on exam with distinctive facial features including hypertelorism, prominent nasal bridge, tapered digits and acrodysplasia. On day of life 2, the patient developed increased abdominal circumference, delayed passage of meconium and decreased urine output. A contrast enema was concerning for Hirschsprungs disease, which was later confirmed with tissue pathology showing aganglionic cells up to the splenic flexure.

Genetics testing with chromosomal micro array showed deletion at chromosome 2q.22.2 of 9.6 MB in size, which included 25 genes. Of these 25 genes ZEB2 and MBD5 were deleted yielding diagnosis of MWS and MBD5 neurodevelopmental disorder.

Discussion A Majority of reported cases of MWS are associated with ZEB2 gene mutation. However, our patient's presentation is secondary to a unique large deletion, which contains deletion of 25 genes including ZEB2 and MBD5 which from the literature we have been unable to find another deletion like it. These genes play a major role in neurodevelopment, so monitoring of her neurodevelopmental milestones and seizure disorder is expected to be crucial and only time will tell.

23 UNUSUAL BREATHING PATTERN IN A NEONATE

ES Farnsworth*, B Drabu. *University of Oklahoma Health Science Centre, Edmond, OK*

10.1136/jim-2017-000697.23

Introduction For most term newborns, respiratory distress is transient, with major causes being transient tachypnea of the newborn, respiratory distress syndrome, or persistent pulmonary hypertension. Although rare, anatomical causes may be an aetiology of respiratory distress. In this case we describe a patient who was in apparent respiratory distress, but later diagnosed with a genetic condition causing anatomical dysfunction.

Case report A male infant was born to a 35 year-old G4P2 at 39 week gestation via scheduled caesarean section, with no complications during pregnancy or delivery. Apgar scores were 7 and 8 at 1 and 5 min, respectively. However, at a few hours old, his chest appeared to move oddly whenever he took a breath, making it seem that he was in respiratory distress. On physical examination the infant had an asymmetric chest, with an area in right upper chest, approximately at the second rib, with paradoxical movement with inspiration. He had excellent oxygen saturation, normal respiratory rate, and no signs of increased work of breathing, including grunting or retractions. On further examination the patient appeared to be missing musculature over the right chest. The remainder of his newborn examination, including newborn reflexes and hip examination were normal. A chest ultrasound showed missing vs severely underdeveloped right pectoralis muscle, consistent with the diagnosis of Poland syndrome. An echocardiogram and renal ultrasound were obtained to rule out congenital structural abnormalities and both were unremarkable. He was admitted to the newborn unit and managed routinely. He remained stable on room air during admission. Because his mother had a history of neonatal death of a male infant from osteogenesis imperfecta, a skeletal survey was also performed on the patient, and no fractures were observed. Genetic studies had also been performed in utero with no concerns.

Discussion This case is clinically significant in that apparent respiratory distress in an infant can actually be just unusual breathing due to an anatomical reason, like Poland syndrome. Although additional imaging was done for this particular infant because of concerning family history, this case demonstrates that a full detailed physical exam at birth can decrease the need for unnecessary testing in a newborn.

24 PERSISTENT TACHYPNEA IN A TERM NEONATE DIAGNOSED WITH NEUROENDOCRINE CELL HYPERPLASIA OF INFANCY

J Gallois*, C Mumfhey, J Patrick. *LSUHSC School of Medicine, New Orleans, LA*

10.1136/jim-2017-000697.24

Case report Neuroendocrine cell hyperplasia of infancy (NEHI), formerly known as persistent tachypnea of infancy, is a form of childhood interstitial lung disease characterised by tachypnea, retractions, crackles, and hypoxia. Symptoms can appear at birth, but can present at 3 months of life or greater. Although the diagnostic gold standard for NEHI is

increased neuroendocrine cells on lung biopsy, the diagnosis can be made with clinical and radiographic findings.

We present a term male infant who required oxygen by non-invasive positive pressure ventilation for desaturations and severe persistent pulmonary hypertension (PPHN) at birth. The PPHN resolved within two days and the hypoxia resolved within one week. The tachypnea persisted after resolution of PPHN and hypoxia. Infectious work up was negative. Inhaled albuterol, chest physiotherapy, flow from nasal cannula and oral diuretics failed to improve the tachypnea. Initial chest radiography showed bilateral interstitial densities that persisted on subsequent chest radiographs. Lung CT scan was notable for diffuse ground glass opacities consistent with NEHI. The patient was able to safely nipple and breastfeed all feeds. The patient was discharged on day of life eighteen with persistent tachypnea, and close follow up for weight gain.

The incidence of NEHI is not known, but is rare, and epidemiologic data are largely from case series reports. Increased awareness and clinical suspicion in the neonatal population are important as the diagnosis may go unrecognized. Over time, most patients show clinical improvement without intervention and radiographic changes persist regardless of the initial severity of the disease. The diagnosis of NEHI generally supports a good prognosis.

25 A BUMPY ROAD: SUBCUTANEOUS FAT NECROSIS OF THE NEWBORN ASSOCIATED WITH SYMPTOMATIC HYPERCALCEMIA

DL Charles*, U Narsinghani. *Navicent Health, Macon, GA*

10.1136/jim-2017-000697.25

Case report We report the case of a 39 week female born via emergency c-section for loss of fetal heart tones. Infant received CPR. Apgars were 0 and 2 at 1 and 5 min. Initial studies revealed severe metabolic acidosis which improved after resuscitation and mechanical ventilation. Infant was subjected to hypothermia protocol for 72 hours. Seizures were noted and treated with Phenobarbital.

Patient was discharged home on day of life 11 and readmitted on day 14 with fever and lethargy. Patient underwent full sepsis workup. Initial vital signs: Temp 37.7, RR 52, Pulse 159, BP 72/54, SpO₂ 100%. On exam, patient had erythematous nodules on her back since day 11 of life. Total and Ionised calcium (Ca) were both elevated at 11 mg/dl and 1.32 mMol/L, respectively. Additional lab work was normal. Patient was treated with empiric antibiotics and IV hydration. Patient was diagnosed with subcutaneous fat necrosis of the newborn (SCFN) based on clinical findings. Symptoms improved with supportive care and patient was discharged home at 72 hours. Skin changes resolved by 2 months of life.

SCFN is a self-limiting panniculitis affecting newborns who have birth asphyxia, experience perinatal stress including maternal hypertension or are subjected to therapeutic hypothermia. This condition is characterised by erythematous, violaceous subcutaneous nodules, red to purple in colour which develop on the cheeks, trunk, or extremities. Although, self-limiting, it may be associated with thrombocytopenia, hypoglycemia, hypertriglyceridemia, and symptomatic hypercalcemia. Symptoms of hypercalcemia may include lethargy, poor feeding, nephrocalcinosis and fever. The specific cause is unknown, but may be related to increased levels of $1\hat{I}\pm$ -

hydroxylase which stimulates Ca absorption in the intestine and promotes Ca mobilisation from bone which could lead to secondary hypercalcemia. Hypercalcemia is a life-threatening complication that requires close monitoring including IV hydration, use of Ca-wasting loop diuretics and restricting Ca and Vitamin D intake. Diagnosis of SCFN is clinical and most lesions resolve within weeks to months.

REFERENCE

1. Del Pozzo-Magana BR, Ho N. Subcutaneous fat necrosis of the newborn: A 20-year retrospective study. *Pediatr Dermatol* 2016;**33**:e353.

26 SUCCESSFUL ANGIOJET® AORTIC THROMBECTOMY OF ECMO-RELATED THROMBUS IN A NEWBORN

ME Gutierrez*, M Law, J Alten. *University of Alabama at Birmingham, Vestavia Hills, AL*

10.1136/jim-2017-000697.26

Case report Thrombosis and systemic embolization are morbid complications of extracorporeal membrane oxygenation (ECMO). We present a 2.5 kg newborn with hypoplastic left heart who required ECMO support after a cardiac arrest. A ECMO associated thromboembolism resulting in occlusive distal aortic thrombus was subsequently managed by transcatheter Angiojet (Boston Scientific, Boston, MA) thrombectomy. The procedure successfully restored perfusion to the lower extremities, confirmed by angiography. This case reports of the use of Angiojet thrombectomy in a newborn on ECMO support with complex congenital heart disease.

27 CENTRAL DIABETES INSIPIDUS: A RARE COMPLICATION OF INTRAVENTRICULAR HAEMORRHAGE IN A PRETERM INFANT

P Thakore*, A Dunbar, EB Lindsay. *Tulane-Ochsner Paediatric Residency Program, Metairie, LA*

10.1136/jim-2017-000697.27

Case report A 710 g male infant was born at a referring hospital at a gestational age of 23 weeks and 2 days via vaginal delivery and was transferred to our facility at 14 days of age. His delivery was complicated by breech presentation with difficult head extraction. The infant's initial course was significant for respiratory distress syndrome, grade III-IV intraventricular haemorrhage (IVH), acute renal failure, and large PDA. On day of life 29, a gradual increase in serum sodium level which was refractory to increase in total fluid volume was noted. The combination of persistent hypernatremia (150–160 mmol/L), polyuria (8.4 ml/kg/hr), high plasma osmolality (323 mosm/kg), hyposthenuria (75 mosm/kg) and an undetectable serum ADH (<0.8 pg/ml) confirmed the diagnosis of Central Diabetes insipidus (CDI). Serum sodium and urine output decreased and urine osmolality increased after subcutaneous DDAVP administration and the DDAVP dose was titrated to achieve normal values.

CDI is an uncommon cause of hypernatremia in neonatal period. The diagnosis can be difficult as excessive urine output and high serum sodium can often be attributed to high insensible water loss in the extremely premature newborn. Persistent hypernatremia despite increased fluid intake combined with polyuria and hyposthenuria should increase suspicion for DI. The causes of neonatal CDI include asphyxia, severe

bacterial infections such as meningitis, congenital CNS malformations, and intraventricular haemorrhage. CDI in our patient was thought to be due to grade III-IV IVH complicated by post haemorrhagic hydrocephalus. There are few reports describing CDI as a complication of IVH, and the incidence of CDI following IVH is unclear. In conclusion, the diagnosis of central DI should be considered as a complication of severe IVH in the extremely premature neonate who demonstrates persistent hypernatremia, polyuria, decreased urine osmolality, and increased plasma osmolality. Serum ADH levels can be helpful in confirming central origin of DI and subcutaneous desmopressin can be an effective treatment in the preterm infant.

28 IDENTIFYING BARRIERS TO DIAGNOSIS OF INFANTS WITH NEONATAL ABSTINENCE SYNDROME: A CASE REPORT AND REVIEW OF LITERATURE

¹M Howell*, ²A Smith, ^{1,2}S Drury. ¹Tulane University School of Medicine, Metairie, LA; ²Tulane University School of Medicine, New Orleans, LA

10.1136/jim-2017-000697.28

Background Neonatal abstinence syndrome (NAS) is a growing public health concern. Accurate identification of infants at risk for NAS is crucial to quality neonatal care. Current efforts to identify mothers at risk and their infants have poor specificity and sensitivity.

Case report A 36 2/7 week infant was born to a mother with limited prenatal care and self-reported prenatal heroin/tobacco use, last 12 hours before delivery. APGARs were 8 and 9. Infant's and mother's urine toxicology were negative. NAS risk protocol was initiated. Within 24 hours, Finnegan scoring criteria for NAS was met and medication withdrawal protocol began. The infant was in the NICU for 30 days, with 16 days of withdrawal medication. Cleft palate compounded feeding difficulties associated with NAS. Meconium resulted positive

for opiates after one week. Per state mandate, Department of Child and Family Services was notified. Baby was discharged home with mother.

Conclusions In this case, we highlight several factors. First, mothers often fail to disclose opioid use or to obtain adequate prenatal care. Often this is the result of shame, inadequate resources, fear of removal of infant from parents' custody or lack of education about safe options during pregnancy, coupled with inadequate provider training/support. Second, the negative urine toxicology highlights the rapid metabolism of heroin and the limitations of universal and targeted drug screening. Community level education targeting moms, soon-to-moms and providers is needed. There remains a need to expand research related to multi-substance use exposure in infants. Table 1 highlights the variable pharmacokinetics of different opioids and the limited data about rates of NAS following exposure.

Paediatric clinical case symposium

12:00 PM

Thursday, February 22, 2018

29 IDIOPATHIC DILATED CARDIOMYOPATHY: AN ATYPICAL PRESENTATION

VC Diaz Vidal*, JP Scimeme. University of Florida College of Medicine Jacksonville, Jacksonville, FL

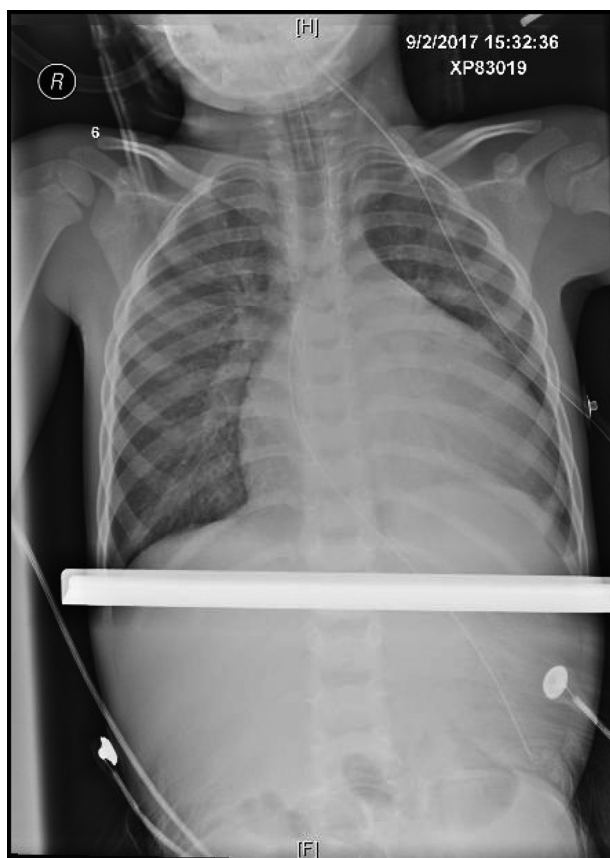10.1136/jim-2017-000697.29

Case report Dilated cardiomyopathy is one of the most common cardiomyopathies in the paediatric population, but compared to other diseases affecting children, it is quite rare. Heart disease in children presents differently compared to adults. Most symptoms are non-specific and may resemble common conditions or illnesses, like asthma or gastroenteritis. Some children may complain of fatigue or dyspnea as the cardiomegaly worsens, and signs of heart failure can be subtle with only tachycardia or tachypnea as abnormal vital signs. Most children may also present with hepatomegaly and a gallop on auscultation suggesting signs of congestion later on. These subtle findings can make diagnosis difficult.

We present the case of a previously healthy 4-year-old male with the sudden loss of consciousness due to a cardio-embolic stroke affecting the left middle cerebral artery and anterior cerebral artery territories of the brain due to a left ventricular thrombus found on echocardiogram after cardiomegaly was seen on initial x-ray. He presented to his primary care physician with vague symptoms of fatigue, abdominal discomfort and decreased activity in April 2017 after a viral upper respiratory infection, 5 months before presentation. This case is a classic example of the subtle and non-specific symptoms that make the diagnosis of idiopathic dilated cardiomyopathy difficult in the paediatric population. We believe the dilated cardiomyopathy could have been secondary to viral myocarditis, most likely parvovirus B19, based on PCR results. Having a high index of suspicion is crucial to identifying and treating dilated cardiomyopathy early before irreversible complications arise.

Abstract 28 Table 1 Highlights the variable pharmacokinetics of different opioids and the limited data about rates of NAS following exposure

Drug	Half-life (PO)	Incidence of NAS with intra-uterine exposure	Time to onset of NAS symptoms	Time to peak withdrawal	Duration of withdrawal
Buprenorphine	24–42 hour	7%–67%	36–60 hour	72 hour	>/=28 days
Buprenorphine/Naloxone	24–42 hour/2–12 hour	40%	36–60 hour	72 hour	>/=28 days
Methadone	9–87 hour	13%–94%	36–72 hour	96–144 hour	>/=30 days
Heroin	<30 min	18%–80%	8–48 hour	36–72 hour	8–10 days
Hydrocodone	4 hour	5%–20%	8–12 hour	36–72 hour	10–30 days
Oxycodone	3–5 hour	5%–20%	8–12 hour	36–72 hour	10–30 days
Morphine	2–4 hour	5%–20%	8–12 hour	36–72 hour	10–30 days



Abstract 29 Figure 1 Initial chest X-ray demonstrating cardiomegaly and pleural effusions

30 SEIZURES, MEDS, AND V-TACH: A JOURNEY TO A BRUGADA DIAGNOSIS

D Fitzgerald*, S Das, M Malone, S Schexnayder. *University of Arkansas for Medical Sciences, Little Rock, AR*

10.1136/jim-2017-000697.30

Purpose To describe a case of Brugada syndrome in a child treated with psychotropic medications who presented with seizures and cardiac arrest.

Methods Descriptive Case Report.

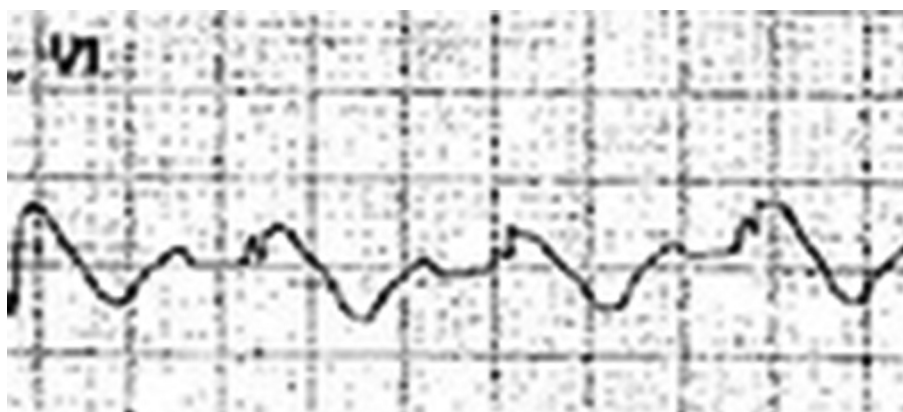
31 CHASING FEVER OF UNKNOWN ORIGIN INTO THE RABBIT HOLE

S Clark*, A Alsulami, S Boppana. *University of Alabama-Birmingham, Birmingham, AL*

10.1136/jim-2017-000697.31

Introduction Fever of unknown origin (FUO) is a common clinical problem in children that carries with it a vast differential, including infectious, rheumatologic, and neoplastic disorders. Diagnostic evaluation can become expansive and expensive and should be guided by the history and physical exam. Tularemia is a rare but important consideration in the evaluation of FUO.

Case Patient is a 10 month old male who presented with daily fevers >102 for two weeks. He developed a skin lesion on the right thigh 3 days following fever onset, but had no other



Abstract 30 Figure 1 Initial ECG

symptoms. Parents denied any known insect, tick, or new animal exposures including rabbits. Was found to have leukocytosis with elevated CRP and ESR at an outside hospital. Initial workup including blood, urine, and wound cultures, and viral panel, were negative. On admission to our hospital, he remained febrile with elevated inflammatory markers (CRP 16, ESR 99). Skin lesion persisted and became a central punched out ulcer with surrounding erythema. Biopsy of lesion showed microabscesses but stains and cultures were negative. Patient also had right inguinal adenopathy. Lymph node biopsy revealed necrotizing granulomas and universal PCR was positive for *Francisella tularensis*. Tularemia titers were also positive at 1:2560. Parents later recalled their dog killing a rabbit in their yard 2 weeks prior to symptom onset. Patient was treated with IV gentamicin for 10 days before being discharged home, and has remained afebrile since.

Discussion Tularemia is a zoonotic infection caused by the aerobic gram-negative bacterium *F. tularensis*. In the US, primary reservoirs are rabbits and ticks, and infections are typically spread to humans via skin inoculation. The most common manifestation in children is ulceroglandular disease, characterised by skin ulcers, lymphadenopathy (LAD), and fever. Diagnosis can be confirmed with serum agglutination titers >1:160 or other testing such as ELISA or PCR. Treatment of choice is gentamicin, and treatment failure rates and mortality are quite low for patients receiving recommended therapy.

Conclusion Evaluation of FUO should be tailored based on history and physical exam findings. Tularemia is a rare cause of FUO, but should be considered in children with exposure to ticks or rabbits in addition to fever, skin ulcers, and LAD.

32 SCURVY, ONLY A DISEASE IN PIRATES?

SE Mayberry*. *University of Alabama Birmingham, Birmingham, AL*

10.1136/jim-2017-000697.32

Introduction Vitamin C deficiency is often thought to be obsolete, however, prevalence among 12–17 year olds in the United States was found to be 5%–6% based on the latest National Health and Nutrition Examination Survey. Vitamin C deficiency should still be considered in certain at risk populations.

Case-report A 9 year old male with a history of epilepsy, non-verbal global developmental delay and cerebral palsy presented to the hospital with a 3 week history of worsening petechial rash on all extremities, gum bleeding, intermittent fever, leg pain and swelling. On arrival he was febrile to 101, with fussiness, refusal to straighten his legs, bilateral lower extremity oedema, gingival bruising and bleeding, and extensive follicular petechiae on his extremities. His labs were remarkable for normocytic anaemia (haemoglobin 6.5), elevated CRP (4.9 mg/dL), ESR (45 mm/h) and x-rays and venous ultrasound of the lower extremities were unremarkable. An extensive lab work-up was unrevealing of any rheumatologic, infectious, or oncologic etiologies, including a normal skin biopsy to rule out a vasculitis. Vitamin C supplements were initiated due to concern for possible Vitamin C deficiency in the setting of developmental delay and poor oral intake. Within 24–48 hours, he showed remarkable improvement in the rash, gingivitis, and leg swelling. His vitamin C level was found to be extremely low (<0.1 mg/dl) supporting the diagnosis of scurvy. He was

discharged home on vitamin C supplementation, 100 mg 3 times a day for 1 week then daily for 2 months.

Discussion Vitamin C deficiency leads to impaired collagen synthesis. Manifestations include irritability, low-grade fevers, gum bleeding, petechiae (particularly perifollicular), ecchymoses, corkscrew hairs, leg swelling, arthralgia, elevated inflammatory markers, normocytic anaemia, and coagulopathy. Scurvy is diagnosed clinically by dietary history and physical findings as well as rapid improvement in symptoms after starting vitamin C supplementation. If untreated, scurvy can be fatal from infection, cerebral haemorrhage or hemopericardium.

Conclusion Although rare in the modern era of fortified foods, scurvy and other nutritional deficiencies should still remain on the differential diagnosis in a child who is malnourished, developmentally delayed, has intestinal malabsorption syndromes, or other restrictive diets.

33 TACHYCARDIA (IN A CHILD WITH VOMITING AND DIARRHOEA) UNRESPONSIVE TO CRYSTALLOID BOLUSES IN THE PAEDIATRIC EMERGENCY ROOM

R Dababneh*, E Fontane. *University of Florida, Jacksonville, FL*

10.1136/jim-2017-000697.33

Case report A 23 month old girl was brought to the paediatric emergency department (PED) by her grandmother for non-bloody, non-bilious vomiting and watery diarrhoea worsening over a 4 day period. In addition, the child had subjective fever and was noted to be less active than usual. She had an unremarkable birth and medical history. On exam she was irritable but consolable. She was ill-appearing without signs of respiratory distress. She was small for age, her skin appeared sallow, and she had fine scalp hair. Her rectal temperature was 98.7 F. Her heart rate was initially noted to be 134 beats per minute but upon re-evaluation was noted to be 150–160 beats per minute. Her blood pressure was 112/73. Her respiratory rate and SpO₂ were normal. Her weight was at the 25th percentile. Her eye exam was notable for mild proptosis. Her precordium was hyper-dynamic and her heart exam revealed a grade 3/6 harsh systolic murmur. She had normal skin turgor and moist mucous membranes. Her lungs were clear. Her abdomen was soft and non-tender. Her bedside glucose was normal. Her treatment in the PED included two intravenous 20 mL/kg crystalloid boluses and intravenous ondansetron. Upon reassessment, her heart rate and blood pressure remained elevated. Her other vital signs remained unchanged as well.

Diagnostic tests in the PED included a 12 lead EKG that was notable for sinus tachycardia with a pericarditis pattern versus early repolarization. A chest radiograph showed a normal heart size and no lung abnormalities. Echocardiography showed hyper-dynamic systolic function, normal valves and chamber size, and no septal defects. Her chemistry panel were notable for a HCO₃ of 12 mmol/L and anion gap of 30 mg/dL. T₃ and Free T₄ were elevated; 3.30 ng/dL and 5.80 ng/dL, respectively. TSH was markedly suppressed at <0.005 mIU/L. Exam and diagnostic findings were concerning for hyperthyroidism. She was admitted and the paediatric endocrine team was consulted. Her Thyroid stimulating immunoglobulins (TSI) were 299% of reference control confirming Graves' disease as the cause of hyperthyroidism in this patient, and she was treated with atenolol and methimazole.

34 THAT'S BELOW THE BELT: A CURIOUS CASE OF INFANTILE METHEMOGLOBINEMIA

P Redmond*, MN Frascogna, B Dillard. *University of Mississippi Medical Centre, Jackson, MS*

10.1136/jim-2017-000697.34

Case report Cyanosis in children can present for a variety of reasons. When presenting outside the immediate newborn phase or when accompanied by dyspnea, respiratory compromise is the leading cause. However, if oxygen administration or airway protection does not improve symptoms, other causes should be considered. In this case we present a previously healthy infant with acute onset cyanosis.

A three week old male presented in respiratory distress as an flight transfer from a tertiary care facility. He had undergone a circumcision the day prior and had subsequently developed apneic episodes and colour change in the last 12 hours. Once in our unit, the patient was noted to be hypoxemic and lethargic. He had clear breath sounds but decreased respiratory drive. His heart rate and abdominal exam were normal. His skin was blue and mottled. He was placed on oxygen with no change in oxygen saturation levels. Basic labs were obtained, including an arterial blood gas with co-oximetry. Blood was visually noted to be dark brown in appearance on phlebotomy. Initial methemoglobin level was 26.7% confirming diagnosis of methemoglobinemia. The patient was intubated for airway protection due to persistent apnea and given 3.5 mg of methylene blue. Subsequent saturations returned to normal levels and repeat methemoglobin level was 3.3%.

The patient was admitted to the paediatric intensive care unit where he was weaned to extubation and recovered completely. Further history revealed that the patient's mother had been using a prescribed lidocaine/prilocaine gel on the circumcision site. In consultation with toxicology services, further use of this medication was halted and no further symptoms persisted.

35 AN UNUSUAL CASE OF CHICKENPOX IN A NEWBORN

AV Agwu*, AZ Solaiman. *MGovern Medical School at UT Health, Houston, TX*

10.1136/jim-2017-000697.35

Case report A 17-day-old infant was admitted for five day history of worsening rash. Initially, a single pustule was noted on his right fourth digit. It was small and round without erythema. On admission, he had single pustules on erythematous bases on his head, right eyelid, hands, scrotum, back, and feet. They were in various states of healing with occasional crusting.

The baby was born term via repeat caesarean section to a mother with adequate prenatal care. She denied all STDs in this pregnancy, during delivery, or prior to conception. History significant for a maternal grandmother who lived with the infant having shingles 2.5 weeks prior to the infant's admission. She had symptoms for 4 days before initiating and completing 4 days of therapy. Also, the infant's older brother had a cold sore on his bottom lip noted 4 days before admission. Mother had chickenpox as a child. All other contacts in the house had been vaccinated against Varicella Zoster Virus (VZV). Review of systems was negative for fevers, cough, congestion, rhinorrhoea, diarrhoea, emesis, decreased oral intake, jaundice, or other clinical signs of infection.

Complete blood count, comprehensive metabolic panel, and cerebrospinal fluid analysis were unremarkable. Acyclovir and Mupirocin were ordered due to concerns for Cutaneous Varicella vs Herpes Simplex Virus (HSV). Varicella and HSV 1/2 PCR on CSF, HSV eye swab, HSV genitoretal, and blood cultures were negative. Acyclovir was discontinued. HSV wound PCR eventually resulted negative. Varicella wound PCR resulted positive confirming the diagnosis of Cutaneous Varicella.

Discussion Cutaneous Varicella acquired postnatally is rarely seen in the neonatal period due to protection from maternal antibodies. Even if a newborn does not fit the age range of those typically infected with chickenpox, their exposure history and exam should guide clinicians to consider it in their differential diagnosis. The rash of cutaneous varicella obtained postnatally can mimic HSV, and the consequences of missing HSV can be severe. As such, a complete HSV workup should be completed if cutaneous varicella is suspected in a newborn. For term infants diagnosed with postnatally acquired cutaneous varicella, VZV Immunoglobulin is not indicated.

36 CAN'T HEAR THE DIAGNOSIS? JUST FOLLOW YOUR NOSE

AS Marshall*. *University of Alabama at Birmingham, Birmingham, AL*

10.1136/jim-2017-000697.36

Case report A 14-year-old male presented to the ED with a 60-pound weight loss over 1 year complaining of increased respiratory effort and secretions. Previously healthy, he is now tracheostomy dependent due to apparent iatrogenic subglottic stenosis, with vocal cord paralysis, progressive hearing loss, and recurrent joint swelling also noted. He is wheelchair bound due to pain and weakness. Exam revealed a mute cachectic male with poor dentition, right knee swelling, hearing loss, saddle nose deformity, and cauliflower ear. Initial work-up was unremarkable on imaging, with normal electrolytes, kidney, and liver function. ESR/CRP were 110 and CRP 16.9. Depressed protein, albumin, and pre-albumin levels indicated poor nutrition. Patient was admitted for respiratory support and further work-up.

Right knee MRI imaging showed soft tissue inflammation consistent with synovial fluid analysis. ANA and ANCA were not detected. ACE levels were normal. Tissue biopsies of the lung and gastrointestinal tract biopsies/brushings revealed no fungal/malignant disease. Hearing loss was sensorineural in nature. Cartilage biopsies of the nose/ear revealed chronic inflammatory changes, and with the patient's clinical picture were consistent with Relapsing Polychondritis as a diagnosis. Collagen Type II antibody levels were elevated at 51.7 U/mL. Patient received solumedrol during admission, and Cyclophosphamide and rituximab were started with a significant clinical response after discharge.

Relapsing Polychondritis is an autoimmune disease affecting cartilage types 2, 9, and 11. Exact aetiology is unknown. Most commonly, it affects whites, both genders equally, and presents typically at 40–60 years of age. Symptoms often include inflammation of the ears, nose, and eyes manifesting as cartilage deformities, audiovisual deficits, tinnitus, vertigo, and hypogeusia. Other symptoms such as arthralgias and joint swelling, and severe tracheobronchomalacia presenting as hoarseness, aphonia, wheezing, stridor, and obstructive apnea

can also occur. Genetic predisposition may exist, but there is no evidence of familial inheritance.

Misdiagnosis of chronic rheumatologic diseases in children can lead to unnecessary work up, residual sequelae, and significantly reducing quality and potential quantity of life.

37 A COMMON DENOMINATOR: ENTEROVIRUS-INDUCED MYOCARDITIS AND ACUTE FLACCID PARALYSIS

MD Lisenby*, V Godsey, N Tofil. *University of Alabama School of Medicine, Birmingham, AL*

10.1136/jim-2017-000697.37

Case report MC is a previously healthy 22-month-old male who presented to the emergency department with fever, vomiting and lethargy for one day. On arrival, he had mild respiratory distress. Chest x-ray showed bilateral opacities, concerning for pneumonia. Despite escalating oxygen therapy, he became increasingly hypoxic, requiring intubation and admission to the paediatric intensive care unit. An echocardiogram showed dilated ventricles and mitral regurgitation concerning for myocarditis. He developed recurrent episodes of non-sustained ventricular tachycardia requiring infusions of lidocaine and calcium and required multiple vasopressors to maintain adequate perfusion. On hospital day 4, his cardiac function improved enough to allow him to be weaned off vasopressors. However, despite decreased sedation he continued to have altered mental status and was unable to be weaned from the ventilator. Initial neurologic work-up with head computed tomography, magnetic resonance imaging and long-term electroencephalogram was unremarkable. Spinal fluid was notable for slight protein elevation (49) and 12 white blood cells. Despite treatment aimed at sedation withdrawal and possible delirium, he failed to improve and his exam was notable for generalised severe weakness and horizontal nystagmus. Repeat imaging showed a large area of demyelination in the cervical region and lower brainstem consistent with acute flaccid paralysis. Further testing was positive for Enterovirus non D-68. Respiratory muscle weakness persisted, requiring tracheostomy and ventilator for respiratory support.

Discussion This case represents a challenging neurologic work-up in the setting of myocarditis management. Enteroviruses are a known cause of myocarditis and acute flaccid paralysis but rarely involve cardiovascular and neurologic systems concurrently. Central nervous system involvement of enterovirus is often devastating and although polio virus has been largely eradicated, other enteroviruses may have similar impact. No antiviral treatments have been developed and evidence for intravenous immunoglobulin is somewhat controversial. Long-term outcomes for enterovirus-induced neurologic impairment are variable, but unfortunately many studies indicate ongoing symptoms at one year follow-up in most patients.

38 A CASE OF PUZZLING PARALYSIS: ACUTE FLACCID MYELITIS

BL Clampitt*, D Hahn. *University of Oklahoma, Edmond, OK*

10.1136/jim-2017-000697.38

Case report Acute onset paralysis in children can represent a range of diagnoses and treatment possibilities. A more recently

recognised entity, acute flaccid myelitis (AFM), should be considered in differential.

A previously healthy 12 year old girl presented with 2 days of new onset left upper extremity and facial weakness after 9 days of intermittent fevers, cough, malaise, nausea/vomiting, and headache. Exam noted significant left triceps, biceps, and deltoid weakness, dysarthria and left facial droop. Lumbar puncture was normal except for pleocytosis. She was initially treated for presumed infection with Ceftriaxone, Vancomycin, and Acyclovir, however bacterial and viral cultures and studies were negative. MRI of the brain showed leptomeningeal enhancement in the posterior fossa, with subtle T2 hyperintensity of the pons. Cervical spine MRI showed extensive T2 signal abnormality in central grey matter, most notably the anterior horns. Anterior horn disease has been described in Enterovirus infections, and a diagnosis of AFM was made given her presentation with corroborating imaging findings and prodromal viral illness, although enterovirus was not isolated. She received a 5 day course of intravenous immunoglobulin. Fluoxetine was also started, as there are reports of improvement of Enterovirus-related AFM with its use; it was later discontinued due to side effects. She did note some improvement of facial droop and triceps weakness, although had persistent severe biceps/deltoid weakness and dysarthria; she was discharged with speech, occupational, and physical therapy follow up. At recent clinic follow up 1 year post onset, she shows continued improvement.

Although AFM is very rare, it should be included in the differential for paediatric patients presenting with acute onset paralysis, even without identified Enterovirus infection. While there are limited case reports of various therapies, there is no formally recognised successful treatment for AFM. Appropriate diagnosis in this setting allows for exploration of treatment options, early services for physical and occupational therapies, and realistic expectations of potential outcomes for patients and families, as well as the opportunity to obtain valuable data and expand the literature that assists in the continued effort for surveillance and investigation of this condition.

Case reports in cardiovascular medicine

2:00 PM

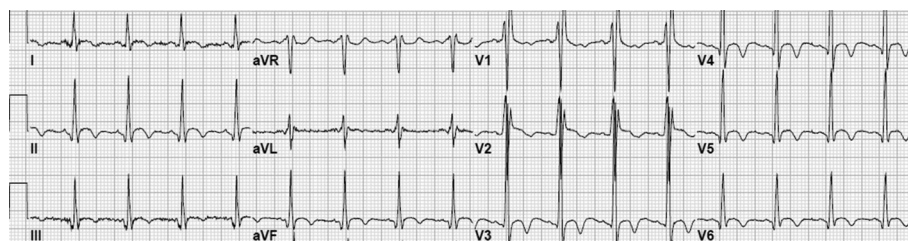
Thursday, February 22, 2018

39 EPI-PERICARDITIS AS A MANIFESTATION OF ACUTE MYELOID LEUKAEMIA

¹D Sahni*, ²ML Hess, ^{1S} Vijayanagar. ¹VCU School of Medicine, Richmond, VA; ²Virginia Commonwealth University, Richmond, VA

10.1136/jim-2017-000697.39

Case report A 30 year old male with no significant past medical history presented with tachycardia, anaemia, thrombocytopenia and blasts consistent with acute myeloid leukaemia (AML). The patient was asymptomatic from a cardiac standpoint. Vital signs were remarkable for a temperature of 38.6°C. Chemistries were significant for a troponin of 2.5 ng/ml, normal creatinine kinase and elevated brain natriuretic peptide of 426 pg/ml. ECG findings showed normal sinus rhythm with incomplete bundle branch block and lateral diffuse ST-T wave elevations suggestive of evolving myo-



Abstract 39 Figure 1 Epi-pericarditis as a new complication of EML-AML

pericarditis. Echocardiography revealed no pericardial effusion and an ejection fraction of 55%. The patient had a pericardial friction rub at the right lower sternal border. Cardiac MRI was recommended, but due to tumour lysis syndrome an endomyocardial biopsy was performed. The biopsy was negative for leukemic infiltration. A right heart catheterization was also performed and intracardiac pressures were normal. Following a short interim, the pericardial rub subsided. The troponin level remained elevated. A cardiac MRI was obtained before discharge and revealed mild left ventricular hypertrophy, enhanced pericardium, and inferior basilar enhancement. The patient was confirmed to have epi-pericarditis secondary to AML.

Discussion Acute myeloid leukaemia (AML) is a cancer with predisposition for infiltration of the blood, bone marrow and mucosal sites. Extramedullary AML (EML-AML) is a known manifestation of the disease. Currently, less than 1% of EML-AML is associated with invasion of the myocardium. The known complications of EML-AML include the formation of a myeloid sarcoma (chloroma), sudden cardiac death, restrictive cardiomyopathy, heart failure and pericardial effusion. A cardiac chloroma consists of myocardial infiltration by leukemic cells and was ruled out with biopsy and cardiac MRI. At a 6 month interval, following intensive chemotherapy, the epi-pericarditis resolved. We have identified epi-pericarditis as a new complication of EML-AML.

showed undifferentiated SCC. She was discharged after clinically justable. In consultation with oncology as an outpatient, multiple metastases were found, including brain mets and patient chose palliative care.

Discussion Cardiac tumours are uncommon, whether benign or malignant, and data on the best management and outcome of these tumours is limited. Frequency of secondary cardiac tumours of any type, as in our case, is estimated to occur in up to 1.2% of cancer patients although it is exceedingly rare to diagnose these during life. Lung cancer accounts for 36% of cancers known to metastasize to the heart. Metastatic pathways include direct extension, via the bloodstream, lymphatic system or by intracavitary diffusion from the IVC or pulmonary veins. Pericardial disease is most common (64%), myocardial and epicardial (35% combined). Endocardial mets, as in our case are rare. Histologically, adenocarcinoma accounts for 26% of these mets, SCC 23%, undifferentiated 21%, and bronchoalveolar 17%. We suspect our patient's left atrial mass originated hematogenously or via a small atrial septal defect that was found at the time of surgery. Although the tumour was successfully removed, the extent of the patient's disease dictated her ultimate demise.

40 **STRAIGHT TO THE HEART: UNUSUAL SITE OF METASTATIC DISEASE**

¹PP Kyaw*, ¹S Ahmed, ²R Smalligan, ¹T Vo. ¹Texas Tech Univ HSC Amarillo, Amarillo, TX; ²UAB-Huntsville, Huntsville, AL

10.1136/jim-2017-000697.40

Case report A 54 yo African American woman with HTN and hypothyroidism presented with progressive dizziness and fatigue for 2 months along with persistent cough with blood streaks. Meds: HTCZ, levothyroxine; FH neg for cancer; SocHx-few cigarettes per day, no alcohol, no drugs. PE: T 36.7, SpO₂ 98% on RA, HR 113, RR 15, alert and oriented, no JVD, chest-clear, heart- RRR with no murmurs. Labs: CBC and CMP, TSH, T4 WNL. CT chest- right lower lobe pneumonia with mediastinal lymphadenopathy, cardiomegaly, small pericardial effusion. EKG – sinus tachycardia. Hospital course: patient was treated for community acquired pneumonia initially. She had recurrent episodes of atrial flutter with RVR; TTE showed a 3.3×2.9 cm mass in left atrium suspicious for myxoma. She underwent excision of the tumour and path showed undifferentiated squamous cell carcinoma (SCC). Endobronchial ultrasound showed small masses in the trachea and the right main stem bronchus. Primary site was confirmed by CT guided biopsy of the right infrahilar mass which

41 **MYASTHENIA GRAVIS MASQUERADING AS A NON-ST-ELEVATION MYOCARDIAL INFARCT (NSTEMI)**

¹A Richardson*, ¹P Staiano, ¹CM Baldeo, ¹C Harris, ²E Benitez, ²F Franchi. ¹University of Florida Jacksonville, Jacksonville, FL; ²University of Florida College of Medicine Jacksonville, Jacksonville, FL

10.1136/jim-2017-000697.41

Case report A 57 year old male with a past medical history of Hypertension, Hyperlipidemia, and Myasthenia Gravis presented to the emergency department for severe shortness of breath which occurred while climbing stairs. Denied chest pain, diaphoresis or previous history of coronary disease. Vitals upon presentation revealed blood pressure of 115/85 mmHg, heart rate of 86 beats per minute, oxygen saturation of 96% on room air, and respiratory rate of 18. Electrocardiogram revealed normal sinus rhythm with no ischaemic changes. Initial troponin T was noted to be 0.04 ng/ml, with subsequent troponin T two hours later at 0.233 ng/ml. Creatine kinase-MB was 7.5 ng/ml, total creatine kinase 561 ng/ml, and pro-BNP <5 pg/ml. He was placed on a heparin infusion and admitted to the Coronary Care Unit for NSTEMI. Left heart catheterization revealed normal coronary arteries. Echocardiogram showed no abnormalities, left ventricular ejection fraction of 55%–60%, normal diastolic function. Troponin T returned to normal limits before discharge.

Troponin T is part of a regulatory protein complex located in striated muscle. It is a sensitive and specific biomarker of suspected cardiac injury. The most common cause for elevated

troponin T is myocardial ischemia. Rarely it can be elevated in patients with neuromuscular disease. Although cardiac disease can occur as a result of neuromuscular disease, up to 15% of Myasthenia gravis patients, it is unusual to see elevation of troponin T in the setting of no detectable disease.

Elevated troponin T in patients with neuromuscular disease is troublesome as it can lead to misrecognition of acute coronary syndromes. Further complicating diagnosis is overlapping of symptoms such as dyspnea and fatigue. Theories for elevated troponin T in neuromuscular disease range from upregulation of embryonic myogenic pathways for repair of damaged muscle to undetectable cardiac damage. Although physicians should retain a high clinical suspicion for acute coronary syndromes, elevated troponin T must be interpreted within the entire clinical context.

42 CANNABINOID-INDUCED SYMPTOMATIC SECOND DEGREE AV BLOCK

M Heckle*, SB Latham, KT Weber, S Haji. *University of Tennessee Health Science Centre, Memphis, TN*

10.1136/jim-2017-000697.42

Case report Cannabinoids are the bioactive components of the marijuana plant. Over the past decade and even more so recently, medicinal and recreational uses of marijuana have progressively risen. While considered a relatively safe drug, significant cardiovascular side effects can accompany its use, which we have previously reported in the *American Journal of the Medical Sciences*. We present a patient with syncope from second degree AV block due to chronic daily inhaled marijuana use.

A 30-year-old male with a history of a single chamber atrial pacemaker due to symptomatic bradycardia was sent to the emergency room (ER) after having a syncopal event while conducting a grocery store robbery. On initial evaluation he was bradycardic with an average heart rate of 40 beats per minute. His electrocardiogram revealed an atrial-paced rhythm with 4:3 s degree Mobitz type II AV block. He was admitted to the cardiology service and by the second day there was no evidence of AV block. On further questioning the patient revealed he is a chronic daily smoker of marijuana. It was felt

that his marijuana use was the likely culprit of his transient second degree AV block leading to his syncopal event. Due to having symptomatic second degree AV block and his addiction to marijuana his pacemaker was upgraded to a dual chamber pacemaker.

Chronic inhalation of cannabinoids can be associated with bradyarrhythmias. Although bradycardia is considered a rare side effect of marijuana, it is likely an under recognised complication. With the recent legalisation of marijuana in 29 states, physicians should be made aware of its potential side effects especially in daily users. Recognition of these cardiovascular effects can help providers avoid expensive and unnecessary testing with potential serious side effects leading to life threatening situations.

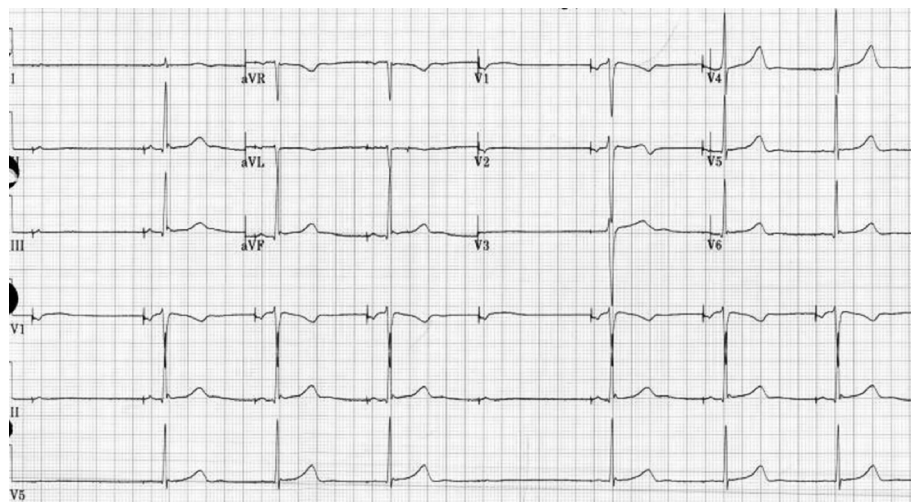
43 A PECULIAR AORTIC VALVE VEGETATION

X Solis*, SK Prieto, B Rosales. *TUHS, Lubbock, TX*

10.1136/jim-2017-000697.43

Case report Our patient was a 61 year old male with a PMH of COPD, who presented to our ER after being found wandering the streets with confusion. He did not recognise his daughter who was at bedside. He was disoriented but was complaining of extreme generalised muscular pain and weakness. Vital signs were notable for a MAP of 54, T 100.6 F. He was noted to have a grade II systolic murmur over the right upper sternal border with minimal radiation to the carotids, it was unknown how long this murmur had been present as the patient did not get regular medical care. He also had extreme tenderness to palpation over all quadrants of the abdomen and large muscle groups. Pertinent labs were WBC 15.42, platelets 28, lactate 2.04, CK 698. Urine drug screen did test positive for amphetamines and cannabinoids. Chest X-ray was notable for bibasilar oedema. CT abdomen/pelvis was notable for bibasilar pulmonary oedema. CT head was negative for acute abnormalities. He was started on pressor support as well as vancomycin and piperacillin-tazobactam.

Blood cultures from admission were positive for *Staphylococcus aureus*, MSSA. Antibiotic therapy was then changed to nafcillin and rifampin. Transthoracic echocardiogram was notable for a large aortic valve vegetation measuring up



Abstract 42 Figure 1

1.6×2.7×2.2 cm, highly mobile, extending into in the left atrium. Moderate to severe aortic regurgitation was also noted AVA 1.6 cm, and transvalvular gradient measuring 6.3 mmHg. LVEF was estimated at 55%–59%. LHC was negative for any epicardial CAD.

He underwent bioprosthetic AVR by cardiothoracic surgery. Small vegetations were seen on the mitral valve leaflets, which were surgically resected. He did develop post-operative pleural effusions and was progressing well until he suddenly developed respiratory distress and metabolic acidosis. Repeat TTE was notable for pericardial effusion and tamponade, so he was taken to the operating room once again for chest exploration and pericardial drain placement. Aortic regurgitation did improve was now moderate, with LVEF maintained. The patient then had increased ventilator requirements, aneuric renal failure requiring CRRT, as well as hematochezia and family decided to withdraw care and forego any aggressive treatment.

44 DIABETIC KETOACIDOSIS-INDUCED HYPOTHERMIA CAUSING CARDIOMYOPATHY

D Gill*, M Hess. *SUNY Upstate Medical University, Syracuse, NY*

10.1136/jim-2017-000697.44

Case report Diabetic ketoacidosis (DKA) is often triggered from underlying stressors, and can rarely lead to hypothermia. The proposed mechanism of hypothermia is secondary to the inability of glucose molecules to be transported intracellularly because of lack of insulin, hence leading to lack of substrate for cellular heat production. Hypothermia serves as a stressor, which can cause catecholamine surge. Catecholamine surge is the underlying mechanism for stress induced cardiomyopathy.

25-year-old male with past medical history of diabetes mellitus type 1, presented with 3 days of nausea, vomiting and confusion. In the emergency department he was found to be hypothermic with temperature of 31.3°C, with blood pressure of 137/94 mm Hg, and heart rate of 108 beats per minute. On physical exam he appeared to be lethargic, had a dry oral mucosa and poor skin turgor. He had a regular rate and rhythm and did not have any jugular vein distension, or inspiratory crackles. His labs showed pH of 6.77, and bicarbonate of 5 mmol/L, anion gap of 29 mmol/L, betahydroxy butyrate of 13.3 mmol/L and glucose of 1396 mg/dL. His electrocardiogram showed sinus bradycardia and Osborn waves.

Echocardiogram on day 1 showed left ventricular ejection fraction of 30% along with diffuse hypokinesis of all walls. Patient was admitted to the intensive care unit and started on insulin drip and aggressively hydrated for DKA, along with rewarming. Repeat echocardiogram on day 4 had shown ejection fraction of 40%. Cardiac enzymes remained benign throughout the hospital stay. Patient did not have any prior cardiac history and he was not drinking, smoking or abusing illicit drugs. He also denied autoimmune disease or radiation therapy. Hence patient was diagnosed by the cardiology service with stress-induced cardiomyopathy, a Takotsubo variant the most likely aetiology. He was started on beta blocker and an ACE inhibitor, with full recovery of his ejection fraction and wall motion abnormalities during follow up visit at 3 months.

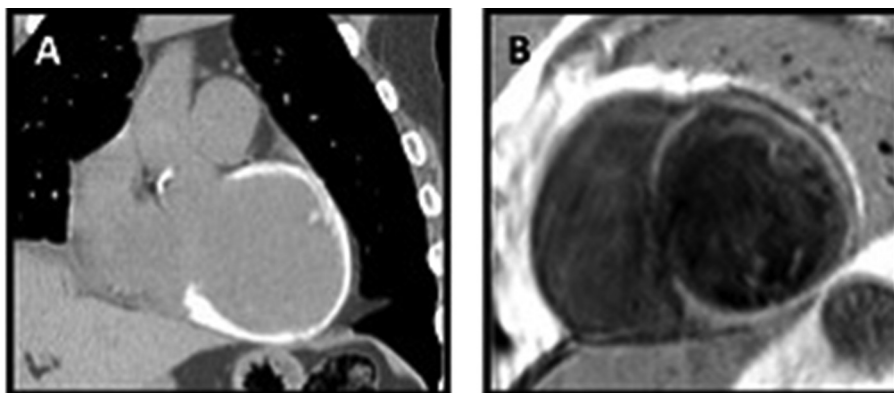
This case is an illustration of a rare case of DKA induced hypothermia, which then caused stress induced cardiomyopathy. Electrocardiogram findings of Osborn waves were crucial to the diagnosis of hypothermia. Physicians should keep in mind that diabetic patients can present with new onset cardiomyopathy from DKA and hypothermia.

45 SEPTIC DIFFUSE LEFT VENTRICULAR CALCIFICATION

B Lennep*, RC Long, ME Hall, CS Guild. *University of Mississippi Medical Centre, Madison, MS*

10.1136/jim-2017-000697.45

Case report A 54-year-old man with no cardiovascular history aside from hypertension presented with complaint of abdominal pain and shortness of breath. Computed tomography (CT) imaging revealed right-sided pneumonia with empyema. He rapidly deteriorated into septic shock requiring intubation and 3 vasopressors. He was treated with antibiotics and drainage of the empyema, with gradual recovery over 4 weeks. During this time, he had several chest CT scans to evaluate the pleural space. At discharge, he was referred to cardiology for left ventricular (LV) ejection fraction of 20% by echocardiogram. Review of the serial CT scans revealed development of diffuse calcification of the LV myocardium over a period of 6 days following his initial CT (*figure A*). Coronary angiography demonstrated only nonobstructive coronary disease. Cardiac magnetic resonance imaging demonstrated diffuse subepicardial late gadolinium enhancement (*figure B*). Three years later, the calcification and diminished ejection fraction persist.



Abstract 45 Figure 1 Computed tomography image (A) demonstrating diffuse epicardial calcification of the left ventricle. Short axis cardiac magnetic resonance image (B) demonstrating diffuse subepicardial late gadolinium enhancement

Diffuse calcification of the LV is a rare complication of severe sepsis, with less than 10 published case reports. The mechanism has not been clearly established but is thought to represent dystrophic (as opposed to metastatic) calcium deposition. This phenomenon differs from the calcification seen post-infarct in that it is diffuse and from that seen following myocarditis in that it spares the right ventricle. Severe LV dysfunction is common and short-term mortality is very high.

46 RIGHT VENTRICULAR FAILURE WITH PULMONARY HYPERTENSION AND PROGRESSIVE RESPIRATORY FAILURE AFTER RUPTURED BREAST IMPLANTS

M Shahreyar*, S Koshy, KT Weber, N Garg. *UTHSC Memphis, Collierville, TN*

10.1136/jim-2017-000697.46

Introduction Several reports have described an association between free silicone injections with multisystemic complications, including acute and chronic pneumonitis, silicone pulmonary embolism and connective tissue disease. Right ventricular failure and pulmonary hypertension with progressive respiratory failure after ruptured breast implants has rarely been reported.

Case report A previously healthy 42-year-old transsexual female presented with progressive shortness of breath over a 3 months period. For cosmetic augmentation, 10 years prior, she received silicone breast implants and free silicone injections to the buttocks and calves. Prior to the onset of her pulmonary symptoms, her silicone breast implants ruptured following motor vehicle accident.

At initial evaluation diffuse crackles more noticeable in bilateral upper lung fields were found. Chest radiograph showed opacities in upper lobes bilaterally, computed tomography demonstrated severe pulmonary fibrosis predominantly in upper lobe peripheral distribution. Severely dilated right ventricle with reduced systolic function and a normal left ventricular size and function were found on echocardiogram. On right heart catheterization, mixed venous saturation was 47% mean pulmonary artery (PA) pressure 47 mmHg, capillary wedge pressure 11 mmHg, pulmonary vascular resistance (PVR) 11 wood units and cardiac index 1.83 L/min/M². Vasoreactive testing with inhaled nitrous oxide was negative. Right upper lobe transbronchial biopsy revealed interstitial multinucleated giant cells and focal small multicystic area with minimal fibrosis suggestive of silicone-induced pneumonitis.

Conclusion Silicone implants and free silicon injections have been increasing worldwide with 2/3 breast implants rupture over 11 years. This case highlights a devastating cardio-pulmonary complication such cosmetic surgery and should raise patient and physicians awareness of these life-threatening complications.

47 CASTING LIGHT ON PLASTIC BRONCHITIS: AN INSIDE LOOK AT COMPLICATIONS FOLLOWING FONTAN PALLIATION

¹EJ Schwartzenburg, ¹RE Herdes*, ²SS Maqsood, ²D Edell, ²A Gutierrez, ²C Lilje. ¹Louisiana State University Health Sciences Centre, New Orleans, LA; ²LSUHSC, New Orleans, LA

10.1136/jim-2017-000697.47

Case report Plastic bronchitis (PB) is a rare complication of single-ventricle patients following Fontan palliation. Patients expectorate impressively intact 'tree-like' casts, which can vary in size and can cause filling defects in the lung. This can present as acute respiratory failure or hypoxia, and can lead to asphyxiation and death. Pathophysiology of PB remains unknown. It is believed to be associated with central venous congestion and subsequent lymphatic abnormalities. There are no clinical trials that demonstrate superior efficacy of any single treatment for PB beyond optimising cardiac hemodynamics. Case studies have suggested aerosolized mucolytics, steroids, bronchoalveolar lavage, bronchoscopic extraction, pulmonary vasodilators, and nebulized fibrinolytics.

We report the case of a 16 yo female with history of Tricuspid Atresia with a VSD following Fontan palliation who presented tfor recurrent tussive episodes of white casts. Oxygen saturation at time of presentation was 90% on room air. Cardiac imaging and catheterization studies revealed reasonable cardiac function. Mean pressure in the fontan system was 14 mmHg. A fenestration had closed spontaneously years ago. There was no evidence of intracardiac thrombosis, Fontan stenosis, or airway filling defects. CBC, CMP, and coagulation studies were within normal limits. Patient was treated with Azithromycin, low fat diet, and nebulized heparin. The PB exacerbation resolved and patient was sent home on day 4..

This case represents a unique complication of paediatric cardiac patients with single ventricles after definite Fontan palliation. PB should be considered in all such patients who present with expectorated casts. These casts is usually an ominous prognostic sign. The underlying cardiac status needs to be carefully investigated and optimised if possible. Symptomatic treatment options to resolve the casts are evolving, as there are very few cases documented. The successful resolution of symptoms in our patient suggests support for the use of nebulized heparin in this population.

48 RESISTANT PRINZMETAL ANGINA DUE TO PHEOCHROMOCYTOMA

R Subedi*, R Dean, D Villarreal. *SUNY Upstate Medical University, Syracuse, NY*

10.1136/jim-2017-000697.48

Case report Prinzmetal angina is caused by the spasm of the coronary arteries. Pheochromocytoma can cause release of catecholamines and vasospasm of coronary arteries precipitating prinzmatal angina in susceptible patients. This is a case of a difficult to control prinzmatal angina from underlying metastatic pheochromocytoma.

A 36 year old male presented with intermittent chest pain for 3 days and an episode of loss of consciousness. His chest pain occurred even at rest, was worse at night and relieved by nitroglycerine. Physical exam, vital signs and electrocardiogram (EKG) were normal. In the hospital, he had further episodes of chest pain. He had a heart rate of 34 beats/min and a BP of 70/46 mmHg. An EKG showed ST elevations in the inferior leads with 3rd degree atrioventricular (AV) block. Telemetry monitoring showed intermittent 3rd degree AV block. He had presented to an outside hospital with similar complaints and findings. A cardiac catheterization performed at that time revealed normal coronaries. He was started on isosorbide mononitrate and ranolazine but he continued to have nocturnal chest pain with ST elevations and 3rd degree

AV block. Diltiazem and cilostazol were added. A nitroglycerin patch was applied at night. Aspirin was switched to clopidogrel and atorvastatin was started to stabilise the endothelium. His symptoms improved with this regimen. Because of his very difficult to control vasospastic angina, plasma nor-metanephrines and 24 hour urine nor-metanephrine were sent which were elevated at 3694 pg/ml and 14876 ug/24 hour respectively. Further workup revealed metastatic pheochromocytoma.

Prinzmetal angina can cause arrhythmias, including high grade AV block and sudden cardiac death. It usually occurs at rest, mainly between midnight and early morning because of the natural circadian variation of hormones. Calcium channel blockers and nitrates which promote coronary vasodilatation are commonly used. Cilostazol, a vasodilator, can be added to control the symptoms. Because endothelial dysfunction and oxidative stress are involved in the pathogenesis, statins and antiplatelets can be helpful to stabilise the endothelium. In refractory cases, endogenous production of catecholamines by pheochromocytoma should be considered, as in our patient.

Moving your clinical case presentation into a published manuscript

2:45 PM

Thursday, February 22, 2018

49 ADENOCARCINOMA OF THE APPENDIX PRESENTING AS RECURRENT ABSCESS FORMATION

I Serrano*, J Ruiz, A McCarthy. *University of Florida, Jacksonville, FL*

10.1136/jim-2017-000697.49

Case report 24-year-old African American male with a medical history of appendiceal abscess and perforation presented to the hospital with complaints of abdominal pain and an open draining wound with purulent foul-smelling fluid. His abdominal symptoms initially started eight months prior, when he was found to have an appendix rupture with a superimposed abscess at an outside institution. At that instance, he was managed with intravenous antibiotics and a percutaneous Jackson-Pratt drain was placed. In the subsequent months, the patient had 3 admissions with similar presentations requiring percutaneous catheter to drain the abscess recollection and antibiotics. On physical exam, there was evidence of purulent discharge from an open abdominal wound in the right lower quadrant concerning for recurrence of abscess with possible formation of an enterocutaneous fistula. A computed tomography (CT)-scan of the abdomen and pelvis was done with evidence of a thick-walled, multilobulated collection in the anterior lower abdomen/pelvis, which passed through the right rectus abdominis muscle communicating with the skin surface. He was started on antibiotic coverage and a drainage catheter was placed. CT-guided core biopsy of the abdominal mass confirmed the diagnosis of adenocarcinoma with mucinous features. A PET-scan revealed bilateral metastasis to inguinal and iliac lymph nodes. He was scheduled to start neoadjuvant chemotherapy with Folinic acid, Fluorouracil and Oxaliplatin (FOLFOX) with plans of reassessment for surgical resection.

Discussion Appendix cancer is an extremely rare gastrointestinal malignancy found in approximately 1 percent of appendectomy specimens and accounting for less than 0.5 percent of all tumours of gastrointestinal origin. Mucinous adenocarcinomas are one of the histologic types causing glandular invasion and mucus secretion. It commonly presents as acute appendicitis but on rare occasions, can develop an abscess and perforation of the appendix with spreading of cancerous cells into the peritoneum. We report an unusual case of recurrent intra-abdominal abscess formation masquerading a diagnosis of appendiceal mucinous adenocarcinoma. Mucinous adenocarcinomas like the one presented, can cause build-up of mucin leading to appendiceal rupture and abscesses.

50 A RARE PRESENTATION OF ACHALASIA IN A TEENAGER

NS Jones*, W Thomas, J Bocchini. *LSUHSC Shreveport, Shreveport, LA*

10.1136/jim-2017-000697.50

Case report Achalasia is a rare childhood disease. Due to its association with nonspecific symptoms, its diagnosis is often delayed. Delayed diagnoses often lead to delayed treatment. The most common symptoms in the paediatric population are as follows: weight loss, dysphagia, and regurgitation. Children presenting to their primary care physician with complaints of the aforementioned symptoms are often diagnosed with Gastroesophageal Reflux, Failure to Thrive, or other nonspecific eating disorders. When patients complain of progressive dysphagia accompanied by increasing frequency in regurgitation, it is imperative to work up the patient for this diagnosis. A 17 year old male with no pertinent past medical history presents with complaints of worsening epigastric burning pain occurring in the late evening. The patient states that his symptoms have been present for about one year. Approximately nine months prior to presentation, he began having difficulty swallowing solids such as steak, but was able to swallow chicken, bread, and liquids. Seven months prior to presentation, his dysphagia worsened, making it harder to swallow softer textured foods. The patient developed manoeuvres to aid himself with swallowing; however, over time these manoeuvres failed resulting in further progression of his dysphagia to include liquids as well. Over a two month time period, the patient lost 30 pounds. His initial physical examination was benign except for minimal epigastric tenderness to palpation. An upper gastrointestinal series demonstrated incomplete spontaneous contrast flow through the lower esophageal sphincter with significant fluid buildup in the proximal oesophagus. The study also demonstrated esophageal dilation proximal to the lower esophageal sphincter. Paediatric gastroenterology was consulted and an extensive work up was performed including esophageal manometry and esophagogastroduodenoscopy. These diagnostic tests confirmed the diagnosis of achalasia. Paediatric surgery was consulted, and after discussing with the family the therapeutic interventions available, the decision to perform a Heller myotomy with partial fundoplication was made. The patient tolerated the procedure well and his diet was advanced without complication. At time of discharge, he was able to tolerate a regular diet without any pain or discomfort.

Adolescent medicine and paediatrics
 Joint plenary poster session and reception

4:30 PM

Thursday, February 22, 2018

51 GAPS IN ATV INJURY REPORTING IN ALABAMA: A CASE FOR STATEWIDE TRAUMA DATABASES

A Burks*, K Jeffries, A Klasner, M Nichols, K Monroe. *University of Alabama, Birmingham, AL*

10.1136/jim-2017-000697.51

Purpose of study In 1998 Alabama passed legislation requiring hospitals to submit data regarding head and/or spinal cord injuries; collection began in 1999. That same year this was extended to include all traumatic injuries but only head and spinal cord reporting was mandated. In 2007–2008 the Alabama Trauma System (ATS) was established, data is entered by EMS in the field or from hospital entry; this is optional reporting. ATS and head/spinal injuries are recorded in same database. Currently there is no state plan to expand or mandate recording of paediatric trauma injuries in Alabama. The purpose of this study was to compare data from multiple reporting agencies within the state of Alabama, including chart review from the state’s paediatric trauma centre, regarding ATV injuries to determine if accurate reporting is being achieved.

Methods used Data from 4 sources in the state of Alabama was reviewed from 01/01/16 to 12/31/16 for patients aged 0–18 years old who sustained an injury from an ATV related accident. Data was compared between sources to establish if accurate reporting of ATV injuries is being achieved. Key-words and diagnosis codes were searched through the National Electronic Injury Surveillance System (NEISS), Children’s of Alabama retrospective chart review, Alabama Trauma System (ATS), and Alabama pre-hospital EMS records.

Summary of results National Electronic Injury Surveillance System reported 30 injuries, 73% male, 27% female, median 12.5 years (mean 11.7). Children’s of Alabama chart review revealed 104 injuries, 60% male, 40% female and one unknown gender, median 12, (mean 11.5). Alabama EMS recorded 25 injuries 56% male, 44% female, median age 12 (mean 12.2). Alabama Trauma System reported 5 injuries, 80% male, 20% female, median age 14 (mean age 11).

Conclusions Injuries are the leading cause of death in paediatric patients. The current reporting of ATV injuries in Alabama demonstrates large gaps in accuracy. Without a uniform reporting system it is impossible to track the number of ATV accidents, or other traumatic injuries, occurring in the state. Prevention of injuries is key to decreasing paediatric mortality and a statewide trauma database would allow development of targeted prevention programs, education and outcome monitoring.

52 HPV VACCINE IS RECOMMENDED LESS OFTEN IN THE SOUTH

A Caldwell*, P Darden. *The University of Oklahoma, Edmond, OK*

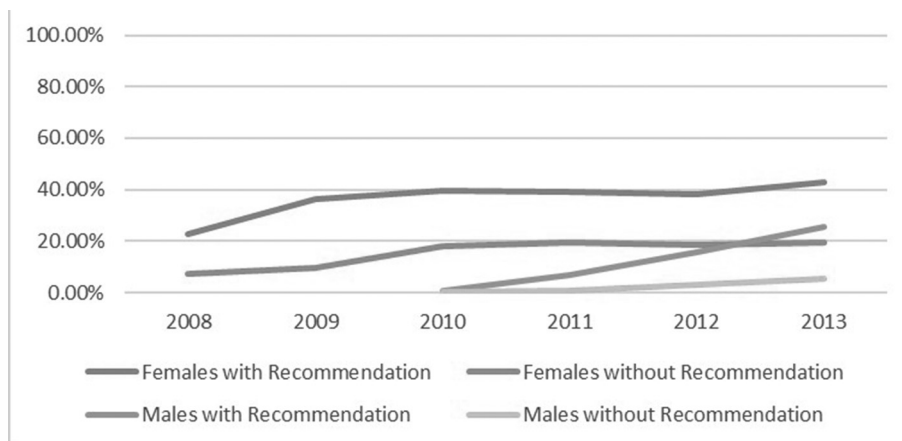
10.1136/jim-2017-000697.52

Purpose of study HPV vaccine receipt for males and females remains low. Provider recommendation in favour of the HPV vaccine is associated with increased vaccination. Regional variations in practice, including vaccine recommendations, may explain variations in vaccine uptake.

Methods used Data were from the 2008–2013 National Immunisation Survey-Teen. Provider recommendation was from parent report and vaccination status by provider report. All analyses accounted for the complex sampling design. Up to date (UTD) was defined as receipt of 3 doses of HPV vaccine.

Summary of results UTD did not differ among males in the South compared to the US. UTD increased for females in the South from 13.9% in 2008 to 35% in 2013, however, this was lower than US females who increased from 17.9% to 37.6%. Provider recommendation of HPV vaccine was also lower among females in the South compared to the US, increasing from 44.6% to 66% in the South and from 49.2% to 69.5% in the US. Among males, recommendation did not differ except in 2013. HPV vaccine was recommended 39.4% in the South and 45.7% in the US for males in 2013. The attached figure displays percent UTD by provider recommendation and sex among those who live in the South.

Conclusions Females in the South receive a provider recommendation and the HPV vaccine less often than females in the US as a whole. Male vaccine receipt did not differ in the South compared to the US and neither did recommendation except for 2013. There are regional variations in both HPV



Abstract 52 Figure 1 UTD by provider recommendation and sex in the south

vaccine receipt and frequency of provider recommendation. Recommendation is key for HPV vaccine receipt for both sexes in the South. Improving frequency of provider recommendation for HPV vaccine could improve UTD for HPV in the South.

53 TRENDS IN SUICIDE ATTEMPT ADMISSIONS 2012-PRESENT AT THE CHILDREN'S HOSPITAL AT OU MEDICAL CENTRE

M Cooper*, S Gillaspay, R Wallace, S DeLeon. *Oklahoma University Health Science Centre, Oklahoma City, OK*

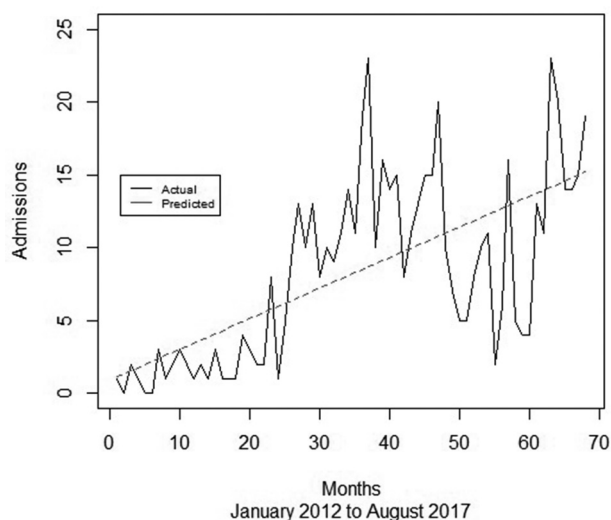
10.1136/jim-2017-000697.53

Purpose of study The purpose of this study is to evaluate secular trends and seasonal variations in admissions for suicide attempts at the Children's Hospital at OU Medical Centre over the last five years.

Methods used Charts of children and adolescents aged 4–18 years of age admitted to The Children's Hospital at OU Medical Centre with the diagnosis of suicide attempt, self-harm, or intentional ingestion from January of 2012 to August 2017 were identified using ICD-9 and ICD-10 codes from the hospital electronic medical record. Records were individually examined to evaluate for appropriateness for inclusion and admissions were grouped by month. Linear regression was used to identify the overall trend in the data, and we plan to use Auto Regressive Integrated Moving Average (ARIMA) analysis to analyse separately for seasonal variation and trend.

Summary of results Linear regression detected a significant increase in monthly suicide attempt admissions between January 2012 and August 2017. There was an average overall increase of 0.21 admissions per month over the entire time period ($p < 0.0001$). See figure for actual admissions per month over the 68 month period and the predicted regression line. ARIMA modelling is underway to examine for seasonal variations and recent changes in trend.

Conclusions There has been a significant increase in suicide admissions at The Children's Hospital at OU Medical Centre since January of 2012. Full analysis to define seasonal variation and changes in trend will be completed prior to meeting.



Abstract 53 Figure 1 Suicide admissions by month

54 ASSESSMENT OF A PAEDIATRIC CLINICAL ASTHMA SCORE'S ABILITY TO PREDICT DISPOSITION

¹L East*, ²K Kepple, ¹R Gibson, ¹N Lane. ¹Augusta University, Augusta, GA; ²Orlando Health, Orlando, FL

10.1136/jim-2017-000697.54

Purpose of study This research is part of a feasibility study for a paediatric emergency department observation unit. This study examined the ability of a clinical asthma score (CAS) to predict disposition of paediatric patients treated in a paediatric emergency department (ED). The CAS is used to assess asthma severity and is based on respiratory rate, lung sounds, retractions, and oxygen saturation.

Methods used This study was a retrospective chart review of patients ages 2–17 treated at a paediatric ED with a diagnosis of asthma between July 1, 2012 and June 30, 2013. CAS scores were obtained for patients twice: upon presentation to the ED and at the time of disposition. The CAS is rated on an evenly distributed scale of 0–12. Student's t-tests were performed to evaluate the relationships between CAS and age, gender, or race. Linear regression was used to analyse the relationship between patients' CAS and length of stay. Student's t-tests were conducted to analyse the association between patients' CAS and disposition.

Summary of results A total of 608 visits from 499 patient charts were analysed. The CAS was not significantly impacted by age, gender, or race ($p > 0.05$). A higher CAS, regardless of whether it was evaluated at presentation or disposition, correlated to a longer length of stay ($p < 0.0001$). A patient's disposition also correlated to their CAS. Patients that were discharged had the lowest CAS scores on average (Presentation CAS=4.1, CI: 3.8 to 4.3; Disposition CAS=1.4, CI: 1.2 to 1.5), while those that went to the PICU had the highest CAS scores on average (Presentation CAS=8.2, CI: 7.7 to 8.7; Disposition CAS=6.9, CI: 6.5 to 7.3) and those patients admitted to the floor had, on average, a CAS in between (Presentation CAS=6.0, CI: 5.7 to 6.4; Disposition CAS=3.2, CI: 3.0 to 3.5) ($p < 0.0001$).

Conclusions The CAS is significantly correlated with both length of stay and disposition of patients. A higher CAS score predicts both a longer length of stay and a more acute disposition. Future work developing an algorithm inclusive of the CAS to evaluate patients for appropriate disposition including the use of an observation unit for paediatric asthma patients is planned.

55 TESTING TEENS FOR HIV – ARE WE DOING WHAT WE SHOULD?

^{1,2*}J Fernelius, ^{1,2}K Migacz, ^{1,2}A Srinivasan, ^{1,2}C Bell, ^{1,2}L Benjamins. ¹UTHealth, Houston, TX; ²McGovern Medical School, Houston, TX

10.1136/jim-2017-000697.55

Purpose of study Globally, nearly 25% of patients with HIV are 10–24 years old. In 2015, about 51% of the 61,000 HIV infected youth ages 13–24 in the U.S. were unaware of their status. Although CDC (2006), AAP (2011), and USPSTF (2013) guidelines recommend routine testing of adolescent patients, little is known about how often physicians screen for HIV per these standards. Thus, we set out to assess the prevalence of HIV testing among adolescent patients and to compare rates of testing from 2010 to 2015 in our practice.

Methods used After IRB approval, we conducted a retrospective chart review of patients aged 13–18 seen in general paediatric and adolescent outpatient clinics in a large university-based setting. Whether or not a teen was tested for HIV at these visits was the primary outcome. Additional variables included sexual history, reported condom use and HPV vaccine status. Descriptive statistics were performed.

Summary of results To date, 473 charts have been reviewed. Mean patient age was 14.9 (14.6 in paediatrics, 16 in adolescent), 49.9% were female, 67.2% African American and 16.0% Hispanic. In 2010, 7.6% of patients were tested for HIV in the paediatric clinics, 34.3% in adolescent. In 2015, rates were 6.3% and 38.2% for paediatric and adolescent clinics respectively. Of the 63 patients tested for HIV, the average age was 16. In this group, 63.5% reported sexual activity, 20.6% reported unprotected sex, 44.4% had used a condom at their last sexual encounter, and 46.0% had received at least one HPV vaccine. Among patients not tested for HIV, 15.9% reported sexual activity, however, for 28% sexual activity was not assessed.

Conclusions Overall testing rates for HIV were similar in 2010 and 2015. Teens were more likely to be tested in the adolescent clinics, however, these patients were also older. Teens who reported sexual activity were also more likely to be tested. This study provides important information on how often teens were tested within this population, but may not be generalizable to other settings. Thus, similar studies in other practice settings to determine how and when physicians decide to test for HIV will be crucial. Understanding this is important for the future design and implementation of interventions directed towards routine, non-risk based screening.

56 BRUISED BUTTOCKS: IS IT ABUSE?

JP George*, R Brown, K Morgan. *University of Oklahoma Health Science Centre, Oklahoma City, OK*

10.1136/jim-2017-000697.56

Case report Bruising is the most common evident injury in children who have been physically abused¹. Moreover, certain locations of bruising are more consistent with physical abuse. For example, in children younger than 4 years, and back, buttocks, forearm, foot and abdomen are rarely bruised from day to day activities². Here we discuss a 7 month old child who presented with bruised buttocks and was diagnosed with Acute haemorrhagic oedema of infancy (AHEI)

K.H. is a 7-month-old male who presented with bruised buttock that mother noticed when giving the child a bath. The mother states that the child had fallen asleep on a hard-plastic swing, had a low height fall onto the floor from the family sofa 3 days prior, and had been increasingly fussy.

Physical exam shows a well appearing, afebrile, non-toxic child who is noted to have a grossly benign exam except for a nontender 3 cm circular purpuric patch on the left buttock and a similar 3×2 cm patch on the right buttock with extension down the right thigh laterally. Given the vague history provided by the mother our child abuse service was consulted and agreed a non-accidental trauma work up was warranted. The work up included labs, a computerised tomography scan of the head, a skeletal survey and ophthalmological evaluation. The work up was negative except for an elevated d-dimer,

which would be expected with the presence of bruising seen. Consequential, the diagnosis of AHEI was made. Child was discharge home and was followed to note complete resolution of bruising without other complications and no other situation concerns for abuse.

Acute haemorrhagic oedema of infancy (AHEI) is a rare cutaneous illness that affects children between the ages of 4 months and 2 years of age and is classically thought of as a purely cutaneous form of Henloch-Schonlein Purpura³. AHEI has classically been characterised with a triad fever, purpuric lesions and oedema which can yield the physician to be faced with a wide differential⁴, however in the absence of a fever and often an unclear history non-accidental trauma must also be considered and can often pose a diagnostic challenge given that bruising patterns associated with AHEI are not often associated childhood activities.

57 IMPROVING SCREENING AND REFERRAL FOR POSTPARTUM DEPRESSION IN A PAEDIATRIC PRIMARY CARE CLINIC

AL Hoppmann*, M Silverberg, B Ratliff, S Hall, S Walley, C Dye. *University of Alabama at Birmingham, Birmingham, AL*

10.1136/jim-2017-000697.57

Purpose of study Postpartum depression (PPD) has been shown to impact maternal-child bonding and infant development. As PPD is often under-recognised and undertreated, our aims included increasing paediatric resident knowledge and comfort of screening a mother for postpartum depression by 30% and referring 50% of positively screened mothers for depression counselling.

Methods used We implemented a resident-driven quality improvement project at the University of Alabama at Birmingham (UAB) Paediatric Primary Care Clinic (Clinic) with partnership with the UAB Community Counselling Centre. Residents had an educational curriculum which included PPD and a new screening/referral process over a 1 week period in Clinic. Maternal depression was evaluated using the Edinburgh Postnatal Depression Scale at the 1 month – 6 month well child check appointments, while resident knowledge was evaluated via online survey collected pre and post educational intervention. Mothers who screened positive for PPD were referred. Strategies included process mapping and collaborative intervention planning with clinic faculty and support staff. Data was compiled and analysed using Microsoft Excel.

Summary of results Fourty-six residents completed the survey prior to intervention while 36 residents completed the post-survey. Following the educational intervention, the proportion of residents who knew how to screen for PPD increased by 30%, while the proportion of residents who felt comfortable screening and referring mothers with PPD increased by >50%. Of the 35 mothers who screened positive for PPD, 17 (49%) were referred for counselling and 3 (15%) mothers attended an initial counselling session.

Conclusions A clinic based educational curriculum improved resident knowledge and comfort of maternal screening/referral for PPD. While almost one-half of mothers who screened positive for PPD were referred for counselling, only a small proportion attended. Future aims include determining alternative strategies to assist mothers with PPD.

58 AN UNSUSUAL CAUSE OF HIP PAIN IN A YOUNG GIRL

MN Frascogna, B Dillard, E Landry*. *University of Mississippi Medical Centre, Jackson, MS*

10.1136/jim-2017-000697.58

Case report Hip pain is a common complaint evaluated and treated in the Paediatric Emergency Department. Even though musculoskeletal causes are the most common, practitioners must keep a broad differential diagnosis list in mind, including pain referred from nearby structures. We present a case of hip pain in a young girl with an unusual cause.

A 5 year old female presented to the paediatric emergency department (PED) with a complaint of recurrent left hip pain that started approximately 3–4 months prior to her presentation. The pain occurred infrequently and typically would resolve when treated at home with ibuprofen. She had been worked up for this complaint by her primary care physician and by a local orthopaedic surgeon with lab work and imaging reported by the patient's mother to be normal. Prior to evaluation in the PED, she began to have worsening left hip pain and vomiting. On exam, she was afebrile, had no abdominal tenderness, and had full range of motion of her hips with no gait abnormalities. She reported pain to palpation of her left lower flank above her hip. An abdominal X-ray was performed showing moderate stool in the distal colon but no signs of obstruction or mass effect. A complete blood count, metabolic panel, and urinalysis were obtained and were noted to be unremarkable. She was given a normal saline bolus and morphine with improvement, but not resolution, of her pain. An abdominal CT was performed and showed a pelvic mass in the area of the left ovary. A pelvic ultrasound was obtained and showed no definite vascular flow within the left ovary, leading to a diagnosis of left ovarian torsion with ischemia. The paediatric surgery service was consulted and she was taken to the operating room where an exploratory laparotomy was performed with detorsion and left oophoropexy. She was monitored post-procedure and was discharged home three days after admission in good condition.

Ovarian torsion can be difficult to diagnosis, especially as it can be intermittent. Though it is much more common in reproductive aged girls, ovarian torsion should be kept on the differential in all females with unilateral abdominal, back, or hip pain.

59 EXPLORATORY STUDY ON DISCUSSION OF TRANSITION OF CARE FOR ADOLESCENTS DURING WELL CHILD CHECKS

S Leung*, S Mennito. *Medical University of South Carolina, Charleston, SC*

10.1136/jim-2017-000697.59

Purpose of study Despite guidelines on transitioning paediatric patients to adult care, many young adults do not receive appropriate preventative care resulting in emergency department overuse, high medical costs, and low adult vaccination rates. A core factor is whether transitional care discussions occur between medical providers and patients. This study evaluated whether transition discussions are held during adolescent well child checks (WCC) and if teen health status impacts the likelihood of those conversations occurring.

Methods used We identified adolescents ages 15 and up seen in a resident continuity clinic for a well check between

January 2015 and January 2016 and categorised them as being 'overall healthy' or 'medically complex' based on pre-set criteria. We reviewed charts for transitional discussion key words or for the use of an electronic medical record (EMR) transition template developed locally for teen WCC. Two-tailed Z-test was used for two statistical analyses: at the subject level, $n=100$, and at the visit level of each well child check, $n=161$.

Summary of results A total of 432 subjects were identified of whom 100 were randomly selected for review. Patients were 59% female and 65% overall healthy when seen between 2013 and 2017, ages 15–18 years old. At the subject level, transitional discussions occurred for 60% of medically complex teens compared to 49% of overall healthy teens ($p=0.3$; Z-score of 1.02). At the visit level, a transitional discussion occurred at 45% of WCC for medically complex teens compared to 33% of WCC for overall healthy teens ($p=0.14$; Z-score of 1.4). No documentation of transition discussions occurred without the use of the EMR template.

Conclusions Despite transition EMR template availability, transition of care topics are not consistently documented for any adolescent, healthy or otherwise. Use of a template encouraged documentation of transition discussions. Sports physicals and sick visits, which utilise separate EMR templates, may be missed opportunities. Additionally, transition of care topics are at the end of the WCC template, which may limit its use during visits with numerous topics to cover. Adjustment of the available template and further education to encourage earlier and more frequent talks about transition may improve rates of those discussions.

60 IMPACT OF MULTIDISCIPLINARY MANAGEMENT ON COMORBIDITIES OF PAEDIATRIC OBESITY

AN Metcalf*, AE Weedn, S Gillaspay. *University of Oklahoma Health Sciences Centre, Oklahoma City, OK*

10.1136/jim-2017-000697.60

Purpose of study 17% of US children ages 2–19 are obese, and at risk for dyslipidemia, type 2 diabetes, and non-alcoholic fatty liver disease. The United States Preventive Services Task Force recommends multidisciplinary management, which has been shown to stabilise body mass index (BMI), but studies on the impact of this treatment on obesity comorbidities are limited. This study examined the effect of a paediatric multidisciplinary weight management clinic on targeted cardio-metabolic markers of health.

Methods used Participants 2–18 years of age presented to the Healthy Futures Clinic from August 2012 to October 2016 and had a BMI ≥ 99 th percentile or a BMI ≥ 95 th percentile with an obesity-related comorbidity. Patients and families received behavioural counselling from a paediatrician, dietitian, physical therapist, and psychologist at an initial visit and every 3 months, with individualised follow-up visits in the interim. BMI, fasting cholesterol, triglycerides, HDL, LDL, glucose, ALT, and haemoglobin A1c were obtained at baseline and at 6 months. Changes in BMI and lab values were analysed continuously by paired t-tests and categorically (abnormal vs normal results) by McNemar's Test.

Summary of results 138 participants presented to the clinic; 63% were female and 61% were between 6 and 12 years of age. At baseline, 43.8% had abnormal ALT levels, 43.8% had

elevated triglyceride levels, and 34.1% had high cholesterol. Among patients still participating in the clinic at 6 months (n=78), total cholesterol improved by an average of 6 mg/dL (p<0.05), and triglycerides improved by an average of 14.6 mg/dL (p<0.05). Of these patients (n=78), 32.0% had hypercholesterolemia at baseline, which improved to 19.2% after six months of treatment. Similarly, 39.7% of returning patients (n=78) had abnormal triglyceride levels at baseline, which was reduced to 25.6% at six months. Glucose, HDL, LDL, and ALT also improved at six months but no significant difference was demonstrated. These improvements occurred despite a lack of change in BMI with treatment.

Conclusions Six months of multidisciplinary clinical intervention improved dyslipidemia in obese children, and these improvements occurred without change in BMI. Future studies will examine treatment effect at 12 months.

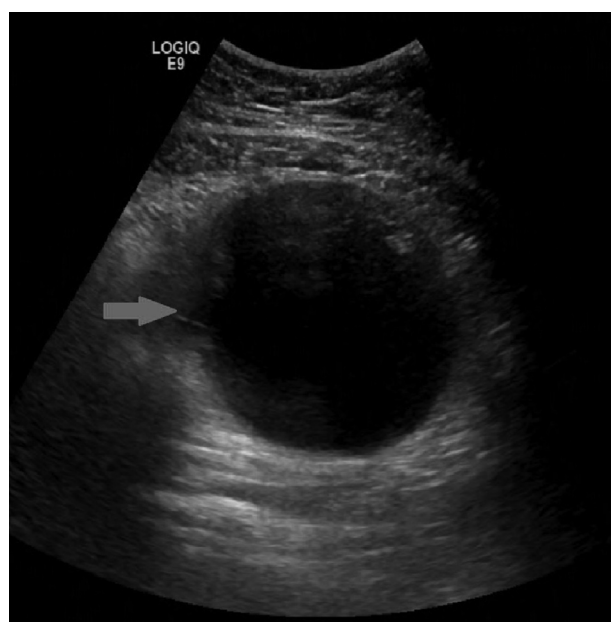
61 ABDOMINAL MASS(ES) IN A PAEDIATRIC PATIENT

Y Nathani*, J George, C Knoles. *University of Oklahoma, Oklahoma City, OK*

10.1136/jim-2017-000697.61

Case report D.J. – an obese 10-year-old premenarchal female presented with worsening RLQ abdominal pain with nausea and vomiting. ROS negative for fever, jaundice, weight loss, trauma. Initial VS were normal and exam was only impressive for RLQ tenderness without peritonitis. Ultrasound showed a 9×9×10 cm complex anechoic structure right pelvis with normal blood flow (figure 1) and a mass in RUQ. Subsequent CT scan showed a 5 cm solid, well circumscribed mass in liver (figure 2) in addition to complex mass in pelvis. Labs were normal and HCG was negative. Due to progressive symptoms, she underwent a laparoscopic right salpingectomy for paratubal cyst torsion with normal viable ovary. The liver mass was determined to be focal nodular hyperplasia (FNH).

This was diagnostically challenging as the patient had two distinct masses with progressive symptoms. Possible etiologies



Abstract 61 Figure 1 Ultrasound showing complex mass in right adenexa

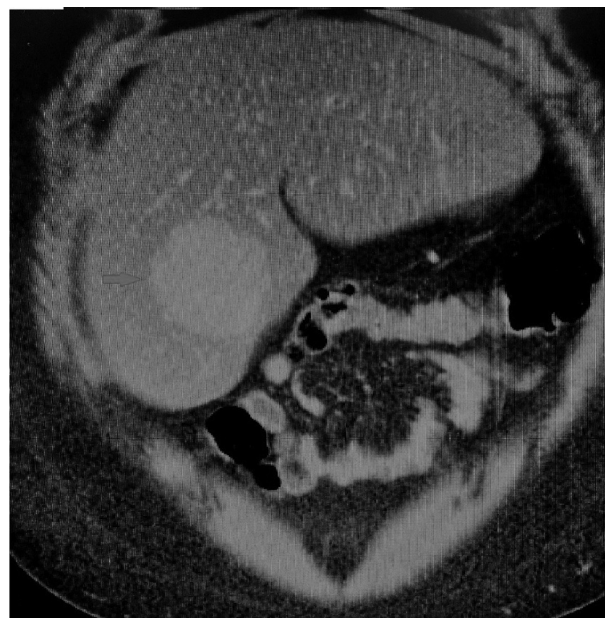included ovarian or tubal cyst, primary ovarian/hepatic tumours, metastases, abscess, ovarian/tubal torsion and ectopic pregnancy.

Paratubal cysts are remnants of Wolffian and Mullerian ducts and constitute 3%–7% of adenexal masses in paediatric patients.¹ Increasing size of paratubal cysts are associated with obesity, likely due to excess androgens. Most are asymptomatic; however, they can present with abdominal pain due to haemorrhage, rupture and torsion. These cysts are non-physiologic and unlikely to spontaneously regress and definitive management is operative.

FNH is generally a benign and asymptomatic lesion of the liver, usually discovered incidentally. These lesions are associated with high oestrogen states, including obesity and require surgical intervention only if symptomatic.

REFERENCE

1. Muolokwu E, Sanchez J, *et al.* The incidence and surgical management of paratubal cysts in paediatric and adolescent population. *J Pediatr Surg* 2011;**46**:2161–2163.



Abstract 61 Figure 2 CT scan showing liver mass

62 INPATIENT BREASTFEEDING STUDY: WHAT ARE THE BARRIERS TO INPATIENT BREASTFEEDING EXCLUSIVITY?

¹E Omoruyi*, ¹MS Evangelista, ²TA Sugañes. ¹University of Texas Health Science Centre at Houston, Houston, TX; ²New York-Presbyterian/Weill Cornell, New York, NY

10.1136/jim-2017-000697.62

Purpose of study Breastfeeding is widely accepted as the best nutritional source for infants. In the United States, exclusive breastfeeding is recommended until at least 6 months of age. Although breastfeeding has been shown to have beneficial effects, studies have shown that problems and emotional discomfort experienced during early breastfeeding are risk factors for breastfeeding cessation before 6 months. Determining why mothers are unable to achieve breastfeeding exclusivity in the immediate postpartum period is important to the creation of targeted interventions.

Methods used This cohort study enrolled 510 women who were each personally interviewed using a survey tool during the immediate post-partum period in an urban county hospital. Factors assessed included breastfeeding history, perceptions regarding breastfeeding/breastmilk, socioeconomic factors, as well as hospital and family support. Breastfeeding exclusivity at discharge was assessed based on the mothers' self-reported infant feeding behaviour during her hospital stay.

Summary of results 38% of women exclusively breastfed during their inpatient stay. Several maternal, hospital, and external factors influence exclusive breastfeeding in a hospital. While the knowledge and experience of breastfeeding other children is a determining factor (OR=3.33; 95% CI: 1.01 to 11.04), several hospital factors such as skin to skin contact, knowledge about whom to approach and ask about breastfeeding help after discharge, and encountering issues in hospital are responsible for encouraging the behaviour of exclusive breastfeeding in a hospital ($p<0.05$).

Conclusions This study highlights that knowledge regarding breastfeeding as well as knowledge regarding sources of support, both inpatient and outpatient, are important factors that affect immediate breastfeeding outcome. This is one of the few studies that looks at specific factors affecting exclusive breastfeeding in the inpatient setting.

63 BREASTFEEDING DURATION AND BONE STRENGTH IN YOUNG ADULT FEMALES

K Perofsky*, NK Pollock. *Augusta University, Augusta, GA*

10.1136/jim-2017-000697.63

Introduction Data on the relationship between breastfeeding and bone health are scant and equivocal. This study investigated the relationships between breastfeeding duration and indices of bone strength in young adult females.

Methods Bone mass, density, and geometry at trabecular and cortical sites of the tibia were measured in 71 white females (aged 21 ± 0.4 years) by using peripheral quantitative computed tomography. Breastfeeding duration was self-reported by each participant's biological mother. Fat-free soft tissue (FFST) and fat mass were measured using dual-energy X-ray absorptiometry. Relationships between breastfeeding duration and bone parameters was determined using multiple linear regression models, including height, FFST, and fat mass as covariates.

Summary of results 20% of the participants reported not having been breastfed; 32% were breastfed 1–6 months; 24% were breastfed 6–12 months; and 24% were breastfed 12 months or longer. At the trabecular site of the tibia, breastfeeding duration was a positive independent predictor of total volumetric bone mineral density ($\beta=0.28$, $p=0.045$). Although breastfeeding duration was positively correlated to bone strength index (BSI; $r=0.28$, $p=0.03$), it was not an independent predictor of BSI in the regression model. At the cortical site, breastfeeding duration was a positive independent predictor of bone mineral content ($\beta=0.24$, $p=0.02$), cross-sectional area ($\beta=0.23$, $p=0.02$), and cortical thickness ($\beta=0.36$, $p<0.01$). There were no associations between breastfeeding duration and the other bone parameters.

Conclusions Our results suggest that a greater duration of breastfeeding may have long-term benefits on cortical and trabecular bone. Given that our findings should be considered

hypothesis generating, further studies are needed to elucidate the role of breastfeeding on bone development.

64 INAPPROPRIATE PRESCRIBING OF SYSTEMIC STEROIDS AND OPIOIDS TO PAEDIATRIC PATIENTS WITH PNEUMONIA OR SINUSITIS

¹KG Phang*, ¹J Roberts, ²S Garner, ¹M Ebeling, ¹W Basco. ¹*Medical University of South Carolina, Charleston, SC*; ²*South Carolina College of Pharmacy, Charleston, SC*

10.1136/jim-2017-000697.64

Purpose of study National clinical guidelines do not recommend use of systemic steroids or opioids in treating paediatric pneumonia or sinusitis. The purpose of the study was to compare the frequency of systemic steroid or opioid prescribing for children with pneumonia and sinusitis based on location of care. We tested the hypothesis that inappropriate prescribing of systemic steroids and opioids for paediatric pneumonia or sinusitis was greater in the emergency department than other clinical sites.

Methods used The study evaluated paid claims for visits and medications using 2016 South Carolina Medicaid data. Subjects were 5 to 18 years old with a primary diagnosis of pneumonia or sinusitis, selected using the ICD-9 and ICD-10 Clinical Classification Software Category System. The prescription of a systemic steroid or an opioid dispensed 0–7 days from a visit claim was evaluated. Medicaid visits were associated with one of 3 locations: emergency department (ED), urgent care (UC), or ambulatory site. Patient demographic data available included ethnicity, gender and age in months.

Summary of results A total of 16 480 visits were evaluated from all 3 settings. Of 2153 visits in the ED 273 (13%) included a systemic steroid and 98 (5%) included an opioid. Of 14 149 visits in the ambulatory setting 974 (7%) included a systemic steroid and 376 (3%) included an opioid. Of 178 visits in the UC 15 (8%) included a steroid. Too few patients were prescribed an opioid in the urgent care setting to perform statistical analysis. ED visits were associated with a higher steroid prescription rate (chi square, $p<0.0001$) when compared to ambulatory and UC visits. ED visits were associated with a higher opioid prescription rate (chi square, $p<0.0001$) when compared to ambulatory visits.

Conclusions Our results suggest that school age children and adolescents received steroid and opioid prescriptions at higher frequency when seen in the ED versus ambulatory setting. Given safety concerns of steroids and opioids in paediatric patients, improved prescribing practices for these medications are needed.

65 KNOWLEDGE OF AND ATTITUDES TOWARD HPV VACCINE IN PREADOLESCENTS AND TEENS

L Raney*, E Owers, R Pasternak, P Prasad, R Gardner. *LSUHSC, New Orleans, LA*

10.1136/jim-2017-000697.65

Purpose of study Human Papilloma Virus (HPV), common in both females and males, is responsible for pathologies ranging from benign genital warts to cervical and penile cancer. Pharmaceutical companies have now developed a vaccine that will help prevent the virus-associated malignancies. The CDC recommends that females ages 11–26 years and males ages 11–

21 years receive the vaccine series. Despite being widely available and highly publicised, only 40% of eligible females receive the vaccine. This study aims to assess the knowledge of HPV, the attitudes towards the HPV vaccine, and identify barriers preventing full utilisation of the vaccine. Once identified, we aim to overcome the barrier(s) and improve vaccination rates in eligible adolescents.

Methods used We distributed a standardised questionnaire to the parents of eligible female and male patients in both paediatric hematology-oncology and general paediatric clinics. It assessed the parents' knowledge of HPV and the vaccine, their views of the vaccine, and reasons why they may oppose it. Additionally, we will compare the views of parents between these two settings, in order to determine if the patient's personal history of a hematologic or oncologic disease influences their decision to permit vaccination.

Summary of results 75% of parents say they have been educated about HPV, mostly by their primary care physician. However, only 25% knew what disorders HPV caused. Only 40% felt the vaccine should be added to the typical vaccine schedule. Surprisingly, eighty percent of parents intend to or already have vaccinated their child. In those that opposed the vaccine, one-third were concerned about potential side effects and nearly 20% feel they do not have enough information.

Conclusions The largest barrier to the utilisation of the HPV vaccine that we have identified appears to be lack of education. As a result, we have begun distributing the CDC's HPV and vaccine patient guide to our patients' families as an intervention. We will resurvey these families after implementing the intervention to assess its success in increasing both knowledge and utilisation of the HPV vaccine.

66 SEPARATING FACT FROM FICTION: DIAGNOSING FUNCTIONAL NEUROLOGICAL DISORDER

HA Rehman*, S DeLeon, D Hahn. *OUHSC, Oklahoma City, OK*

10.1136/jim-2017-000697.66

Case report Patient is a 13 year old girl with a history of complex regional pain syndrome who presented with new onset visual changes and severe headaches. Ophthalmologic exam showed bilateral optic disc cupping, lumbar puncture (LP) revealed a mildly elevated opening pressure and magnetic resonance imaging (MRI) revealed bulging optic discs; she was admitted for presumed idiopathic intracranial hypertension (IIH). Multiple therapeutic LPs resulted in mild headache relief with no improvement in vision. An intracranial pressure monitor showed normal pressure, ruling out IIH. A comprehensive autoimmune, endocrine and infectious work-up was negative. She later reported back pain and spine MRI noted L1-L2 discitis osteomyelitis of unclear aetiology. She received extensive treatment with steroids, a selective serotonin reuptake inhibitor, a carbonic anhydrase inhibitor and several pain medications.

After 6 weeks with no definitive diagnosis, she was transferred to our facility per parent request. Multiple specialists were consulted including neurology, ophthalmology, psychology, infectious disease, physical therapy (PT), pain management and neurosurgery. She had various complaints including persistent headaches, changes in visual acuity and fields, and weakness and numbness of her left extremities. Her exam, however, remained inconsistent and all symptoms except for

headache and vision changes spontaneously resolved. Repeat MRIs and ophthalmology exam revealed normal orbits with resolution of disc cupping. Given persistent complaints with normal exams and studies, she was diagnosed with functional neurologic disorder (FND) in addition to lumbar osteomyelitis and discitis. She worked with psychology and PT and was transferred to a rehab facility specialising in the disease process. Though potential stressors were identified, these were never fully accepted as the aetiology by the patient or family.

FND, previously known as conversion disorder, is manifested by neurologic symptoms that cannot be explained by an underlying disease pathology. Patients experience motor, visual, speech or sensory changes believed to be triggered by an emotional or physical stressor. Treatment involves a multidisciplinary approach with therapy and often medication. Early diagnosis is key to prevent unnecessary testing that can lead to a poorer prognosis.

67 ACUTE DISSEMINATED ENCEPHALOMYELITIS IN A SIX YEAR OLD MALE PRESENTING AS UNILATERAL OPTIC NEURITIS

AR Riggs*, D Hahn. *Oklahoma Health Sciences Centre, Oklahoma City, OK*

10.1136/jim-2017-000697.67

Case report Our patient is a previously healthy 6 year old male who presented with a ten day history of intermittent nausea and vomiting, fluctuating periods of hyperactivity and fatigue, as well as acute onset loss of colour vision, decreased visual acuity, and appearance of scotomata in his right vision field. The patient's primary care physician referred him to an Ophthalmologist, who noted right optic nerve swelling. The patient was then transferred to our Emergency Room, where a thorough initial lab workup yielded only mild leukocytosis on a blood sample. The only pertinent physical exam finding was fatigue. A brain Magnetic Resonance Imaging (MRI) was obtained to evaluate for optic neuritis. The MRI revealed global involvement of the brain with diffuse white matter lesions predominantly in bilateral cerebral hemispheres. These findings steered us to a diagnosis of Acute Disseminated Encephalomyelitis (ADEM). We treated our patient with a five day course of high dose steroids. Within days, the child responded with symptomatic improvement. At a one month follow up, he continued to have improvement in his visual problems.

While ADEM has certainly been well-documented in children in our patient's age group, his clinical presentation did not initially suggest the severity of the brain involvement found on MRI. Vacillating fatigue and hyperactivity paired with unilateral optic neuritis made for an unusual and unique presentation of ADEM.

68 HEMATEMESIS AND HEMATURIA IN A HEALTHY 3 MONTH OLD MALE

AR Riggs*, D Hahn. *Oklahoma Health Sciences Centre, Oklahoma City, OK*

10.1136/jim-2017-000697.68

Case report Our patient is a previously healthy 3 month old male who presented to our Emergency Department with a report of poor oral intake, decreased urine output, hematemesis, and hematuria. The initial lab work-up was unremarkable with the

exception of microscopic hematuria in a bagged urine. We admitted the child for further evaluation of the hematuria. Due to concern for formula intolerance and reflux causing his hematemesis, his formula was switched to Nutramigen and he was started on a trial of Omeprazole. The child failed to respond to our interventions and continued to have guaiac positive hematemesis. An esophagogastroduodenoscopy was performed, which showed no evidence of bleeding or ulcer. While repeat bag urine specimens continued to show microscopic hematuria, an in-and-out catheterization specimen surprisingly showed no red blood cells. At this time, multiple team members noted that patient only had positive findings when his mother was alone with the child, but never had positive findings when in care of nursing alone. When we confronted our patient's mother with our observations, she soon admitted to contaminating the child's stool, emesis, and urine with her own menstrual. The mother further confessed that she created the ruse in order to keep her son hospitalised so they would both be safe from the patient's father. At this point, we contacted our Child Maltreatment, and the Department of Human Services was notified for concern for Medical Child Abuse.

Medical Child Abuse, also known as Munchausen Syndrome by Proxy, is an unfortunately common condition seen in the paediatric population. The simulation of symptoms can result in procedures and hospitalizations that are not necessary and are potentially harmful, as seen in our patient. Although it is difficult to recognise and confront medical child abuse, it is invaluable to do so early in order to protect patients from unnecessary discomfort and harm.

69 ARM PAIN AMONG SOUTH CAROLINA YOUTH BASEBALL PLAYERS

J Roberts*, M Rao, E O'Brien, A Greenhouse, E Dawley, J Eichinger. *Medical University of South Carolina, Charleston, SC*

10.1136/jim-2017-000697.69

Purpose of study Arm and shoulder injury to young athletes is increasing in the United States, especially among baseball pitchers. Although pitch count limitations have been implemented in youth league baseball, the need for ulnar collateral ligament reconstruction is increasing at a younger age, with 56% of these procedures being performed on 15–19 year olds. The objective of this study is to describe the injury burden to young athletes in South Carolina where baseball and softball are played year round.

Methods used We asked parents who brought their 7–17 year old child to any visit to one of 13 South Carolina Paediatric Practice Research Network (SCPPRN) practices to complete a survey. Initial questions included the age of the child, position (s) played, injuries and past surgeries. Examples of throwing-specific questions included timing and quality of arm pain, occurrence of pain or fatigue during games or practice, limitations of the pain in terms of participation or performance, and pressure to play through the pain. We also inquired about the number of months they play during the year, and interest in a pitch-tracking smart phone application. Questions were based on a previous study conducted in the Northeast for comparison. Descriptive statistics were calculated.

Summary of results To date, 131 parents have completed the survey. 35 (26.7%) reported a previous injury, and 3 (2.3%) reported having previous surgery. Responses of 'never' and 'rarely' were counted as responses in the negative, and

'sometimes', 'often', and 'always' were counted as responses in the affirmative. 34 (26.0%) report pain when they throw or play and 29 (22.1%) report that pain the day after playing. 7 (5.3%) reported that previous arm pain has negative effect on their enjoyment of the game. 9 (6.9%) report that a coach has encouraged him/her to keep playing despite the presence of arm pain. 81 (61.8%) of parents would be interested in having access to a pitch count app.

Conclusions Approximately one quarter of young athletes report the presence of arm pain while playing. The use of a smart phone app to track pitch counts may be a helpful tool to prevent overuse injury and should be tested in a cohort of youth baseball players.

70 ADOLESCENT WEIGHT MANAGEMENT – IS THERE AN APP FOR THAT?

C SanGiovanni*, M Steffen, C Pope, J Roberts. *Medical University of South Carolina, Charleston, SC*

10.1136/jim-2017-000697.70

Purpose of study Adolescent obesity has quadrupled in the past thirty years from 5% to 20.5% for 12–19 year olds. Paediatricians report lack of resources as a barrier to management. Since adolescent smartphone use has increased significantly and apps are useful in managing chronic diseases in adolescents, apps that assist with weight management could be a beneficial resource. However, little is known about features that overweight/obese adolescents have considered helpful. The objective of this study was to explore adolescents' preferences about weight management app features and willingness to use collaboratively with their healthcare provider.

Methods used Participants, recruited from an urban and rural practice in South Carolina, were eligible if between 13–17 years old, had a Body Mass Index (BMI) at or above the 85th percentile and had access to a smartphone or tablet. Semi-structured interviews were conducted from May to October 2017. Participants were presented with 3 popular mobile health apps and asked to complete tasks using each app. Likes/dislikes about each app and which features (customised workouts, logging physical activity and food/beverage consumption, and social support) would encourage further use were elicited. Content analysis was performed on interview transcripts.

Summary of results Twelve adolescents were interviewed. Average participant age was 14.7 years, and average BMI was 96.6 percentile. Eight (67%) were female, and 8 (67%) identified as White, while the remainder identified as African American. The majority had used health apps in the past, but none were recommended by healthcare providers. All adolescents felt apps would be helpful in managing their weight. Adolescents' most favourable features were finding healthy food alternatives and customising their workouts. Additional features they would include in health apps were competing with friends to exercise more or eat healthy, incentives to work toward healthy goals, sharing customised workouts with friends, creating a music playlist for exercising, and hearing weight loss success stories from other adolescents.

Conclusions Adolescents think health apps would be helpful in weight management. The use of apps should be studied to determine their role as part of an effective weight management program.

71 KAWASAKI DISEASE OUTBREAK IN CENTRAL APPALACHIA

VP Smith*, D Macariola, JW Schweitzer. *ETSU, Johnson City, TN*

10.1136/jim-2017-000697.71

Purpose of study In the US, Kawasaki Disease (KD) has a global hospitalisation rate of 17.1 per 1 00 000 children. Although the aetiology remains unknown, the current consensus is that KD is likely caused by an infectious trigger initiating an abnormal immune response in genetically predisposed children. In March of 2017, Central Appalachia had an outbreak of KD, with 4 patients concurrently hospitalised with this disease. It is unclear whether this outbreak was due to the genetic susceptibility of the Appalachian population, or exposure to an antigen which was particularly toxic. This study seeks to better understand the underlying genetic predisposition and pathogen antigenicity related to KD in the Appalachian region.

Methods used All data was collected via chart review and retrospective study. Subjects were all admitted to the hospital within 1 week of each other and presented with fever prior to admission. During their admission, each subject was diagnosed with KD. All patients were followed for sequelae in the outpatient setting.

Summary of results Table 1 summarises the data during each subject's hospitalisation. All subjects met criteria for KD while in the hospital. All subjects were treated with IVIG and had resolution of fever. The mortality associated with all subjects was 0%. No subjects had long-term sequelae.

Conclusions The Appalachian population may be more susceptible to KD, however, a larger chart review of incidence of KD in the region for multiple years would be necessary to draw these conclusions. It is much more likely that there was a highly antigenic pathogen present in the population in early spring 2017 that increased the incidence of this outbreak. Although a small sample size was used, the study's incidence was dramatically increased from the US incidence when considered on a monthly basis. Public health officials and providers should be aware that the Appalachian region may be more genetically susceptible to outbreaks of KD, or be exposed to pathogens with increased antigenicity, and thus have a lower index of suspicion for diagnosis of KD when multiple cases occur in relative proximity to one another.

72 PERSISTENT HYPERGLYCEMIA SECONDARY TO SECOND-GENERATION ANTIPSYCHOTIC MEDICATIONS

N Soulages Arrese*, AB Middleman, JD Meyer. *University of Oklahoma Health Sciences Centre, Oklahoma City, OK*

10.1136/jim-2017-000697.72

Case report It has been shown in the literature that second-generation antipsychotics are associated with patients developing hyperglycemia and diabetes mellitus along with other metabolic changes such as weight gain and lipid profile abnormalities. This reports highlights a case of a paediatric patient with hyperglycemia while taking second-generation antipsychotics in the setting of a complex social situation and weight loss. C.K. is a 16 year old with a history of family dysfunction, depression, suicidal behaviours, and cognitive delay and prolonged psychiatric admissions. She presented at age thirteen to endocrine clinic with hyperglycemia, impaired

Abstract 71 Table 1 Summarises the data during each subject's hospitalisation

Patient	Age	Gender	Days of fever before hospitalisation	Ophthalmic changes	Oral mucosal changes	Rash	Changes of hands and feet	Cervical lymphadenopathy	GI symptoms	Leukocytosis	Neutrophilia	Hypoalbuminemia	Elevated LFTs	ESR	CRP	Coronary abnormalities	Recent illness
A	4 year	M	6 day history	+	+	+	+	+	+	+	+	+	.	+	+	.	.
B	2 year	M	11 day history	+	+	+	+	+	.	+	.	+	.	+	+	+	.
C	11 mo	F	10 day history	+	+	+	+	+	+	+	+	+	.	No ESR drawn	+	+	+
D	3 year	M	5 day history	+	+	+	+	+	+	+	+	+	.	+	+	+	.

fasting glucose, normal HgbA1c while taking quetiapine. Approximately 1.3 years later, 1 year prior to presenting to our service, the patient developed polyuria, polydipsia, hyperglycemia, elevated HgbA1c of 9.2%, without diabetic ketoacidosis, and BMI 19.7. The patient had recently been switched from quetiapine to olanzapine. Antibodies associated with Type 1 Diabetes Mellitus were negative. The patient was treated with an intensive insulin regimen including long and rapid acting insulin. At presentation to our service, an inpatient service for malnutrition, the patient had severe malnutrition, BMI of 15.3 and HgbA1c of 5.7%. The mother had discontinued insulin when the patient had stopped eating. The patient indicated that she had been too tired to eat. The mother reported she was giving the patient additional olanzapine 'as needed'. Genetic testing for Maturity-onset diabetes of the young was completed and results were negative. The patient was transitioned from olanzapine to risperidone, as it is associated with less risk of hyperglycemia. During treatment for malnutrition, glucose levels improved, requiring rare corrections with regular insulin. This case serves as a reminder of the importance of appropriate metabolic screening for paediatric patients, regardless of weight, before and during treatment with second-generation antipsychotics; the metabolic changes may cause significant and potentially irreversible morbidity.

73

DO CHILDREN SEEN IN THE EMERGENCY DEPARTMENT FOR SKIN AND SOFT TISSUE INFECTIONS WHO ARE ADMITTED TO THE INPATIENT SERVICE MEET CRITERIA FOR SEPSIS?

B Weaver*, D Nakayama, JJ Burns, B Weidner. *University of Florida, Pensacola, FL*

10.1136/jim-2017-000697.73

Purpose of study Admission of patients with skin and soft tissue infections (SSTI's) have increased as have hospital charges. The main treatment of these is incision and drainage (I and D) for abscesses which can take place as an outpatient or inpatient.

Systemic inflammatory response syndrome (SIRS) criteria include temperature, heart rate, breathing rate, and white blood cell count. A patient with positive SIRS criteria and source of infection qualifies as having sepsis, justifying admission.

The purpose of our investigation is to determine the frequency of positive SIRS criteria in patients admitted for SSTI management. We also wish to determine if SIRS criteria status correlated with positive blood cultures, resolution without I and D and if I and D was performed in the operating room OR.

Methods used A retrospective chart analysis was conducted on 203 patients admitted with SSTI's from the paediatric ED during 2011–2016. Charts were excluded if patients were repeat visitors for the current SSTI, outside hospital transfers, immunocompromised state, chronic debilitating illnesses, or if affected area was the face, mouth or inside the scrotum. Age, heart rate, respiratory rate, temperature, blood culture results, WBC, SIRS status (positive or negative), I and D status (required or not), and I and D setting were recorded (OR or not).

Summary of results Thirty-seven met criteria for study entry; mean age was 24.7 (STD 28.8) months.

59.5% patients met SIRS criteria; 40.5% did not.

Two patients had positive blood cultures. Both were contaminants.

72.7% of those who met SIRS criteria went to OR vs 53.3% who did not meet SIRS criteria. (Chi-square; $p=0.225$).

22.7% of patients who met SIRS criteria had SSTIs that resolved without I and D vs 40% with negative SIRS criteria (Fisher's Exact Test) 0.295.

Conclusions Most of the admitted patients with SSTIs met SIRS criteria, yet there were 40.5% who did not and may have therefore been unnecessary admissions.

This study supports previous studies that indicate that blood cultures are not useful in SSTI management.

SIRS status did not correlate with rate of resolution without I and D or need for OR I and D.

Studies with higher N are needed to confirm these findings.

Adult case reports/ageing/geriatrics

Joint plenary poster session and reception

4:30 PM

Thursday, February 22, 2018

74

SYNCOPE EVALUATION USING POINT-OF-CARE ULTRASOUND

EK Addo-Yobo*, J Treece, N Kakkar, V Pai, MA Alawoki, C Rosero. *Shamas, S, East Tennessee State University, Johnson City and Mountain Home, TN*

10.1136/jim-2017-000697.74

Case report While syncope represents a common presentation of cardiovascular compromise, it is rarely the first presenting symptom of a pulmonary embolism (PE). If syncope occurs, delay in therapy can quickly become fatal. We describe a complex presentation of syncope in which bedside point-of-care echocardiogram would have directed appropriate management of a PE.

Eighty seven year old male with no significant cardiac history presented with three syncopal episodes. There were no prodromal symptoms or evidence of seizure activity. Blood pressure of 76/42 mmHg and pulse of 118 bpm were recorded by paramedics. Electrocardiogram (EKG) showed atrial fibrillation with rapid ventricular rate. He presented hypoxemic and hypotensive. Labs showed serum troponin of 3.7 ng/mL and acute renal insufficiency. EKG showed no acute ischaemic changes. Head imaging showed no acute intracranial pathology.

Acute coronary syndrome protocol with heparin drip was initiated. The patient opted for medical management and was transitioned to apixaban for stroke prophylaxis. Transthoracic echocardiogram (TTE) showed characteristic signs of right heart strain. Chest angiogram showed a large central pulmonary embolus in the right lung with additional multifocal segmental bilaterally. Subsequent lower extremity ultrasound showed a deep vein thrombosis in the left lower extremity. Apixaban was continued since the patient was oxygenating well on nasal cannula and was hemodynamically stable.

Syncope is an uncommon presentation for PE. Even when an alternative reason for syncope exists, it is estimated that

PE is present in 12% of patients with syncope. Our patient presented with syncope in the setting of ACS, new onset atrial fibrillation and hypotension. The TTE showed the McConnell sign, a finding which has a 94% specificity for a PE. This sign is a pattern of right ventricular dysfunction with akinesia of the mid wall and hyper contractility of the apical wall. If bedside sonography was part of the initial encounter, the patient's presentation would have appropriately directed treatment towards thrombolysis or thrombectomy. It has been shown that prognosis for PE is best if treatment within the first hour. Prompt initiation of treatment is even more important because syncope is an ominous sign of PE.

75 INTRAVASCULAR LYMPHOMA PRESENTING AS RESPIRATORY FAILURE

A Bokhari*, D Trofimovitch, B Boonpheng, H Zaver, T Nold, J Goldstein. *ETSU, Johnson City, TN*

10.1136/jim-2017-000697.75

Case report Lymphoma, a great mimicker, presents with an array of signs and symptoms in almost any organ system. Here we present a case of acute respiratory failure in an otherwise healthy elderly man.

A 73-year-old man presented with four weeks of progressive dyspnea on exertion. He reported a non-productive cough, low-grade fevers, chills, and night sweats. He denied chest pain, weight loss, or lack of appetite and was hemodynamically stable on presentation. Physical examination was significant only for diffuse crackles and 2+ pitting ankle oedema bilaterally. Chest x-ray demonstrated bibasilar infiltrates, mild pleural effusion and cardiomegaly. Metabolic panel revealed hyponatremia (119 mEq/L) with high urine osmolality and Na, consistent with SIADH. Serum cortisol was normal; however TSH, free T4 and rT3 were compatible with central hypothyroidism. CBC was within normal limits. Initially he was on antibiotic therapy for presumed Community-Acquired Pneumonia. CT chest showed bibasilar atelectasis, bilateral pleural effusions, and no evidence of embolism. Multiple incidental calcified mediastinal lymph nodes were aspirated, with benign pathology. Patient underwent thoroscopic wedge lung biopsy; pathology indicated high-grade intravascular large B cell lymphoma positive for CD20, CD79a, Pax-5, CD10, Mum-1, and negative for CD3, cytokeratin AE1/AE3, S100, Cam5.2, and CD34. The lymph node histology was consistent with a remote granuloma. Gram stain, AFB, culture and fungal studies were negative. Bone marrow showed minimal presence of lymphoma. CT abdomen showed mild hepatosplenomegaly, a mildly enlarged epigastric lymph node, and no other intra-abdominal lymphadenopathy. The patient developed type 1 respiratory failure likely due to lymphangitis carcinomatosa, which improved with chemotherapy [R-CHOP].

Intravascular lymphoma is rare and aggressive. It was an unexpected diagnosis in our patient with predominant respiratory distress and pulmonary infiltrates. This subtype of lymphoma can manifest in any organ system and presents a diagnostic challenge given most information is from a paucity of case reports. Clinicians should maintain a high index of suspicion in high-risk patients presenting with an atypical constellation of symptoms.

76 DOUBLING DOWN ON ANAKINRA: A CASE OF RELAPSING STILL'S DISEASE

S Chalasani*, V Majithia, S Kishore. *University of Mississippi, Jackson, MS*

10.1136/jim-2017-000697.76

Case report Adult onset Still's disease (AOSD) is a rare systemic inflammatory disease of unknown aetiology characterised by fever, arthralgia, salmon-pink rash and leukocytosis. We present as classic case of AOSD who was refractory to treatment with high dose steroids and Anakinra.

A 21-year-old African American male with no past medical history presents with 1 month history of worsening joint pains and fever. 2 weeks prior to presentation, he had a diffuse scaly erythematous rash on his trunk and extremities. Fevers were as high as 104 °F responsive to Tylenol. Patient had similar symptoms 9 months ago that resolved with doxycycline and prednisone. On exam, he was ill appearing with fever of 100.3 °F. He had peeling macular rash involving trunk, arms and legs. He complained of pain with active and passive range of motion in all joints. Pertinent labs include: haemoglobin 7.1 g/dL, white blood cells 17.8 TH/cmm with 73% neutrophils, platelets 362 TH/cmm, aspartate transaminase 163 U/L, alanine transaminase 117 U/L, sedimentation rate of 104 mm/hr, C-reactive protein 21.4 mg/dL, Ferritin >100,000 ng/ml and elevated IL-2 receptor at 4090 pg/mL. Other rheumatological and infectious work up was negative. Imaging relieved hepatosplenomegaly and diffuse lymphadenopathy. Bone marrow biopsy ruled out malignancy and there was no evidence of hemophagocytosis. Patient was started on methylprednisolone 60 mg thrice daily and noticed significant clinical and serological improvement. He was later discharged on 60 mg prednisone. Follow-up at 2 weeks, he had clinically worsened requiring admission for pulse dose steroids. He was also started on Anakinra 100 mg daily. Four weeks into therapy with Anakinra, as the steroids were being tapered he had relapsed again. Therefore, the dose of Anakinra was doubled. Patient has been doing well on the current regimen. He is now undergoing slow taper of his steroids with recent addition of Methotrexate.

AOSD is considered an interleukin (IL)-1 or IL-6 and IL-18-driven disease. Treatment in severe disease requires high-dose steroids and IL-1 or IL-6 blockers. Anakinra is an IL-1 receptor antagonist used for treatment of AOSD at recommended dose of 100 mg daily. However, our patient's disease was not controlled on this recommended dose and required higher levels of Anakinra for stabilisation.

77 LATE RENAL MANIFESTATIONS OF HENOC-SCHOLEIN PURPURA IN ADULTS AND ITS RELATION TO IMMUNOGLOBULIN A NEPHROPATHY

SH El Nawaa*, A Shredi, H Edriss, P Laoveeravat. *TTUHSC, Lubbock, TX*

10.1136/jim-2017-000697.77

Introduction Henoch-Schonlein purpura (HSP) is the small vessel vasculitis primarily seen in children with self-limiting disease, however, it is rare in adults with annual incidence of 0.1–1.8 per 1 00 000 individuals. HSP can lead to severe complications with multi-organ involvement in adults in comparison to children. Kidney is one of major organs affected which can contribute to significant morbidity and mortality.

Case presentation A 41-year-old Caucasian male from Texas, with past medical history of well controlled hypertension, type 2 diabetes mellitus, gouty arthritis, alcoholism, and hyperlipidemia, presented to his primary care physician's office with complaints of severe colicky abdominal pain, nausea, vomiting, and an itchy purpuric skin lesion mainly on his lower extremities and the buttock area. Patient also had diffuse arthralgia, but denied having any bloody stools or gross hematuria. Labs were significant for mildly elevated liver enzymes and normal urinalysis. Metabolic profile showed a serum creatinine (0.66 mg/dl), and BUN (15 mg/dl). Patient was diagnosed with alcoholic liver cirrhosis and the skin lesions were not thoroughly investigated at the time. Almost six months later he presented to our hospital with hypertensive emergency and generalised anasarca. Labs showed AKI with a serum creatinine of 5.2 mg/dl and BUN of 35 mg/dl, nephrotic range proteinuria, and gross hematuria. There was active urinary sediment. kidney biopsy revealed mesangial expansion on LM, IgA and C3 deposits were seen on IF, no fibrin, IgG, IgM deposition were seen. Focal effacement of foot processes and numerous large deposits were seen on EM in the mesangium. The renal biopsy was diagnosed as IgA nephropathy. He was treated with high dose steroids without much improvement. With worsening renal function and anasarca, patient was eventually placed on hemodialysis with a hope of improvement in due course of time.

Discussion We describe a possible correlation between HSP and IgA nephropathy. Renal involvement of HSP with an IgA nephropathy like pathology is usually seen within 3 months of onset of rash; however, this patient's had unusually delayed renal involvement till 6 months after the initial rash was noticed.

78 FUROSEMIDE AS A TOOL FOR THERAPY AND DIAGNOSIS

AL Heifner*, Engel LS, Lo B. *LSU Health Sciences Centre, New Orleans, LA*

10.1136/jim-2017-000697.78

Introduction We describe a case of cardiogenic pulmonary oedema in a patient with negative biomarkers and a non-diagnostic echocardiogram.

Case A 68-year-old Spanish speaking woman with type 2 diabetes and hypertension presented to the hospital with a worsening chronic nonproductive cough and recent onset of lower extremity and periorbital oedema. She was seen by her primary care physician who prescribed furosemide and support hose one week prior. Her physical exam was significant for bilateral rales at the mid-lung zones and trace pedal oedema. Initial chest radiograph findings were suggestive of pulmonary oedema. Initial labs including troponin and BNP were unremarkable. During her admission, she became acutely hypoxic with desaturations in the 80s requiring supplemental O₂. CT angiography of her chest was negative for pulmonary embolism but showed bilateral pleural effusions and basilar airspace disease with ground glass opacities. One dose of intravenous furosemide was given in the emergency department followed by an extensive workup that included an aborted thoracentesis, non-diagnostic echocardiogram, non-diagnostic bronchoscopy with negative AFB stains, and labs for rheumatologic and infectious processes which were all negative. Cardiology

recommended a repeat echo with straight leg raise to assess for occult diastolic dysfunction but this was not performed. The team then decided on a trial of aggressive diuresis which resulted in significant symptom improvement. A diagnosis of heart failure with preserved ejection fraction was made based solely on the clinical improvement.

Discussion The differential diagnosis for our patient was broad and included heart failure, infection, rheumatologic disorders, and malignancy. Her diagnosis was further impaired due to a language barrier and an inability to provide a good medical history. This led to a workup that may have been overly aggressive. A simple therapeutic trial of diuresis ultimately provided the diagnosis. This case illustrates that patients presenting with pulmonary oedema of unclear aetiology can be safely given a trial of diuresis, a non-invasive and cost-effective intervention with both diagnostic and therapeutic benefit.

79 PRIMARY CENTRAL NERVOUS SYSTEM LYMPHOPROLIFERATIVE DISORDER IN A PATIENT WITH CADAVERIC RENAL TRANSPLANT

¹JM Hernandez*, ¹S Maharaj, ²J Chique-Figueroa, ¹C Isache. ¹*UF Health, Jacksonville, FL;* ²*Mayo Clinic, Jacksonville, FL*

10.1136/jim-2017-000697.79

Case presentation A 72 year-old African American female with history of cadaveric renal transplant in 2005 on tacrolimus and mycophenolate mofetil (MMF) presented after generalised tonic-clonic seizures. She required intubation for status epilepticus. CT brain revealed multifocal hypodensities in both cerebral hemispheres. MRI brain characterised these lesions as rim and nodular enhancing. A left cerebellar lesion was also identified. Craniotomy and biopsy of a frontal lesion was performed, histopathology revealing post-transplant lymphoproliferative disorder (PTLD), polymorphic type. MMF was discontinued and tacrolimus dose reduced. Rituximab was commenced to be followed by whole brain irradiation. Serology for EBV was IgG (+) and IgM (-), with no evidence of infection prior renal transplant. Bone marrow biopsy had no signs of malignancy.

Discussion PTLD is a known complication of transplantation. Its incidence following kidney or liver transplant is 1%–5%. Risk factors include degree of immunosuppression, viral infection, allograft type, and therapy with calcineurin inhibitors (CIs). Primary central nervous system post-transplant lymphoproliferative disorder (PCNS PTLD) is a rare complication of solid organ transplantation representing 5%–15% of PTLD. The highest incidence of systemic PTLD occurs within one year after transplantation, whereas the median time of transplantation to CNS PTLD is 54 months. CNS disease is most often monomorphic, associated with renal transplant, EBV infection, and has a poor prognosis. Studies show that patients taking CIs have a significantly lower incidence of CNS disease, while the use of MMF has been linked to an increased risk in EBV (+) CNS PTLD. Optimal therapy is not known.

Conclusion PCNS PTLD is most often associated with renal transplant and EBV. With the upsurge in transplantations, clinicians and pathologists must be aware of this entity. CIs have been linked as a potential risk factor for PTLD in multiple studies; however recent studies postulate a protective effect for CNS involvement.

80 **COMPLICATED LUNG ABSCESS WITH EMPYEMA THORACIS IN AN ELDERLY PATIENT FROM PRIMARY DENTAL INFECTION**

MK Islam*, A Islam, T Vo. *Texas Tech Univ HSC Amarillo, Amarillo, TX*

10.1136/jim-2017-000697.80

Case report An 91 year old male with past medical history of Dementia, CAD, Type 2 DM, Hypertension; brought to the hospital due to recurrent non-resolving pneumonia. Patient was treated twice for pneumonia in last 8 weeks without complete resolution, no fever, weight loss, and hemoptysis. He was living at assisted living facility for last 8 months due to advanced dementia. Vitals: temperature 99 F, pulse 90/min, respiratory rate 18/min, BP 130/64 mmHg, SPO₂%–95% on room air. On physical exam- dehydrated, bad oral hygiene including multiple dental caries, confused, oriented only to person, crackles in left lower lung, S1/S2 normal, no murmur/pericardial rub, no rash, neck stiffness, focal weakness. Initial lab: Hb 10 gm/dl, MCV 90, WBC 13 K, Neutrophil 78%, Bands 2%, Platelet 248 K, Na 138, K 4, Cl 100, HCO₃ 23, BUN/Cr 19/0.8, Blood sugar 81, Ca 8, Mg 2.1, albumin 2.9, AST 17, ALT 10, Alkaline Phosphatase 83, PT 13, PTT 300, d-dimer 329. CXR revealed LLL consolidation; CT chest showed right apical infiltrate, left lingular abscess and left loculated pleural effusion. Thoracentesis was performed, showed purulent fluid. Pleural fluid analysis suggestive of empyema, culture grew streptococcus anginosus. Patient was treated with ceftriaxone IV for 4 total weeks.

Discussion The Streptococcus anginosus group (also known as the S. milleri group) is a subgroup of viridans streptococci that consists of three distinct streptococcal species: S. anginosus, S. intermedius, and S. constellatus. The organisms are normal flora of the human oral cavity and gastrointestinal tract and are known for their pathogenicity and tendency for abscess formation. Oral, head and neck, and abdominal infections caused by members of the S. anginosus group are often mixed; they may involve other bacteria such as Eikenella corrodens, Fusobacterium nucleatum, or other microorganisms. Lung abscess and empyema thoracis of our patient is thought to be due to bad oral hygiene and dental caries; which cause bacteremia or aspiration pneumonia complicating with lung abscess and empyema. In resistant cases, surgical drainage may be considered if needed. Our patient reminds physicians' about the importance to identify undiagnosed dental/oral infections which might be the source of systemic infection and abscess.

81 **A CASE OF METASTATIC STAGE 4 RENAL CANCER AND THE RELEVANCE OF HOSPICE IN END STAGES**

F Mathai*, R Pattabhi, TM Reske, L Ali, S Barry, EA Aguilar. *LSU Health Sciences Centre in New Orleans, New Orleans, LA*

10.1136/jim-2017-000697.81

Case report A 65-year-old female patient was admitted to the hospital for recurrent episodes of fever, chills and dysuria. She had no past medical history, was not on any medications, no history of alcohol use, cigarette smoking, no history of exposure to any chemicals and no family history. Evaluation revealed that she had metastatic, Stage 4, renal cancer ultimately not responsive to chemotherapy. She would have benefited from hospice. Although this option was discussed with the patient multiple times, she refused it.

In this case, despite the poor prognosis, the patient requested multiple sessions of chemotherapy, which were unsuccessful. She finally agreed to hospice the day before she passed.

In order to receive hospice, it is important for the patient to understand the course of their illness and their outlook must be directed towards symptom relief rather than cure of illness. In addition to optimising medical management, hospice would have tailored the services to help with the patients emotional and medical needs. This case serves as a great example of how the available resources are underutilised in our community.

Conclusion The goal of hospice is to provide a continuum of home, outpatient and homelike inpatient care for the terminally ill patient and their families. It consists of an interdisciplinary team that meets the special needs arising out of the physical, emotional, spiritual, social and economic stresses, which are experienced during the final stages of illness and during dying and bereavement.

The bias against hospice is a major issue that undermines its importance and prevents it from being utilised to its fullest potential. Patient and family education is as important as spreading an awareness amongst the physicians on its availability and indications

82 **COMPLICATED RECURRENT INTRA-ABDOMINAL ABSCESSSES IN A PATIENT WITH FABRY DISEASE**

L Ngo*, RD Smalligan, A Islam. *Texas Tech Univ HSC Amarillo, Amarillo, TX*

10.1136/jim-2017-000697.82

Case report A 29 y/o Hispanic male with Fabry disease, HTN, and ESRD on peritoneal dialysis was admitted for *C.difficile* diarrhoea and peritonitis and severe sepsis. CT of the abdomen showed multiple loculated intraabdominal abscesses. Peritoneal dialysis catheter was removed and patient had IR guided drainage of abscesses. Family history revealed that three cousins had been diagnosed with Fabry disease and that three male members of older generation had died of renal failure before the diagnosis of Fabry disease. Our patient was diagnosed with Fabry disease at age 25 when he was admitted to ICU for acute on chronic renal failure requiring dialysis. During childhood and adolescence, the patient had noticed impaired sweating after exercise, heat and cold intolerance, periods of intense neuropathy in knee and feet, and intermittent purple-red skin rashes on extremities. After patient was diagnosed with Fabry disease, he was on peritoneal dialysis for four years and had experienced two episodes of peritonitis and abdominal abscess. Patient was planned to initiate enzyme replacement therapy (ERT) with fabrazyme once the infections are treated.

Discussion Fabry disease (FD) is a progressive, X-linked inherited disorder of glycosphingolipid metabolism due to deficient or absent lysosomal alpha-galactosidase A activity. This results in accumulation of globotriaosylceramide (Gb3) within lysosomes in a wide variety of cells, thereby leading to the protean manifestation of multiple organs. Renal manifestations occur in approximately 50 percent of affected patients who eventually develop end stage renal disease (ESRD). Patient with Fabry disease are also prone to life threatening infections. Current treatment focuses on replacing the missing or deficient enzyme with recombinant alpha-galactosidase A.

Studies have shown that enzyme replacement therapy (ERT) has effectively reduced tissue deposition of Gb3 in the heart, skin, and in most cell types of the kidneys. Thus, we strongly advise all patients with strong family history of Fabry disease to have screening, so that enzyme replacement and adjunctive therapy can be initiated early, to prevent further organ damage and to reduce the severity of disease manifestations.

83 A COMMONLY MISSED CAUSE OF HYPONATREMIA

R Pattabhi*, F Mathai, TM Reske, L Ali, S Barry, EA Aguilar. *LSUHSC-NO, New Orleans, LA*

10.1136/jim-2017-000697.83

Case report A 75 year old female, with a medical history significant for hypertension presented to the ER complaining of a three day history of bilateral lower extremity muscle cramps, nausea, vomiting, decreased oral intake, loose stools and lethargy.

She had started hydrochlorothiazide (HCTZ) two weeks prior to admission. Physical exam showed lethargy and dry oral mucosa. Lab showed sNa 108 mmol/L, sCl 70 mmol/L, glucose 104 mg/dL, AST 49 u/L and, ALT 44 u/L. Other labs were normal.

Normal saline at 100 ml/hour was started and HCTZ stopped. She was admitted to the ICU with neurochecks. sNa was 111 mmol/L after 4 hours and remained unchanged after 9 hours. One hour later she developed tonic-clonic seizures requiring Lorazepam and intubation for airway protection. Stat labs revealed sNa 113 mmol/L, sCl 84 mmol/L, and glucose 119 mg/dL. Head CT showed no acute changes and EEG did not reveal focal or epileptiform abnormalities. Post seizure her family disclosed her long history of substantial alcohol intake, with the consumption of wine nightly for many years. Unfortunately at the time of admission this information was not known.

Alcohol dependence is an important cause of hyponatremia, which is sometimes missed. This case iterates the fact that an accurate history is essential for proper diagnosis and treatment of hyponatremia. Had alcohol withdrawal been high on the differential, lorazepam would have been started earlier preventing her seizure episode and subsequent intubation. Alcohol use is associated with hypomagnesemia, hypophosphatemia, hypocalcemia, hypokalemia and hyponatremia. 22.8% of chronic alcohol users have been found to be hyponatremic at ER presentation, half of cases were found to be hypovolemic as well.¹ According to the National Institute of Alcohol Abuse and Alcoholism, alcohol is the third leading cause of death in USA, it is estimated that 14 million Americans have an alcohol use disorder.²

REFERENCES

1. *Addict J.* 2015;2015:541–536.
2. *Clin North Am* September 2013;42(3): 593–615.

84 AUTOIMMUNE HEPATITIS ASSOCIATED CHRONIC MYELOMONOCYTIC LEUKAEMIA

A Shredi*, H Edriss, SH El Nawaa. *Texas Tech Univ Health Science Centre, Lubbock, TX*

10.1136/jim-2017-000697.84

Case report Chronic myelomonocytic leukaemia is a rare malignant hematopoietic stem cell disorder with clinical and

pathological features of both a myeloproliferative neoplasm and myelodysplastic syndrome. It occurs most commonly in older men with a median age at diagnosis of 65 to 75 years. Cytopenia and hepatosplenomegaly are common.

As many as 10% of patients diagnosed with myelodysplastic syndromes including CMML have autoimmune manifestations which range from vasculitis to glomerulonephritis.

A 62 year old man presented with an upper GI bleed. Physical examination included blood pressure 110/60 mmHg, heart rate 94 beats/minute, respiratory rate 23 breaths/minute, and temperature 98.3 F. His abdomen examination revealed a distended abdomen and a nodular liver. Computed tomography of the abdomen revealed liver cirrhosis. The patient denied any history of liver disease, drinking alcohol, using antiplatelet drugs, NSAIDs or anticoagulants. His initial lab tests showed WBC 16,500/ μ L, Hb 9.6 gm/dL, platelets 92 k/ μ L, and INR 2. His total bilirubin was 1.4 mg/dL, albumin was 2.6 mg/dL, and AST and ALT were normal. An EGD revealed a non-obstructing Schatzki ring at the gastroesophageal junction and an erythematous gastric mucosa. Biopsies were negative of *H. pylori*. Tests for Hepatitis B and C were negative. He had a positive smooth muscle antibody; other antibodies, including ANA, anticentromere, CCP, antiglomerular basement membrane, ANCA, antimitochondrial antibodies, were negative. He underwent bone marrow biopsy which showed a hypercellular marrow with monocytosis. His prognosis based on the MD Anderson CMML prognostic calculator was very poor with a median overall survival 10 months. The patient died after 3 months of diagnosis.

This patient likely had autoimmune hepatitis which caused liver cirrhosis and GI bleeding. This case report represents a rare association between autoimmune hepatitis and CMML. There are reported cases of association of other types of leukaemia with autoimmune hepatitis, however, none reported about autoimmune hepatitis associated with CMML. I hope reported case here could raise the awareness of the medical personnel to consider this rare association.

Allergy, immunology, and rheumatology

Joint plenary poster session and reception

4:30 PM

Thursday, February 22, 2018

85 THE SARCOID CRISIS: NEUROSARCOIDOSIS CAUSING PITUITARY-HYPOTHALAMIC DYSFUNCTION

NS Harrison*, ME Lindsey, A Subauste, V Majithia. *University of Mississippi Medical Centre, Jackson, MS*

10.1136/jim-2017-000697.85

Case report Sarcoidosis is a granulomatous disease of unknown aetiology that affects the lungs in 90% of cases. Thirty percent develop extra-pulmonary manifestations, and 5% develop neurosarcoidosis (NS). NS most often presents with cranial mononeuropathy; hypothalamic-pituitary abnormalities are rare and have been identified in 2.5% of NS cases.

Case This is a 31-year-old African American female with a long history of systemic sarcoidosis. She initially presented with incontinence and lower extremity weakness, and imaging

revealed a lumbar mass. Biopsy of this mass revealed non-caseating granulomas. Despite treatment with IV steroids followed by oral prednisone and azathioprine, the disease progressed. She was noted to have poor compliance. She developed sarcoid in her lymph nodes, maxillary sinuses and GI tract. Therapy was changed to mycophenolate mofetil without success and her disease progressed to the central nervous system. Decision was made to start IV cyclophosphamide, but patient only received one infusion. Four months later she presented to ER with nausea, hypotension, and tachycardia with polyuria of 7 L in 24 hours. Laboratory data revealed hypernatremia, hypokalemia, lactic acidosis, abnormal cortisol, abnormal thyroid function, and low urine osmolality that improved with water deprivation. She was diagnosed with panhypopituitarism and diabetes insipidus and treated with hydrocortisone, desmopressin, and IV cyclophosphamide in the hospital. She was discharged on prednisone, cortef and desmopressin. She completed 6 months of cyclophosphamide. However, the pituitary mass has been unchanged on repeat imaging. She remains on prednisone 40 mg with plans to start Infliximab for further treatment.

Conclusion Less than 1% of intrasellar lesions are associated with hypothalamic pituitary dysfunction. Clinicians must consider neurosarcoidosis when these lesions are noted in a patient with pre-existing sarcoidosis. Glucocorticoids are the initial treatment followed by immunomodulators. These patients have poor prognosis, and most will require long term hormone replacement in addition to sarcoidosis therapy.

86 A CASE OF MAFFUCCI SYNDROME

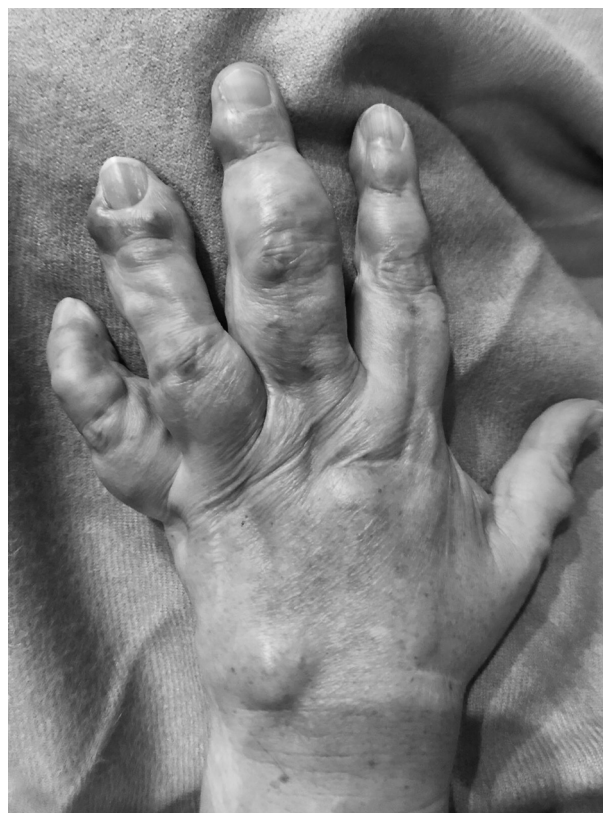S Kolagatla*, N Moka, S Bailey. *ARH-Markey Cancer Centre, Hazard, KY*

10.1136/jim-2017-000697.86

Case report Maffucci syndrome (MF) is a rare genetic disorder occur as a result of somatic heterozygous mutation of Isocitrate dehydrogenase 1 and 2 (*IDH1/IDH2*) genes that affects skin and bone. Enchondromas, skeletal deformities and hemangiomas are characteristic of this syndrome. We report a case of MF.

53 year old female presented to the clinic with gradual worsening of left hand swelling for the past several years. Her review of systems is positive for fatigue, musculoskeletal pains of multiple joints and long standing skin lesions. Past history of hemangiomas, enchondromas and chondrosarcoma, multiple surgeries for joints. Her family history is negative for enchondromas. Exam is significant for multiple purplish skin lesions on the extremities and multiple healed scars from remote surgeries.

MF is a rare genetic syndrome so far less than 200 cases have been reported worldwide. Differential diagnosis includes Ollier syndrome but can be distinguished by absence of cutaneous lesions and age of onset. Diagnosis of MF can be made by detailed history, examination and radiological assessment. Pathological assessment of enchondromas will support the diagnosis. Enchondromas must be distinguished from chondrosarcomas as the later possess malignant potential. No association with mental or psychiatric disorders has been reported. Multidisciplinary team management with orthopedician is encouraged in the management of the patients



Abstract 86 Figure 1 Severe deforming joint of hand due to multiple enchondromas

87 A RING-ENHANCING LESION BY ANY OTHER NAME

ME Lindsey*, NS Harrison, J Bridges, J Blossom, V Majithia, S Kishore. *University of Mississippi, Jackson, MS*

10.1136/jim-2017-000697.87

Case report Systemic lupus erythematosus (SLE) affects the central nervous system in up to 20% of patients and is often termed neuropsychiatric lupus. Neuropsychiatric lupus may present with a wide array of clinical manifestations, and appropriate diagnostic workup is essential. A crucial step in this process is to rule out primary etiologies that neuropsychiatric lupus may mimic. Appropriate brain imaging can play a role in this setting, although unexpected findings may lead to misdirection of the final diagnosis. We present a 27 year old African American male with an eight-year history of SLE who presented to the emergency department with altered mental status. His symptoms had developed insidiously over the course of several days. His underlying SLE had previously been treated with hydroxychloroquine monotherapy. At time of presentation, routine lab findings were fairly unremarkable and computed tomography (CT) of the brain was normal. Lumbar puncture was performed; routine cerebrospinal fluid analysis revealed normal glucose, elevated protein, and slightly elevated opening pressure. Magnetic resonance imaging (MRI) of the brain was obtained; this revealed unusual ring-enhancing lesions reported as possible neurocysticercosis. This led to more extensive infectious disease evaluation which ultimately revealed no evidence of any bacterial, viral, fungal, or

parasitic infectious processes. Further autoimmune serology testing revealed a positive anti-ribosomal-P protein. The patient was diagnosed with neuropsychiatric lupus, and he responded rapidly to treatment with high dose intravenous glucocorticoids. Cyclophosphamide was later added to his treatment regimen. The patient has continued to show clinical improvement and repeat brain MRI shows complete resolution of the previously noted ringed lesions. This case highlights the challenges of diagnosing neuropsychiatric lupus and illustrates the importance of viewing all clinical information as part of the whole patient scenario rather than making assumptions based on one abnormal finding.

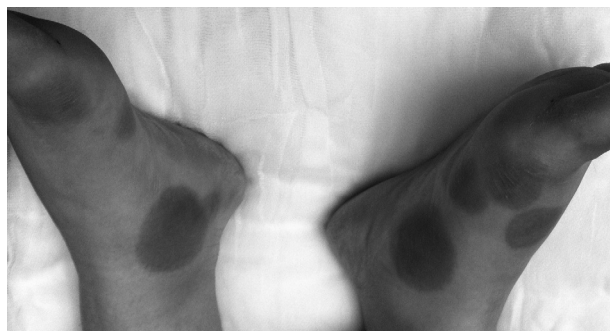88 FIXED DRUG ERUPTION ASSOCIATED TO ASPIRIN

RM Medrano*, M Orellana-Barrios. *TTUHSC, Lubbock, TX*

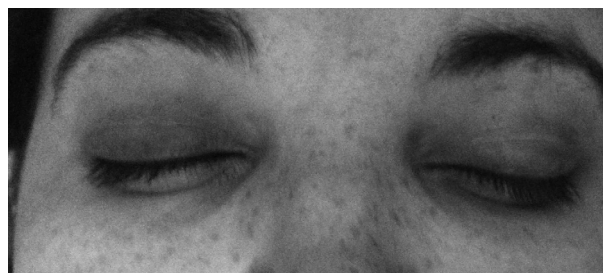
10.1136/jim-2017-000697.88

Case report A previously healthy 27-year-old female presented to Outpatient Urgent Care Clinic complaining of dark spots that appeared suddenly on both her feet and face. She had been prescribed Aspirin (650 mg PO every 6 hours as needed) the day prior to presentation as therapy for migraine-type headache. She also then recalled that these spots had appeared suddenly, in exactly the same areas approximately one year before the current episode, also associated with ingestion of an over the counter medication (Alka-Seltzer). Physical examination was unremarkable with the exception of dark, erythematous, slightly oedematous round plaques asymmetrically distributed over feet (figure 1) and left eyelid (figure 2). A complete blood count was ordered (results within normal range) and patient advised to substitute Aspirin with Ibuprofen, which controlled her headache. The skin lesions subsided and disappeared without complications within 2 weeks.

Fixed drug eruption is a cutaneous drug reaction noted to recur in the same anatomical locations upon recurrent exposure to the offending agent. Lesions usually resolve with no further treatment, but may leave post inflammatory hyperpigmentation. Supportive treatment may include oral H1 antihistamines and short course of steroids in more severe cases. The most common drugs associated with fixed drug eruption are antibacterial agents, aspirin and other non-steroidal anti-inflammatory agents, acetaminophen, and barbiturates.



Abstract 88 Figure 1 Physical examination was unremarkable with the exception of dark, erythematous, slightly oedematous round plaques asymmetrically distributed over feet



Abstract 88 Figure 2 Left eyelid

Cardiovascular

Joint plenary poster session and reception

4:30 PM

Thursday, February 22, 2018

89 OUTCOMES OF CORONARY ARTERY OCCLUSION FOLLOWING TRANSCATHETER AORTIC VALVE REPLACEMENT

O Akinseye*, C Nwagbara, S Jha, UN Ibebuogu. *University of Tennessee Health Science Centre, Memphis, TN*

10.1136/jim-2017-000697.89

Purpose of study Coronary Occlusion (CO) is a rare but serious complication following transcatheter aortic valve replacement (TAVR) with limited published data. We sought to evaluate the immediate and short-term outcomes of CO complicating TAVR.

Methods used Studies, including case reports, case series and original articles published from 2002 to 2016 describing CO following TAVR were identified with a systematic electronic search using the PRISMA Statement. Only studies reporting data on demographic and procedural characteristics, management and follow up outcomes were analysed.

Summary of results A total of 40 publications describing 96 patients (86 native, 10 bioprosthetic) were identified. Mean age was 83 ± 7 years and most (81%) were females. The mean logistic EuroSCORE and STS score was $23.5\% \pm 14.6\%$ and $9.1\% \pm 3.2\%$ respectively. TAVR access site was transfemoral in 73% and a balloon expandable valve was used in 78%. Among those with LCA occlusion, the mean LCA ostium height was 10.1 ± 1.8 mm while the mean RCA ostium height was 10.4 ± 2.0 mm among those with RCA occlusion. CO frequently involved the left main coronary artery (80%) and the most common mechanism was displacement of native valve leaflet (60%), and most cases occurred within 1 hour post-implantation (88%). Percutaneous coronary intervention was attempted in 82 patients and successful in 89%. Procedural death was 10.4%. CO following TAVR in native aortic valve stenosis was associated with a 30 day mortality rate of 35.3%. **Conclusions** CO following TAVR is associated with a high procedural and 30 day mortality rate despite aggressive resuscitative measures including percutaneous coronary intervention.

90 ATRIAL FIBRILLATION IN HOSPITALISED, NON-CRITICALLY ILL ELDERLY PATIENTS

M Heckle*, M Nayyar, BM Ramos, KT Weber. *University of Tennessee Health Science Centre, Memphis, TN*

10.1136/jim-2017-000697.90

Purpose of study Atrial fibrillation (AF) is the most common sustained tachyarrhythmia. It is associated with increased cardiovascular morbidity, mortality and preventable stroke. It accounts for a third of all hospitalizations for cardiac dysrhythmias. The incidence of AF rises with advancing age. Herein, we reviewed the profiles of elderly hospitalised, non-critically ill patients diagnosed with AF on standard 12 lead electrocardiogram to determine if certain variables were characteristic of these patients.

Methods used A retrospective review of 413 patients with AF at an urban medical centre from November 2015 to July 2017, of which 197 were >65 years of age. The following variables were analysed: sex, electrolytes (potassium, magnesium, calcium), brain natriuretic peptide, serum creatinine, race, body mass index, left ventricular hypertrophy present on electrocardiogram, corrected QT interval and presence of rapid ventricular response (heart rate >100 bpm). Variables were compared with identical features in those <65 years (n=61).

Summary of results In our elderly population there were more males (59.4%) and Caucasians (64.3%) with atrial fibrillation. When compared to the younger cohort, the elderly population had a higher level of brain natriuretic peptide (1171 vs 736 pmol/L $p=0.05$) and average BMI (30.2 vs 24.9 kg/m² $p=0.02$), but less incidence of rapid ventricular response (49.1% vs 61.7% $p=0.04$). The presence of left ventricular hypertrophy on electrocardiogram was also more common, but not statistically significant in the younger population (19.6% vs 13.3% $p=0.09$).

Conclusions In our cohort elderly hospitalised patients with atrial fibrillation are more likely to be male Caucasians with a higher level of serum brain natriuretic peptide and BMI when compared to their younger counter parts. Younger hospitalised patients with atrial fibrillation are more likely to have electrocardiographic evidence of left ventricular hypertrophy and have a higher incidence of rapid ventricular response.

91 HEART FAILURE WITH RECOVERED EJECTION FRACTION. A NEW PHENOTYPE OR A RESULT OF PERCUTANEOUS CORONARY REVASCLARISATION

*I Ifedili, A Pathak, O Akinseye, KT Weber. *University of Tennessee Health Science Centre, Memphis, TN*

10.1136/jim-2017-000697.91

Purpose of study Recent observational studies would suggest the presence of a new heart failure (HF) phenotype, termed heart failure recovered ejection fraction (HFrecEF). However, several reversible negative inotropic stimuli may explain the recovery in EF. We examined the characteristics of patients with ischaemic cardiomyopathy (ICM) who had recovery in EF following percutaneous coronary revascularisation.

Methods used Retrospective review of our cardiology clinic patients with prior ICM and reduced EF (HFrEF) (<40%) who subsequently had HFrecEF (>40%) between March, 2015 and April, 2017. The baseline characteristics, medical history and echocardiogram of these patients were analysed

after percutaneous coronary revascularisation on average of 503±320 days.

Summary of results A total of 10 patients with ICM were identified. Mean age ±SEM was 50.2±8.7 years, 60% were females and all patients were African American (AA). Baseline characteristics reveal that 80% had hypertension, 50% had diabetes and 70% had hyperlipidemia. Seventy percent had acute coronary syndrome (ACS) (3 STEMI and 4 non-STEMI) at the time of their initial EF and all had percutaneous coronary revascularisation with most interventions done on the left anterior descending artery (57.1%). Baseline EF was 26.6% ±6.4% and which improved to 50.0%±5.9% on average of 503±320 days. Seventy percent and 90% of patients were on aspirin and a statin, respectively, while 100%, 90%, and 60% were on a beta-blocker, angiotensin converting enzyme inhibitor and aldosterone receptor blocker, respectively.

Conclusions A substantial number of our AA patients with ACS and having ICM with HFrEF had HFrecEF following percutaneous coronary revascularisation. This would suggest hibernating myocardium that subsequently improved with revascularisation and optimal medical therapy and would further imply their HF was in remission rather than a new HF phenotype.

92 ATRIAL FIBRILLATION IN PATIENTS WITH RAPID VENTRICULAR RESPONSE

M Nayyar*, M Heckle, M Agarwal, J Tran, KT Weber. *University of Tennessee Health Science Centre, Memphis, TN*

10.1136/jim-2017-000697.92

Purpose of study Atrial fibrillation (AF) is the most common sustained tachyarrhythmia. The ventricular rate of patients with AF is determined by the conduction properties of the atrioventricular (AV) node. Avoidance of rapid ventricular response (RVR) is important in preventing haemodynamic instability and tachycardia-induced cardiomyopathy. Herein, we reviewed the profiles of atrial fibrillation in patients with and without rapid ventricular response.

Methods used We performed a retrospective review of 239 patients with AF who were seen at an urban medical centre from November 1, 2015 to July 1, 2017. Rapid ventricular response was defined as a heart rate greater than 100 beats per minute. The following variables were analysed: age, sex, electrolytes (potassium, magnesium, calcium), brain natriuretic peptide, serum creatinine, race, body mass index (BMI), left ventricular hypertrophy present on electrocardiogram and corrected QT interval. Variables were compared with features found in those patients whom atrial fibrillation with RVR was not present.

Summary of results Upon review, 127 patients were found to have RVR. These patients were younger with an average age of 60.5 (1.35) versus 66.4 (1.5) $p<0.01$ and had a higher body mass index, with an average BMI of 29.2 (1.77) versus 25.5 (1.29) $p=0.09$. Electrolytes were similar between the two groups except that serum calcium was significantly lower in patients with RVR, 8.42 (0.07) versus 9.03 (0.07) $p<0.01$. In addition, patients with RVR had a significantly longer QTc interval, 468.7 m/sec (3.64) versus 453.3 m/sec (3.89) $p<0.01$ and were more likely to have evidence of left ventricular hypertrophy found in 20.5% versus 9.8% $p=0.02$.

Conclusions In our study, patients with atrial fibrillation and evidence of rapid ventricular response were younger, had a

higher BMI, lower serum calcium, longer QTc and were more likely to have electrocardiographic evidence of left ventricular hypertrophy. The importance of critical illness with a hyperadrenergic state in AF with RVR was not considered herein. BMI is a clinically important and potentially modifiable risk factor to prevent rapid ventricular rates in patients with atrial fibrillation.

93 WITHDRAWAL OF CARDIOTOXINS AND SUBSEQUENT RECOVERY IN HEART FAILURE WITH REDUCED EJECTION FRACTION

*A Pathak, I Ifedili, O Akinseye, KT Weber. *University of Tennessee Health Science Centre, Memphis, TN*

10.1136/jim-2017-000697.93

Purpose of study Heart failure with recovered ejection fraction (HFrecEF) has been considered a distinct HF phenotype. However, HF in remission due to the withdrawal of a cardiotoxin and the subsequent response to optimal medical therapy may explain such a response. Herein, we monitored patients having HFrecEF at our urban medical centre.

Methods used Retrospective review of our cardiology clinic patients with nonischemic cardiomyopathy (<40%) with history of alcohol, cocaine, marijuana and other cardiotoxin use who subsequently had recovered EF (>40%) between March, 2015 and April, 2017. The baseline characteristics, medical history and echocardiogram of these patients were analysed.

Summary of results There were 10 alcohol (7 former and 3 current), 5 marijuana (2 former and 3 current), 4 former cocaine abusers, and a former energy drink consumer. All stopped their abuse of the offending agent within 1 month of HF diagnosis. Mean age \pm SEM was 52.1 ± 9.9 years, 64.3% male, 100% African American (AA). Baseline characteristics revealed that 85.7% had hypertension, 28.6% had diabetes, 42.9% had hyperlipidemia, 28.6% had either stroke or transient ischaemic attack and 28.6% had coronary artery disease. Baseline EF was $28.7\% \pm 6.8\%$ and improved in all patients to $52.5\% \pm 9.6\%$ at 396.5 ± 305.9 days. 100%, 92.9% and 57.1% of patients were on a beta-blocker, angiotensin converting enzyme inhibitor and aldosterone antagonist respectively.

Conclusions In our AA patient cohort with HFrecEF, the improvement in systolic function accompanied cessation of a negative inotropic agent and optimal medical therapy to suggest HF was in remission rather than a new HF phenotype.

94 MECHANICAL FAILURE OF ANGIO-SEAL DEVICE NEEDING SURGICAL EXTRACTION

S Pruthi*, M Abdelghany, D Chaudhuri. *SUNY Upstate Medical University, Syracuse, NY*

10.1136/jim-2017-000697.94



Abstract 94 Figure 1

Case report Vascular closure devices have found their place to achieve homeostasis after percutaneous endovascular procedures, however consequences of failure are not clear. We describe a case of Angio-Seal malfunction with failure of locking system.

Case 65-year-old gentleman with history significant for peripheral vascular disease with iliofemoral-tibial-peroneal bypass and renal artery stenosis with stenting was brought after out of hospital cardiac arrest. Cardiac catheterization was attempted via right radial approach showing heavily calcified, 95% stenosed RCA which could not be crossed. For repeat cardiac catheterization left femoral artery approach was used with ultrasound guided micro-puncture needle and 10 cm Terumo Pinnacle sheath, exchanged to 35 cm 6F sheath. Multiple attempts to cross RCA lesion were unsuccessful.

A 6F VIP Angio-Seal was used as closure device. Insertion sheath and arteriotomy locator were advanced over a guide wire into femoral artery and good pulsatile flow obtained. The locator was removed and compaction tube advanced through the sheath until a click was heard. The compaction tube was pulled back, but second click, indicating tube locking was not obtained. Device was left in place, vascular surgery consulted and device extracted surgically. There was no fracture or missing pieces. Analysis of the device by St. Jude Medical Company revealed mechanical failure of the device for unclear reasons.

Discussion Although Vascular closure devices are safe, several complications like pseudo-aneurysm, AV fistula formation, peripheral vascular embolization with lower limb ischemia have been reported. To treat limb ischemia authors recommend direct surgical cut down, retrieval of the device and definitive arterial repair. Though these procedures are limb sparing, they are associated with significant morbidity. We report a relatively rare complication of closure device with failure of deployment of collagen plug and sandwich mechanism which should be kept in mind when faced with such situations.

95 CHEST X-RAY TO PREDICT A TORTUOUS RIGHT BRACHIOCEPHALIC ARTERY PRIOR TO TRANS-RADIAL CATHETERIZATION. A RETROSPECTIVE STUDY

S Salem*, D Ardeshtna, P Jagadish, S Koshy, RN Khouzam, N Garg. *University of Tennessee Health Science Centre, Memphis, TN*

10.1136/jim-2017-000697.95

Purpose of study Cardiac catheterization is one of the most widely used diagnostic and therapeutic modalities in modern cardiology. In recent years, there has been a paradigm shift towards percutaneous trans-radial artery catheterization as the preferred access site. Its accessibility, lower bleeding risk, lower mortality with ST elevation myocardial infarction,

patient comfort, early ambulation and discharge, cost, and reduced post procedural monitoring makes it superior to femoral artery access.

A subset of patients have a tortuous right brachiocephalic (innominate) artery that makes catheter manipulation difficult, which can result in increased procedure time, radiation, patient discomfort, and radial artery spasm. We hypothesised that such patients may be identified by certain measurable parameters pertinent to the shape of their thoracic cage as measured by plain chest x-ray.

Methods used We reviewed chest x-ray films on 56 patients that had undergone radial cardiac catheterization in our lab. We prospectively identified 23 patients with tortuous innominate artery identified by fluoroscopy (cohort group), and 33 patients with no tortuosity (Control group). Chest x-ray films were analysed and several measurements were obtained between cohort and control groups using *t*-test and P-Value models.

Summary of results Among all measurements, we concluded that vertebrocarinal distance (VCD), identified on chest X-ray as distance from thoracic T1 spinous process to carina, as the most statistically significant, with mean distance of 9.2 cm in cohort group, compared to 11.3 cm in control group (P value of <0.001). Other parameters derived from VCD, including ratio of body height to VCD, area of rectangle formed between VCD and thoracic diameter at carinal level were also statistically significant.

Conclusions Short distance between the spinous process of T1 vertebral body and the inferior edge of carinal bifurcation measured on chest x ray is a strong predictor of tortuous right innominate artery and may be helpful in considering an alternative access site prior to trans-radial catheterization.

96 HYPOPARATHYROIDISM ASSOCIATED WITH HYPOMAGNESEMIA, HYPOCALCEMIA AND VITAMIN D DEFICIENCY

M Agarwal*, YI Harper, KT Weber. *University of Tennessee Health Science Centre, Memphis, TN*

10.1136/jim-2017-000697.96

Purpose Hypomagnesemia (HypoMg²⁺) is a frequent disorder associated with gastrointestinal and/or renal losses whose pathophysiologic mechanisms have included vitamin D deficiency and impaired secretion of parathyroid hormone (PTH). Herein, we describe a case of HypoMg²⁺ with associated hypoparathyroidism-related hypocalcemia and vitamin D deficiency.

Case report This was one of several admissions for this 66 year old African American male with hypertension, alcoholism, diabetes and coronary artery disease who was hospitalised with the chief complaint of weakness and fatigue, but denied diaphoresis, seizures, tremors, vomiting, diarrhoea or urinary symptoms. He also reported experiencing frequent palpitations and dizziness. He was compliant with his outpatient medications: aspirin, atorvastatin, lisinopril, carvedilol, magnesium oxide (800 mg daily), pantoprazole and furosemide (80 mg BID). BP 110/64 mm Hg with regular heart rate of 94 beats/minute. Examination of all systems was noncontributory. Pertinent laboratory findings included: serum K⁺ 3.1 mEq/L, Mg²⁺ 0.2 mg/dl, Ca²⁺ 7.1 mg/dl, albumin 2.8 g/dl, 25-hydroxyvitamin D 15 ng/ml and PTH 10 pg/ml with hypokalemia,

HypoMg²⁺ and hypocalcemia also seen on previous admissions. EKG revealed sinus tachycardia without arrhythmias. Over the next 48 hours, his symptoms, serum Mg²⁺ and Ca²⁺ levels each improved, however, they remained abnormal despite cation supplementation and discontinuation of furosemide. Considering the clinical presentation and laboratory workup, we attributed his hypoparathyroidism as HypoMg²⁺-induced with hypocalcemia and vitamin- D deficiency. His supplementation was continued and he was begun on oral vitamin D (6000 units/daily) together with abstinence from alcohol, whereby his Mg²⁺ (2.1 mg/dl) and Ca²⁺ levels (8.5 g/dl) each further improved and remained normal thereafter.

Conclusion Hypoparathyroidism with hypocalcemia and vitamin D deficiency are under recognised in patients presenting with HypoMg²⁺ and should be considered in its differential diagnosis. In our African American patient with hypovitaminosis D, diuretic-induced and alcohol-related magnesium wasting led to HypoMg²⁺ with impaired release of parathyroid hormone and consequent hypoparathyroidism.

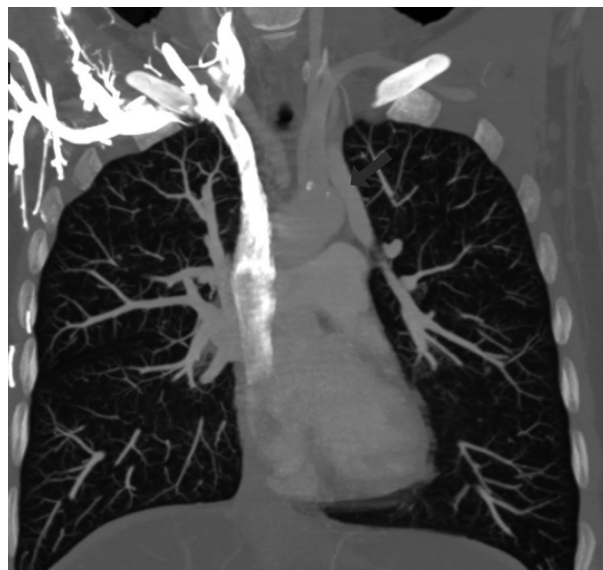97 PARTIAL ANOMALOUS PULMONARY VENOUS RETURN

MA Alsharif*, C Ashangari, D Murray, R Murray. *Texas Tech University Health Science Centre Amarillo, Amarillo, TX*

10.1136/jim-2017-000697.97

Background Partial anomalous pulmonary venous return (PAPVR) is an anatomic variant in which one to three pulmonary vein drains into the right atrium or its tributaries rather than into the left atrium. We present the case of PAPVR from the left upper lobe with drainage to the left brachiocephalic vein.

Case A 47 year old woman with past medical history of factor V Leiden mutation presented with sudden onset left side chest pain radiated to the back. Vitals were normal. Physical exam was unremarkable. EKG showed normal sinus rhythm with no ST changes. TTE showed LVEF of 45%. LA, RV and RA size was normal. RVSP was 30–40 mmHg. CT chest angiogram



Abstract 97 Figure 1 PAPVR from the left upper lobe with drainage to the left brachiocephalic vein

was negative for PE. PAPVR was incidentally noted involving the left upper lobe with drainage to the left brachiocephalic vein.

Discussion PAPVR is a rare congenital condition which is usually recognised in the paediatric population but may also be diagnosed during adulthood in patients who develop PAH, or in asymptomatic patients undergoing pulmonary vascular studies for other indications. For the treatment, In adult patients, the criteria for surgical repair are less clear cut. Those who have already developed symptoms due to shunting, or have evidence of right-sided volume overload, regardless of the magnitude of the shunt, are also considered for surgery. However, in asymptomatic patients with a low shunt fraction and no clinical or echocardiographic evidence of right heart overload, pulmonary hypertension, or other symptoms, surgery may be unnecessary.

98 WEARABLE CARIOVERTER DEFIBRILLATOR (WCD) – A NOVEL TREATMENT OPTION IN THE PREVENTION OF SUDDEN CARDIAC DEATH

C Ashangari*, A Qasim, N Salagundla, B Khandheria. *Texas Tech Univ HSC Amarillo, Amarillo, TX*

10.1136/jim-2017-000697.98

Background Implantable cardioverter defibrillator (ICD) is a life saving device ensuring protection against life threatening ventricular arrhythmias. There are certain situations which do not recommend the implantation of an ICD while the patient can still be at a risk of demise due to a life threatening ventricular arrhythmia. The wearable cardioverter defibrillator (WCD) is a device which comes to the rescue in such situations.

Case report 48 y old, Caucasian, male with significant PMH of HTN, hypothyroidism, COPD, DVT came with the C/O chest pain. EKG, troponins, nuclear stress test, cardiac cath and CTA were negative. Patient's echocardiogram showed severely depressed left ventricular systolic function with ejection fraction less than 10% and dilated left atrium and left ventricle. Patient also had grade 3 diastolic dysfunction. In the hospital stay, patient went into nonsustained VT, AVNRT, and SVT. He was stabilised and then discharged.

Patient was readmitted after few weeks due to syncopal episodes. During this episode, there were no jerking movements, no urinary or faecal incontinence. BNP was in the range of 2000's. Chest examination showed bilateral crepitations, there was JVD with positive hepatojugular reflux, S3. Patient was treated for CHF and discharged on WCD.

Patient was readmitted a few days later with chest pain. He noticed that the screen on the WCD showed waves of his heart rate during that episode, but he has not feel the shock. WCD interrogation showed episode of sustained VT, successfully terminated by the WCD. Patient denied any syncopal episode since he started wearing his WCD.

Discussion WCD may be used in patients in the early phase after acute myocardial infarction with poor left ventricular function, after acute coronary revascularisation procedures, reduced left ventricular ejection fraction ($\leq 35\%$) and in patients with non-ischaemic cardiomyopathy of uncertain aetiology. Also, patient may not be aware of the shock delivered by the WCD as by the time shock was delivered, patient may pass out. The WCD may also replace ICD implantation in

patients waiting for heart transplantation or who need a ventricular-assist device. However, patient compliance is essential for the effective use of this device.

99 ONE INSANE MURMUR

A Thibodeaux*, MR McMullan, WF Campbell. *University of Mississippi Medical Centre, Madison, MS*

10.1136/jim-2017-000697.99

Introduction Atrioventricular septal defects (AVSD) are a group of congenital cardiac defects involving the atrial and ventricular septum and the AV valves. This diagnosis is usually made at a young age and has a strong association with Down syndrome. Some variations may be largely asymptomatic and not diagnosed until adulthood. Here we report a case of a non-syndromic, 20 yo female with a transitional AVSD diagnosed after a referral for a murmur evaluation.

Case description A 20 yo white female was referred to our clinic after an ENT physician heard a murmur on her preop exam. She was sent to her PCP and then set up for an echocardiogram. This showed a primum atrial septal defect (ASD) with severe tricuspid regurgitation. The patient stated that she played sports and did some cheerleading with no limitations in high school. She exercises regularly and had recently completed 8 weeks of 'Insanity' workout with no problem. She has noticed easy fatigability for the past 6 months. She also had a trip to Tennessee where she had difficulty completing a 6 mile hike in the mountains. Her physical exam revealed a fixed, split second heart sound, a 4/6 systolic murmur at left lower sternal border with a right ventricular heave. Electrocardiogram showed normal sinus rhythm with a right bundle branch block and left axis deviation. A cardiac MRI revealed she had a transitional AVSD with 2 separate AV valves (cleft mitral valve) and a small ventricular septal defect (VSD). Right heart catheterization hemodynamics showed her mean pulmonary pressure to be 24 mmHg, with a pulmonary vascular resistance of 0.4 Wood units and QP:QS ratio of 3.7:1. She was referred for surgical correction. She underwent patch repair of her ASD and VSD with cleft mitral valve repair. She had an uneventful recovery and reports increased exercise tolerance on follow up.

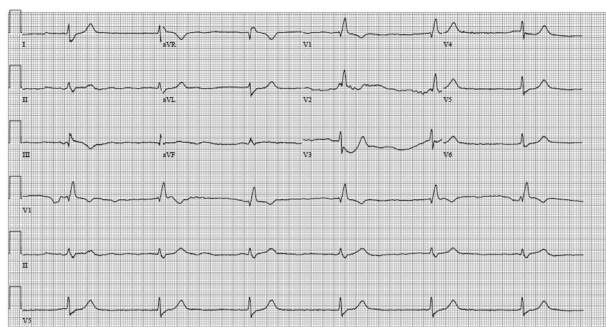
Discussion This case illustrates two key points in patients with AVSDs. First, AVSDs are not found solely in Down syndrome patients, although there is a strong association. Secondly, partial and transitional AVSDs can be well tolerated and not diagnosed until adulthood. They may present with a murmur, heart failure or atrial fibrillation. Primary complete repair is the preferred surgical approach, with overall low morbidity and mortality. It is important to remember these facts when diagnosing and treating patients with AV septal defects.

100 DIALYSIS: TREATMENT FOR COMPLETE HEART BLOCK

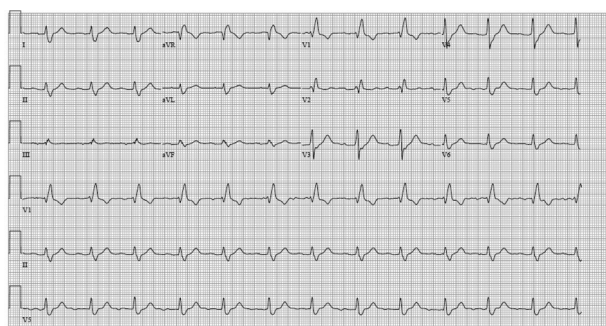
K Gada*, L Perera, M Hess. *SUNY Upstate Medical University, Syracuse, NY*

10.1136/jim-2017-000697.100

Case report A 58-year-old female with history of HTN, ESRD, seizure disorder presented after a seizure like episode. She was found to have heart rate <20, was given 0.5 mg atropine with no significant response. She was started on transcutaneous



Abstract 100 Figure 1



Abstract 100 Figure 2

pacings and glucagon was administered for potential beta blocker toxicity with no improvement. Basic lab work showed Na 136, K 6.6, Cl 93, Cr 5.3, BUN 46. EKG showed complete heart block with wide QRS. She was given calcium gluconate and insulin drip. Thereafter urgent hemodialysis was initiated with return to sinus rhythm.

Hyperkalemia leads to cardiac rhythm disturbances by altering the resting membrane potential of the cell which depends on the ratio of intracellular to extracellular potassium. In the myocardium, hyperkalemia depresses electrical conduction velocity but increases the rate of repolarization.

Our case highlights the fact that clinicians should be aware of heart block as a potential manifestation of hyperkalemia and it should be high on our list of differentials if a new onset complete heart block is seen in ESRD patients. Our case also highlights the fact that though transcutaneous pacing is usually helpful for hemodynamically bradycardia, in hyperkalemia given the underlying changes in cell excitability it is not helpful and in such patients, dialysis should be undertaken without delay to prevent adverse outcomes.

101 **DIAGNOSTIC VALUE OF SELECTIVE ANGIOGRAPHY APPROACH IN A FEMALE PATIENT WITH CHEST PAIN**

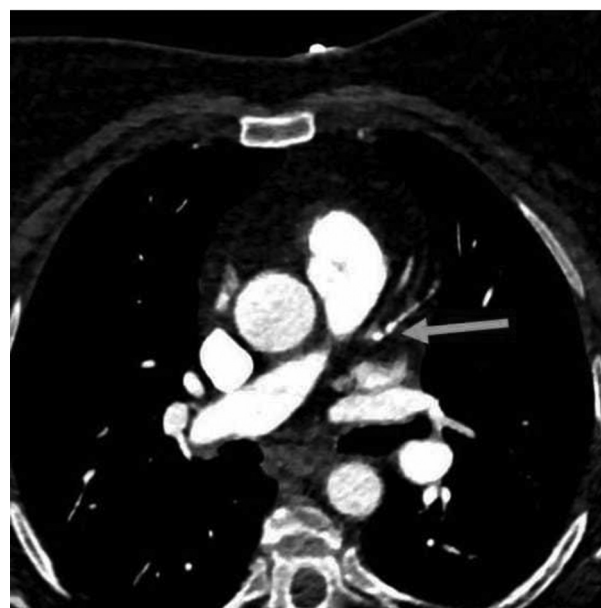*M Khalid, G Murtaza, D Hidalgo, M Kanaa, T Paul. *East Tennessee State University, Johnson City, TN*

10.1136/jim-2017-000697.101

Case report 62-year-old female with past medical history of hypertension was admitted with chest pain, nausea, epigastric pain and shortness of breath. Physical exam was significant for epigastric tenderness. Labs were unremarkable. Troponins were negative and EKG was normal. She had normal stress

test in 2013. Computed Tomography Angiography showed severe atherosclerotic plaque with 70%–99% percent stenosis in a diagonal branch of Left Anterior Descending Artery (figure 1) and total coronary artery calcium score was 176. she had a Left heart catheterization that revealed Non obstructive mild proximal LAD 30%–40% disease and 20%–30% diagonal stenosis.

CCTA has high diagnostic accuracy for detection of obstructive coronary artery disease. Recent Studies compare Selective angiography approach; CCTA followed by invasive angiography Vs Direct invasive angiography approach showed no difference in major adverse cardiac events and has a lower cardiovascular cost with selective approach. The only disadvantage of CCTA is higher radiation dose exposure. Factors that can influence the diagnostic accuracy of CCTA include gender, age, duration of symptoms, atypical presentation and coronary artery calcification. Young female patients with atypical presentations of chest pain might have less diagnostic accuracy just like in our case leading to overestimation of coronary artery disease on CCTA.



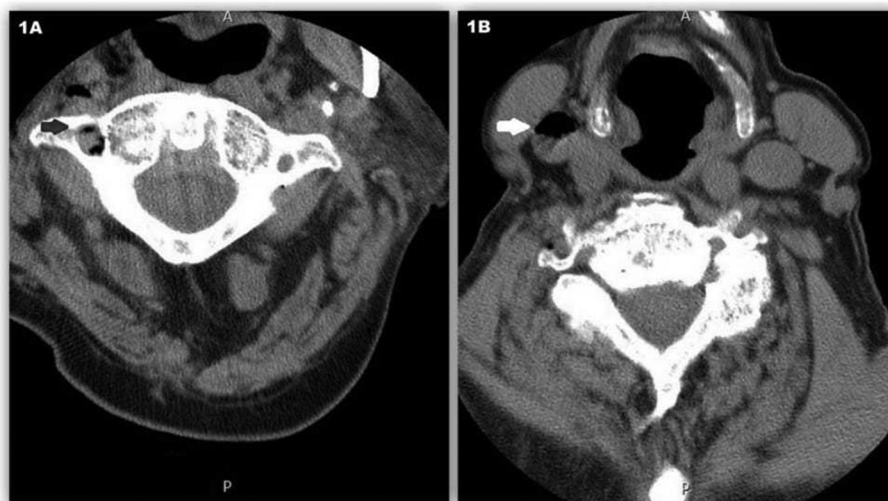Abstract 101 Figure 1 CCTA showed diagonal stenosis (blue arrow)

102 **IATROGENIC CAVERNOUS SINUS AIR EMBOLISM DURING PERIPHERAL VENOUS CATHETER INSERTION**

M Khalid*, ES Josan, P Sankhyan, G Hoskere. *East Tennessee State University, Johnson City, TN*

10.1136/jim-2017-000697.102

Case report 86 year old male with advanced dementia admitted with worsening confusion for 2 weeks. Physical exam was significant for disoriented to place and time (baseline) but no neurological deficit. Labs and CXR were normal. Computed tomography (CT) of the head without contrast showed air in left cavernous sinus and right transverse foramen on C1 which tracked down into venous circulation of neck. He didn't have any central line placement, however it was later discovered that he had a peripheral catheter insertion with a poorly primed line for saline administration and was the most likely



Abstract 102 Figure 1 Computed tomography (CT) of head without contrast revealed cerebral atrophy, air in left cavernous sinus, right transverse foramen on C1 (A) which tracked down into venous circulation of neck (B) but no traumatic injury

cause of air embolization. He was kept in Trendelenburg position and hyperbaric therapy was indicated, but deferred due to patient non-compliance in the setting of advanced dementia. Serial follow up neurological exam showed no deficits. Repeat CT head later showed resolution of air embolism. Echocardiography with bubble study showed normal left ventricular function.

Cavernous sinus air embolism is associated with infection, penetrating trauma or complication of vascular interventions. The most common cause is peripheral or central venous catheter lines insertion. Air embolism should be considered one of the differentials if the patient has acute change in neurological function especially during venous cannulation. Diagnosis usually made by CT scan of the brain and treatment is 100% oxygen.

103 BRACHIAL ARTERY PSEUDOANEURYSM: A RARE COMPLICATION OF INTRAVENOUS DRUG ABUSE

V Kohli*, M Ibrahim, D Ginn. *East Tennessee State University, Johnson City, TN*

10.1136/jim-2017-000697.103

Introduction Trauma is the leading cause of vascular injuries in the general population. However, this case reports a rare complication of intravenous drug use (IVDU) that resulted in the development of a pseudoaneurysm (PSA) of the brachial artery (BA). Very few cases of BA PSA have been described in literature.¹ To the best of our knowledge, none of these cases occurred in relation to IVDU. In addition, the PSA's in most of the previously cases were not infected, while ours was.

Case presentation An 18-year-old female patient with extensive IVDU history presented to the emergency department (ED) complaining of pain, bluish discoloration, and swelling of her right (Rt.) upper extremity for 4 days. She was seen in ED 2 days prior to that for the same complaint, was not septic, had a negative roentgenogram of the Rt elbow, was prescribed oral antibiotics, and sent home. However, A computerised tomography (CT) scan of the Rt. upper extremity on her returning to the ED showed a 1.8-centimetre (cm) PSA of the

BA with a surrounding 3.6 cm fluid collection, suspected to be a hematoma, abscess or injected material. Despite intravenous antibiotics for her Methicillin-resistant *Staphylococcus aureus* (MRSA) bacteremia, cutaneous thromboembolic complications with erosions of multiple Rt fingertips could not be avoided. Her heart valves remained intact though. The swelling and pain continued to worsen. Therefore, a magnetic resonance imaging (MRI) with contrast was ordered. It showed a significant vascular compromise at the medial aspect of her forearm where the PSA obstructed the ulnar artery. The radial artery lumen was patent and so it maintained the circulation in her forearm and hand. Considering this finding, the vascular surgery service was consulted. When her repeat blood cultures proved sterile, the BA PSA was resected and grafted with a vein from her lower extremities. The patient circulation, swelling, pain, and discoloration improved afterwards with continuation of the intravenous antibiotics.

Summary Penetrating, blunt, and hemodialysis are the leading causes of arterial pseudoaneurysms and other malformations. However, given the rarity of IVDA association with this complication, a case of BA PSA was reported here.

REFERENCE

1. *Tex Heart Inst J* 2003;**30**(4):293–297.

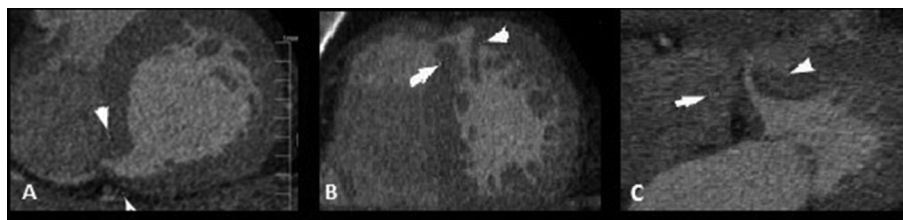
104 VENTRAL SEPTAL DEFECTS & VENTRICULAR ARRHYTHMIAS: NOT SO BENIGN

K Donovan*, M Nayyar, D Ardeshtna, S Alsafwah. *University of Tennessee Health Science Centre, Memphis, TN*

10.1136/jim-2017-000697.104

Case report Ventricular septal defects (VSD) are the most common congenital heart defect and is seen in approximately 38 infants per 1000 live births. Although relatively uneventful in the first 2 decades, arrhythmias become prevalent in the 3rd decade of life.

We present the case of a 52 year-old male who presented to the clinic with a one month history of palpitations and diaphoresis. Physical exam was significant only for a grade 2/6 holosystolic murmur best heard at the right lower sternal



Abstract 104 Figure 1 (A) There was a 3–4 mm ventriculospetal defect at the base of the heart inferiorly, slightly anterior to the coronary sinus, (B) Adjacent to this VSD, slightly more apical was a second contrast filled channel with possible right ventricle conduit, and (C) Also a third VSD (3.2 mm) between the left ventricle and the pulmonary outflow tract

border. Basic laboratory work up, including electrolytes and TSH were normal. ECG revealed sinus rhythm with incomplete right bundle branch block. TTE showed trace mitral and tricuspid regurgitation without evidence of elevated right heart pressures.

The patient noted palpitations and 19 beats of polymorphic non-sustained ventricular tachycardia were captured by Holter monitor. A cardiac catheterization revealed normal coronary arteries and evidence of possible VSD by left ventriculogram.

A CT heart with contrast identified multiple VSDs. There was a 3–4 mm ventriculospetal defect at the base of the heart inferiorly, slightly anterior to the coronary sinus (figure 1A). Adjacent to this VSD, slightly more apical was a second contrast filled channel with possible right ventricle conduit (figure 1B). Also a third VSD (3.2 mm) between the left ventricle and the pulmonary outflow tract (figure 1C).

A study in UK of adults with small VSDs noted a 2% incidence of ventricular arrhythmias and symptomatic arrhythmias in 8.5% of patients. Although this patient's VSD was classified as small, he is at an increased risk for malignant arrhythmias. There are limited studies investigating serious arrhythmias in patients with VSDs and no studies including patients with VSDs. We conclude that it is prudent to exclude inducible arrhythmias in patients with small VSDs given their underlying diseased conduction system, increased prevalence, and increased risk of sudden cardiac death when presenting with lifestyle limiting symptoms.

105

CARDIAC SARCOIDOSIS: A LETHAL ARRHYTHMIA PRESENTATION

JR Rivas*, KR Green, J Shah, F Rollini. *University of Florida, Jacksonville, FL*

10.1136/jim-2017-000697.105

Case report A 50-year-old male with history of stage four sarcoidosis, non-ischaemic cardiomyopathy with non MRI compatible implantable cardioverter-defibrillator (ICD) for secondary prevention who presented to our institution after a spontaneous ICD discharge. Interrogation of his device revealed appropriate ICD discharge for a sustained monomorphic ventricular tachycardia that failed anti-tachycardia pacing. Left heart catheterization was performed to evaluate for possible ischaemic precipitant of his arrhythmia, however, revealed normal coronary arteries. He was then started on anti-arrhythmic control with Sotalol. A PET scan was performed which showed mild to moderate increased uptake within the anterior and anteroseptal wall of the left ventricular myocardium suspicious for active inflammatory from cardiac sarcoidosis. Thus he was treated with prednisone. No other episodes of

monomorphic ventricular tachycardia were observed. He was then discharged with cardiology follow-up.

Discussion This case supports that sarcoidosis with cardiac involvement is an important entity that leads to life-threatening disorders. It is found in at least 5% of patients that could be asymptomatic or present with heart block, congestive heart failure, lethal arrhythmias or sudden death. Cardiac involvement may occur at any point during the course of sarcoidosis and may occur in the absence of pulmonary or systemic involvement. Conduction disturbances and arrhythmias are the most common cardiac manifestations and reflect granulomatous infiltration within the conduction system or ventricular walls. Noncaseating granulomas in the ventricular myocardium is a potential focus for abnormal automaticity, increasing the risk for reentrant tachyarrhythmias such as ventricular tachycardia. Prognosis of cardiac sarcoidosis can account for upto 65% deaths from it.

Conclusion Cardiac sarcoidosis may occur alone or alongside systemic sarcoidosis but could be frequently clinically silent. Due to initial non-specific findings, the diagnosis can be challenging, frequently missed or delayed. Echocardiography, MRI, PET or Nuclear scan and Endomyocardial biopsy are some of the available modalities for diagnosis. Early recognition and diagnosis is imperative, especially in symptomatic patients due to the high risk of lethal complications.

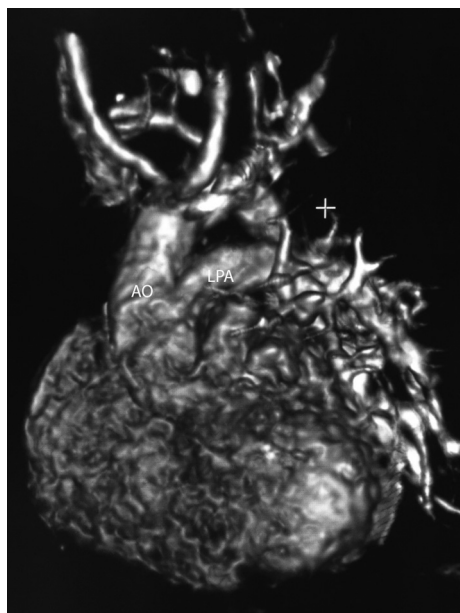
106

TETRALOGY OF FALLOT AND ANOMALOUS ORIGIN OF THE LEFT PULMONARY ARTERY FROM THE ASCENDING AORTA IN A NEWBORN PATIENT WITH DIGEORGE SYNDROME

¹C Schmitt*, ¹G Pridjian, ¹A Dunbar, ²J Caspi, ¹S Yang. ¹Tulane University School of Medicine, New Orleans, LA; ²LSUHSC School of Medicine, New Orleans, LA

10.1136/jim-2017-000697.106

Case report Anomalous origin of the left pulmonary artery (AOPA) is a rare cardiac defect that is more commonly associated with conotruncal heart defect and 22q11 deletion syndrome. The natural history of AOPA without surgical correction is the onset of congestive heart failure, pulmonary hypertension and severe pulmonary vascular obstructive disease, that has a 30% 1 year survival rate. This case reports a newborn with a prenatal diagnosis of Tetralogy of Fallot and DiGeorge Syndrome found to have an anomalous origin of the left pulmonary artery from the ascending aorta. The cardiac anatomy was confirmed by 3-D CT angiogram before the newborn underwent successful complete surgical repair. This case highlights the importance of a genetic testing for 22q11 deletions in fetuses diagnosed with conotruncal cardiac malformations, and the significance on recognition of AOPA in postnatal echocardiogram for newborns diagnosed with Tetralogy of Fallot.



Abstract 106 Figure 1 Computed tomographic angiography of the chest demonstrating the left pulmonary artery [LPA] originating from the ascending aorta [AO]

107 COLLISION IN MY HEART

EK Swe*, MN Alexander, ME Hall. *University of Mississippi Medical Centre, Jackson, MS*

10.1136/jim-2017-000697.107

Introduction The differential diagnoses of right atrial (RA) masses are normal variants, primary cardiac tumours, secondary tumours and thrombi. Collision tumour of hepatocellular carcinoma (HCC) and cholangiocarcinoma is very rare, and to our knowledge cardiac involvement has not been reported. Therefore, one needs to be aware of the possible direct extension of hepato-biliary carcinoma while evaluating an RA mass. **Case A** 58-year-old white man with coronary artery disease status post CABG 8 months prior, diabetes mellitus and hypertension presented to his cardiologist's office with extreme fatigue, dyspnea and weight loss for 6 weeks. Physical examination was remarkable for only mild hypotension and pallor. In-office echocardiogram showed normal left ventricular systolic function with a new right atrial mass, measuring 4.2 cm × 2.1 cm extended from the inferior vena cava, partially prolapsing into the right ventricle in diastole. Admission laboratory findings revealed acute renal failure (estimated glomerular filtration rate was 15) and abnormal liver enzyme levels. Chest X-ray showed a new 1.6 cm nodular density at left lung base. Venous Doppler showed venous thrombosis in the lower extremities. CT scan of chest, abdomen and pelvis as malignancy workup revealed a large infiltrating right liver mass. Labs were positive for markedly elevated alpha-fetoprotein but negative for hepatitis panel. Two-phase MRI showed a large (17 cm) necrotic mass with features consistent with a collision tumour of HCC and cholangiocarcinoma, extending via IVC cranially into the right atrium and caudally into the renal veins. After thorough discussions regarding the extensive

and aggressive nature of the disease, treatment options were limited. The patient and family opted for home hospice. He was discharged home and passed away 3 days posts discharge. **Discussion** A unique case of a collision tumour of HCC and cholangiocarcinoma extending into the inferior vena cava and right heart had an aggressive clinical course. Collision tumour of HCC and cholangiocarcinoma is extremely rare with few symptoms until alerted by metastasis. It is even more unusual for such tumour to have cardiac involvement. The different diagnosis of RA mass should include not only the common aetiology, but also the collision tumour of HCC and cholangiocarcinoma.

108 GIANT CORONARY ANEURYSMS IN A PATIENT WITH NOONAN SYNDROME

PR Thurmond*, EM Khansur, WF Campbell, ME Hall, C Richards, G Aru, MR McMullan. *University of Mississippi Medical Centre, Jackson, MS*

10.1136/jim-2017-000697.108

Case report Coronary artery aneurysm is defined as a localised luminal dilation of at least 1.3 to 2 times the diameter of a normal adjacent reference segment. Giant coronary artery aneurysms (GCAA) are generally defined as dilation of the artery greater than 4 times the reference diameter. GCAAs are very rare, with an estimated prevalence of 0.02%–0.2%.

We present a 35-year-old black man with a history of Noonan syndrome variant and mental retardation, who was referred for surgical evaluation of ascending aortic root dilation and left anterior descending (LAD) GCAA. During initial evaluation for Noonan syndrome in childhood, an echocardiogram was performed revealing the presence of aortic root dilation. Due to progression of the dilation on echocardiogram in 2010, a chest CT was obtained which noted an aneurysm of the LAD. While not formally diagnosed, review of old records revealed symptoms consistent with Kawasaki disease as an infant. In 2016, CT angiography demonstrated diffuse coronary ectasia with a GCAA in the proximal LAD measuring over 50 mm with a dilated aortic root measuring 57 mm. There was also noted mild fusiform aneurysmal dilation of the left branch pulmonary artery measuring 30 mm in maximal diameter. Repeat echocardiogram showed moderate concentric left ventricular hypertrophy consistent with cardiac findings in Noonan syndrome. Prior to surgery, a coronary angiogram revealed stenosis distal to the aneurysm. In May 2016 he underwent valve sparing root placement, aortic valvuloplasty, septal myectomy, and coronary artery bypass graft (CABG) with left internal mammary artery to LAD without ligation of the GCAA. Current post-operative management includes beta-blocker, anticoagulation, and aspirin.

GCAAs are rare occurrences most often attributed to atherosclerosis, vasculitis including Kawasaki disease, and connective tissue disease. Clinical sequelae include thrombus formation, distal embolization, fistula formation, and rupture. Surgical correction is generally the preferred treatment including CABG with or without resection or ligation of the aneurysm. In the absence of ligation of the GCAA, the decision was made to initiate anticoagulation to reduce the risk of thrombus embolization.

109 WELLEN'S SIGN IN AN ATYPICAL PRESENTATION OF STROKE

S Werner*, LS Engel. *LSU Health Sciences Centre, New Orleans, LA*

10.1136/jim-2017-000697.109

Introduction Wellen's sign is an ominous EKG finding, suggestive of significant stenosis of the left anterior descending (LAD) artery, with a high risk of progression to myocardial infarction if untreated.

Case A 73 year-old man without reported medical history presented to the Emergency Department (ED) after a losing consciousness while running on his treadmill. The patient was performing his morning exercise, and without warning or prodromal symptoms, had spontaneous loss of consciousness. His wife found him on the floor and activated EMS. The patient was reportedly altered until arrival to the ED, where a Code Stroke was activated. Initial computed tomographic scan of the head was unremarkable but MRI showed an acute right frontal lobe CVA. Initial troponin was 0.94 and EKG did not suggest changes associated with ischemia. The patient was admitted to the ICU for stroke workup and monitoring. On exam, he did not have any neurologic deficits or chest pain. Troponins trended to 9.01 and EKG showed dynamic changes, which included deep inverted T-waves in V2-V3, and V4-V6. Echocardiogram showed apical dyskinesis, without left ventricular thrombus. Cardiology was consulted, and angiography showed a 95% stenosis in the proximal Left Anterior Descending Artery (LAD), which was opened with a single drug eluting stent. The patient was discharged on dual antiplatelet therapy, ACE inhibitor and a statin. Apixaban was also prescribed due to his apical akinesis and new onset stroke. Continuation of apixaban would be re-evaluated after a repeat echocardiogram could be performed as an outpatient.

Discussion This patient had an atypical presentation of stroke and myocardial infarction. A Wellen's pattern was identified and stenosis in the proximal LAD was diagnosed with angiography. The characteristic biphasic T-wave or deeply inverted T-wave seen in leads V2-V3 are a result of myocardial reperfusion, and should alert clinicians to the likelihood of obstructive coronary disease.

Endocrinology and metabolism

Joint plenary poster session and reception

4:30 PM

Thursday, February 22, 2018

110 FUNCTIONS OF LONG NON-CODING RNA IN TRIMETHYLAMINE N-OXIDE PRODUCTION

MA Al-Obaide*, T Vasylyeva. *Texas Tech University Health Science Centre, Amarillo, TX*

10.1136/jim-2017-000697.110

Purpose of study We recently provided evidence of the elevated levels of trimethylamine N-Oxide (TMAO) in type 2 diabetes mellitus (T2DM) and chronic kidney disease (CKD) patients, which strongly links to cardiovascular diseases [Al-Obaide *et al.*, 2017]. Five FMO genes are differentially

expressed in liver, kidney, and other tissues and are involved in the production of TMAO that promotes vascular inflammation through NF- κ B signalling. Long non-coding RNAs (lncRNAs), 200 nucleotides to many kilobases in length, are found to have critical functions in the tissue-specific regulation of gene expression and considered therapeutic targets. The objective of this study was to investigate unexplored regulatory functions of lncRNAs LOC105371611 in the expression of FMO genes.

Methods used NCBI-Gene/Nucleotide, UCSC Genome Browser, Ensembl, were used to search for the genomic setting of FMO and lncRNAs genes. The locations of the identified sequences were verified and updated to hg38 version of human genome sequence by the BLAT tool. RNA expression of FMO genes and LOC105371611 (lncRNA) were extracted from the data in the NCBI-Gene/HPA RNA-seq normal tissues. Identification of mature sequences (miR) of lncRNA transcript was performed by using the miRBase BLASTN search tool. The miRNA recognition element (MRE) of FMO transcripts, were analysed and identified by the RNA22 v2 tool.

Summary of results To date, there are no reports on the regulatory functions of lncRNAs in FMO expression. The FMO and lncRNA LOC105371611 mRNAs showed differential expression in the kidney and liver, which indicated the tissue-specific pattern. Our analysis showed the lncRNA LOC105371611 locus mapped contiguous to FMO1 and FMO3 and hosted FMO2 produce miRNA mature sequences (miR) could target the MRE of FMO transcripts and consequently, downregulate the TMAO production.

Conclusions This study provided insight into the functions of lncRNA LOC105371611 to downregulate FMO genes' expressions at transcriptional and posttranscriptional levels in the kidney and liver and could be exploited in targeted therapy of T2DM-CKD.

111 SHORT-TERM EFFICACY AND SAFETY PROFILES OF INTRAVENOUS CONTINUOUS GLUCAGON INFUSION FOR THE MANAGEMENT OF REFRACTORY NEONATAL HYPOGLYCEMIA

J Bhat*, A Kaulfers, M Zayek, R Bhat, F Eyal. *USA, Mobile, Alabama, Mobile, AL*

10.1136/jim-2017-000697.111

Purpose of study Intravenous continuous glucagon infusion is one of the treatment options for persistent neonatal hypoglycemia despite high glucose infusion rates. However, in the literature, limited published data exist on its short-term safety and efficacy. Hence, our objective was to evaluate the efficacy and safety profiles of continuous glucagon infusion for treating refractory hypoglycemia in moderately preterm and term neonates.

Methods used In this retrospective, single-centre study, neonates born at ≥ 30 weeks of gestational age from 2012 through 2014, treated with intravenous continuous glucagon infusion for refractory hypoglycemia (blood glucose levels persistently < 47 mg/dl despite high glucose infusion rates) were included. The lowest blood glucose, serum sodium, and serum bicarbonate values twelve hours before and up to 24 hours after the initiation and stoppage of glucagon infusion were collected and compared.

Summary of results Totally, 26 neonates with mean (\pm SD) gestational age (weeks) of 36 (\pm 2) and birth weights (g) of 2990 (\pm 868) were included in the study. Among the included infants, 13 (50%) were preterm, and 18 (69%) were infants of diabetic mothers. During the first 24 hours of glucagon treatment, lowest blood glucose levels increased from a mean (\pm SD) of 26 (\pm 10) mg/dl to 61 (\pm 13) mg/dl ($p < 0.01$). The rates of hyponatremia, thrombocytopenia and metabolic acidosis were comparable before and during the periods of glucagon infusion (table 1).

Conclusions In this study, intravenous continuous glucagon infusion was efficacious in improving blood glucose levels in neonates with refractory hypoglycemia without causing short-term adverse events.

Abstract 111 Table 1 Short-term efficacy and safety profiles of intravenous continuous glucagon infusion in 26 neonates

Variables	Intravenous continuous glucagon infusion			P value	
	Before (12 hour period)	During (24 hour period)	After (24 hour period)	Before vs during	Before vs after
Lowest blood glucose (mg/dl)	26 \pm 10	61 \pm 13	68 \pm 21	<0.001	<0.001
Maximum intravenous fluid glucose infusion rates (mg/kg/min)	7.7 \pm 2.3	7.5 \pm 2.6	4.9 \pm 3.2	0.73	0.001
Number of hypoglycemic episodes, n	4 \pm 2	1 \pm 1.4	1 \pm 2	<0.001	<0.001
Intravenous fluid volume (ml/kg/day)	85 \pm 24	77 \pm 24	50 \pm 31	0.22	<0.001
Hyponatremia (serum sodium<135), n (%)	10(38)	7 (27)	4 (15)	0.37	0.06
Thrombocytopenia (platelets<100, 000/ml), n (%)	5 (19)	5 (19)	3 (11)	>0.99	0.42
Metabolic acidosis (serum bicarbonate<18 mEq/L), n (%)	3 (11)	1 (3)	2 (8)	0.3	0.63

112 A RARE CASE OF EMPHYSEMATOUS URINARY TRACT INFECTION

JA Carlson*, J Verdecia, C Horn, J Ruiz, R Javb. *University of Florida, Jacksonville, FL*

10.1136/jim-2017-000697.112

Case report A 41 year old female with history of diabetes mellitus (haemoglobin A1c 12.4%) with neuropathy, gastroparesis, and neurogenic bladder presented with complaint of abdominal pain and intractable vomiting. On physical exam, the patient was afebrile, with tenderness at the left costovertebral angle and suprapubic area. Workup showed serum white blood cells (WBCs) of 15 125. Urinalysis had 180+WBCs, 500+glucose, and nitrites. Abdominal CT showed gas in the urinary bladder and urine culture grew *Klebsiella pneumoniae*. A foley catheter was placed and she was treated with 2 weeks of antibiotics.

Emphysematous UTIs (EUTIs) are infections of the lower or upper urinary tract associated with gas formation. Air seen on imaging along the urinary tract along with nitrites on

urinalysis is essentially pathognomonic for EUTI diagnosis. Although extremely rare (less than 135 reported cases in English literature before 2006) they are becoming more prevalent in the United States. This is due to 2/3 of cases involving diabetics, and in the U.S. the number of diabetics increased 4 fold from 1980 to 2014, totaling over 20 million. EUTI pathogenesis is poorly understood, but it is believed increased glucose in diabetic urine provides nutrients for glucose fermenting bacteria to thrive.

Emphysematous cystitis can usually be treated with medical therapy, 90% requiring IV antibiotics until susceptibilities are returned. Bladder irrigation may be needed if blood clots are present, and catheter placement is often required in order to rest the bladder and prevent bladder tamponade. If there is still no improvement, surgery may be necessary.

The typical EUTI patient is a female (2:1 female to male ratio), over the age of 60, with a hgbA1c of 10% or higher. These patients can present asymptotically or in florid sepsis, but most often with abdominal pain. In over 80% of cases *Escherichia coli* or *Klebsiella* are the identified culprits, however, fungal and more ominous bacterial strains (*Pseudomonas*, *Staphylococcus*) have been reported. It is critical hospitalists are able to recognise EUTIs as even with proper antibiotic treatment, EUTIs have a mortality rate of 7%. If the diagnosis is missed, a patient can progress to emphysematous pyelonephritis where mortality approaches 40%.

113 DOES PKC MEDIATE THE HIGH RISK OF PREECLAMPSIA IN PREGNANT WOMEN WITH DIABETES?

^{1,2*}RP Chow, ²J Zhao, ²TM Curtis, ¹T Lyons, ¹J Yu. ¹Medical University of South Carolina, Charleston, SC; ²Queen's University Belfast, Belfast, UK

10.1136/jim-2017-000697.113

Purpose of study Preeclampsia (PE) is a leading cause of pregnancy-related mortality and morbidity, and its prevalence is 4-fold higher in women with diabetes vs those without, but the underlying mechanism is unclear. The anti-angiogenic factor soluble fms-like tyrosine kinase-1 (sFlt1) plays an important role in the pathogenesis of PE. Evidence suggests that PKC activation, which is associated with the development of diabetic vascular complications, may mediate the enhanced sFlt1 release in non-trophoblast cell types; but it is unclear whether this mechanism occurs in the placenta and thus mediate the high risk of PE in diabetes. We aimed to determine:

- the role of PKC in the regulation of sFlt1 expression in a human placental trophoblast cell line
- whether diabetes-relevant conditions promote sFlt1 expression via the PKC pathway.

Methods used Quiescent human trophoblast HTR-8/SVneo cells were treated with the PKC activator phorbol-12-myristate-13-acetate (PMA), or the diabetes stimuli 'heavily oxidised, glycated' low-density lipoproteins (HOG-LDL) vs native LDL \pm glucose, over 24 hours, with or without PKC inhibitor GF109203X. Both sFlt1 mRNA expression (RT-PCR) and protein release (ELISA) were measured.

Summary of results We found that 5 nM PMA increased sFlt1 mRNA expression ($p \leq 0.001$ for sFlt1e15a) and protein release ($p \leq 0.001$) in HTR-8/SVneo cells; this effect was abrogated by the pre-treatment of 5 μ M GF109203X ($p \leq 0.001$ for sFlt1e15a expression, $p \leq 0.001$ for protein). Similarly, 50 μ g/ml HOG-

LDL increased sFlt1 expression ($p \leq 0.001$) and protein release ($p \leq 0.001$), which were attenuated by GF109203X. However, glucose did not appear enhance the effect of HOG-1DL.

Conclusions The results are consistent with the possibility that modified lipoproteins may promote PE development in women with diabetes, likely via a PKC-mediated up-regulation and release of sFlt1. These findings provide new insights into the disease mechanism, and potential targets for developing preventative and interventional measures for PE.

114 A CASE OF CUSHING SYNDROME

K Ellard*, B Hartman, LS Engel, T deSilva. *LSU Health Sciences Centre, New Orleans, LA*

10.1136/jim-2017-000697.114

Case report Cushing's syndrome is characterised by over-secretion of cortisol. Three main subtypes of Cushing's syndrome exist:

- Cushing's disease,
- ACTH dependent release of glucocorticoid (ectopic ACTH syndrome),
- Adrenal overproduction of cortisol such as seen in an adrenal adenoma or carcinoma.

A 28 year old woman presented to Endocrine clinic for evaluation of secondary amenorrhea of 2 years duration. The patient did not bleed in response to a progesterone challenge and was subsequently referred to Endocrine clinic. She was anxious and tearful. She denied any recent acne, excess hair growth, or voice deepening. She had not experienced galactorrhea or problems with peripheral vision. She noted intermittent tension headaches, fatigue, polydipsia, polyuria, easy bruising, and weight gain distributed primarily on her face, abdomen, and the back of her neck. At presentation, her BMI was 21.7 kg/m² and physical exam demonstrated a round face with increased facial plethora, and an increased posterior fat pad. Significant labs included DHEA sulfate 15 mcg/dL (18–391 mcg/dL), FSH 6.3 mIU/mL, estradiol <15 pg/mL for a non-premenopausal woman (19–357 pg/mL), total testosterone 3 ng/dL (2–45 ng/dL), prolactin 25.9 ng/dL (3.0–30 ng/dL), ACTH <5 pg/mL (6–50 pg/mL), and AM cortisol of 22.9 mcg/dL (<2.0 mcg/dL), following administration of 1 mg of dexamethasone the previous evening. Repeat low dose dexamethasone suppression test was significant for an AM cortisol 20.7 mcg/dL (4–22 mcg/dL) and dexamethasone 258 ng/dL. CT Abdomen revealed a left side adrenal mass. Left adrenalectomy was performed and pathological was consistent with an adrenal cortical adenoma. Her post-operative midnight salivary cortisol levels were appropriately low. Her menstrual cycles gradually returned, facial plethora and sites of abnormal fat deposition resolved and she reported a significant improvement in her psychological well-being

Menstrual irregularities are very common in women with Cushing's syndrome. Curative treatment for an adrenal source of Cushing's syndrome is unilateral adrenalectomy. Post-operatively, patients may experience transient adrenal insufficiency due to contralateral suppression of the other adrenal gland. Post-operatively, resolution of symptoms of Cushing's syndrome usually occurs over a period of several months.

115 TRIPLE THREAT AFTER CRANIOPHARYNGIOMA RESECTION REQUIRES CLOSE ATTENTION

¹HV Gates*, ¹N Arshad, ²N Tangutur, ¹R Smalligan. ¹UAB, Huntsville, AL; ²Huntsville Hospital, Huntsville, AL

10.1136/jim-2017-000697.115

Case report A 71 yo AAF with a h/o HTN and hyperlipidemia underwent trans-sphenoidal surgery for craniopharyngioma. On post-op day (POD) 2, she developed polydipsia and polyuria requiring DDAVP for early diabetes insipidus (DI). She went home on POD 5 with a Na of 146. POD 7 she had nausea and vomiting that worsened and was accompanied by weakness, disorientation, and an inability to keep food down. She was brought to the ER on POD 10. Home meds: aspirin, losartan, gabapentin, baclofen and diltiazem. PE: disoriented woman with a normal exam except for nonfocal, generalised weakness and decreased vision in her right visual field. Labs: Na 107 and otherwise WNL. The patient was admitted to the ICU and started on 3% saline with q2 hr monitoring of Na. Her Na and symptoms slowly improved.

Discussion Trans-sphenoidal surgery is commonly needed for symptomatic pituitary adenomas but is also required for craniopharyngioma rx. Damage to the hypothalamus during surgery (or trauma) can result in a triphasic response in a minority of patients. First, the polyuric phase results from inhibition of ADH release due to hypothalamic dysfunction. It starts within 24 hour of surgery and can last 5 days. Second, the antidiuretic phase results from stored hormone being released from remnants of the posterior pituitary. This phase can last 5–7 more days. Excessive water intake during this phase can lead to severe hyponatremia due to transient ADH secretion. Third, the permanent DI phase occurs due to complete depletion of ADH from the posterior pituitary. Less than 20% of patients experience all three phases.

Each phase requires a unique treatment approach. IV desmopressin or dilute arginine ADH is used for the polyuric phase. The antidiuretic phase is treated like SIADH: stopping IVF and restricting PO fluids. If severe hyponatremia continues or the patient is symptomatic, then 3% saline may be used. Patients who enter the third phase of permanent central DI require regular desmopressin. Treatment of these patients is delicate and challenging because of variation in patient presentation and treatment responses, and few studies help guide management. However, treatment should include a multidisciplinary team approach.

116 IMPLEMENTING THE AMERICAN ACADEMY OF PAEDIATRICS RECOMMENDATIONS ON SCREENING PRETERM INFANTS AT RISK FOR METABOLIC BONE DISEASE

¹O Ginnard, ¹S Jain, ¹A Nella, ²CL Blanco, ²K Bonagurio, ²A Moreira, ³AC Calabria. ¹University of Texas Medical Branch, Galveston, TX; ²University of Texas Health Science Centre of San Antonio, San Antonio, TX; ³Children's Hospital of Philadelphia, Philadelphia, PA

10.1136/jim-2017-000697.116

Purpose of study Metabolic bone disease of prematurity (MBD) remains a common comorbidity in ELBW neonates. In 2013, AAP provided a Consensus Statement on screening and

treating MBD in high-risk preterm infants. Our goal was to i) evaluate the feasibility of implementing a modified AAP MBD practice guideline-based protocol, ii) describe preliminary findings, and iii) identify potential barriers to implementation.

Methods used An 18 month retrospective study in ELBW neonates without major anomalies was conducted. Bone minerals and markers obtained at 4–6 weeks of age included: serum alkaline phosphatase (APA), calcium (Ca), phosphorus (P), magnesium (Mg), parathyroid hormone (PTH), and 25-OH-vitamin D (25-OH-D).

Summary of results 46 neonates were included. APA, Ca, P, and Mg were available in 43 (93%) neonates, while PTH and 25-OH-D in 76%, drawn at 36 ± 18 days of life. Mean gestational age was 26 ± 2 weeks with a birth weight of 773 ± 140 grams. At one month of age 52% were receiving parenteral nutrition and 87% had advanced to fortified feeds. Ca, P, Mg were all within normal limits whereas APA, 25-OH-D, and PTH values were 423 ± 188 IU/L, 33 ± 15 ng/mL, and 137 ± 103 pg/mL, respectively. Of note, 3 of 43 (7%) neonates had APA levels >800 IU/L and 4 out of 36 (11%) had 25-OH-D levels <20 ng/mL, the latter normalised with supplementation. Radiographic findings were not obtained on patients with APA >800 . Barriers to implementation included: volume of blood draw, cost, faculty preference, and collaboration with radiologists.

Conclusions Implementation of a practice guideline-based protocol focusing on MBD in ELBW infants is feasible. These preliminary findings suggest that serum bone analytes may demonstrate abnormalities as early as 4–6 weeks after birth and require further study. Limitations include small sample size, single-institution, and absence of bone imaging.

117 REPEATEDLY IN RHABDO

C Gooch*, L Marzullo. *UAB, Birmingham, AL*

10.1136/jim-2017-000697.117

Case report Repeated presentations of an uncommon symptom in a patient should prompt a physician to evaluate for rare conditions. A teenager presented to the Children's of Alabama ED with recurrent episodes of rhabdomyolysis and weakness. He was eventually diagnosed with McArdle's Muscular Dystrophy, Glycogen Storage Disease Type V. His rhabdomyolysis has been severe, with a creatine kinase measurement of $>320,000$, myoglobinuria, transaminitis and elevated bilirubin. He has a low threshold for going into rhabdomyolysis, such as doing an hour of aerobic exercise two days in a row.

McArdle's Disease is a Glycogen Storage Disorder in which the skeletal muscle cannot turn glycogen into glucose. Unlike other glycogen storage disorders, this only affects skeletal muscle, sparing the brain and visceral organs, and leading to a vague phenotype. These patients have exercise intolerance, rhabdomyolysis, and muscle cramps. Many patients report loading with simple carbohydrates before exercise as they have learned this can increase their stamina. The vague symptoms can lead to decades of delayed diagnosis and significant mismanagement.

Rhabdomyolysis is the most severe finding in McArdle's Disease and it can lead to acute kidney injury, requiring dialysis in the severest cases. Rhabdomyolysis has numerous causes, but recurrent episodes, especially with seemingly insignificant triggers, should prompt a broader differential and advanced testing. This testing can include specific exercise tests, genetic sequencing, and muscle biopsy. Our presentation will guide the clinician through the process of evaluating recurrent rhabdomyolysis, working through a differential diagnosis and testing options.

118 HYPOTHYROIDISM & DVTS

M Henry*, AW Maier. *UMMC, Jackson, MS*

10.1136/jim-2017-000697.118

Introduction First discovered in the nineteenth century, hypothyroidism was diagnosed after observing the effects of the surgical removal, which resulted in systemic tissue swelling. The pathology of thyroid disease, either through hypothalamic dysfunction or primary thyroid failure, results in a generalised slowing of the metabolic processes leading to a plethora of abnormalities affecting nearly all body systems. Here we report an atypical presentation of hypothyroidism.

Case report A 74 year old African American female with history of hypertension, diabetes mellitus, hyperlipidemia, and previous history of treated TB presented with a chief complaint of right leg pain for three weeks, most prevalent in her right hip and foot. She had been bed-bound for over one year after months of severe depression following the death of her brother, resulting in severe deconditioning further worsening her weakness.

On physical exam, patient was found to have significant bilateral lower extremity pitting oedema, cold feet, and decubitus ulcers on the right heel and midline sacrum. A CT lower extremity and abdomen/pelvis was obtained showing filling defect in right common femoral vein concerning for DVT, body wall oedema, diffuse lower extremity oedema. Doppler ultrasound of bilateral lower extremities showed multiple non-occlusive DVTs in both legs and one occlusive DVT in the right femoral vein. It was felt that these clots were a result of the patient's extended immobility. Thyroid function labs were tested due to her history of depression and her significant weakness and fatigue. Laboratory evaluation resulted in a high TSH level of 20.2 mIU/mL, low T4 measurement of 0.312 ng/dL and subsequently found to have thyroid peroxidase antibody of 443.56 IU/mL and antithyroglobulin antibody 28.94 IU/mL. She was started on Synthroid 50 mcg. During hospitalisation, her weakness improved with physical therapy and she was discharged to an acute rehab facility with outpatient follow up and thyroid ultrasound scheduled in 4 weeks.

Discussion 1. Hypothyroidism can manifest through a wide variety of clinical presentations and must never be overlooked as an underlying aetiology for a patient's symptoms, even with an atypical picture. 2. When treating a patient with depression, even with a clear instigating factor, thyroid dysfunction should still be considered as an underlying cause.

119 'BI-ECTOPICS': THYROID CANCER AND PARATHYROID ADENOMA

N Jain*, W Bibars, H Steinberg. *University of Tennessee Health Science Centre, Memphis, TN*

10.1136/jim-2017-000697.119

Background Most thyroid cancers and parathyroid adenomas are eutopic. About 400 cases of ectopic thyroid cancer have been reported while mediastinal parathyroid adenoma (MPA) is commonly identified on autopsies than during surgery. We report an interesting case of both ectopic thyroid malignancy and MPA.

Case A 54 year old Caucasian woman with heart failure and COPD stage IV presented with an enlarging left neck mass causing odynophagia and shortness of breath. Vital signs were stable. On examination, normal oral cavity, without tonsillar masses or tongue base lesions, and normal thyroid. She had an obese neck, with a palpable, firm, non-mobile, non-tender mass in left level IB/II without other palpable masses. Thyroid function normal: TSH 3.24 mIU/ml, Free T4 1.35 ng/dL, but calcium high at 11 g/dL. Two ultrasound guided Fine Needle Aspirations were non-diagnostic and laryngoscopy normal. CT scan neck showed a 4 cm complex necrotic mass suggestive of squamous cell or salivary gland malignancy. A core-needle biopsy showed a malignant lesion of unknown primary: positive for TTF-1 and HBME-1, and negative for Napsin A and thyroglobulin. A diagnosis of papillary thyroid malignancy TxN2aMO was preliminarily made, and she underwent thyroidectomy with sentinel lymph node and neck dissection. Incidentally during surgery, a large anterior mediastinal mass was found. It was identified as thymic enlargement and was removed. Pathology showed normal native thyroid and left parathyroid gland, right parathyroid showed benign thyroid tissue. 13.4×6×5.3 cm thymic mass showed enlarged and hypercellular parathyroid gland (2 cm), with small amount of benign thymic tissue. The 1.8 cm left submandibular mass had mixed components of papillary thyroid cancer (TTF-1+) with de-differentiation into squamous cell components (p40, CK5/6 +), both with psammomatous calcifications. A final diagnosis of papillary thyroid cancer of ectopic thyroid tissue and parathyroid ectopic in thymus was made.

Conclusion Our case highlights peculiarity of two ectopic glands in an adult female presenting as malignancy of ectopic thyroid and a ectopic parathyroid adenoma in the thymus gland, which is usually regressed in adults.

120 EXTREME PARATHYROIDEMIA

N Jain*, A Wynn, A Ogunsakin, H Steinberg. *University of Tennessee, Memphis, Memphis, TN*

10.1136/jim-2017-000697.120

Background Parathyroid hormone (PTH) elevation is frequently associated with a parathyroid adenoma. Levels >1000 pg/ml are almost always due to parathyroid carcinoma, unless proven otherwise.

Case 67 year old African American female brought in for abdominal pain, confusion and lethargy for 3 days. She also had change in her speech and gait. Vital signs stable; exam with abdominal tenderness, disorientation, slow speech and unsteady gait. Workup for sepsis and stroke was normal. On labs, she had low potassium (3.1 mmol/L) and magnesium

(1.5 mg/dL) but elevated Calcium (Ca) (14.1 mg/dl) and PTH (901 pg/ml). Albumin (3.5 g/dL) and 25(OH)Vitamin D (18.4 ng/ml) were low while renal function normal. She was treated with fluids, cinacalcet and pamidronate. A sestamibi scan showed a left lower parathyroid adenoma and nodular thyroid tissue on the right. Adenoma resection was performed. Ca and vitamin D replacement started for prevention of hypocalcemia. On one-week follow up, pathology showed 1.15 g hyper-cellular parathyroid tissue, PTH 257 pg/ml and Ca 12.9 mg/dl. The Ca-carbonate dose was reduced, cinacalcet restarted and labs repeated in 6 weeks. She was called for admission when PTH came at 647 pg/ml and Ca 15.1 mg/dl. Repeat tests confirmed elevated PTH 1999 pg/ml and Ca 14.2 mg/dl and low normal PTH-related peptide. Ultrasound revealed a new parathyroid adenoma to the right of thyroid lobe and sestamibi showed persistent nodular thyroid. Concerned for malignancy, a CT neck/chest was performed showing 5.5 cm heterogeneously enhancing mass posterior to trachea, increased in size, contiguous with right thyroid and suspicious for malignancy, but without metastasis. Subsequently, right parathyroidectomy and hemithyroidectomy were performed revealing a 2.5 cm pale, firm, well circumscribed, focally haemorrhagic mass; pathology reported a parathyroid adenoma and benign nodular hyperplasia of thyroid. A work up for Multiple Endocrine Neoplasia-1 was recommended, however the patient declined and was discharged home.

Conclusion Very high PTH (>1000) and Ca levels (>14 mg/dl) are associated with parathyroid malignancy, but can be reported with parathyroid adenomas, as highlighted by our case.

121 MATURE ONSET DIABETES OF THE YOUNG: A RARE BUT IMPORTANT ENTITY OF DIABETES

AL Marle*, RE Guinto. D Dwight. *Eisenhower Army Medical Centre, Fort Gordon, GA*

10.1136/jim-2017-000697.121

Case report Mature onset diabetes of the young (MODY) is a group of genetic disorders manifested by non-ketotic diabetes mellitus, autosomal dominant mode of inheritance and age of onset before 25 years. Though rare, accounting for only 1% to 2% of all cases of diabetes, MODY is often misdiagnosed as type 1 or type 2 diabetes. Given this disorder is autosomal dominant, diagnosing this distinct endocrine disorder from the more common forms of diabetes has treatment and prognostic implications across generations.

Here we report a 33 year old Caucasian male with MODY subtype 5. The patient initially presented with diabetes at the age of 24. His BMI was 22 and he participated in regular physical activity. Routine labs obtained at the time of presentation showed an elevated fasting glucose, glucosuria and a haemoglobin A1C of 9.2%. Glutamic acid decarboxylase autoantibodies were obtained to evaluate for type 1 diabetes but found to be negative. He was given a formal diagnosis of type 2 diabetes mellitus and started on appropriate oral diabetic medications. After one year his haemoglobin A1C improved to 6.8%.

Over the next few years, however, the patient demonstrated worsening glycemic control and was referred to Endocrine. Interestingly, the patient reported no family history of diabetes. Additional pancreatic autoantibodies were obtained but negative (tyrosine phosphatase-like protein IA2 and zinc transporter 8). Imaging demonstrated an atrophic pancreas and multiple renal

cysts. Lantus was added to Metformin and Sitagliptin which improved the patient's fasting blood glucose levels.

In MODY 5, a mutation occurs in the hepatocyte nuclear factor 1 β (HNF-1 β) gene. Normally, this gene produces transcription factors that regulate insulin production. In addition to defective insulin production, the mutations in HNF-1 β are associated with pancreatic agenesis, renal abnormalities, genital tract malformations and liver dysfunction. Our patient was found to have a heterozygous frameshift mutation in the HNF-1 β gene confirming the diagnosis of MODY 5.

This case highlights the phenotypic manifestations and early disease progression seen in MODY 5. It also underscores the importance of accurate diagnosis in patients with autosomal dominant disorders. In this gentleman's case, he was referred for genetic counselling.

122 SEVERE HYPOGLYCEMIA- A CASE OF VON GIERKE'S DISEASE

A Ogunsakin*, H Steinberg, E Nyenwe. *University of Tennessee Health Science Centre, Memphis, TN*

10.1136/jim-2017-000697.122

Background Glycogen storage disorders type 1 have an incidence of 1 in 1 00 000 individuals. Presentation with hypoglycemia at initial diagnosis or periods of acute stress or illness is common. Frequent small servings of carbohydrates must be maintained throughout life to prevent hypoglycemia, lactic acidosis, hypertriglyceridemia, hyperuricemia and other long-term complications.

Case presentation A 43-year-old male who presented to the emergency room with nausea, vomiting and severe hypoglycemia. Past medical history was significant for a history of type 1 glycogen storage disease type 1a that had been managed most of his life with daily corn starch to prevent the symptoms and consequences of hypoglycemia; however, he was unable to tolerate any oral intake on the day of presentation. Laboratory data showed severe hypoglycemia in association with significant metabolic acidosis and Lactic acidosis. He had a serum glucose of 29 mg/dL, anion gap of 26, carbon dioxide level of 6 mmol/L, lactic acid level of 19.2 mmol/L and beta-hydroxybutyrate level of 2.9 mmol.

Hospital Course Hypoglycemia resolved over 24 hours in response to 10% intravenous dextrose for glucose infusion rate of ~2.3 mg/kg/min. Lactic acidosis resolved gradually.

Discussion Von Gierke's disease, also known as glycogen storage disease (GSD) type 1a, is a rare autosomal recessive disorder of the metabolism in which there is an inability to break down glycogen into glucose due to the deficiency of enzyme glucose 6-phosphatase. Patients with GSD type 1 usually present at infancy with hepatomegaly and signs and symptoms of hypoglycemia, and less commonly as adults. Severe hypoglycemia is potentially life-threatening and individuals with glycogen storage disease such as Von Gierke's disease can present with severe hypoglycemia, when they are unable to maintain a steady source of exogenous glucose.

Conclusion Glycogen storage disorders are rare and a high index of suspicion for such disorders is warranted when severe hypoglycemia exists in combination with severe lactic acidosis, in the absence of sepsis. Prompt treatment of hypoglycemia is important to prevent significant morbidity and death.

123 ENDOCRINE COMPLICATIONS OF LITHIUM THERAPY IN A CRITICALLY-ILL WOMAN

C Ogwo*, M Haltom, E Nyenwe. *University of Tennessee Health Science Centre, Memphis, TN*

10.1136/jim-2017-000697.123

Case report Lithium is an effective therapy for psychiatric disorders but has several adverse effects including endocrine dysfunction. We present a critically-ill woman with multiple endocrine abnormalities due to lithium therapy.

Case presentation A 60-year-old female with a history of bipolar disorder treated with Lithium was brought unconscious to the Emergency Room. She had tachycardia (heart rate-140/minute), tachypnea (respiratory rate-26/minute) and crackles in both lung fields. Chest imaging showed bilateral lower lobe consolidation and patchy infiltrates in the upper lobes. She was diagnosed with multifocal pneumonia and admitted to the intensive care unit. She was mechanically ventilated for acute respiratory failure. Blood chemistry showed hypernatremia-147 mmol/L, hypercalcemia-ionised Ca -1.41 mmol/L, TSH-0.236 uIU/mL, free T4-0.69 ng/mL, and free T3 <0.50 pg/mL, PTH-53.1 pg/ml, Lithium level- 0.4 mmol/L. She was treated with antibiotics and corticosteroids for pneumonia, intravenous hydration for hypernatremia and hypercalcemia. Hypercalcemia and hypernatremia improved but ionised Ca remained elevated at 1.34 mmol/L. She also developed hyperglycemia. She made full recovery after 31 days and was discharged.

Discussion We have presented a patient with severe pneumonia, respiratory failure and multiple endocrinopathies attributable to chronic lithium therapy (hypercalcemia, hypernatremia, hyperglycemia and abnormal thyroid function). These endocrine defects may have contributed to the severity of her illness. Lithium treated patients could have endocrine abnormalities commonly diffuse goitre but a constellation of endocrine defects as in our patient is not common. Since lithium is commonly used in psychiatry, physicians should be aware of the potential for endocrine abnormalities that could complicate other co-morbid conditions. Hypercalcemia is due to decreased sensitivity of the calcium sensing receptor in the parathyroid gland. Hypothyroidism with goitre is due to inhibition of iodine uptake, coupling and thyroid hormone secretion. Lithium inhibits the expression of aquaporins in the collecting ducts leading to concentrating defects and diabetes insipidus. Hyperglycemia results from the inhibition of calcium influx into the β -cell which blocks insulin secretion.

124 GRAVES THYROTOXICOSIS IN A PATIENT WITH SICKLE CELL ANAEMIA

C Ogwo*, A Ogunsakin, E Nyenwe. *Uthsc, Memphis, TN*

10.1136/jim-2017-000697.124

Case report Graves' disease (GD) is a common cause of hyperthyroidism with an annual incidence of 20–50 cases/100,000 persons but GD is extremely rare in patients with sickle cell anaemia (SCA). We present a patient with SCA who developed GD that complicated the course of her disease and ultimately contributed to mortality.

Case presentation A 28 year old African-American woman with a history of SCA, presented with painful vaso-occlusive crisis. She had been hospitalised several times in our facility with bone pain crises but at this admission she complained of loose

stools, palpitation and fluttering in her chest. On examination, her heart rate was 168/minute and irregular, she had mild proptosis. ECG showed atrial fibrillation with rapid ventricular response. Her thyroid function tests revealed undetectable TSH, free t4-10.42 pg/mL (2.18–3.98), free t3-3.13 ng/dL (0.76–1.46). Thyroid scintigraphy showed diffuse radioiodine uptake of 69% at 24 hours (10%–30%). She was treated with methimazole and metoprolol but treatment was complicated by non-adherence and frequent episodes of vaso-occlusive crisis. Attempts to treat with radioiodine to control thyrotoxicosis were not successful due to recurrent painful crises requiring hospitalisation, atrial fibrillation and difficulty keeping her appointments. She presented to the hospital a few months ago with acute chest syndrome, thyrotoxicosis and atrial fibrillation. She developed acute respiratory failure requiring mechanical ventilation, hypotension and cardiac arrest. Resuscitation was unsuccessful and she died. Her post mortem studies showed an enlarged thyroid of 94 grams; the cause of death was reported as cardiac arrest due to acute chest syndrome from vaso-occlusive crisis.

Discussion Hypothyroidism is uncommon in patients with SCA but GD is extremely rare. Thyrotoxicosis complicates the course of SCA due to added burden from thyro-cardiac disease. Upregulation of adrenoceptors in hyperthyroidism results in a hyperdynamic circulation and arrhythmias, which contributed to worsening episodes of vaso-occlusive crises and ultimately death in our patient. Physicians who care for patients with SCA should keep this rare but potentially fatal condition in mind. Thyroid function tests would be warranted in patients with recurrent vaso-occlusive crises and tachycardia or arrhythmias.

125 CANCELLED

126 INAPPROPRIATELY HIGH PARATHYROID HORMONE WITH LOW SERUM CALCIUM IN A 60-YEAR-OLD FEMALE WITH SUSPECTED ALBRIGHT HEREDITARY OSTEODYSTROPHY

P Ratanasrimetha*, T Mingbunjerdskul, S Thavaraputta, S Suchartlakitwong, A Rivas-Mejia. *Texas Tech University Health Sciences Centre, Lubbock, TX*

10.1136/jim-2017-000697.126

Background Parathyroid hormone (PTH) and vitamin D play a crucial role in serum calcium and phosphorus regulation. Pseudohypoparathyroidism is a rare condition that results from parathyroid hormone resistance. As a result, patients present with low calcium level, high phosphorus level and inappropriately high PTH level as well as characteristic phenotypic appearances.

Case report 60-year-old female with sustained hypocalcemia documented 14 years ago. She had no symptom of hypocalcemia. She had been on calcium carbonate and vitamin D replacement for several years. She had history of normal menstruation periods until menopause. She denied history of neck surgery. She did not have family history of calcium disorders.

Current medications were calcium-vitamin D 1200 mg-1600 IU per day, hydrochlorothiazide, metoprolol, rosuvastatin and paclitaxel. On physical examination, her BMI was 36.9. She was obese and had clinical features that are compatible with Albright hereditary osteodystrophy including round face and

short digits. She did not have knuckles abnormality. Laboratory studies were as follow: calcium 6.4 (normal 8.8–10.5) mg/dL, phosphorus 5.7 (normal 2.7–4.5) mg/dL, PTH 140 (normal 15–65) pg/mL, thyroid stimulating hormone 3.54 (normal 0.27–4.20) IU/mL, and 25-hydroxy vitamin D 37 (normal 30–100) ng/dL. 24 hour urine calcium after discontinuation of calcium supplements was 17 mg. Genetic studies are pending.

Conclusion Prevalence for Albright hereditary osteodystrophy is 0.79 per 1 00 000. It is characterised by end organ resistance to PTH action. Albright hereditary osteodystrophy has clinical findings such as brachydactyly, round face, short stature, central obesity and variable degrees of mental retardation.

Pseudohypoparathyroidism (PHP) has several variants resulting in varying degrees of disorders. PHP type 1 is inherited as autosomal dominant. There are differentiated between maternal and paternal transmission. Maternal transmission manifests in PHP type 1a expression, whereas paternal transmission associates with pseudo-pseudohypoparathyroidism with Albright hereditary osteodystrophy features but without hormonal resistance.

127 A RARE CASE OF METASTASIS TO THORACIC SPINE FROM MALIGNANT PHEOCHROMOCYTOMA

A Reddy*, WS Orr, V Manucha. *University of Mississippi Medical Centre, Jackson, MS*

10.1136/jim-2017-000697.127

Case report Pheochromocytoma is a rare, destructive neuroendocrine malignancy that occurs primarily in the adrenal glands and can metastasize anywhere along the sympathetic chain. The diagnosis of malignant pheochromocytoma is often problematic to analyse microscopically and thus is primarily dependent on the existence of local invasion or metastasis. The incidence of malignant pheochromocytoma with bone metastases is approximately 10%. Vertebral involvement is exceedingly rare with only a few cases reported. We present a case of malignant pheochromocytoma with metastatic lesions to the thoracic spine.

A 60 year-old female presented with a constant cough in the setting of increasingly intense headaches, dizziness, nausea, and vomiting over a few weeks. A chest x-ray revealed a nodule. Laboratory work-up showed significantly elevated catecholamines in both blood and urine. Computerised Tomography (CT) scan demonstrated a large right-sided adrenal mass with metastatic lesions to liver, sacrum and bilateral iliac bones. A radical right adrenalectomy was performed with tumour measuring 5.9×5.6 cm extending into the peri-renal fat. Focal renal capsular invasion at superior pole and lympho-vascular invasion was identified. Multiple wedge resections of liver and right nephrectomy were performed. Immunohistochemistry demonstrated tumour cells positive for synaptophysin and chromogranin; S-100 focally highlighted sustentacular cells. Stains for cytokeratin, calretinin and MART-1 were negative. Ki-67 was approximately 8%–10%. Findings consistent of pheochromocytoma. Germ-line genetic testing revealed no mutations. Patient complained of back pain at 3 month follow-up. CT showed T11 and T12 thoracic spine lesions. Subsequent bone biopsy contained bony trabeculae with tri-lineage hematopoietic elements and interspersed tumour cells positive for synaptophysin and negative for leukocyte common antigen, consistent with a metastatic pheochromocytoma.

She underwent radiofrequency ablation and cement augmentation to the thoracic spine lesions. The surgical, radiological, and pathological overlap of this case highlights the importance of a multidisciplinary approach to these patients.

128 ADRENAL INSUFFICIENCY INDUCED BY MEGESTROL ACETATE

HA Rehman*, M George, K Shah, J Krodel. *OUHSC, Oklahoma City, OK*

10.1136/jim-2017-000697.128

Case report Megestrol acetate (MA), or Megace, is a synthetic progestin commonly used as an appetite stimulant in patients at high risk for malnutrition or cachexia due to chronic illnesses such as cancer or HIV/AIDS. It is often used in the adult population, with limited use in the paediatric setting. Evidence has shown the benefits of MA with respect to weight gain, however, it is not without adverse effects. Due to its affinity for the glucocorticoid receptor, MA has been reported to cause suppression of the hypothalamic-pituitary-adrenal (HPA) axis. Thus these patients can present with clinical signs of Cushing's syndrome and/or adrenal insufficiency (AI), as seen in this case.

A 4 year old Hispanic male presented to the general paediatrics clinic for a well child visit. Review of systems was positive for weight gain and generalised weakness. His medical history was significant for myopathy of unknown aetiology and failure to thrive. He had been taking MA (300 mg/day) for over 1 year prior to presentation prescribed as an appetite stimulant due to poor weight gain. Physical exam was notable for mild moon facies, diffuse muscle weakness and decreased muscle tone. He was referred to endocrinology where an ACTH stimulation test was performed to assess for adrenal insufficiency. His basal cortisol was 0.7 mcg/dL and 0.5 mcg/dL and 0.6 mcg/dL at 30 and 60 min, respectively, suggestive of severe adrenal insufficiency. MA was slowly tapered off over a period of 2 weeks and the patient was prescribed stress-dose steroids. A repeat ACTH stimulation test 4 months later showed a normal response suggestive of recovery of the HPA axis with notable resolution of moon facies.

Significant complications, including death, have been associated with the use of Megace in adults. MA-induced adrenal insufficiency can be potentially life-threatening in children as well. AI has been noted to occur either following abrupt withdrawal or during active treatment with the medication. Although the mechanism remains unclear, it is believed to be due to suppression of the HPA axis. With the widespread use of appetite stimulants like Megace, it is important for clinicians to be aware of the adverse effects, particularly related to cortisol axis due to its severity.

129 CLINICAL CHARACTERISTICS AND OUTCOMES OF PAEDIATRIC PATIENTS WITH SEVERE HYPERTRIGLYCERIDEMIA

¹TH Richardson, ¹A Ashraf, ²S Aslibekyan. ¹Children's of Alabama, Birmingham, AL; ²UAB School of Public Health, Birmingham, AL

10.1136/jim-2017-000697.129

Purpose of study Severe hypertriglyceridemia (HTG i.e., Serum TG >1000 mg/dl) is extremely rare in children. Little is

known about the aetiology, management and treatment outcome of this disease in children. The primary objective was to evaluate the aetiology and outcomes of severe hypertriglyceridemia. A secondary objective was to analyse the metabolic abnormalities associated with severe HTG categorised by the aetiology.

Methods used This was a retrospective Electronic Medical Record (EMR) chart review of paediatric patients with severe hypertriglyceridemia at Children's Hospital of Alabama, University of Alabama at Birmingham (UAB) between 1999 to 2016. Inclusion criteria were:

- serum total triglyceride concentration >1000 mg/dL
- adequate documentation of lipid panels and complete metabolic panels
- a weight recorded within 6 months of when their triglycerides were over 1000 mg/dl.

Patients were excluded if they had insufficient anthropometric information, biochemical testing, or lacked documentation providing a clinical picture.

Summary of results 2987 patients had elevated triglycerides based on the ICD 9 code of 272.1 for pure hypertriglyceridemia and 272.2 for mixed hyperlipidemia. 140 had severe hypertriglyceridemia. 29 subjects were excluded. Etiologies included renal disease (n=14), diabetes (n=40) TPN related (n=27), malignancy related (n=42, ALL=24, CML=3, other malignancies=17) and miscellaneous (n=5). The average number of days for serum TG to decrease to <1000 mg/dl was 147.68±567.28 days. The average number of days for serum TG to decrease to <500 mg/dl was 136.84±230.9 days. 64 patients had persistent dyslipidemia. The triglyceride levels fell below 500 mg/dl in 73 patients.

Conclusions Severe HTG is rare in paediatrics and is often due to secondary causes rather than primary genetic abnormalities. More than half the patients continue to have persistent dyslipidemia at follow up indicating underlying metabolic abnormality. Severe HTG in children is a serious condition with serious complications that lacks specific management guidelines. We postulate that severe hypertriglyceridemia occurs when patients with genetic susceptibility to hypertriglyceridemia are in situations where there is increased biosynthesis and/or of failure to clear TG-rich lipoproteins.

130 A COMPARISON OF FLUID RESUSCITATION USING 0.9% SALINE AND LACTATED RINGERS IN PAEDIATRIC DIABETIC KETOACIDOSIS

A Rughani*, M Marin. *University of Oklahoma Health Sciences Centre, Oklahoma City, OK*

10.1136/jim-2017-000697.130

Purpose of study Patients with diabetic ketoacidosis (DKA) are dehydrated and require fluid resuscitation prior to insulin therapy. However, there are currently no clinical guidelines on the optimal resuscitation fluid in paediatric DKA. This study determines the effects of 0.9% saline (NS) vs lactated ringers (LR) during initial fluid resuscitation in paediatric DKA.

Methods used A retrospective cohort analysis of paediatric patients over 5 years who presented to the ED of a tertiary care centre and received NS, LR, or both NS and LR as resuscitation fluids. DKA was defined as bicarbonate <15 mEq/L. 3 cohorts (NS only, LR only, NS and LR) were analysed. Outcomes measured were time to

metabolic resolution, changes in serum glucose, potassium, chloride, creatinine, and bicarbonate, and admission length. Student *t* statistic was used to compare the statistical significance of outcomes between NS vs LR, and NS vs NS and LR cohorts. Least squares regression analysis was used to determine the correlation between fluid volume and outcomes.

Summary of results 96 paediatric patients were studied. 69 received NS, 19 received LR, and 8 received both NS and LR. The mean age was 12.3 years; the mean fluid bolus was 23 ml/kg (95% CI: 20.8 to 25.2). At presentation, mean bicarbonate was 7.6 mEq/L, glucose was 552 mg/dL, potassium was 4.9 mEq/L, chloride was 101 mEq/L, and creatinine was 1.16 mg/dL. After correction of acidosis, mean bicarbonate increased to 17.3 mEq/L over 10.1 hours (95% CI: 9.0 to 11.2); glucose corrected to 203 mg/dL at a rate of 42 mg/dL/hr (95% CI: 35.0 to 49.0), potassium declined by 1.4 mEq/L, chloride increased by 13 mEq/L, and creatinine normalised to 0.53 mg/dL. Mean hospital stay was 1.9 days. Outcomes between cohorts (NS vs LR, NS vs NS and LR) were not statistically significant ($\alpha=0.05$) and there was no statistically significant correlation between the amount of initial fluid received and metabolic outcomes.

Conclusions There were no statistically significant differences in metabolic outcomes between NS vs LR, or NS vs NS and LR as initial fluid resuscitation agents in paediatric DKA. Given cost and accessibility considerations of LR in the ED, NS is efficacious for initial fluid resuscitation in paediatric DKA.

131 IMPROVING GUIDELINE BASED DIABETES MANAGEMENT IN AN ACADEMIC OUTPATIENT CLINIC

S Sareen*, M Agarwal, C Stanton, G Hamman, J Campbell, NA Hommos. *University of Tennessee Health Science Centre, Memphis, TN*

10.1136/jim-2017-000697.131

Purpose of study Diabetes mellitus (DM) is a chronic illness. Haemoglobin A1c (HbA1c) is a good marker of glycemic control over previous 3 months. Metformin monotherapy should be started in patients at time of diagnosis of type 2 DM unless contraindications are present. Furthermore, in patients with fasting blood glucose >300, A1c>10% or patients with hyperglycemic symptoms, insulin therapy must be considered. We had observed clinical inertia in initiating and intensifying insulin treatment by housestaff in our outpatient clinic. Considering this, we designed a quality improvement project to educate and update housestaff on current ADA guidelines.

Methods used We evaluated consecutive patients with type 2 DM and reviewed their baseline demographics, A1c, metformin use, and insulin dosing using our electronic record system from April 1 2016 to June 30 2016 (pre-intervention period) and from Jan 1 2017 to March 31, 2017 (post-intervention period). We collected data on what management was offered to these patients on their subsequent visits (2–3 months after the A1c was drawn in both groups). Our intervention included conducting small group discussions of current ADA guidelines, placing posters on appropriate use of oral anti-diabetic agents and insulin regimens in clinic. We performed analysis to see improvement in pre and post intervention groups.

Summary of results Our pre-intervention group included 101 DM patient], while 98 patients were included in post-intervention group. The pre-intervention group did not differ from post intervention groups in terms of percentage of patients who were offered metformin (71.6% vs 75%, $p=0.58$), insulin initiation for non-users (41.7% vs 21.4%, $p=0.27$) and increase in dose of insulin (34.4% vs 34.5%, $p=0.98$). The post-intervention group had significant increase in rate of life style modification intervention offered (48.5% vs 32.1%, $p=0.02$) compared to pre-intervention group.

Conclusions We observed a significant increase in rates of life style modification intervention offered in the post-intervention group, the most important aspect of diabetes management.

132 TRANSIENT HYPERTHYROIDISM CAUSED BY PEMBROLIZUMAB: A CASE REPORT

SK Prieto, J Lado, R Shroff*. *TTUHSC, Lubbock, TX*

10.1136/jim-2017-000697.132

Background Immune checkpoint inhibitors are new, effective treatment options for some cancers. Programmed cell death protein 1 (PD-1) receptors are found on lymphocytes as well as several cancers such as melanoma, lung cancer and lymphoma. PD-1 inhibitors like pembrolizumab have been shown to prolong survival and are generally well tolerated, however, there are adverse side effects that can occur. Checkpoint inhibitors are associated with autoimmune induced endocrinopathies but the mechanism by which this occurs remains unclear. Pembrolizumab has been associated with thyroid dysfunction, more specifically hypothyroidism, that typically develops weeks after treatment is initiated. It remains to be elucidated as to which patients are most susceptible to developing these adverse side effects.

Case report A 55 year-old male with significant smoking history presented to clinic with shortness of breath, dysphagia and weight loss. A chest computerised tomography (CT) showed multiple pulmonary nodules, a right lower lobe mass, and enlarged mediastinal and hilar lymph nodes suggestive of malignancy. Biopsy of the lung mass was positive for poorly differentiated adenocarcinoma. Further imaging revealed nodules on the adrenal glands bilaterally and multiple ring enhancing masses within the brain. Pembrolizumab was started as palliative chemotherapy after whole brain radiation and thyroid function tests drawn prior to treatment were normal. Two days later he presented to the emergency department with vomiting, palpitations and constipation. Thyroid function tests showed hyperthyroidism. Pembrolizumab was stopped and the patient decided to return home on hospice after repeat CT imaging showed progression of his cancer.

Discussion This unusual case reiterates the importance of screening patients for possible endocrine related side effects while on these medications. Further research is needed to investigate how checkpoint inhibitors cause autoimmune mediated endocrinopathies. Once better understood, there may be specific factors that can be targeted to help clinicians determine which patients will likely develop these adverse side effects.

133

SKULL METASTASIS OF PAPILLARY THYROID CARCINOMA: A CASE REPORTSK Prieto, T Warmoth, J Lado, R Shroff*. *TTUHSC, Lubbock, TX*

10.1136/jim-2017-000697.133

Background The calvarium is a common site for metastasis, especially for breast cancer, lung cancer and prostate cancer. While 15%–25% of all cancer patients will have metastasis to the skull, only about 2%–5% of skull metastasis are due to thyroid carcinoma. Follicular thyroid carcinoma is the most reported type of thyroid cancer to metastasize to the skull and is typically found at the base and the calvaria. Papillary thyroid carcinoma, on the other hand, does commonly metastasize to the bone but rarely to the calvaria. Due to its rarity, calvaria metastasis from thyroid carcinoma pose many diagnostic and therapeutic challenges.

Case presentation A 54-year-old man presented to his primary care physician with swelling over the scalp and a mass that he noted to be increasing in size. Magnetic resonance imaging and computed tomography showed a large destructive mass overlying the frontal convexity bilaterally involving the extra-axial intracranial space, full-thickness of the calvarium and extending into the sagittal sinus. Frontal craniectomy was performed and pathology of the mass confirmed metastatic papillary thyroid carcinoma involving the dura with lymphovascular invasion. After thyroidectomy, craniectomy and resection of metastasis to the right humerus, he underwent radioactive iodine ablation 6 months later. Unfortunately, post-treatment I-131 Whole Body Scan showed new activity involving the pelvis, right femur and left thyroid lobe. He continues to undergo treatment for metastatic papillary thyroid cancer.

Discussion Calvarial and dural metastasis from papillary thyroid carcinoma is extremely rare and surgical resection is the treatment of choice followed by postoperative radiotherapy. Due to the rarity and complexity of such widespread metastatic cancer, a multidisciplinary approach helps to provide the best treatment outcomes.

134

CHARACTERISTICS OF PATIENTS WITH ESTABLISHED TYPE 1 DIABETES MELLITUS ADMITTED TO THE PAEDIATRIC INTENSIVE CARE UNIT FOR DIABETIC KETOACIDOSIS FROM 2012 TO 2016S Vazquez Diaz*, N Bilbao. *University of South Alabama, Mobile, AL*

10.1136/jim-2017-000697.134

Purpose of study Diabetic Ketoacidosis (DKA) in established Type 1 Diabetes (T1D) patients is an extremely common cause of hospital admission, despite being highly preventable. In the past decade, there were remarkable improvements in insulin therapy and glucose monitoring, but the risk of recurrent DKA admission remains high. We aim to describe the characteristics of patients who had multiple hospital admissions for DKA in the last five years, in order to identify high risk groups. We hope to use the findings for future development of targeted intervention for prevention of recurrent hospitalizations for DKA.

Methods used After obtaining IRB approval, a retrospective chart review was performed using electronic health records of USA Children's and Women's patients ages 1 to 20 years old with established T1D, who were admitted with a diagnosis of

DKA in the Paediatric Intensive Care Unit, from January 2012 to December 2016. Age, sex, race/ethnicity, type of insulin treatment (pump, basal/bolus, conventional, mixed) and HbA1c at time of admission were collected and analysed for frequency distribution.

Summary of results A total of 567 admissions were reviewed, of which 383 met the inclusion criteria. These admissions were divided by year (2012–2016). 2014 was the year with most admissions (n=84). Most admissions fall under the ages 13–17 years. There were more females admitted in every year (54%), except in 2016, in which there were more male admissions (55%). More patients admitted were Caucasian (49%), except for 2015 in which there were more African American patient admissions (58%). The most common treatment modality was basal/bolus regimen in all years, except 2012 when patients admitted were mostly on conventional (twice daily) insulin regimen. The HbA1c range of these patients was mostly 10%–16%.

Conclusions Patients with established T1D who were admitted for DKA were mostly 13 to 17 years old, with a HbA1c of 10% and above. Most patients admitted were receiving Multiple Daily Injections (basal-bolus), except in the earliest study year (2012), in which conventional dosing was the most prevalent treatment modality. Development of targeted intervention for patients with these characteristics may help decrease their recurrent hospitalizations for DKA.

135

EXPLORING A RARE COMPLICATION OF DIABETIC KETOACIDOSISM Yousif*, K Shah, K Ward, S Krishnan. *University of Oklahoma Health Science Centre, Oklahoma City, OK*

10.1136/jim-2017-000697.135

Case report Diabetic Ketoacidosis (DKA) is typically the presenting sign of Diabetes Mellitus type I (DMI). Among the serious complications of DKA, cardiac issues are not appropriately highlighted. We report a case of a child presenting with DKA complicated by myocardial ischemia. This association has been well studied in the adult population, but there is limited data in the paediatric population, and its possible long term consequences.

A previously healthy 13 year old African American obese male (BMI-36.5 kg/m²) was admitted to the Paediatric ICU with altered sensorium. Review of symptoms revealed polyuria, polydipsia and extreme fatigability for 2 weeks. Admission labs showed bicarbonate of <10 mmol/L, pH of 7.09, glucose of 1,300 mg/dL, anion gap of 27, and elevated creatinine of 2.9 mg/dL. He was started on standard DKA protocol with insulin infusion and fluids. After acidosis resolved, he was noted to have an irregular rhythm on exam, so an electrocardiogram (EKG) was obtained and showed ST elevation in the inferolateral leads along with prolonged QT interval. Cardiology was consulted and cardiac enzymes were obtained, which revealed both troponin I and CK-MB to be elevated (2.215 ng/mL (normal <0.4 ng/mL) and 5.9 ng/mL (normal 0.0–4.9 ng/mL) respectively). An echocardiogram was normal. The EKG changes and elevated cardiac enzymes were believed to be secondary to metabolic abnormalities resulting from DKA rather than acute coronary syndrome and no additional intervention was needed. Repeat chest pain profile obtained

on outpatient follow up showed complete normalisation of cardiac enzymes.

There are very few case reports describing cardiac dysfunction as suggested by elevation of cardiac enzymes and EKG changes in paediatric patients presenting with severe DKA. The aetiology of myocardial cell damage is not secondary to an acute coronary event. Metabolic abnormalities, fluid shifts, tachycardia, and increased sympathetic tone may lead to focal myocardial necrosis and troponin release. Elevations in the cardiac enzymes have been associated with increased mortality in adult population, but this is not well described in children. Paediatricians should be aware of rare complications of DKA like myocardial strain in absence of acute coronary syndrome, for appropriate management of these children.

Gastroenterology

Joint plenary poster session and reception

4:30 PM

Thursday, February 22, 2018

136 OMELSARTAN INDUCED ENTEROPATHY

MA Alawoki*, A Gaba. *East Tenn State University, Johnson City, TN*

10.1136/jim-2017-000697.136

Case report Omelsartan is a relatively new angiotensin receptor blocker (ARB) but unlike most other ARBs, it has been associated with drug induced enteropathy. We present the case of a 75 year old female who presented to clinic with complaints of diarrhoea of 5 years duration. She had multiple episodes a day with no association with meals and stools were loose, fatty but not foul smelling or bloody. Abdominal pain and weight loss were present with onset of diarrhoea 5 years ago. Symptoms were first thought to be due to methotrexate used to treat eczema (misdiagnosed as psoriasis) but they failed to resolve on discontinuation of methotrexate. Diagnosis of irritable bowel syndrome was later made after workups and evaluation by gastroenterologist but symptoms still persisted with

trial of cholestyramine and pancrelipase. On review of medications, she had been on omelsartan, omeprazole, paroxetine, and simvastatin for many years. Omelsartan was then suspected as the cause of her diarrhoea and she was switched to losartan. On return to clinic 2 weeks later, patient reported resolution of diarrhoea and she was still stable 3 months after.

Discussion Enteropathy was initially not associated with omelsartan when approved in 2002 but the FDA advised that sprue-like enteropathy be included as an adverse effect in 2013. Between 2008 and 2010, Mayo clinic reported 22 cases and the ACG reported another 40 cases by mid 2012. In general these patients had moderate to severe diarrhoea, lost significant weight, had villous atrophy, negative celiac antibodies and failed trial of gluten free diet. On stopping omelsartan, symptoms resolved and there was appropriate weight gain. Though there is a lag between initiation of therapy and onset of symptoms, it is important for clinicians to be vigilant and recognise that symptoms can occur at any point. Pathophysiology is unclear but likely due to suppression of intestinal acidity which potentiates bacterial overgrowth, effects of infectious agents and destabilisation of gut motility. Delayed cell mediated immune response is also a potential cause. In the wake of the rising awareness of omelsartan induced enteropathy, a case of valsartan induced enteropathy has also been reported. Consequently, if symptoms fail to resolve in a suspected case after switching omelsartan to another ARB, it is reasonable to switch to a new class of antihypertensive.

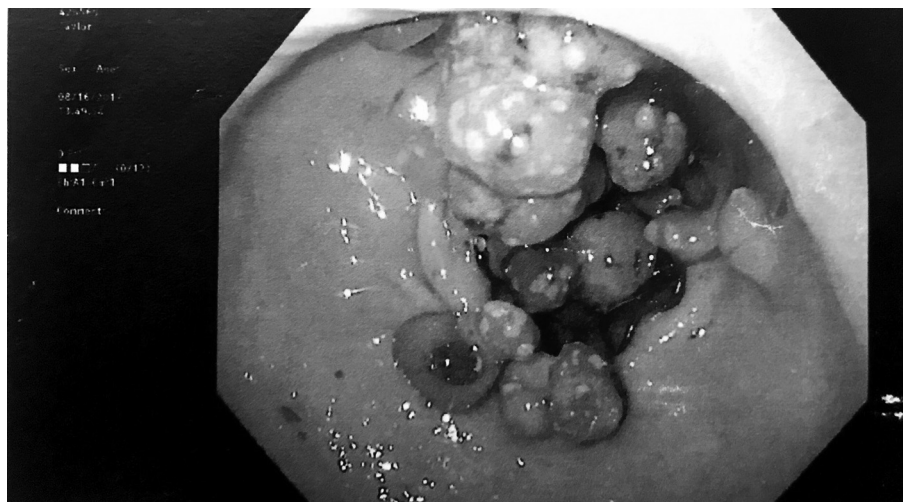137 PYOGENIC GRANULOMA: RARE CAUSE OF GASTROINTESTINAL BLEEDING

C Ashangari*, N Salagundla, S Siddiqui, JP Garrido. *Texas Tech Univ HSC Amarillo, Amarillo, TX*

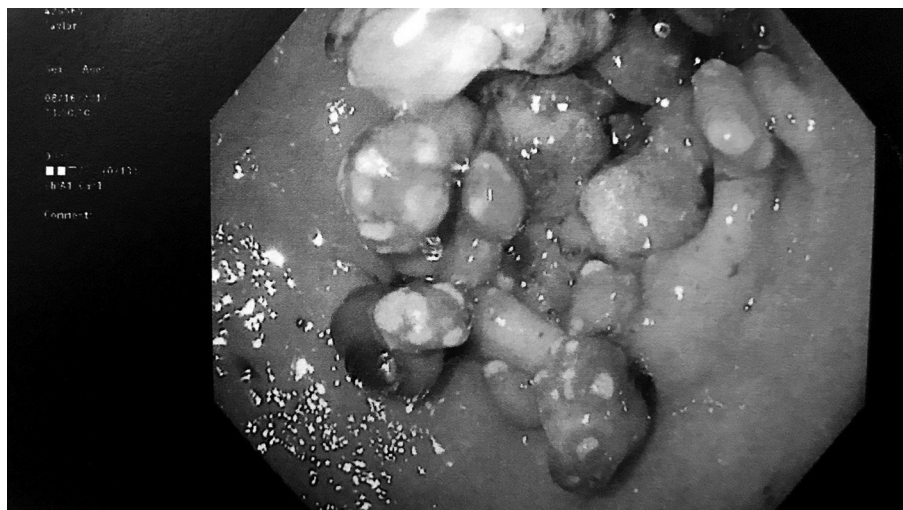
10.1136/jim-2017-000697.137

Background Pyogenic granuloma is a benign, lobular capillary hemangioma that most commonly occurs on the skin. Only a handful of cases have been reported in the gastrointestinal tract.

Case report 67-year-old, Caucasian male with significant PMH of liver cirrhosis, DM, HTN and MI presented with black



Abstract 137 Figure 1 Endoscopic appearance of multiple antral gastric polypoid nodules



Abstract 137 Figure 2 Endoscopic appearance of the 12 to 15 gastric polypoid nodules in the antrum measuring from 0.6 to 1.5 cm

tarry stools. Hb was 9.9. EGD showed 3 columns of grade 1 non-bleeding esophageal varices and moderate portal hypertensive gastropathy. Pathology report showed polypoid gastric mucosa with mild chronic focally active gastritis with acute inflammation superficially within the epithelium with areas of erosion and acute inflammation within fibrinous debris. There was underlying lamina propria granulation tissue, foveolar hyperplasia, and elongation of the muscularis mucosa. No intestinal metaplasia, dysplasia or malignancy was identified. Repeat upper endoscopy was done which showed multiple large polyps in the antrum measuring from 0.6 to 1.5 cm about 12 to 15 of them in the antrum area, status post band ligation of 6×16 and 1 polyp identified in the distal body greater curvature. Diagnosis of pyogenic granuloma was made based on the findings.

Discussion Pyogenic granuloma is an uncommon lesion of the GI tract most commonly managed by excision using a polypectomy snare, endoscopic mucosal resection, or surgical resection.

138 DIAGNOSTIC DILEMENA IN ADOLESCENT WITH MULTIPLE SYSTEMIC COMPLAINTS

JJ Burns*, P Tran, R Dillard. *University of Florida, Pensacola, FL*

10.1136/jim-2017-000697.138

Case report

HPI A 16-year-old white female presented to clinic with multiple complaints including fatigue, weakness, abdominal pain, anorexia, headaches, depression, weight loss and syncopal episodes for 1 year. No fever, vomiting or diarrhoea.

PMH Hereditary Multiple Osteochondromatosis requiring 4 surgical interventions for excision of bony exostosis with many problems including pseudoarthrosis.

Pregnancy 8 months prior; at first prenatal visit, she had a low albumin of 1.7, a total protein of 4.5 and HGB of 9.8 with microcytic indices. She also had post-partum endometritis and haemorrhage requiring transfusions and ICU admission. After delivery, patient had significant depression, being uninterested in caring for the baby. When evaluated 6 months post-partum, she was experiencing persistent weakness, fatigue, weight loss and

vegetative symptoms with nearly no memory of the pregnancy or post-partum period.

Over the past 2–3 years, she had gone to the ED eight times and had consultations from many specialists and had numerous radiological and lab procedures for the myriad of symptoms noted above.

On PE, patient appeared chronically ill, had BMI of <1 st percentile, T 96.8 and had pains over multiple osteochondromas throughout. She had otherwise an unremarkable exam except for weakness and slight tenderness in the right upper quadrant.

Pertinent labs revealed a normal CBC, ESR, phosphorous, CMP, thyroid function tests and negative HIV. TTG IgA antibody was 50 U/ml (normal <3) and she was referred to Paediatric Gastroenterology where a biopsy of the small bowel showed marked villous blunting and dense lymphoplasmacytic infiltrate to the lamina propria. A bone density DEXA scan revealed osteoporosis with Z-score of -2.7.

Course Patient was placed on gluten-free diet, iron, vitamin D and calcium supplementation and is showing dramatic improvement with overall weight gain and resolution of depression and weakness.

Discussion In retrospect, this patient's celiac disease symptoms including unexplained malnutrition, depression, anaemia, and hypoproteinemia likely contributed significantly to her difficult pregnancy, complicated post-partum course and chronic bone disease.

139 LIVER FAILURE CAUSED BY HEPATITIS A TREATED WITH N-ACETYL CYSTEINE

JA Carlson*, G Nelson, C Harris, J Cury. *University of Florida, Jacksonville, FL*

10.1136/jim-2017-000697.139

Case report An 88 year-old female with history of HTN and heart failure presented for evaluation of chest discomfort and abdominal pain for 3 days. On admission patient was encephalopathic with scleral icterus, RUQ abdominal tenderness, asterixis, multiple spider angiomas and 3+ pitting oedema. Imaging included CXR showing pulmonary oedema and ultrasound with hepatic steatosis. Labs were significant for ammonia of 127, AST 5403, ALT 2336, ALP 77, albumin 3.2, total

bilirubin 1.8, INR 1.8, AG 18, Cr 2.99, troponin 0.39, and WBC 16.18 with 12% monocytes. Acute hepatitis panel revealed hepatitis A (HAV) IgM positivity. After 5 days of supportive care and intermittent N-acetylcysteine (NAC) infusions, her mental status had improved as well as troponins and LFTs returning to normal range, creatinine approached baseline, and she was stable on room air.

HAV can be difficult to diagnose as it can be subclinical or present in fulminant hepatic failure, with a worsening course for older adults or patients with underlying hepatic disease. Patients present with vague symptoms as 70% experience abrupt nausea, vomiting, anorexia, fever, malaise and abdominal pain. HAV is diagnosed by testing anti-HAV IgM antibodies which are present 2–14 weeks after initial exposure. The overall prognosis for acute HAV in its less severe manifestations are good as long as patients are not presenting in liver failure or with underlying liver disease. If these features are absent, the course is generally self-limiting. Typically within 3 months 85% of patients achieve clinical and biochemical resolution, with almost all patients resolving by 6 months. Survival rates for Hep A patients with acute liver failure, however, are approximately 60%, with over half of these patients requiring liver transplantation.

While NAC is well known for acetaminophen toxicity treatment, it may be beneficial in other forms of acute liver failure. A placebo-controlled trial with 173 patients with acute liver failure due to causes other than acetaminophen found significantly higher transplant-free survival (40 vs 27%) in patients randomised to NAC. Thus, for patients who are unlikely to qualify for liver transplant and presenting in fulminant hepatic failure, as in this case, NAC may give these patients a better chance at survival.

140

POLYSPLENIA SYNDROME WITH PANCREAS MALFORMATION; AN UNFORESEEN CLINICAL PRESENTATION OF CHAUDHREY'S DISEASE

C Castillo Latorre*. *San Juan City Hospital, San Juan*

10.1136/jim-2017-000697.140

Case report From the zygote to the lateral plate mesoderm subsequently develops a primitive organ called the spleen. A rare clinical presentation of an even rarer pathology, we present the case of a 34 year old Hispanic patient, that came to the emergency department with black stools of a few days of evolution, also associated with a recently 10 pound weight loss history. With further interrogation an interesting surgical history was evident, and an even more noteworthy past family history. Upon supplementary evaluation in the case an abdominal pelvic computer tomography was performed, multiple spleens were seen and surprisingly absence of the pancreas body. We present a rare clinical presentation of polysplenia syndrome (Incidence 1/250,000), a congenital abnormality that is characterised of two or more spleens and various organ anomalies. An extremely rare case of a 34-year-old male without past medical history or toxic habits, which presented with upper gastro intestinal bleeding, associated with severe thrombocytopenia. When embryological changes occur major clinical complications develop. Those alterations are commonly seen in childhood, however major catastrophic presentations could

be seen in adulthood as in our case. It is a well-documented relationship between malposition of visceral organs and multiple anomalies such as cardiovascular malformations, bowel malrotation, pancreas agenesis, biliary atresia, and portal vein anomalies. Most of them will die during childhood, mainly due to cardiovascular anomalies. However, less than 10% of affected individuals with no major cardiac anomaly reach adulthood and are nearly asymptomatic, but a even less percentage of them will present with upper gastrointestinal bleeding.

141

GASTROINTESTINAL STROMAL TUMOUR AT AMPULLA OF VATER PRESENTED WITH UPPER GASTROINTESTINAL BLEEDING

P Chariyawong*, P Laoveeravat, A Rakvit. *Texas Tech University Health Sciences Centre, Lubbock, TX*

10.1136/jim-2017-000697.141

Case report Gastrointestinal stromal tumours (GISTs) is a mesenchymal tumour accounted for only one percent of primary GI cancer. An estimated 4000 to 6000 new cases of GISTs are diagnosed annually in the United States. Common locations of tumour are stomach and small intestine. GISTs at ampulla of Vater is extremely rare of only 12 cases per literature review. We presented the rare case of GISTs at ampulla of Vater presented with upper gastrointestinal bleeding.

Sixty five years old female with history of diverticulitis status post laparoscopic sigmoidectomy, and gastroparesis presented with melena for 2 weeks. Upper endoscopy showed submucosal mass at the Ampulla of Vater. Biopsy showed normal duodenum. CT abdomen showed common bile duct dilation and 1 cm soft tissue nodule with peripheral enhancement within the third portion of duodenum. Endoscopic ultrasound confirmed submucosal mass, but the fine needle biopsy was complicated with bleeding, and the biopsy showed normal duodenum. ERCP with stent was placed in common bile duct to relieve the obstruction. MRI abdomen showed enhancing 1.7×1.5 cm mass within the periampullary region. She was referred to surgery. Open pancreatic sleeve duodenectomy was performed. Pathology revealed 2.3 cm GISTs with free margin and positive for CD 117, CD 34 and smooth muscle actin, negative for S100. No mitosis per fifty high power fields reported. No adjuvant chemotherapy is indicated.

Melena is a common presentation of GISTs. However, diagnosis can be difficult because it is a submucosal mass which causes obtaining biopsy problematic. This patient was proved to have GISTs by expression of CD 117 which differentiated GISTs from leiomyoma and leiomyosarcoma. From previous reports, ulcerative lesion is concomitant findings in several cases but not presented in our case. Although GISTs at ampulla of Vater are rare, GISTs should be included in the differential diagnosis especially if the mass has an enhancement per CT scan which is characteristic of GISTs. Overall, prognosis is less favourable for small intestinal GISTs. Literature reviews show that GISTs at Ampulla of Vater has fair prognosis. Most of them has no metastasis or lymph node involvement. Only one case had liver metastasis and died from hepatic failure.

142 BIRD WATCHING: A CASE OF SEVERE ACHALASIA

JA Coba*, PR Sanchez. *Texas Tech University, Lubbock, TX*

10.1136/jim-2017-000697.142

Case report Achalasia is chronic incurable motility disorder of the oesophagus characterised by loss of esophageal peristalsis and inadequate relaxation of the lower esophageal sphincter (LES).^{1,2} We present a case of severe achalasia and the complications associated. The patient is a 67 y/o male with PMH of achalasia s/p balloon dilation in 1995 presenting with chief complain of hematemesis. Two days prior to presentation, patient had been diagnosed with community-acquired pneumonia and was treated as outpatient. He was admitted to medical ICU for suspected GIB and scheduled for EGD. Prior to the procedure, he experienced recurrent episodes of hematemesis that resulted in aspiration pneumonia. He subsequently required intubation with mechanical ventilation. He underwent an EGD that revealed dilation of the entire oesophagus. He required a repeat EGD 2 days later for balloon dilation and endoscopy-guided NGT placement. He was successfully extubated, but he required antibiotic treatment for aspiration pneumonia. He demonstrated clinical improvement, thus, an esophagram was performed which showed the oesophagus with massive dilation and tortuosity and stenosis at the gastroesophageal junction. General surgery was consulted who proceeded with outpatient manometry and planned for laparoscopic Heller myotomy with Dor fundoplication. Achalasia, although rare, is the most common esophageal motility disorder. Its underlying aetiology is unknown. The proposed pathophysiological process is described as myenteric plexus and ganglion cell degeneration in the body of the oesophagus and LES, which leads to unchallenged action by cholinergic nerves and incomplete LES relaxation. This eventually leads to esophageal dilation from mechanical elongation to accommodate food accumulation.

143 DEMOGRAPHIC PREDICTORS OF HEALTH RELATED QUALITY OF LIFE IN CAREGIVERS AND PATIENTS WITH CHRONIC GASTROINTESTINAL CONDITIONS

M Casper*, C Pierce, M Lynch, MJ Barnes, R Dimmitt. *University of Alabama, Birmingham, AL*

10.1136/jim-2017-000697.143

Purpose of study This study aimed to determine what, if any, demographic variables predict health-related quality of life (HRQoL) in children with chronic gastrointestinal conditions and their caregivers. It is understood that individuals with these conditions, and their caregivers, may have impacted HRQoL. Literature suggests that certain demographic information can be used as predictors of HRQoL.

Methods used The caregivers of 203 paediatric gastroenterology patients, age 5–17 years, were recruited for the study at the time of their scheduled upper endoscopy. Caregivers provided demographic information including age, race, employment status, and annual family income. The patient's diagnosis and current treatment were extracted from the medical record. Caregivers were asked to complete the PedsQL Family Impact Module, providing self-reported HRQoL, as well as the caregiver-report PedsQL Generic Core Scale, providing child HRQoL.

Summary of results Analysis of caregiver self-report indicates that the caregiver HRQoL scores were predicted by caregiver sex ($b=0.20$, $t=2.79$, $p<0.01$), annual family income ($b=0.142$, $t=1.98$, $p=0.05$), and caregiver employment status ($b=-.26$, $t=-3.59$, $p<0.01$). Further, the child HRQoL scores were also predicted by annual family income ($b=0.17$, $t=2.34$, $p<0.05$) and employment status ($b=-.19$, $t=-2.66$, $p<0.01$), as well as their diagnosis ($b=0.21$, $t=2.98$, $p<0.01$) and number of medications ($b=-.20$, $t=-2.17$, $p<0.05$).

Conclusions Analysis of data indicates that certain demographic factors, specifically socioeconomic factors, are predictive of both child and caregiver HRQoL scores. This suggests that beyond the child's diagnosis and treatment, outside stressors impact the quality of life of both the caregiver and child. As these predictors have been identified, preemptive measures, such as involvement of social workers, could be taken. By doing so, the impact of outside stressors on the ability of a family to function when a child has a chronic illness can be greatly diminished.

144 PRURITIS AS A PRESENTATION OF IGG4 RELATED DISEASE

V Fonseca-Ferrer*, M Miranda. *San Juan City Hospital, San Juan, Puerto Rico*

10.1136/jim-2017-000697.144

Case report IgG4-related sclerosing cholangitis (IgG4-SC) is a characteristic type of sclerosing cholangitis, with an unknown pathogenic mechanism. Patients with IgG4-SC display increased serum IgG4 levels and dense infiltration of IgG4-positive plasma cells with extensive fibrosis in the bile duct wall. IgG4-SC is frequently associated with autoimmune pancreatitis and is commonly observed in elderly men. Obstructive jaundice, pancreatitis, weight loss and salivary involvement are frequently observed. The diffuse cholangiographic abnormalities observed in IgG4-SC may resemble those observed in primary sclerosing cholangitis (PSC), and the presence of segmental stenosis suggests cholangiocarcinoma (CC). IGG4 levels more than 135 mg/dl are 80% sensitive and 86% specific for diagnosis. A 71-year-old man with T2DM, chronic kidney disease stage III, osteoporosis and cholelithiasis presents to his primary care physician due to pruritus of 2 weeks duration. Pruritus was constant and not associated with food intake. No fever, rash, weight loss, jaundice, dizziness, abdominal pain, nausea, or bleeding. Physical examination was unremarkable. Initial laboratory work up showed elevated liver enzymes and elevated alkaline phosphate. MRCP presented intrahepatic and extrahepatic ductal dilations that suggested primary sclerosis cholangitis (PSC). In the ERCP patient was found with strictures consistent with PSC. Cytology and biopsies from biliary strictures were negative for malignancy or PSC. IgG4 levels, schistosomiasis and strongyloides were ordered for further evaluation. IgG4 levels were found to be considerably elevated, more than 300 mg/dl. Patient was diagnosed with IgG4-SC. Azathioprine and prednisone was started with significant improvement. Even through, he did not have pancreatitis or jaundice as seen in IgG4-SC, it is imperative to identify IgG4-SC in patients with suspected PSC due different prognoses between these conditions. Among patients with bile duct radiographs that look like PSC, those who have elevated serum IgG4 levels have a much more severe course of disease; these patients are more likely to die or require transplantation

than patients who have normal IgG4 serum levels. Fortunately, patients with IgG4-associated disease are often very responsive to steroid therapy, which is not the case with PSC.

145

DARK STOOLS AS AN INITIAL PRESENTATION OF LUNG CANCER

D Hidalgo, S Gaddam*, M Khalid, J Phemister, M Young. *East Tennessee State University, Johnson City, TN*

10.1136/jim-2017-000697.145

Case report Lung cancer is the most frequently diagnosed malignancy and the leading cause of cancer mortality worldwide. While the preferred sites of lung cancer metastasis are brain, liver, adrenal glands and bone, the gastrointestinal (GI) tract is an unusual site of spreading.

The latest reports estimate that the incidence of gastrointestinal metastases from lung cancer ranges between 0.5% and 10% and only 0.2% to 0.5% are gastric metastases. As patients are usually asymptomatic, most of this information has been obtained from post mortem analysis.

We report a case of an 80 years-old male with past medical history remarkable for chronic obstructive pulmonary disease, essential hypertension and smoking, who presented to the emergency room after 'passing out'. He had two episodes of syncope and reported he has been weaker than normal due to shortness of breath for the last couple of weeks. He also complained of a 6 months history of dark stools but no active bleeding.

On admission labs were remarkable for haemoglobin of 8.2 g/dl. Once the patient was stabilised, he underwent an Esophagogastroduodenoscopy (EGD) that showed a 5 cm large, friable and ulcerated mass at the junction of the antrum and gastric body towards the lesser curvature. Biopsies were taken and the immunohistochemistry revealed the tumour was positive for cytokeratin AE1/AE3, cytokeratin 7, TTF-1, napsin and MOC-31. These findings showed a poorly differentiated adenocarcinoma. The morphologic and immunostain findings were consistent with a metastasis from a lung primary.

When a metastatic tumour is found in the gastric tract, it is most commonly metastatic melanoma, carcinoma of the cervix uteri, ovary, or breast. A study published in 1975 reviewed 1010 autopsies of patients with cancer, 17 cases were gastric metastases (incidence of 1.7%).

More recent studies have shown a considerable increase in this number. A study of 470 patients with lung cancer identified 11.9% of GI metastasis, 5.1% of them were gastric. This same study showed that the most common histological type was adenocarcinoma, followed by squamous cell and large cell carcinoma.

Although gastric metastasis from lung cancer is very rare, GI manifestations should be always taken seriously, with EGD and PET scan being very useful in the diagnosis of GI metastasis.

146

SERIOUS COMPLICATIONS FROM A BENIGN CONDITION: CECAL LIPOMA

D Hidalgo, S Gaddam*, M Khalid, J Phemister, M Young. *East Tennessee State University, Johnson City, TN*

10.1136/jim-2017-000697.146

Case report A lipoma is a non-epithelial benign tumour that originates from the adipose tissue. Incidence in general population is 0.2% to 4.4% and constitutes 1.8% of all the colonic lesions. Most of these are found incidentally during surgery, colonoscopy or autopsy, as they are asymptomatic or present with nonspecific symptoms. Lipomas exceeding >2 cm are more likely to be associated with symptoms that range from mild abdominal pain to gastrointestinal bleeding, intussusception or obstruction.

This is a 63 years old female with PMH remarkable for breast cancer, hypertension and diabetes mellitus 2. She presented to the emergency room (ER) due to intense abdominal pain and nausea. An abdominal CT scan incidentally showed a 3.5×3.2 cm mass consistent with a lipoma. As her symptoms resolved spontaneously and this was a benign lesion, she was sent home. Three years later she presented to the ER with melena and abdominal pain. An upper endoscopy did not reveal any acute source of bleeding and was scheduled for a colonoscopy as an outpatient. Two months later the colonoscopy revealed a 5 cm ulcerated lipoma in the cecum. A couple hour after the procedure she came back to the ER complaining of intense mesogastric pain, nausea and vomiting. She denied fever, chills, diarrhoea or blood in stools. An abdominal CT revealed a long colonic intussusception with the cecum intussuscepting into the colon up to the splenic flexure and an increased 5.8 cm cecal lipoma as the lead point. Due to persistent symptoms, she underwent exploratory laparotomy with right hemicolectomy and anastomosis. Post operative course was uneventful and symptom-free.

Although the majority of colonic lipomas are asymptomatic, treatment is warranted in symptomatic cases. Endoscopic or surgical resection can be done based on the size and location of the lesion. In our case, given the size of the lesion (>2 cm), ulceration causing bleeding, and intense pain, surgery was considered as the best option. We recommend close monitoring and timely intervention for the treatment of symptomatic lesions. Laparoscopic tumour removal is the standard-of-care for large and symptomatic colonic lipomas. Unfortunately, our patient underwent open laparotomy with hemicolectomy and anastomosis given the large area of intussusception as well as mass size.

147

A CASE OF PANCREATIC NEUROENDOCRINE TUMOUR IN AN ADOLESCENT WITH AUTOIMMUNE HEPATITIS

A Glinky*, R Zwiener, Iglesias Escabi, B Keith. *LSUHSC, New Orleans, LA*

10.1136/jim-2017-000697.147

Case report Pancreatic neuroendocrine tumours (PNETs) are a rare malignancy with an incidence of less than 1 case per 1 00 000 persons per year. Neuroendocrine tumours can arise in any tissue of the body where neuroendocrine cells are found but are most commonly seen in the gastrointestinal tract, pancreas and lung. They can appear in conjunction with other syndromes such as MEN1 or Von Hippel-Lindau or in solidarity. The tumours may produce and secrete functional peptides or may be inactive and produce nothing at all. Symptomatology varies based on the product secreted by the tumour.

Autoimmune hepatitis (AIH) is an inflammatory condition of the liver marked by elevated aminotransferases. Diagnosis is often made through the exclusion of other chronic liver

diseases. Hyperglobulinemia, particularly of IgG, is often seen along with IgA deficiency in children.

We present a 16 year old male with history of AIH, IgA deficiency and non-alcoholic steatohepatitis on 6-mercaptopurine who presented to gastroenterology clinic for routine follow-up. He endorsed a one month history of left upper quadrant abdominal pain and 3 kg weight loss over the last four months. He reported dieting as well as decreased appetite and energy. Abdominal ultrasound was performed showing a localized hypovascular 4.5 cm mass near the tail of the pancreas. CT scan and MRI showed similar findings and also noting a concern for autoimmune pancreatitis (AIP). Further workup for AIP was negative.

The patient was referred to an advanced endoscopist at an outside hospital for endoscopic ultrasound (EUS) with fine needle aspirate. The EUS showed a well-differentiated grade I neuroendocrine tumour with strongly positive synaptophysin stain. The patient is currently undergoing further work-up for neuroendocrine tumour markers and will have a distal pancreatectomy.

Our team was unable to find any previous reports of patients with AIH later being diagnosed with PNETs. However, there have been reported cases of patients with autoimmune conditions having subsequent diagnoses of neuroendocrine tumours. Given the relative rarity of neuroendocrine tumours in paediatric patients, there are limited resources to guide treatment in this case.

148 CLOSTRIDIUM DIFFICILE MASKING BILOMA

A Guzman*. *University of South Florida, Tampa, FL*

10.1136/jim-2017-000697.148

Case report Sub-hepatic bilomas typically manifest as persistent right upper quadrant or epigastric pain, abdominal distention, fever and leukocytosis¹. Though bile duct injuries infrequent, they are potentially devastating complications of biliary tract surgery and high index of suspicion should be maintained in patients presenting with abdominal pain post-cholecystectomy. Here we present a case of a biloma masked by *Clostridium difficile* colitis.

A 69 year-old male with a history of hypertension, alcohol abuse and obesity presented with shortness of breath, subjective fevers, and abdominal pain. He was recently treated for gangrenous cholecystitis requiring emergent cholecystectomy and 7 day course of Augmentin. He reported no change in abdominal pain since procedure, though developed 2 days of non-bloody, watery stools.

Physical exam showed a soft, diffusely tender abdomen with well healing incisions at the right upper quadrant, hyperactive bowel sounds and a palpable liver. Vitals were stable with temperature elevation of 100.3 F. On laboratory, there was mild leukocytosis (10.6), transaminitis, and significantly elevated inflammatory markers (CRP=27.7 mg/dL, ProCalcitonin=1.24 ng/mL). Stool studies were positive for C diff. CXR unremarkable.

Patient was admitted and placed on oral vancomycin. He developed a supraventricular tachycardia that resolved with adenosine. Further imaging revealed a large complex fluid and gas bubble collection in the gallbladder fossa suspicious for

post cholecystectomy abscess or biloma. A biliary drain was placed and 250 mL bilious fluid was aspirated, cultures growing *E. coli*. Patient was placed on IV antibiotics. HIDA scan showed no evidence of active biliary leak. Further evaluation by ERCP demonstrated a leak from cystic duct stump and a biliary stent was placed.

A biloma is a sub-hepatic bile collection outside of the biliary tree caused by iatrogenic or traumatic causes. Bile duct injuries are infrequent but potentially devastating complications of biliary tract surgery and have become more common since the introduction of laparoscopic cholecystectomy². Evidence of hepatomegaly on exam prompted further investigation, ultimately leading to detection of the biloma.

149 SUPERIOR MESENTERIC ARTERY SYNDROME: A RARE BUT REAL CAUSE OF ABDOMINAL PAIN

¹J Johnson*, ²C Cantrell, ¹R Smaligan, ¹S Malhotra. ¹UAB School of Medicine, Huntsville, AL; ²UAB School of Medicine, Birmingham, AL

10.1136/jim-2017-000697.149

Case report A 40 yo CM with a history of chronic abdominal pain (treated with narcotics) and malnutrition presented with recurrent severe symptoms to the hospital. Chart review included multiple upper endoscopies showing only mild gastritis, an ultrasound showing no signs of acute or chronic cholecystitis, a normal HIDA scan, an elective cholecystectomy, and multiple normal colonoscopies. Urine tox screen was negative for cannabis. Infectious causes had been excluded. He presented within 24 hours of an outpatient repeat upper endoscopy with nausea and vomiting and CT revealed a small bowel obstruction with a transition point over the 3rd portion of the duodenum. This was confirmed by upper GI series. He was diagnosed with superior mesenteric artery (SMA) syndrome with an aortomesenteric angle of 18 degrees. After the obstruction resolved he was treated with a non-surgical approach of positioning in the left lateral position after meals to promote weight gain. This allowed for weight gain and resolution of symptoms including complete cessation of narcotic use.

Discussion Recurrent abdominal pain is an extremely common complaint in both the inpatient and outpatient setting and drug-seeking behaviour is always a concern. Since the pain is frequently self-limiting, the underlying cause often goes undiagnosed. SMA syndrome has been shrouded in controversy in the literature due to its non-specific symptoms, its rarity, and the fact that some patients do not improve despite aggressive therapy. The aetiology is believed to be compression of the 3rd portion of the duodenum due to a reduced angle between the SMA and the aorta leading to compression, obstruction, and other symptoms. Treatment is conservative initially, with a variety of surgical procedures available if needed including dividing the ligament of Treitz (Strong's procedure), gastrojejunostomy or duodenojejunostomy. This case reminds physicians to maintain an open mind and to think through a full differential diagnosis when evaluating chronic abdominal pain patients since making the correct diagnosis can be life-changing. This patient has made a remarkable recovery with conservative measures and no longer seeks narcotics.

150

MALIGNANT TRANSFORMATION OF TYPE I CHOLEDOCHAL CYST INTO PAPILLARY BILIARY NEOPLASM ASSOCIATED WITH A HISTORY OF ANABOLIC STEROID USE

TV Joshi*, LS Engel, S Walvekar. *LSU Health Sciences Centre, New Orleans, LA*

10.1136/jim-2017-000697.150

Introduction Choledochal cysts are congenital malformations and can be classified into four types. The type 1 lesion is the usual form. Type 1 is defined as an extrahepatic ductal dilatation. Malignant transformation can occur in 10% to 30% of choledochal cysts.

Case A 27 year old man who had no previous past medical history presented with a 2 week history of pruritus, jaundice, and a notable absence of abdominal pain. He also reported dark urine, pale stools, indigestion as well as nausea and vomiting. Upon further investigation he described a rigorous diet and exercise regimen which resulted in the loss of 15 pounds, extensive anabolic steroids abuse, use of testosterone boosting supplements, and a10 pack/year smoking history. Ultrasound and ERCP revealed a dilated proximal bile duct with an irregular mass classified as Choledochal Cyst (type 1). Biopsy was unsuccessful, however cytology brushings were obtained. The patient underwent cyst excision. Intraoperatively, a mass in the medial duct attached to the portal vein was noted. Complete mass excision, portal node dissection, and partial portal vein dissection was performed. Biliary-enteric continuity was restored with a Roux-en-y hepaticojejunostomy. The cytology results from the ERCP brushings identified the mass as a malignant adenocarcinoma with a rare papillary configuration. Surgical pathology specimens confirmed this result indicating a differentiated adenocarcinoma with negative biopsied lymph nodes.

Discussion We describe investigations leading to diagnosis of intraductal papillary adenocarcinoma. Animal studies suggest the possibility of expression of androgen receptors on bile canalicular tissue and the possible carcinogenic effect of tobacco leading to the development of papillary adenocarcinoma. Our patient's history of anabolic steroids abuse, androgenic hormone boosting supplements, smoking history may have played a significant part in the development of his cancer at such an early age.

151

INTERESTING CASE OF INTRA PAPILLARY MUCINOUS NEOPLASM OF BILE DUCT

M Kanaa*, EK Addo-Yobo, M Khalid, S Arikapudi, J Yorke, M Young. *ETSU, Johnson City, TN*

10.1136/jim-2017-000697.151

Case report 81-year-old female with no significant past medical history was found to have elevated liver enzymes on a routine follow up clinic visit followed by abdominal Computed Tomography showed evidence of intrahepatic and extrahepatic bile duct dilation with no evidence of calcified stones. She had an Endoscope Retrograde Cholangio-pancreaticography (ERCP) that revealed distal common bile duct stone (CBD) and CBD dilatation. The stone was removed and a spyglass showed a nonfriable, villas, hypertrophic appearing lesion with proximal upstream dilated left hepatic duct with normal appearing mucosa. Multiple biopsies were taken with the spy-bite biopsy forceps. The pathology analysis was suggestive of

intra-ductal papillary neoplasm of the bile duct (IPNB), with high-grade dysplasia. Approximately 1 month after the ERCP, the patient presented with jaundice and pruritus that was refractory to medications. She had another ERCP with placement of 2 stents. A follow up MRI showed the malignancy started at the level of the common hepatic duct and extended into the proximal aspects of the right and left hepatic biliary ducts. The tumour extended into the left hepatic lobe parenchyma, the medial and lateral segments. Referral to oncology was made, however she was not a surgical candidate due to the tumour burden.

Intra-ductal papillary mucinous neoplasms (IPMN) are a very rare group of machine producing tumours that originates from epithelial cells. IPMNs of the pancreas are well known; however, subset of IPMNs that involves the bile ducts (IPNB) is unusual. Because IPNB is a precursor to invasive carcinoma, surgery remains the treatment of choice in both non-invasive and invasive once the IPN-B is suspected or diagnosed. Awareness of this condition along with diagnostic modalities such as cholangioscopy Early recognition is essential because there is evidence that complete surgical resection has a good survival rate even when malignant transformation has occurred.

152

REFERRAL, EVALUATION, AND MANAGEMENT PATTERNS AT THE ALABAMA AERODIGESTIVE PROGRAM

¹R Kassel*, ²AC Kraus, ³B Crawford, ³A Chapman, ³L Boehm, ⁴N Smith, ⁴B Kulbersh, ¹G Hector, ⁴W Brian, ¹R Dimmitt, ¹WT Harris. ¹University of Alabama Birmingham, Birmingham, AL; ²UT Southwestern, Dallas, TX; ³Children's of Alabama, Birmingham, AL; ⁴Pediatric ENT Associates, Birmingham, AL

10.1136/jim-2017-000697.152

Purpose of study The Alabama Aerodigestive Program was founded in 2012 to meet the multidisciplinary needs of children with complex, chronic airway and digestive concerns. Currently available literature describing referral diagnoses and diagnostic evaluation of Aerodigestive patients is limited.

We seek to report the evaluation and management of referrals to a single-centre Aerodigestive Program.

Methods used We performed a retrospective chart review of the first 200 patients referred to the Alabama Aerodigestive Program from 2012–2014.

Summary of results Mean age at referral was 41 months. The most common indications for referral were gastroesophageal reflux (77%), chronic cough (67%), and dysphagia (56%). Most patients (83%) were evaluated by all four disciplines: otolaryngology (ENT), pulmonology, gastroenterology, and speech pathology. Approximately 2/3 of patients underwent an endoscopic airway evaluation by flexible bronchoscopy (64%), and 70% with direct laryngoscopy and bronchoscopy (DLB). Over half had an esophagogastroduodenoscopy (EGD, 58%). Endoscopic airway examination frequently revealed bronchitis (43%), tracheomalacia (41%), laryngomalacia (34%), and bronchomalacia (33%). A laryngeal cleft was identified in 12% of evaluations. EGD and pH/impedance studies were typically normal (66% and 70% respectively), but 16% of EGD biopsies found eosinophilic esophagitis (EoE). Reflux was only found in 11% of patients. Swallow dysfunction was common, present in 58% of patients undergoing video fluoroscopic swallowing evaluation. Nearly half (49%) of polysomnograms indicated obstructive sleep apnea (OSA).

Conclusions Children referred to The Alabama Aerodigestive Program represent a broad spectrum of medically complex children. Most have airway abnormalities and/or swallow dysfunction. Findings of laryngeal cleft and EoE are increased in this population.

153 **11.28 CANCELLED**

154 **A RARE CASE OF ECTOPIC PANCREATIC TISSUE WITHIN BARRETT'S OESOPHAGUS**

P Laoveeravat*, S Suchartlikitwong, T Mingbunjerdsuk, P Chariyawong, Y Vorakunthada, A Rakvit. *Texas Tech University Health Sciences Centre, Lubbock, TX*

10.1136/jim-2017-000697.154

Background Ectopic pancreatic tissue can be found in stomach but rarely in oesophagus. It is reported to be in paediatric or teenaged patients with the belief that it is congenital in origin. The patients with ectopic pancreatic tissue mostly presented with epigastric pain due to pancreatic enzyme secretion or mass effect.

Case presentation We present a case of 69-year-old female presented with heartburn for more than five years. She denied any abdominal pain, weight loss, or loss of appetite. She underwent esophagogastroduodenoscopy (EGD) in the past, and was found to have 2 cm Barrett's oesophagus at 38–40 cm from incisors. Biopsy showed columnar mucosa and chronic inflammation without dysplasia. Her GERD symptoms are well controlled with omeprazole 40 mg daily. Follow-up EGD at 2 years showed the same endoscopic findings. Biopsy of the Barrett's oesophagus showed focal ectopic pancreas at squamous-columnar junction with foveolar hyperplasia.

Discussion Ectopic pancreatic tissue at oesophagus can be found very rare in adults with Barrett's oesophagus. Specifically, pancreatic acinar tissue, one of cell types in pancreas, is existed 3% of adults with Barrett's oesophagus. There are some postulations that it is from metaplastic process of Barrett's oesophagus but more likely from congenital process without correlation to Barrett's oesophagus. The risk of development to malignant tissue is still unknown. We still need to observe and monitor the tissue changes by endoscopy and tissue biopsy.

155 **PNEUMOPERITONEUM: A CASE FOR CONSERVATIVE MANAGEMENT**

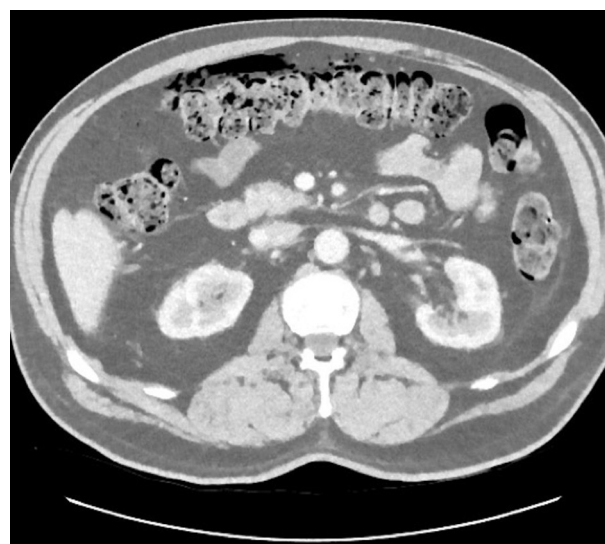A Mahajan*, P Sankhyan, K Muhammad, T Bhandari. *East Tennessee State University, Johnson City, TN*

10.1136/jim-2017-000697.155

Case report A 69 year old male was admitted for elective left foot subtalar joint fusion. His post-op course was complicated by severe constipation. He denied any nausea, vomiting and tolerated his diet well. On post-op day 4, he had mild generalised abdominal discomfort with minimal tenderness without rigidity or rebound tenderness and stable vital signs. CT abdomen (figure 1) showed pneumoperitoneum with a large amount of faeces in colon and rectum. All labs were normal. Surgery recommended conservative management and he was discharged on post-op day 5.

Pneumoperitoneum generally signifies perforation of gastrointestinal (GI) tract and these patients present with an acute abdomen. It is a conditioned reflex for the surgeons to proceed with laparotomy in such cases. Pneumoperitoneum without peritonitis or non surgical pneumoperitoneum (NSP) is a rare entity, where laparotomy is not a necessity. Mularski *et al* identified 96 cases of NSP from MEDLINE database, of which 45 had surgical exploration without any evidence of perforated viscus. Common etiologies include tension pneumothorax, mechanical ventilation, peritoneal dialysis catheter placement and post GI endoscopic procedures. Yamana *et al* described first case of NSP due to severe constipation where emergent laparotomy didn't reveal any evidence of viscus perforation.

Our case highlights the importance of conservative management in carefully selected patients with NSP and development of a good bowel regimen early in the post-op period.



Abstract 155 Figure 1 CT abdomen showed pneumoperitoneum with a large amount of faeces in colon and rectum

156 **ASSOCIATIONS BETWEEN CHANGES IN FEEDING BEHAVIOURS AND PSYCHOSOCIAL FUNCTIONING IN PAEDIATRIC PATIENTS WITH FEEDING DISORDERS AND THEIR FAMILIES FOLLOWING AN 8-WEEK INTENSIVE FEEDING PROGRAM**

^{1,2*}ME Mastin, ¹MJ Barnes, ¹AJ Melton. ¹University of Alabama at Birmingham, Birmingham, AL; ²Children's of Alabama, Birmingham, AL

10.1136/jim-2017-000697.156

Purpose of study Children with complex medical and developmental issues treated for feeding disorders in multidisciplinary intensive outpatient programs show success. Few studies have reported quantitative group results following treatment. Given the relative dearth of information regarding outcomes following intensive outpatient treatment, the present study examined associations between changes in body mass index, feeding behaviours, and psychosocial functioning in paediatric patients with feeding disorders and their families following an 8 week intensive feeding program.

Methods used Caregivers of 22 patients (mean age=5.50 years) completed pre- and post-treatment measures of feeding

behaviours and psychosocial function including the Behavioural Paediatrics Feeding Assessment Scale (BPFAS), Paediatric Assessment Scale for Severe Feeding Problems (PASSFP), Paediatric Quality of Life (PedsQL) General and Family Impact Modules, and the Parenting Stress Index (PSI). Anthropometric outcomes were abstracted from the medical record. Paired samples t-tests evaluated differences between pre- and post-treatment measures. Pearson correlations assessed associations between change scores computed for relevant variables. Data collection is ongoing.

Summary of results Maladaptive mealtime behaviours improved on the BPFAS [$t(21)=11.80$, $p<0.001$] and PASSFP [$t(20)=-8.84$, $p<0.001$]. Family Impact [$t(21)=-2.52$, $p=0.020$] and PedsQL [$t(17)=-3.32$, $p=0.004$] also showed improvements. No other variables met significance although all change scores indicated improvements post-treatment with the exception of parenting stress that showed a slight increase. Correlations amongst change scores indicate that reductions in maladaptive feeding behaviours are associated with increases in family quality of life ($r=-0.565$).

Conclusions Results support the benefits of an intensive feeding program for children with severe feeding disorders. The only variable to show no improvement following treatment was parenting stress which may reflect the increased responsibility placed on caregivers at the end of treatment to maintain their child's feeding protocol outside the program.

157

LIVER IMAGING REPORTING AND DATA SYSTEM (LI-RADS) IN PATIENTS AT HIGH RISK FOR HEPATOCELLULAR CARCINOMA

^{1,2}BP McCullar, ³A Appelbaum, ^{1,3}JK Phillips, ^{1,3}A Weir, ^{1,3}B Waters. ¹University of Tennessee, Memphis, TN; ²Baptist Medical Group, Memphis, TN; ³VA Medical Centre, Memphis, TN

10.1136/jim-2017-000697.157

Purpose of study Hepatocellular Carcinoma (HCC) may be diagnosed radiographically without the need for biopsy if the typical imaging features are present. The American College of Radiology endorsed the Liver Imaging Reporting and Data System (LI-RADS) algorithm with the goal of reducing variability in lesion interpretation through standardisation and improving communication with clinicians. This study utilised LI-RADS to retrospectively analyse screening scans prior to the diagnosis of HCC to determine if this system could provide earlier detection.

Methods used Following IRB approval, a retrospective chart review was performed at the Memphis VA Medical Centre on patients with HCC and benign liver nodules between 2009–2014. Patients with HCC who had surveillance CT images performed 6 to 13 months prior to their diagnosis of HCC were reviewed. Also identified were patients with benign liver nodules undergoing surveillance CTs who did not develop HCC with two year follow-up. Two Radiologists scored each CT according to the LI-RADS diagnostic algorithm.

Summary of results 70 nodules were reviewed by two Radiologists. 42 nodules were in patients who developed HCC and 28 nodules remained benign. The sensitivity for predicting eventual HCC was 64.3%–69% and specificity was 75%–82.1%. LI-RADS accuracy was 71.4%. The false-negative rate

was 31.0%–35.7% and the false-positive rate was 17.9%–25%. The Radiologists agreed in scoring of 58 of the 70 nodules. The kappa statistic was 0.5992 which indicated moderate agreement.

Conclusions LI-RADS was shown to have a good diagnostic accuracy for surveillance CTs in terms of determining the risk of HCC. Utilising LI-RADS scoring would have provided an earlier suspicion of HCC in over 65% of nodules. Such information could lead to closer follow-up and additional imaging, resulting in an earlier diagnosis of malignancy.

158

RELATIONS BETWEEN HEALTH BEHAVIOURS, BODY COMPOSITION AND DISEASE STATUS IN PAEDIATRIC PATIENTS WITH INFLAMMATORY BOWEL DISEASE

AJ Melton*, M Lynch, MD Lisenby, MJ Barnes. University of Alabama at Birmingham, Birmingham, AL

10.1136/jim-2017-000697.158

Purpose of study Lean body mass (LBM) deficits in youth with Inflammatory Bowel Disease (IBD) are well-established and persist despite achievement of remission and restoration of body mass. LBM deficits are associated with both short and long-term health outcomes including sarcopenia, metabolic dysregulation, and development of osteopenia/osteoporosis. The LBM deficits are multifactorial in nature though largely explained by inflammatory processes, inadequate dietary intake, and increased energy needs. In addition, physical activity (PA) may also play a role in LBM deficits. Unfortunately, PA and diet in youth with IBD have been understudied. The present cross-sectional study describes relations between PA, diet, body composition, and disease status in a sample of youth with IBD.

Methods used 40 patients with IBD aged 8–17 (M=14.58 years; 60% female; 78% Caucasian; 60% Crohn's) completed the study. Measures included: moderate to vigorous PA (MVPA; Godin Leisure Time Exercise Questionnaire), Diet (4 day Food Record), Body Composition and Bone Mineral Density (BMD; Dual-energy X-ray Absorptiometry), and Disease Status (Physician Global Assessment). Analyses included independent samples t-test for between group differences and two-tailed Pearson correlations to evaluate relations between variables across groups. Data collection is ongoing.

Summary of results No differences were found on variables based on group. Correlational analyses ($n=40$) revealed that greater MVPA was associated with higher LBM ($r=0.39$) and lower fat mass ($r=-0.38$). Average percent protein intake was associated with older age ($r=0.38$), lower percent carbohydrate intake ($r=-0.72$) and higher BMD ($r=0.37$). Less active disease was associated with higher BMI ($r=-0.38$), higher BMD ($r=-0.46$), and higher LBM ($r=-0.48$). Interestingly, disease status was not associated with health behaviour engagement.

Conclusions The present study suggests the need for further research into PA and diet to promote health and development outcomes for paediatric patients with IBD. Harnessing health behaviours to compliment treatment modalities may lead to improvements in body composition that in turn may mitigate long-term health outcomes associated with IBD.

159 AN UNUSUAL AETIOLOGY OF ACUTE RECURRENT PANCREATITIS

N Menaker*, DJ Askenazi. *University of Alabama-Birmingham, Birmingham, AL*

10.1136/jim-2017-000697.159

Introduction Acute recurrent pancreatitis is an uncommon paediatric disease which can predispose patients to chronic pancreatitis and islet cell dysfunction. Thus, it is critical to evaluate anatomic and medically correctable etiologies to reduce patient morbidity. Hypercalcemia is a recognised cause of pancreatitis particularly in the setting of primary hyperparathyroidism, but other causes of hypercalcemia including thyrotoxicosis must be considered.

Case presentation A 15-year-old Caucasian female with a history of renal sarcoma status post nephrectomy with chronic kidney disease IV presented as a transfer from an outside hospital for the second time in two months with an elevated lipase (1100 U/L) and epigastric abdominal pain, consistent with acute recurrent pancreatitis. The patient was hypercalcemic (12.7 mg/dL) with normal triglycerides and ethanol levels. Abdominal ultrasound was without evidence of gallstones. Magnetic resonance cholangiopancreatography revealed pancreatic divisum, and a genetic pancreatitis panel was collected. Medication review did not reveal any high-risk agents for drug-induced pancreatitis.

The patient's hypercalcemia was confirmed, and an intact parathyroid hormone (PTH) was low-normal (10 pg/mL) indicating a non-PTH mediated process. Vitamin D and PTHrP levels were unremarkable, but TSH was decreased (<0.03 iU/mL) and free thyroxine (T4) was elevated (3.56 ng/dL) consistent with hyperthyroidism. Thyroid stimulating immunoglobulin was increased (12 U/L), and radioactive iodine study showed diffuse uptake consistent with Graves' disease. The patient was initiated on atenolol and methimazole before a successful thyroidectomy. Outpatient follow-up revealed normalisation of calcium and free T4 levels, and the genetic pancreatitis panel returned normal.

Discussion This case highlights the importance of a thorough evaluation of anatomic and medical causes of acute recurrent pancreatitis. When hypercalcemia induced pancreatitis is suspected, an investigation into the aetiology of hypercalcemia that focuses on differentiating PTH-driven from non-PTH mediated processes is necessary. This report lends insight that hypercalcemia induced pancreatitis can be caused by thyrotoxicosis as suggested by the resolution of hypercalcemia and pancreatitis via medical and surgical treatment of hyperthyroidism.

160 HUMAN IMMUNODEFICIENCY VIRUS ASSOCIATED GASTROPARESIS

T Mingbunjersuk*, P Laoveeravat, S Suchartlikitwong, P Ratanasrimetha, A Rakvit. *TTUHSC, Lubbock, TX*

10.1136/jim-2017-000697.160

Case report Gastroparesis is a syndrome of delayed gastric emptying in the absence of mechanical obstruction. Multiple conditions have been described causing delayed gastric emptying. Among common etiologies, many viral infections have been associated with the occurrence of gastric stasis and severe dysautonomia.

We describe a 51 year-old African American woman with HIV infection for 33 years presented with abdominal bloating

and esophageal dysphagia. She has been compliance with anti-retroviral treatment. Barium swallow study and upper endoscopy showed normal findings. Gastric emptying study revealed 252 min emptying time.

Human Immunodeficiency Virus (HIV) associated gastroparesis has not been well demonstrated. HIV infection has been associated with autonomic dysfunction result in delayed gastric emptying. Whether mechanism is secondary to viral infection or immune systems remains unclear. HIV-associated gastroparesis can become manifest at any stage of the disease. Treatment with dietary modification and prokinetic agents have shown to improve quality of life.

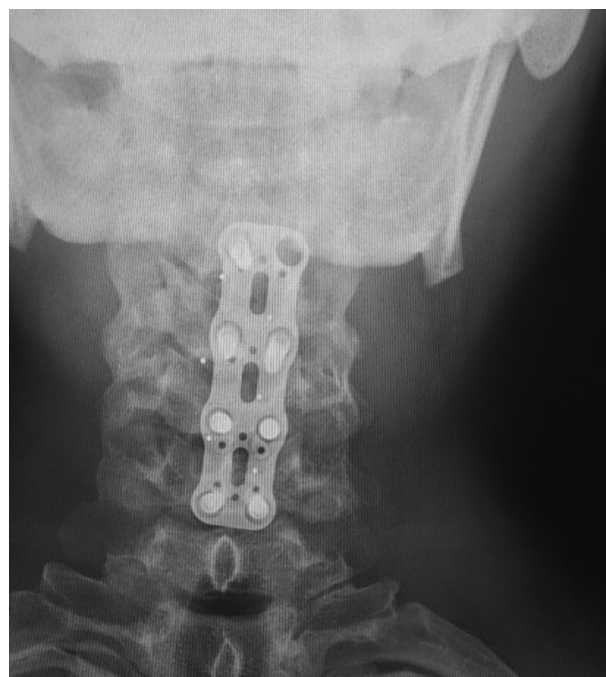
161 A 'SCREWED UP' CASE OF HEMATEMESIS

A Mirza*, N Salagundla, JP Garrido. *TTUHSC, Amarillo, TX*

10.1136/jim-2017-000697.161

Case report 43 yo male with PMH of cervical stenosis s/p anterior cervical discectomy and decompression of C3-C6. Presented with fever, dysphagia and vomiting blood; a 2 cm screw came up in his vomit. The screw was confirmed to be a part of the ACFD. X ray of the neck showed intact hardware, however one screw was missing. Gastrografin swallow did not show any leakage. EGD showed soft tissue swelling, but no perforation. The mechanism of screw dislodgement was thought to be slow chronic extravasation. Conservative management was opted. Patient improved and was discharged. Outpatient follow up showed recovery.

Discussion ACDF is the standard treatment for cervical trauma, tumours and DJD. Complications of ACDF include donor sight morbidity, graft dislocation, etc. Pharyngeoesophageal perforation is an uncommon complication, with an incident rate of less than 2%. Most of these injuries heal



Abstract 161 Figure 1 X-ray of the neck showed intact hardware, however one screw was missing, screw was confirmed to be a part of the ACFD

spontaneously, the risk of mediastinitis, sepsis, and death are present. Most perforations are identified immediately. Delayed perforations may occur due to esophageal wall compression leading to ischemia, abscess, and ultimately perforation. For contained leaks and no systemic symptoms, conservative management recommended. The incidence of delayed complications after ACFD is low however it is important to recognise it early due to associated morbidity and mortality. Patients with hematemesis, dysphagia or neck pain who have a history of cervical spine hardware should be evaluated for hardware related complications.

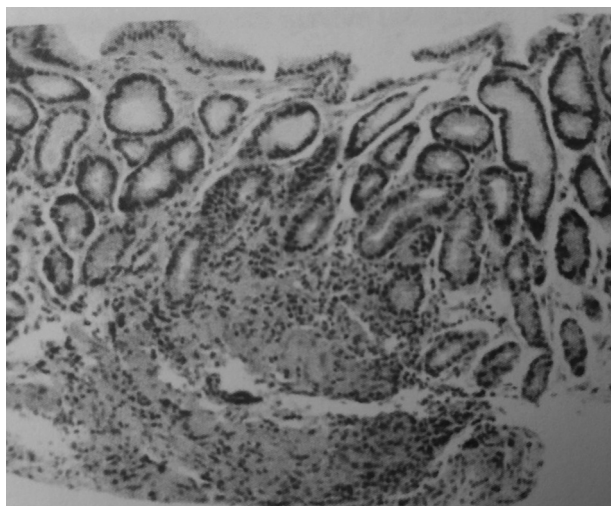
162 COLLAGENOUS GASTRITIS A RARE AND UNDERDIAGNOSED ENTITY

A Mirza*, S Prakash, N Salagundla, JP Garrido. *TTUHSC, Amarillo, TX*

10.1136/jim-2017-000697.162

Case report 64 yo female with PMH of diabetes, asthma, Hashimoto thyroiditis and sarcoidosis. Reports symptoms of dyspepsia for long time. EGD done 8 and 3 years prior showed chronic gastritis; biopsies were negative for malignancy. She presented again due to dyspepsia and 20 lb weight loss. EGD showed nodular atrophic gastritis. Biopsy results revealed aggregates of giant cells in the basal lamina propria, superficial chronic gastritis, subepithelial collagen deposition and surface epithelial degeneration. Colonoscopy was normal.

Discussion Collagenous gastritis is a rare clinical entity and is commonly present in the paediatric population. In adults, is associated with collagenous colitis. The aetiology of collagenous gastritis is not clear and as such there is no specific treatment. In this case, the patient has a history of hypothyroidism, and sarcoidosis. It has been previously suggested that collagenous gastritis and colitis are associated with other autoimmune diseases, but no specific association with sarcoidosis has been reported. We know from literature that collagenous gastritis may not be a primary pathology but possibly an abnormal response to an underlying trigger. Given that this patient had underlying chronic gastritis without any pathological evidence of collagenous gastritis in the previous 2 EGDs, the question remains if her autoimmune condition contributed



Abstract 162 Figure 1 Collagenous gastritis

towards her abnormal immune response leading to collagenous gastritis.

We recommend reporting more cases of collagenous gastritis so we can have a better understanding of the disease and in turn develop a successful treatment regime.

163 CASE REPORT OF HEPATIC ABSCESS IN AN ADOLESCENT WITH CROHN'S DISEASE

J Nelson*, M Shaukat, El Halabi, J Grunow, F Ramji. *University of Oklahoma Health Sciences Centre, Oklahoma City, OK*

10.1136/jim-2017-000697.163

Case report This patient is a 14-year-old male with past medical history significant for Crohn's disease of the terminal ileum who presented to the ER for acute abdominal pain and fever. Four weeks prior to presentation, he had had diffuse abdominal pain, fatigue, headache, subjective fever and chills, non-bloody and non-bilious emesis, as well as constipation and an associated 10 pound weight loss after vacationing in Colorado. He was started on a prednisone taper for a presumed Crohn's disease flare. Symptoms resolved, but on the last day of his prednisone taper he developed fever to 103F and right upper quadrant abdominal pain. He presented to the emergency room where labs were significant for leukocytosis with left shift, and an elevated ESR and CRP. Abdominal ultrasound indicated hypoechoic lesion in liver that was 6.5×4.2×7.6 cm. CT scan was consistent with hepatic abscess and showed multiple areas of wall thickening prominently in the terminal ileum, with a possible mucosal ulceration in the terminal ileum. On exam, his abdomen was mildly distended and he was tender to palpation over his RUQ with guarding. He was started on IV flagyl and IV rocephin prior to drainage of 60ccs of purulent material the following day. His abscess culture grew *Streptococcus intermedius*. Flagyl was stopped. He was continued on rocephin daily until repeat abdominal ultrasound showed significant improvement of his hepatic abscess, which totaled 30 days.

Discussion While hepatobiliary diseases are common extraintestinal manifestations of IBD, the development of hepatic abscesses is uncommon. Hepatic abscesses are more common in Crohn's disease than in ulcerative colitis, and typically present in patients with active Crohn's but may be the initial presenting complaint as well. This case illustrates the need to complete a thorough workup in a patient with Crohn's disease presenting with abdominal pain and fever to rule out hepatic abscess prior to starting treatment for a presumed Crohn's flare.

164 CELIAC ARTERY COMPRESSION SYNDROME: AN UNDER-DIAGNOSED CAUSE OF ABDOMINAL PAIN: PRESENTATIONS AND OUTCOMES

¹J Nichols*, ¹B Davis, ¹I Al-Bayati, ²M Ghaleb, ¹J Diaz, ¹R McCallum. ¹Texas Tech Health Science Centre El Paso Paul L. Foster School of Medicine, El Paso, TX; ²University Medical Centre El Paso, El Paso, TX

10.1136/jim-2017-000697.164

Purpose of study Celiac artery compression syndrome (CACS), an uncommon disorder due to compression of the celiac artery (CA) by the median arcuate ligament (MAL), presents

unexplained severe upper abdominal pain. This study presents three cases.

Methods used Three CACS cases are summarised with chief complaint, diagnostic studies, therapies, and outcomes.

Summary of results Case 1: A 38-year-old female presented with unexplained upper abdominal pain refractory to traditional therapies. Doppler ultrasound (DU) showed a peak systolic velocity (PSV) of 213 cm/s and end diastolic velocity (EDV) of 57.8 cm/s on inspiration while expirational PSV and EDV were 323 cm/s and 103 cm/s, respectively. Abdominal aortogram (AA) was diagnostic for CACS at >70% compression of CA on expiration. Intra-operative DU velocities normalised after surgical release of MAL with expirational PSV and EDV at 178 cm/s and 52.0 cm/s, respectively. At 2 year follow-up, there was >80% pain relief, and a repeat AA was normal.

Case 2: A 55-year-old female presented with severe epigastric pain requiring narcotics and unexplained by standard diagnostic studies. DU velocities and AA findings were typical of CACS including >50% narrowing on expiration. Endoscopic ultrasound-guided celiac plexus block (ECB) provided transient relief, and surgical release of MAL was confirmed by intra-operative DU. Over a 3 year follow-up, a repeat AA study was normal with 75% relief of abdominal pain being achieved.

Case 3: A 21-year-old female presented with epigastric pain of enigmatic aetiology. DU velocities suggested CACS, and then AA revealed diagnostic CA narrowing. Surgical release of MAL was confirmed with intra-operative DU normalisation, and pain relief was 100% at 3 month follow-up.

Conclusions CACS:

- Consider when patient's epigastric pain is disproportionate to objective findings.
- Initial screening by DU reveals typical CA flow velocities, while diagnosis is confirmed by >50% narrowing on AA during expiration.
- ECB provides brief symptomatic relief, possibly predictive of full resolution after surgical release of MAL.
- Celiac plexus compression and not blood flow obstruction explains the clinical spectrum.

165 OUTCOMES OF INCIDENTALLY FOUND PANCREATIC CYSTS

L Parsa*, S Sontj, CR Tombazzi, C Tombazzi. *UTHSC, Germantown, TN*

10.1136/jim-2017-000697.165

Purpose of study The prevalence of pancreatic cysts among U. S population varies between 3%–15% and increases to 15%–25% after the age of 70. The risk of malignant transformation of an asymptomatic pancreatic cyst is estimated to be 0.24%/yr. The risk is even lower if no change in characteristics over five years. The aim of our study is to find the incidence of malignancy in incidentally found pancreatic cysts and to evaluate the accuracy of endoscopic ultrasound in predicting malignancy.

Methods used We conducted a retrospective chart review of all incidentally found pancreatic cysts who underwent endoscopic ultrasound (EUS) between the 1/1/2011 until present date at our VA Medical Centre. We included 30 patients.

Data gathered included demographics, cyst features on the initial diagnostic study, and changes found on surveillance.

Summary of results Out of 30 patients, we lost two patients to follow up. On initial evaluation with EUS/FNA, two cysts were found to be mucinous cystic neoplasms (MCN), one to be a serous cystic adenoma, and one pancreatic adenocarcinoma all of which were confirmed after surgery. Out of the remaining 24 patients followed, only one patient developed pancreatic cancer. This patient's initial evaluation didn't show worrisome criteria, however it showed increase in size over a three year follow-up; he underwent surgery and a diagnosis of malignant intraductal papillary mucinous neoplasm (IPMN) was made. An additional patient that underwent surgery due to increasing cyst size revealed serous cystadenoma. Twenty two patients with no worrisome criteria by EUS have been followed for a mean duration of 48 months. None of them have developed cancer. Overall EUS was able to differentiate benign from malignant cyst in all patients.

Conclusions Our study showed that endoscopic ultrasound is a valuable tool in both initial diagnosis as well as follow-up of pancreatic cysts. We should be concerned of even a single worrisome feature as one of our patients developed malignancy only with one worrisome feature during follow-up.

166 SYMPTOM PRESENTATION OF PAEDIATRIC PATIENTS WITH EOSINOPHILIC ESOPHAGITIS: NEW DIAGNOSIS VS FOLLOW-UP

*C Pierce, W Casper, M Lynch, MJ Barnes, R Dimmitt. *University of Alabama, Birmingham, AL*

10.1136/jim-2017-000697.166

Purpose of study The study examined the symptom presentation of paediatric patients newly diagnosed with Eosinophilic Esophagitis (EoE) compared to patients with EoE requiring a follow-up endoscopy. Given treatment, it was hypothesised that the group receiving a follow-up scope would present with improved symptom presentation as compared to patients who are newly diagnosed with EoE.

Methods used 49 paediatric patients with EoE (mean 11.33 years) were recruited at the time of their upper endoscopy. 18 patients were newly diagnosed, while 31 were undergoing a follow-up scope. Caregivers completed the PedsQL EoE Symptoms Scales, recording how much of a problem 10 symptoms of EoE have been for their child over the past 7 days. Medical information was gathered via medical record.

Summary of results Results indicate that while histological results (i.e., eos/hpf) were similar, patients with EoE requiring a follow-up scope reported an overall symptom experience that was significantly more severe than patients newly diagnosed with EoE after controlling for patient age, race, and sex ($F(1,43)=4.55$, $p<0.05$). Patients with EoE undergoing a follow-up scope identified chest pain ($t^2(2)=6.75$, $p<0.05$) and needing more time to eat ($t^2(2)=10.71$, $p<0.01$) as a significantly greater problems than patients newly diagnosed with EoE. There were no significant differences in the other EoE symptoms (i.e., stomach ache, dysphagia, etc.) between groups.

Conclusions The symptom presentation of paediatric patients with EoE requiring a follow-up scope was significantly worse but histological results were similar to than those newly diagnosed. While all patients requiring a follow up scope were being treated for EoE, adherence was not assessed. Given the

cross sectional design of the study, it is not possible to determine the progression of symptoms. Physicians should continue to be aware of the possible change and/or increase in symptom presentation over time to monitor the degree to which treatment is successfully managing symptoms.

167

DIOS: A DIFFICULT CASE OF INTESTINAL OBSTRUCTION IN A CYSTIC FIBROSIS PATIENT

¹A Pogribny*, ¹R Zwiener, ²P Arias. ¹LSUHSC, New Orleans, LA; ²Children's Hospital of New Orleans, New Orleans, LA

10.1136/jim-2017-000697.167

Case report Distal Intestinal Obstruction Syndrome (DIOS) is a complication in cystic fibrosis (CF), where viscid mucofeculent material becomes obstructed in the distal small bowel, typically the ileocecum. Pancreatic insufficiency, history of abdominal surgery, history of meconium ileus, and severe CF genotypes place patients at highest risk. Patients typically present with acute abdominal pain and radiographical evidence showing faecal loading in the right lower quadrant. Aggressive medical management with laxative or mucolytic therapy will often relieve the obstruction; however, the severity of obstruction, signs of perforation or intestinal ischemia, or clinical worsening may require invasive methods for relief.

We present the case of a 12 year old male with a history of cystic fibrosis with minimal lung disease, but with pancreatic insufficiency requiring exogenous pancreatic enzymes who presented on two occasions to the ER with abdominal pain and constipation. He was initially treated with a Fleet's enema which provided little relief and returned several days later with worsening abdominal pain, distension, and persistent emesis. Due to the location of the obstruction in the distal small intestine, directed therapy was needed to reach the occlusion. Radiologically-guided gastrografin enema was attempted twice unsuccessfully. Due to the extent of obstruction, progression of abdominal distension, and limited improvement, surgery was involved. The patient was taken to the OR for a diverting ileostomy with a conduit for directed n-acetylcysteine lavage. His course was complicated by septic shock and aspiration of gastric contents leading to ARDS requiring an extended antibiotic course, multiple pressors, and mechanical ventilation. Continued n-acetylcysteine directed therapy into the ileostomy successfully relieved the obstruction. After a long ICU course requiring significant supportive therapy, the patient recovered fully.

With aggressive medical management utilising a variation of laxatives or mucolytics, most cases of DIOS may be treated medically. Progression to severe obstruction, perforation, or ischemia prompt surgical intervention. Surgical risks include intra-abdominal infection, aspiration of gastric contents, and septic shock.

168

SIMPLE GASTROINTESTINAL BLEED TURNED OUT TO BE A FISTULA FROM HEART: VERY RARE PRESENTATION

A Qasim*, D Harper, T Johnson, M Patel. *TTUHSC, Amarillo, TX*

10.1136/jim-2017-000697.168

Background Penetration of the heart is uncommon which usually results from traumatic injuries. Even more uncommon is to

develop a fistula between myocardium and GI tract. We describe a very rare presentation of Ventriculo-gastric fistula in a patient with esophageal cancer.

Case report A 77 years old male patient, h/o esophageal carcinoma presented with severe UGIB. had h/o esophagectomy and jejunal esophagogastric interposition along with radiation and chemotherapy in 1982. He was unstable, BP of 60/40 and HR 120. OG Tube yields 2 L of dark red coloured blood. Initial Hb was 3.9. Because of instability, he was intubated and transferred to ICU. Massive transfusion protocol was initiated to maintain BP. An emergent EGD revealed jejunum (interposed between oesophagus and stomach) full of blood. Stomach also full of blood. Source of bleeding was not clear. Emergent angiogram of superior mesenteric artery and celiac trunk did not show source of bleeding. Then CTA of abdomen was done which showed a tracking of contrast from inferior wall of left ventricle through diaphragm into the stomach. The possibility of ventriculo-gastric fistula was sought. After 12 hours, patient became hemodynamically stable and stopped bleeding. Echocardiogram showed inferior wall akinesia. Cardiac cath showed normal coronaries. Ventriculogram showed inferior wall akinesia with aneurysm formation but no extravasation of contrast (Most likely as patient stopped bleeding). The site of aneurysm formation without coronary artery disease was indirectly suggestive of the site of ventriculogastric fistula. Patient was transferred to higher level of care for surgical correction of fistula.

Discussion Our case is unique because it is extremely rare to diagnose this condition in an alive patient. We think that this patient developed ventricular-gastric fistula as a complication to his previous surgery. We think that extravasation of blood happened during the diastolic phase and fistula obliterated during the systolic phase resulting in relatively slower bleeding giving time to stabilise the patient. There are only few cases reported in literature. Outcome of these cases is very poor and mostly diagnosis is made during autopsy.

Conclusion Ventriculo-gastric fistula can present as a very rare cause of severe UGIB in a patient with previous upper GI surgeries.

169

HEPATIC ENCEPHALOPATHY WITH RAPID DEGENERATION INTO HEPATOCEREBRAL DEGENERATION

SK Prieto, T Mingbunjerdsuk, M Quirch*. *TTUHSC, Lubbock, TX*

10.1136/jim-2017-000697.169

Background Hepatic encephalopathy develops acutely in patients with liver dysfunction and is reversible with proper treatment. Multiple episodes can cause a degeneration into a persistent irreversible condition called acquired hepatocerebral degeneration (AHD). Clinical manifestations can include neuropsychiatric symptoms, extrapyramidal symptoms or both. Magnetic resonance imaging (MRI) demonstrates cerebral, basal ganglia, and cerebellar damage.

While hepatic encephalopathy is commonly reported in patients with advanced liver failure, AHD is rare and estimated to occur in about 1% of cirrhotic patients. The pathogenesis is not clear but it has been proposed that advanced liver failure causes deposits of toxic metabolites in the brain. Ammonia, gamma-aminobutyric acid receptors, altered amino acids, neurotransmitters, short-chain fatty acids, and manganese deposition all likely play a role.

Case report A 52-year-old man with hepatitis C and alcoholic liver cirrhosis was admitted to the intensive care unit with gastrointestinal haemorrhage and haemodynamic instability. Upper endoscopy revealed gastroesophageal varices with stigmata of recent bleeding and moderate portal hypertensive gastropathy. He was scheduled for transjugular intrahepatic portosystemic shunt placement, however, his mental status declined and he developed seizure-like activity. Labs showed an elevated ammonia level. He was treated aggressively for acute hepatic encephalopathy but continued to be obtunded after the ammonia level normalised. MRI and electroencephalogram were consistent with severe metabolic encephalopathy. He remained in a state of persistent impaired consciousness and acquired hepatocerebral degeneration was diagnosed. Treatments were unsuccessful and his neurological status never recovered.

Discussion The clinical presentations of AHD vary widely making it difficult to diagnose. The most common symptoms are extrapyramidal such as focal dystonia, dysarthria and choreoathetosis. Occasionally neuropsychiatric manifestations occur like lethargy, excessive somnolence and dementia. Impaired consciousness and coma-like states have only been reported in a few case reports. This rare presentation of AHD shows that there is much more to learn about the pathogenesis of AHD.

170 A RARE CASE OF GASTRO SPLENIC FISTULA ARISING FROM DIFFUSE LARGE B CELL LYMPHOMA

N Salagundla*, S Siddiqui, A Mirza, A Islam. *Texas Tech University HSC Amarillo, Amarillo, TX*

10.1136/jim-2017-000697.170

Case report A 55 year-old Caucasian male with PMH of HTN, MDD and GERD presented with melena for 3 weeks with LUQ abdominal pain and diarrhoea, up to 10 bowel movements/day, 13 lbs weight loss along with frequent subjective fever and night sweats. Social history/habits: Brief smoking history of 8 pack-years. No chronic alcohol or drug use. Vitals were within normal limits. Exam revealed fullness of LUQ without tenderness. Labs: include WBC: 17 100 with 85%neutrophils, 7% lymphocytes. Hgb 6.5 g/dL, Plt 648 k, LDH 501. CT scan of chest/abdomen/pelvis has shown 11×11.8 cm necrotic mass near stomach, spleen, and pancreatic tail with large air-fluid level in spleen and gastric wall. Bulky retroperitoneal lymphadenopathy present. CT-guided retroperitoneal para-aortic lymph node biopsy pathology and histology:100% Ki-67. Negative stain for BCL2. Flow cytometry indicated CD20, CD19, and CD10 positivity, consistent with diffuse large B cell lymphoma of monoclonal origin. Surgical exploration with drainage of intra-abdominal abscess was performed, notable gastro splenic fistula and tumour involvement of left lobe of liver, posterior wall of stomach, and distal pancreas, arising from spleen.

Discussion Gastrosplenic fistulas are rarely reported, but when occurring, tend to be associated with malignant processes. Abdominal mass with air-fluid levels can indicate tumour necrosis but can often indicate abscess collection due to GI tract communication. Here we report a middle-aged male who presented with upper GI bleeding found to have a large upper abdominal mass involving adjacent organs. CT-guided lymph

node biopsy indicated non-Hodgkin lymphoma (NHL), diffuse large B-cell lymphoma (DLBCL) subtype. Patient had subsequent resection of tumour and involved organs. After recovery from surgery, Initial treatment involved R-EPOCH (rituximab, etoposide, prednisone, Oncovin, cyclophosphamide, and doxorubicin). R-EPOCH shown to be superior to R-CHOP for high-intermediate IPI. Patient showed initial response with decreasing LDH. Surgical drainage with initial IV antibiotics and correction of fistula are typically necessary. Gastro splenic fistulas, while rare, may present with symptoms of GI bleeding. Current literature suggest primary resection of tumour involvement and treatment with chemotherapy.

171 ABERRANT RIGHT SUBCLAVIAN ARTERY: A RARE CAUSE OF DYSPHAGIA

C Saraceni*, W Kwan, TV Joshi, M Spera, S Landreneau. *LSUHSC, New Orleans, LA*

10.1136/jim-2017-000697.171

Introduction Aberrant right subclavian artery is the abnormal involution of the right 4th aortic branch and proximal right dorsal aorta. The retroesophageal course of the right subclavian artery behind the oesophagus, although usually asymptomatic, may cause compression and a type of dysphagia known as dysphagia lursoria.

Case description A 50 year old female with a medical history of von Willebrand disease and hypertension presents with a complaint of several weeks of progressive dysphagia. Her dysphagia began with solid foods and progressed to include liquids. Three days prior to presentation, she could not tolerate any solids or liquids by mouth and would have immediate regurgitation. The patient admits to about 60 lbs weight loss in the past two months.

Follow-up course CT neck angiography revealed a congenitally anomalous aortic arch with a retroesophageal aberrant right subclavian artery reaching as far superiorly as the T1 vertebral body. Barium esophagram revealed mild extrinsic mass effect on the posterior aspect of the upper oesophagus EGD revealed a normal appearing oesophagus, stomach, and duodenum with no eosinophilic components on biopsy. Esophageal manometry revealed a normal LES with normal relaxation.

Discussion Most patients with aberrant right subclavian arteries remain symptom-free throughout their lifetimes. Childhood disease usually presents as recurrent pulmonary infections and respiratory abnormalities. Possible mechanisms of adult onset disease including age related increased esophageal rigidity, right subclavian aneurysm formation, and elongation of the aorta.

Barium swallow may reveal a characteristic diagonal impression in the oesophagus at the level of 3rd-4th vertebra. EGD may reveal a pulsating mass at around the same level. Esophageal manometry may reveal a high-pressure zone 25–30 cm from the nose. CT angiography, angiography of the aortic arch, or endoscopic ultrasound may be used for definitive diagnosis.

Initial treatment should be conservative management using prokinetic or antireflux drugs. Surgical treatment may be attempted in those who do not respond to conservative management. In patients unsuitable for a surgical procedure, endoscopic dilation may temporarily relieve symptoms.

172 ABERRANT RIGHT SUBCLAVIAN ARTERY: A RARE CAUSE OF DYSPHAGIA

*C Saraceni, W Kwan, LS Engel, M Spera, S Landreneau. *LSU Health Sciences Centre, New Orleans, LA*

10.1136/jim-2017-000697.172

Introduction Aberrant right subclavian artery (also known as Arteria Lusoria) is the most common congenital anomaly of the aortic arch occurring in 0.5% to 1.8% of the population. The aberrant artery crosses midline behind the oesophagus (80%), between the trachea and oesophagus (15%), or anterior to the trachea (5%). The retroesophageal course of the right subclavian artery, although usually asymptomatic, may cause compression and a type of dysphagia known as dysphagia lursoria.

Case A 50 year old woman with a medical history of von Willebrand disease, hypertension, asthma, and peripheral neuropathy presented with several weeks of progressive dysphagia associated with heaviness in her chest and 60 lb weight loss. Her dysphagia began with solid foods and progressed such that three days prior to presentation, she could no longer tolerate solids or liquids. CT neck angiography revealed a congenitally anomalous aortic arch with a retroesophageal aberrant right subclavian artery. Barium esophagram did not reveal any intrinsic mass, polyp, diverticulum, or stricture. There was mild extrinsic mass effect on the posterior aspect of the upper oesophagus however this caused no limitation of contrast passage. An EGD was unremarkable and esophageal manometry was unremarkable with normal LES with normal relaxation.

Discussion Most patients with aberrant right subclavian arteries remain symptom-free throughout their lifetimes. Various proposed mechanisms for dysphagia include age related increased esophageal rigidity, right subclavian aneurysm formation, and elongation of the aorta.

Barium swallow remains an effective tool for initial evaluation usually showing a characteristic diagonal impression in the oesophagus at the level of 3rd-4th vertebra. EGD may reveal a pulsating mass around the same level. Esophageal manometry may reveal a high-pressure zone 25–30 cm from the nose. CT angiography of the aortic arch, or endoscopic ultrasound are often used for definitive diagnosis. Initial treatment with a prokinetic or anti-reflux drug may be followed by surgery or endoscopic dilation if conservative therapy fails

173 LARGE MASS IN DUODENUM SECONDARY TO PANCREATIC DIVISUM

Y Vorakunthada*, A Rakvit. *Texas Tech University Health Sciences Centre Lubbock, Lubbock, TX*

10.1136/jim-2017-000697.173

Case report Pancreas divisum (PD) is a common anatomical variation when there is failure of fusion of dorsal and ventral pancreatic buds during embryogenesis. Malignancy of minor duodenal papilla (MDA) is extremely rare, but cases of adenoma and carcinoid tumours have been reported. So, mass in the duodenum warrants further investigation. Here, we present a case of large mass at MDA due to PD.

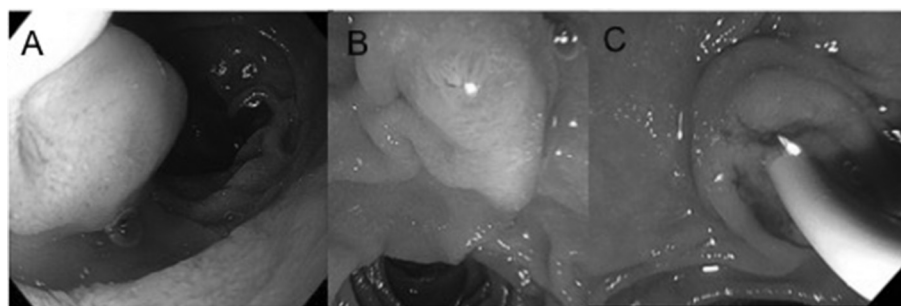
A 57-year-old female presented to clinic for screening endoscopy. She had epigastric pain for many years. Laboratory investigation was remarkable for elevated WBC of 16.99 K/UL and alkaline phosphatase of 200 INT units/L. Upper endoscopy revealed large mass, suspicious for adenoma, in the duodenum. Biopsy revealed acute duodenitis. Subsequently, she underwent Endoscopic Retrograde Cholangiopancreatography that revealed PD and significant bulging of the minor papilla (MP) that prevented cannulation. Biopsy from MP was negative for malignancy. The Plan of our patient is to investigate further with Magnetic resonance cholangiopancreatography with secretin and pancreatic enzymes.

MDP is composed of accessory pancreatic duct and remnant of pancreatic tissue from dorsal pancreas. In PD, the dorsal pancreatic duct becomes prominent vessel for drainage through the MDP, resulting in hypertrophy and recurrent pancreatitis.¹ However, our patient had no evidence of recurrent pancreatitis, possible from early diagnosis.

The correlation between PD and pancreatitis remained unknown but studies have demonstrated increase incidence of post ERCP pancreatitis.² MDP enlargement should be suspected in any patient with underlying PD who presents with recurrent abdominal pain.

REFERENCES

1. Terumi Kamisawa, *et al.* Clinical implications of accessory pancreatic duct. *World J Gastroenterol* 2010;**16**(36):4499–4503.
2. Jinru Shia, *et al.* Adenocarcinoma of the Minor Duodenal Papilla and its precursor lesions a clinical and pathologic study. *Am J Surg Pathol* 2014;**38**:526–533.



Abstract 173 Figure 1 (A) Duodenal mass, EGD, (B) Mass at minor papilla, ERCP, and (C) Stent at major papilla

174

CYTOMEGALOVIRUS INDUCED HEPATITIS IN A PATIENT WITH SYSTEMIC LUPUS ERYTHEMATOSUSM Zhang*, S Arikapudi, K Devani, M Young. *East Tennessee State University, Johnson City, TN*

10.1136/jim-2017-000697.174

Case report Human Cytomegalovirus (CMV) is a member of the herpesvirus family that is ubiquitous in the environment, causing flu like symptoms in immunocompetent patients. However, in immunocompromised patients, CMV infection may lead to the development or flare up of autoimmune diseases like Systemic Lupus Erythematosus (SLE) (Hsieh AH *et al.* 2011, 13: R162-10). Here, we report a 25-year-old female with history of discoid lupus admitted to hospital due to flare up. Patient presented with complaints of abdominal pain and rash. Exam revealed shallow oral ulcers and scattered patch of macular rash on face and extremities. Lab revealed pancytopenia and elevated transaminases. Serology revealed high titers of anti-nuclear antibody, anti-double stranded DNA (anti-dsDNA) antibody and low complement levels, consistent with SLE flare up. Antibody panel also revealed positive anti-smooth muscle and anti-ribonucleoprotein antibodies. Viral panel was negative for viral hepatitis and Human Immunodeficiency Virus, but revealed very high titers of CMV IgM of 236AU/ml (Normal <29.9) and positive CMV IgG. Patient was treated for SLE flare up with intravenous steroid. Patient's symptoms improved significantly within few days and transaminases trended down to the normal limits. CMV infection is frequently seen in patients with SLE. It may cause the onset of SLE, flare up of SLE or the virus may present as an isolated infection in patients with underlying SLE. This is due to a C terminal peptide of CMV protein pp65 that is highly immunogenic in the serum of patients with SLE and other autoimmune conditions (Hsieh AH *et al.* 2011, 13: R162-10). It is important for physicians to realise that there are many similarities of symptoms and overlaps between CMV infection and SLE flare (Ramos-Casals M *et al.* 2008 Nov;87(6):311-8). Although the consensus on treatment guideline is still not clear, it is important to identify underlying infections since the majority of SLE patients are immunocompromised and takes immune suppressive therapy. With early detection of treatable infections including herpesvirus and viral hepatitis, physicians can better treat many detrimental opportunistic infections and may shorten the flare up of rheumatologic diseases.

Health care research, quality improvement
and patient safety

Joint plenary poster session and reception

4:30 PM

Thursday, February 22, 2018

175

UTILITY OF INDEX HOSPITALISATION CHARACTERISTICS IN PREDICTING 30-DAY HOSPITAL READMISSION IN THE UNITED STATES

¹M Agarwal*, ²M Shah, ¹R Bradsher. ¹UTHSC, Memphis, TN; ²Montefiore Medical Centre, Bronx, NY

10.1136/jim-2017-000697.175

Purpose of study 30 day readmissions after patient's initial hospitalisation are broadly accepted as a negative utilisation of healthcare resources. Despite this, impact of index hospitalisation characteristics on readmissions is poorly understood. Hence we studied patient characteristics and readmission outcomes in 18,520,527 patients who survived the index hospitalisation across US.

Methods used Using the 2013–2014 National Readmission Database, patient demographics, hospital and admission characteristics, and clinical comorbidity burden (measured by the Charlson Comorbidity Index) recorded at the time of admission were studied to describe the impact on 30 day readmissions. We then randomly selected 50% population to derive a predictive model and validated it in other 50% cohort.

Summary of results There were 18,520,527 hospitalizations with top five primary reasons for admissions as septicemia (5.1%), heart failure (5.0%), acute respiratory failure (3.1%), atrial fibrillation (2.8%) and acute myocardial infarction (2.7%). Among whole cohort, 10.5% (n=1,936,236) patients were readmitted within 30 days of discharge. When compared with single-admitters, re-admitters were older (mean: 62.8 years vs 55.4 years), males (46.7% vs 38.2%), public insurers (73.5% vs 59.2%) and belonged to lower socioeconomic status (29.9% vs 27.3%) (all $p < 0.001$). Higher readmission rates were seen in patients who were admitted on weekends (21.1% vs 19.6%), emergent basis (84.0% vs 73.0%) and to non-teaching facilities (56.2% vs 55.5%) (all $p < 0.001$). Higher comorbidity burden and longer length of stay were both significantly associated with higher 30 day readmission (all $p < 0.001$). Our model had a good prediction ability (area under curve, c-statistics 0.70, 95% CI: 0.69 to 0.71) for 30 day readmissions in both derivation and validation cohort.

Conclusions Patient demographics, admission characteristics, and clinical comorbidity burden at the time of index hospitalisation significantly predicted 30 day readmissions. The proposed readmission predictive model can be used to guide healthcare resources and target interventions for reducing readmission among the highest-risk patients.

176

CHRONIC PERITONEAL IN-DWELLING CATHETERS FOR THE MANAGEMENT OF MALIGNANT AND NON-MALIGNANT ASCITESJ Caldwell*, H Edriss, K Nugent. *Texas Tech University Health Sciences Centre, Lubbock, TX*

10.1136/jim-2017-000697.176

Purpose of study Ascites is a debilitating condition affecting many patients with end-stage liver disease and advanced abdominal malignancies. Serial paracentesis can reduce the symptoms of refractory ascites, but this procedure requires frequent trips to a clinic. Indwelling peritoneal catheters are an alternative which can allow these patients to manage their symptoms at home. This review aims to assess the safety and efficacy of these devices.

Methods used A literature database search was conducted to identify relevant studies which reported indwelling catheter placement in patients with chronic ascites. Inclusion criteria were articles which included at least 20 adult patients and had been published within the past 15 years. Patient demographics, indication, complication rates, and survival times were analysed.

Summary of results Fourteen studies comprising 957 patients (687 with malignancy [71.7%], 270 without [28.3%]) were reviewed. Symptom improvement was reported in all cohorts. The most common complication in patients with malignant ascites was catheter dysfunction (39/687, 5.7%). Overall infection rate for patients with malignancy was 5.4% (37/687); patients with pancreatic malignancy made up at least 70.2% (26/37) of these infection cases. The infection rate for patients with nonmalignant ascites was 12.2% (33/270), while catheter malfunction was 1.1% (3/270). In general, infection risks significantly increased for devices in place for longer than 12 weeks. Average survival time after catheter placement was 7.2 weeks for patients with malignancy and 164 weeks for patients without malignancy.

Conclusions Indwelling peritoneal catheters are an effective alternative to paracentesis for the palliation of ascites in patients with certain malignancies. Peritonitis is a concern with these devices in patients with ascites due to nonmalignant etiologies in whom prolonged use is usual, but proper implantation technique and maintenance may greatly reduce infection risks.

177 REDUCING UNPLANNED EXTUBATIONS IN THE NEONATAL INTENSIVE CARE UNIT – A QUALITY IMPROVEMENT PROJECT

^{1,2*}SK Chilakala, ^{1,2}AJ Talati, ¹K Willis, ²K Smith, ²K Conlee. ¹UTHSC, Germantown, TN; ²Regional One Health, Memphis, TN

10.1136/jim-2017-000697.177

Purpose of study Unplanned extubation (UE) in the Neonatal Intensive Care Unit (NICU) is a serious safety hazard and can be tied to increased risk of mortality and morbidity. There is no established best practice of securing an Endotracheal tube (ETT). The incidence of UEs within NICUs is not well described in the literature, but the associated rates are thought to range between 2–4.8 per 100 ventilator days. We aim to estimate our baseline UE rate, and implement a quality improvement initiative in our Level IV NICU to reduce our unplanned extubation rate by 50% within 6 months of implementation. We also aim for a stretched goal of achieving an UE rate below 2 per 100 ventilator days within 1 year.

Methods used In April 2016, UE Task Force was formed in our unit and developed an interdisciplinary cause analysis tool to identify root causes and calculate incidence of UE. In November 2016, the QI was initiated in which we implemented standardised securement approach of Endotracheal tube (ETT). This included using right size Neobar, spiral taping of the ETT, re securing the tape every 3 days, 2 care givers for all the patient procedures, documentation of the position of ETT and verification with airway alert card. In addition, increasing the awareness amongst the staff by using display board showing the number of days since last UE, extra caution in airway management for infants with higher risk of UE, tracking all events and debriefing after every UE, multi-disciplinary weekly respiratory rounds have been implemented.

Summary of results The Key measure used was median UE rate per 100 ventilator days. Data was collected and abstracted for 6 months prior to intervention and 11 months following the intervention. During the pre-intervention period the UE rate was 6.5. During the post intervention period, the UE rate remained 3.6 which is a 46% decrease.

Conclusions In addition to the standardised securement approach of ETT which has been shown to be effective previously, our approach of resecuring the ETT every 3 days and identifying and implementing extra caution in infants with higher risk of UE has been effective in reducing the UE rate. With ongoing staff training, education, detailed documentation and debriefing, we plan to achieve and sustain our stretched goal.

178 PILOTING UNIVERSAL HEALTH LITERACY PRECAUTIONS IN SPANISH SPEAKING PARENTS OF PAEDIATRIC PATIENTS

M Cooper*, S Gillaspay, R Blucker, M Dunlap. Oklahoma University Health Science Centre, Oklahoma City, OK

10.1136/jim-2017-000697.178

Purpose of study The purpose of this study is to evaluate acceptability of institution of universal health literacy precautions consisting of standardised visual aids, instruction, and teachback targeting dosing of liquid medicines by Spanish speaking caregivers of paediatric patients.

Methods used We are currently in the process of recruiting a convenience sample of twenty Spanish speaking caregivers of paediatric patients between one month and twelve years of age who are receiving liquid medication at their visit. Following a visit at which liquid medication is prescribed, caregivers will be consented and administered the Newest Vital Sign (NVS) and the Short Test of Functional Health Literacy in Adults (S-TOFHLA) by a research assistant in Spanish. Caregivers will undergo a brief tutorial using print materials based on the HELPix program from NYU School of Medicine consisting of an illustration of their medication dosing in a syringe, and a log tailored to their dosing schedule. Pictogram/teachback sessions will be timed to test for possible clinic integration acceptability. Each caregiver will be given a survey regarding the universal health literacy precautions procedures. We will invite each participant in the intervention arm to return for a focus group, with the goal of having four focus groups of five participants each to review the procedures and suggest improvements to the process.

Summary of results As of October 2017 we have recruited four caregivers, and we anticipated having our full complement for the study within two months.

Conclusions From the surveys and focus groups sessions we expect to gauge acceptability of an intervention which has been shown to be effective in other settings. With this pilot data we plan to adjust the intervention if needed and transition into a larger scale efficacy trial.

179 USING ELECTRONIC HEALTH RECORDS TO IDENTIFY ADVERSE DRUG EVENTS IN AMBULATORY CARE: A SYSTEMATIC REVIEW

¹C Feng*, ²AB McCoy. ¹Tulane University School of Medicine, New Orleans, LA; ²Tulane University School of Public Health and Tropical Medicine, New Orleans, LA

10.1136/jim-2017-000697.179

Purpose of study Previous work has established a high prevalence of adverse drug events (ADEs) in the ambulatory setting. We aimed to identify the methods used and determine the

roles of electronic health records (EHRs) in detecting and assessing ADEs in the ambulatory setting through systematic review of published literature.

Methods used We performed a systematic literature review by searching PubMed and Google Scholar for studies on ADEs detected in the ambulatory setting involving any EHR use published before June 2017. We extracted study characteristics from included studies related to ADE detection methods for analysis.

Summary of results We identified 30 studies that evaluated ADEs in an ambulatory setting with an EHR. In 27 of the studies, EHRs were used only as the data source for ADE identification. In 2 studies, the EHR was used as both a data source and to deliver decision support to providers during order entry. In 1 study, the EHR was a source of data and generated patient safety reports that researchers used in the process of identifying ADEs. Methods of identification included manual chart review by trained nurses, pharmacists, and/or physicians; prescription review; computer monitors; electronic triggers; ICD codes; natural language processing of clinical notes; and patient phone calls and surveys. Seven of the studies provided examples of search phrases, lab values, and rules used to identify ADEs.

Conclusions Tools such as computer monitors and electronic triggers are replacing traditional chart review as means of detecting ADEs. These tools can be used with EHRs to enable researchers to better measure, characterise, and detect ADEs in the ambulatory setting. Further research is necessary and underway to measure ease of chart review in the EHR versus with traditional paper charts to determine which is most effective.

180 A GLOBAL HEALTH TRIP EXAMINED – RURAL PERU

H French*, C Studdard, A Herren, J Cavo, T Littmann, S Ashley, D Caton, R Smalligan. *UAB, Huntsville, AL*

10.1136/jim-2017-000697.180

Purpose of study Designing a health care trip to a developing country can be difficult if patient needs and expectations are not known. As more students and faculty take part in short-term experiences to developing countries, having an idea of what to expect can improve patient care, satisfaction and outcomes. This study summarises recent experiences from such a trip to rural Peru.

Methods used Prior to the trip the team reviewed a global health trips ethics module. The team included 5 medical students, 1 FM resident, 1 IM resident, and 1 IM/Peds attending. Dose packs of multiple meds were prepared with instructions in Spanish. Clinics were held in five villages within a 2 hour drive of the small town of Curahuasi, Peru. Medical and vision stations were set up in a school, community centre or church as available. Patients' age, sex, chief complaints, BP and meds given were recorded and analysed using Excel.

Summary of results A total of 541 patients of Quechua lineage were seen during the 5 clinic days: 306 female, 186 male, (43 not recorded) with a F:M ratio of 1.7:1; average age 32, (6 mo-92 years); average adult BP 100.2/68.9 mmHg. Common complaints included parasites (101), back pain (99), vision/eye problems (91), musculoskeletal pain/OA (89), abd pain (88), gastritis/GERD (79), headaches (69), and UTI (34). Most dispensed meds were albendazole, acetaminophen,

ibuprofen, omeprazole, ranitidine, multi-vitamins, iron, tinidazole among others. Less than 10 patients were referred to a local mission hospital for further rx or w/u (CHF, HTN, gall bladder dz, cervical CA). 90 pairs of reading glasses (+1-+4) were provided and over 100 pairs of sunglasses (to slow pterygium).

Conclusions The team had prepared for infectious diseases, GERD, DM, HTN, CHF, vision problems, and pain issues. Few patients had chronic diseases, likely because of their active (mostly agrarian) lifestyle, no obesity, low BPs and low-fat diet. The patients truly appreciated the personal evaluation and symptomatic rx. Many were thrilled with their reading glasses which allowed them to resume sewing, tapestry making or reading. Only a few were sick enough to be referred out. It is recommended that groups investigate and discuss expected common conditions with a local clinician if possible prior to such a trip to improve planning.

181 ANTI-EPILEPTIC MEDICATION AVAILABILITY IN RURAL OKLAHOMA

BC Gruenberg*, P Johnson, J Miller, I Kumar, M Deen, C Knoles. *University of Oklahoma, Oklahoma City, OK*

10.1136/jim-2017-000697.181

Purpose of study It's imperative that rural hospitals have access to appropriate medications to effectively abort status epilepticus as treating status epilepticus is time-sensitive. The objective of this study was to identify the availability of anti-epileptic drugs (AEDs) on formulary, and quantify the number of Stage I, II, and III AEDs available.

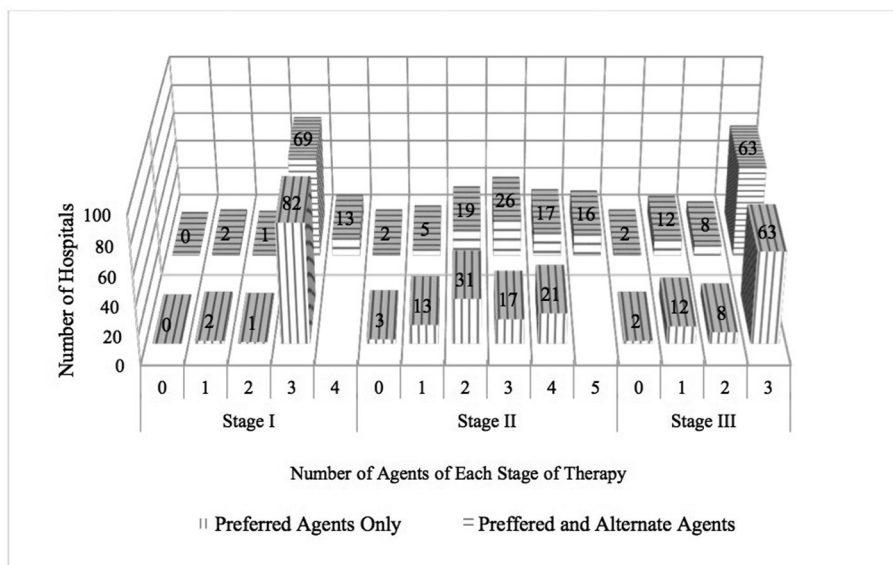
Methods used All Oklahoma hospitals in towns of less than 50 000 people were contacted and asked to participate in an anonymous phone survey about the availability of AEDs in their hospital.

Summary of results In rural Oklahoma only four hospitals have all of the recommended medications; although 96% have at least one preferred medication from each Stage. The most common medications available were from Stage I and III with 19% of responding hospitals reporting one or less preferred Stage II medications.

Conclusions There is a disproportionate availability of Stage I and III AEDs compared to Stage II.

Abstract 181 Table 1 Treatment stage and name of each medicine in this study

Stage	Subcategory	Generic name
Stage I	Preferred	Lorazepam (85)
		Diazepam (82)
		Midazolam (83)
Stage II	Preferred	Diazepam (rectal) (13)
		Fosphenytoin (59)
		Phenytoin (67)
Stage III	Preferred	Valproic Acid (36)
		Levetiracetam (48)
		Phenobarbital (67)
Stage III	Alternate	Propofol (68)
		Ketamine (66)
		Midazolam (83)



Abstract 181 Figure 1 Number of medications available per stage as reported by hospitals (responses rate=95.5%)

Number of hospitals which have the medication in parentheses.

182 IDENTIFICATION OF HIGH BLOOD PRESSURE DURING WELL-CHILD AND OBESITY ENCOUNTERS IN A PAEDIATRIC TEACHING CLINIC

C Hays*, N Connolly. *University of Oklahoma Health Sciences Centre, Oklahoma City, OK*

10.1136/jim-2017-000697.182

Purpose of study Approximately 3.5% of children have clinical hypertension; this prevalence increases to nearly 25% in those overweight or obese. Identifying and appropriately managing elevated blood pressure in children can help reduce serious adverse health effects related to hypertension in both childhood and adulthood. The 2017 AAP Clinical Practice Guideline outlines recommendations for routine blood pressure screening during well-child visits and other healthcare encounters to identify primary hypertension and asymptomatic secondary hypertension. Clinical practice guidelines should guide routine clinic processes to insure quality health care and to provide evidence-based education regarding blood pressure management for paediatric residents. The purpose of this study is to evaluate blood pressure measurement practices and identification of elevated blood pressure during well-child and obesity follow-up appointments in the University of Oklahoma (OU) Sooner Paediatrics first-year resident outpatient teaching clinic.

Methods used Using 2016–2017 billing records, 20 well-child appointments and 20 obesity follow-up appointments will be selected for each month. Retrospective chart review using the electronic health record will be used to determine the following for each visit: if blood pressure was measured, if elevated blood pressure was present, and if elevated blood pressure was acknowledged. Standard statistical methods will be used to analyse the data. Qualitative data involving the initial management of any identified elevated blood pressure will also be recorded.

Summary of results Results from the study will identify any missed opportunities in several areas: routine screening of blood pressure, identification of elevated blood pressure, and management/follow-up for patients with elevated blood pressure. Data from this study is currently being collected.

Conclusions The analysis of the survey results will help the OU Sooner Paediatrics first-year resident clinic recognise missed opportunities for identification and management of elevated blood pressure. This will open discussion regarding potential quality improvement related to nursing/clinic procedures and resident education in order to meet clinical guidelines, provide quality care, and help prevent co-morbidities associated with childhood hypertension.

183 SUPER-UTILIZERS: CHARACTERISTICS OF PAEDIATRIC PATIENTS THAT FREQUENTLY VISIT THE EMERGENCY ROOM

C Jacobs*, A Tufton, B Casey, K Wojcicki, M Benak, W Morgan. *LSUHSC, Metairie, LA*

10.1136/jim-2017-000697.183

Purpose of study Providing healthcare to children in the United States amid rising costs has become a highly debated issue. ‘Hot-spotting’ is a method of analysing patterns of super-utilizers of the healthcare system consume and receive services in an effort to decrease costs and improve the quality of patient care by providing super-utilizers with alternative, affordable healthcare options.

Methods used We reviewed 200 patients with four or more visits (defined as super-utilizers) to one paediatric ER over the course of one year. Patients seen by the hematology-oncology service, or who were admitted to the intensive care unit at any point over the course of the same year were excluded from the study. Data were collected on time of visits, diagnosis, whether the patient had a PCP, history of chronic medical conditions, demographic information, and other medical information, and were compared to a separate group of patients who had only one ER visit over the course of the same year.

Summary of results Super-utilizers had an average age of 5.5 years, with 50% of the patients under the age of 3. 45% of

the patients lived in the same 3 zip codes. The average time of visit was 2:30 on a weekday, and less than 5% were admitted to the hospital for closer monitoring. Over 80% had a documented primary care physician, and 30% had at least one chronic medical condition; 20% had a prior diagnosis of asthma. There was no statistical significance in admission rates, ages, or time of visit between super-utilizers and patients with a single ER visit over this one year period.

Conclusions More data and further analyses are needed to determine the reasons these patients consistently chose an ER visit instead of going to their PCP for minor health concerns. By understanding why these super-utilizers are not selecting to visit primary care physicians we hope to improve physician-patient communications, and patient education by addressing the issues that are currently influencing their decisions to go directly to the ER. The goal is to lower healthcare costs by ensuring these patients make appropriate healthcare choices to receive affordable, quality healthcare from a primary care physician.

184 ALL-TERRAIN VEHICLE INJURIES IN 2006 AND 2016: DETERMINING DEMOGRAPHICS TO INITIATE INTERVENTIONS

K Jeffries*, A Burks, M Nichols, W King, K Monroe. *University of Alabama, Birmingham, AL*

10.1136/jim-2017-000697.184

Purpose of study Over the past decade, the number of all-terrain vehicle (ATV) related injuries treated in United States emergency departments has decreased by thirty-three percent with nearly 1 00 000 injuries in 2016. AAP guidelines state that ATV operators should be at least 16 years of age. Yet, children under the age of 15 continue to represent nearly a third of all ATV-related injuries.

Methods used In this retrospective study, medical records of an urban paediatric children's hospital were queried for ATV-related injuries. Relevant demographic information including sex, age, ethnicity, type of injury, month of injury and zip code of residency were obtained using EMR queries and chart review from 2006 and 2016. Inclusion criteria included children less than 18 years of age and an Emergency Department visit for an ATV-related injury. Data were entered into Excel spreadsheet for comparisons. Pearson correlation coefficient was used to compare rates of ATV-related injuries and rates of ED annual census.

Summary of results A total of 47 children were seen in the study ED in 2006 and 105 were seen in same ED in 2016. The median age of children seen in 2006 was 9 years old (SD \pm 3.99) while the median age in 2016 was 12 years old (SD \pm 3.88). These children were primarily males (78% in 2006, 60% in 2016) and nearly half of them live in the same region (43% in 2006, 56% in 2016). Based on the dramatic increase from 2006 to 2016, we looked at ATV-related injuries from 2000 onward and found strong positive correlation between year and ATV injury visit rate (adjusted for number of ED visits in that particular year) ($r=0.86$, $r^2=0.74$), with a significant increase from 2012 to 2016.

Conclusions The total number of children evaluated for ATV injuries in study ED more than doubled within 10 years. This demographic information illustrates a dramatic rise in ATV-related injuries seen in our ED which interestingly appears to be counter to the gradual decline in national treated injuries

over the same time period. We also note a higher than expected increase in ATV-related injuries in our ED per volume. Using this information, we can help define where and with whom specific interventions will be most effective in reducing the number of ATV-related injuries.

185 CHARACTERISATION OF YOUNG CHILDREN PRESENTING TO THE EMERGENCY DEPARTMENT FOR MENTAL HEALTH COMPLAINTS

K Mallicoat*. *University of Alabama at Birmingham School of Medicine, Birmingham, AL*

10.1136/jim-2017-000697.185

Purpose of study The primary objective of this study was to characterise children less than 10 years of age who presented to a paediatric emergency department for mental health complaints.

Methods used One researcher reviewed medical records of children less than 10 years old who presented to Children's of Alabama emergency department between January 2016 and May 2016 with a mental-health-related chief complaint. We then categorised patients based on demographic information, characteristics of the emergency department visit, and past medical and social history. Descriptive analyses were run using SAS version 9.4.

Summary of results 222 patients ages 10 years and under were seen between January and May 2016. This age group makes up 20% of all children seen in the ED for mental-health-related complaints. In this group of patients, 73% were male ($n=162$) and ages ranged from 3–10 years with a mean age of 7.8 years. Patients were 55% Caucasian ($n=122$), 42% African-American ($n=94$), 1% Hispanic ($n=2$) and 1% other ethnicity ($n=3$). Patient's insurance coverage was 76% Medicaid ($n=168$), 18% private insurance ($n=39$), and 6% uninsured ($n=14$). Of the 219 patients treated in the ED (3 left without treatment), 45% of patients were admitted ($n=100$). Univariate analyses showed increased odds of admission for children with 2 or more prior psychiatric diagnoses (OR=2.33, $p=0.03$), a family history of psychiatric illness (OR=2.53, $p<0.01$), history of any previous psychiatric care (OR=2.61, $p=0.01$), and a history of trauma (OR=1.84, $p=0.03$).

Conclusions The paediatric emergency department sees a significant amount of children under age 10 for mental-health-related complaints. Nearly half of these children were admitted for psychiatric care. Several factors were found to predict admission, which reflect psychosocial influences.

186 USE OF CELL PHONES WHILE DRIVING AMONG PARENTS

¹K Massey*, ²G Spears, ²W King, ²K Monroe. ¹Childrens Hospital of Sacred Heart, Pensacola, FL; ²University of Alabama, Birmingham, AL

10.1136/jim-2017-000697.186

Purpose of study Motor vehicle crashes (MVCs) are the number one cause of death for adolescents. Distracted driving has been implicated as a major contributor to MVCs. Previous studies show that parental behaviours impact teen driving behaviours. This study evaluates cell phone use of parents at a community paediatrician office versus cell phone use of

parents of adolescents in an urban Emergency Department (ED).

Methods used After approval from the UAB Institutional Review Board, parents (of children birth to 18 years) at community paediatrician offices (n=150) were surveyed as they brought their child for paediatrician visit (GROUP 1) while parents (of children 13–18 years) were surveyed during an ED visit (GROUP 2). Survey questions included how often do you use your cellphone while driving?

Summary of results A total of 150 participants were enrolled in Group One with 76% (n=114) females, 24% (n=36) male. A total of 42 participants were enrolled in Group Two with 95% Female (n=40) with 5% male (n=2). A total of 132 (88%) parents in group one reported using the cell phone while driving versus 17 (41%) of parents in group two reported using the cell phone while driving. More parents in Group one reported cell phone use while driving than parents in Group two ($X^2=42.6$, $p<0.0001$).

Conclusions Previous studies have shown that parental behaviours have an impact on adolescent driving behaviours. We also know that distractions such as cell phone use put adolescent drivers at increased risk of mvc. This study shows that while many parents engage in cell phone use while driving, more parents of attending community paediatrician visit reported engaging in this high risk behaviour than did parents of adolescents in the ED. Outreach efforts to decrease high risk driving behaviour among parents is needed.

187

DONOR-RECIPIENT MATCHING IN DECEASED DONOR LIVER TRANSPLANTS: ANALYSIS OF OUTCOMES USING UNITED NETWORK FOR ORGAN SHARING MATCH SEQUENCE DATA

MG Park*, J Seal, L De Gregorio. *Ochsner Medical Centre, New Orleans, LA*

10.1136/jim-2017-000697.187

Purpose of study A large proportion of the liver allografts at our centre are imported in many cases after being turned down by other transplant centres. We hypothesise that outcomes of transplantation with expanded criteria allografts can be optimised by selecting lower MELD low surgical risk recipients, by minimising blood loss, cold and warm ischaemic times and by maintaining haemodynamic stability during reperfusion period. To assess the effectiveness of this strategy, we analysed outcomes at our centre based on UNOS match sequence number to identify the cohort of expanded criteria grafts turned down by other transplant centres.

Methods used We conducted a single centre retrospective review of liver transplants performed at Ochsner Medical Centre from Jan 2012-Mar 2015 (n=533). The MSN, obtained from the match run for each donor, ranged from 1–7536 and was divided into quartiles. The 4th quartile (MSN 26–7536, n=133) was defined as the High MSN group and compared with quartiles 1–3 as a control group (MSN 1–25, n=400). Primary outcomes were patient and graft survival and early graft function as assessed by AST, ALT, total bilirubin and INR in the first week post-transplant.

Summary of results Higher rate of early allograft dysfunction was observed in the High MSN group as defined by Peak AST or ALT >2000 or bilirubin day 7 >10 or INR day 7 >2.0. The cold ischaemia times for the High MSN group were significantly longer than the control. Nearly 70% of control group

livers were from local OPO with the majority import livers from Share 35. Over 90% of the High MSN livers were imported from regional or national share. There was no significant difference in mean AST, ALT, bilirubin or INR between the control and High MSN groups at post-transplant day 7. There were no significant differences in patient and allograft survival between the control and High MSN groups during the early and follow-up periods. There was no significant difference in graft survival between local, regional and national share livers.

Conclusions Increasing marginal liver allografts utilisation in lower MELD recipients is possible without compromising post-transplant outcomes. Minimization of cold and warm ischaemia and avoiding surgically complex recipients are important factors to avoid intra-operative and post-transplant complications.

188

JET-INJECTION OF LIDOCAINE FOR PERIPHERAL VENOUS ACCESS IN THE PAEDIATRIC EMERGENCY DEPARTMENT

P Redmond*, J Davis, MN Frascogna. *University of Mississippi Medical Centre, Jackson, MS*

10.1136/jim-2017-000697.188

Purpose of study Peripheral venous access is one of the most common causes of pain in the paediatric emergency department (PED). Among the available techniques for local anaesthesia prior to peripheral venous access, jet-injection of 1% buffered lidocaine (or 'J-tip') is a promising modality because it is rapid and doesn't involve a needle. In most but not all reports in the literature, jet-injection of lidocaine has been shown to be effective for pain associated with peripheral venous access, however first attempt success rate has not been studied by means of a large prospective cohort. The primary objective of this study is to determine if using J-tip for local anaesthesia for peripheral venous access in the paediatric emergency department is associated with a reduction in first attempt success rates versus peripheral access performed without local anaesthesia. Our hypothesis is that there will not be a difference in first attempt peripheral venous access success rates between the two groups. Secondary objectives are to measure pain score differences and post-procedure complications between the cohorts.

Methods used Parents of children 6 months to 18 years old presenting to the ED and requiring intravenous (IV) access completed a survey. Nurses performing the IV placement were separated into control and exposure groups with equal ranges of experience and expertise and also completed surveys. Patients in the exposure group received 0.25 ml of 1% buffered lidocaine via jet injection prior to IV placement. Patients in the control group received no local anaesthesia prior to placement. First attempt success rate and pain scores were recorded. A three day follow up survey of patients was also conducted with both groups and post-procedure complications documented.

Summary of results To date, over 70 patients and nurses have been enrolled in the exposure group and 20 in the control group. Data collection is ongoing. Analysis is also to be undertaken in the next few months and preliminary results are anticipated to be ready for presentation at the SSPR conference.

Conclusions No conclusions as of today.

189

PHYSICIAN OVERPRESCRIBING: ONE DRUG FITS ALL?

¹R Renacci, ^{2,3}C Rolle, ^{2,4}E DeJesus. ¹Georgetown University School of Medicine, Washington; ²Orlando Immunology Centre, Orlando, FL; ³Emory University, Atlanta, GA; ⁴University of Central Florida-School of Medicine, Orlando, FL

10.1136/jim-2017-000697.189

Purpose of study Many clinical practices lack oversight of the preference and pattern of prescriptions (RXs) written by their healthcare providers (HCPs). Currently, there are no formal quality assessment (QA) tools for healthcare organisations to identify overprescribing of non-opioid drugs. We describe the impact of a single HCP-of-interest's (HCPOI) RX behaviour at a large HIV clinic in Central Florida.

Methods used Dolutegravir (DTG) was FDA-approved as a single agent to be used in combination with other antiretrovirals (ARVs) for the treatment of HIV infection in August 2013 and as a single DTG plus abacavir/lamivudine tablet (ADL) in November 2014. A routine QA in 2014 revealed an unexpectedly high proportion of patients were being treated with a DTG-containing regimen (DCR). We subsequently conducted a retrospective chart review of all patients seen from the date of DTG approval to 12 weeks after ADL approval. We used descriptive statistics to quantify the amount of DTG RXs written by the HCPOI, and compared it to 2 other clinic HCPs.

Summary of results We reviewed 6168 clinic charts; 4096 patients had an HIV diagnosis, and 3150 met inclusion criteria. The median age was 49 years, 83% were males, and the median duration of ARV therapy was 10 years. ARVs were initiated or changed in 971/3150 (31%) patients, and 670/971 (69%) were prescribed a DCR. Of these, 511/670 (76%) were prescribed by the HCPOI (who was caring for 38% of all HIV patients). At week 12 following ADL approval, 43% (511/1197) of all HCPOI patients were on a DCR, and he had an estimated 1.9% of the nationwide ADL market share.

Conclusions The impact of a single HCP on new drug sales can be easily missed and underestimated within the flow of patients seen at a large practice. Though, the novelty of new agents could be perceived as beneficial, an appropriate risk-benefit analysis must always be conducted to protect the welfare of patients. This study describes the experience observed at an HIV clinic; however, similar scenarios could be encountered at other specialty practices and highlights the need for a practical method to identify inappropriate prescribing of non-opioid drugs.

190

GEAUX WELL: AN INITIATIVE FOR RESIDENT WELLNESS

R Schexnayder*, A Severio, M Lemoine, C Diaz, C Sandlin. LSUHSC, New Orleans, LA

10.1136/jim-2017-000697.190

Purpose of study Burnout is the feeling of emotional and physical exhaustion and depersonalization. There have been strong associations between physician burnout and suicidal ideation. The purpose of this study was to determine if implementation of a formal wellness program would improve resident well-being and prevent burnout. We hypothesised that through establishment of the 'Geaux Well' program, residents would develop an increased resilience to overcome stressors both emotionally and physically.

Methods used LSU Paediatric residents were anonymously and voluntarily surveyed using the Physician Well-Being Index, a

questionnaire that evaluates for resident fatigue, burnout, stress, and overall quality of life. Residents were surveyed prior to program implementation and five months after implementation. The 'Geaux Well' program consisted of monthly wellness activities and conferences. Lectures focused on educating residents on stress management, coping techniques, and healthy lifestyle habits. Wellness activities served as physical and psychological outlets for residents to engage in and take a break from the work routine. In addition, residents had the opportunity to participate in social activities outside of work. Index scores pre and post-implementation were analysed to determine if overall resident wellness was improved after initiation of the 'Geaux Well' program.

Summary of results Pre-implementation survey results revealed that majority of residents felt burnt out from work and had been bothered by emotional problems. These results also demonstrated that most residents felt neutral to the notion that our residency program fostered an environment of wellness. Post-implementation survey results showed an improvement in residents' total index scores. Most residents also felt the implemented curriculum showed that the residency program fostered an environment of wellness.

Conclusions Nearly fifty percent of physicians report symptoms of burnout during their career. Due to the association between physician burnout and suicidality, especially among medical trainees, many residency programs are developing curricula that promote physician wellness. Our survey results suggest that implementation of a formal resident wellness program improves resident well-being and resilience.

191

THE ROLE OF PATTERNS IN FOLLOW-UP TESTING FOR LIVER FUNCTION TEST ABNORMALITIES

A Schreiner*, P Mauldin, V Durkalski-Mauldin, W Moran, J Zhang, D Rockey. Medical University of South Carolina, Charleston, SC

10.1136/jim-2017-000697.191

Purpose of study In this study, we compared liver function test (LFT) follow-up by patterns of original LFT panel abnormality. We studied LFT panels with single versus multiple abnormalities, as well as clinical patterns: cholestatic, hepatocellular, and mixed.

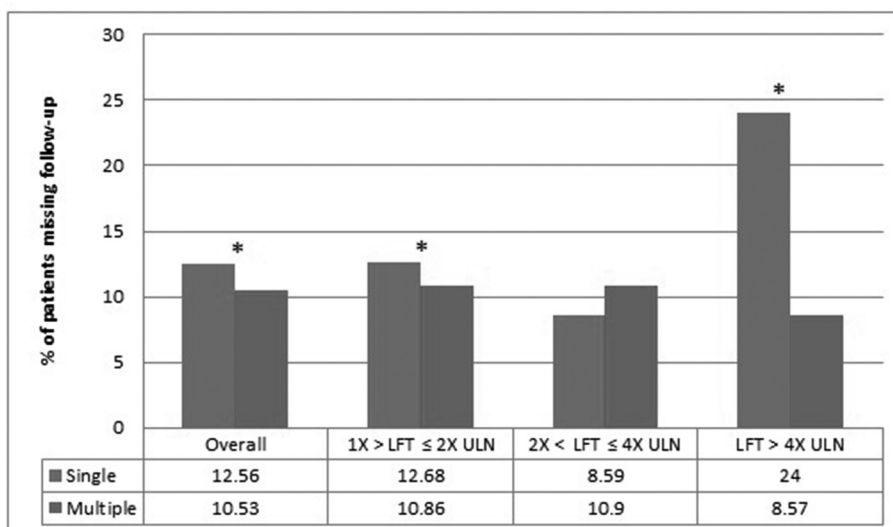
Methods used We performed a retrospective cohort study of patients with abnormal liver function tests (LFTs) in a primary care clinic. LFT abnormalities were categorised by the number of abnormal analytes (single vs multiple) and the patterns of those tests. Outcomes were repeat LFT testing and the time to repeat testing.

Summary of results Of the 9545 unique patients included, 6155 (64.5%) had 1 abnormal test and 3390 (35.5%) possessed multiple abnormalities.

Patients with only one abnormal LFT component were more likely to lack follow-up (12.56%) than those with multiple abnormalities (10.53%, $p=0.003$, figure 1).

Patients with only abnormal AST had the lowest rates of follow-up (10.7%, table 1). For combinations of abnormal LFTs, the AST-ALT combination of initial abnormality was most often lacking repeat assessment (12.6%).

Conclusions LFTs are not only frequently abnormal, but abnormalities clinically notable by test (i.e. bilirubin) or degree (i.e., >4 fold abnormal) are often not followed up.



Abstract 191 Figure 1 Proportion of patients missing follow-up LFT testing by number of abnormal LFT components

Abstract 191 Table 1 Proportion of patients missing follow-up LFTs, by test with initial abnormality

Test (n)	Overall	Degree of initial abnormality			p-value
		1–2 X ULN (n=5874)	>2–4 X ULN (n=256)	>4 X ULN (n=25)	
Bili (1679)	13.7%	13.7%	13.2%	22.2%	0.753
AST (3017)	10.7%	10.9%	6.8%	20.0%	0.217
ALT (838)	16.8%	16.9%	9.1%	-	0.701
ALP (621)	12.7%	13.0%	6.7%	33.3%	0.148
p-value	<0.001	<0.001	0.410	0.854	

was used to identify the barriers. Implementation approaches were discussed.

Summary of results Collaboration, sharing experience, education and a dedicated leader were key to implementing NRP changes. Barriers were issues related to obtaining new equipment at the different geographic location, technological coordination, new or inexperienced staff and amount of time needed to educate staff, and the delivery room culture (table 1).

Conclusions Overcoming the barriers to implementing cardiac monitoring by ECG during neonatal resuscitation in the delivery room required changes in administrative, budgetary, logistical, educational and personal practices, and successfully accomplished through a QI multidisciplinary team approach.

Abstract 192 Table 1 Barriers and multidisciplinary team approach used to facilitate implementation of revised NRP guidelines

Barriers	Coordinating party (meeting frequency)
Issues related to obtaining new equipment	Unit medical leadership (quarterly)
Challenges with technological coordination	Biomedical engineering (quarterly)
New or inexperienced staff	Nursing champion (monthly)
Amount of time needed to educate staff	Providers and staff physicians (bi-monthly)
Delivery room culture	Neonatal resuscitation team (ongoing)

192

IMPLEMENTATING ELECTROCARDIOGRAPHIC MONITORING DURING NEONATAL RESUSCITATION IN THE DELIVERY ROOM: A NEW CHALLENGE

BA Shah*, A Wlodaver, M Blunt, A Foulks, A Makkar, M McCoy, M Escobedo, E Szyld. *University of Oklahoma Health Sciences Centre, Oklahoma City, OK*

10.1136/jim-2017-000697.192

Purpose of study As neonatal heart rate is a vital sign used to assess the need for and response to resuscitation, measuring it rapidly, accurately and affordably is important to clinicians around the world. Therefore neonatal resuscitation program (NRP) has recently revised the guidelines regarding heart rate monitoring by electrocardiogram (ECG). Feasibility of this implementation in the delivery room has not been systemically studied. Our objective of this project was to demonstrate the processes related to implementation of cardiac monitoring by ECG as per revised NRP guidelines in the context of a quality improvement (QI) project.

Methods used Focus groups were conducted with responsible parties at a tertiary regional perinatal centre and level IV neonatal intensive care unit. An interdisciplinary needs assessment

193

A QUALITY IMPROVEMENT PROJECT TO REDUCE BRONCHIOLITIS READMISSIONS

¹J Cleavenger, ¹LL Sisterhen*, ²D Goad, ²J Holt. ¹University of Arkansas for Medical Sciences, Little Rock, AR; ²Arkansas Childrens Hospital, Little Rock, AR

10.1136/jim-2017-000697.193

Purpose of study The aim of this project is to reduce bronchiolitis readmissions by 0.7%, from 3% to 2.3% by July 1, 2017 (PHIS data).

Methods used An interdisciplinary team identified key drivers to impact readmission rates: all patient education is delivered on a second grade level during hospital stay and caregivers

should be comfortable with suctioning their infant's nares. Interventions developed included:

- nursing education on teaching nasal suctioning and documenting teach-back
- an educational video was developed to teach caregivers about bronchiolitis diagnosis and management including instructions on nasal suctioning
- posters and reminders of teach-back were displayed on the unit and
- staff on the unit were asked to stock admission supplies with bulb syringe and saline for all respiratory admissions, to ensure that caregivers had access.

7 day readmission rates were collected monthly using data extracted from Solutions for Patient Safety (SPS) for DRG-138 Bronchiolitis and RSV Pneumonia. The data source changed from PHIS to SPS due to the delay by three months of PHIS data availability. The electronic medical record was reviewed for nursing documentation of bronchiolitis education, teach-back of nasal suctioning, and video viewed by caregiver.

Summary of results In June 2017, the median 7 day readmission rate was 1.65% (SPS). In addition, the median 7 day readmission rate over a 4 year period is 2.67% in quarter 1 of 2017 (PHIS). Nursing documentation of bronchiolitis teaching was 100% the entirety of the project. Teach-back documentation increased from 11% to 33% with a peak of 40%, and documentation of caregiver video education went from 0% to 9% with a peak of 18%.

Conclusions Linked improvement cycles resulted in modest improvements in discharge instructions, with a corresponding decrease in the median readmission rate from 3.0% to 2.67%. It is desirable that parents feel comfortable with care of an infant with bronchiolitis upon discharge. Implementing teach-back methods improves understanding and may reduce readmissions. Lessons learned included that key driver diagrams are useful tools to guide plans for interventions, and annotating run charts helps to communicate the current project status.

194 TEEN DRIVING EDUCATION IN A PAEDIATRIC EMERGENCY DEPARTMENT

¹G Spears*, ²B Schoen, ²L Maloney, ²J Smelcer, ²T Thompson, ²E Remington, ¹M Nichols, ¹W King, ¹K Monroe. ¹University of Alabama, Birmingham, AL; ²Childrens of Alabama, Birmingham, AL

10.1136/jim-2017-000697.194

Purpose of study In the US, the leading cause of death for adolescents is motor vehicle crashes. The aim of this project is to determine efficacy of education within a paediatric emergency department (ED) and assess current driving habits and knowledge of state law of teenagers and parents.

Methods used This IRB-approved pre-post intervention study of English-speaking, non-critically ill teenagers 13–19 years old and their parents was conducted in an urban paediatric emergency department. Pre-surveys assessed current driving habits and knowledge. Intervention was a 'Safe Driving Toolkit' followed by post-surveys to measure education outcomes. Pre and post survey data were then analysed and compared using Epistat

Summary of results 40 parents, 2 grandparents, and 44 teenagers were enrolled. Of the 19 participants who responded

that they knew the specifics of the GDL Law, only 1 was correct on all three counts. The most common item missed was the curfew with n=4 believing it to be 8 p.m., n=14 believing it to be 9 p.m., n=23 believing it to be 10 p.m., and n=7 believing it to be 11 p.m. Sixty-nine percent of respondents correctly answered that there was to be no cell phone use while driving for teenagers under the GDL law. Sixty-three percent of participants had never heard of the law, and of that sixty-three percent, 37% had been enrolled in a driver's education course. Chi square analysis revealed no significant difference between parents and teenagers having taken a drivers' education course ($z=1.16$, $p=0.11$), and there was no significant difference in parents and teens who reported learning new information from this study (97.2% of surveyed reported learning new information).

Conclusions The majority of participants were not aware of GDL Law, which has been in place since 2002. Over 97% of those surveyed were given new information in intervention. There is a need for further public education of the law and safe driving habits. 61% of respondents believe curfew is earlier than the current law's curfew, which support strengthening the current law. Night-driving restrictions starting at 10 p.m. or earlier have been shown to have greater reductions in motor vehicle crashes involving teenagers.

195 IMPROVING THE INPATIENT DISCHARGE PROCESS FOR SPANISH-SPEAKING PATIENTS: A QUALITY IMPROVEMENT INITIATIVE

S Williams*, AM Wolf, M Adams, B Bawa, J Freeman, ME Gutierrez, SE Mayberry, T Moore, S Stagno. University of Alabama at Birmingham, Birmingham, AL

10.1136/jim-2017-000697.195

Purpose of study As the Spanish-speaking population in the US grows, efforts to provide adequate translation of medical information must also increase. Patients and their families, regardless of which languages they speak, should always receive informative and understandable instructions, especially after an inpatient admission. In order to improve access to health care information for Spanish-speaking patients, our objective is to identify current barriers in our institution that prevent patients from receiving discharge instructions in Spanish.

Methods used This effort will be the first PDSA cycle of several which will seek to ensure that all Spanish-speaking families at our institution are provided bilingual discharge instructions. We retrospectively collected data over a four-month period on all inpatients whose families identified Spanish as their preferred language. We examined this data to identify (1) how many patients received written instructions in Spanish and (2) how many patients' charts had documentation of a Spanish interpreter being present during the discharge process. We then worked with Language Services and Nursing Informatics in focus groups to identify potential barriers in the discharge process.

Summary of results Of 171 patient visits in which families identified Spanish as their primary language, written Spanish discharge instructions were provided in 35.7%. Only 17.5% had documentation of a Spanish interpreter being present. There was no clear standardisation of the discharge process to ensure that patients with Spanish as their preferred language received comprehensive and intelligible instructions in Spanish.

Conclusions Spanish-speaking patients and their families are not currently being provided with adequate discharge instructions. Our second PDSA cycle will involve working with Language Services to develop standardised Spanish discharge instructions for the ten most common discharge diagnoses from our General Inpatient Paediatric Service. We will also develop a comprehensive program to increase physician and nursing awareness of the need for appropriate language interpretation for non-English-speaking patients. Data collection will begin again after implementation of the new discharge instructions.

196 KNOWLEDGE SUSTAINMENT AMONG PROVIDERS AFTER REGIONAL CME: AN QUALITY IMPROVEMENT INITIATIVE

C Lail, E Tomlin*, C Dunn, M Elrod, D Adams, C Rogers, SM Marchegiani. *Naval Medical Centre Portsmouth, Suffolk, VA*

10.1136/jim-2017-000697.196

Purpose of study Knowledge sustainment is a challenge for active duty, contract, and General Schedule (GS) providers caring for patients in military treatment facilities (MTFs) who have variable access to paediatric continuing medical education (CME). Re-organising some MTFs into enhanced multi-service markets provided uniform clinical and business operations, however quality patient care also depends on provider knowledge sustainment. To meet this need and CME access as a quality improvement (QI) project for the Tidewater eMSM, we created a regional one-day paediatric symposium for MTF providers. We assessed knowledge of attendees in paediatric sub-specialty areas and measured the impact of our event on knowledge improvement and retention.

Methods used Participants were assessed prior to the symposium with paper versions and at one and two months after with provided electronic assessments. The infectious disease quiz had 7 items, while the quiz for adolescent medicine had five. All corresponded with lecture objectives. Due to absent provider names on initial assessments, differences in individual scores could not be calculated and samples were assumed independent.

Summary of results Average scores are shown in the table. One way analysis of variance yielded significant differences for each assessment between the three time points. Post hoc comparisons with Tukey's paired test found significant differences between the pre and first post tests for both assessments (ID: $p < 0.01$, Adol $p = 0.03$), but sustained improvement from pre-

test to second post-test for the adolescent medicine assessment only (ID $p = 0.12$, Adol: $p < 0.01$). Of post-test respondents, over 45% reported <10 hours of paediatric CME annually at their MTF.

Conclusions Provision of regional CME provides one method to improve medical knowledge sustainment for providers of military beneficiaries.

Haematology and oncology

Joint plenary poster session and reception

4:30 PM

Thursday, February 22, 2018

197 AN UNUSUAL COURSE OF A RECENTLY DIAGNOSED SYSTEMIC LUPUS ERYTHEMATOSUS (SLE) THROMBOTIC MICROANGIOPATHY

*S Ahmed, PP Kyaw, L Ngo, JP Garrido, T Vo. *TTUHSC, Amarillo, TX*

10.1136/jim-2017-000697.197

Case report A 28 yo Hispanic female diagnosed of SLE, IV lupus nephritis 2 weeks back from admission, on prednisone, mycophenolate, and hydroxychloroquine presented with severe anaemia, fluid overload and respiratory distress requiring intubation. Physical exam significant for BL basilar rales and pedal oedema. Lab: Hgb 7.8, BUN/Cr 58/2.7, platelets 135 k, LDH 294, haptoglobin 13, UA: 3+protein;2+hematuria, peripheral smear showed schistocytes. Patient developed anuric renal failure and fall of Hgb and platelet count shortly after admission. Emergency plasmapheresis and hemodialysis was initiated due to concern for TTP. Further workup was consistent with lupus flare with high anti-DS DNA(284) and low complement level (C3 29.6, C4 14.2) prompting initiation of high dose IV steroid and mycophenolate. Following a course of prolonged plasmapheresis and immunosuppressive therapy, cell counts and inflammatory markers improved. Ultimately ADAMTS13 level returned slightly low at 52%. Presence of lupus flare and normal ADAMTS13 activity excluded diagnosis of TTP and therefore was more suggestive of SLE associated thrombotic microangiopathy.

Discussion Microangiopathic hemolytic anaemia with thrombocytopenia immediately raises concern for TTP. Other etiologies include severe sepsis, DIC, Shiga Toxin associated HUS, ITP, SLE, malignancy, HELLP syndrome or adverse drug reaction. Our patient did not have bloody diarrhoea, mental status was difficult to assess, Beta HCG, HIV, DIC panel, HIT and Coombs tests were negative. TMA is a rare but known hematologic manifestation of SLE. Patients with SLE associated TMA often have significant proteinuria, severe renal insufficiency with mildly low ADAMTS13 activity; all as seen in our patient. TTP in contrast is characterised by milder proteinuria, less severe renal failure and very low ADAMTS13 activity. These two conditions can be difficult to distinguish. Case reports suggest survival benefit to early treatment with plasmapheresis despite normal ADAMTS13 activity. Early recognition and initiation of plasmapheresis along with high dose immunosuppressive is crucial to reduce morbidity and mortality in SLE associated TMA.

Abstract 196 Table 1 Average scores

Infectious disease lecture				
	Pre-test	Post-test 1	Post-test 2	F-statistic (p value)
n	38	14	13	5.9 (0.004)
Mean(SD)	4.1 (1.5)	5.7 (1.5)	4.5 (1.5)	
MD/Nurse	16/2	12/3	9/2	
Adolescent medicine lecture				
	Pre-test	Post-test 1	Post-test 2	F-statistic (p value)
n	30	11	10	10.5 (<0.001)
Mean(SD)	2.9 (1.0)	3.8 (0.6)	4.3 (0.7)	
MD/Nurse	16/3	9/2	7/1	

198

AN UNUSUAL CASE OF NONBACTERIAL THROMBOTIC ENDOCARDITIS SECONDARY TO METASTATIC UROTHELIAL CARCINOMA

N Amilineni*, S Bhogal, P Sankhyan, C Cook. *East Tennessee State University, Johnson City, TN*

10.1136/jim-2017-000697.198

Case report Nonbacterial thrombotic endocarditis (NBTE) is a constellation of noninfectious valvular lesions, most commonly on the aortic and mitral valves. It is most often seen in the setting of systemic lupus erythematosus or late stage malignancy, with the highest prevalence among those with adenocarcinoma of the colon, lung, ovary, prostate and biliary tract.

A 60 year old male with a past medical history of bilateral pulmonary emboli diagnosed four months earlier and subsequent diagnosis of urothelial carcinoma with bilateral renal masses, presented to the hospital 3 days after underdoing renal biopsy, with complaints of progressively worsening exertional dyspnea since his biopsy.

On physical exam he was tachycardic at rest with heart rate in the 130 s and electrocardiogram evidence of new atrial flutter with rapid ventricular response. Transthoracic echocardiogram showed evidence of masses on valves (tricuspid and aortic), with a confirmatory transesophageal echocardiogram (TEE) consistent with two separate 1.5 cm echodense masses on his tricuspid and aortic valves. Initial and multiple repeat blood cultures showed no evidence of pathogen growth. Retroperitoneal lymph node biopsy results at that time were positive for metastatic urothelial carcinoma. Based on TEE findings with negative blood cultures, in the setting of advanced urothelial carcinoma, the diagnosis of NBTE is considered most likely. During hospitalisation, his clinical status deteriorated rapidly with significant hypotension and pulmonary oedema resulting in acute respiratory failure. The patient expired due to hypoxemic respiratory failure.

This case illustrates an interesting presentation of a malignancy associated NBTE, with pulmonary emboli and multiple endocardial lesions without evidence of pathogens. The increased concentration of circulating cytokines seen in malignancy damages endothelium, ultimately leading to platelet activation and deposition of inflammatory molecules. These sterile platelet thrombi often affect previously undamaged valves, and up to half of NBTE cases will present solely with embolic phenomena. Patients with NBTE may appear otherwise asymptomatic without the classical symptoms of cardiac murmurs or fevers seen in infective endocarditis.

199

TYROSINE KINASE INHIBITOR ASSOCIATED DILATED CARDIOMYOPATHY IN CHRONIC MYELOID LEUKAEMIA

N Amilineni*, S Bhogal, P Sankhyan, C Cook. *East Tennessee State University, Johnson City, TN*

10.1136/jim-2017-000697.199

Case report Prior to the introduction of tyrosine kinase inhibitors (TKIs) as a means of therapy for chronic myeloid leukaemia (CML), outcomes were poor and the prognosis grave. While these drugs have drastically improved outcomes, they come with significant adverse effects.

A 53 year old man with a past medical history of Philadelphia chromosome-positive CML, diagnosed 14 years ago and previously managed with imatinib, presented to the hospital

with acutely worsening dyspnea and peripheral oedema. 3 months earlier, he had suffered an acute blast crisis and was switched from imatinib to second generation dasatinib.

On physical exam he was noticeably short of breath with minimal exertion. Previous echocardiograms from the time of his initial CML diagnosis showed normal atrial and ventricular size and function, with an ejection fraction (EF) ranging 50%–60% and grade I diastolic dysfunction. Recently he was found to have an EF 25%–30%, with significant bi-atrial and left ventricular dilation, after which he had undergone cardiac catheterization with no evidence of coronary artery disease (CAD). This was further decreased on presentation with an EF <15% with significant grade III diastolic dysfunction. As he had no prior history of cardiovascular disease and current cardiac workup did not show any evidence of CAD or ischemia, it was determined that his cardiomyopathy was not ischaemic but instead secondary to tyrosine kinase inhibitor toxicity.

He failed to improve after initial management with aggressive intravenous diuretics and his hospital course was complicated by thrombocytopenia and anaemia requiring transfusion, after which dasatinib was discontinued. Despite maximal medical management to optimise cardiac function, his condition continued to deteriorate and he eventually entered hospice care.

Cardiotoxicity, characterised as dilated cardiomyopathy, is a rare but potentially devastating adverse effect from TKI's used to treat CML. Up to 2%–4% of those taking TKI's, specifically second generation dasatinib, will develop complications of cardiomyopathy with diastolic dysfunction. While the hematologic complications of TKIs have been well studied, this patient's case illustrates some of the rarer cardiotoxic effects that may be irreversible and potentially fatal.

200

BREAST CANCER WITH METASTASIS TO GASTROINTESTINAL TRACT

MR Arevalo*, SK Prieto, S Ball, C Jones. *Texas Tech University Health Sciences Centre, Lubbock, TX*

10.1136/jim-2017-000697.200

Case report Breast cancer is the most common cancer in women. Though recent advancements have improved early diagnosis and therapy, many patients ultimately develop metastases. The most common metastases are to lymph nodes, bones, lungs, liver, and brain. Metastasis in the gastrointestinal tract has been reported as low as 1%. Despite this low overall incidence, breast cancer is the second most common cancer metastasizing to the gastrointestinal tract. Even so, the metastatic involvement of the gastrointestinal tract is not well known nor well described in medical literature.

Here we review the case of a 69-year-old African American female, whose case highlights gastrointestinal metastasis. Initially the patient presented with severe neck and back pain. X-rays were consistent with degenerative changes only. Shortly afterwards she developed postprandial diarrhoea and reportedly lost 80 pounds in a three month period. Computed tomography (CT) scan of the abdomen and pelvis showed extensive bony abnormalities suggestive of metastatic disease and magnetic resonance imaging (MRI) revealed extensive marrow infiltration suggestive of metastatic disease. Bone marrow biopsy was positive for metastatic carcinoma most

consistent with breast primary (positive CK-7, GATA-3 and ER, HER2 equivocal). Anastrozole was started and the patient initially responded well to aromatase inhibitor therapy. However, the patient developed recurrent profound anaemia prompting endoscopic evaluation. Biopsies of the stomach body, ascending colon and rectum were compatible with metastatic breast cancer. Within one month, the patient developed gastrointestinal bleeding and elevated levels of CA-15-3, indicating progression of her gastrointestinal metastasis, prompting the decision to begin chemotherapy with paclitaxel.

Gastrointestinal metastasis of breast cancer poses a significant diagnostic challenge due to the nonspecific nature of symptoms. This case highlights the necessity of consideration of anaemia and gastrointestinal symptoms as potential diagnostic indicators in patients with breast cancer. Despite its rarity, additional research outlining a standard of care for patients with gastrointestinal metastasis of breast cancer is needed to improve clinical outcomes for this group of patients.

201 A RARE CASE OF OPTIC NEURITIS IN EARLY STAGE CLL

KC Arthur*, S Elkins, C Bigelow. *University of Mississippi Medical Centre, Jackson, MS*

10.1136/jim-2017-000697.201

Case report Chronic Lymphocytic Leukaemia is the most common leukaemia in the Western world. CLL is considered a disease of the elderly with the average age of 72 years at diagnosis. CNS involvement of CLL is rare, usually occurring late in the disease course. Optic involvement is even less common, and when reported, is associated with hematologic relapse. There are few cases in the literature of optic neuritis in early CLL.

We present a 40-year-old Caucasian male with no medical history who was referred to the neuro-ophthalmologist for optic disc oedema and progressive blurry vision of several months' duration. Extensive work up included negative ANA, CRP, ESR, ACE, HIV, RPR, Bartonella, Lyme, Zoster, ANA, and HSV. MRI brain did not show an abnormality. CSF studies were normal, and cytology was negative for malignancy. CBC revealed a WBC of 19.7 with lymphocytic predominance. Peripheral flow was consistent with CLL, and FISH revealed 13q14 deletion, portending a favourable prognosis; otherwise negative for high-risk markers. Optic involvement of CLL is definitively diagnosed by optic nerve sheath biopsy showing leukemic infiltrates. However, this procedure is not without significant risks. Given the extensive negative work-up, optic neuritis secondary to CLL was a diagnosis of exclusion.

He was then referred to our Haematology clinic where he was staged as a Rai 0 Binet A, and observation was recommended. He started 60 mg of prednisone daily by the neuro-ophthalmologist. However, after no response to steroids and rapidly progressive neuritis, the decision was made to initiate systemic treatment for CLL with fludarabine and rituximab. Optical Coherence Tomography (OCT) was used to measure Nerve Fibre Layer (NFL) loss. After 3 cycles of chemotherapy, OCT showed cessation of progression and stabilisation of

disease. He completed 4 cycles of fludarabine/rituximab with no significant side effects.

Case reports of optic neuritis in early stage CLL are limited for review. Radiation therapy and intrathecal methotrexate have traditionally been used to treat leukemic infiltration of the optic nerve, but more recently, chemotherapy alone has produced good results in the return of visual acuity. We present a rare case of optic neuritis in early stage CLL in a young patient with good risk cytogenetics.

202 DIFFUSE LARGE B-CELL LYMPHOMA INVOLVING LUNG PARENCHYMA

C Ashangari*, A Qasim, R Bharadwaj, P Tumula, JP Garrido. *Texas Tech University HSC Amarillo, Amarillo, TX*

10.1136/jim-2017-000697.202

Background Diffuse large B-cell lymphoma (DLBCL) is the most common form of NHL, accounting for 30 percent of newly diagnosed cases. Usual presentation of DLBC involves nodal or extranodal mass with systemic features. Lung Parenchymal involvement is an uncommon presentation of DLBC.

Case report 56 y old, male with PMH of RA and DM type 2, presented with on and off fever and night sweats since 1 month. He also had unintentional weight loss of >20 lbs for 6 months. His home medications consisted of metformin and abatacept. He was a smoker 1.5 PPD since 40 years. He was exposed to copper sulphate at work. On examination there was generalised tenderness on palpation of abdomen and spleen palpated 8 cm below the costal margin. Lab work showed pancytopenia with WBC-1.0, Hb-9.9, Platelets-49, ANC-0.1, AST-98, ALT-62, ALP-233. Hepatitis panel, quantiferon test and HIV were negative. CT thorax showed bilateral upper lobe and bibasilar infiltrates, multiple small nodules all over the lung. A 1.3 cm large nodule was found in the posterior aspect of right lung base. Patient was initially was started on empiric antibiotic treatment with cefepime, vancomycin, metronidazole and micafungin. Bone marrow biopsy and aspiration was done which was consistent with DLBCL. CT guided needle biopsy of lung nodule showed large atypical cells positive for LCA, and CD20, BCL6 positive in >30% of cells, Ki67 shows semi-quantitative proliferative index of 98%. FISH negative for c-MYC. These findings consistent with diffuse B-cell lymphoma involving bone marrow, lung and liver parenchyma activated B-cell type, negative for BCL2 and negative for EBER. Patient was started on rituximab followed by gemcitabine and oxaliplatin.

Discussion Patients with RA are at increased risk of malignant lymphomas, most pronounced for diffuse large B cell lymphomas (DLBCLs), characterised by relatively frequent extranodal presentation, the most common are in stomach, CNS, bone, testis and liver. Simultaneous detection of multiple extranodal involvement at presentation is quite uncommon, with the majority of these cases characterised by gastric or intestinal disease localization. Our case is unique as we report a patient with an unusual presentation of DLBCL with significant visceral involvement including lung.

203

CONCURRENT JAK2 POSITIVE MYELOPROLIFERATIVE DISORDER AND CHRONIC MYELOGENOUS LEUKAEMIA: A NOVEL ENTITY?

¹G Bader*, ¹D Hansen, ²B Dreiling. ¹University of Mississippi Medical Centre, Ridgeland, MS; ²GV Montgomery VA Medical Centre, Jackson, MS

10.1136/jim-2017-000697.203

Introduction JAK2 mutation and BCR-ABL translocation have been considered mutually exclusive. However, few cases of coexisting JAK2 positive myeloproliferative disorders (MPD) and chronic myelogenous leukaemia (CML) have been reported. We describe a case of concurrent JAK2 positive myelofibrosis and CML that we have recently diagnosed.

Case Report A 75 y old male presented with weight loss, night sweats and left upper quadrant abdominal pain. Physical exam was pertinent for hepatosplenomegaly. His WBC count was $23.2 \times 10^3/\text{mcl}$ with neutrophil count of 21.3 and no blasts. Haemoglobin was 14.3 g/dl and platelet count $741 \times 10^3/\text{mcl}$. Neutrophilia and thrombocytosis started in 2013 and 2014 respectively. Quantitative RT-PCR was positive for both b2a2 and b3a2 transcripts at 2.1% and 1.2% respectively. Imatinib was started for CML. Eight weeks later, WBC count was $16.8 \times 10^3/\text{mcl}$ and Platelet count $649 \times 10^3/\text{mcl}$. RT-PCR was negative for BCR-ABL. The complete molecular response (CMR) without hematologic response triggered further testing. JAK2 V617F mutation was positive on peripheral blood. Bone marrow was hypercellular with proliferation of atypical megakaryocytes and widespread grade 2 reticulin fibrosis. No BCR-ABL translocation was detected by FISH. DIPSS PLUS score revealed intermediate 1 risk disease. Hydroxyurea was added while waiting mutational profile. Neutrophilia and thrombocytosis resolved four weeks later.

Discussion The patient had both CML and myelofibrosis as featured above. Persistence of neutrophilia and thrombocytosis despite CMR was due to myelofibrosis.

In most reported cases of concurrent MPD and CML, JAK2 mutation preceded BCR-ABL translocation. JAK2 mutated clone appeared to expand with BCR-ABL clone suppression. We suggest JAK2 mutation testing in CML with atypical course where major or complete molecular response are achieved without hematologic response. Alternatively, we suggest checking BCR-ABL translocation in cases of JAK2 positive MPD with CML-like features.

Conclusion Diagnostic criteria of MPD probably need to be revised to account for the possibility of co-occurrence of JAK2 mutation and BCR-ABL translocation which might be a novel clinical entity.

204

NASOPHARYNGEAL SQUAMOUS CELL CARCINOMA PRESENTING AS CHRONIC SINUSITIS

B Bajric*, S Maharaj, J Verdecia, C Palacio. University of Florida, Jacksonville, FL

10.1136/jim-2017-000697.204

Case report A 54 year old African-American male with no past medical history presented with sinusitis of three months. He complained of right-sided nasal congestion, maxillary sinus tenderness, and a diffuse headache. The headache was worse when lying down. He intermittently experienced ear fullness over the same time period. He had completed three separate courses of amoxicillin, amoxicillin-clavulanate, and doxycycline with no improvement. Fluticasone and decongestants gave

minimal symptomatic relief. Physical exam revealed swollen nasal turbinates, worse on the right. A right-sided middle ear effusion was indicated by a bulging tympanic membrane. Palpation over the right maxillary sinus elicited subjective tenderness. No neck mass, lymphadenopathy, or neurological deficits were appreciated. Given the chronicity of symptoms and failed antibiotic treatment, a Computed Tomography scan of the sinuses was obtained. This showed a 5 centimetre wide by 5 centimetre long mass arising from the posterior wall of the right nasopharynx, extending into the masticator space, the right cavernous and maxillary sinus, and the pterygopalatine and right middle fossa. Magnetic Resonance Imaging confirmed the mass and the skull base invasion. A biopsy of the tumour showed poorly differentiated squamous cell carcinoma. The plan at the time of discharge was primary radiotherapy.

Discussion Nasopharyngeal carcinoma is uncommon in the United States. Instead, it is endemic in Southeast Asia and North Africa. The symptoms are often difficult to recognise and can lead to a delay in diagnosis. Risk factors include tobacco and alcohol use, exposure to Epstein-Barr Virus, and early exposure to carcinogens. Tumours often remain asymptomatic for prolonged periods. The most common presentation for this cancer includes headache, double vision, facial numbness, and a neck mass. Due to varying presentations, there is often a delay or misdiagnosis for nasopharyngeal carcinoma. The tumours tend to metastasize quickly and typically invade the skull base. This case demonstrates that when a patient presents with symptoms of chronic sinusitis not responding to treatment, it is imperative to consider malignancy as a possibility.

205

HEPATOBLASTOMA IN A 9-YEAR-OLD CHILD: CONSIDERATIONS IN AN OLDER PAEDIATRIC PATIENT

L Powell*, L Raney, L Caleon, M Benak, MC Velez. Louisiana State University Health Sciences Centre, New Orleans, LA

10.1136/jim-2017-000697.205

Case report Hepatoblastoma (HB) is the most common primary hepatic malignancy of early childhood, occurring mostly in those less than 5 years of age. From 1997–2012, only 13 cases were reported worldwide in children older than 5 years. While surgery remains the mainstay of therapy, less than 50% of tumours are resectable at diagnosis. Neo-adjuvant chemotherapy has led to many non-metastatic, initially unresectable tumours becoming resectable. While liver transplant offers a last resort to unresectable cases, only 25 transplants were performed from 1993–2007. The 5 year event-free survival is approximately 90% for completely resected tumours; it falls to <70% when resection is unfeasible. A 9-year-old male presented with right upper quadrant abdominal pain, anorexia, and emesis for several days. Physical exam revealed a palpable liver 10 cm below the right costal margin. A complete blood count and complete metabolic profile showed mildly elevated liver transaminases, and coagulation studies assessing liver function were normal. Computed tomography and magnetic resonance imaging demonstrated a large $9.8 \times 10 \times 16.2$ cm hepatic mass in the right lobe of the liver, additional hepatic involvement in all segments, and inferior vena cava and portal vein intraluminal tumour extension, without distant metastasis. His alpha-fetoprotein (AFP), a tumour marker for HB, was over 195,000 ng/ml. An ultrasound-guided biopsy confirmed

the diagnosis of HB, mixed fetal and embryonal epithelial type. The tumour was initially unresectable, and he received three cycles of neo-adjuvant chemotherapy with vincristine, doxorubicin, cisplatin, and 5-fluorouracil following the Children's Oncology Group protocol for non-metastatic HB, aiming to decrease tumour size. Unfortunately there was no significant change. He was then transferred to another institution where he successfully received a liver transplant in order to achieve remission. This case exemplifies a more extensive, aggressive disease associated with the atypical age of presentation that appears resistant to standard chemotherapy. This suggests a potentially different tumour biology and clinical behaviour in older patients with HB.

206 CHORIOCARCINOMA SYNDROME

S Bhama*, JC Henegan. *University of Mississippi Medical Centre, Flowood, MS*

10.1136/jim-2017-000697.206

Case report Choriocarcinoma syndrome is a rare condition in which patients with metastatic nonseminomatous germ cell tumours (NSGCT) with multiple large metastases and a high serum HCG concentration (>50,000 IU/L) often present with haemorrhage from metastatic sites.

To promote early recognition of this rare, life threatening condition, we report a case of a patient with choriocarcinoma syndrome who presented with symptomatic anaemia, melena and hemoptysis.

A 29 year old Caucasian male presented with left testicular swelling in June 2016. A left orchiectomy showed a localised mixed germ cell tumour (75% teratoma, 25% embryonal carcinoma). He was lost to follow up.

In August 2017 he was admitted to an ICU for melena and hemoptysis with symptomatic anaemia (Hgb 2 g/dL). Scans showed multiple tumours in his chest and abdomen. He was transfused blood and asked to follow-up with medical oncology. Two weeks later, he had hemoptysis and a haemoglobin of 3.5 g/dL. Scans showed extensive liver and lung metastases, necrotic lymphadenopathy and 7 haemorrhagic brain metastases consistent with relapsed, Stage IIIC (pT1b cN3 cM1b S3), poor risk NSGCT. Esophagogastroduodenoscopy and bronchoscopy did not show any areas of active bleeding or mass. Beta human chorionic gonadotropin was 319,520 IU/L. He was treated with cisplatin 20 mg/m² and etoposide 100 mg/m² on days 1–3 with bleomycin and two more days of cisplatin and etoposide added later in to cycle 1 per the GET-UG 13 protocol.

His course was complicated by a spontaneous pneumothorax requiring a chest tube placed prior to cycle 2. He tolerated the first five days of cycle 2 well but unfortunately died suddenly in his sleep and the cause of death is unknown.

Logothetis initially described choriocarcinoma syndrome in 1984, with haemorrhage at sites of metastasis containing high volume choriocarcinoma elements with significantly elevated B-HCG levels. The bleeding is hypothesised to be the result of extensive vascular invasion by syncytiotrophoblasts and

cytotrophoblasts leading to early haematogenous dissemination. Haemorrhagic complications can occur immediately after the start of chemotherapy and/or in patients with rapid disease progression. Prompt recognition and early multimodal intervention including chemotherapy and surgical control of bleeding may prevent fatalities from this rare complication of NSGCT.

207 ARGATROBAN DOSING IN HEPARIN-INDUCED THROMBOCYTOPENIA IN THE SETTING OF AN ELEVATED APTT DUE TO ANTIPHOSPHOLIPID SYNDROME

Z Bhatti*, D Manta. *SUNY Upstate Medical University, Massapequa, NY*

10.1136/jim-2017-000697.207

Case report Heparin-induced thrombocytopenia (HIT) is a serious, life-threatening complication which occurs in 1%–3% of patients receiving heparin. Treatment is based upon clinical suspicion, stopping heparin therapy and initiation of anticoagulation with a rapidly acting alternative non-heparin anticoagulant, such as argatroban. Argatroban is a synthetic direct thrombin inhibitor that reversibly binds to the thrombin active site. The recommendation for initial dosing of argatroban in HIT is 2 µg/kg/min, adjusted to achieve aPTTs >60 s. Our case highlights the unusual circumstance of dosing argatroban in the setting of a falsely elevated aPTT due to antiphospholipid syndrome.

A 36-year-old male with a recent history of iliac artery stenting presented to the hospital with complaints of shortness of breath. A computerised tomography angiography (CTA) of the chest showed a large acute saddle embolus. He was started on intravenous heparin. On day three, his platelet count fell over 50% of his baseline count. HIT was suspected and he was switched to argatroban. Argatroban was monitored using aPTT with a goal aPTT of >60 s. Anticardiolipin antibodies were elevated and mixing studies suggested a factor inhibitor. Due to these findings, there was concern for antiphospholipid syndrome. Approximately four days later the patient abruptly went into cardiac arrest and was pronounced dead.

In antiphospholipid syndrome (APS), the autoantibodies, anticardiolipin antibodies, anti-B2-glycoprotein antibodies and lupus anticoagulant bind to the phospholipid part of the PTT reagent and the patient's specimen does not clot. The coagulation tests are therefore falsely prolonged. In our patient with undiagnosed APS, aPTT was falsely elevated and therefore was an inaccurate measurement of anticoagulation. This case demonstrates the limitations of current treatment recommendations of argatroban in patients with antiphospholipid syndrome. One case report recommended the use of a fixed-dose argatroban regimen without laboratory monitoring as a management strategy.

Limited and inconsistent data exist about dosing patterns, efficacy, and safety of argatroban therapy in patients with HIT and an elevated baseline aPTT due to APS.

208 **AN OBSTRUCTING DUODENAL MASS WITH PERITONEAL INVOLVEMENT: NOT ALWAYS ADENOCARCINOMA!**

C Busack*, M Zaarour, R Munker. *Tulane University School of Medicine, New Orleans, LA*

10.1136/jim-2017-000697.208

Case report Primary small bowel neoplasms are uncommon tumours with overall poor prognosis. The predominant histological type is adenocarcinoma followed by carcinoid, lymphoma, and sarcoma. These tumours have often similar clinical, radiologic, and morphologic features making the distinction difficult without tissue examination. Peritoneal involvement can be a manifestation of adenocarcinoma known as peritoneal carcinomatosis. More uncommon is the peritoneal involvement by lymphoma, known as lymphomatosis. Herein, we report a rare case of small bowel obstruction secondary to a duodenal mass along with peritoneal involvement. Surprisingly, the diagnosis was not adenocarcinoma but lymphoma.

In August 2017, a 41 year-old Hispanic woman with no significant medical history presented with worsening nausea, abdominal pain, and 60 pound weight loss over a period of 7 months. The patient was initially admitted to the ICU with severe metabolic derangements. A contrast CT of the abdomen and pelvis showed a mass-like thickening at the level of the 2nd portion of the duodenum resulting in severe luminal narrowing. Also, peritoneal 'carcinomatosis' was noted. Serum CEA and Ca 19-9 levels were normal. Upper endoscopy visualised a friable obstructing mass in the 2nd portion of the duodenum that was biopsied. Pathology showed a CD20 +diffuse large B-cell lymphoma with germinal centre immunophenotype. Treatment was initiated with Rituximab, Cyclophosphamide, Doxorubicin, Vincristine and Prednisone (R-CHOP). The patient tolerated cycle 1 well, and she was discharged home with outpatient oncology follow-up.

Although, the gastrointestinal (GI) tract is the leading extranodal site of non-Hodgkin lymphoma (NHL), primary GI lymphomas remain uncommon. Most cases occur in the stomach, followed by the colon and small intestine. Primary duodenal lymphoma account for less than 2% of all cases of GI NHL. Peritoneal involvement is an extremely rare presentation of lymphoma and is often highly indistinguishable from the more common carcinomatosis seen with adenocarcinoma. Therefore, a high index of suspicion is warranted to prevent delay in diagnosis.

209 **ISCHAEMIC STROKE IN A CHILD WITH DOWN SYNDROME AND ACUTE LYMPHOBLASTIC LEUKAEMIA**

L Caleon*, L Powell, M Benak, VA Cruz Flores, R Gardner. *LSUHSC, New Orleans, LA*

10.1136/jim-2017-000697.209

Case report Patients with Down Syndrome (DS) and leukaemia (ALL) have a higher incidence of treatment-related toxicity. ER, a sixteen-year-old girl with known DS, presented after 2 weeks of low grade fever, malaise, myalgias, and pallor. Her white blood count was 8970, haemoglobin was 4.6 gm%, and platelet count was 9,000, with 67% lymphoblasts. A diagnosis of pre-B ALL was made. ER was started on the COG high-risk arm for DS patients (vincristine, dexamethasone, intrathecal (IT) cytarabine (ARA) on day 1; pegylated-asparaginase (PEG-ASP) on day 5; day 8, IT methotrexate and leucovorin).

Two days later, ER acutely developed right lower extremity weakness. Computed tomography (CT) of the brain had no focal findings, but magnetic resonance imaging (MRI) of the brain revealed acute infarcts in bilateral fronto-parietal areas with extensive vasculitis involving internal carotids, anterior, proximal, and posterior cerebral arteries without haemorrhage. The patient then developed dysarthria, dysphagia and right-sided paresis. Repeat brain CT showed right frontal lobe oedema. After intensive rehabilitation and high dose steroids, ER progressively improved, regaining speech and use of her extremities. She completed induction therapy without further use of PEG-ASP, and consolidation with systemic ARA and cytoxan.

Patients with DS have an incidence of ALL 10- to 20-fold greater than the general population in conjunction with worse outcomes. Treatment of ALL in DS can be problematic since there is increased sensitivity to chemotherapy. It is uncertain to what extent methotrexate played a role in causation of ER's neurologic complications. Although PEG-ASP has also been proposed as a possible cause, there was no hypofibrinogenemia, d-dimer elevation, or other indicators of thrombotic risk. Our patient had no evidence of pre-existing neurologic problems, but it is entirely possible that preexisting conditions such as MoyaMoya, seen in DS, could have predisposed her to vasculitis once treatment started. The case highlights difficulties of treating those with DS and ALL, and underscores a need for thorough neurologic exam, and poses the question of need for brain imaging before starting therapy.

210 **GRAFT VERSUS HOST DISEASE AFTER SYNGENEIC TRANSPLANT – A CASE REPORT AND REVIEW OF THE LITERATURE**

C Capra*, N Patel, J King, R Brodell, C Milner. *UMMC, Jackson, MS*

10.1136/jim-2017-000697.210

Introduction Syngeneic bone marrow transplant for multiple myeloma is known to decrease treatment-related mortality while increasing progression free survival (PFS) and overall survival (OS) as compared to autologous transplant.^{1-3, 7} Previous studies cite the incidence of syngeneic graft-versus-host disease (sGVHD) from 0% to 20%, yet prophylaxis is not routinely used in syngeneic transplants.¹⁻⁵ Herein, we report sGVHD affecting the gut and skin.

Case presentation A 63 year-old Caucasian male with an IgG Kappa Multiple Myeloma previously treated with Lenalidomide with Bortezomib and Dexamethasone and subsequent Carfilzomib with Dexamethasone treated to a complete response was referred for transplant evaluation. He had a monozygotic identical twin brother and the decision was made to proceed with syngeneic bone marrow transplant. Human leukocyte antigen (HLA)-typing confirmed a 10/10 match between the patient and donor. The patient underwent a myeloablative regimen with Melphalan followed by a transplant of 3.35×10^6 CD34 cells/kg taken directly from the donor's unstimulated marrow. GVHD prophylaxis was deemed unnecessary. By day +10, the patient was having more than two litres of stool per day and developed a diffuse, erythematous macular rash without bullous formation. Biopsies of the duodenum, colon, and skin were all consistent with acute GVHD. With appropriate immunosuppression, the rash and

diarrhoea resolved by day +19 and patient was suitable for discharge from the hospital on day +23.

Discussion Death attributed to GVHD after HLA-matched sibling and matched unrelated donor stem cell transplants are as high as 9% and 10%, respectively.⁸ We routinely administer GVHD prophylaxis for every allogeneic transplant, yet we do not when performing a syngeneic transplant. There are identifiable risk factors for sGVHD⁴ as well as a previously utilised model to predict GVHD and individualise prophylaxis.^{9–11} We propose the need for further investigation into which patients would benefit from GVHD prophylaxis to preserve the benefit of syngeneic transplant.

211 TESTICULAR SEMINOMA METASTASIS PRESENTING AS CARDIAC ARRHYTHMIA

JA Carlson*, I Serrano, K Seegobin, P Reddy. *University of Florida, Jacksonville, FL*

10.1136/jim-2017-000697.211

Case report Testicular cancer is the most common cancer among males aged 15–35 years, with seminomas accounting for approximately 45% of all primary testicular tumours. Diagnosis is established with radical orchiectomy, which also serves as the initial treatment. In patients with seminoma limited to the testes (Stage I), orchiectomy provides a cure rate of greater than 85% if conducted with active surveillance after surgery.

A 59-year-old male smoker with history of right testicular pure seminoma, status post-radical orchiectomy one year prior, presented to the hospital with complaints of mild chest pain, palpitations, and shortness of breath. Patient stated he had experienced these symptoms intermittently for 5 months, and was unable to correlate clear precipitant factors and noted to have spontaneous resolution of these symptoms.

On exam, he was found to be tachycardic in the 130 s and an electrocardiogram showed atrial fibrillation with rapid ventricular rate. Chest x-ray revealed a new rounded, soft tissue density superior to the left hilum. Follow-up with CT-chest confirmed the 6.2 cm mass located in the left anterior/middle mediastinum which was concerning for malignancy. CT-guided biopsy was performed and cytology was sent, affirming the diagnosis of recurrent metastatic seminoma.

Oncology diagnosed this as stage III mediastinal seminoma, and the patient was started on chemotherapy with VIP (Vinblastine, Ifosfamide and Cisplatin) for 4 cycles. On day 5 of VIP treatment, he spontaneously converted to normal sinus rhythm. He was discharged on day 7 of chemotherapy with close outpatient follow-up with hematology-oncology.

This case illustrates the uncommon presentation of metastatic seminoma after treatment with radical orchiectomy. This procedure can help avoid adjuvant medications and therapies due to its excellent cure rate, as long as there is close follow-up. After careful chart review of this patient, oncology had ordered a CT abdomen/pelvis and repeat tumour markers 4 months after surgery to ensure full resolution, however, this patient did not follow up. As a result, 1 year later he was found to have stage III metastatic seminoma. This case emphasises that even though seminoma prognosis is excellent, active surveillance is required to monitor for long-term remission.

212 CASCADES IN COAGULATION AND COMPLIMENT

D Chander*, P Rigby. *LSU-HSC, Metairie, LA*

10.1136/jim-2017-000697.212

Introduction Both the complement system and coagulation pathway proceed in a stepwise fashion via the activation of various soluble factors. The interaction between the complement and coagulation cascades is increasingly being seen as an important mediator in the pathophysiology of diffuse intravascular coagulopathy.

Case report A 56 year old male with a history of colon cancer presented to the Emergency Department with 2 months of abdominal pain and progressive loss of appetite. Prothrombin time (PT) was 14.6 and partial thromboplastin time (PTT) was 56.8. His white blood cell count (WBC) was elevated at 27 thousand. The day after hospital admission a CT scan of the abdomen was ordered which demonstrated a contained perforation and intraabdominal abscess. He was begun on antibiotics and his intraabdominal abscess was drained. His WBC and coagulation parameters normalised over the following hospital days.

Discussion Ratnoff and colleagues first proposed a ‘waterfall’ sequence of coagulation in 1964. The elucidation of the complement system dates even further to the end of the 19th century. Traditionally these pathways have been thought of as separate, however increasing research demonstrates key interactions between the two pathways play a role in the pathogenesis of dysfunctional coagulation. In particular, the anaphylatoxin C5a has been shown to be an important mediator of coagulation via increased tissue factor expression. We aim to describe the characteristics of Cascades and update the well-described waterfall sequence to reflect our modern understanding of the coagulation and complement pathways.

213 WHEN THINGS AREN'T AS THEY SEEM: A CASE OF A RARE LUNG CANCER

E Dauchy*, W Baumgartner, M Modica, LS Engel. *LSU Health Sciences Centre, New Orleans, LA*

10.1136/jim-2017-000697.213

Case report A 67 year old woman with chronic neck pain secondary to known cervical stenosis presented with acutely worsened neck pain and headache. She reported painful swallowing and palpitations, but denied chest pain or shortness of breath. While in the Emergency Department, she was noted to be in atrial fibrillation and was admitted for further workup. Physical examination was notable for a frail woman who appeared older than her stated age, an irregularly irregular pulse, and unremarkable musculoskeletal and neurologic findings. With the exception of an alkaline phosphatase of 163 U/L, labs were normal. EKG demonstrated an irregularly irregular rhythm consistent with atrial fibrillation and a chest x-ray revealed mediastinal lymphadenopathy that was new when compared to previous imaging. This was explored further with a CT of the chest and demonstrated a 2×3 cm mass in the right upper lobe of the lung with innumerable pulmonary nodules as well as a 7.5×6.2 cm mass in the right mediastinum with multiple enlarged lymph nodes. A CT of

the abdomen and pelvis revealed likely metastatic disease in the liver, adrenals, kidneys and ovaries. MRI of the brain noted a mottled appearance of the cervical spine concerning for metastasis to the bone. Interventional Radiology performed a biopsy of a kidney lesion and pathological findings suggested a neuroendocrine growth pattern with high mitotic growth rate, high proliferation index (50%–60%) and positive neuroendocrine markers (CD56 and synaptophysin); consistent with metastatic large cell neuroendocrine carcinoma.

Discussion Large cell neuroendocrine carcinoma is a rare pulmonary malignancy, representing approximately 3% of all lung cancers. Diagnosis relies on careful attention to neuroendocrine features on light microscopy and immunohistochemical staining. LCNEC, like small cell lung cancer, carries a very poor prognosis. Unfortunately, there is little data available to define a standard treatment due to lack of clinical trials.

214 CATCH-22: ANTICOAGULATION IN A PATIENT WITH ITP AND VENOUS THROMBOEMBOLISM

E Dauchy*, J Decuir, B Mathew, LS Engel. *LSU Health Sciences Centre, New Orleans, LA*

10.1136/jim-2017-000697.214

Case report A 62 year old man with ITP presented with three weeks of right leg swelling and pain. He denied chest pain or any recent travel. He reported chronic dyspnea on exertion, without change from baseline. He also denied any bruising or bleeding. Physical examination demonstrated a swollen right lower extremity with pitting oedema from the ankle to knee. Admission labs demonstrated a normal white blood cell count and haemoglobin and hematocrit. Platelet count was 36 000. Venous ultrasonography of the right LE was notable for deep venous thrombosis involving the popliteal, femoral and deep calf veins. CT angiogram with PE protocol demonstrated multiple bilateral pulmonary emboli. Haematology was consulted to assist with the discussion of anticoagulation in this patient. Using recommendations from the 4th Intercontinental Cooperative ITP Study Group that follow VTE treatment recommendations in cancer patients with high bleeding risk, the patient was started on prednisone 1 mg/kg and half of the therapeutic dose of low molecular weight heparin. Within three days, the patient's platelet count increased to 1 01 000 and he suffered no bleeding events. He was eventually tapered off of steroids and was increased to full therapeutic dosing of low molecular weight heparin with no adverse events.

Discussion ITP is a rare hematologic diagnosis that affects both young and elderly patients. Some studies have suggested that the risk of VTE in ITP patient is just as high as in those with cancer, which poses treatment issues as anticoagulation is routinely contraindicated when the platelet count is less than 50 000. Furthermore, ITP patients with thrombocytopenia have been excluded from pivotal studies investigating newer anticoagulation agents and clinical data is lacking. Although more clinical investigation is needed, this case demonstrates that patients with ITP can be safely treated with anticoagulation.

215 AN UNCOMMONLY CONSIDERED CAUSE OF HEMOLYTIC ANAEMIA

E Dauchy*, A Muhs, LS Engel, C Hebert. *LSU Health Sciences Centre, New Orleans, LA*

10.1136/jim-2017-000697.215

Case report A 46 year old woman with previously treated Grave's Disease presented to the Emergency Department with gingival bleeding when brushing her teeth, dark coloured urine, easy bruising and an unintentional 10 pound weight loss in the last six months. She also admitted to drinking 48 ounces of beer three times weekly. Admission labs were notable for a haemoglobin and hematocrit of 6.2 g/dL and 17.6 g/dL, respectively, platelet count of 163, MCV of 104 and RDW of 44%. The differential was notable for schistocytes, tear drop cells, and many hypersegmented neutrophils. Her AST was 84, ALT was 24, alkaline phosphatase was 60 and total bilirubin was 1.4. Faecal occult blood was negative. Her serum iron was 56, TIBC was 287, ferritin was 18, vitamin B12 level was 55 and folate level was 12.2 with a normal thyroid profile. Reticulocyte percent was 1.3. Haptoglobin was <30 and LDH was markedly elevated, consistent with hemolytic anaemia; direct antiglobulin test was negative. She was started on parenteral vitamin B12. EGD was notable for diffuse atrophic gastric mucosa. Intrinsic factor antibody level was equivocal, but gastrin level was elevated at 366 and parietal cell antibody level was elevated at 57.9 making this consistent with a pernicious anaemia. Biopsy samples taken during EGD demonstrated intestinal metaplasia and the presence of ECL cell hyperplasia in segments negative for gastrin staining, suggestive of autoimmune gastritis.

Discussion Pernicious anaemia is a common cause of vitamin B12 deficiency and is often associated with autoimmune gastritis. Although the precise cause of autoimmune gastritis is unknown, individuals with this condition are more likely to have a pre-existing autoimmune condition. What makes our case interesting is that our patient presented with a hemolytic anaemia picture, which was thought to be due to ineffective erythropoiesis. Our case highlights the importance of considering vitamin B12 deficiency in a patient presenting with severe anaemia and hemolysis.

216 LONG TERM NEED OF IV IRON IN PATIENTS WITH HEREDITARY HAEMORRHAGIC TELANGIECTASIA

E Ellent*, P Rigby. *LSUHSC, New Orleans, LA*

10.1136/jim-2017-000697.216

Case report A 45-year-old woman with HHT presented to the ER with recurrent epistaxis, which had been worsening over the past 6 years despite outpatient standard of care treatment. Over this course in time, this patient had 16 ER visits with 10 admissions secondary to epistaxis directly or IDA induced chest pain. The patient's baseline haemoglobin (Hg) level is approximately 10 grams/DL, however, an average of her Hg upon presentation to the ER is 7.48 grams/DL. Ferritin ranged from 1.3 ng/mL to 75.6 ng/mL, with an average of 16.24 ng/

mL. During this time, she has also had 15 units of pRBC transfused. Oral iron failed and the patient was started on intravenous (IV) iron infusions. Initially, the patient received IV iron infusions sporadically, which did not decrease her visits to ED for HHT complications. More recently, the patient was placed on scheduled bimonthly IV iron infusions. Since establishing care, this patient has received 5100 mg of IV ferumoxytol and 7300 mg of Iron Dextran in 40 months' time.

Discussion There are 6 main forms of IV iron and pharmacokinetics vary based on preparation. Regardless of the preparation, IV iron has significant potential adverse effects such as anaphylactic reactions and infections. Clinicians must weigh the risks versus benefit, over time. Patients with HHT do have increased morbidity, however, mortality is generally not affected. In 2015, women had an average life expectancy of 81.2 years. If this patient lives to her anticipated life expectancy and continues IV iron infusions then she will need 869 more IV infusions which would total 443,088 mg of elemental iron. If her care is transitioned to monthly infusion then she will require 435 IV infusions and 221,544 mg of elemental iron.

Conclusion Patients with HHT may be destined to a lifetime of IV iron infusions. This can have an adverse quality of life as well as economic implications.

217

ISOLATED MYELOSARCOMA TREATED AS AML, WITH PROGRESSION TO MDS/MPN

¹A Fuentes, ²G LaBier, ¹B Boulmay. ¹LSU Health Sciences Centre, Metairie, LA; ²LSU, New Orleans, LA

10.1136/jim-2017-000697.217

Case report A 67-year-old woman with stage IIB lung adenocarcinoma in January 2014, in remission after cisplatin, etoposide, and radiation, presented January 2017 with lower extremity skin lesions, dismissed as insect bites. One month later, she developed persistent fevers, splenomegaly, and Coomb's-negative hemolytic anaemia requiring recurrent transfusions. Labs included WBC 3,300/uL (3% metamyelocytes, no blasts), Hgb 6.6 gm/dL, Plt 456,000/uL, CRP 3.4 mg/dL. Rheumatologic and infectious workup was non-revealing. Bone marrow biopsy showed mild non-specific megakaryocytic and

myeloid dysplasia, normal FISH/cytogenetics, negative for mutations in JAK2, CALR, BCR-ABL.

In June, the lower extremity skin lesions enlarged; biopsy revealed myelosarcoma with monocytic differentiation. Labs showed WBC 3,600/uL (3% blasts), Hgb 6.5 gm/dL, Plt 555,000/uL. Repeat bone marrow biopsy showed 16% blasts, 2.5% monocytes, background dysplasia, 7q31 deletion in 19% of the nuclei by FISH. She was refractory to induction chemotherapy with idarubicin and cytarabine. After re-induction with mitoxantrone, etoposide, and cytarabine, her blood counts did not fully recover, and bone marrow biopsy showed blasts <5%, worsened dysplasia including abnormal monocytes (37.5% of differential), marked reticulin fibrosis, and more prominent 7q31 deletion in 61% of the nuclei. Cytopenias worsened with WBC 500/uL with monocytic predominance (28%), Hgb 5.3 gm/dL, Plt 29,000/uL. She was started on azacitidine, to which she is thus far clinically responding with improving blood counts.

Myelosarcoma is rare and most often an extramedullary manifestation of acute myeloid leukaemia (AML). Isolated myelosarcoma without bone marrow involvement is exceedingly rare, but in the scarce literature it is thought to seed the bone marrow, which is why treatment is the same as that for AML – with induction chemotherapy. This case highlights how myelosarcoma can start as a primary extramedullary lesion, with bone marrow dysplasia occurring thereafter. The evolution of her bone marrow findings resembles that of myelodysplastic/myeloproliferative neoplasm, and she is currently responding to treatment with azacitidine. Her prior history indicates that the myelodysplasia is likely secondary to etoposide.

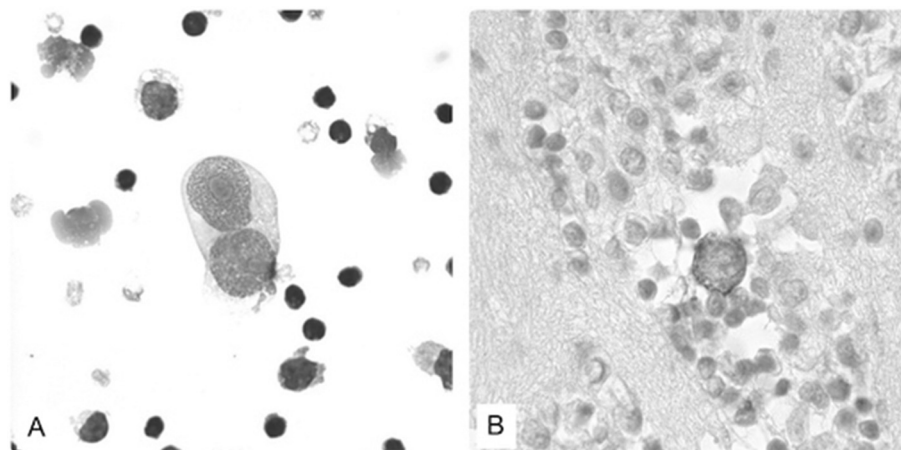
218

SYMPTOMATIC PERICARDIAL EFFUSION AND CYTOLOGIC DIAGNOSIS WITH HODGKIN'S DISEASE

Z Ghandour*. Tulane Medical Centre, Metairie, LA

10.1136/jim-2017-000697.218

Purpose of study Hodgkin lymphoma (HL) accounts for approximately 10% of all lymphomas and is diagnosed predominantly during two age peaks, 20 and 65 years. Approximately 65% of HL patients present with mediastinal involvement. Pericardial effusion is seen in only approximately



Abstract 218 Figure 1 The pericardial fluid cytologic examination showed large binucleated cells (A) in a background of a mixed inflammatory cell infiltrate. Immunohistochemical stains showed CD30 positivity (B)

5% of HL patients and is rarely symptomatic. Histologically, HL has Reed-Sternberg (RS) cells in a background of inflammatory cells. Cytologic examination of pericardial fluid usually only show inflammatory cells.

Methods used A 72-year-old female patient, recently diagnosed with mixed cellularity HL on an excisional axillary lymph node biopsy, presented to the emergency room with shortness of breath and bilateral lower extremity oedema. Her echocardiogram revealed a decreased ejection fraction of 45% and a large pericardial effusion. Diagnostic pericardiocentesis was performed. The pericardial fluid cytologic examination showed large binucleated cells (figure A) in a background of a mixed inflammatory cell infiltrate. Immunohistochemical stains showed CD30 positivity (figure B) and CD45 negativity in the binucleated cells, consistent with RS cells.

Summary of results HL has four classical subtypes, nodular sclerosing being the most prevalent. HL has been genetically identified as a B-cell neoplasm with RS cell expression of CD30 and CD15 with lack of CD45 expression by immunostains. RS cells only compose approximately 1% of the cellular content of HL, so it is rarely seen in cytologic preparations. Selection of initial treatment for HL is usually based on presenting stage and prognostic factors, including extranodal involvement, such as pericardial involvement

Conclusions Symptomatic pericardial effusions are rare with HL patients. RS cells make up a small percentage of cells present in HL and may not always be present in cytologic preparations. Accurate diagnosis in this setting is needed, as the consequences may be dire if the patient is not treated properly

219

TESTICULAR MYELOID SARCOMA: A RARE MANIFESTATION OF ACUTE MYELOID LEUKAEMIA

D Hansen*, S Elkins, C Milner. *University of Mississippi Medical Centre, Jackson, MS*

10.1136/jim-2017-000697.219

Introduction Myeloid sarcoma of the testis is a rare entity and may occur *de novo* or concomitantly with bone marrow disease. Myeloid sarcoma (MS) is a neoplasm of myeloid blasts that involves an extramedullary anatomic site. MS can arise in lymph nodes, skin, gastrointestinal tract and central nervous system. The incidence of MS in adults is approximately 2% and it has been linked to a poor prognosis.

Here, we report a case of a patient who developed a late recurrence of acute myelogenous leukaemia (AML) in the form of testicular myeloid sarcoma twelve years after initial treatment.

Case report A 59-year-old white man was admitted for management of relapsed AML in the form of testicular MS. Patient was initially diagnosed with AML in June of 2005 with unknown diagnostic cytogenetics. He was treated with induction chemotherapy consisting of cytarabine plus idarubicin and three cycles of consolidation chemotherapy with high-dose cytarabine. He remained in remission until July of 2017 at which time, he began to experience weight loss, fatigue and left testicular swelling. Testicular ultrasound revealed orchitis for which he was treated with ciprofloxacin without improvement. He was then evaluated by urology and had a left orchietomy with pathology revealing MS. Bone marrow biopsy had no evidence of involvement by AML.

Examination of cerebrospinal fluid revealed no evidence of leukaemia. Patient has received induction chemotherapy with cytarabine plus daunorubicin with complication of febrile neutropenia. He is now in remission and awaiting allogeneic hematopoietic stem cell transplantation (alloHSCT).

Discussion Isolated extramedullary relapse in the form of testicular MS is rare with only a handful of cases described. Testicular MS remains a therapeutic challenge as no established treatment strategy exists due to lack of prospective trials. Treatment recommendations are based on retrospective studies with available options including surgical resection, systemic chemotherapy, local radiotherapy, alloHSCT or a combination of these methods. The role of alloHSCT has been highlighted in several studies, in which it has been shown that alloHSCT improves overall survival in patients with MS and may be the most beneficial element of MS therapy.

220

THALLESSEMIA COMPLICATED BY MOYAMOYA CURED WITH UNRELATED DONOR HEMATOPOIETIC STEM CELL TRANSPLANTATION

CL Harper*, A Baker, D Gunda, D Crawford. *University of Oklahoma School of Medicine, Oklahoma City, OK*

10.1136/jim-2017-000697.220

Case report Our patient was diagnosed in infancy with β -thalassaemia trait due to anaemia and paternal family history. Since his haemoglobin was lower than expected, a more thorough evaluation was performed revealing a triplicated α -globin gene from his mother. He remained asymptomatic until age 4 when he required a transfusion for an aplastic crisis associated with a Parvovirus B19 infection. He infrequently received transfusions until he presented with ataxia, headaches, and vomiting at 6 years of age. MRI revealed numerous acute and subacute strokes in watershed areas of the anterior and middle cerebral arteries. MRA demonstrated vascular abnormalities consistent with Moyamoya syndrome. He was subsequently treated with aspirin and chronic transfusion therapy. Several months later, he underwent two synangiosis revascularisation procedures to reduce the risk of further ischemia. Chronic PRBC transfusions, aspirin, and oral iron chelation were continued for 6 more years. The patient proceeded with hematopoietic stem cells transplant (HSCT) using a well-matched unrelated donor. Since graft failure and graft-versus-host disease (GVHD) are major complications of HSCT for thalassaemia, he was enrolled on a protocol investigating pre-treatment with hydroxyurea and post-transplant Abatacept to minimise the risk of these complications. His transplant course was complicated by prolonged neutropenic fever and respiratory distress with opportunistic pneumonia leading to a 17 day PICU stay. Another complication was stage II skin aGVHD. After discharge, he has full donor chimerism, is transfusion-independent, and doing well more than 4 months after transplant. Moyamoya is recognised as a complication of sickle cell anaemia including sickle/ β -thalassaemia. However, it has only been reported in 9 thalassaemia patients, the majority of which are thalassaemia intermedia patients, like ours. Another report has shown a high rate of silent infarcts in thalassaemia intermedia patients demonstrating that Moyamoya is not the only cerebrovascular manifestation of thalassaemia intermedia.

221

RACE-SPECIFIC GENETIC MUTATIONS IN PAEDIATRIC PATIENTS WITH B-ACUTE LYMPHOBLASTIC LEUKAEMIA

¹A Reddy*, ¹I Espinoza, ¹D Cole, ¹J Schallheim, ¹E Bhanat, ¹Y Zhou, ²J Zabaleta, ¹G Megason, ¹C Gomez. ¹University of Mississippi Medical Centre, Jackson, MS; ²LSUHSC, New Orleans, LA

10.1136/jim-2017-000697.221

Purpose of study The most common form of cancer in paediatric patients is B-acute lymphoblastic leukaemia (B-ALL) and comprises more than 30% of all childhood malignancies. The survival of patients was found to be significantly lower in African American (AA) children compared to European (EA) children in previous studies. This disparity is not related to socioeconomic variables, suggesting a molecular basis for the lower survival rates of AA. Here we present a study showing race-specific genetic aberrations (GA) that may play a role in health disparities in B-ALL in AA and EA children.

Methods used Twenty newly diagnosed paediatric patients were enrolled in our study (5 AA and 15 EA). Ages range between 1 and 18 years with a median age of 4 years. None of the patients had a relapse. Median percent of blasts was 94.8% (64.5%–99.9%). Frozen bone marrow aspirates were used to extract DNA and whole exome sequencing (WES) was performed, focusing on race and B-ALL specific germline mutations.

Summary of results Specific germ-line mutations were identified within the most widely accepted cancer-related genes related to B-ALL. Most GA (339) were shared between AA and EA, for example those present in the Anaplastic Lymphoma Receptor Tyrosine Kinase (*ALK*) gene. Some GA were specific for AA (58) such as Lipoma Preferred Partner Gene (*LPP*) and others specific for EA (52) such as, Leukaemia Inhibitory Factor Receptor (*LIFR*). The ingenuity pathway analysis revealed these genes clustered in race-specific canonical pathways. In AA, the pathways were related to telomerase signalling and cancer signalling. While in EA, it was related to stem cell pluripotency and hereditary cancer. Our findings suggest the value of WES as a tool for development of individual gene signatures and gene scores for AA and EA children afflicted by B-ALL.

Conclusions Aberrant biological networks revealed by our study, provide information on GA and signalling networks that may be involved in race-specific leukemogenesis. Our findings suggest that it may be possible to develop a WES gene signature in B-ALL to help define a race-specific prognosis. These findings may ultimately impact disease management and contribute to the elimination of disparate outcomes in B-ALL in AA children.

222

FROM METASTATIC MELANOMA TO COMPLETE RESPONSE IN SEVEN MONTHS: THE POWER OF COMBINED CHECKPOINT IMMUNOTHERAPY

SM Jeong*, N Sheehan. University of Mississippi Medical Centre, Jackson, MS

10.1136/jim-2017-000697.222

Introduction Treatment for advanced melanoma has improved considerably since the introduction of checkpoint immunotherapy. Recently, combination therapy with nivolumab and ipilimumab has demonstrated increased antitumor activity compared with ipilimumab alone and has become a first-line treatment for metastatic melanoma. Here we report a case of

a patient with advanced melanoma who achieved complete response to combined checkpoint immunotherapy.

Case report A 62-year-old Caucasian male with history of malignant peripheral nerve sheath tumour (MPNST) of the scalp presented for evaluation of a pathologic fracture of the right humerus. Two weeks prior, he was found to have a lung mass on computed tomography of the chest; biopsy revealed a high grade malignant epithelioid and spindle cell neoplasm that was diffusely S-100 positive. PET-CT revealed metastatic disease in the brain, lungs, heart, pancreas, abdominal mesentery, soft tissues, and throughout the osseous structures. Bone biopsy of his fracture site was consistent with metastatic melanoma. He underwent whole-brain radiation as well as radiation therapy to his right humerus.

It was felt that the features of the patient's disease were most characteristic of malignant melanoma. The biopsy was negative for BRAF V600 mutation. LDH was 456 U/L. In 12/2016, he was started on therapy with ipilimumab 3 mg/kg and nivolumab 1 mg/kg every 3 weeks.

After the fourth cycle, the patient experienced significant immune-mediated side effects, including hypothyroidism, colitis, dermatitis, and hepatitis, requiring hospitalisation. However after recovery, a repeat PET-CT in 7/2017 showed no residual, recurrent, or metastatic disease. MRI of the brain showed a small cavity in the right thalamus at the sight of treated metastasis with no new intracranial metastases. LDH returned to normal at 183 U/L. The patient remains in complete response.

Discussion The treatment and prognosis for advanced melanoma continues to improve as further immunotherapy combinations are explored. Clinicians should be aware of the significant improvement in progression-free and overall survival that combination immunotherapy offers compared to monotherapy alone, yet be cautious in monitoring for higher rates of grade 3 or 4 immune-related adverse events.

223

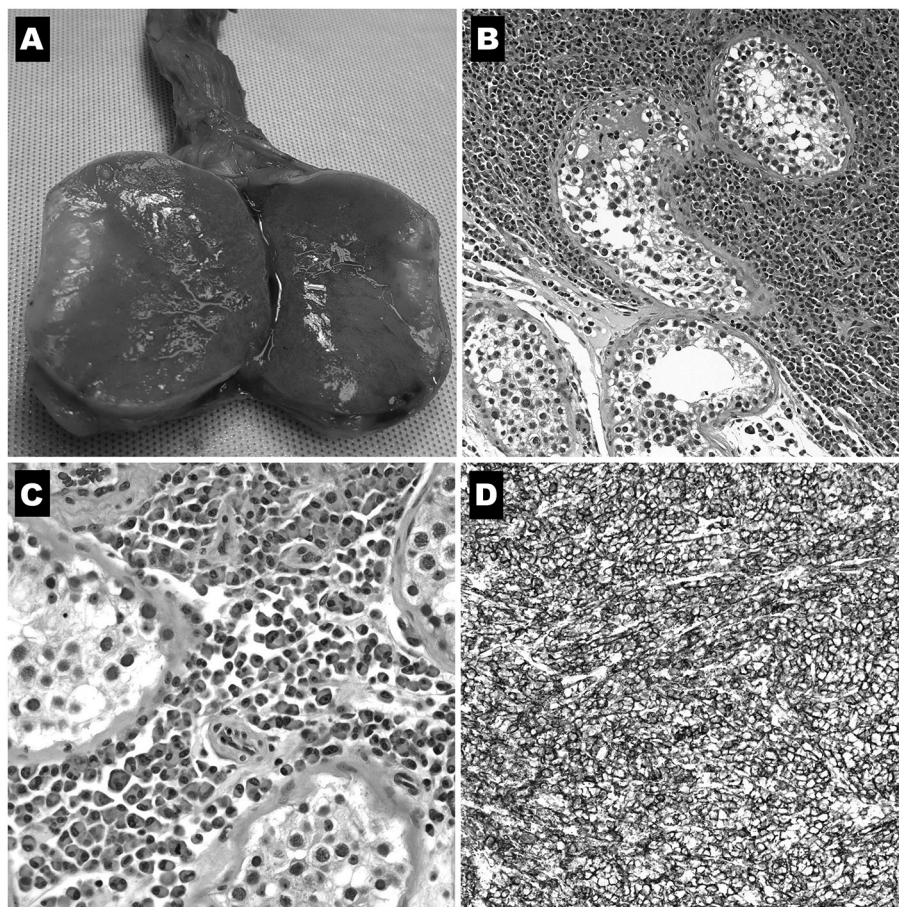
PLASMACYTOMA TESTIS – RARE EXTRAMEDULLARY LESION OF PLASMA CELL MYELOMA

¹ES Josan*, ¹M Zayko, ¹T Bhandari, ²R Villilla, ²T Tamarro. ¹East Tennessee State University, Johnson City, TN; ²Mountain Home VAMC, Johnson City, TN

10.1136/jim-2017-000697.223

Case report A 45 year old male with stage III Plasma Cell Myeloma (PCM) previously treated with Bortezomib, Thalidomide, Dexamethasone and maintenance Thalidomide and Zoledronate presented with back pain and left testicular swelling for 1 month. Imaging showed multiple skeletal lytic lesions but no abdominopelvic lesions or lymphadenopathy. AFP, β hCG and LDH were normal. A radical orchiectomy performed after ultrasound revealed a 3 cm pale yellow, firm, homogenous and partially lobulated tumour (figure 1A). Histopathology showed sparing of epididymis and spermatic cord (figure 1B); partial tubular effacement, diffuse proliferation of small/intermediate size plasma cells and occasional prominent bi/multinucleate cells (figure 1C). The atypical plasma cells were strongly positive for CD138, λ -light chain and negative for CD20 by immunohistochemistry (figure 1D). A neoplastic plasma cell process was confirmed by flow cytometry with 60% of abnormal cells expressing CD38, CD56 and sIg- λ .

Extramedullary lesions in PCM indicate poor prognosis with a survival rate of 1 month–2 years. Testicular lesions are seen in 0.1% cases, although the testis is a suspected



Abstract 223 Figure 1 (A) A radical orchietomy performed after ultrasound revealed a 3 cm pale yellow, firm, homogenous & partially lobulated tumour. (B) Histopathology showed sparing of epididymis & spermatic cord. (C) Partial tubular effacement, diffuse proliferation of small/intermediate size plasma cells & occasional prominent bi/multinucleate cells. (D) The atypical plasma cells were strongly positive for CD138, λ -light chain & negative for CD20 by immunohistochemistry

sanctuary site. Solitary lesions warrant orchietomy while diffuse disease requires chemotherapy. Palliative radiation is used in advanced disease. Plasmacytoma is an important differential diagnosis of testicular neoplasms, especially in patients with PCM. A thorough physical examination is crucial for early detection and treatment.

224

THYROID MALT LYMPHOMA: A RARE CANCER WITH A GOOD PROGNOSIS

R Khalaf*, S Singal, E Spradling, D Jaishankar. *ETSU, Johnson City, TN*

10.1136/jim-2017-000697.224

Case report Marginal Zone lymphoma (MZL) accounts for 10% of all Non Hodgkins lymphomas (NHL). MALT (Mucosa associated lymphoid tissue) Lymphoma is the commonest subtype of MZL. Over half of all MALT Lymphomas are seen in the gastrointestinal tract (80% in the gastric area). MALT Lymphomas can be seen less commonly in other organs such as skin, lung, ocular adnexa, and rarely in small bowel, salivary glands, thyroid, breast and bladder. Lymphomas account for 1%–5% all thyroid neoplasms. A seventy three year old female with multiple medical problems presented with progressive neck swelling of a few months duration. No fever, sweats or weight loss reported. No

dysphagia or dysphonia noted. Imaging studies revealed a thyroid nodule/mass. Patient underwent a thyroidectomy. Pathology revealed diffuse, dense atypical lympho-plasmacytic cells infiltrating around residual reactive thyroid follicles. Neoplastic cells were positive for CD20, CD79a, Pax-5, and BCL2. Extensive chronic lymphocytic thyroiditis with Hurthle cell change and adenomatous nodular hyperplasia was also noted. PET scan revealed no other involved sites. Postoperative radiation was delivered for positive margins. Thyroid lymphoma is associated with chronic inflammation, autoimmune diseases, Hashimoto's thyroiditis or chronic infections. It occurs in the seventh decade equally among both sexes. Immunophenotypically, MALT cells express Ig, B cell markers (CD19-CD20, CD22 and CD 79a) and are negative for CD5, CD10, CD23 and Cyclin D1. Cytogenetic abnormality t(11,18) are commonly reported. MALT lymphomas often present with early stage disease without B symptoms or bone marrow involvement. HCV, HIV, H.Pylori and Myeloma panel testing is recommended. MALT lymphomas can be treated with resection or radiation with curative intent. Early stage gastric MALT lymphomas often regress with H.Pylori treatment. Systemic treatment with rituximab based immuno chemotherapy regimens offer reasonable control in advanced stage disease. The ten year survival with Thyroid MALT lymphomas is 95%. There are very few cases of MALT lymphoma in the thyroid, which account for less than 0.1% of all thyroid neoplasms and we are reporting one such interesting case.

225 A RARE CASE OF UROS GENE NEGATIVE CONGENITAL ERYTHROPOETIC PORPHYRIA

S Kolagatla*, N Moka, S Bailey. *ARH-Markey Cancer Centre, Hazard, KY*

10.1136/jim-2017-000697.225

Case report Congenital Erythropoietic Porphyria (CEP) also known as Gunther disease is due to autosomal recessively inherited deficiency of uroporphyrinogen III synthase (UROS) an enzyme needed for heme synthesis that leads to accumulation of porphyrins in tissues along with hemolytic anaemia and cutaneous photosensitivity. CEP is always due to mutations in the UROS gene. Rarely due to other genes that affect UROS gene expression. In few cases UROS coding region and the intron-exon boundaries can be unrevealing suggesting additional sites of mutations.

48 year old Caucasian male with long standing history of blistering skin lesion on sun exposed areas presented to the clinic with worsening fatigue. His past medical history include multiple staphylococcal infections, hemolytic anaemia. One of his brothers had blistering lesions. Exam showed blistering of left arm and healed lesion on both arms and head otherwise no mucosal blistering appreciated. Quantitative porphobilinogen are consistently elevated in the plasma, urine and stool. UROS gene testing was performed which was unrevealing for any mutations. He developed Normocytic anaemia with low retic count and extreme neutrophilic leukocytosis. Bone marrow biopsy which demonstrated evidence of myelodysplastic/myeloproliferative neoplasm. Within a few months he had deceased with sepsis.

In CEP excess porphyrins in the urine turn red upon exposure to sunlight (Image 1). Mainstay of treatment is to avoid sunlight especially in patients with high levels of porphyrins, also include vitamin D replacement as this patients are usually deficient in Vitamin D because of sun avoidance, blood transfusions, iron chelation, skin and eye care. Case reports describing cure with allogenic stem cell transplant with suitable donor. CEP could potentially treated with gene therapy as over expression of UROS gene is possible in cultured hematopoietic stem cells but no studies no demonstrate the efficacy and feasibility have been reported. Our case is interesting because of UROS gene was unrevealing and development of myeloproliferative/myelodysplastic syndrome.

226 FAMILIAL POLYCYTHEMIA LIKELY DUE TO NOVEL HAEMOGLOBIN VARIANT- HAEMOGLOBIN HYDEN

S Kolagatla*, N Moka, S Bailey. *ARH-Markey Cancer Centre, Hazard, KY*

10.1136/jim-2017-000697.226

Purpose of study In order to identify the Haemoglobin variant resulting in familial polycythemia in a family from Hyden in Eastern Kentucky.

Methods used p50 analysis, Haemoglobin electrophoresis, Bi-directional sequence analysis to test for mutation in all coding regions and non-coding portions of the beta haemoglobin gene.

Summary of results In the course of work up of familial polycythemia that is negative for Jak-2 with reflex Exon 12 and CALR mutation. Oxygen dissociation p50 of 19 which is low indicating left shifted dissociation curve. Electrophoresis cascade

demonstrate Haemoglobin A 61.2%, Haemoglobin A2 3.0% and Variant 35.8% of Beta variant.

Bi-directional sequence analysis for Molecular alterations Gene: HBB, DNA change: Codon 39, heterozygous CAG >CCG Protien change: P.G1n39Pro. [glutamine (Q) to proline (P)].

HGVS: c.119A>C, p.Q40P, Classification: Likely deleterious variant. (GenBank accession number NM_000518.4).

Conclusions This is a previously unreported beta chain haemoglobin variant present. This particular haemoglobin variant is named as Haemoglobin Hyden based on the place where this is found in Hyden, Kentucky. There have been four variants reported at codon 40 of the beta globin gene, which is an external contact site between beta globin and alpha-2 globin. One variant, Hb vassa, is associated with mild hemolytic anaemia. The three other variants (Hb Alabama, Hb Tianshui and Hb San Bruno) are not associated with clinical or haematological abnormalities.

In our opinion p.Q40P is likely a cause of erythrocytosis. In order to further establish the causality it may be beneficial to test first degree relative to in this family in order to determine whether the p.Q40P alteration tracks with disease and is not present in unaffected individuals. Haemoglobin threshold for phlebotomy to lower the risk of thrombosis and cardiovascular events is yet to be defined.

227 GRAFT-VERSUS-HOST DISEASE PRESENTING WITH PANCYTOPENIA AFTER ORTHOTOPIC LIVER TRANSPLANT

E Long*. *University of Mississippi Medical Centre, Jackson, MS*

10.1136/jim-2017-000697.227

Case report Graft-Versus-Host Disease (GVHD) is a devastating complication of bone marrow transplantation. GVHD is caused by the activation of donor T-cells by the antigen presenting cells of the recipient. This case report describes GVHD presenting as pancytopenia after solid organ transplant, highlighting a rare presentation of this disease.

A 68-year-old female presented with fever to 101, shortness of breath, fatigue, and diffuse rash; she had undergone an orthotopic liver transplant one month prior. She was found to leukopenic, with a white blood cell count of 1.2. Her TMP-SMX and mycophenolate mofetil were held, and she was given a dose of filgrastim. CMV and EBV titers were negative. On follow-up a worsening leukopenia was noted, with WBC now 0.2.

She was admitted to the hospital. Physical exam was notable for the absence of rash, and the absence of erosions of mucous membranes. Labs revealed marked pancytopenia, with WBC 0.1, Hb 22.8, and platelet count 129.

Bone marrow biopsy and aspirate revealed markedly hypocellular marrow with ten percent cellularity and marked hypoplasia of granulocytes. There was no evidence of acute leukaemia. Peripheral blood showed marked leukopenia and pancytopenia. Likely causes were considered to be medication or infection.

Tacrolimus was stopped in favour of cyclosporine. Filgrastim was begun. Counts began to slowly recover, with WBC 2.0, Hb 9.4, and platelets 105. Patient was discharged home.

Patient represented several days later with altered mental status and seizure. CSF studies were positive for HHV-6. WBC was 0.1. Concern was raised for GVHD as a cause of her pancytopenia. Post-transplant analysis of the peripheral blood showed chimerism, with 27% donor cells and 73% patient cells, consistent with a diagnosis of Graft-versus-Host disease. Unfortunately, the patient died rapidly thereafter as a result of her disease.

Acute GVHD is rarely seen after solid organ transplant, with the number of reported cases in the hundreds. Furthermore, GVHD usually affects the skin, liver, and digestive tract. GVHD presenting as pancytopenia is quite rare. We present this case to raise awareness of the GVHD as a cause of profound pancytopenia in the post-transplant setting. We hope this will allow the diagnosis to be made more expeditiously in future presentations.

228 IMPELLA INDUCED HEMOLYTIC ANAEMIA

S Maharaj*, K Seegobin, B Bajric, F Rana. *University of Florida College of Medicine, Jacksonville, FL*

10.1136/jim-2017-000697.228

Case report A 72 year old male with a history of non-ischaemic cardiomyopathy with reduced ejection fraction (20%) was admitted with electrical storm from ventricular tachycardia (VT). He was intubated, sedated and managed with antiarrhythmic therapy (amiodarone, lidocaine) but with recurrent VT required support with placement of an Impella. He did not have any hemoglobinopathy or valvular disease and there was no infection. After Impella placement, the haemoglobin (Hb) was 10.0 g/dL. The following day, Hb declined to 8.8 g/dL with no source of bleeding. Acute anaemia continued to worsen with a decline to 7.0 g/dL by day 5. Leukocyte and platelet counts were normal. Hemolytic indices revealed elevated LDH of 671 IU/L, haptoglobin below the detectable limit of assay and increased unconjugated bilirubin. Review of the peripheral blood smear confirmed the presence of helmet cells. The patient was transfused and the Impella device was removed shortly after with no further drop in haemoglobin.

Anaemia in patients with acute heart failure is important as it leads to worsening disease. The Impella microaxial flow device is placed across the aortic valve and generates blood flow out of the left ventricle into the aorta by revolving at high speeds. Impella is increasingly used in cardiogenic shock, VT ablation and high-risk coronary intervention. A recent case report suggested improper placement leads to hemolysis, but in this case even with proper placement there was significant hemolysis. We postulate that turbulent flow through leads to excessive shear stress on the erythrocytes. The interaction with foreign surfaces also lends to mechanical trauma. Large scale data is lacking but one retrospective study found that Impella therapy was associated with a significant decrease in haemoglobin after 24 hours, and two thirds of patients underwent transfusion. Patients on Impella therapy should be monitored closely for hemolysis which can be significant. These patients are often in cardiogenic shock and we suggest that the need for transfusion should be anticipated. Serial monitoring of hematologic and hemolytic indices is therefore advised to allow early detect and management to prevent haemodynamic compromise.

229 USE OF GENE EXPRESSION PROFILING IN THE EVALUATION OF PATIENTS WITH UNCOMMON CANCER PRESENTATION: A RARE CASE OF METASTATIC BREAST CANCER TO THE UTERINE CERVIX

¹J Manalac*, ²A Garcia. ¹LSUHSC, Lafayette, LA; ²LSUHSC, New Orleans, LA

10.1136/jim-2017-000697.229

Purpose of study To describe an unusual presentation of metastatic breast cancer (BC) in a 63 year old woman and the clinical application of tumour gene expression profiling in the diagnostic evaluation.

Methods used Case report and literature review.

Summary of results We present a 63 year old female with a new cervical mass. In 2002 she was diagnosed with stage II oestrogen receptor positive BC. She was treated with surgery, chemotherapy and endocrine therapy. She was in remission until 2007 when she developed isolated left hip metastasis treated with radiation therapy, and a second recurrence to the right supraclavicular lymph node in 2015 with receptor positive disease. She was subsequently placed on fulvestrant. Two years later, routine staging studies revealed interval development of a cervical mass with uterine, vaginal and bladder wall extension clinically and radiologically highly suspicious for locally advanced cervical cancer. Biopsy of the cervical mass revealed a poorly differentiated carcinoma. Immunohistochemistry stains were positive for CK7, GATA-3, oestrogen receptor, P16 (weak) and negative for Pax-8, CK5/6, p63, CK20 and CD10, consistent with metastatic BC. Gene expression profiling using a validated 92-gene real-time PCR assay was used to distinguish a new primary tumour of the cervix from an unusual presentation of isolated metastasis to the cervix. This gene assay revealed a 96% probability of BC and ruled out carcinoma of the cervix with 95% confidence.

Conclusions Metastases to the cervix occur very rarely and represent a diagnostic challenge for clinicians and pathologists. It has been reported that up to 42% of metastatic lesions to the cervix are mistaken for primary tumours. Information on the tumour type is crucial in guiding treatment decisions. Clinicians should be aware of these new platforms which, in conjunction with clinical and pathologic evaluation, can aid in the identification of the primary site in selected patients who present with carcinoma of unknown primary or unusual clinical presentations. These assays can help the treating physician to estimate patient prognosis, select the most appropriate therapy, and determine whether tissue-dependent biomarker testing is indicated.

230 PATIENT-DERIVED TRIPLE NEGATIVE BREAST CANCER XENOGRAPTS TO DISCOVER NOVEL KINASE PATHWAYS

M Matossian*, M Burow, B Collins-Burow. *Tulane University School of Medicine, New Orleans, LA*

10.1136/jim-2017-000697.230

Purpose of study Triple negative breast cancers (TNBCs) have an aggressive clinical presentation due to high rates of metastasis, recurrence and chemoresistance; Louisiana, specifically New Orleans, has among the highest incidences of TNBC in the country. Targeted therapy remains elusive in TNBC and discovery of novel therapeutic targets are necessary. Current models in target discovery research cannot accurately recapitulate the complex architecture and heterogeneity of TNBC.

Immortalised cell lines have been selected in a 2D environment and may have lost important features of original tumours. Our primary objective was to dissect and evaluate the various components that drive complex interactions within TNBC tumours using patient-derived xenografts from New Orleans hospitals.

Methods used We analyse relevant transcript (qRT-PCR) and protein (flow cytometry, immunohistochemistry) expression patterns that are unique to each PDX model. Using qRT-PCR and 3D culture, we examine effects of the pan-deacetylase inhibitor, LBH589 on mammospheres, *in vivo* tumorigenesis and collagen expression. We also generated cell lines and mammospheres (TU-BcX-2K1, TU-BcX-2O0, TU-BcX-49S, TU-BcX-4IC) from each PDX model. Finally, we utilise novel techniques such as tissue decellularization to examine extracellular matrix components and evaluate the necessity of the scaffold in TNBC tumorigenesis.

Summary of results Our laboratory has established four TNBC PDX models representing various patient ethnicities, response to chemotherapy, and TNBC molecular subtypes and metastatic behaviour. We demonstrate these models can be used in therapeutic discovery research and recapitulate results observed in preliminary studies using immortalized TNBC cell lines. Finally, we dissect these models using various techniques to examine aspects of this complex tumour that can be targeted by developing therapeutics, including specific cell populations, the extracellular matrix, and cancer stem-like cells.

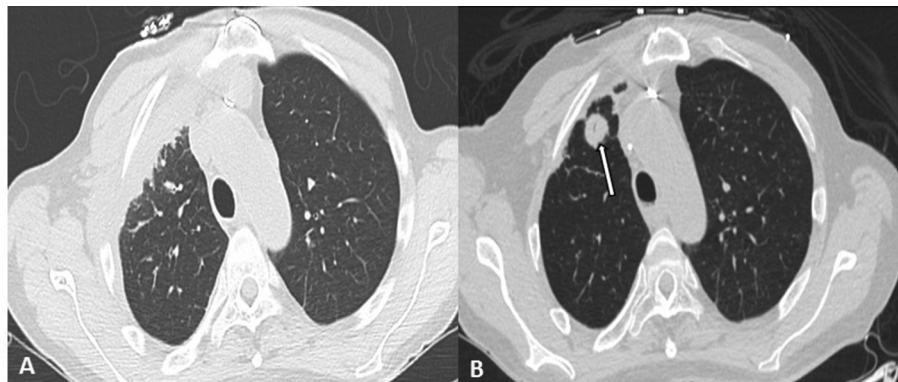
Conclusions Our aim is to leverage novel patient-derived models from under-studied patients with a range of clinical presentations to guide the selection of therapeutically targetable pathways in specific molecular subtypes of TNBC.

231 RECURRENT DIFFUSE LARGE B CELL LYMPHOMA PRESENTING AS A SOLITARY SPICULATED LUNG NODULE

RM Medrano*, A Fuller, E Islam. *TTUHSC, Lubbock, TX*

10.1136/jim-2017-000697.231

Case report Diffuse large B-cell lymphoma (DLBCL) is the most common type of extra-nodal lymphoma. The majority of extra-nodal cases occur in the gastrointestinal tract, with pulmonary involvement is very rare. Here we present a case of pulmonary lymphoma presenting as a solitary spiculated lung nodule.



Abstract 231 Figure 1 Chest CT at the time of DLBCL diagnosis is shown in figure A. On admission, chest CT revealed a 1.9 cm rounded, spiculated nodule in the right upper lobe (RUL) as seen in figure B (arrow)

A 61-year-old male with a history of long standing tobacco use and DLBCL diagnosed 6 months prior, presented with shortness of breath and cough productive of clear sputum. He had completed 7 of 8 R-CEOP chemotherapy cycles with apparently good response. Chest CT at the time of DLBCL diagnosis is shown in figure A. On admission, chest CT revealed a 1.9 cm rounded, spiculated nodule in the right upper lobe (RUL) as seen in figure B (arrow). Given the spiculated appearance of the nodule and his long standing tobacco use, there was concern for a second primary malignancy. Navigational bronchoscopy and transbronchial biopsy of the RUL nodule was completed. Histopathology revealed high grade B cell lymphoma. Bacterial and fungal cultures were negative.

Pulmonary involvement in extranodal lymphoma represents less than 1% of cases. Clinically, it can present with non-specific symptoms such as shortness of breath, cough, fatigue, weight loss and fever. Radiographically, it can have various presentations such as consolidation, a well-defined mass, single or multiple nodules, interstitial infiltrates, cavitary or endobronchial lesions. There was significant concern for a second primary in our patient given his long standing tobacco abuse and the presence of a solitary spiculated lung nodule. Our patient represents a rare presentation of extranodal lymphoma, and highlights the importance of considering a wide array of diagnoses when completing work-up for a solitary pulmonary nodule.

232 A RARE CASE OF TRANSFORMATION FROM MYCOSES FUNGOIDES TO HODGKIN'S LYMPHOMA

¹N Moka*, ¹S Arikapudi, ¹B Boonpheng, ¹M Janelle, ^{1,2}T Tamarro. ¹ETSU, Johnson City, TN; ²Mountain Home VA, Johnson City, TN

10.1136/jim-2017-000697.232

Case report Primary cutaneous lymphomas are non-Hodgkin lymphomas that can be divided into three major subtypes based on neoplastic cell of origin. The three subtypes include cutaneous T-cell lymphomas (CTCL), cutaneous B-cell lymphomas (CBCL), and natural killer cell lymphomas. Mycosis fungoides (MF) is a variant of CTCL that can present with a variety of skin lesions ranging from eczema or psoriatic-like patches in the early phases to papular or nodular cutaneous tumours in later stages. The natural history of untreated MF is to evolve into systemic disease. MF can transform from a

CD4 +dominant to a more malignant CD30 +variant. However, there are rare case reports of transformation between cell lineages from a CTCL to Hodgkin lymphoma.

A 70 year old male with a 10 year history of MF presented to the haematology/oncology clinic with worsening skin lesions and cervical lymphadenopathy. Pertinent to his history is the clinical trajectory of his diagnosis of MF. He first presented with cutaneous plaques on the extensor surfaces of his legs and was diagnosed with psoriasis. Treatment with narrow band UV light and topical steroids was initiated without improvement in his symptoms. He underwent treatment with etanercept and concurrent photo-chemotherapy for 3 years, after which new lesions were biopsied that were consistent with folliculotropic MF. He was lost to follow-up for 2 after his diagnosis of MF and presented to the clinic to reestablish care complaining of a new neck mass. Excisional lymph node biopsy was consistent with nodular sclerosing Hodgkin lymphoma (CD15+, CD30+, CD20-, CD45-). He received 6 cycles of ABVD and is currently in remission.

The clinical distinction of this case ultimately lies in the aetiology of the patient's Hodgkin's lymphoma. Our first hypothesis is that the MF underwent transformation between cell lineages and the Hodgkin's lymphoma was an extension of his pre-existing neoplasm. A competing theory is that two distinct neoplastic processes occurred simultaneously. The major confounding variable is his 3 year treatment with etanercept, a TNF-alpha antagonist with a known association with the development of lymphoma.

233

16 YEAR OLD GIRL DIAGNOSED WITH CAPS AND PROBABLE HIT

¹M Nguy*, ²V Agarwal, ³C Gauger. ¹UFCCOM, Jacksonville, FL; ²Nemours, Pensacola, FL; ³Nemours, Jacksonville, FL

10.1136/jim-2017-000697.233

Case report Catastrophic antiphospholipid syndrome (CAPS), also known as Asherman syndrome, is an uncommon complication of antiphospholipid syndrome that occurs in <1% of patients that causes thrombus in multiple organs.¹ In treating CAPS, it is important to recognise heparin induced thrombocytopenia (HIT), as it can occur in up to 5% of patients taking unfractionated heparin.² We present a case of a 16-year-old Caucasian female with concurrent diagnosis of CAPS and probable HIT. There are few case reports on these diagnoses in tandem in adults however none previously reported in paediatrics.

REFERENCES

1. Asherson RA, Cervera R, de Groot PG, *et al*. Catastrophic antiphospholipid syndrome registry project group. Catastrophic antiphospholipid syndrome: International consensus statement on classification criteria and treatment guidelines. *Lupus* 2003;**12**(7):530–534.
2. Triplett DA, Asherson RA. Pathophysiology of Catastrophic Antiphospholipid Syndrome (CAPS). *American Journal of Haematology* 2000;**65**:154–159.

Diagnostic criteria for CAPS

1. Evidence of involvement of >3 organs systems or tissues
2. Development of symptoms in
3. Positive antiphospholipid antibodies (at least 6 weeks apart)
4. Histopathological findings of microthromboses in vasculature

Review of literature of concurrent cases of CAPS and HIT

Case	Age/Sex	Diagnosis/Aetiology
1	63 yo male	Sepsis leading to bilateral haemorrhagic adrenal infarction
2	28 yo female	Post renal transplantation (end stage renal failure)
3	37 yo male	DVT and Cellulitis
4	42 yo female	Oestrogen
5	63 yo male	Coronary heart disease with hematoma

234

WHAT CAME FIRST: THE OVARY OR THE LYMPHOCYTE?

H Oddo Moise*, A Coulon, J Doan, S Sanne. *LSUHSC, New Orleans, LA*

10.1136/jim-2017-000697.234

Case A 31 year old woman with history of daily IVDU and untreated Hepatitis C presented to the emergency department with 3 months of non-specific progressive ailments including left knee pain, shortness of breath with exertion and three-pillow orthopnea, twelve pound weight loss, abdominal 'tightness' greatest in the left lower quadrant, early satiety, dysphagia to liquids and solids, left axillary node swelling and bilateral supraclavicular lymph node swelling. She denied fever, chills, night sweats, recent travel, sick contacts or family history of cancer. Chest CT showed a substantial left pleural effusion with lobulated pleural thickening and mediastinal and hilar lymphadenopathy consistent with sarcoma versus metastatic disease. Subsequent abdominal and pelvic CT showed enlarged retroperitoneal lymph nodes of the left pelvis and groin with a solid mass in the left deep pelvis concerning for ovarian malignancy, metastatic disease, lymphoma or sarcoma. Transvaginal ultrasound revealed a solid left adnexal mass measuring 5.6×3.4×5.2 cm. Workup was begun to ascertain the primary site of malignancy suspicious for lymphocyte versus ovarian source. A right supraclavicular lymph node biopsy was performed during which she was intubated for increasing left pleural effusion with compression of mediastinal structures. Thoracentesis was performed with removal of 1.5 L of blood-tinged pleural fluid and a chest tube was placed. Flow cytometry of the lymph node biopsy showed 95.6% T lymphoblasts positive for CD2, CD3, CD7, TdT and CD99 consistent with the diagnosis of Non-Hodgkin T-cell lymphoblastic lymphoma. CA125 was mildly elevated at 47, not suggestive of ovarian malignancy. Despite numerous attempts at discussing the importance of a bone marrow biopsy and cancer treatment options, the patient declined all medical intervention or palliative resources.

Discussion Malignant lymphoma involvement of the female genitourinary tract, including the ovary, is not commonly seen. While ovarian involvement is relatively rare, non-Hodgkin lymphomas such as T cell lymphoblastic lymphoma (T-LBL) represent a frequency of approximately 7% to 26% of those diagnoses and should be considered in the differential diagnoses of young females with ovarian masses.

235 POEMS: AN ODE TO A SYNDROME

*S Ozair, B DeBoisblanc, S Subbiah, R Jetly. *Louisiana State University Health Sciences Centre, New Orleans, LA*

10.1136/jim-2017-000697.235

Case report A 45 year-old man with normal coronary arteries on angiography was referred for evaluation of thrombocytosis (platelet count of $812 \times 10^3/\text{UL}$) following two separate acute myocardial infarctions. Testing for JAK2 and CALR mutations were negative. He also described symptoms of worsening polyneuropathy and anasarca. POEMS (Polyneuropathy, Organomegaly, Endocrinopathy, Monoclonal protein, Skin changes) syndrome was suspected. Physical exam was additionally remarkable for splenomegaly and newly developed hyperpigmentation of both hands with white nails. On laboratory testing he was found to have adrenal insufficiency and hypothyroidism. Both kappa and lambda free light chains were elevated but there was no M-spike on serum protein electrophoresis. Bone marrow biopsy was consistent with an increased population of plasma cells that formed atypical aggregates rimming non-paratrabeular lymphoid aggregates. These plasma cells were noted to have a lambda predominant expression pattern, suspicious for monoclonality. Imaging studies confirmed osteosclerotic lesions in T10 and mediastinal lymphadenopathy. VEGF (vascular endothelial growth factor) was elevated at 264 pg/ml.

The cause of POEMS syndrome is unknown, although chronic overproduction of pro-inflammatory cytokines (eg, IL-1, IL-6, and VEGF) appears to be a major contributor to the microangiopathy, increased vascular permeability, thrombocytosis, and neovascularization that leads to thrombosis, tissue oedema, polyneuropathy, and pulmonary hypertension.

The International Myeloma Working Group (IMWG) criteria for the diagnosis of POEMS requires the presence of two mandatory criteria (polyneuropathy and monoclonal protein), and at least one major and one minor criterion. Major criteria include sclerotic bone lesions, elevated VEGF, and Castleman disease. Minor features include organomegaly, endocrinopathy, characteristic skin changes, papilledema, extravascular volume overload, and thrombocytosis.

Patients with POEMS syndrome are best treated with chemotherapy with or without autologous stem cell transplantation similar to that used for the treatment of multiple myeloma.

236 FAILED SCREENING OF ADVANCED MYELOMA IN AN ASIAN WOMAN

T Dickerson, S Bautista, S Palumbo*, S Hebert, LS Engel. *LSU Health Sciences Centre, New Orleans, LA*

10.1136/jim-2017-000697.236

Introduction The incidence of multiple myeloma (MM) varies with ethnicity and age; Asian populations have a lower incidence. The mean age of onset of MM in Asian population is 62 years.

Case A 51-year-old Asian woman without significant medical history had multiple Emergency Department visits with progressive, non-radiating low back pain of two months duration. Spinal radiographs were unrevealing and no screening labs were obtained. Eventual referral to an ambulatory clinic identified substantial hypercalcemia. Upon reassessment, the patient

endorsed weakness, cramps, anorexia, fever, abdominal pain, constipation, urinary frequency, and a 15-pound weight loss. Physical exam revealed a thin female with tenderness over L4-S1 vertebrae and a 1 cm firm left axillary node. Labs showed corrected calcium 14.52 mg/dL, haemoglobin 10.1, protein gap 8.2 g/dL, and creatinine 1.4 mg/dL. Lumbar CT revealed numerous lytic foci throughout the spine and pelvis supported by skeletal survey revealing lytic foci of the cranium, axial and proximal appendicular skeleton. Her other labs showed elevated IgG, B2-microglobulin, Kappa light chain, and M spike, UPEP with monoclonal band in gamma region, and bone marrow biopsy of >50% plasma cells. FISH analysis showed translocation (11;14) with fusion of CCND1 (BCL1) at 11q13. The patient was diagnosed with multiple myeloma (MM) Stage III by ISS criteria. Hypercalcemia was treated with IV fluids, zoledronic acid, and calcitonin. Radiation was utilised for spinal compression at S1. Lastly, bortezomib and dexamethasone were initiated with plans for stem cell transplant.

Discussion A lower incidence of MM in the Asian population has been partly attributed to genetic polymorphisms with doubled incidence in the last 10 years in South Korea and Taiwan. Analysis of genetic versus environmental risk factors is lacking. MM is 'a disease of the elderly' but in an Asian cohort, 58.5% of those diagnosed were <65 years-old. Based on these findings, prevalence in this cohort at earlier ages is likely to continue and research should be sustained.

237 ACUTE LIVER FAILURE CAUSED BY MULTIPLE MYELOMA

T Poosarla*, S Elkins, A Reddy. *University of Mississippi Medical Centre, Jackson, MS*

10.1136/jim-2017-000697.237

Case report Multiple Myeloma (MM) is a plasma cell neoplasm that accounts for about 15 percent of all haematological malignancies. It is a disorder that involves clonal proliferation of neoplastic plasma cells in the bone marrow with an increase in monoclonal paraprotein. It is uncommonly associated with extraosseous involvement such as spleen or liver, especially at initial presentation. Reports of liver involvement in MM are usually secondary to amyloidosis rather than plasma cell involvement. Here we present a rare case of a patient with acute liver failure (ALF) who was found to have MM.

A 56-year-old African American female with history of hypertension and hypothyroidism who was admitted to the hospital with complaint of 2 weeks of abdominal swelling, difficulty ambulating secondary to bilateral lower extremity pain, lower extremity swelling, and shortness of breath. She also notes a 15-pound weight loss over the last 2 months. In the emergency room, she was found to have ascites, globulin gap, elevated serum total protein, hypoalbuminemia, anaemia, and renal failure concerning for cirrhosis. CT of abdomen and pelvis showed a large volume of ascites, abnormal appearance of liver parenchyma, and enlargement of the IVC and hepatic veins suggestive of cirrhosis. She underwent further workup including liver biopsy which showed sinusoidal involvement by plasma cells concerning for MM and no evidence of hepatitis or cirrhosis. Cytology on peritoneal fluid also showed malignant plasma cells. Serum protein electrophoresis consistent with IgG lambda with M protein of 10. Bone marrow biopsy revealed hypercellular marrow with 80% plasma cells. There

were multiple subcentimeter lesions throughout the skeleton consistent with MM. She was started on treatment with bortezomib, revlimid, dexamethasone with marked improvement in symptoms and resolution of ascites.

MM presenting as ALF is extremely rare and only a few cases have ever been reported. Liver involvement can be seen and is discovered incidentally but is clinically silent. It is associated with poorer prognosis as treatment is limited with liver failure. It is important to consider MM in patients who present with ALF, especially with no risk factors for cirrhosis, since prompt diagnosis can lead to quicker treatment and theoretically improve survival.

238 BLOOD CELLS: TOLERANCE, AUTOIMMUNITY, MODULATION

¹EC Quintin*, ²KN Rezkallah, ¹S Ozair, ¹TM Reske, ¹H Boulares, ¹P Rigby. ¹LSUHSC New Orleans, New Orleans, LA; ²Presence Saint Joseph Hospital, Chicago, IL

10.1136/jim-2017-000697.238

Purpose of study All haematological cells originate from a multipotent mesenchymal stem cell that are produced via myeloid and lymphopoietic pathways in the niches of the bone marrow. The marrow structure plays a key role in the mixing of cells and cytokines resulting in cell production, maturation, kinetics, homing and circulation in the niches and sinusoids. The purpose is to enumerate, identify, and access crosstalk of blood cells related to Myeloid Derived Suppressor Cells (MDSC).

Methods used By identifying blood cells using fluorescence-activated cell sorting (FACS), we aim to locate pairs or clusters utilising standard procedures and studying the function and relationship of these cells.

Summary of results The stem cells are held in place by surface receptors and divide under a stimulus. They mature and travel to a sinusoid where they mix with other cells before being released into the venous circulation. Certain cells seek out specific partners according to their own specific surface receptors to crosstalk, exchanging particles and messages causing downhill haematological and immunological cascades.

As individuals grow and age from birth, tolerance is arranged for all self-antigens and tissues. If tolerance is lost, disease may follow. The number, types and proportions of different cells change throughout a lifetime. The mix of MDSC with Tregs, memory cells, NK cells, stem cells, and other lymph cells maintain tolerance for self but changes in the numbers of cells can affect their function, maturity or host characteristics.

Conclusions When autoimmune disease is found, cell crosstalk changes depend on appropriate numbers, proportions, and cross-functions. They may be exogenously altered to regain a tolerant state through modulation of the immune systems via immunosuppressive medications. Specific pairs are linked through cell surface marker/receptor anatomy, relating cells to activity producing certain cytokines. The relationship of cell pairs or other groupings will likely determine inhibition or activation of certain processes that may lead to pathology.

239 A CASE OF CONCURRENT RENAL CELL CARCINOMA AND HODGKIN'S LYMPHOMA

M Quirch*, RE Gavidia Quezada, S Phisitkul. *Texas Tech University Health Sciences Centre, Lubbock, TX*

10.1136/jim-2017-000697.239

Background The association between developing secondary malignancy after treatment for a primary malignancy is well known, particularly with leukemias and lymphomas such as Hodgkin's lymphoma. Patients treated for Hodgkin's Lymphoma are known to have an increased risk of developing a second malignancy such as breast, thyroid, bone, colorectal, or stomach cancer. In a small retrospective study, multiple primary malignancies have been reported, particularly in women from the ages 43–68, with concurrent malignancies typically being breast, uterine, or cervical.

Case presentation This is a 71 year old female admitted for generalised weakness, hyponatremia, pancytopenia, and lactic acidosis with no verifiable signs or source of infection. One month prior to admission, the patient was undergoing work up with her private urologist for a recently discovered renal mass per CT scan that was suspicious for renal cell carcinoma of 2.3×2.0 cm with multiple small lymph nodes. Decision at the time of discovery of the mass was to proceed with surgery however she became acutely ill and that is what led to her admission to our hospital.

Initial blood cultures and urine culture were negative however lactic acid remained persistently elevated and LDH was also elevated so a bone marrow biopsy was done revealing Hodgkin Lymphoma. The patient rapidly deteriorated after bone marrow biopsy. She developed acute respiratory failure, altered mental status, and hypotension which required intubation, vasopressors, and admission to the medical intensive care unit. Broad spectrum antibiotics were started with cultures being drawn seven days after admission. Urine cultures after transfer were positive for pansensitive *Klebsiella pneumoniae* and *E. coli*, and respiratory culture was positive for *Staphylococcus aureus*. Blood cultures remained negative throughout her stay. Despite aggressive care, the patient did not recover and the patient's family pursued comfort measures.

Conclusion While there is an established relationship between developing secondary malignancy after treatment with chemotherapy, concurrent malignancies tend to be very rare. Until now, there has been one other reported case of Hodgkin's lymphoma occurring concurrently with renal cell carcinoma.

240 A CASE OF INCOMPLETE CARNEY TRIAD

A Ismail, M Quirch*, S Mousa, MR Arevalo. *TTUHSC, Lubbock, TX*

10.1136/jim-2017-000697.240

Case report Carney triad is a synchronous or metachronous association of gastric gastrointestinal stromal tumours (GIST), pulmonary chondroma and extra-adrenal paraganglioma. Most patients have only one or two components of the triad, all three tumours being found in only about 2% of the patients.

We present a case of a 28-year-old woman that came to the emergency department for epigastric pain with regurgitation. She has a medical history of rheumatoid arthritis, Hashimoto's thyroiditis and Celiac disease. She reported 6 month history of 20-pound weight loss and loss of appetite. She denied dysphagia or changes in bowel habits. She had a CT of the abdomen showing a large exophytic gastric mass, concerning for malignancy and incidental calcified masses were seen in the lungs. EGD and EUS showed a subepithelial lesion, suspicious for malignant stromal cell neoplasm. Biopsy confirmed it to be GIST, positive for CD117. Molecular diagnosis was negative for Kit and platelet-derived growth factor alpha (PDGFRA) mutations. Lung mass biopsy was consistent with pulmonary chondroma. Curative surgery was planned. Intraoperatively, the tumour was found invading the liver and lymph nodes. She had total gastrectomy with esophago-jejunostomy, celiac lymphadenectomy, and partial liver resection with negative margins. She was discharged 2 weeks after surgery and follows at the cancer centre.

GIST is a mesenchymal neoplasm affecting the gastrointestinal tract typically presenting as a subepithelial neoplasms. Although the majority of GISTs appear to be sporadic, 5% of patients have one of the familial autosomal dominant syndromes, including neurofibromatosis type 1, Carney triad, and primary familial GIST syndrome. Most GISTs are characterised by KIT or PDGFRA activating mutations. There are 10%–15% of GISTs lacking KIT and PDGFRA mutations, called wild-type GISTs. Among these WT GISTs, a small subset is associated with succinate dehydrogenase (SDH) deficiency, known as SDH-deficient GISTs. GISTs that occur in Carney triad represent specific examples of SDH-deficient GISTs. SDH-deficient GISTs locate exclusively in the stomach, showing predilection for children and young adults with female preponderance. The tumour generally pursues an indolent course and exhibits primary resistance to imatinib therapy in most cases. Surgical resection is the preferred mode of therapy.

241 DIPLOPIA AND PROPTOSIS WITH A PITUITARY MASS EQUALS A MACROADENOMA? THINK AGAIN!

D Reddy*, M Ibrahim, K Krishnan, D Jaishankar. *ETSU, Johnson City, TN*

10.1136/jim-2017-000697.241

Case report Acute Myeloid Leukaemia (AML) is an aggressive hematologic malignancy. Central nervous system (CNS) involvement is rare among adult patients with AML. We describe a patient with AML presenting with visual disturbances and a pituitary mass which resolved after systemic AML chemotherapy.

A seventy one year old female with a history of AML treated successfully (without allogeneic hematopoietic stem cell transplantation {allo-HSCT}) sixteen years ago, was hospitalised with a two week history of fatigue, weight loss and intermittent blurry vision. Clinical exam was notable for diplopia and right sided proptosis without visual field defects. MRI Brain revealed a 2.4 cm sellar mass (suggestive of a macroadenoma) with cavernous sinus invasion, right carotid artery encasement, and mass effect on right optic chiasma. Peripheral blood smear documented 28,000 WBC count with 84% blasts. Pituitary function assay was normal. Bone marrow biopsy reported hyper cellularity (60%) and 70% myeloblasts. Molecular studies t (8;21) established a new clonal leukaemia

distinct from her previous AML (normal cytogenetics). Lumbar puncture revealed monocytes with rare Auer rods. She completed induction chemotherapy with Idarubicin and cytarabine achieving first complete remission (CR1). She received one dose of intrathecal methotrexate and 3 cycles of cytarabine consolidation chemotherapy course. Her diplopia and proptosis resolved completely.

AML is characterised by a rapid clonal proliferation of immature hematopoietic cells in the peripheral blood and bone marrow. The overall survival of AML is dictated by cytogenetics/molecular markers and age. When CR1 is achieved, most relapses occur in the first two years. Extramedullary involvement with CNS leptomeningeal infiltration can be noted in acute lymphoblastic leukaemia and in 2%–10% of patients after allo-HSCT. Leukemic infiltration of the pituitary gland with AML is extremely rare and documented in isolated case reports. Our patient represented an extremely rare and unique case of a second-primary AML with pituitary involvement that responded to induction and consolidation chemotherapy.

242 'DOSE ESCALATED' CHEMOTHERAPY FOR AGGRESSIVE LYMPHOMA IN THE ELDERLY

D Reddy*, F Tawadros, D Jaishankar. *ETSU, Johnson City, TN*

10.1136/jim-2017-000697.242

Case report Diffuse large B-cell lymphoma (DLBCL) is an aggressive Non Hodgkins Lymphoma (NHL). The anti-CD20 antibody rituximab anchors various immuno chemotherapy regimens, including R-CHOP (Rituximab, cyclophosphamide, adriamycin, vincristine, prednisone) a gold standard for DLBCL. Management of DLBCL in the elderly poses unique challenges given increased risk of toxicity. Anthracycline based regimens are avoided in the elderly leading to lower response rates. We present a case of an elderly patient who achieved complete response with a unique protocol of Adriamycin based therapy.

An eighty-five year old female with multiple medical problems was hospitalised with dyspnea and weakness. Non-tender cervical and inguinal adenopathy was noted. Nodal excision biopsy demonstrated high grade (Ki-67 >90%), B cell 'double-hit' lymphoma with MYC/BCL-2 rearrangement and grade IIIB follicular lymphoma. PET/CT revealed splenomegaly and diffuse hypermetabolic adenopathy above and below the diaphragm. A positive bone marrow biopsy established stage IV disease. CSF analysis was negative. The patient and family were very keen on treatment despite her advanced age and borderline performance status (ECOG II). She received 2 cycles of R-CVP (Rituximab, cytoxan, vincristine, prednisone). Adriamycin at 50% of full dose (akin to mini R-CHOP) was introduced at cycle 3 and continued at 75% of full dose for cycles 4–6. Post treatment PET-CT demonstrated excellent response.

DLBCL is the commonest type of NHL, usually presenting in the seventh decade. With improving life expectancy, its incidence in the elderly is predicted to rise. DLBCL is curable with a long term survival rate of 40% with anthracycline based regimens. Multiple non-anthracycline based regimens are available for frail patients. mini-CHOP is a variant with 50% dose reduction of Cytoxan, Vincristine and Adriamycin. Our protocol differed in maintaining full doses of Cytoxan and Vincristine while introducing Adriamycin at 50% of full dose

and escalating doses as tolerated. Our patient completed therapy successfully without serious complication with clinical and radiographic improvement during therapy. Complete response was noted at the end of treatment. We propose 'dose escalated' mini R-CHOP as an intermediate regimen for the elderly.

243

BILATERAL OTITIS EXTERNA MASKING EXTRAMEDULLARY RELAPSE OF ACUTE PROMYELOCYTIC LEUKAEMIA

¹C Rivera-Franceschini*, ^{1,2}V Vestal, ¹A Cruz. ¹San Juan City Hospital, Ponce, PR; ²VA Hospital San Juan

10.1136/jim-2017-000697.243

Case report Acute promyelocytic leukaemia (APL) is a subtype of acute myelogenous leukaemia that is characterised by the translocation of chromosomes 15 and 17. The introduction of all-trans retinoic acid (ATRA) as an early therapy has increased the overall remission rates in these patients but relapses still occur. Most relapses are limited to the bone marrow and blood. However, APL can also relapse to extramedullary sites involving the skin, central nervous system (CNS) and other organs. A 48-year-old man with APL on remission for 2 years presented to the emergency room with bilateral ear pain of 3 weeks duration. Pain began after swimming in a pool. It was 8/10, constant and associated with tinnitus, bloody secretions and decreased bilateral hearing acuity. Upon evaluation patient was found with a bilateral swollen and erythematous ear canal with granulating tissue formation. He was evaluated by an otorhinolaryngologist who recommended IV antibiotic piperacillin/tazobactam and dexamethasone/ciprofloxacin ear drops. A maxillofacial CT scan of the head showed opacified external auditory canals bilaterally, which could correlate with mucormycosis infection. Ear infection improved with antibiotics and biopsies of the external ear canals were taken. The left external ear canal biopsy was extensively involved with immature myelocytes, compatible with involvement by acute promyelocytic leukaemia. Bone marrow biopsy was negative for leukaemia. Cerebral spinal fluid analysis was negative for malignancy. Patient was started on ATRA, arsenic trioxide and radiotherapy. Even though CNS involvement is the most common cause of extramedullary relapse in APL, a biopsy of the ear canal should be considered in a patient with suspected otitis externa since it could be a rare presentation of APL. It is imperative to identify this type of extramedullary relapse considering that patients could benefit from induction chemotherapy.

244

LDH AS AN EARLY MARKER FOR PRIMARY MYELOFIBROSIS?

EB Saul*, B Dreiling. University of Mississippi Medical Centre, Madison, MS

10.1136/jim-2017-000697.244

Introduction Primary myelofibrosis (PMF) is a type of chronic myeloproliferative neoplasm with an estimated incidence of 1.5 per 1 00 000 per year occurring mainly in middle aged and older adults. There are various different clinical manifestations of the disease some of which include fatigue, low-grade fever or night sweats, weight loss and splenomegaly.

Case A 68 year old Caucasian male presented with a mild hypoproliferative anaemia of obscure origin that dated back to 2012. He has had no fevers, night sweats or weight loss. In 2012, his haemoglobin and hematocrit (H/H) were 11.6 and 35.2 respectively however has gradually trended down to 9.1/29.2. WBC and platelet counts are normal. Interestingly, his LDH was elevated in 2012 at 670 and has continued to increase over the years to a current level of 1057. LDH fractionation was done revealing fraction 2>1>3>4>5 suggesting a bone marrow, cardiac or renal aetiology. CPK, renal function and cardiac workup were all normal. Peripheral blood smear revealed nucleated red blood cells, moderate large platelets, elliptocytosis, and teardrop cells. Bone marrow biopsy was done given concerns for ineffective hematopoiesis. Pathology returned as a myeloproliferative neoplasm, best regarded as primary myelofibrosis. A JAK2 V617F mutation analysis was sent and returned positive. His spleen measured 14.14 cm in length on ultrasound. He remains asymptomatic with a DIPSS-plus score of 2 and a median overall survival of 2.9 years. However, given that he is asymptomatic with stable blood counts he has chosen observation at this time.

Discussion There are various nonspecific abnormal laboratory tests in patients with primary myelofibrosis. Since there is no 'gold standard' for the diagnosis of PMF, there have been diagnostic criteria that have been proposed by the WHO. LDH is an enzyme found in the marrow and blood precursors. With intramedullary hemolysis associated with PMF, one could presume elevations in LDH may actually precede changes in the CBC assisting in the early detection of PMF.

245

CUTANEOUS LYMPHOMA: THE NON RESOLVING NODULE

P Shelley*, KR Green. UF Health, Jacksonville, FL

10.1136/jim-2017-000697.245

Introduction Primary cutaneous anaplastic large cell lymphoma is rare malignancy which characteristically exhibits CD30 positivity. Usually presenting in the sixth decade with spontaneous solitary or grouped nodules that fail to resolve. Diagnosis is made by skin biopsy which demonstrate characteristic large cells with eosinophilic cytoplasm and occasional horseshoe shaped nuclei with evidence of epidermal hyperplasia. Treatment modalities include localised surgical excision and systemic chemotherapy. The latter is reserved for those cases with widespread lesions.

Case report A forty three year old female with a history of non-hodgkin's lymphoma and sarcoidosis presented to an outside institution with a complaint of progressive swelling in her right axilla for the past five weeks. The mass was both itchy and tender to palpation. She also complained of fevers, night sweats, and a thirty pound unintentional weight loss. Due to concern for potential abscess an incision and drainage was attempted but upon incision no spontaneous drainage was seen. She was prescribed a course of antibiotics and instructed to follow up with her primary care physician. She then presented to our institution with complaint of multiple flesh coloured skin lesion which spontaneously erupted over the past week in sporadic areas from head to toe sparing the palms and soles. Further exam revealed numerous five to ten millimetre, firm, well circumscribed lesions on the breasts, arms, thighs, abdomen, back, neck, and face. Along with a large five

by three tender and firm mass in the right axilla. A punch biopsy was performed of the lesions on the left breast and right clavicle. Dermatopathology of the aforementioned samples were positive for anaplastic large cell CD30 positive lymphoma. She was then referred to an oncologist to discuss treatment options and to begin staging of her malignancy.

Discussion This case highlights the necessity of prompt evaluation of skin lesions via biopsy, especially in those patients with previous history of malignancy. Most cases of primary cutaneous anaplastic large cell lymphoma have a ten year survival rate of ninety percent if treated appropriately. However recurrence is common. Systemic chemotherapy is typically reserved for those with disseminated disease or those with multiple recurrences with surgical excision.

246 EXTENDED THIRTY MONTH PROGRESSION FREE SURVIVAL WITH THIRD LINE ERIBULIN FOR METASTATIC BREAST CANCER

S Singal*, R Khalaf, D Jaishankar. *East Tennessee State University, Johnson City, TN*

10.1136/jim-2017-000697.246

Case report Eribulin is a non-taxane microtubule inhibitor approved for treatment of metastatic breast cancer after two prior chemotherapeutic regimens. Eribulin as third line agent in the palliative setting has shown a median overall survival (OS) of 13 months and median progression free survival (PFS) of 3 months. We report a patient with extended (PFS) of more than 30 months with metastatic breast cancer treated with Eribulin in the third line setting. A forty-eight year old lady was diagnosed with stage IIA (T2N0M0), high grade, triple negative, invasive ductal carcinoma (IDC) of the left breast. She underwent neo adjuvant chemotherapy with Adriamycin and Cytoxan followed by a negative sentinel lymph node biopsy. At mastectomy she was noted to have a 2.5 cm tumour, high grade, triple negative IDC with three additional lymph nodes negative for metastatic carcinoma. She subsequently pursued further chemotherapy and was treated with 6 cycles of Cytoxan, Methotrexate and Fluorouracil (CMF). She then transferred care to our cancer centre and eight months into her surveillance program developed a 2.8 cm right lower lobe (RLL) pulmonary mass with SUV of 27 on a PET-CT. A fine needle biopsy was consistent with metastatic triple negative breast cancer with sheets of poorly differentiated carcinoma similar in morphology to previous breast pathology. Imaging studies revealed oligometastatic disease. She commenced single agent Taxol in the 1st line metastatic setting with dramatic decrease in RLL pulmonary mass to less than 1 cm with SUV of 1.7 and resolution of other sub cm pulmonary nodules. The response was short lived lasting only six months. She started 2nd line Gemcitabine with subsequent largely stable disease for a period of 11 months. Progression of RLL pulmonary nodule measuring 2.1 cm with SUV of 10 noted. She then started 3rd line Eribulin with a dramatic response on imaging studies within three months and has maintained no evidence of disease (NED) on scans over the subsequent 30 months. She is clinically stable and her tumour markers have plateaued. She has required Eribulin dose reductions on account of neuropathy. Our patient has shown excellent response and tolerance to Eribulin with PFS of over 30 months (ten times the norm) which is rare.

247 INTRAVASCULAR LARGE B CELL LYMPHOMA PRESENTING AS CHRONIC COUGH

S Singal*, R Khalaf, D Jaishankar, E Spradling. *East Tennessee State University, Johnson City, TN*

10.1136/jim-2017-000697.247

Case report Intravascular large B cell lymphoma (IVLBCL) is a rare and aggressive subtype of large cell lymphoma that is characterised by proliferation of lymphoma cells within the lumina of small blood vessels, particularly capillaries and post-capillary venules most commonly reported as cutaneous and CNS lesions. We report a rare case of IVLBCL involving the lungs. A 73-year-old male, never smoked, presented with persistent cough and hyponatremia. Chest imaging showed calcified mediastinal adenopathy. Pulmonary function testing showed no restrictive or obstructive pattern. Bronchoscopy with endobronchial ultrasound guided biopsy was non-diagnostic. Patient underwent video assisted thoracoscopy with right upper middle and lower lung wedge biopsies. Pathology showed IVLBCL with large B cells located mainly intracapillary and intra-small artery and veins. Tumour cells were positive for CD20, CD79a, Pax-5, CD10, Mum-1. Tumour cells were negative for CD3, CK AE1/AE3, S100, Cam5.2, CD34. Bone marrow biopsy and aspiration showed minimal involvement of large B-cell lymphoma. PET scan revealed focal uptake at T4, T9, L2, L4 vertebrae concerning for lymphomatous involvement of the bone. Cerebrospinal fluid was negative for malignancy. Brain imaging was negative. Patient was diagnosed with Stage IV IVLBCL. During recovery from right lung wedge biopsies he developed acute respiratory failure requiring oxygen at 10 L/min. Urgent chemotherapy with R-CHOP cycle 1 was initiated providing complete resolution of all symptoms. The final treatment plan includes 6 cycles of R-CHOP with CNS prophylaxis.

Our case demonstrates extranodal disease, aggressive biology, and the requirement of urgent treatment. The rarity of this disease and difficulty of detecting intravascular infiltration often contributes to delay of diagnosis and high mortality.

248 PENILE LYMPHOMATOUS DISEASE PORTENDS POOR PROGNOSIS?

F Tawadros*, D Reddy, K Krishnan, D Jaishankar. *ETSU, Johnson City, TN*

10.1136/jim-2017-000697.248

Case report Diffuse Large B Cell Lymphoma (DLBCL) accounts for 25% of all non-Hodgkin Lymphomas. DLBCL presents as a rapidly enlarging mass, usually nodal enlargement, or less often as a mass lesion anywhere in the body. We present a patient with DLBCL with highly atypical extra nodal presentation. A sixty-two year old male presented with persistent right upper quadrant abdominal pain and weight loss over six weeks. Imaging studies suggested gallbladder adenomyosis and patient underwent a cholecystectomy. Pathology reported DLBCL, activated B cell type, CD20 + and MUM1 + with Ki67 90%. Molecular studies ruled out double and triple hit lymphoma but were positive for additional copies of IgH, amplification of BCL-2 gene and BCL-6 gene deletion. Clinical exam revealed significant penile induration. PET-CT revealed mediastinal and abdominal adenopathy with mild tonsillar, parotid, and massive penile involvement. CSF cytology, MRI Brain, Testicular Ultrasound and Bone marrow

biopsy were negative. Chemo immunotherapy with R-CHOP and intrathecal methotrexate was initiated. Dramatic regression of penile induration which served as an index lesion, was noted within days. Post treatment PET-CT documented complete response. Three months after therapy he developed a biopsy proven intracranial relapse in the left occipital lobe. He succumbed to his illness while receiving palliative salvage chemotherapy with high dose cytarabine and methotrexate. DLBCL is a heterogeneous entity derived from germinal centre B cells or post-germinal centre B cells. Extra nodal disease (liver, lung, skin) is a less common but well known occurrence. Penile involvement may present as primary penile lymphoma or secondary to systemic disease. While testicular lymphoma is well reported, secondary penile involvement is rare accounting for less than 1% of extra nodal disease. Prognosis in DLBCL is dictated by clinicopathologic factors and extra nodal involvement portends higher relapse risk. Paraneoplastic lymphoma is associated with a risk of CNS relapse. Our case highlights a high risk variant of DLBCL with atypical presentation, multiple rare extra nodal sites of disease, unusual molecular features, excellent response to therapy culminating in CNS relapse.

249 A SUSPICIOUS CASE OF PERNICIOUS ANAEMIA AND VITAMIN B12 DEFICIENCY

A Traina*, J Dubuc, H Oddo Moise, A Coulon, A Bourgeois, J Doan, S Guillory, S Sanne. LSUHSC, New Orleans, LA

10.1136/jim-2017-000697.249

Case report A 56 year old man with a past medical history of hypertension was brought to the emergency department with progressively worsening dyspnea on exertion and fatigue for 2 months. He endorsed subjective fever for 2 weeks and his family noted confusion over several days. He also reported 15 pound weight loss for several months. He was febrile to 105.5F on arrival. The physical exam was significant for a systolic flow murmur, mild confusion and slowed speech with unclear baseline neurologic exam, and normal sensation and proprioception in the distal extremities. Initial labs revealed pancytopenia and a macrocytic anaemia with WBC of 2.3 10^3 /UL, ANC of 100 cells/ μ L, haemoglobin 8.7 g/dL, hematocrit 26%, MCV 113.9 FL and platelets 41 10^3 /UL with schistocytes and tear drop cells. He underwent further studies for pancytopenia and fever with negative infectious work up including HIV, blood and urine cultures. His vitamin B12 level was profoundly deficient at 64 PG/mL with normal folate and iron studies. His reticulocyte count was inappropriately normal at 0.9%. Haematology was consulted due to concern for hematologic malignancy. There were no blast cells identified on peripheral blood smear. Bone marrow biopsy and flow cytometry revealed hypersegmented neutrophils, but there was no definitive immunophenotypic evidence of hematopoietic neoplasia with normal CD markers, immunophenotyping and cytogenetics. There was no identifiable source of fever or malignancy on CT images of the chest, abdomen or pelvis. The patient was started on intramuscular vitamin B12 supplementation with improvement in all cell lines. Intrinsic factor

antibody test was elevated at 32.6 AU/mL and anti-parietal cell antibody was also elevated at 71.6 units, consistent with pernicious anaemia.

Discussion Although pancytopenia may be caused by severe vitamin B12 deficiency, it is not usually accompanied by fevers and warrants and infectious and malignancy work up. We present a case of profound B12 deficiency due to pernicious anaemia, an autoimmune disorder characterised by the destruction of parietal cells of the gastrointestinal system resulting in vitamin B12 deficiency. Lifetime intramuscular B12 supplementation will be required and can prevent progression of irreversible neuropsychiatric changes.

250 CHEMOTHERAPY TOXICITY CONFIRMS DIAGNOSIS OF URACHAL CARCINOMA

¹D Vesselinovich*, ^{1,2}K Thomas, ^{1,2}M Matrana. ¹University of Queensland, Ochsner Clinical School, New Orleans, LA; ²Ochsner Health System, New Orleans, LA

10.1136/jim-2017-000697.250

Purpose of study The urachus is a fibrotic remnant of the allantois, a canal that collects liquid waste and exchanges gases from the fetal bladder with the umbilical cord. Urachal cancer is a rare and aggressive cancer that often presents as adenocarcinoma at the dome of the bladder. If found early and confined to the urachus, cystectomy with en bloc re-section of the urachal ligament and umbilicus can be curative. For inoperable patients, chemotherapy generally has low efficacy. Gem-FLiP (gemzar, 5-FU, leucovorin, and cisplatin) is undergoing clinical trials but its efficacy and adverse effects with urachal carcinoma have not been confirmed.

Methods used A 76-year-old male with a long history of genitourinary disease including renal stones, urethral stricture, and transitional cell carcinoma *in situ* of the bladder presented with gross painless hematuria. A flexible cystoscopy showed a sessile tumour at the dome of the bladder. A CT Urogram of abdomen and pelvis confirmed an enhancing, exophytic mass at the dome of the bladder. A CT guided biopsy revealed adenocarcinoma consistent with urachal cancer.

Summary of results The patient began chemotherapy with Gem-FLiP. He developed pedal oedema and drainage of the umbilicus. A CT of abdomen and pelvis showed an anterior extension through the abdominal wall just below the umbilicus as well as central hypo attenuation within the mass in the bladder; this represented a fistula between the bladder and umbilicus, confirming the diagnosis of urachal cancer. Following completion of the second cycle, restaging showed partial response, but the patient was intolerant of the regimen. The patient began FOLFOX treatment (leucovorin, fluorouracil, and oxaliplatin). FOLFOX has been supported for adenocarcinoma in peer reviewed literature. He tolerated this but was hospitalised shortly after for recurring anaemia.

Conclusions In this case, Gem-FLiP produced an impressive partial response. The formation of a fistula along the anatomic location of the urachus confirmed the diagnosis of urachal cancer that was strongly suspected. It is highly unusual that a response to chemotherapy confirms a diagnosis.

251 **PRIMARY LUNG DIFFUSE LARGE B-CELL LYMPHOMA WITH HEPATIC METASTASES: A RARE NEOPLASM**

¹Y Vorakunthada*, ²W Lilitwat. ¹Texas Tech University Health Sciences Centre Lubbock, Lubbock, TX; ²University of Iowa Hospitals and Clinics, Iowa City, IA

10.1136/jim-2017-000697.251

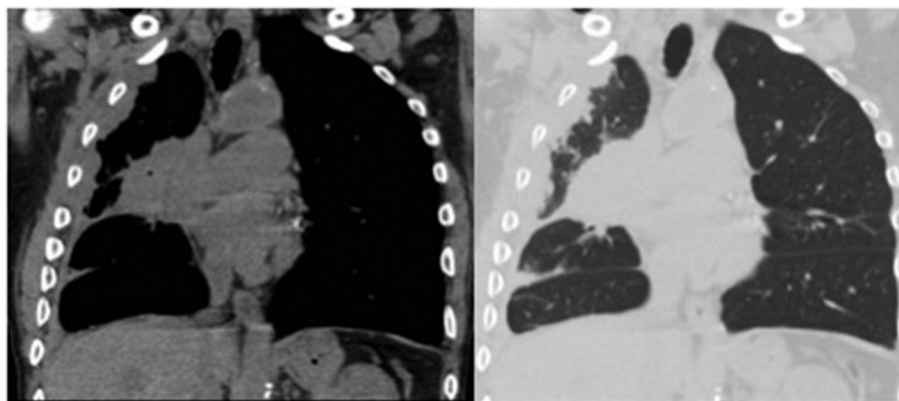
Case report Primary pulmonary lymphoma is very rare. Here, we present a 66-year-old male with primary lung diffuse large B cell lymphoma (DLBCL) who presented with productive cough and shortness of breath for a week. He had weight loss of 40 lbs. over 2 months. His exam showed decreased breath sounds with dullness on percussion on the right side of chest. Contrast-enhanced CT of chest and abdomen revealed 6.6×4.5 cm right hilar mass, 3 and 4 mm nodules within right upper lobe, nodular thickening within the right middle lobe (figure 1), and multiple hypodensity lesions throughout the liver. Bone marrow biopsy was negative for malignancy. However, both transbronchial needle aspiration and liver biopsy showed diffuse, high-grade B cell lymphoma, confirmed by positive immunohistochemistry of CD20, CD79a, CD10, BCL-2 and Ki-67. He responded well with rituximab, cyclophosphamide, doxorubicin, vincristine, and prednisone (R-CHOP).

Primary pulmonary DLBCL represents only 0.04% of all lymphoma cases. In our case, hilar mass, multiple pulmonary and hepatic nodules raise a concern of lymphoma. We do not find radiographic characteristics of intratumoral bronchial translucency.¹ For prognosis, positive CD99 DLBCL has a better 2 year survival. However, prognostic factor for primary lung DLBCL has not been reported. R-CHOP was started due to strong CD 20 expression for rituximab. Nonetheless, the outcomes are contradicting between R-CHOP and CHOP regimen.

Pulmonary lung DLBCL with hepatic metastasis should be suspected in lung mass and multiple hepatic nodules. This rare entity needs to be studied for effective chemotherapy treatment.

REFERENCE

1. Saitoh Y, et al. Unique radiological features of two cases of primary pulmonary diffuse large B-cell lymphoma. *Thorax* 2017;**72**(9):859–60.



Abstract 251 Figure 1 CT chest with mediastinal (A) and lung (B) window settings

252 **A RARE CASE OF EPIDURAL FOLLICULAR LYMPHOMA**

MH Williams*, C Capra, C Milner. *UMMC, Jackson, MS*

10.1136/jim-2017-000697.252

Case report Back pain is one of the most common complaints encountered in medicine, with more than 80% of adults experiencing back pain during their lifetime. The most frequent aetiology of back pain is lumbar strain. Malignancy accounts for less than 1% of cases of back pain, with follicular lymphomas comprising less than 10% of those. Here we present a very unusual case of follicular lymphoma presenting as worsening low back pain.

A 46-year-old male with a previous traumatic back injury with mild, chronic cauda equina syndrome and severe chronic back pain presented with a new and different constant dull ache in his back. He denied any new weakness, difficulty ambulating, bowel or bladder incontinence, weight loss, night sweats, fever, chills, lymphadenopathy, and headaches. Neurologic examination was normal and there was no palpable adenopathy or splenomegaly. Magnetic resonance imaging (MRI) of the lumbar spine revealed an 8.5 cm epidural mass extending out multiple neural foramen and causing severe spinal cord stenosis, greatest at T12-L1. Additional imaging, including MRI of the brain, computed tomography (CT) of chest, abdomen, and pelvis, and bone scan, demonstrated extensive osseous metastases involving the left frontal skull, right distal humerus, and thoracolumbar spine. There was also adenopathy in the left axillary region and multiple large masses in the mediastinum and paraspinal soft tissues. Patient then underwent bilateral laminectomies at T12-L3 for partial resection of the lumbar spinal cord mass. Histopathology revealed a grade 2 follicular lymphoma with fluorescence *in-situ* hybridization (FISH) detecting a t(14;18). He was treated with four cycles of Bendamustine and Rituximab with subsequent positron emission tomography/computed tomography (PET/CT) demonstrating a complete response.

Although it is uncommon for follicular lymphoma to involve organs outside of the lymphatic system and bone marrow, cord compression may develop when epidural tumours do occur. Follicular lymphoma uncommonly involves the spinal cord, with an epidural location for lymphoma occurring in

only 0.9%–6.5% of previously undiagnosed non-Hodgkin lymphomas. Even though epidural follicular lymphoma is rare, and malignancy in general is a less common cause of low back pain, clinicians should consider it in the differential diagnosis since treatment delay can adversely affect outcomes.

253 RECURRENT CERVICAL CANCER: A UNIQUE PATH TO DIAGNOSIS

MH Williams*, RA Williams, D Hansen, L Punecky, K Wilkinson. *UMMC, Jackson, MS*

10.1136/jim-2017-000697.253

Case report Cervical cancer is the third most common gynecologic cancer in the United States and human papillomavirus (HPV) is the etiologic agent of 99.7% of cases. The most common histologic type of cervical cancer is squamous cell carcinoma. Here we present a case of cervical cancer originally thought to be urothelial carcinoma with squamous differentiation given its immunohistochemical profile.

A 53 year old black female presented with progressively worsening back pain, anorexia, and a 40 pound weight loss. She had a history of stage 1B squamous cell carcinoma of the cervix treated definitively with neoadjuvant chemoradiation and hysterectomy. Computed tomography (CT) of the abdomen and pelvis revealed a large retroperitoneal mass that extended into multiple lumbar vertebra, with extensive osseous destruction and spinal canal involvement. The mass also invaded the psoas muscle and encased the inferior vena cava, aorta, and right ureter. Pathology from biopsy of the mass was thought to be consistent with high grade urothelial carcinoma with squamous differentiation given that p40, p63, CK 5/6, and GATA3 were positive, and PAX8 was negative. She was initially treated with 5-fluorouracil (5-FU), mitomycin-c, and radiation for stage IV urothelial carcinoma. However, due to her history of cervical cancer, we were concerned for recurrent disease. Subsequently, her pathologic specimen was stained for p16 and tested for *in situ* HPV. Both returned positive, supporting our suspicion. After further review of imaging and pathology, her tumour was felt to be consistent with recurrent cervical cancer rather than urothelial carcinoma. She will be treated with cisplatin, paclitaxel, and bevacizumab.

GATA3 is a transcription factor that is expressed in >90% of primary urothelial carcinomas; however, it is not specific. Squamous cell carcinoma of the cervix less commonly displays this marker with an estimated 33% expression. PAX8 is positive in 91% of cervical lesions, but was negative in this instance. Although the pathologic profile seen in this case is less common in cervical cancer, it highlights the importance of considering the overall clinical picture when making a diagnosis. Additionally, p16 positivity helped support the diagnosis of cervical cancer as it is an immunohistochemical marker strongly associated with high risk HPV subtypes.

254 CHOP-R IS AN EFFICIENT TREATMENT FOR PRIMARY DURAL DIFFUSE LARGE B-CELL LYMPHOMA (PD-DLBCL): A SYSTEMATIC REVIEW OF 45 CASES

K Zakharia*, ZL Quinn, L Yin, TC Brown, JJ Schmiege, H Safah, NS Saba. *Tulane University, New Orleans, LA*

10.1136/jim-2017-000697.254

Purpose of study PD-DLBCL is an aggressive lymphoma that affects the Dura mater, imitating other central nervous system tumours, and remains with unclear optimal management.

Methods used We conducted a retrospective review of the literature on pathologically confirmed PD-DLBCL and analysed data on biology, treatment outcomes, and survival.

Summary of results Out of 245 screened cases, 45 cases of PD-DLBCL were detected. 16 cases were intra-cranial and 29 were intra-spinal. Median age at diagnosis was 59 years. Incidence was nearly equal between women (22/45) and men. When tested, CD20 was positive in each instance (21/21). Using Hans criteria when possible to determine cell of origin, 3 cases were classified as ABC-DLBCL and 5 as GCB-DLBCL, confirming the representation of both subtypes in PD-DLBCL. All cases were stage IE and 6 of the 9 cases which provided Ki-67 data were less than 70%, reflecting an overall less aggressive behaviour. Survival data available from 40 cases showed an OS of 84% at 1 year, and 81% at 5 years, which compares favourably to PCNSL and matches early-stage DLBCL. Tumour location (intracranial vs intra-spinal) did not impact OS ($p=0.82$). Treatment was reported in 19 cases with available survival data. 11 patients received CHOP, 6 of which additionally received rituximab (CHOP-R). Eight patients received high-dose methotrexate (MTX)-based therapy. Interestingly, no difference in OS was observed between CHOP vs MTX-based therapy ($p=0.97$), suggesting that PD-DLBCL should be treated as DLBCL rather than PCNSL. Moreover, all patients who received CHOP-R remained disease free and alive. Radiation therapy was given often (25/29) in treatment of spinal disease, but rarely (4/16) when treating cranial disease, but did not impact OS.

Conclusions The good outcomes associated with CHOP-R eliminate the need for applying more toxic treatment regimens such as High-dose MTX or radiation therapy, and are consistent with the PD-DLBCL location outside the blood brain barrier.

Infectious disease, HIV, and AIDS

Joint plenary poster session and reception

4:30 PM

Thursday, February 22, 2018

255 OUTBREAK OF PENICILLIN-RESISTANT MENINGOCOCCEMIA IN RURAL APPALACHIA

S Albracht*, D Macariola, JW Schweitzer, DL Wood. *East Tennessee State University, Johnson City, TN*

10.1136/jim-2017-000697.255

Purpose of study In Spring 2017, multiple *N. meningitidis* cases erupted in rural Appalachia. *N. meningitidis* in the United States is typically penicillin-sensitive. It was hypothesised *N. meningitidis* isolated among paediatric patients in the Appalachian outbreak would be penicillin-sensitive and patients would have identical clinical presentations and CSF studies.

Methods used Data was compiled via qualitative retrospective case series. Inclusion criteria were age <18 years plus positive CSF studies, or presence of meningismus plus petechiae, fever, and antibiotic treatment prior to lumbar puncture. Three

Abstract 255 Table 1 Subject findings

	Patient A	Patient B	Patient C
Age	9 years	5 years	8 years
Fever	+	+	+
(temperature ≥ 100.4 °F)			
Headache	+	+	+
Emesis	+	+	+
Meningismus	+	+	+
Back tenderness	no	no	+
Difficulty ambulating	+	no	+
Subconjunctival	no	+	no
haemorrhage			
Skin findings	diffuse petechiae	diffuse petechiae with periobital concentration	diffuse petechiae with erythema
Pretreated CSF studies	no	no	+
CSF Culture	Negative	N. meningitidis resistant to benzylpenicillin	Negative
CSF PCR	N. meningitidis	Negative	Negative
Blood Culture	Negative	N. meningitidis resistant to benzylpenicillin	Negative

'+' indicates positive finding

subjects met inclusion criteria. Subjects received 7 day course of Ceftriaxone or Meropenem if Ceftriaxone-allergic.

Summary of results Table 1 presents subject findings. All subjects improved with treatment. Mortality rate was 0% with no sequelae to date.

Conclusions Although subjects had identical classic meningococcal symptoms (meningismus, fever, and petechiae), exact skin findings varied. CSF studies were not identical among subjects, even among those who did not receive pretreatment with antibiotics. Ceftriaxone and Meropenem adequately treated subjects. The penicillin-resistant *N. meningitidis* recovered in this small study and variety of subject findings did not support the original hypothesis. Health care providers in Appalachia should strongly consider non-penicillin therapy with future meningococcal outbreaks and recognise that not all cases may have identical findings.

256 MYCOPLASMA CEREBELLITIS WITH HYDROCEPHALUS

^{1,2}P Ameta, ^{1,2}VH Nayak, ^{1,2}JJ Burns. ¹Sacred Heart Children Hospital, Pensacola, FL; ²University of Florida, Pensacola, FL

10.1136/jim-2017-000697.256

Introduction CNS manifestations of mycoplasma pneumoniae occur in approximately 0.1 percent of all patients, which includes aseptic meningitis, encephalitis, cerebellar ataxia and cranial nerve palsies, this can be early onset or late onset.

Case 9 yo M with history of cough and fever (Tmax of 101F) for 2 weeks, was initially evaluated by PCR, where he was diagnosed with pneumonia and was prescribed 10 days of amoxicillin. His fever and cough resolved in 3–4 days, but a week later, he developed headache, in occipital region, moderate to severe in intensity associated with unsteady gait, poor appetite and non-bilious vomiting, 2–3/day. As he wasn't improving, mom brought him to the hospital. His initial labs were: CBC showed reactive thrombocytosis (plt-575,000), BMP was normal, RPP was positive for mycoplasma

pneumoniae, CT head – normal, CSF – 55 wbc with lymphocytic predominance, protein and glucose normal, enterovirus CSF PCR was negative, and chest x ray was negative.

He was admitted to floors with working diagnosis of aseptic meningitis. He continued to worsen even after a day of fluids and symptomatic management. He was requiring opioids every 1–2 hours for his headache. Hence, an MRI of his brain was obtained, which showed cerebellar oedema suggestive of cerebellitis with changes of early acute obstructive hydrocephalus. He was transferred to PICU and was started on high dose steroids (dexamethasone at 1 mg/kg) to decrease cerebellar oedema and azithromycin for 5 days. He showed dramatic improvement with in 24 hours. His steroids were tapered gradually and stopped prior to discharge.

Additional labs were obtained – CSF encephalitis panel including mycoplasma pneumonia was negative, CSF culture and blood culture were negative, serum IgM for mycoplasma was negative but serum IgG was positive.

Discussion Exact pathogenesis of neurological manifestations caused by mycoplasma is unknown. However, it is postulated that early onset is due to direct invasion and late onset is due to immune mediated process. In our patient, latency between respiratory and neurological symptoms, lack of any other aetiology, absence of mycoplasma in CSF, and with positive mycoplasma in RPP led to the conclusion that he might have had late onset CNS disease due to mycoplasma.

257 A DELETERIOUS COMBINATION OF INTRAVENOUS DRUG USAGE WITH A CHRONIC VIRAL INFECTION; HOW RENAL REPLACEMENT THERAPY EMANATED?

^{1,2}C Castillo Latorre. ¹San Juan City Hospital, San Juan; ²Centro Medico De Puerto Rico, San Juan

10.1136/jim-2017-000697.257

Purpose of study Intravenous drug usage of substances like cocaine and heroin; encompasses a spectrum of generalised state of illness. A continuum insult which predispose patients to chronic viral illnesses, bacterial infections and subsequently end organ damage due to multiple factors. The renal structure is one of the target organs involved in this process, by which a majority of them will lately developed end stage renal disease and as a result renal replacement therapy. However, the spectrum of complications of this population is enormous starting with acquire infections like HIV, Hepatitis C, Hepatitis B, severe skin infections, pneumonia, cardiovascular diseases, endovascular complications as the well known Lemierre's syndrome, central nervous system infections, systemic complications like renal failure ending up in hemodialysis and most of them with a low expectancy of life. Our purpose was mainly in finding most common conditions associated with intravenous drug usage and compared them.

Methods used Electronic medical record was used to reach patients with documented to be active intravenous drug users. Of the patients been study the admission diagnosis that lead to renal replacement therapy was recorded, and later in the process compared.

Summary of results Our population of 69 patients, 16 of them ended up in hemodialysis 23% (16/69), of this patients that had renal replacement therapy 4 of them had Hepatitis C 25% (4/16), Hepatitis B 19% (3/16), HIV 13% (2/16), Hypertension 6% (1/16) and Diabetes mellitus 6% (1/16)

respectively. There were several precise findings that lead to hemodialysis in the population, with the majority been infected ulcers 25% (17/69), multilobar pneumonia 20% (14/69), upper gastrointestinal bleeding in 10% (7/69) and symptomatic anaemia 10% (7/69) respectively. All of this patients did not had good social support, none of them knew about the long term consequences of renal failure and most of them did not had positive approach of stopping drug usage.

Conclusions As a whole, illicit intravenous drug usage is associated with a broad spectrum of diseases, all of them creating a rapid deleterious clinical picture; mostly debuting to medical assistance with an infectious aetiology and almost 25% will require lifelong hemodialysis.

258 INTRACRANIAL HYPERTENSION SECONDARY TO EOSINOPHILIC MENINGITIS BY ANGIOSTRONGYLUS CANTONENSIS

RA Cruz*, C Smith, AB Ramos, BJ Copeland, PS Seal. *LSUHSC, New Orleans, LA*

10.1136/jim-2017-000697.258

Purpose of study Increase awareness to practitioners about A. Cantonensis in patients with eosinophilia specially if patients have exposure history, or have recently travel to endemic areas now including Louisiana, Texas, or Florida.

Methods used Single case report.

Summary of results Angiostrongylus Cantonensis, a nematode, is a well-known cause of eosinophilic meningitis in endemic areas such as Southeast Asia, the Pacific Islands, and Hawaii. Nevertheless, an increasing number of cases in the southeast of the United States have been documented recently, specifically in Louisiana, Texas, and Florida. Infection is acquired after the undercooked fresh water snails, mollusks, or undercooked vegetables contaminated by the slime from infected snails or slugs. Typical signs and symptoms include fever, general malaise, meningeal signs, headaches, photophobia, nausea and vomiting. Here we present a 23 year-old female that presented to our emergency department with signs and symptoms consistent with intracranial hypertension, malaise, mild photophobia, and without fever, or meningeal signs.

Conclusions Angiostrongylus Cantonensis, is the most common cause of eosinophilic meningitis, presentation can be atypical including intracranial hypertension signs and symptoms without significant meningeal signs. It is important for practitioners to consider A. Cantonensis in patients with suspected intracranial hypertensions, or meningitis if eosinophilia is present. Diagnosis is made with PCR for A. Cantonensis. The treatment is focus on decreasing intracranial pressure, and corticosteroids to reduce meningeal inflammation. Anti-helminthics are not recommended as they can induce a larger immune response and therefore worsen the symptoms.

259 CHYLOUS ASCITES IN INTRA-ABDOMINAL MYCOBACTERIUM AVIUM COMPLEX IMMUNE RECONSTITUTION INFLAMMATORY SYNDROME

R Dean*, R Subedi, A Karkee. *Upstate Medical University, Liverpool, NY*

10.1136/jim-2017-000697.259

Case report Chylous ascites, a rare form of ascites, is defined as leakage of lipid-rich lymph into the peritoneal cavity. It has

been described very rarely in HIV/AIDS patients related to intra-abdominal Mycobacterium avium complex immune reconstitution inflammatory syndrome (MAC-IRIS). We present a 51 year old male with a history of AIDS and a colonic MAC infection that presented with abdominal distension and chylous ascites.

A 51 year old male with a history of AIDS and colonic MAC infection presented for abdominal distention. One year prior, he had been diagnosed with colonic MAC on biopsy and at the same time, with AIDS, and had an initial CD4 count of 9 cells/ μ L. He was started on HAART therapy with ritonavir, darunavir, lamivudine and efavirenz as well as levofloxacin, ethambutol and rifampin for treatment of his MAC infection. His CD4 count increased to 150 cells/ μ L and undetectable viral load at the time of presentation. Physical examination showed abdominal distention with tense ascites. A paracentesis removed 9050 mL milky white ascitic fluid. Fluid analysis showed a triglyceride level of 1487 mg/dL with a high lymphocyte count. Analysis revealed no signs of infection or malignancy. There was no history of trauma or signs of cardiac or autoimmune causes. The patient was continued on his MAC and HAART medications, as well as intermittent therapeutic paracenteses.

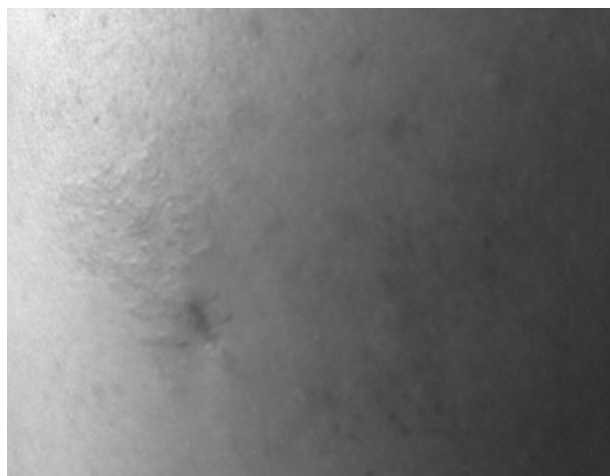Chylous ascites is rare in HIV/AIDS patients and its association with MAC-IRIS has been rarely reported. The diagnosis is made by fluid analysis, which shows a milky white ascitic fluid with triglyceride levels greater than 110 mL/dL and a high leukocyte count with a mononuclear predominance. The etiologies include neoplastic, congenital, acquired cardiac or gastrointestinal causes, inflammatory causes, and most commonly manipulation of lymph drainage in surgery or trauma. Infectious causes from tuberculosis and MAC in HIV patients have been described, though rarely in MAC infected patients as a result of IRIS. It is caused by well-formed granulomas in the lymphatics. Because granuloma formation is dependent on CD4 cells to stimulate macrophages, it is not until the patient demonstrates increasing CD4 counts in IRIS that we see chylous ascites, making it a late complication of disseminated MAC infections.

260 CHRONIC TREATMENT OF CUTANEOUS CHROMOBLASTOMYCOSIS IN A PAEDIATRIC PATIENT

VC Diaz Vidal*, A Mirza. *University of Florida College of Medicine Jacksonville, Jacksonville, FL*

10.1136/jim-2017-000697.260

Case report Chromoblastomycosis is a chronic fungal infection which typically affects the skin and subcutaneous tissue. It can be found normally in the environment, in soil, wood and decaying material. Chromoblastomycosis can be due to several organisms from the dematiaceous group of fungi, with Phialophora verrucosa, Cladosporium carrionii, and Fonsecaea species, among the most common. Infection is usually due to traumatic inoculation of the organism and generally presents as papillomatous, verrucous or vegetative lesions. Chromoblastomycosis is one of the most difficult mycotic infections to eradicate, despite multiple treatment options which include prolonged courses of oral antifungals, surgical removal, and destructive physical therapies. It occurs more commonly in tropical and sub-tropical areas, but world-wide cases have been reported. We present the case of a 13-year-old female



Abstract 260 Figure 1 Facial lesion after being on oral terbinafine for 5 months

with cutaneous chromoblastomycosis, who presented initially with an erythematous pinpoint lesion on her left cheek back in 2014. She was started on oral antifungals of which itraconazole proved to be successful. She has been on oral itraconazole for 13 months or so, with marked improvement in size and contour of the lesion, proving that proper compliance, follow-up and anticipatory guidance are key in the treatment of chronic infections.

261 HHV-6 CNS INFECTION IN A YOUNG INFANT

^{1,2}ML Dietrich, ³A White, ¹J Schieffelin, ⁴K Queen. ¹Tulane Hospital for Children, New Orleans, LA; ²Ochsner Hospital for Children, New Orleans, LA; ³Tulane School of Medicine, New Orleans, LA; ⁴Lakeview Regional Medical Centre, Covington, LA

10.1136/jim-2017-000697.261

Case report This case presentation will review the course and treatment of an infant with the rare finding of HHV-6 CNS infection, the current literature available on the subject, as well as touch on the increasing challenges we may face in clinical decision making as more advanced and rapid diagnostics are becoming available. H is a 25 day old baby boy, previously healthy, who presented with 1 day of fever and runny nose. Full sepsis work-up was initiated, and meningitis/encephalitis PCR panel of the CSF demonstrated Human Herpesvirus-6 (HHV-6). Initial symptoms included an episode of apnea and bradycardia in the emergency room, and a possible staring spell on day two. MRI demonstrated small non-specific area of restriction. On day two HHV-6 quantitative serum PCR was sent and resulted with 12 000 copies per mL of virus. He was treated with intravenous ganciclovir for 14 days without incident. Repeat HHV-6 quantitative serum PCR demonstrated presence of virus, but too low to quantify, and confirmed HHV-6 subtype B. HHV-6 is a common infection in young children presenting with rash and fever, coined roseola infantum. While this illness is well described, the CNS manifestations of the virus are less well understood. With the fairly recent advent of the widespread use of rapid, sensitive diagnostics presumably diagnosis of this infection in the CNS will

become a more common occurrence. The literature on CNS HHV-6 is for the most part limited to severely immunosuppressed patients, as well as those presenting with obvious signs and symptoms consistent with encephalitis. Efficacy of ganciclovir is limited to demonstration of decrease in viral load, without paired controls. There also exists chromosomal integration of HHV-6 in the gametes, which can be passed to offspring, which occurs in an estimated 0.2% to 0.8% of births. A better understanding of the significance of the presence of the virus in CSF is needed in order to dictate treatment and prognosis for the febrile, immunocompetent infant in whom this virus is identified in the CSF.

262 NOCARDIOSIS EXACERBATED BY IMMUNE RECONSTITUTION INFLAMMATORY SYNDROME

J Doan*, L Damioli, R Lillis. LSUHSC, New Orleans, LA

10.1136/jim-2017-000697.262

Case report A 62 year old woman with past medical history of HIV/AIDS with CD4 48/mm³ and noncompliance with combination antiretroviral therapy (cART) was admitted to an outside hospital 2 months prior and diagnosed with cavitary *Nocardia farcinica* pneumonia. She was treated with imipenem and amikacin, but developed a morbilliform drug eruption concerning for DRESS; dermatology determined that the rash was more likely secondary to imipenem. Her treatment was discontinued after only twelve days of imipenem and seven days of amikacin. Repeat CT chest showed a new cavitary lesion in the right upper lobe of the lung. She was discharged with oral trimethoprim/sulfamethoxazole (TMP-SMX). She followed up with her HIV provider and was started on cART, which she took consistently. She felt well until the following month when she suffered two tonic-clonic seizures and left sided weakness. She denied diplopia, headache, nausea or vomiting. CT brain scan demonstrated a right frontal lobe ring enhancing mass consistent with a brain abscess. She was started on amikacin, moxifloxacin and TMP-SMX with improvement of weakness. She was continued on cART with significant increase in CD4 T-cell count from 48 to 92/mm³ and decrease of viral load from 1 95 128 to 1955 copies/mL. A MRI brain was later repeated with increased size of the brain abscess and vasogenic oedema. She was transferred for evacuation of the abscess. Gram stain from the brain abscess grew filamentous, branching, beaded gram positive rods that were modified acid fast positive that speciated as *Nocardia farcinica*. She was treated with six weeks of induction with TMP-SMX and amikacin followed by oral treatment with TMP-SMX and minocycline for at least one year given her HIV/AIDS status. cART was held due to concern for immune reconstitution inflammatory syndrome (IRIS) with plans to resume based on continued radiologic improvement.

Discussion Pulmonary Nocardiosis with neurological deficits should prompt evaluation for CNS involvement. Perhaps, early initiation of cART along with inadequate treatment of pulmonary Nocardia resulted in 'unmasking' her brain abscess consistent with IRIS, a paradoxical inflammatory response that may result when a patient with HIV/AIDS has regained an immune response.

263 ENLARGED THYROID-NEITHER A GOITRE NOR A NODULE OR A TUMOUR

PK Errabelli*. *UAMS, Little Rock, AR*

10.1136/jim-2017-000697.263

Case report A 26 y/o male without significant PMH presented with nausea, vomiting, diarrhoea and decreased urine output for several days. He also complained of a diffuse neck swelling 1 day before presentation. He denied fever, chills, cough, dysuria, sick contacts, recent travel, and tick/bug bites. He was afebrile with stable vital signs. On examination he had B/L thyroid enlargement with tenderness (R>L) and axillary lymphadenopathy. Labs revealed, WBC 12.5, Hb 9.4, Hct 28.2, platelets 143, Na 125, K 3.9, BUN 136, Cr 21, Phos 7.9, AG 18, glucose 104, LDH 1030. The patient was admitted for work-up. He was found to be HIV positive on a screening test. CT showed cardiomegaly w/small/mod pericardial effusion, enlarged kidneys w/perinephric stranding compatible with renal failure, lymphadenopathy, and soft tissue masses w/in lower anterior neck, mildly dilated proximal descending aorta of 3.6 cm.

CD4 count of 113 and HIV RNA copies 4 73 536. Work-up for other sexually transmitted infections was negative. Dialysis was required for the poor kidney[KN1] function(AKI). USG revealed B/L enlarged kidneys with increased cortical echogenicity suggestive of medical renal disease. Kidney biopsy was suggestive of HIVAN (HIV associated nephropathy). Blood culture grew E.coli. The same organism was also isolated from his thyroid aspirate sample which showed suppurative thyroiditis. The thyroid pain and swelling improved on treatment with IV antibiotics and a 2 week course was completed. He is being discharged on PO antibiotics in the appropriate renal dose. He remained dialysis-dependent at discharge. ID f/u for starting HAART as outpatient was suggested at discharge.

We present a rare case of acute infective thyroiditis with E Coli. There are only few case reports in literature.

264 UNUSUAL OPPORTUNISTIC CO-INFECTIONS IN AIDS PATIENT

LO Gerena Montano*, MA Farinacci Vilaro. *San Juan City Hospital, San Juan, PR*

10.1136/jim-2017-000697.264

Case report Mucormycosis is an opportunistic fungal infection, 3 genera are known to be human pathogens, Rhizopus, Absidia and Mucor. The incidence is 1.7 per million people per year in the USA. This infection occurs due to the inhalation of fungi spores and results in the rapid progression of pneumonia or endo-bronchial disease and is most common on immunocompromised patient with neutropenia and malignancy.

Mycobacterium avium complex (MAC) is most commonly observed in AIDS patients with a CD4 <50. One survey estimated that 3000 cases of MAC pulmonary disease occurred annual in the USA in the early 1980s.

We present the case of a 53-year-old male with PMHx of HIV not on antiretroviral therapy, crack smoker, former jail convict who presented to ER complaining of general malaise, chills, productive cough, yellow sputum, and SOB of 3 days duration and a previous admission with pneumonia 1 month

prior. Physical exam was relevant for: cachectic appearance and bilateral ronchi on lung auscultation. ABGs with hypoxemia and metabolic acidosis +respiratory alkalosis; chest CT with left upper lobe cavitation, nodular opacities on both lower lobes and right upper lobe, bilateral ground glass infiltrates and left sided pleural effusion. Patient was placed on airborne respiratory isolation; started on IV antibiotic therapy for hospital acquired pneumonia (HAP) and Pneumocystis carinii pneumonia (PCP). In view of patient's clinical deterioration and persistent hypoxemia, sputum samples were sent for cytology and stain which results came back positive for Mucor sp. Also Acid Fast Bacilli stain and PCR samples results were negative for TB but positive for MAC in 2 different samples. PPD was negative.

Pulmonary mucormycosis is a rapidly progressive infection that can spread to contiguous structures or disseminate hematogenously with a mortality of 87%. Widely disseminated mucormycosis have a mortality rate of 90%–100%. MAC has a 5 year mortality of approximately 18%. There is no documented pulmonary co-infection with both Mucor and MAC. Due to the aggressiveness of this conditions and high mortality rate in which patient survival is dependent on an early diagnosis, physicians should be aware of this entity and the possibility of a co-infection in an AIDS patient.

265 IS IT A MOLE? THINK AGAIN!

¹MF Habib*, ²D Zheng, ¹A Islam, ¹T Naguib. ¹Texas Tech Univ HSC Amarillo, Amarillo, TX; ²University of Texas at Houston, Houston, TX

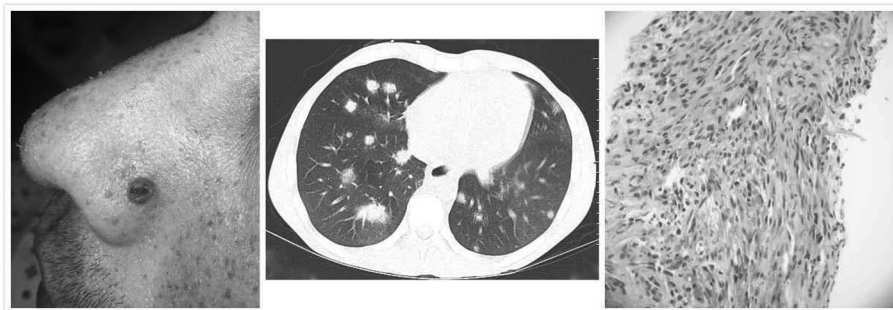
10.1136/jim-2017-000697.265

Introduction Kaposi's Sarcoma (KS) is an AIDS defining malignancy in HIV-positive patients associated with HHV-8 co-infection. The incidence of KS has declined drastically since the use of highly active antiretroviral therapy (HAART). Cutaneous involvement is most common but it can also affect visceral organs. In present-day, pulmonary KS is a rare finding. However, high clinical suspicion with prompt diagnosis and treatment can lead to improved prognosis and outcome.

Case report 36 y.o. HIV positive male not on HAART therapy presented with a 2 months history of SOB. He was diagnosed with HIV 8 years ago and KS of left nose 7 months ago. CD4 count was 32 and viral load was 1480. Chest X-ray and CT scan of the lung showed bilateral infiltrates, lung biopsy confirmed Pulmonary KS. Patient was started on chemotherapy and HAART.

Discussion Pulmonary KS is seen in low CD4 count patients. The clinical features are non-specific; hence, making the diagnosis indistinguishable from other opportunistic infections involving the lungs. Diagnosis is often based on clinical presentation, imaging studies, and findings on bronchoscopy; lung biopsies are often needed. Histology shows angiogenesis and spindle cells proliferation. Immunohistology: CD31, CD34, and HHV-8 latent nuclear antigen –1. HAART is associated with improvement/resolution of pulmonary symptoms and increased survival time. In more advanced cases, chemotherapy plus HAART is associated with significant reduction in disease progression than HAART alone.

Conclusion With the advent of HAART and decline of incidence over the past 2 decades, young physicians may lack the necessary exposure to suspect pulmonary KS. We suggest, keeping a high clinical suspicion for pulmonary KS, early



Abstract 265 Figure 1 Lesion on the nose, CT scan and lung biopsy

initiation of HAART with proper patient education regarding disease progression and management would lead to better prognosis and outcomes.

266 **STREPTOCOCCUS CONSTELLATUS CAUSING SOFT TISSUE NECROSIS SURROUNDING THE TRACHEA IN AN IMMUNOCOMPROMISED PATIENT**

J Norsworthy, M Hess*. *SUNY Upstate, Syracuse, NY*

10.1136/jim-2017-000697.266

Case report *Streptococcus constellatus* is a member of the *Streptococcus milleri* group, and this family of bacteria is particularly known to cause pyogenic infections in the oral cavity, as well as the head, neck and abdomen. Complications of pyogenic head and neck infections include mediastinitis, airway obstruction and septic shock. We describe an uncommon case of *S. constellatus* phlegmon formation resulting in soft tissue necrosis surrounding the trachea.

A 50 year-old male with a history of a tracheostomy secondary to metastatic small cell thyroid cancer presented in septic shock with tenderness and erythema adjacent to his tracheostomy site. He also reported foul smelling drainage that had been ongoing for several weeks. One week prior to presentation, he was started on a new chemotherapy regimen and subsequently was found to have severe neutropenia. A CT scan of the neck demonstrated a defect with multiple foci of air in the anterior soft tissues overlying the right proximal clavicle extending into the superior aspect of the mediastinum, as well as an ill-defined hypodensity and multiple foci of air within the infra-glottic posterior pharyngeal space causing severe narrowing of the subglottic airway. The patient was taken for immediate surgical debridement and a 7 by 2 cm area of necrotic tissue was debrided. The infection was found to have formed a tract communicating with the tracheostomy stoma. His tracheostomy tube was exchanged. Intraoperative wound cultures grew *Streptococcus constellatus*. The patient did not require further debridement and after several days was discharged on long term antibiotics.

S. constellatus is a known pyogenic pathogen and has been implicated in severe head and neck soft tissue infections. It is important to recognise and treat these infections as they can cause rapid clinical deterioration, especially in immunocompromised patients. Our patient had a favourable outcome because of early diagnosis, surgical intervention, airway stabilisation and antibiotic therapy.

267 **AN UNUSUAL CASE OF *BRACHYSPIRA* DIARRHOEA IN AN IMMUNOCOMPETENT ADULT DURING MIDDLE EAST DEPLOYMENT**

^{1,2*}L Hoang, ^{1,2}A Minocha, ¹M Constantinescu, ^{1,2}V Mekala, ^{1,2}R Washburn. ¹Louisiana State University Health Sciences Centre, Shreveport, LA; ²Overton Brooks VA Medical Centre, Shreveport, LA

10.1136/jim-2017-000697.267

Background *Brachyspira aalborgi* and *B. pilosicoli* are nontreponemal spirochetes capable of causing persistent diarrhoea in paediatric patients and individuals with HIV infection. Otherwise these spirochetes are usually asymptomatic and do not require treatment. Carriage rates are high in developing countries including those in the Middle East (11%–64%) but lower in developed countries (1%–5%). We now report an unusual case of chronic *Brachyspira* diarrhoea in an immunocompetent adult.

Case report A previously healthy 33 year old Caucasian male presented with eight years of chronic epigastric and lower abdominal discomfort that began during deployment to the Middle East, associated with bloating, gas, diarrhoea, fatigue, and an involuntary seventy pound weight loss. Physical examination was normal and noninvasive gastrointestinal evaluation was negative, but colonoscopy revealed multiple nodules. Mucosal biopsies showed lymphoid aggregates, and spirochetes were visualised by Steiner and periodic acid Schiff stains as well as immunohistochemistry. Rapid plasma reagin and HIV testing were negative.

Clinical course Treatment with metronidazole 500 mg by mouth thrice daily for ten days led to complete resolution of all previous gastrointestinal symptoms and restoration of normal energy levels.

Discussion Onset of symptoms during Middle East deployment suggested that *Brachyspira* exposure occurred in that region. This case highlights (1) the importance of performing mucosal biopsies for evaluation of chronic unexplained diarrhoea followed by special stains when morphologically indicated, and (2) the efficacy of metronidazole in treating *Brachyspira* diarrhoea.

268 **ROTHIA MUCILAGINOSA NATIVE TRICUSPID VALVE ENDOCARDITIS IN A NEUTROPENIC PATIENT**

M Ibrahim*, J Yorke. *Quillen College of Medicine/ETSU, Johnson City, TN*

10.1136/jim-2017-000697.268

Introduction *Rothia mucilaginosa*, while long known to be of a low virulence,¹ is being reported here as the culprit of native tricuspid valve endocarditis in a patient with a dental abscess. To the best of our knowledge, this is the first case report of right² sided native valve endocarditis caused by *Rothia*.

Case presentation A 31-year-old female patient with history of sarcoidosis, treatment-naïve hepatitis C, and remote intravenous drug abuse (IVDA) presented to the emergency department with progressive right-sided back pain of 4 days' duration. Intermittent right sided toothache, palpitations, shortness of breath, and fatigue were also reported for the last 2–3 months. Physical exam revealed a septic, cachectic, very pale patient in moderate pain and respiratory distress. Labs revealed pancytopenia with mild neutropenia, microcytic anaemia with a haemoglobin of 4.0 g/dl, iron saturation of 3%, and two out of two blood cultures positive for *Rothia mucilaginosa*. X-ray of the right mandible revealed an apical abscess. Chest x-ray revealed right middle and lower lobes consolidation with an associated effusion. Coronal tomography exam of the chest, abdomen, and pelvis revealed massive hepatosplenomegaly, pancreatic atrophy, diffuse soft tissue oedema, and signs of portal hypertension but no emboli to the lungs. Echocardiography revealed moderate right sided heart failure with tricuspid valve mobile density consistent with vegetation 1.4×0.9 centimetre in size. The patient continued to do better after the thoracentesis, starting her on iron therapy, and continuing intravenous vancomycin. The haematology service was consulted for her pancytopenia who emphasised the likelihood of her hypersplenism besides iron deficiency being the culprits of her pancytopenia and that bone marrow exam seemed unnecessary at that time.

Summary *Rothia mucilaginosa* continues to emerge as an opportunistic organism of variable virulence in neutropenic patients. The full potential of this organism is yet to be identified. However, this case adds right sided, native valve endocarditis to its potential in the medical literature.

REFERENCES

1. *J Clin Microbiol* May 2013;51(5):1629–1632. doi:10.1128/JCM.03173-12
2. *J Clin Microbiol* September 2014;52(9):3184–3189. doi:10.1128/JCM.01270-14

269

NOT EVERYTHING THAT VOMITS IS REFLUX, AN ATYPICAL PRESENTATION OF AN ATYPICAL INFECTION IN A NEONATE

*SR Induru, C Poole. *University of Alabama, Birmingham, AL*

10.1136/jim-2017-000697.269

Case report We present the case of a 1 month old female with three weeks of worsening emesis. This patient was born full-term by vaginal delivery with an uncomplicated pregnancy and delivery. All antenatal testing including Group B streptococcus were negative. Baby developed emesis around a week of life which increased in frequency and forcefulness. She had an ultrasound at 2 weeks old which excluded pyloric stenosis. Parents were given feeding recommendations for reflux. She however became more difficult to feed and her weight gain was suboptimal, falling from the 50th percentile to the 5th percentile while length and head circumference remained in the 75th and 65th percentiles. On the day of presentation to our ER, parents noted some blood in the emesis together with 10 min episode of rhythmic jerking movements of her

upper extremities en route to the ER. She had remained afebrile throughout. On arrival to the ER her vital signs were T 98.3 F, heart rate 159 bpm, BP 99/65, respiratory rate 23, but she was noted to have a bulging anterior fontanelle.

Clinical course and management

Given her neurologic findings she had an emergent non-contrasted head CT revealing holovertriculomegaly and a subsequent emergent MRI showing communicating hydrocephalus. The patient emergently had an EVD placed by Neurosurgery with CSF studies revealing profound leukocytosis, elevated protein and low glucose consistent with bacterial meningitis and gram stain positive for gram-positive cocci CSF cultures grew *Streptococcus infantarius*, a bacterium from the *S. Bovis* family.

Discussion The pathways of care of infants failed to pick up this patient's presentation of a serious infection. Although benign reflux is common in infants, failure to thrive would warrant further work-up. *Streptococcus infantarius* has rarely been described as a cause of neonatal sepsis and to our knowledge this is the first case presenting with hydrocephalus. We report this case to identify not only an atypical pathogen, *S. infantarius*, but also to highlight the importance of maintaining high clinical suspicion of infection in infants even without presentation of fever.

270

VANCOMYCIN AND LINEAR IGA BULLOUS DERMATOSIS

A Ismail*, RE Gavidia Quezada, K Iwuji, M Tarbox. *TTUHSC, Lubbock, TX*

10.1136/jim-2017-000697.270

Case report A 56-year-old man presented to the hospital complaining of generalised skin rash with blisters. He has a medical history of alcoholic cirrhosis with pancytopenia, chronic pancreatitis and chronic osteomyelitis. Prior to this presentation, he was admitted for osteomyelitis of his left arm. He had a hardware removed from his arm and was discharged 3 days prior to his presentation on intravenous vancomycin, oral ciprofloxacin and metronidazole. Initially, he developed an itchy purpuric rash on his trunk. The rash progressed rapidly to involve his extremities, back, lips, and tongue. Dermatology was consulted and a skin biopsy was done. The biopsy showed sub-epidermal blister with neutrophils and eosinophils. Immunofluorescence showed linear IgA and IgG deposition at the dermal/epidermal junction. Dermatology recommended supportive treatment. He also had acute on chronic thrombocytopenia not responding to transfusion. Haematology was consulted and he was treated for immune thrombocytopenic purpura with one dose of 85 g of Intravenous immunoglobulin and 100 mg of prednisone, followed by 40 mg of prednisone daily over the next 3 days. His platelet count improved to his baseline after 1 unit of platelets. The patient was hospitalised for a week and his skin lesions continued to improve daily. It is unclear how the IVIG and prednisone altered the course of his skin disease. He was re-admitted at our hospital 2 months later and his skin findings had completely resolved.

LABD is a sub-epidermal bullous disease defined by the presence of homogeneous linear deposits of IgA at the dermal-epidermal basement membrane on direct immunofluorescence. Histologically, it is characterised by sub-epidermal bullae with a predominantly neutrophilic infiltrate and basal cell vacuolization. Patients with drug induced LABD have spontaneous resolution of skin lesions within 1 to 3 weeks

after removal of offending agent. They will need supportive care including pain control, fluid and electrolyte management, and nutritional support. After the vancomycin is discontinued, the patient should have prompt improvement without residual skin lesions. If patients are re-challenged with vancomycin, they may have a more severe recurrence, including a shorter latency and a longer course.

271 AN UNUSUAL 'BLACK EYE' AND SHORTNESS OF BREATH IN A 27 YEARS OLD MALE

K Iwuji*, D Payne, S Thakolwiboon. *Texas Tech University Health Science Centre School of Medicine, Lubbock, TX*

10.1136/jim-2017-000697.271

Purpose of study To describe a unique presentation of Kaposi Sarcoma in a newly diagnosed HIV/AIDS patient.

Methods used Clinical observation and physical examination.

Summary of results Acute human immunodeficiency virus infection may present with constellation of nonspecific symptoms which can sometimes be missed by clinicians. An estimated 10% to 60% of individuals with new HIV infection will not experience any symptoms¹. Some patients diagnosed with HIV infection already have evidence of AIDS defining illnesses (e.g. Kaposi sarcoma, Lymphoma, mycobacterium infection, pneumocystis jirovecii and others) at the time of diagnosis as seen in the images of this patient with disseminated kaposi sarcoma. Despite occasional late presentation at the time of diagnosis, patients with no other commodities who are treated appropriately and are compliant with their antiretroviral medications are expected to have same life expectancy as the general population.

Case A 27-year-old male presented to a hospital with a one month history of black eye and shortness of breath. He had recently been released from jail where he had experienced progressive shortness of breath and fatigue. His black eye had appeared near the same time and patient related it to recent dental work. Examination revealed an oval shaped lesion 3 cm in length below the right eye (Panel A) with multiple similar lesions on the chest back and lower extremities. Intraoral examination revealed violaceous non-blanching plaque along hard and soft pallet (Panel B). Biopsy of skin lesions revealed atypical vascular proliferation consistent with nodular Kaposi's sarcoma. Computed tomography of the chest showed multifocal airspace disease suspicious for Pneumocystis Jirovecii pneumonia versus Kaposi's sarcoma. HIV screening returned positive with a CD4 count of 41/MCL. He was started on treatment for Pneumocystis Jirovocii and anti-retroviral therapy. He tolerated therapy well and continues to follow in the outpatient HIV clinic.

Conclusions The diagnosis of acute HIV infection requires a high level of clinical suspicion, detail history and physical examination.

272 A RARE CASE OF VARICELLA ZOSTER MENINGITIS

R Kamat*, R Helm, E Machen, LS Engel, S Sanne. *LSU Health Sciences Centre, New Orleans, LA*

10.1136/jim-2017-000697.272

Introduction Aseptic meningitis can have various etiologies, although viruses remain the most common cause. Historical clues, seasonality, and regional variation can be helpful in narrowing down the specific viral pathogen.

Case A 54-year-old man with a past medical history of hypertension, type 2 diabetes, cervical stenosis and hyperlipidemia presented to the Emergency department with complaints of headache, nuchal rigidity, and shoulder pain for the past three days. The patient has chronic neck pain from his stenosis, but he felt that this nuchal rigidity differed from his previous pain crises. He also described intermittent subjective fever, chills, and nausea. One week prior to presentation he developed vesicular lesions on the right C4-C5 dermatome distribution on his shoulder, but he believed they were insect bites from being outside while gardening. He denied any previous history of chicken pox, but admits he may have had it as a child. Following a lumbar puncture, he was started on broad spectrum antibiotics and acyclovir to empirically treat bacterial meningitis and HSV encephalitis. He had an unremarkable CT scan of the head. CSF studies showed WBC count of 121 cells/mm³ with 94% lymphocytes, glucose of 90 mg/dL, and protein of 104.2 mg/dL. Gram stain at that time was negative. MRI of brain was obtained to rule out temporal involvement, and based on CSF data antibiotics were discontinued. PCR studied of CSF eventually returned positive for varicella zoster virus, and the patient was discharged on a two-week course of acyclovir.

Discussion In this patient, empiric therapy for both bacterial meningitis and HSV encephalitis was initiated at the time of initial exam after obtaining CSF and blood cultures. After CSF studies showed a relatively low white count with lymphocyte predominance, treatment was de-escalated to acyclovir alone. Careful physical examination, history taking and proper diagnostic testing helped identify a clear cause and treatment course for this patient's VZV meningitis.

273 SPLENIC ABSCESS IN PAEDIATRIC PATIENT

¹CS Keith*, ²C Trieu, ¹S Srialluri, ¹S Boppana. ¹*Children's of Alabama, Birmingham, AL;* ²*Mercer School of Medicine, Macon, GA*

10.1136/jim-2017-000697.273

Introduction Splenic abscesses are uncommon in children with a reported incidence of 0.03%–0.7%. The diagnosis is not frequently considered due to its rarity and lack of specific clinical findings. The most common findings include fever, splenomegaly and left upper quadrant pain.

Case presentation A 14 yo previously healthy male presented to an outside hospital (OSH) with 10 days of fever and abdominal pain. A CT scan showed a complex splenic laceration with large hematoma and possible abscess. The patient denied trauma. He was admitted and started on piperacillin-tazobactam prior to transfer to our institution.

On physical exam he had splenomegaly with tenderness in the left upper quadrant. He had a WBC of 21.74 with 84% neutrophils and an elevated CRP (21.02 mg/dl). Paediatric radiology read his abdominal CT as a 16 cm × 14 cm × 16 cm fluid collection in the spleen. Ultrasound showed a large complex cystic mass.

Patient underwent a laproscopic-assisted drainage of the abscess. Cultures grew methicillin susceptible staphylococcus aureus. He was treated with nafcillin but the abscess persisted

requiring 3 additional drainage procedures. He ultimately required splenectomy.

Immunology work up revealed an abnormal neutrophil respiratory burst assay concerning for autosomal recessive chronic granulomatous disease. Genetic evaluation is pending.

Discussion Splenic abscesses are uncommon in paediatrics. Predisposing factors include metastatic or contiguous infection, haematological disorders, trauma or immunodeficiency. A retrospective review of data at our institution from 04/2007–03/2017 showed three other cases of splenic abscess in which contiguous infection was the cause. The clinical features of splenic abscesses include fever, localised or diffuse abdominal pain and splenomegaly. Ultrasound shows hypoechoic or anechoic lesions in the spleen and additional imaging such as CT or MRI may be needed. The most common organisms are gram-positive cocci. Splenectomy is usually required but conservative drainage procedures can be effective.

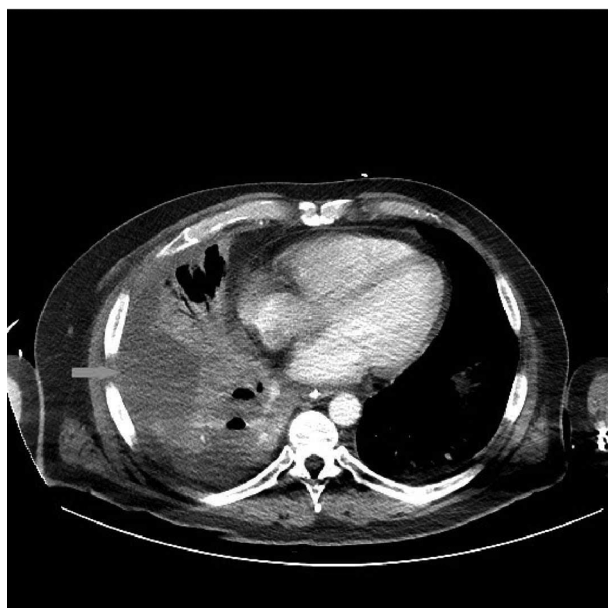Conclusion Splenic abscesses are incredibly rare in paediatrics. It is important to investigate for predisposing factors, especially immunodeficiency, if no other source is found. Although splenectomy may be required, it is prudent to try percutaneous drainage first.

274 RESPIRATORY FAILURE DUE TO PERSISTENT THORACIC FUNGAL EMPYEMA

M Khalid*, ES Josan, A Mahajan, R Akella, W Shams. *East Tennessee State University, Johnson City, TN*

10.1136/jim-2017-000697.274

Case report 48-year-old male with poorly controlled insulin dependent diabetes mellitus was admitted with septic shock due to pneumonia. He was intubated for acute respiratory failure. Respiratory cultures obtained by bronchoscopy grew *Candida dubliniensis* and *Escherichia coli*, which were treated with Micafungin and Ceftriaxone. A thoracentesis revealed an exudative pleural effusion with lactate dehydrogenase >1800



Abstract 274 Figure 1 Right sided pleural effusion with air-fluid level (blue arrow)

U and culture grew the previous organisms as well. A pig tail catheter was inserted and alteplase was administered due to persistence of emphysematous pleural effusion on follow up imaging which led to adequate drainage. The patient failed weaning trials on multiple occasions due to excessive respiratory secretions with persistent lung pathology. He underwent right thoroscopic lung de-cortication and eventually tracheostomy placement for prolonged weaning.

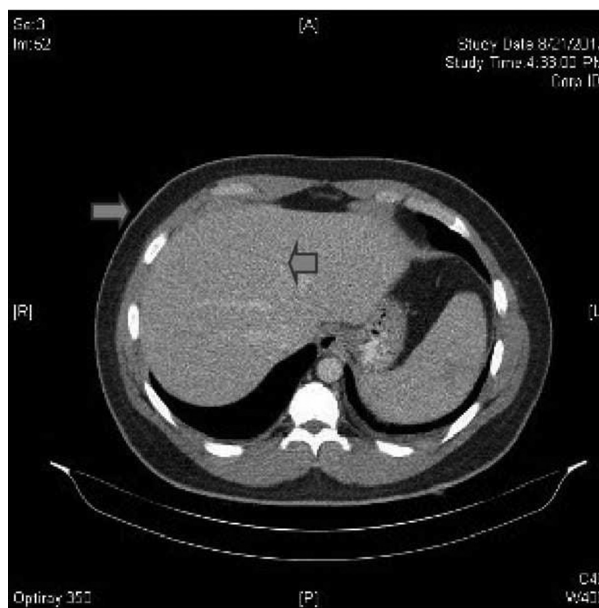
Fungal Empyema Thoracis is rare most common nosocomial acquired life threatening infection with high mortality up to 60%–73%. *Candida* species are the most common pathogens, followed by *Aspergillus* species. The incidence of *Candida* pneumonia in mechanical ventilated patients is much higher than non-ventilated patients. *Candida Albicans* is the most frequently encountered infections, especially after abdominal or thoracic procedures, gastroesophageal fistula. Treatment includes systemic antifungal, chest tube drainage, decortication, and salvage therapy with micafungin in refractory empyema.

275 INTERESTING CASE OF LEPTOSPIROSIS PRESENTED AS WEIL'S DISEASE

M Khalid*, I Khan, D Hidalgo, L Ibrahim, J Moorman. *East Tennessee State University, Johnson City, TN*

10.1136/jim-2017-000697.275

Case report 26-year-old healthy male admitted with complaint of generalised non pruritic rash associated with high grade fever, chills, headache, nausea, vomiting, myalgias, dark urine and discoloration of eyes and skin. Denied sick contacts, tick bites. Patient reported exposed to mosquitoes. Physical exam showed jaundice, pallor and faint diffuse macular rash that spared palms and soles. Labs showed anaemia, thrombocytopenia, high bilirubin and renal failure with creatinine of 1.41 mg/dl. Blood cultures were negative. Peripheral smear showed moderate thrombocytopenia with no schistocytes.



Abstract 275 Figure 1 CT scan showed hepatosplenomegaly (blue arrows)

Detailed work up for infectious causes include HIV, viral hepatitis panel, EBV, CMV, monospot test, Dengue test, chikungunya, Ehrlichia, Anaplasmosis, RMSF which were negative. Computed Tomography abdomen and pelvis showed hepatosplenomegaly (figure 1). Leptospirosis serology was sent to a laboratory which came back positive and patient was started on doxycycline with improvement in the symptoms.

Leptospirosis is zoonosis transmitted by domestic animals or contact with water, soil and food contaminated with urine of infected animal. Weil's disease is a severe form of presentation characterised by kidney, liver dysfunction and Jaundice with a high mortality rate. This case highlights the importance of recognition of leptospirosis in patient with rash with liver and kidney dysfunction.

276 CANDIDURIA DUE TO CANDIDA KRUSEI IN A PATIENT WITH PROLONGED ICU STAY: CAN WE TREAT THIS RESISTANT INFECTION WITH ECHINOCANDINS?

V Kohli*, P Sankhyan, L Ibrahim. *East Tennessee State University, Johnson City, TN*

10.1136/jim-2017-000697.276

Introduction Candiduria is common in high risk patients in the hospital. A recent trend of non albicans candiduria is being reported and among those *Candida krusei* is a rare species to be isolated. A very small percentage of non albicans candiduria is blamed on this species, known to be inherently resistant to triazoles. This report aims at finding out if micafungin is effective to clear UTI caused by *Candida krusei* which does not have a good urine concentration, in a setting ofazole resistant candida infection.

Case report A 47 year old male who was admitted to the ICU with multiple comorbidities and stayed for 23 days was shifted to the ICU step down as he was improving, with a foleys catheter in place. After two days in the step down, patient started spiking fevers of 102F and with leukocytosis (WBC 17.2 K/uL) with unknown origin of foci. He was not on any antibiotics at the time. Piperacillin-tazobactam and daptomycin were considered to treat the patient empirically. His urine and blood was sent for cultures. The blood cultures were negative but his urine culture was positive for *Candida krusei* (CFU > 10⁵/mL). The sensitivity test showed the organism to be resistant to tri azoles (eg. fluconazole and itraconazole). The echinocandins does not have good urine concentration but we did not have more options so we tried to treat the patient with micafungin. Repeat culture was positive on the day we started the patient on micafungin again with *Candida krusei* (> 10⁵ CFU/mL). After 8 days of initiation of the treatment, we sent in another urine sample for culture. The results came back with no growth of *Candida krusei*. The patient did not have any signs of infection and the leukocytosis resolved.

Conclusion The patient required a minimum of 1 week of micafungin until negative cultures and was continued to complete the course for 14 days. We were able to treat the UTI with micafungin completely and thus we believe echinocandin is a good option in candiduria with candida resistant to tri azoles. More studies are needed to confirm this finding as the number of cases seen with this infections are very limited.

277 THE MITIS TOUCH

D LaChance*. *Dwight David Eisenhower Army Medical Centre, Augusta, GA*

10.1136/jim-2017-000697.277

Case report 58 year-old male with essential hypertension presented to the ED after development of acute chest pain. Pain was sharp, constant, fluctuating in intensity, exacerbated by swallowing and deep inspiration, and radiated to his neck. Ibuprofen did not relieve his symptoms prior to presentation. Patient also noted a recent URI which was self-limited. Further ROS was also positive for odynophagia. On presentation, his vital signs were stable and he was afebrile. Cardiac biomarkers were negative; however labs were notable for a leukocytosis. Chest xray was unremarkable. Electrocardiogram was normal sinus rhythm and demonstrated no changes consistent with ischemia. Sublingual nitroglycerin and full dose aspirin in the emergency department did not relieve his symptoms. Given concern for acute aortic dissection, a D-Dimer was obtained which returned positive. A CT pulmonary angiogram was obtained which revealed a soft tissue density mass within the superior mediastinum adjacent to the oesophagus with adjacent free air. Concern for esophageal neoplasm versus esophageal perforation arose. An esophogram with gastrografin ruled out esophageal perforation. Subsequent EGD with esophageal ultrasound revealed a lesion consistent with an infected bronchogenic cyst anterior to the oesophagus was identified with clear delineation between the lesion and the oesophagus. Cardiothoracic surgery performed a video assisted thorocostomy for incision and drainage of the abscess. Purulent fluid was aspirated and sent for gram stain and culture and antibiotic therapy with vancomycin and piperacillin-tazobactam were started. Culture data revealed pan-susceptible *Streptococcus mitis*. The patient was started on course of amoxicillin clavulanate with full resolution of infection and chest pain syndrome.

Bronchogenic cysts are an uncommon congenital anomaly of the foregut which can lead to tracheobronchial compression and infection, with a prevalence of 1/42,000–68 000. They predominantly develop in the lung parenchyma, however about 24% develop in the mediastinum, as in the case. They are mostly discovered as incidental radiologic findings. They can become symptomatic with chest pain being the most common presenting complaint. This represents an unusual aetiology of chest pain due to bronchogenic cyst infection in an immune-competent individual.

278 AN ATYPICAL PRESENTATION OF A TYPICAL MYCOBACTERIUM

T Liddell*, J Lucar Lloveras, R Webb. *University of Mississippi Medical Centre, Brandon, MS*

10.1136/jim-2017-000697.278

Case report Mycobacterium tuberculosis is a common pathogen which infects one third of the world's population. Often clinical suspicion is high when patients present with typical symptoms of pulmonary tuberculosis, however, tuberculosis is often left out of the differential when it presents atypically.

We present a 65 year-old Vietnamese female living in the US for two years with no known past medical history who presented

with left ankle pain for six months. She had been treated for gout though foot pain continued to progress. On admission, ankle was inflamed, and imaging revealed destruction of the talus and an enlarged left inguinal lymph node. She underwent resection of her left talar head and neck and left inguinal lymph node. Infectious Diseases was consulted due to osteomyelitis. Patient then reported symptoms of fever, night sweats, and weight loss of 20–25 lbs that began around the development of her left ankle pain. Laboratory studies revealed mild leukocytosis, thrombocytosis, anaemia, and elevated inflammatory markers. She was also found to have undergone biopsy of her talus prior to her arrival at our hospital. Slides were obtained and reviewed with our pathologist who reported granulomatous inflammation with some granulomas displaying central necrosis. Chest imaging was unremarkable. She was started on active tuberculosis treatment with rifampin, isoniazid, pyrazinamide, and ethambutol. Pathology of talus and lymph node were consistent with biopsy, and cultures eventually grew *Mycobacterium tuberculosis* in six of six samples.

Of the 8.7 million cases of tuberculosis reported each year, musculoskeletal tuberculosis accounts for 1%–5% or 87 000 to 4 35 000 cases each year. Osteoarticular tuberculosis, particularly outside the spine, requires a high level of suspicion for prompt diagnosis. Our case has multiple characteristics that should cause consideration for tuberculosis including visiting from an endemic area, negative bacterial cultures, biopsy with caseating granulomas, and imaging with irregular cavities of destruction with little surrounding sclerosis. Despite a few significant diagnostic clues, our patient's symptoms were present for six months before she received appropriate treatment underlining the importance of maintaining a high suspicion for tuberculosis despite an atypical presentation.

279

VISUAL DEFICITS AS A LATE MANIFESTATION OF CONGENITAL TOXOPLASMOSIS: FAMILIAR SIGN IN AN UNFAMILIAR SETTING

¹WJ Lindsey*, ¹V Habet, ²S Lefevre. ¹Children's Hospital, New Orleans, LA; ²LSU Health, New Orleans, LA

10.1136/jim-2017-000697.279

Purpose of study While *Toxoplasma gondii* is generally asymptomatic in immunocompetent hosts, severe disease can manifest in congenital infection or immunocompromised hosts. 70%–90% infants acquiring *Toxoplasma* infection transplacentally may be asymptomatic initially. It's persistence can end in reactivation leading to clinical disease. The most common late manifestation is retinochoroiditis. Approximately 90% of untreated children will acquire retinal lesions per year. The prevalence of ocular toxoplasmosis in the United States (US) ranges from 0.6% to 2%. Infection rates are higher in regions that are at lower altitudes with a tropical climate with high prevalence in South America. We discuss a case of congenital toxoplasmosis in an immigrant with singular, anterior cervical lymphadenopathy and worsening vision.

Methods used Case Study.

Summary of results A 5 yo male with developmental delay presented to general paediatric clinic for routine well-child check. The patient had recently emigrated from Brazil with his family and had not been examined by a physician in over one year. The parents' primary concerns were assessing a 'lump' on the patient's neck, receiving necessary immunizations to attend school and obtaining visual examination. Physical exam

revealed a 5 cm nontender, mobile rubbery mass of the anterior cervical chain which had been present for over a year. Visual acuity and ocular alignment tests were attempted, but the patient was unable to identify characters at 10 feet. The patient was referred to ophthalmology but was evaluated by an optometrist due to lack of insurance. Retinal images revealed bilateral macular and peripapular scarring consistent with congenital toxoplasmosis. The patient was referred to ID who recommended close follow up without antimicrobial treatment but has since been lost to follow-up.

Conclusions In the US, prenatal testing for toxoplasmosis is not done. This contrasts other countries with higher prevalence of disease where prenatal testing is of significant value. Because toxoplasmosis can be asymptomatic paediatricians must have a high index of suspicion in children presenting with visual disturbance. This is particularly important for immigrants. Visual disturbances in this population should have a broader differential diagnosis including congenital toxoplasmosis.

280

DRESS SYNDROME IN A PATIENT WITH ARDS

R Mangat*, Z Jones, A Eranki. SUNY Upstate Medical University, Syracuse, NY

10.1136/jim-2017-000697.280

Case report Drug reaction with eosinophilia and systemic symptoms (DRESS) syndrome is a relatively rare drug hypersensitivity reaction that can present with organ dysfunction and skin symptoms two to six weeks after starting a new drug. In this case, a middle-aged male was diagnosed with DRESS syndrome when he developed fever, elevated transaminases and worsening eosinophilia after being restarted on antibiotic therapy.

A 53-year-old male with a past medical history significant for Becker's muscular dystrophy presented to the ICU with acute respiratory failure secondary to ARDS in the setting of community acquired pneumonia and septic shock. His oxygenation improved after an initial 7 days treatment with vancomycin, zosyn and azithromycin, but he remained febrile with worsening leukocytosis. Chest x-ray showed bilateral infiltrates and he was restarted on vancomycin and zosyn for recurrent pneumonia. He developed rash and was found to have a white count of 26 000 with 61% eosinophils, ALT of 133 and AST of 122. After the antibiotics were discontinued, the patient's clinical syndrome improved in 2 days.

DRESS syndrome is an important and under-recognised differential diagnosis to consider in patients with fever, unexplained leukocytosis and rash. In this case, the patient was restarted on the offending agents due to concern for infection several days prior to a diagnosis being made. Skin eruptions typically involve greater than fifty percent of the body surface area including facial oedema, infiltrative lesions, scaling and purpura. Abnormal laboratory values that can help diagnose DRESS include leukocytosis with an eosinophil count >700, atypical lymphocytosis, increased transaminases and reactivation of human herpesvirus-6. The most common offending drugs include antiepileptics, sulfonamides, allopurinol with beta lactams being increasingly reported. Removal of the offending agent along with supportive care is the mainstay of treatment in these patients. Prompt diagnosis of DRESS syndrome is clinically important as patient deaths have been reported due to multi-organ system failure in unrecognised cases.

281 A CASE OF AEROCOCCUS AND GLOBICATELLA BACTEREMIA

D Markabawi*, R Mangat, Z Jones, H Singh Gambhir. *SUNY Upstate, Syracuse, NY*

10.1136/jim-2017-000697.281

Introduction *Globicatella sanguinis* are catalase-negative, gram-positive cocci that were first discovered in 1992. There have been multiple case reports of *Globicatella sanguinis* isolated from blood, urine and cerebrospinal fluid. The clinical significance of this bacteria is still unknown. *Aerococcus viridans*, is a very rare microorganism, which causes invasive infections in immunocompromised patients, but rarely in immunocompetent patients. It has been associated with bacteremia, septic arthritis, and especially infective endocarditis.

Case A 72 year old male with a past medical history of CVA, hypertension, and dementia, was brought to the emergency department for complaints of increased fatigue and lethargy. The patient was constipated with the last bowel movement being several days prior to presentation. In the ED, the patient was noted to be afebrile and hemodynamically stable. A CT abdome/pelvis was positive for stercoral colitis. The patient underwent manual dis-impaction. Patient was also noted to be dehydrated with an elevated lactic acid, this improved with IV hydration. Two sets of blood cultures were obtained in the emergency department. One out of the two sets grew *Globicatella sanguinis* and *Aerococcus viridans*. Upon consultation with the infectious disease service, it was decided to treat patient and not deem this a skin contaminant as this bacteremia might have been a result of bacterial intestinal translocation due to colitis and faecal dis-impaction. Both organisms were susceptible to Penicillin and third generation Cephalosporins. Patient was successfully treated with Ceftriaxone 2 g IV daily for 2 weeks.

Discussion While *Aerococcus viridans* is known to cause invasive infections in humans, the pathogenic role of *Globicatella sanguinis* remains partially known. Human carriage of both species has been established. There have been reports of infective endocarditis due to *Aerococcus viridans* and meningitis due to *Globicatella sanguinis*. In our case, the bacteremia likely resulted from bacterial intestinal translocation. Both species were susceptible to third generation Cephalosporins.

Conclusion Although human carriage for both *Aerococcus viridans* and *Globicatella sanguinis* is well known, it is important to consider the pathogenic role of these bacteria in the right setting.

282 BACK PAIN

¹BE O'Brien*, ¹M Bahn, ^{1,2}R Steele. ¹Tulane University, New Orleans, LA; ²Ochsner Medical Centre, New Orleans, LA

10.1136/jim-2017-000697.282

Case report 11 yo caucasian male presented w/fracture of L4. He was in usual state of good health until 3 months prior when he developed fever, myalgia, HA, and left cervical LAD. He was dx'd w/flu, treated with Oseltamivir/Azithromycin. His brother was flu positive 2 weeks prior.

2 weeks s/p tx for flu- he developed acute, intermittent left-sided flank pain went to an ED, CTAP was normal. Patient had a kitten, Bartonella titers were drawn, and showed B. henselae IgG $\geq 1:1024$ (normal $< 1:128$) and IgM $\geq 1:20$ (normal $< 1:20$).

He was dc'd home on Azithromycin/toradol. He continued to have fatigue, decreased appetite. 10 days later- went to urgent care for flank pain, was treated empirically for UTI w/ Augmentin. Labs (cbc, cmp, UA) were normal. S/P treatment, he went to ED for continued flank pain, RUS was normal. 2 weeks later- he went to his paediatrician w/fatigue, decreased appetite. Xrays of spine obtained for concern of MSK aetiology of pain. He was dx'd with scoliosis and referred to Ortho. Flank pain resolved. 1 month prior to presentation, he heard a 'popping sound' and had sudden, severe pain. Was seen by Ortho the next day. MRI of spine showed pathological fracture of L4. He was referred to Hem-Onc to r/o malignancy.

His CBC was normal except for elevated eos (7.4%) on diff, CRP (7.32 mg/L). Otherwise labs (CMP, uric acid, ESR) were normal. Quant. TB Gold was negative. Repeat MRI of CTL spine obtained showed heterogeneously enhancing lesion measuring 2.7 cm within left central portion of L4 vertebral body with mild height loss and associated fracture.

PE: +small palpable lymph nodes in his anterior cervical triangle/inguinal regions. No bone pain, restriction in mobility or ROM, or neurologic deficits.

Biopsy of lesion was sent for gram stain, aerobic/anaerobic culture/AFB/fungal culture (all negative). Path showed necrotizing granulomatous inflammation in bone and bone marrow, no neoplasm. Biopsy sent to Mayo Clinic for Bartonella PCR, which was negative.

1 month later, labs were normal including crp. No hx of recurrent infections, but due to severity of presentation, concern for CGD. Neutrophil oxidative burst assay was negative. Patient has returned to baseline activity level, now has nightly lower back pain and was fitted for a brace.

283 AN UNUSUAL PRESENTATION OF DISSEMINATED VARICELLA ZOSTER IN AN IMMUNOCOMPETENT ADULT

P Pachariyanon*, S Thakolwiboon, D Payne. *Texas Tech University Health Science Centre, Lubbock, TX*

10.1136/jim-2017-000697.283

Case report A 63-year-old man with a history of bladder cancer status post transurethral resection of bladder tumour presented with 5 days of fever, progressive diffuse headache, and photophobia. Initial physical examination revealed multiple discrete erythematous papules on his left post auricular area, trunk and both thighs. A neurological examination revealed neck stiffness without any focal neurological deficit. A computerised tomography scan did not demonstrate any intracranial pathology and cerebral spinal fluid analysis showed a mild lymphocyte-predominated pleocytosis. He was initially empirically treated by intravenous vancomycin, ceftriaxone, ampicillin, and acyclovir. On the third day of admission, he developed left facial droop and hearing difficulty. A repeat physical examination revealed multiple groups of vesicles in the left C2 and C3 dermatome and diffuse erythematous vesiculopapular rash on his trunk and both thighs and peripheral left facial palsy. Weber's and Rinne's tests suggested left sensorineural hearing loss (SNHL) which was confirmed by audiogram. Magnetic resonance imaging was done and did not reveal any structural lesion. Blood and CSF cultures did not grow any microorganism. CSF PCR for HSV-1, HSV-2, and enterovirus were negative as well as HIV and Syphilis

screening. Subsequent immunological study revealed positive serum IgG for HSV-1, VZV, and CMV while negative for HSV-2. However, serum IgM was positive for VZV. Additionally, lymphocyte subset panel did not suggest any immunodeficiency disorder. All anti-bacterial medications were discontinued. Intravenous acyclovir 10 mg/kg was continued for total 14 days. At 1 month follow up, the skin lesions were crusted over and had begun to recede. However, left facial paralysis and remained.

Herein, we described the unusual presentation of disseminated varicella zoster which included both chickenpox-like rash and typical zoster skin lesion as well as neurological involvement in an immunocompetent host.

284

EATING YOUR WAY TO MENINGITIS: WHY MATERNAL PLACENTOPHAGY MIGHT BE A BAD IDEA

C Parrish*, R Welliver. *University of Oklahoma College of Medicine, Oklahoma City, OK*

10.1136/jim-2017-000697.284

Case report Our patient is a previously healthy unvaccinated 15 day old female who presented with decreased oral intake (PO) and fever for 1 week. Patient was a full term infant born at home. Maternal laboratory investigations including group B streptococcus (GBS) were negative. Birth was uncomplicated and patient was healthy until day 7 of life, when she began having decreased PO and fevers. On exam she was alert with no focal neurological deficits. A septic workup showed cerebral spinal fluid (CSF) cultures positive for GBS; blood cultures were negative. A 14 day course of IV ampicillin was started. Initial MRI showed purulent material within subarachnoid spaces, and antibiotic course was extended to 21 days. MRI prior to discharge showed stable purulence. She was discharged home after completing full antibiotic course. At her 6 week follow up, she had age-appropriate development. Of note, mom had sent her placenta to an outside facility to be processed into supplemental pills. Mom began taking these two days prior to admission, and was advised to stop. Our laboratory recommended testing the pills for GBS be completed by the Health Department, however at this time we are unsure whether the family did this.

Late onset meningitis in neonates is often associated with horizontal transmission, one such transmission that we may not consider is maternal ingestion of the placenta. Placental ingestion has been promoted for its potential physical and psychological benefits, although there is no scientific evidence to support this. In a previously reported case in Oregon the mother of an infant with recurrent GBS meningitis had ingested her placenta in the form of pills that were tested and found to be GBS-infected; the final diagnosis: 'late onset GBS disease attributable to high maternal colonisation secondary to consumption of GBS-infected placental tissue'.

These cases show us the importance of expanding our clinical questions and differential diagnoses as the culture we practice medicine in also expands. There is little research into the number of women who choose to ingest their placentas, and even less scientific research on the risks of doing so. These cases illustrate the need for further investigation and insight into the risks of placental ingestion as a means to better educate families.

285

SEVERE AND PROGRESSIVE CELLULITIS FOLLOWING A DOG SCRATCH IN A NEUTROPENIC PATIENT

¹D Pithadia*, ¹E Weathers, ¹R Colombo, ^{1,2}S Baer. ¹*Medical College of Georgia, Augusta, GA;* ²*Augusta VA Medical Centre, Augusta, GA*

10.1136/jim-2017-000697.285

Introduction Skin and soft tissue infections occur in over 20% of patients with chemotherapy-induced neutropenia. Gram positive bacterial infections predominate early in neutropenia, and incidence of resistant bacteria and fungi increases with prolonged neutropenia. Past infections and exposures influence the risk of rare pathogens.

Case A 55-year-old woman, who was neutropenic from chemotherapy for primary CNS lymphoma, was scratched on her forearm by a dog. She cleaned the wound with isopropanol and was treated empirically as an outpatient with amoxicillin-clavulanate. Over the next 4 days, she developed fever plus erythema and swelling of the forearm without purulence, crepitus, or significant pain. The wound had contacted tap water, and she denied other exposures. She was admitted and started on intravenous vancomycin, piperacillin-tazobactam, and tobramycin. Cultures of blood and urine grew *Pseudomonas aeruginosa* with identical susceptibilities. Vancomycin and piperacillin-tazobactam were continued, and all subsequent cultures were negative. However, daily fevers persisted and the inflammation in her arm progressed resulting in restricted flexion of her elbow and digits. MRI of the arm showed myositis and an elbow joint effusion. Voriconazole was added for empiric fungal coverage. A bulla developed at the wound site as her neutrophils recovered, and culture of the fluid grew *Serratia marcescens*. Antibiotics were switched to cefepime based on susceptibility. She became afebrile with substantial improvement of cellulitis within 48 hours and was discharged on oral ciprofloxacin to complete a 14 day course.

Conclusion *Serratia marcescens* is a gram-negative bacillus that thrives in damp environments and causes opportunistic nosocomial infections. *Serratia* skin infections are rare and, based on our review, this may be the first report of *Serratia* cellulitis associated with dog contact and trauma. This case highlights the need to consider unusual pathogens based on exposure history in cases of treatment-resistant soft tissue infections in immunocompromised patients. It also emphasises the importance of obtaining cultures from skin lesions to establish a microbiologic diagnosis for targeted therapy.

286

DOUBLE TROUBLE AND A DELAY

JP Pruitt*, B Johnson, L Gilliam, R Smalligan. *UAB-Huntsville, Huntsville, AL*

10.1136/jim-2017-000697.286

Case report A 20 yo woman presented with 12 hours of progressive abd pain, lightheadedness, dyspnea and chills 5 days after C-section performed at 35 weeks for preterm labour with breech presentation. On exam vitals were T 103.3, BP 87/44, HR 175, RR 18, O2 sats 100% on RA. She appeared ill and had diffuse abd pain from the umbilicus to her Pfannenstiel incision though it was clean and dry. Labs: WBC 15.4 k, Hgb 11, CRP 15, and lactic acid 1.0 (<1 nl). Abd CT showed some subq fluid and scant air, c/w post-op changes. She received 2 L of IVF but no antibiotics initially apparently due to the low lactic acid level and was sent to the OB ED. Hours after presentation, antibiotics were started with further

IV hydration. She improved initially, but by morning the pain had worsened and lactate had risen to 3.4. At this point her abd pain was out of proportion with exam and the incision had become erythematous. Surgery was consulted and she underwent emergency I and D of what was to be confirmed by pathology as necrotizing fasciitis. Wound cultures grew MRSA. She required repeated debridement and an eventual abd wall mesh but recovered and went home in 2 weeks.

Discussion This patient had two related life-threatening conditions. First was sepsis which must be addressed aggressively with early IV fluids and broad spectrum antibiotics. Treatment was delayed initially because of a normal lactic acid. Sepsis is a clinical diagnosis based on the vitals, exam, lab, and imaging findings as opposed to meeting a long list of diagnostic criteria. While an elevated lactate is associated with a poorer prognosis in sepsis, it is not a diagnostic marker.

Necrotizing fasciitis is also a medical emergency which requires a high clinical suspicion as the dx is not always obvious. In our case the physical exam was initially misleading due to the infection being deeper in the tissues, thus the erythema, greyness and bullae often seen in the condition were not present. Typical CT findings of necrotizing fasciitis are subq inflammation and air which can also be seen post-op. Close f/u of this patient with early surgery when she deteriorated were keys to prompt dx and treatment of her second life-threatening condition. It is important to remember that pain may precede skin changes and surgical debridement is the only definitive treatment.

287

TRAVEL-RELATED LEISHMANIASIS AND TUMOUR NECROSIS FACTOR INHIBITORS: 2 CASES OF MISDIAGNOSIS

E Rabold*, RJ Feldman, J Lutgring, A Moanna, H Wu. *Emory University, Atlanta, GA*

10.1136/jim-2017-000697.287

Case report An association between leishmaniasis and the use of tumour necrosis factor (TNF) inhibitors has been suggested by previous reports, and immunosuppression is a known risk for severe disease. Though leishmaniasis is rarely transmitted in the U.S., travellers are at risk of infection when visiting endemic areas. We present two patients with cutaneous leishmaniasis complicated by initial misdiagnoses and TNF inhibitor therapy. Patient A is a 43-year-old healthy American male who presented with a chronic, non-healing ulcer on his right leg and a smaller lesion on his right arm after travel to Mexico. Histopathology of the leg ulcer was inconclusive, and a presumptive diagnosis of pyoderma gangrenosum was made. Due to non-response to topical treatments, he received various immunosuppressive regimens, including oral glucocorticoids, systemic cyclosporine, and adalimumab. A subsequent biopsy of the arm lesion demonstrated parasitized histiocytes, and PCR testing was consistent with *Leishmania mexicana*. After cessation of all immunosuppressive medications and initiation of oral ketoconazole, both lesions resolved. Patient B is a 59-year-old American male with psoriasis treated with adalimumab who presented with non-healing ulcers on his right chest and right thigh after travel to southern Spain. Squamous cell carcinoma was diagnosed from a biopsy of the thigh lesion, and the patient received MOHS surgery. A subsequent biopsy of the chest lesion demonstrated amastigotes in the dermal layer, which was also seen on reevaluation of the first biopsy.

PCR testing was consistent with *Leishmania infantum/chagasi*. His chest lesion resolved with liposomal amphotericin B and cessation of the adalimumab. In these cases, the delayed diagnosis of leishmaniasis resulted in unnecessary or prolonged exposure to immunosuppressive drugs, including TNF inhibitors. Physicians should consider the possibility of leishmaniasis when starting TNF inhibitors in patients with non-healing wounds, particularly if they have travelled to endemic areas.

288

ACQUIRED TRACHEOESOPHAGEAL FISTULA AS A COMPLICATION OF ACQUIRED IMMUNODEFICIENCY SYNDROME (AIDS)

A Richardson*, KR Green, J Perez-Downes, CM Baldeo, SF Shah, N Najjar, V Seeram. *University of Florida College of Medicine Jacksonville, Jacksonville, FL*

10.1136/jim-2017-000697.288

Case report A 52 year old male with past medical history of HIV/AIDS (CD4 count of 5) presented to the emergency department with a complaint of weakness, fatigue, and dysphagia. He had been non-compliant with antiretroviral therapy for 3 previous years. Two days into his admission he became septic thus chest X-ray was ordered revealing a pneumonia. Given no clinical improvement with antibiotics, a CT chest was ordered. The CT scan revealed a communication between the oesophagus and trachea with gas in the mediastinum. Given severe cachexia, no surgical intervention was recommended. A gastrojejunal feeding tube was inserted, intravenous broad spectrum antibiotics and antifungals started, and serial esophagrams were ordered to evaluate healing and closure of the tracheoesophageal fistula. Fistula formation was attributed to candida esophagitis given oral candida was present on admission. Patient was discharged to follow up for initiation of antiretroviral therapy

Acquired tracheoesophageal fistulas (TEF), although uncommon, usually occur as a complication of mechanical ventilation, trauma, and malignancy. However, the immunocompromised can acquire TEFs secondary to complications from opportunistic infections. Although TEFs were more common early in the AIDS epidemic, acquired TEFs are rare today given advances in antiretroviral therapy. Causative infectious agents of acquired TEFs include *Mycobacterium*, *Candida* species, Cytomegalovirus, and herpes simplex virus. If left untreated, progression to perforation, necrosis, or TEF formation can occur.

TEFs are a serious condition with significant morbidity and mortality. Treatment is necessary to avoid aspiration, sepsis, and pulmonary failure. Surgical repair is the preferred treatment and typically involves esophageal closure with resection of the tracheal fragment. Tracheal or esophageal stents are other treatment options but considered a palliative measure. TEFs must be considered in severely immunocompromised individuals given their life threatening prognosis.

289

KAPOSI SARCOMA PRESENTING AS DYSPHAGIA

J Ruiz*, M Ganji, R Jacob. *UF Health Jacksonville, Jacksonville, FL*

10.1136/jim-2017-000697.289

Case report A 25 year old African American male with past medical history of HIV and neurosyphilis who presented to

the hospital for dysphagia associated with facial and throat swelling. Physical exam was notable for significant submandibular and supraclavicular lymphadenopathy with concern for possible Castleman's syndrome. During mouth evaluation a 3 centimetre hyper vascularized violaceous submucosal lesion below the palate was noticeable. CD4 absolute count on admission was 607. Patient was empirically started on fluconazole for suspected candida esophagitis and gastroenterology was consulted for upper endoscopy which revealed multiple large hyper vascularized violaceous submucosal nodular lesions seen on the soft palate and pharynx. Surgery was also consulted for suspicious soft palate lesion as well for excisional lymph node biopsy. Histopathology of lymph node biopsy was negative for Castleman's disease but notable for spindle cells consistent with Kaposi's sarcoma along with positive CD31 and HHV-8 stain. Dysphagia got progressively worse in a matter of hours. He eventually was transferred to the intensive care unit due to increasing respiratory distress. During the intubation, the patient desaturated, became bradycardic, and experienced cardiac arrest. Unfortunately, the patient expired after multiple rounds of resuscitative efforts with no evidence of cardiac activity on ultrasound.

Discussion Kaposi Sarcoma is angioproliferative disorder that requires infection with human herpes virus-8. Skin lesions are the most common manifestations of Kaposi sarcoma. It can also present in other organs as lymph nodes, oral mucosa and the gastroenterology tract. Usually presented in immunocompromised patients. Patient atypical presentation and findings on oral mucosa and upper endoscopy made this case interesting. Kaposi sarcoma usually is diagnosed by biopsy. Treatment can be either chemotherapy or radiotherapy along with antiretroviral therapy.

Conclusion Kaposi sarcoma should always be kept as a possible differential diagnosis on patients with past medical history of HIV/AIDS despite decreased prevalence due to evolution in medical therapy. This case can lead to further evaluation of dysphagia by upper endoscopy on patients that present with dysphagia and oral lesions since only handful of cases of Kaposi sarcoma are seen now a days.

290 PARADOXICAL RESPONSE TO ANTITUBERCULOUS THERAPY IN AN HIV NEGATIVE TB PATIENT

N Salagundla*, S Siddiqui, A Mirza, A Islam. *Texas Tech University HSC Amarillo, Amarillo, TX*

10.1136/jim-2017-000697.290

Case report A 50 yo F immigrant from Sudan with PMH, presented with symptoms of generalised weakness, nausea, vomiting and chills for 2–3 months. On P/E she appeared cachectic with bilateral diffuse crackles. CT chest: diffuse bilateral nodular infiltrates with cavitory changes in left upper lobe and right pleural effusion. Further CT evaluation showed: diffuse hypodensities in liver, spleen, kidney and adnexa, left parietal lobe ring enhancing lesion. IGRA was positive, HIV was negative. Sputum and pleural fluid AFB were negative and CT guided lung biopsy showed positive for AFB. Patient was started on four drug antituberculous therapy (ATT) and started improving. She was discharged after 2 days and continued with directly observed ATT. After one month, patient was readmitted for worsening symptoms and WBC count of 3500. CT chest: extensive bilateral, predominantly upper lobe

increased cavitory lung lesions. MRI brain: enhancing lesions in right cerebellar and bilateral parietal regions. Drug sensitivity testing of previous specimens showed pan-sensitivity to standard ATT. Therefore, paradoxical response to treatment was diagnosed. ATT treatment was continued with the addition of a quinolone and steroids, but eventually the patient required occipital craniotomy for right cerebellar mass resection. Patient improved on full ATT and steroids over a one year period.

Discussion IRIS (Immune Reconstitution Inflammatory Syndrome) is a widely-recognised cause of paradoxical response in HIV positive patients, but PR can be seen both HIV + and HIV- patients, most commonly extrapulmonary infections associated with lower lymphocyte counts at baseline. Respiratory and CNS TB are most commonly involved. Diagnosis is by exclusion. Exact mechanism is uncertain but immune restitution may play a role even in HIV negative patients. In TB, an imbalanced TH2 to TH1 ratio can impair type IV hypersensitivity reaction and can lead to immunosuppression and ATT can stimulate previously suppressed immune response as a proposed mechanism. Activation and accumulation of lymphocytes and macrophages at the site of bacterial destruction can produce pro-inflammatory substances causing paradoxical response. Steroids are added with continued ATT, with the intent of decreasing the hyper-inflammatory response.

291 BUGS IN MY HEAD: A CASE OF INTRAVENTRICULAR NEUROCYSTICERCOSIS CAUSING ACUTE HYDROCEPHALUS

N Salagundla*, S Siddiqui, A Chandralekha, A Islam. *Texas Tech University HSC Amarillo, Amarillo, TX*

10.1136/jim-2017-000697.291

Case report A 50 YO male with no known PMH presented with C/C of headache which started in the morning, lasted for more than 12 hours gradually became confused with nausea and vomitings. He often had headache in the past which usually resolve with Ibuprofen. Patient came to USA 4 years ago, grew up in Mexico, and denied smoking, alcohol or drug history. P/E and Vitals WNL except for confusion. Initial labs were normal. MRI has shown nonspecific foci of calcifications in the parenchymal and third ventricle which consisted proteinaceous material, Cyst in 3rd ventricle obstructing drainage of CSF causing hydrocephalus. Serological studies were positive for T. Solium antibody. Neurocysticercosis was highly suspicious based on symptoms, imaging and social history. Neurosurgeon immediately performed ventriculostomy with shunt to relieve increased ICP pressure. Initially patient responded well with improvement in mentation. Infectious disease specialist started antiparasitic therapy with Albendazole and Dexamethasone. As 3 days progressed, patient had persistent headache and developed diplopia. Repeat CT head showed increased dilation of 3 rd ventricle. Patient was transferred to tertiary care for further management, underwent uncomplicated endoscopic removal of intraventricular cyst and subsequently discharged home in stable condition. On follow up, patient has recovered well.

Discussion Cysticercosis is a neglected parasitic infection caused by the larval form of the pork tapeworm Taenia solium. Neurocysticercosis is the most serious clinical manifestation of cysticercosis, leading cause of acquired epilepsy in

disease-endemic counties. Intraventricular neurocysticercosis commonly presents with acute obstructive hydrocephalus secondary to either cyst entrapment in foramina or ependymitis. Headache is the most common presentation along with symptoms like nausea, vomiting, decreased visual acuity, altered mental status and CN palsies. The diagnosis is based on imaging with MRI, but serological tests are important supplementary diagnostic tools. Treatment is mainly surgical, preferably using a neuroendoscopic technique, but patients should receive antihelminthic treatment with corticosteroids to reduce incidence of shunt failure and to treat undiagnosed viable lesions elsewhere.

292

SEVERE PAN-SINUSITIS IN AN APLASTIC ANAEMIA PATIENT SUCCESSFULLY TREATED WITH MULTI-AGENT THERAPY

R Samannan*, Z Yu, R Welliver, D Crawford, C Lawrence, J Argo. *University of Oklahoma, Norman, OK*

10.1136/jim-2017-000697.292

Introduction Acute invasive fungal rhinosinusitis (AIFRS) is an often fulminant disease in immunosuppressed patients with mortality rates of 50%–90%. We report a patient with severe aplastic anaemia with invasive *Aspergillus* rhinosinusitis who responded to multimodal therapy with endoscopic sinus (ES) surgery, granulocyte infusions and multi-agent antifungal therapy.

Case description A 5-year-old girl with severe idiopathic aplastic anaemia presented with unilateral periorbital swelling, nasal congestion and tearing of right eye 2 months after initial diagnosis. Hematopoietic stem cell transplant was not done due to lack of HLA matched donor. Due to recurrent infections, immunosuppressive therapy (IST) was not initiated. Upon transfer to our facility, a CT head was done which demonstrated severe right sided pan-sinusitis. Sinus cultures was +ve for *Aspergillus flavus*. Broad spectrum coverage including antifungal therapy was initiated and then modified to amphotericin, micafungin, and voriconazole based on sensitivity. Extensive ES debridement was performed repeatedly over the ensuing weeks. With ongoing evidence of AIFRS, application of Ambisome-embedded gauze was initiated along with daily donor granulocyte infusions with resulting trough ANC of more than 500 cells/ μ L. After 4 weeks of combination therapy, no further re-accumulation of sinus debris was noted and fungal elements were absent on histopathologic evaluation.

Conclusion AIFRS is increasing due to advances in diagnosis and treatment of paediatric malignancies and immune deficiencies. *Aspergillus flavus* is the most common organism. Prolonged neutropenia and *Aspergillus* infection are associated with a high mortality, especially in patients with no prospect for neutrophil recovery like our patient. Early institution of therapy with aggressive sinus debridement and multi-agent antifungals are of paramount importance in reducing mortality.

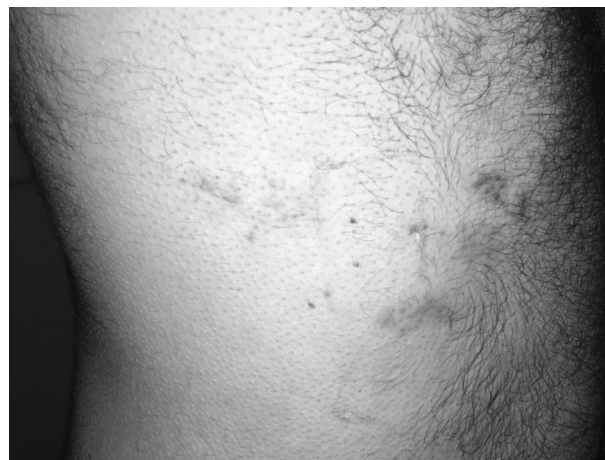293

VARICELLA ZOSTER MENINGITIS WITH SHINGLES IN A YOUNG IMMUNOCOMPETENT ADULT

P Sankhyan*, A Mahajan, M Khalid, V Kohli, D Pierce. *East Tennessee State University, Johnson City, TN*

10.1136/jim-2017-000697.293

Case report A 39 year old man presented with sudden onset burning pain in the right flank, followed a few hours later by a fever (101 Fahrenheit) with headache and associated photophobia and phonophobia. He had no medical problems predisposing him to an immune compromised state and had a self-limited varicella zoster infection during childhood. On physical examination, he had mild neck stiffness and a vesicular erythematous rash in the T7-T8 dermatome (figure 1). Lumbar puncture showed increased protein, pleocytosis with lymphocyte predominance (94%) and normal glucose. All his other tests were unremarkable. Computed Tomography and Magnetic Resonance Imaging of the head was normal. He was diagnosed with aseptic meningitis and started on Intravenous (IV) Acyclovir followed by oral valacyclovir. His cerebrospinal fluid (CSF) returned positive for Herpes zoster polymerase chain reaction (PCR) 4 days after beginning treatment. On follow up, he had improved significantly with minimal fatigue and no sequelae. CSF findings for varicella and herpes simplex are similar, but the incidence of varicella meningitis is much lower (range 3%–20%). It can also cause meningitis preceding the rash or without the characteristic rash in upto 40% cases. Most data suggests treating immunocompromised patients with IV antivirals but guidelines for treating immunocompetent patients are unclear. But timely start of antiviral treatment can help prevent complications like motor neuropathy, herpes encephalitis, post herpetic neuralgia and the vision-threatening complications herpes zoster ophthalmicus and acute retinal necrosis.



Abstract 293 Figure 1 Vesicular erythematous rash in the T7-T8 dermatome

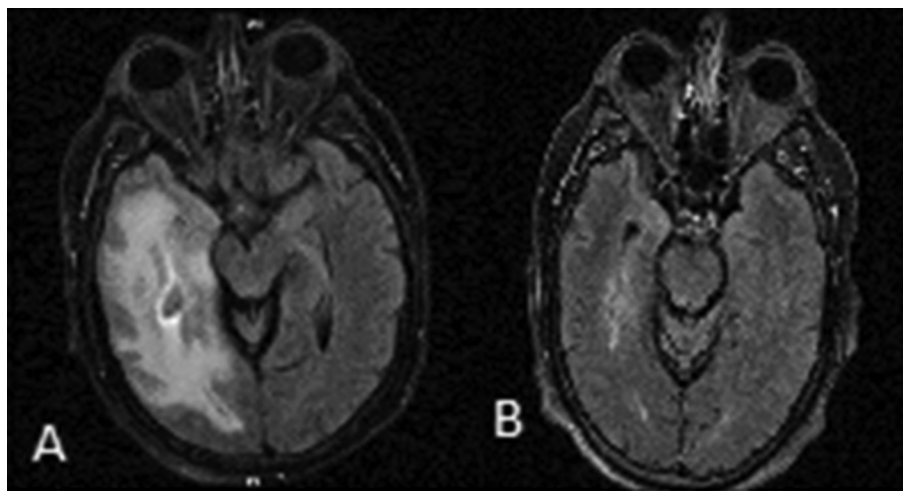
294

CENTRAL NERVOUS SYSTEM ASPERGILLOSIS A MEDICAL CHALLENGE

¹RM Medrano*, ¹D Sotello, ¹K Nugent, ²S Alvarez. ¹TTUHSC, Lubbock, TX; ²Mayo Clinic, Jacksonville, FL

10.1136/jim-2017-000697.294

Case report A 56 year old male with fever and headache 3 days of duration. Four days later he developed generalised tonic-clonic seizures, which improved with anti-seizure medications and steroids. Had history of end-stage liver disease secondary to alcoholic cirrhosis and underwent orthotopic liver transplant 2 years prior. MRI revealed a lobulated enhancing



Abstract 294 Figure 1 (A) lobulated enhancing lesion involving the right fusiform gyrus with extension into the ependymal surface of the right temporal horn and atrium; (B) after 20 months of therapy

lesion involving the right fusiform gyrus with extension into the ependymal surface of the right temporal horn and atrium, figure A. Cerebrospinal fluid (CSF) examination revealed clear CSF, WBC 2 cells/HPF (lymphocytes 86%) glucose 109 mg/dL, protein 82 mg/dL, negative cultures and VDRL. He had normal WBC, chemistry panel, and negative serum *Aspergillus* antigen. MRI guided stereotactic brain biopsy showed focal necrosis and septate fungal hyphae, culture was positive for *Aspergillus fumigatus*. Was treated with voriconazole 400 mg every 12 hours (indefinitely). Surgery was not recommended due to location of the lesion and related risk. The patient had excellent response after 20 months of therapy, figure B. CNS aspergillosis represents the most severe presentation of all forms of aspergillosis. Risk factors: neutropenia, hematologic malignancies, bone marrow or solid organ transplants, and chronic use of steroids. The diagnosis requires a positive CSF culture; CSF *Aspergillus* antigen and/or PCR may be useful, although brain biopsy may be required. Therapy requires combination of surgery and antifungal therapy; mortality without surgical management has been described from 60.4%–100% vs 25%–28.6% with combination therapy. Voriconazole is the antifungal drug of choice. The patient favourable outcome despite the absence of surgical intervention may be due to prompt diagnosis, aggressive antifungal therapy, and decrease of the intensity of immunosuppression.

295

AN UNUSUAL CASE OF PERITONITIS IN A PERITONEAL DIALYSIS PATIENT

¹B Stadsvold*, ^{1,2}M Varghese, ^{1,2}S Baer. ¹Medical College of Georgia at Augusta University, Augusta, GA; ²Augusta VA Medical Centre, Augusta, GA

10.1136/jim-2017-000697.295

Case report Peritoneal dialysis (PD) is a convenient alternative to hemodialysis with a decreased risk of blood stream infections for end stage renal disease patients. However, the risk of peritonitis is significant and when caused by unusual organisms, diagnosis and treatment may be difficult. This is the case of a 60 year old female with a past medical history of diabetes mellitus, hypertension, and end stage renal disease on peritoneal dialysis for 7 years, who presented with diarrhoea and diffuse abdominal pain not improving on amoxicillin/

clavulanate as an outpatient. Four days prior, she had received a blood transfusion for symptomatic anaemia and consequently missed a round of PD. She was admitted for sepsis, suggested by tachycardia and leukocytosis of 30 000. Peritoneal fluid analysis revealed 4000 leukocytes with 90% neutrophils, and gram stain of the fluid revealed no organisms but many neutrophils. Two days after the peritoneal fluid was collected, cultures had growth of mould. Due to her altered mental status and electrolyte abnormalities, anti-fungal therapy with intravenous isavuconazonium sulfate was initiated. The PD catheter, removed the following day, was noted to have gross mould contamination. *Aspergillus niger* was identified in culture of the fluid. Serum galactomannan levels were positive and repeated to trend efficacy of treatment which showed questionable improvement from 6.5 to greater than 5.48 (normal value: <0.5) within a week. The patient's hospital course was complicated by aspiration pneumonia and septic shock requiring multiple vasopressors. Approximately two and a half weeks after admission, due to the patient's worsening clinical status, the family decided to pursue comfort care, and the patient expired. Peritonitis is a common complication in chronic peritoneal dialysis. While the majority of cases are of bacterial origin, fungi are responsible for up to 15% of cases, with a fraction of those caused by filamentous fungi such as *Aspergillus*, *Fusarium*, *Penicillium*, and dematiaceous moulds. This case highlights the difficulties in diagnosis and treatment of mould peritonitis.

296

STARI NIGHT: SOUTHERN TICK ASSOCIATED RASH ILLNESS AFTER AUTOLOGOUS STEM CELL TRANSPLANT

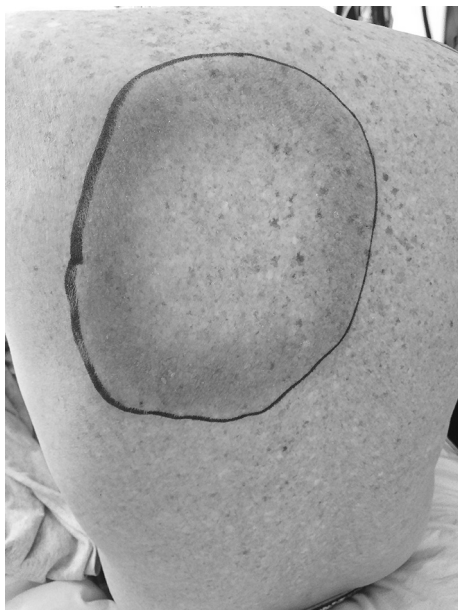N Summers*, Z Chai, M Shums, M Lechowicz, R Friedman-Moraco. Emory University, Atlanta, GA

10.1136/jim-2017-000697.296

Case report A 57 year-old male from Georgia with Stage IV Mantle Cell Lymphoma underwent autologous hematopoietic stem cell transplant conditioned with busulfan/cyclophosphamide/etoposide. On day 5 post-transplant, he developed fevers to >40 C, headache, and multiple large erythematous skin lesions with central clearing on his right arm, right chest, left scapula, and right ankle. He had no other systemic symptoms.

Fevers persisted despite >48 hours of broad spectrum antimicrobial therapy. He endorsed multiple tick bites prior to admission. It was felt that his clinical presentation was most consistent with STARI (southern tick associated rash fever). Treatment with doxycycline 100 mg twice daily was initiated and the patient defervesced within 24 hours. His rash resolved over the course of several days. He completed a 14 day course of doxycycline. Additional work-up, including acute and convalescent antibodies for Ehrlichia and RMSF (Rocky Mountain Spotted Fever) were negative. He was doing well at post-transplant follow-up with bone marrow engraftment and resolution of symptoms.

Discussion STARI causes a similar clinical presentation to that of Lyme disease (*Borrelia burgdorferi*) transmitted by *Ixodes scapularis*, however the vector is the Lonestar tick (*Amblyomma americanum*). Skin lesions tend to be larger and multiple in STARI compared to Lyme disease, and patients may have more systemic symptoms. The causative agent is not known, but is felt to be a spirochete. STARI in immunocompromised patients has not been widely reported. Immunocompromised patients may be at risk for more severe manifestations.



Abstract 296 Figure 1 Patient's back

297

LOAIS MANIFESTED AS AN EYE WORM IN AN ACTIVE DUTY SOLDIER NATIVE OF NIGERIA

T Tobin*, K Davis. Dwight D Eisenhower Army Medical Centre, Fort Gordon, GA

10.1136/jim-2017-000697.297

Case report Ocular loaisis is a subclinical syndrome involving the migration of an adult *L. loa* worm across the sub-conjunctiva. Typical symptoms include eye pruritis and pain in addition to transient angioedema characterised by localised subcutaneous swellings. While common in endemic African countries, it is rarely seen in the United States.

A healthy, 28 year-old male from Nigeria was seen at sick call for left eye pruritis, erythema, and clear discharge for four days. He had no significant medical history and was

taking no medications. He was referred to ophthalmology at Balboa Medical Centre when a worm was visualised in the sub-conjunctiva. On further history, he had returned to Nigeria in 2015 but did not recall any specific insect exposure or if family members were affected. He was transferred back to his home duty station, Fort Stewart, to allow him to be closer to family while receiving treatment. Ophthalmology re-examined him on arrival, but they were unable to visualise the worm again. Physical exam was only positive for left conjunctival injection, but no signs of anterior eye fibrosis, retinal involvement, or concomitant onchocerciasis were noted. Blood tests drawn at noon local time to quantify microfilariae were negative at the reference laboratory. Serologic testing for loiasis was positive and negative for onchocerciasis. He was begun on diethylcarbamazine (DEC) for treatment.

L. loa is transmitted by horse flies, most commonly *Chrysops dimidiata* and *C. silacea*, and it can present years after initial inoculation. Diagnosis is made by visualisation of a worm or by serologic testing at the NIH. Treatment is with DEC. Quantification of microfilariae in the blood is important in the management of this infection. Microfilariae are released by adult worms into peripheral blood and can be found circulating between 10 am and 4 pm. Measurement of microfilariae greater than 2500 per mL increases the risk of developing fatal sequela as an adverse effect of DEC treatment. Plasmapheresis prior to DEC treatment may decrease the risk of adverse effects when elevated microfilarial numbers are present. It is also important to assess for co-infection with onchocerciasis prior to initiating DEC as this can worsen with DEC treatment alone.

298

'EYE' KNOW THIS IS SYPHILIS

A Traina*, J Dubuc, H Oddo Moise, A Bourgeois, A Coulon, J Doan, S Sanne. LSUHSC, New Orleans, LA

10.1136/jim-2017-000697.298

Case report A 34 year old homosexual man with no past medical history presented to the emergency department with left eye pain and redness for 7 days. Upon further questioning, he reported that his last sexual encounter was 2 years ago followed by a flu-like illness. His physical exam was remarkable for diffuse left eye scleral injection, patchy alopecia, and thick hyperkeratotic plaques with hyperpigmented lesions on his palms and soles. Screening tests in the emergency department revealed that he was positive for Human Immunodeficiency Virus (HIV) which prompted further work up for other infections including syphilis. RPR titer was strongly positive at 1:256 with positive FTA-ABS. Although cerebral spinal studies were negative for VDRL, he was started on intravenous penicillin G for treatment of tertiary syphilis given ocular involvement. The following day, he patient became febrile to 103F, consistent with Jarisch-Herxheimer reaction. He was also started on trimethoprim/sulfamethoxazole and azithromycin as prophylaxis for opportunistic infections given his CD4 T-cell count of 16/mm³ with 2.9% CD4 cells. Other diagnoses such as Acute Retinal Necrosis (ARN), Progressive Outer Retinal Necrosis (PORN) and Cytomegalovirus (CMV) retinitis were less likely given his weakly positive antibodies for Herpes Simplex Virus (HSV), Varicella-zoster virus (VZV) and CMV with negative HSV DNA. Ophthalmology performed serial retinal exams without signs of retinal necrosis, but recommended

continuing acyclovir since the entire retina was unable to be visualised. His ocular symptoms and palmar and plantar skin changes improved with antibiotic and antiviral treatment. He was discharged with 14 days of intravenous Penicillin G with outpatient referrals to infectious disease and ophthalmology.

Discussion Patients with severe immunodeficiency may not only be unaware of their HIV status but may also present with complicated presentations of other sexually transmitted infections and opportunistic diseases. This case highlights the importance of screening for HIV infection at least once for individuals ages 13 to 75 years or more frequently for those with increased risk factors to ensure early treatment and to reduce transmission to others.

299

POLYMICROBIAL ENDOCARDITIS CAUSED BY ABIOTROPHIA DEFECTIVA, BACILLUS CEREUS, BACILLUS SUBTILIS AND BACILLUS MEGATERIUM IN THE SETTING OF INJECTION DRUG USE

¹TT Tran*, ¹M Varghese, ^{1,2}S Baer. ¹Medical College of Georgia, Augusta, GA; ²Augusta VA Medical Centre, Augusta, GA

10.1136/jim-2017-000697.299

Case report Polymicrobial infective endocarditis (IE) is more commonly found in the setting of injection drug use (IDU). We present a case of a 52 year-old female with ongoing IDU. She initially presented to the emergency department with lower back and right hip pain. She was discharged with oral trimethoprim/sulfamethoxazole for a presumed urinary tract infection. Blood cultures obtained during the visit later returned positive for *Abiotrophia defectiva*. She was lost to follow up until two months later when she presented with dysarthria, altered mental status, and atrial fibrillation. She was noted to have IE on both mitral and aortic valves and was started on intravenous vancomycin and piperacillin/tazobactam. Preliminary results of her blood cultures were consistent with *Bacillus* species, which were sent to reference lab for further identification. Final identification found *A. defectiva*, *Bacillus cereus*, *Bacillus subtilis* and *Bacillus megaterium*, so antibiotics were simplified to Vancomycin. She defervesced and her bacteremia cleared. Due to her extensive mitral and aortic valve vegetations, she underwent mitral and aortic valve replacement. Her hospital course was further complicated by persistent arrhythmia and critical left leg ischemia requiring a permanent pacemaker and emergent thrombectomy. She was discharged after 38 days to an acute long term care hospital.

This case highlights the risk of polymicrobial IE in the setting of IDU as many variables can introduce common organisms from the oral cavity and the environment into the blood stream such as the type and purity of the drug and the use of unsterile procedures and paraphernalia. *A. defectiva*, part of the normal human flora, is a rare but aggressive cause of IE due in part to its propensity to develop large vegetations and shed septic emboli. *Bacillus* species are common soil microorganisms and are uncommonly associated with bacteremia or IE. Thus isolation of rare or unexpected organisms from endocarditis supports the importance of asking patients about the practices associated with their intravenous drug use.

300

SOFT TISSUE INFECTIONS FOLLOWING WATER EXPOSURE

JP Walther*, R Welliver. University of Oklahoma College of Medicine, Oklahoma City, OK

10.1136/jim-2017-000697.300

Case report A previously healthy 12 yo female presented to ED after a labial laceration. She fell off a raft and was injured by the rope attached to the boat. Patient was seen by the gynaecological team who repaired the laceration which measured 8 cm × 4 cm on R labia majora. Twenty hours after presentation, she developed a fever up to 39.2 C. The incision had appropriate swelling with no induration. Patient was started on ceftazidime. Patient became afebrile and was transitioned to oral Bactrim. Wound culture grew moderate gram positive cocci; blood cultures with no growth. Later that day, patient developed significant pain, was unable to move right leg, and was febrile to 38.3 C. On exam, labial incision had a 1 cm opening at the top with purulent fluid, and the right vulva was erythematous and indurated. Patient was taken to the OR for I and D which found purulent material with necrotic debris at the base of the labial ulceration and purulent drainage tracking 10 cm into the right thigh. After wash-out, patient was started on Vancomycin, Zosyn, Doxycycline, and Ceftazidime covering MRSA, Gram Negative rods, Pseudomonas, and Vibrio. Wound cultures grew *Aeromonas veronii*, *Edwardsiella tarda*, *Streptococcus anginosus*, and coagulase negative *Staphylococcus*. Tissue cultures grew *Edwardsiella tarda*, *Plesiomonas shigelloides*, *Streptococcus anginosus*, *Streptococcus gordonii*, and *Prevotella bivia*. Vancomycin and doxycycline were discontinued after 24 hours. A PICC line was placed. She received 8 days of Zosyn and Ceftazidime, which covered all the bacteria grown in culture. Prior to discharge, patient was afebrile, tolerating regular diet, and able to ambulate. Plan is to continue IV antibiotics for 14 more days.

Soft tissue infections caused by water organisms are uncommon but potentially fatal. The 5 organisms that should be thought of when a patient presents with a wound exposed to water are *Aeromonas* spp, *Edwardsiella tarda*, *Erysipelothrix rhusiopathiae*, *Vibrio vulnificus*, and *Mycobacterium marinum*. Empiric treatment includes Ceftazidime or clindamycin, Levofloxacin, and Metronidazole or Doxycycline depending on exposure. This case illustrates the importance of recognising a potential infection from a soft tissue wound exposed to water with the potential for infection and the importance of empiric antibiotic treatment.

301

INVASIVE DISEASE CAUSED BY HAEMOPHILUS INFLUENZA TYPE A

AM Wolf*, S Boppa. University of Alabama Birmingham, Birmingham, AL

10.1136/jim-2017-000697.301

Case report Historically, paediatricians have feared the *Haemophilus influenzae* type B bacteria due to its ability to cause life-threatening disease in our patients. However since the widespread use of the *H. influenzae* type B vaccine, invasive infections caused by *H. influenzae* type B have been almost completely eradicated. Yet invasive infections caused by other

strains of the *haemophilus influenza* bacterial class have become more common in its absence. Here, we present two children with meningitis due to *H. influenza* type A at Children's of Alabama in the last few months.

The case of an 8 mo F and a 2 yo M with *b. influenza* type A meningitis were examined. The first child an 8 mo female, initially presented to an outside hospital, was diagnosed with hand, food, and mouth disease, and discharged to home. She returned the following day with fever and lethargy at which time CSF studies showed meningitis. She was started on treatment with ceftriaxone, then transferred to COA PICU after seizure activity. CSF cultures grew *H. influenza* type A and the patient quickly recovered, was extubated and transferred out of the ICU. Her course was complicated by persistent fevers and further seizure activity prompting an MRI brain, which revealed a right frontal empyema. The infant was treated with ceftriaxone monotherapy with eventual full recovery. The second case involves a 2 yo M with no past medical history who presented to the ED with multiple days of fever, vomiting, and lethargy and was found to be in septic shock. CSF studies were concerning for bacterial meningitis and the patient was admitted to the ICU, although never required intubation. His CSF cultures also grew *H. influenza* type A and he was treated with ceftriaxone monotherapy. He was placed on seizure prophylaxis due to possible seizure activity. He also had prolonged fevers, but repeat lumbar puncture was negative and MRI brain was consistent only with meningitis. He recovered and was discharged to home.

These two cases of meningitis in addition to another child with unrecognised splenic heterotaxy who had severe sepsis caused by *H. influenza* type A at our institution in the past 18 months highlights the need for awareness of the importance of this organism causing CNS and systemic infections. A retrospective review of charts at COA over the past 10 years is in progress.

Neurology and neurobiology

Joint plenary poster session and reception

4:30 PM

Thursday, February 22, 2018

302 CHIARI-I MALFORMATION: CHALLENGE IN DIAGNOSTIC AND THERAPEUTIC DECISIONS

D Gebremariam*, K Nugent, G Bedanie. *TTUHSC, Lubbock, TX*

10.1136/jim-2017-000697.302

Introduction Chiari malformations refer to a spectrum of congenital hindbrain abnormalities and listed as a rare disease by the National Institute of Health. Diagnostic differentiation from other causes of headache like migraine used to be a challenge. However, with routine use of magnetic resonance imaging, it is discovered with increasing frequency. Chiari type-I is the most common and least severe form. Its hallmark is caudal displacement of cerebellar tonsils below the foramen magnum referred to as congenital tonsillar herniation.

Case presentation A 31 year old man with chronic headaches treated as migraine presented with acute occipital headache of 3 days duration. Headache was exacerbated when bending down with blurring of vision in left eye. He had no motor or cranial nerve deficit. His CSF and opening pressures were normal. MRI showed low lying cerebellar tonsils and syrinx at C6-7; phase contrast cine MRI showed absence of CSF flow posterior to the tonsils. He was readmitted two times within a month due to recurring headaches, loss of sensation, and tingling in his upper extremities. Chiari-I as cause of headache and not migraine was strongly considered; he had a decompression craniectomy leading to resolution of his headaches.

Discussion Chiari-I malformation can present in adulthood and may be misdiagnosed as in this patient. Most common symptom is headache exacerbated by cough and Valsalva manoeuvre. Syringomyelia can present together like in this patient. MRI is the most useful imaging study. CSF flow analysis through foramen magnum with phase contrast cine MRI provides further supportive evidence. However the real diagnostic and therapeutic challenge is encountered in patients like ours who was thought to have migraine for years. He was initially assumed to have his symptoms from his migraine when he was admitted for the first time. He was not responding to medical management. He finally had a decompressive craniectomy with resolution of headache. Our case demonstrates diagnostic and therapeutic challenges when a rare cause of headache like chiari-I malformation which may need a more invasive and aggressive treatment presents like migraine.

303 HYDRANENCEPHALY: A RARE CASE OF CORTICAL ABSENCE IN A NEONATAL PATIENT

HH Patrick, *RE Herdes, LM Lasseigne, E Smith, JM Volk. *Louisiana State University Health Sciences Centre, New Orleans, LA*

10.1136/jim-2017-000697.303

Case report Hydranencephaly is a rare disorder characterised by the near-total absence of cerebral hemispheres. Caudal brain structures are usually present. Aetiology is unknown, hemispheric absence is believed to be caused by a prenatal vascular insult. It is suspected that damage to vasculature at the base of the cranium leads to the destruction of the cerebral hemispheres. Frequently diagnosed in-utero during prenatal screening with ultrasound, MRI after birth is the best modality for diagnosis. Patients can develop irritability, hypertonia, and seizures. Absence of sellar structures leads to panhypopituitarism requiring endocrine workup and treatment. They generally have a poor outcome and survivability, and many children with this disorder expire before one year. Treatment is supportive and palliative.

We report the case of a 39 1/7 WGA term infant who presented to NICU shortly after birth secondary to prenatal concerns for alobar holoprosencephaly on maternal ultrasound. Physical exam revealed macrocephaly with a full anterior fontanelle and splayed sutures. HUS at time of delivery was consistent with hydranencephaly. And the diagnosis was confirmed with MRI. A palliative shunt was placed on DOL 5 due to family's desire to proceed with maximum medical and surgical treatment. Endocrine work-up was within normal limits. Not surprising, the patient initially required respiratory support

and had inconsistent nipple skills requiring gavage feedings for adequate nutrition. Developmental evaluation showed an overall poor prognosis for gross motor development secondary to minimal cortical tissue.

This case represents an unusual case of cortical absence in a neonatal patient. While suspected diagnosis is usually made prenatally with ultrasound, clinicians should be suspicious of neonates who present with macrocephaly, respiratory distress, widened cranial sutures, irritability, seizures, hypertonia, or neurological deficits. Head US should be utilised as an initial imaging modality for diagnosis but should be confirmed with MRI. These patients represent a unique population of paediatric patients who receive palliative care with poor prognostic outlooks.

304 LATERAL MEDULLARY SYNDROME; RESULTING FROM UNEXPLAINED THROMBOCYTOSIS

MK Islam*, A Islam. *Texas Tech Univ HSC Amarillo, Amarillo, TX*

10.1136/jim-2017-000697.304

Case An 53 year old gentleman came to the hospital because of dysphagia, vertigo and facial numbness that has been getting worse over 1 week. Denies any focal weakness, seizure, vision problem. He is a previous cocaine and methamphetamine abuser; quit 10 years ago, but continues to take marijuana in a daily basis. Vitals: temperature 36.7 C, pulse 65/min, respiratory rate 24/min, BP 143/91, SPO₂%–100% on room air. On physical exam: CTA B/L, RRR, S1/S2 normal, alert and oriented ×3, no motor weakness, left sided facial numbness was present and unable to differentiate hot and cold sensations over right upper and lower extremity. Left cranial nerves V, IX, X were involved. Babinski and Pronator Drift were negative, gait couldn't appreciate due to vertigo and unsteadiness. Initial lab: Hb 13.9, MCV 88, WBC 17.2, Platelet 901, Na 139, K 3.5, Cl 109, HCO₃ 23, BUN 11, Cr 0.70, LFT normal, urine toxicology positive for amphetamine and marijuana. Initial CT scan head was negative for stroke, subsequent MRI of brain showed multiple infarct involving left side of medulla, posterior portion of lateral ventricle and right temporal-occipital region. CTA of head and neck showed left intracranial vertebral artery thrombosis. TTE didn't show any vegetation or structural heart disease. Extensive evaluation for thrombocytosis including BCR-ABL, JAK-2, PBF, thrombophilia screen; which came back negative.

Discussion Wallenberg's syndrome (WS) is well defined clinically, and the lateral medullary infarction (LMI) is the most frequent cause. Although the combinations of the various signs and symptoms are helpful for the clinical diagnosis of WS, the presence of the different signs and symptoms may vary from patient to patient. Dysphagia has been reported in 51% to 94% of the patients with WS. It has been widely accepted that, the dysphagia in WS is initially severe enough to require nothing per oral but often improves rapidly. Unexplained thrombocytosis and drug abuse could play a pivotal role for development of LMI in this patient. Our case reminds the physician to consider unexplained thrombocytosis as a potential factor for developing stroke. It is very important for a careful neurological examination which can recognise atypical presentation of stroke very early, which could be lifesaving.

305 NON-SSPE RELATED PERIODIC LONG-INTERVAL DIFFUSE DISCHARGES AND WIDESPREAD DIFFUSION RESTRICTION IN THE GREY MATTER

¹JK Jones*, ¹AB Ramos, ²J Newsom, ¹EC Mader, ¹C Barton. ¹LSUHSC-New Orleans Neurology Department, New Orleans, LA; ²Ochsner, Kenner, LA

10.1136/jim-2017-000697.305

Background The electroencephalogram (EEG) of patients with diffuse encephalopathy may show generalised periodic epileptiform discharges (GPEDs). GPEDs repeating every 0.5–4 s are periodic short-interval diffuse discharges (PSIDDs) and GPEDs repeating every 4–30 s are periodic long-interval diffuse discharges (PLIDDs). PLIDDs have been reported mostly in patients with subacute sclerosing panencephalitis (SSPE) and a few patients with acute encephalopathy. By contrast, PSIDDs are not an uncommon finding in critically ill patients with acute encephalopathy. We report a case of non-SSPE related PLIDDs in a patient with acute encephalopathy and widespread MRI diffusion restriction in the grey matter. Within a week, the PLIDDs were superseded by PSIDDs.

Case report A 55-year-old man with chronic liver disease and portal hypertension presented with bleeding esophageal varices and depressed sensorium requiring transfusion and intubation. On day 4, he had a tonic-clonic seizure prompting treatment with lorazepam and levetiracetam. EEG showed PLIDDs with no clinical correlate. Brain MRI showed bisymmetric diffusion restriction in the insula, temporal neocortex, thalami, and other grey matter structures. After treatment of metabolic disturbances, he started responding to simple commands and was extubated. On day 11, he became stuporous and EEG showed PSIDDs. Lacosamide was added to levetiracetam. EEG the next day showed PSIDDs with shorter interval. On day 15, he developed respiratory failure and passed away.

Conclusion It is not clear why PLIDDs is rare in encephalopathic non-SSPE patients. A possible explanation, suggested by this case, is that PLIDDs represent an unstable state in brain neurodynamics that inevitably transitions to a more stable state, such as PSIDDs. It is also unclear what brain structures must be compromised to produce PLIDDs. In SSPE, MRI lesions usually develop in the cortex and subcortical regions and spread to the periventricular white matter. In the case presented, the MRI obtained on the same day the PLIDDs were recorded showed bihemispheric grey matter diffusion restriction with prominent involvement of the insula, temporal neocortex, and thalami.

306 IDIOPATHIC INTRACRANIAL HYPERTENSION AND LEUKOENCEPHALOPATHY AS AN INITIAL PRESENTATION OF SYSTEMIC LUPUS ERYTHEMATOSUS

DH McVadon*, P Craddock, J Ingram. *University of Mississippi Medical Centre, Ridgeland, MS*

10.1136/jim-2017-000697.306

Case report Idiopathic intracranial hypertension (IIH) is a rare neuro-ophthalmic manifestation of Systemic Lupus Erythematosus (SLE). Diagnosis of IIH in SLE patients can be challenging often with delayed treatment; however, prompt diagnosis is critical to early and appropriate treatment. Reported cases of IIH with diffuse white matter changes on imaging are sparse,

especially in the paediatric population. SLE should be considered in patients with unexplained neurologic symptoms especially females of reproductive age to ensure prompt and optimal treatment. We present a case of a 13-year-old female who presented with symptoms of IIH and significant white matter changes, subsequently found to have SLE with lupus cerebritis.

307 **TRIPLE WHAMMY – ISCHAEMIC STROKE DUE MOYA MOYA DISEASE IN A PATIENT WITH GRAVES AND SICKLE CELL DISEASE**

¹R Samannan*, ²M Allee. ¹University of Oklahoma Health Sciences Centre, Oklahoma City, OK; ²University of Oklahoma, OKC, OK

10.1136/jim-2017-000697.307

Introduction Moya moya disease (MMD) is a chronic occlusive cerebrovascular disorder characterised by bilateral stenosis of the supra-clinoid portion of the internal carotid arteries with collaterals. The disease is rare among black population. Here we describe a young African American patient with sickle cell trait who presented with right middle cerebral artery (MCA) territory infarct and in thyrotoxic crises.

Case description 34-year-old African American male with a history of poorly controlled Grave's disease presented with history of acute onset of left sided weakness and chest pain. Magnetic resonance angiogram (MRA) of brain showed near occlusion of both distal supra-clinoid internal carotid artery (ICA) with patent bilateral proximal MCA and right ischaemic infarct diagnostic of ischaemic type of MMD. Investigations revealed patient to be in thyrotoxic crises with a low thyroid stimulating hormone, elevated free Thyroxine and free tri-iodo-thyronine. Sickle cell screen was positive. Due to intolerance of antithyroid medications due to agranulocytosis, he underwent thyroidectomy. Right superior temporal artery (STA) to middle cerebral artery (MCA) bypass was done later with some improvement of symptoms. At discharge continued to have residual left side weakness.

Discussion Although prevalent in all races, MMD is extremely rare in black population. Various etiologies including hemolytic anemias, genetic and graves disease are for attributed to causing MMD. Cellular proliferation, vascular dysregulation, immunologic stimulation, enhanced sympathetic activity are postulated causes of MMD in graves while and subendothelial anoxia is postulated cause in hemolytic anemias

Cerebral angiography is the gold standard both for diagnosing MMD. Surgical bypass is recommended with superficial temporal artery to MCA (STA-MCA) anastomosis.

Conclusion This presentation of MMD with both Graves disease and sickle cell trait in an African American patient is new and has not been reported in literature.

308 **TRANSIENT GLOBAL AMNESIA AND B12 DEFICIENCY; IS THERE A RELATIONSHIP?**

S Siddiqui*, N Salagundla, S Wan, A Islam. *Texas Tech University HSC, Amarillo, TX*

10.1136/jim-2017-000697.308

Case A 64 year-old Caucasian farmer with no past medical history presented to ER with acute confusional state. He was in good health and went out for buying parts for his tractor.

On his way back he forgot what he was doing. EMS was called in and they found patient to be confused and was brought to ER for evaluation. On arrival he was evaluated for possible stroke or TIA. On examination patient was vitally stable, neurological examination disclosed loss of memory, orientation, swallowing function and repeated questioning with no focal neurological deficits. He underwent further workup with MRI brain, spinal tap and EEG; all of which did not show any pathology. He was started on artificial tube feeding for nutritional purposes for acute dysphagia. He was also started on B12 replacement therapy as his levels were low. Patient was diagnosed with Transient Global Amnesia and over days of supportive treatment patient clinically improved and returned back to his baseline functional status.

Discussion Transient global amnesia (TGA) is a sudden and temporary loss of memory. It consists of anterograde amnesia as well as some retrograde amnesia. However, the patient retains executive functions and procedural memory. TGA can be preceded by trauma and stress but those factors are not necessary. The event normally resolves within 24 hours and the patient returns to baseline memory function. There are no clear tests to confirm diagnosis of TGA. This case presents an atypical look at TGA; while it normally resolves within 24 hours, our patient took more than 48 hours to recover and he had swallowing difficulty merely because he was not sure what to do with his food. Patient received B12 supplementation during his hospital stay. There has been no proven link between B12 deficiency and TGA, but there has been cases reported in which association of TGA with hyperhomocysteinemia is seen. To date TGA is thought to be primarily a diagnosis of exclusion but we may need to explore more in relation to B12 deficiency and hyperhomocysteinemia. We describe a rare case of TGA which required more than 24 hours to resolve and patient had B12 deficiency.

Paediatric clinical case

Joint plenary poster session and reception

4:30 PM

Thursday, February 22, 2018

309 **THAT'S NOT OSTEOMYELITIS**

M Adams*, S Narayanan, M Orr. *UAB, Birmingham, AL*

10.1136/jim-2017-000697.309

Case report An 11 year old male was seen in our ED with 3 weeks of daily fevers, migratory joint pains, hematuria, and a 10 lb weight loss. Two months prior, he was admitted to an outside hospital with migratory joint pain and diagnosed with septic arthritis of the left hip, treated with surgical washout and 2 weeks of clindamycin. After completion, he had continued left leg pain and was treated with Trimethoprim-Sulfamethoxazole for 3 days, after which he developed a generalised petechial rash with rosettes. Labs on admission revealed elevated CRP/ESR, gross hematuria, and an elevated protein/creatinine ratio. A bone scan revealed uptake in the left proximal femur.

Initial differential included drug reaction, vasculitis, osteomyelitis with systemic inflammatory process, and chronic

recurrent multifocal osteomyelitis. A CBC, BMP, LDH and uric acid were normal. MRI showed unclear left proximal femur enhancement that could not rule out osteomyelitis; an orthopaedic surgery consult felt that the findings could be related to post-surgical heterotopic ossification. On hospital day 3, he became hypertensive and hypoxic; a chest X-ray revealed small bilateral pleural effusions. At this point labs returned with a positive cANCA concerning for a systemic vasculitis with glomerulonephritis. Non-contrast sinus and chest CT revealed minor sinus disease without bony destruction and diffuse pulmonary opacities. Renal biopsy revealed necrotizing glomerulonephritis with interstitial neutrophils and eosinophils confirming the diagnosis of Granulomatosis with Polyangiitis (GPA). Femoral biopsy revealed no signs of acute osteomyelitis. Following the biopsy, he developed hypoxemia and pulmonary haemorrhages. He was treated with pulse dose steroids, Rituximab and Cyclophosphamide infusions with symptomatic improvement.

GPA, formerly known as Wegener's Granulomatosis, is a rare progressive necrotizing granulomatous vasculitis that commonly affects the respiratory tract, kidneys, and systemic small vessels. It is important to keep in the differential as its presentation may be non-specific but may rapidly progress to overt renal failure or diffuse pulmonary haemorrhage and can be fatal without prompt treatment. Unique to this case is the concern for joint infection and its demonstration of the importance of quickly ruling out infection so that immunosuppressant medicines may be started early in the course.

310 COMPLEX REGIONAL PAIN SYNDROME OF THE ABDOMINAL WALL IN AN 8-YEAR-OLD FEMALE

¹O Altun*, ²B Faynberg. ¹Karolinska Institutet, Stockholm, Sweden; ²Florida State University, Pensacola, FL

10.1136/jim-2017-000697.310

Case report Complex regional pain syndrome (CRPS) is a rare disease characterised by pain out of proportion to stimulus. Generally associated with trauma or surgery, a small percentage of CRPS cases present spontaneously. With no gold standard test for diagnosis, is a difficult condition to diagnose and manage in the paediatric population.

An 8-year-old female presents with diffuse, progressively worsening abdominal pain and distention that developed over the past 10 days. Mild and periumbilical at first, the pain became severe, diffuse and extremely sensitive to touch, easily triggered by clothing or a blanket. Parents report poor appetite, but no other symptoms. Other than some recent constipation, there is no significant medical history. The patient seemed distressed, with a diffusely tender abdomen and slightly mottled abdominal skin. Vitals were normal and the rest of the examination was unremarkable. Initial labs were only significant for HCO₃ of 12, glucose of 59, and WBC count of 14.2 with a slight elevation in neutrophils and no bands. Contrast CT only showed possible mesenteric lymphadenitis and a distended urinary bladder. Persistent symptoms prompted extensive laboratory workup and ultimately an exploratory laparoscopy, but a definitive cause was not identified. Pain control, meanwhile, was very challenging. Medications were largely ineffective and an epidural finally provided some relief. In coordination with Neurology she was then started on gabapentin, which helped to some degree,

suggesting possible neuropathic origin. With no better explanation for her symptoms, findings were compared to the Budapest criteria, which consider sensory, vasomotor, sudomotor, and motor/trophic characteristics. This patient had two signs and three symptoms among four different categories, which can diagnose CRPS with a sensitivity of 0.99 and specificity of 0.68. Following diagnosis, this patient may require multi-specialty care at a paediatric inpatient pain centre for desensitisation and rehabilitation.

CRPS remains a challenging diagnosis and extensive workup is required to exclude other causes. Though it most commonly affects extremities, it can present on anywhere and is a valid consideration in patients with abdominal pain, but no identifiable origin.

311 AN UNREPORTED CLINICAL FEATURE OF CLASSIC MENKES DISEASE: NATUREL KILLER CELL DYSFUNCTION

J Bhat*, P Maertens. USA, Mobile, Alabama, Mobile, AL

10.1136/jim-2017-000697.311

Case report Menkes disease (MD) is an X-linked, multisystem lethal disorder of copper metabolism resulting from mutations in the ATP7A gene. Features such as Ehler Danlos syndrome, trichopoliodystrophy, urologic and skeletal changes have been reported. We present a case of classic MD treated with copper infusions who suffered from naturel killer (NK) cell dysfunction.

Case description A 2-year-old, Caucasian male child presented at 8-month-old of age with persistent hypotonia, kinky hair and developmental regression. Diagnosis of MD was based on low serum levels of copper {5 mg/dL (18–37)} and ceruloplasmin {18 ug/dL (75–153)} and gene sequencing studies revealing exon 12 deletion in ATP7A gene. Brain MRI showed mild hypoplasia of the cerebellar vermis and vascular tortuosity typical of MD. Copper chloride treatment was immediately initiated. Child became more alert with excellent eye contact and purposeful movements. The child was hospitalised for recurrent respiratory infections, each time caused by enterovirus as confirmed by multiplex PCR. In addition, he was also admitted for multiple episodes of fever of unknown origin. Extensive immunologic studies were negative, except for a severe NK cell dysfunction (0.6 NK lytic Units; n>2.6). We consider that NK cell dysfunction in classic MD can be explained by the deficient incorporation of copper in endoplasmic reticulum leading to an abnormal Fenton chemistry within phagosomes.

Conclusion NK cell dysfunction in classic MD has never been reported. It is known to result in recurrent viral infections, thus increasing morbidity in MD. Therefore, evaluation of NK cell function should be considered in patients with classic MD.

312 A CASE OF RECURRENT CONTISPATION

J Blanding*, N Zeky, E Mcdonough, E Klepper. Our Lady of the Lake Regional Medical Centre, Baton Rouge, LA

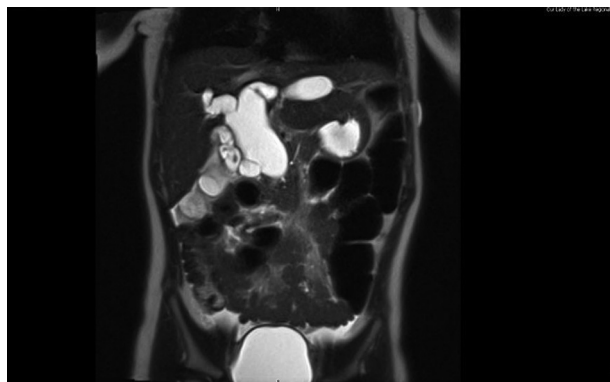10.1136/jim-2017-000697.312

Case report Choledochal cysts are dilations that form along the biliary tree. The most classical presentation is the triad of abdominal pain, jaundice, and abdominal mass. However, only

20% of patients will present in this manner. Most will present in the first decade of life.

A three year old female with chronic constipation presented to the Emergency room for abdominal pain and nonbloody, nonbilious emesis that did not resolve with enema or laxatives. On initial lab testing, she was found to have elevated transaminases, gamma glutamyl transpeptidase, and lipase. Total bilirubin was within normal limits. Because of the abnormal labs, computerised tomography of the abdomen was obtained that showed intra and extrahepatic dilation of the bile ducts concerning for choledochal cyst. A magnetic resonance cholangiopancreatography was obtained and confirmed a type IVA choledochal cyst. Surgery was consulted. Additional laboratory testing showed an elevated Ca 19-9 but normal alpha fetoprotein levels. Ultimately, she was taken to surgery for excision and roux-en-y with hepaticojejunostomy. During surgery, the choledochal cyst was found to encompass the entire length of the extrahepatic biliary tree and bilateral intrahepatic systems. At follow up, transaminases normalised. Pathology was negative for malignancy, though the possibility for malignancy remains if residual cyst tissue was left. She is currently being monitored for post-surgical complications including stenosis of the anastomosis site with annual labs.

While constipation is a common diagnosis in young children with abdominal pain, this case shows that with clinical suspicion and abnormal labs, paediatricians should think about other etiologies for abdominal pain in a young child.



Abstract 312 Figure 1

313 POLYMICROBIAL POTT'S PUFFY TUMOUR: A PAEDIATRIC PREDICAMENT

KS Booker*, S Boppana. *Children's of Alabama, Birmingham, AL*

10.1136/jim-2017-000697.313

Case An eleven-year-old African-American male with haemoglobin SC disease presented with facial swelling and fever with recent positive rapid influenza test. On exam, he had profound swelling over his left forehead. The left eye was swollen shut, with yellow exudate. Initial computed tomography (CT) showed preseptal cellulitis and sinus disease. Inflammatory markers were markedly elevated with ESR of 125. Despite intravenous antibiotics, swelling progressed. Repeat CT demonstrated abscess formation in the preseptal and frontal tissue with an intraorbital component. Patient underwent surgical drainage and was found to have disease extension to the subdural and epidural space. This required intraoperative

consult and drainage by neurosurgery. Cultures from the forehead abscess grew *Gemella morbillatum*, *Bacteroides uniformis*, and *Streptococcus constellatus*. Orbital cultures grew *S. constellatus*, and intracranial abscesses grew *B. uniformis* and *S. constellatus*. The presentation is consistent with Pott's puffy tumour.

Discussion Pott's puffy tumour was originally described by Sir Percival Pott in the 18th century. In the era of antibiotics, it is now a rare complication of frontal sinusitis. Clinical features include headache, fever, and frontal swelling. The condition is defined by forehead oedema, thus 'tumour', due to subperiosteal abscess accompanied by frontal bone osteomyelitis. It can be complicated by life-threatening intracranial infection.

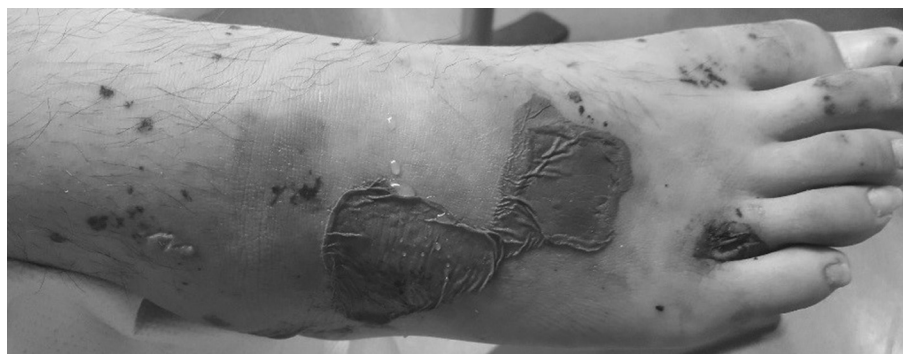This is a case of a rapidly progressive invasive polymicrobial infection of the sinuses, with intracranial extension and orbital involvement. The causative organisms are unusual. *G. morbillatum* is a microaerophilic gram positive coccus. *S. constellatus* is a species of viridans strep of the anginosus group, which has microaerophilic or anaerobic growth. This group of streptococci has a propensity to form abscesses. Finally, *B. uniformis* is a gram negative anaerobe. Although these bacteria have not been previously described in the literature as occurring together, it is not surprising that these anaerobic and microaerophilic organisms thrived in the patient's sinuses, which were inflamed due to the influenza virus, creating the environment suitable for a secondary bacterial infection.

314 RASH AND RENAL FAILURE IN A TEENAGE MALE

NA Booth*, N Chiriboga, T Chadha. *University of Florida, Jacksonville, FL*

10.1136/jim-2017-000697.314

Case report A 15-year-old boy with morbid obesity presented to his paediatrician for a rash on his thighs and was prescribed oral and topical steroids. Two days later, he developed swelling in his extremities, arthralgias, fever to 103F and no improvement of his rash. He returned to his paediatrician who prescribed amoxicillin-clavulanate for a left acute otitis media. As his rash and arthralgias continued to worsen over the next 4 days (bilateral lower extremities down to his feet), he presented to the emergency room and was admitted. While inpatient, his rash was noted to be purpuric and bullous. His initial lab values revealed a normal BMP, elevated WBC of 22.5 K/mcL, elevated ESR and CRP of 95 mm/hr and 24.3 mg/L, respectively and a urinalysis revealed microhematuria. He was pan-cultured and started on vancomycin and piperacillin-tazobactam. Over his 6 day admission, his skin lesions continued to spread over his bilateral upper extremities, trunk and lower back. A culture of the lesions was positive for coagulase negative staphylococcus and he developed progressive renal failure with oliguria, a potassium of 6.5 mEq/L and BUN/Cr of 73/5.5 mg/dL. He was then transferred to our paediatric intensive care unit for further management (figure 1). He received emergent hemodialysis and underwent a complete rheumatological, infectious, and renal work-up including skin and kidney biopsies. While his skin biopsy revealed a leukocytoclastic vasculitis, his kidney biopsy showed acute interstitial nephritis without vasculitis. After a multidisciplinary discussion, he was started on high dose steroids for vasculitis of unknown aetiology. He eventually had resolution of his rash and recovery of renal function. While rashes are



Abstract 314 Figure 1 Sample of widespread rash, on admission to our institution's PICU

commonplace in paediatrics, this case stresses the importance of early recognition of a vasculitic rash as it should prompt serial monitoring of kidney function and potential evaluation by specialists.

315 SARCOIDOSIS IN AN ADOLESCENT MALE PRESENTING WITH HYPERCALCEMIA AND WEIGHT LOSS

¹J Bridges*, ¹C Glendye, ²N Washington. ¹University of Mississippi Medical Centre, Jackson, MS; ²Mississippi Centre for Advanced Medicine, Madison, MS

10.1136/jim-2017-000697.315

Introduction Sarcoidosis in older children usually presents with lymphadenopathy, pulmonary involvement, fever, weight loss, and malaise; it rarely presents with hypercalcemia. Diagnosis is made by histopathologic findings of non-caseating and giant cell granulomas with exclusion of other causes of granulomatosis. In this case, an adolescent male with hypercalcemia was diagnosed with sarcoidosis.

Case description A 14 year old male presented with weakness and 70 lb weight loss over one year, elevated transaminases, thrombocytosis, and severe hypercalcemia. Thyroid stimulating hormone and C-reactive protein were within normal limits; erythrocyte sedimentation rate was elevated and parathyroid hormone and magnesium were low. Chest X-ray and computed tomography lacked hilar lymphadenopathy or visible lung pathology. Aggressive hydration improved the patient's hypercalcemia and acute kidney injury. Angiotensin converting enzyme, lysozyme, and vitamin D-1,25-OH levels were elevated. Concern for sarcoidosis was confirmed via lymph node biopsy revealing granulomatous inflammation without caseating necrosis. Dilated eye exam revealed anterior uveitis and pulmonary function tests showed a restrictive pattern. Symptoms improved with pulse-dosed steroids and methotrexate. He was discharged with rheumatology follow up.

Discussion Only 5% of paediatric patients with sarcoidosis have hypercalcemia at presentation. Hypercalcemia in sarcoidosis is thought to be secondary to autonomous 1-alpha-hydroxylase activity within granulomas. In addition to hypercalcemia, the absence of pulmonary findings at time of diagnosis makes this presentation of sarcoidosis unique. Sarcoidosis is classically associated with bilateral hilar lymphadenopathy, with only 10% of children that present with sarcoidosis having a normal chest X-ray. This patient did not have any abnormal

pulmonary imaging findings at time of presentation, though pulmonary disease was evident on pulmonary function testing. Sarcoidosis, while rare, can have serious complications and should be considered in the differential diagnosis of hypercalcemia, even in the setting of normal pulmonary imaging.

316 OSSEOUS METAPLASIA IN A PAEDIATRIC KIDNEY ALLOGRAFT BIOPSY

¹K Butler*, ¹A Nayak, ²M Turman, ³A Snead, ¹N Mathews. ¹OU Children's Hospital, Oklahoma City, OK; ²Phoenix Children's Hospital, Phoenix, AZ; ³AmeriPath, Oklahoma City, OK

10.1136/jim-2017-000697.316

Introduction Osseous metaplasia (OM) is the presence of heterotopic bone in any soft tissue. To our knowledge, only one case of renal osseous metaplasia has been reported in a paediatric patient, which was discovered after allograft nephrectomy. We present the first case of OM in a biopsy of a functioning paediatric kidney allograft.

Case report Our patient is an 11 year-old female who underwent deceased donor kidney transplant at age 8 for end-stage renal disease secondary to autosomal recessive polycystic kidney disease. Her course was complicated by multiple episodes of acute cellular rejection and chronic antibody mediated rejection (AMR) treated with various immunosuppressants including steroids, rituximab, IVIG, thymoglobulin, plasmapheresis and bortezomib. On presentation eGFR was decreased to 21 ml/min/1.73 M2 from a baseline of 36. A repeat biopsy of the kidney allograft demonstrated ongoing acute and chronic AMR and focal mature bone formation consistent with OM. CT showed pericapsular bony changes with extension into the renal parenchyma and radionuclear bone scan confirmed mild activity in those areas. After treatment, eGFR increased to 31 ml/min/1.73 M2 and has been stable.

Discussion The pathophysiology of OM is not well known, but is hypothesised to be induced by chronic ischaemic conditions in the setting of vascular and parenchymal scarring. In this case, the OM is likely secondary to the chronic inflammation from AMR, which created a suitable environment for the metaplasia to occur.

Bone metaplasia associated with chronic allograft nephropathy. Tousignant, K. *et al.* *Kidney International*, Volume 70, Issue 3, 407.

317 FOOD PROTEIN INDUCED ENTEROCOLITIS SYNDROME (FPIES) INDUCED METHEMOGLOBINEMIA

^{1,2*}RC Calderone, ¹VA Harrison, ^{1,2}JL Stewart. ¹The University of Mississippi Medical Centre, Pearl, MS; ²The University of Mississippi Medical Centre, Jackson, MS

10.1136/jim-2017-000697.317

Case report A 4 week-old female with sickle cell trait was brought to the Paediatric Emergency Department for a 1 week history of vomiting and diarrhoea.

Emesis reportedly occurred within 1 hour of feeds and stools were 6–7 episodes of diarrhoea daily. Mom transitioned from breastfeeding 2 weeks prior to presentation. In the ED, a venous blood gas revealed a methemoglobin level of 14.3%. Patient admitted for evaluation.

Clinical course The patient was noted to have decreased on growth curve from 24th to 3rd percentile. A failure to thrive work-up was benign. The patient started on a hypoallergenic infant formula, with improved diarrhoea, increased weight, decrease in methemoglobin level. She was discharged home with 1 week follow-up.

At follow-up, the patient was pale with mild weight loss. A repeat methemoglobin level was 40.6%. Patient was sent to ED where methylene blue was given and the patient admitted. Her diarrhoea continued, and stool culture was positive for campylobacter. Cow’s Milk IgE returned elevated and patient diagnosed with Food Protein-Induced Enterocolitis Syndrome. Total peripheral nutrition was given until stool losses were controlled and weight gain sustained. Methemoglobin level trended to normal without intervention. The patient discharged home on elemental formula.

Discussion In methemoglobinemia, nitrates are converted to nitrites in the GI tract. Nitrites oxidise iron is oxidised to the ferric state, forming methemoglobin, that binds oxygen poorly. Methemoglobinemia typically presents with cyanosis,

irritability, tachypnea, and altered mental status can develop with higher levels. Methylene blue is the treatment.

318 POTT’S PUFFY TUMOUR & EPIDURAL EMPYEMAS AS COMPLICATIONS OF SINUSITIS IN A TEENAGER WITH JIA

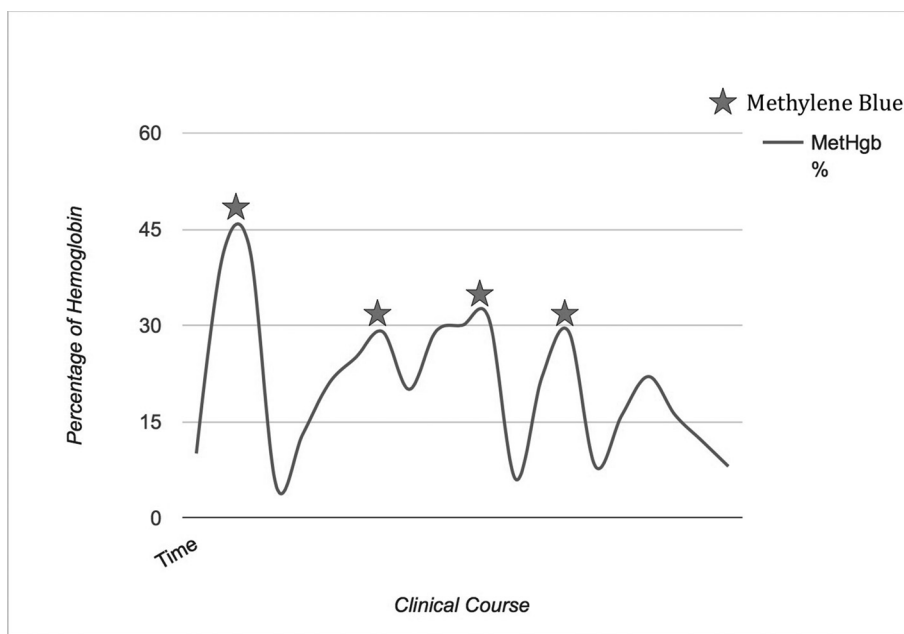
V Chandwani*. Emory, Atlanta, GA

10.1136/jim-2017-000697.318

Background Acute bacterial sinusitis often follows a benign course with outpatient antibiotic treatment but in some cases, has the potential to progress to serious life-threatening complications including epidural abscesses and the rarely seen Pott’s Puffy Tumour.

Case A 14-year-old female with Juvenile Idiopathic Arthritis (on an immunosuppressive study drug) and history of cranial reconstructive surgery for multisuture synostosis nine years prior to presentation who presented with two weeks of rhinorrhea and nasal congestion, three days of headache, fever and forehead swelling associated with vomiting. Although she was neurologically intact on presentation to the paediatric emergency room, there was a high suspicion for facial abscess. Therefore, a CT scan of her head and sinuses with contrast was performed and revealed pansinusitis, bifrontal epidural empyemas, with subperiosteal abscess concerning for Pott’s Puffy Tumour. She was admitted for IV antibiotics and taken to the OR for endoscopic sinus surgery with incision/drainage of her subperiosteal abscess. Her cultures grew out Streptococcus anginosus and she was later discharged home with a PICC line for parenteral systemic antibiotics of six weeks.

Conclusion A high clinical suspicion given this patient’s exam, history and multiple risk factors allowed for early recognition, prompt intervention and successful treatment of this patient’s complicated sinusitis.



Abstract 317 Figure 1 Methemoglobinemia: methylene blue is the treatment

319 **INTERSCAPULAR PAIN PROGRESSING TO LEG WEAKNESS AND ATAXIA: A CASE OF NON-TRAUMATIC EPIDURAL HAEMORRHAGE**

A Chaphekar*, S Kaneaster. *University of Oklahoma Health Science Centre, Oklahoma City, OK*

10.1136/jim-2017-000697.319

Introduction Non-traumatic epidural haemorrhage can be difficult to diagnose due to non-specific symptoms at presentation. Additionally, epidural haemorrhage is rare in children. We describe a case of non-traumatic epidural haemorrhage presenting as upper back pain progressing to neurologic deficits. **Case presentation** A six year old healthy female, with no history of trauma, was initially treated conservatively for upper back pain. Six days later, she presented to an emergency department with worsening back pain, located between the scapulae, and new onset gait changes. She endorsed numbness and tingling of bilateral feet and had a wide based gait with bilateral hip instability. She had midline tenderness to palpation over T2-T4. Neurologic exam revealed bilateral decreased proximal lower extremity strength, numbness of the feet and lower legs, and ataxic gait.

Patient had an MRI done, which showed an epidural haemorrhage from T2-T5. The haemorrhage was displacing the spinal cord laterally and cord oedema was noted to be present. Orthopaedic spine team was consulted and patient was taken to the operating room for laminectomy. The surgeons visualised a possible arteriovenous malformation (AVM) enclosing the spinal cord. The compressing lesion was removed from the dorsal side, but was not safely accessible from the ventral aspect.

Post-operative imaging showed a stable ventral epidural haemorrhage. Concerning over the next 48 hours, patient had progression of the numbness and significant worsening of her weakness. Angiogram revealed a vascular epidural fistula from the left supreme intercostal artery. After embolization, flow through the fistula ceased.

Post-embolization, bilateral leg strength quickly began to improve, but paresthesia persisted. She was soon transferred to a rehabilitation facility for ongoing therapy with hopes for full recovery.

Discussion Non-traumatic epidural haemorrhage, especially in a ventral location, is a rare condition in children. As with our patient, pain is often the presenting symptom followed by neurologic changes. An AVM was the aetiology of our patient's epidural haemorrhage. Prompt laminectomy and interruption of the fistula is the treatment of choice. Early recognition of this condition is vital to neurologic recovery.

320 **MASSIVE CONGENITAL INTRACRANIAL TERATOMA, A RARE CAUSE OF BULGING FONTANELLE AND MACROCEPHALY IN TERM INFANT**

M Choe, T Chatmethakul*, B Merritt, H Imran. *University of South Alabama, Mobile, AL*

10.1136/jim-2017-000697.320

Case report Perinatal brain tumours are uncommon with a prevalence of 1.7–13.5 per 1 00 000 per live births. Intracranial teratoma comprises one third of the total reported cases, mostly diagnosed postmortally. Prognosis worsens with increase in size and decreasing gestational age at diagnosis. Advanced disease at the time of diagnosis and inability to resect these

tumours makes them fatal in almost all cases. Current literature is evident of two case reports with chemotherapy treatments to date. We report a case of term female newborn with massive immature teratoma.

A female infant was born at a gestational age of 37 weeks with an uneventful prenatal and perinatal period. At birth, she was appropriate for gestational age with normal head circumference of 30.5 cm. At day 9 of life, at her first newborn follow up, she was found to have a bulging anterior fontanelle and marked increase in head circumference to 39 cm (>98% ile) which prompted hospital admission. She rapidly deteriorated with apneic episodes necessitating PICU transfer where emergency imaging of the brain showed a huge intracranial supratentorial mass with compression of the posterior fossa and brain stem. Emergent decompressive craniectomy and excision biopsy yielded histopathologic diagnosis of an immature teratoma. After complicated perioperative course with prolonged cardiac arrest requiring cardiopulmonary support, chemotherapy was then discussed. Carboplatin, Etoposide and Vinblastine were started on post op Day 5 which led to a dramatic improvement with ability to wean off cardiopulmonary support, removal of the external ventricular drain and only minimal cytopenia were experienced.

Our case emphasises the importance of recognition of rapid increment in head circumference and identification of uncommon causes of macrocephaly in an infant with a normal delivery. Although most immature teratomas are detected prenatally, some may be missed due to technical difficulties. Albeit with some neurologic deficits, only two survivors were reported in literature who benefited from chemotherapy. Neoadjuvant chemotherapy was effective in initial management and facilitated reduction in size and ultimately allowed for successful resection in both cases. We are hoping the same for this infant.

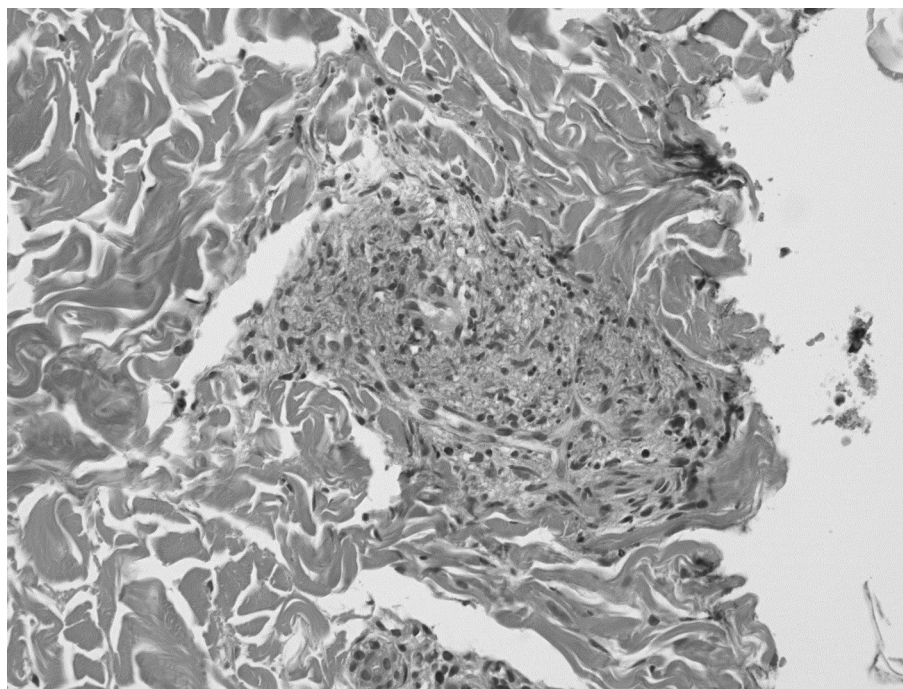
321 **CUTANEOUS POLYARTERITIS NODOSA ASSOCIATED WITH STREPTOCOCCUS PYOGENES INFECTION**

T Chatmethakul*, N Hameed, J Chalam, B Merritt, H Custodio. *University of South Alabama, Mobile, AL*

10.1136/jim-2017-000697.321

Case report A 3 year old female who was treated with intramuscular penicillin for scarlet fever, was reevaluated because of suspected toxic shock syndrome. Erythematous macular rash was noted on the trunk and arms and new purpuric lesions on the legs and thumbs. Empiric therapy with vancomycin, clindamycin and ceftriaxone was started with aggressive hydration and administration of IVIG. However, despite overall improvement, she continued to have fever, arthralgia and persistently elevated inflammatory markers. Blood and throat cultures were negative. ASO titer was elevated. A skin biopsy was consistent with vasculitis (figure 1). RF, ANA, ANCA and C3 and C4 were unremarkable. With no systemic involvement, a diagnosis of cutaneous polyarteritis nodosa was made. Methylprednisolone (1 mg/kg/day) was started resulting in resolution of symptoms.

This report underlies the importance of considering non-suppurative complications of Group A *Streptococcus pyogenes* (GAS) infections. While GAS infection can be self-limiting, non-suppurative complications such as cutaneous polyarteritis nodosa (cPAN) can be seen. cPAN is a vasculitis affecting



Abstract 321 Figure 1 Skin biopsy was consistent with vasculitis

medium sized vessels. In contrast to systemic PAN, cPAN is limited to the skin. However, extracutaneous symptoms may also be seen. Severe cPAN can lead to digital infarction and autoamputation. The aetiology remains unclear. Aside from GAS infections, tuberculosis, hepatitis B and noninfectious illnesses i.e. Crohn's disease have been associated with cPAN. Establishing the diagnosis of cPAN can be difficult given its rarity, similarity of presentation, and association with infection.

322 **GANGLIONEUROMATOUS POLYPOSIS IN A PATIENT WITH IRRITABLE BOWEL SYNDROME**

AW Cohen*, JR Mestre. *University of Alabama, Birmingham, AL*

10.1136/jim-2017-000697.322

Introduction Colonic polyps and associated syndromes in the paediatric population serve as a clinically significant source of morbidity and potential mortality. Often associated with familial origins, sporadic cases can be more challenging to diagnose or determine clinical significance.

Case A 14 year old female sought care from her physician with history of chronic periumbilical abdominal pain, diarrhoea, and episodes of sweating, palpitations, and nausea. She was referred to a paediatric gastroenterologist where a clinical diagnosis of irritable bowel syndrome was made after basic laboratory testing was not suggestive of an organic cause of her symptoms. Due to length of symptoms and findings of iron deficiency anaemia, patient was scheduled for upper and lower endoscopy. Upper endoscopy was without abnormality. Colonoscopy revealed innumerable firm polyps throughout the entire colon and rectum without involvement of terminal ileum. Pathologic examination of polyps was consistent with ganglioneuromatous polyps. Genetic evaluation was negative for common mutations associated with polyposis syndromes (BMP1A, NF1, PTEN, RET, and SMAD4). Patient continued

with similar intermittent symptoms. Follow up endoscopy performed one year after was unchanged with ganglioneuromatous polyps without signs of dysplasia of sampled polyps. Continued follow up planned as well as additional evaluation by a specialist in paediatric polyposis.

Discussion This case demonstrates an abnormal and relatively rare endoscopic diagnosis in a patient who meets clinical criteria for irritable bowel syndrome. The finding of iron deficiency anaemia is a significant finding as it represents the most common presentation for polyps in paediatric patients, painless rectal bleeding. Ganglioneuromatous polyposis can be seen in association with neurofibromatosis type 1, Cowden disease, or juvenile polyposis or as an isolated finding. In the evaluation of juvenile polyps, a detailed family history is of particular importance as guidance for additional testing, intervention, or follow up. Detailed physical exam and review of systems should be performed to evaluate for coexisting symptoms and physical exam findings that could point to one polyposis syndrome or another and modify future screening and evaluation.

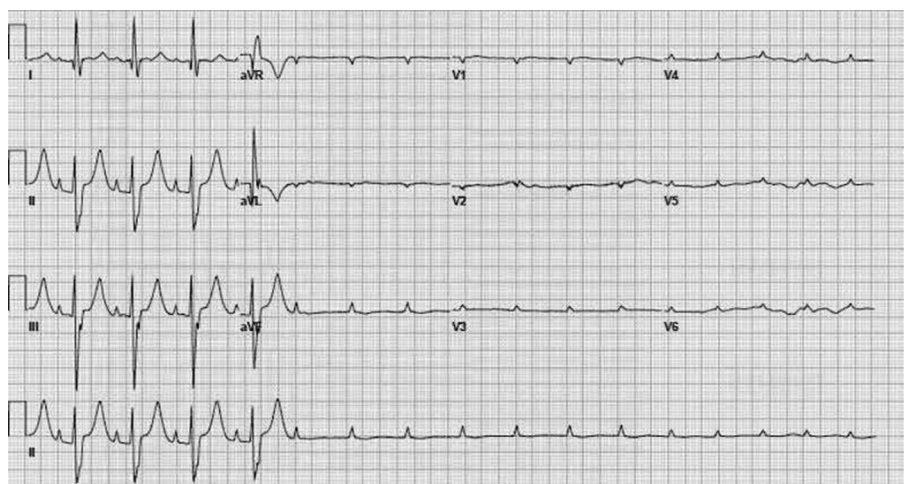
323 **PAROXYSMAL COMPLETE HEART BLOCK IN A CHILD WITH A STRUCTURALLY NORMAL HEART**

JE Cooper*, ST McClanahan, P Glaeser. *University of Alabama, Birmingham, AL*

10.1136/jim-2017-000697.323

Case report A previously healthy 11 year-old African-American male presented with concern for seizure and arrhythmia. On the morning of presentation he had a syncopal episode at school. While his mother was driving him home he had two episodes of generalised body shaking, chest pain and emesis. EMS was called and noted seizure activity and periods of absent pulse and asystole on 3-lead electrocardiogram (ECG).

The patient denied illicit drugs, caffeine or energy drinks. He also denied history of travel outside the state of Alabama,



Abstract 323 Figure 1 Electrocardiogram of normal sinus rhythm and complete atrioventricular block

sick contacts, bug bites, tick exposure, rashes, fever or ill symptoms other than headache and nausea. The mother denied family history of sudden cardiac death, drowning, single car accidents, early myocardial infarction or seizures.

Initial vitals were heart rate of 88, blood pressure 135/78, oxygen saturation of 98% on room-air and afebrile. On exam the he was ill appearing but alert with no apparent distress when not having an episode. He had a regular heart rate with 2+femoral pulses and no murmur noted. The remainder of his exam was unrevealing. His baseline ECG showed normal sinus rhythm with a heart rate in the 80–90 s (figure 1). Episodes began with vibration in his head, loss of consciousness, loss of pulses, flexion of the arms and legs, generalised body shaking for 3–4 s with subsequent return of normal vitals and consciousness. During the episodes his ECG showed complete heart block without ventricular escape rhythm (figure 1). He was found to have normal cardiac anatomy, no signs of infection or electrolyte abnormalities. He underwent emergent placement of a dual chamber pacemaker for paroxysmal complete heart block. Subsequent work-up did not reveal a pathologic aetiology.

macular, erythematous, blanching rash along her chest, back, and groin developed during her ED course.

In the ED, the patient was administered two boluses of normal saline. Laboratory testing was significant for a white blood cell count of $15.44 \times 10^3/\mu\text{L}$, with 86% neutrophils; platelets $118 \times 10^3/\mu\text{L}$; and C-reactive protein 5.37 mg/dL. The total bilirubin was 1.1 mg/dL, alanine aminotransferase 143 U/L, and aspartate aminotransferase 142 U/L. International normalised ratio was 1.5, fibrinogen 390 mg/dL, and lactate dehydrogenase 850 U/L. Intravenous vancomycin and piperacillin-tazobactam were initiated after obtaining blood cultures. She was subsequently hospitalised. Magnetic resonance imaging revealed extensive T2 hyperintensity in the fascial planes of the right chest wall along the axillary region, extending from the infraclavicular location and along the lateral aspect of the chest wall. The patient was diagnosed with acute bacterial fasciitis with secondary toxin-mediated compensated shock. She was successfully treated with IV antibiotics prior to transitioning to an oral regimen and did not require surgical debridement. This case highlights the need for early recognition of necrotizing infections to prevent morbidity and mortality.

324

INFECTIOUS FASCIITIS OF THE CHEST WALL AFTER STRENUOUS ACTIVITY

¹JE Cooper*, ²P Tomeny, ¹CM Pruitt. ¹University of Alabama, Hoover, AL; ²University of Alabama, Birmingham, AL

10.1136/jim-2017-000697.324

Case report A 15 year-old white female presented to the emergency department (ED) after 48 hours of right shoulder pain. The pain started after a week of colour guard tryouts. She described sharp, severe, constant pain located mainly in her axilla. Intramuscular ketorolac and an intramuscular steroid received the day before prior provided temporary pain relief, but her discomfort worsened by the day of presentation.

On physical examination, the patient was febrile to 38.5 degrees Celsius, with a heart rate of 95 and blood pressure of 115/58. She kept her right arm propped on a pillow, internally rotated with 30 degrees of abduction. She had exquisite tenderness to palpation in the right axilla. There was no crepitus. She refused active range of motion of the shoulder. Passive range of motion was limited to less than 90 degrees. A

325

SCLEROSING CHOLANGITIS IN KABUKI SYNDROME: AN UNUSUAL COMPLICATION OF A RARE DISORDER

¹MA Corbera-Hincapie*, ²S Safder, ³R Gonzalez-Peralta. ¹University of Florida, Gainesville, FL; ²Arnold Palmer Hospital, Orlando, FL; ³Florida Hospital, Orlando, FL

10.1136/jim-2017-000697.325

Background Kabuki Syndrome (KS) is a rare disorder characterised by distinct facial and skeletal anomalies, cardiac defects, short stature and developmental delay. Hepatic involvement occurs only rarely. Herein, we describe a child with KS and liver dysfunction that was eventually attributed to sclerosing cholangitis.

Case report A 3-year-old female with KS, repaired VSD and hernia, was evaluated for persistent transaminitis over the preceding 1 year (discovered incidentally). Findings on physical exam were normal except facial dysmorphism consistent with KS. She had no jaundice, hepatosplenomegaly or stigmata of chronic liver disease. Initial laboratory tests showed elevated aspartate transaminase (440 U/L), alanine transaminase (281 U/L), and gamma-glutamyltransferase (408 U/L). Results of

hepatitis A, B and C serology, alpha 1 antitrypsin level and Pi phenotype, antinuclear, liver-kidney-microsomal, antineutrophil cytoplasmic and tissue transglutaminase antibodies were negative; she had detectable smooth muscle antibody (titer 1:20). Abdominal sonogram did not visualise gallbladder but otherwise normal. Liver biopsy showed bile ductular proliferation with pericholangitis and minimal lobular inflammation consistent with sclerosing cholangitis. We initiated ursodeoxycholic acid (URSO; 20 mg/kg/d) with gradual improvement of transaminase levels that have remained normal for 5 years.

Discussion In a series of KS, 2%–21% of patients developed liver disease, ranging from neonatal hyperbilirubinemia, biliary atresia, hepatic fibrosis and sclerosing cholangitis. Clinical data is limited but severe hepatic disease requiring liver transplantation occurs. Our patient's course suggests that URSO can be successfully used to treat sclerosing cholangitis in KS. Our case also highlights the importance of monitoring for liver dysfunction in patients with KS and proceeding with thorough evaluation to arrive at a specific diagnosis and institute appropriate therapy.

326 A RARE CASE OF EPSTEIN BARR VIRUS-ASSOCIATED HEMOPHAGOCYTIC LYMPHOHISTIOCYTOSIS IN AN IMMUNOCOMPROMISED PAEDIATRIC PATIENT

CM Cox*, R Herdes, M Shapiro, B Desselle, C Sandlin. *LSUHSC, New Orleans, LA*

10.1136/jim-2017-000697.326

Case report Kaposiform Lymphangiomas is a rare disorder of lymphatic vessels and is characterised by abnormal lymphatic clusters in various regions of the body. Prognosis can be poor, especially when there is pulmonary involvement. Complications can include pleural effusions, pericardial effusions, and haemorrhage. Current treatment includes chemotherapy and/or immune modulators, specifically vincristine and sirolimus. Patients taking sirolimus have increased risk of infections, including Epstein-Barr Virus (EBV) infection. EBV is a leading cause of hemophagocytic lymphohistiocytosis (HLH), which is a life-threatening disorder of the immune system.

We report a case of a 6-year-old male with a severe form of Kaposiform lymphangiomas who developed EBV associated HLH. The patient presented with persistent fever, intermittent rash, and worsening respiratory distress. He was started on broad spectrum antibiotic therapy for pneumonia, and his Sirolimus was continued upon admission. Due to his worsening clinical status, continued fevers, and progressive pancytopenia, haematology and oncology specialists recommended the initiation of vincristine.

The patient's fevers continued despite these therapies, and his hospital course was complicated by an acute gastrointestinal haemorrhage. His clinical status and pancytopenia continued to deteriorate, prompting consideration of alternative diagnoses. After several days of hospitalisation, viral studies were positive for EBV. A significantly elevated ferritin level (33,000 ng/ml), in conjunction with his other clinical and laboratory findings, led to a diagnosis of EBV associated HLH. Etoposide was given on hospital day 15, but the patient further declined and died the following day.

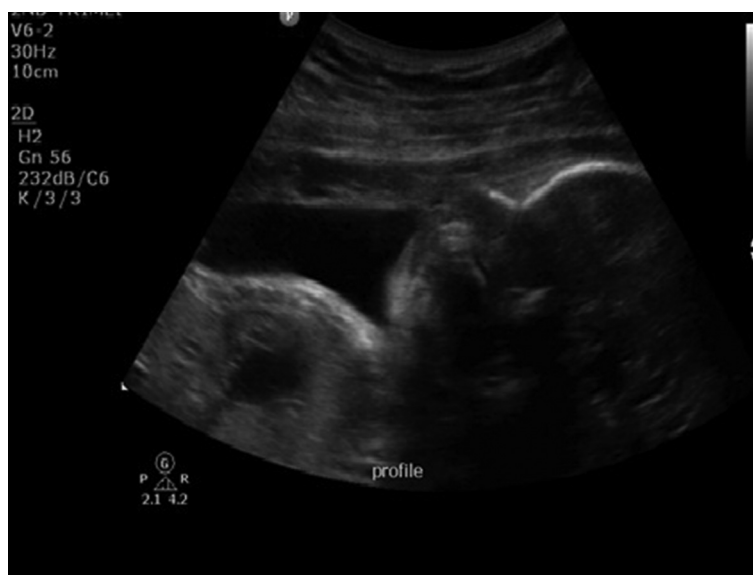
This case highlights the invasive nature of EBV, especially in immunocompromised individuals. It is important for clinicians to recognise the risk factors associated with immunomodulating therapies and consider infectious etiologies early in the patient's clinical course. Though rare, HLH should be considered in patients with persistent fever, pancytopenia, and worsening clinical status in the setting of certain conditions that place patients at increased risk for the disease.

327 TETRAPHOCOMELIA: A CASE REPORT AND LITERATURE REVIEW

J Deitrick*, D Nguyen, W Sessions, M Naqvi, H Heather. *Texas Tech Health Sciences Centre School of Medicine, Amarillo, TX*

10.1136/jim-2017-000697.327

Case report Tetraphocomelia is a condition characterised by severe symmetrical limb reduction in utero. Several syndromes are associated with this finding: Robert's syndrome, Grebe Syndrome, Waardenber syndrome, Holt-Oram syndrome, and Thrombocytopenia with Absent Radius syndrome.



Abstract 327 Figure 1 Unique presentation of a rare congenital anomaly was possibly caused by amniotic bands or a vascular accident in utero

Furthermore, certain in utero exposures, such as thalidomide, alcohol, and cocaine, are also associated with this and similar musculoskeletal deformations. A 24 year old female presented for her 24 week prenatal ultrasound, which revealed incomplete limb development in the fetus. Subsequent to a caesarean section at 38 weeks and 6 days gestation, the newborn female presented with gross musculoskeletal deformities of all four limbs. She was diagnosed with tetraphocomelia but lacked features of a concomitant syndrome and relevant family or birth history associated with this anomaly. Due to the lack of ancillary symptoms, this case did not fit into any specific syndrome and was thought to be the result of a sporadic, non-hereditary limb deficiency involving all four limb buds. While the cause of tetraphocomelia is not fully understood, current literature provides insight into possible genetic and environmental factors contributing to the pathophysiology of this condition. This unique presentation of a rare congenital anomaly was possibly caused by amniotic bands or a vascular accident in utero, resulting in an isolated erroneous occurrence during the critical period of limb development.

328 A CASE OF TOXIC EPIDERMAL NECROLYSIS CAUSED BY CEFADROXIL

TT Doan*. *LSU Health Sciences, Shreveport, LA*

10.1136/jim-2017-000697.328

Case report Toxic epidermal necrolysis (TEN) is a rare and severe adverse mucocutaneous drug reaction characterised by haemorrhagic erosions, erythema, and epidermal detachment due to immune mediated destruction of the epidermis. Drugs such as allopurinol, Trimethoprim-Sulfamethoxazole, cephalosporins, quinolones, and anticonvulsants are assumed to be the main cause of TEN in most case. Early diagnosis and aggressive treatment of TEN is important for the reduction of morbidity and mortality associated with his condition. We present a rare case of successfully recovered TEN caused by cefadroxil, a first-generation cephalosporin. A 4-year-old girl presented to the emergency room with progressively worsened blisters on trunk after the second dose of oral cefadroxil prescribed for otitis media. The lesion started as a diffuse erythematous, maculopapular rash over body, progressed into painful blisters, followed by diffuse exfoliation of the skin involving face, back, abdomen, and bilateral upper and lower extremities over the course of 3 days. Past medical history was significant for chronic otitis media. She has no known allergies and immunisation was up to date. The initial physical exam revealed a listless child with fever of 102.2F. She was tachycardic with heart rate of 160. Ophthalmologic exam showed bilateral periorbital oedema, skin blisters with haemorrhagic crusts involving both upper eyelid, but no injection of conjunctiva and no corneal involvement. She had denuded oral lesions and cracked lips with haemorrhagic crusts. There were multiple, thick bullous lesions filled with turbid fluids and epidermal detachments on face, oral mucosa, neck, abdomen, genital, arms, legs, and feet covering approximately 60% of body surface area. Nikolsky sign is positive. Initial laboratory investigations were unremarkable including negative Herpes simplex virus and Mycoplasma pneumoniae culture. She was admitted to the PICU with burn surgery assistance. Cefadroxil was discontinued immediately. She was managed with intravenous fluids, prophylactic antibiotics, IVIG, hydrotherapy

and proper wound care. Her haemodynamic status was monitored continuously in the unit. She successfully recovered after 2 weeks of hospitalisation and was discharged to home in great condition.

329 PAIN IN THE NECK: A CASE OF INFANTILE TUMORAL CALCINOSIS

B Ducote*, C Jacobs, SN Epps, R Rao, M Murphy. *LSUHSC, New Orleans, LA*

10.1136/jim-2017-000697.329

Case report A four month old full term female presented to her paediatrician after her mother noticed that over the past 3 weeks she lost the ability to roll over and hold her chest up 45 degrees while prone. She had recently been diagnosed with torticollis and plagiocephaly and was seen by occupational therapy, but the onset of this regression prompted her paediatrician to refer her to neurology, who then admitted her for a full workup.

On exam she was difficult to console, head lag was noted, she was unable to actively turn her head, and she cried with passive movement. Initial labs of CBC, CMP, TSH, and FT3 were normal, while ESR and CRP were elevated. MRI of the brain and CT of the neck showed abnormal calcifications at the articulation of the C1/C2 vertebrae likely secondary to tumoral calcinosis. Skeletal survey showed only abnormal calcifications around the cervical vertebrae. Endocrine was consulted and completed a workup for secondary causes of tumoral calcinosis which was negative, with normal values of PTH, calcium, vitamin D, and phosphorus. Hematology-oncology was consulted to rule out neoplasm and suggested a biopsy. ENT performed a biopsy of the lesion which showed calcified material without inflammatory changes confirming our presumed diagnosis of tumoral calcinosis.

The patient was started on gabapentin for pain management per neurology recommendations. She was given NG feeds until her pain improved and she could tolerate full feeds by mouth. She was also given 5 days of steroids to decrease inflammation in the area, and the range of motion of her neck improved throughout her hospital stay. MRI after biopsy showed decreased residual calcifications around the C1/C2 vertebrae without evidence of spinal cord impingement. Over the next two months, she regained head control and better range of motion of her neck.

Tumoral calcinosis consists of calcium crystal deposits in periarticular soft tissues. It can be hereditary with hyperphosphatemia, a complication of dialysis, or a rare isolated finding which was likely what our patient had. In one previously reported case study in an infant, biopsy was found to be curative. Tumoral calcinosis is a rare diagnosis and cause of torticollis and loss of developmental milestones especially in infants.

330 UNUSUAL OSTEOMYELITIS IN AN INFANT

M Duplantier*, SN Epps, M Heffernan, A Bauchat, R Gardner, A Messer. *LSUHSC, New Orleans, LA*

10.1136/jim-2017-000697.330

Case report Leg pain in an infant can be difficult to detect and diagnose. Osteomyelitis is rare in a clinically well-

appearing infant, though more common when *Pseudomonas* is the underlying aetiology. In this case, initial concern for non-accidental trauma (NAT) in an otherwise healthy infant led to a diagnosis of osteomyelitis secondary to an unusual organism. Based on benign initial evaluation, there was potential for this patient's infection to go undiagnosed and untreated. However, our Orthopaedic Surgery team reviewed her case and uncovered her diagnosis.

Here we describe a 10-month-old female initially diagnosed with a proximal femur buckle fracture and found to have osteomyelitis and *Pseudomonas stutzeri* bacteremia. She presented with refusal to move left leg as well as upper respiratory symptoms. There was no history of trauma and, on exam, she was febrile with pain on left hip manipulation.

Evaluation was significant for a subacute proximal femur buckle fracture seen on x-ray. Subsequent MRI findings were consistent with surrounding osteomyelitis. On presentation, white blood cell count was $12.32 \times 10^3/\text{UL}$, C-reactive protein was $<0.5 \text{ mg/dL}$, which later rose to 1.4 mg/dL , and erythrocyte sedimentation rate was 37 mm/hr . Clinically, the patient was well-appearing with no external abnormalities. Blood culture later grew *Pseudomonas stutzeri* at 1.05 days. A respiratory viral panel revealed influenza A and adenovirus.

The Infectious Disease team recommended IV clindamycin and ceftazidime for 7 days to treat susceptible *Pseudomonas* as well as typical infectious etiologies. She was then transitioned to oral clindamycin and ciprofloxacin to complete a 4 week course. A Spica cast was placed; no surgical intervention was required.

The differential diagnosis for leg pain in an infant is broad, which may delay prompt diagnosis. Trauma and osteomyelitis are occasionally competing diagnoses due to similarities on initial evaluation and imaging, particularly in an otherwise well-appearing, non-ambulatory infant. This case serves to increase initial indices of suspicion for both diagnoses and demonstrates that these diagnoses are not mutually exclusive and require an interdisciplinary team of experts for best care.

331 NEONATAL CONJUNCTIVITIS: AN UNUSUAL CAUSE OF A COMMON COMPLAINT

MN Frascogna*, L Moore. University of Mississippi Medical Centre, Jackson, MS

10.1136/jim-2017-000697.331

Case report Infectious conjunctivitis is a common presentation in neonates and young children. The disease course is often benign and can be easily treated in most cases. However, it is important to be aware of the more serious etiologies that can become lethal if not identified early and promptly treated. In this report, we present a rare case of *Neisseria meningitidis* as the primary cause of conjunctivitis in an otherwise healthy infant.

A 20 day old African American female born at 39 weeks via normal spontaneous vaginal delivery presented to the paediatric emergency department with a two day history of right eye swelling and discharge. The patient's mother denied any fever, irritability, rash, or upper respiratory symptoms. Pregnancy and delivery were largely uncomplicated and screening labs were reportedly negative for any sexually transmitted infections.

In the emergency department, patient was noted to have significant mucopurulent discharge from the right eye with

associated eyelid swelling and erythema. Slit Lamp and fundoscopic exam showed conjunctival injection and chemosis, but was otherwise normal. The remaining exam was unremarkable. The patient underwent a full septic workup including ocular, CSF, blood, and urine cultures and was admitted for empiric antibiotic treatment of the presumed causative organisms, *Neisseria gonorrhoeae* and *Chlamydia trachomatis*.

The patient was started on intravenous Ampicillin and Cefotaxime and Erythromycin ophthalmic solution. Symptoms improved after twenty-four hours of treatment and infectious workup remained negative; however, on day two of hospitalisation, ocular cultures returned positive for *Neisseria meningitidis*. Ampicillin was stopped and intravenous Cefotaxime was continued. The Health Department was notified per protocol, and chemoprophylaxis for contacts was not recommended due to strict confinement of the infection to the eye. The patient completed five days of intravenous antibiotics with marked improvement. She was discharged home to complete a 14 day course of oral and ophthalmic Erythromycin. At a 2 week follow up appointment with ophthalmology, symptoms had completely resolved and no ocular abnormalities were noted.

332 SALMONELLA IN THE SCROTUM: NOT YOUR TYPICAL NEONATAL INFECTION

E Friedrich*, R Welliver, S DeLeon. University of Oklahoma Health Sciences Centre, Oklahoma City, OK

10.1136/jim-2017-000697.332

Case report A 17 day old male, born at 38 weeks without complications, presented with a 7 day history of irritability, and fever on day 2 of illness. On the day of fever, his paediatrician prescribed amoxicillin/clavulanic acid for unknown reasons, and he then remained afebrile until admission. Two days prior to presentation, his scrotum became swollen and tender, which prompted the family to seek further care. In the emergency room, a sepsis work up and testicular ultrasound (US) with doppler was performed. The work up yielded no evidence of systemic infection. His only abnormal lab was a C-reactive protein of 32 mg/dL . The US showed a right scrotal abscess with blood flow to both testes. Urology recommended admission for incision and drainage (I and D) of the abscess. A renal US and voiding cystourethrogram (VCUG) were obtained to evaluate for vesiculo-ureteral reflux or abnormal fistula connexion and were negative. He was started on intravenous vancomycin, ampicillin, and gentamicin. The I and D was performed with removal of 50 cc of purulent material, along with a right orchiectomy due to necrosis. The tissue culture grew a Salmonella species susceptible to ampicillin, which coverage was then narrowed to. He received 14 days of antibiotics. His mother denied exposure to raw chicken, reptiles, or sick contacts. A granulocyte dihydrorhodamine fluorescence test showed normal NADPH oxidase activity, decreasing the likelihood of chronic granulomatous disease.

Salmonella typically affects the gastrointestinal tract and is most often associated with exposure to raw chicken or reptiles. Most cases are seen in children under the age of 5. All other reported cases of Salmonella orchitis are in immunocompromised patients or occur in areas where Salmonella is an endemic infection. Extra-intestinal focal infections typically result from hematogenous spread, though anatomic urologic abnormalities can predispose to isolated genitourinary (GU)

infections. Management of extra-intestinal infections includes I and D and antibiotics. This case is unique because our patient's GU imaging was normal, blood culture was negative (although he had received antibiotics prior to admission), had no history of exposure, and had no risk factors for immunodeficiency other than age.

333 CASE REPORT CYCLIC NEUTROPENIA AND ASSOCIATED AMYLOIDOSIS

KM Galipp*, C Ilonze, K Shah, A Rughani, S Travis, A Nayak, WF Kern, K Wierenga, WH Meyer. *University of Oklahoma Health Sciences Centre, Oklahoma City, OK*

10.1136/jim-2017-000697.333

Study purpose Cyclic neutropenia is a rare hereditary disorder, characterised by recurrent neutropenia, cycling at about 3 week intervals, with variable associated symptoms including oral ulcers and fever. There are 4 reported cases of cyclic neutropenia associated with chronic inflammation leading to development of reactive AA amyloidosis. One patient also presented with amyloid goitre. We report a new case of cyclic neutropenia with associated renal and thyroid amyloid.

Method (case report) A 12-year-old female presented with a 1 month history of thyromegaly, and recurrent aphthous ulcers associated with fevers. Laboratory workup showed severe neutropenia, anaemia, azotemia, and abnormal thyroid function, with an absolute neutrophil count – 0/ μ L, haemoglobin – 9.0 g/dL, serum creatinine – 1.89 mg/dL, and uric acid – 9.0 mg/dL. Thyroid stimulating hormone was elevated – 12.5 μ IU/mL, and normal free T4. Urinalysis showed 2+protein, 2 +blood, and 5–10 urine red blood cells/hpf. Chest radiograph showed mild narrowing of the trachea from thyroid compression. Bone marrow biopsy showed a hypocellular marrow, with tri-lineage hematopoiesis, left shifted myeloid maturation with very rare mature neutrophils. Both renal biopsy and thyroid fine needle aspiration revealed abundant amyloid. Of note, her father had AA amyloidosis, resulting in end-stage renal disease (ESRD) requiring hemodialysis, and recurrent aphthous ulcers. The family history suggested a familial predisposition. Genetic testing revealed a pathogenic ELANE c.358 A>T gene mutation with autosomal dominant inheritance confirming the diagnosis of cyclic neutropenia. We treated our patient with daily granulocyte colony stimulating factor to reduce the burden of chronic inflammation induced by cyclic neutropenia, and to preserve renal and other end organ function affected by further amyloid deposition.

Summary of results Proband with ELANE gene mutation positive cyclic neutropenia, amyloidosis of thyroid and kidney, with a positive paternal history of AA amyloidosis resulting in ESRD.

Conclusions Cyclic neutropenia may result in chronic inflammatory states leading to secondary amyloidosis.

334 ALVEOLAR CAPILLARY DYSPLASIA PRESENTING AS REFRACTORY PULMONARY HYPERTENSION

J Gallois*, J Patrick, J Surcouf. *LSUHSC School of Medicine, New Orleans, LA*

10.1136/jim-2017-000697.334

Case report Alveolar capillary dysplasia with misalignment of the pulmonary veins (ACDMPV) is a developmental anomaly

of the pulmonary vasculature that takes place in the late canalicular to early saccular phase of lung development. This maldevelopment results in the failure of the formation of the normal air-blood diffusion barrier. It is almost universally fatal. 90% of those effected are term gestation, 60% present with cyanosis within the first 48 hours of birth, and 80% of cases are associated with other congenital malformations. Ninety percent of cases are associated with a genetic mutation on the FOXF1 gene on chromosome 16, and 90% of cases are *de novo* mutations. Diagnosis is confirmed by lung biopsy or autopsy, where pathologic features include a paucity of alveolar capillaries, widened alveolar septae, muscularization of pulmonary arterioles, and usually misalignment of pulmonary veins in the bronchovascular bundle. No current supportive therapies have been shown to change mortality.

We present a term female infant born to a 33 year old mother with an unremarkable prenatal course. The infant was initially stable, then at six hours of life she was transferred to the neonatal intensive care unit for cyanosis and hypoxia with oxygen saturations in the 50's. She was ultimately transferred to a tertiary care facility for concerns of a congenital heart defect versus persistent pulmonary hypertension (PPHN). The echocardiogram at admit revealed a structurally normal heart and evidence of PPHN. Other congenital malformations were not found. Although she initially stabilised with medical management including inhaled nitric oxide, her PPHN progressed despite maximal support. She significantly decompensated with a prolonged code while being placed on extracorporeal membranous oxygenation (ECMO) on day of life 2, requiring simultaneous initiation of therapeutic hypothermia. After two failed weans off ECMO, a lung biopsy was performed on day of life 25 which revealed ACDMPV. With the family at the bedside, support was withdrawn.

The incidence of ACDMPV is rare, but is increasingly recognised. Early diagnosis may prevent unnecessary therapies and prolongation of treatment. Neonates with refractory PPHN, especially if associated with anomalies, should prompt evaluation for ACDMPV.

335 ACTINOMYCES EPIDURAL ABSCESS: A VIRTUALLY UNHEARD OF PROCESS IN THE VIRTUAL AGE

AL Gibson*, S Liu, M Naifeh. *OU Children's, Edmond, OK*

10.1136/jim-2017-000697.335

Case report *Actinomyces* has been termed the 'great pretender' in many case reports due to its ability to invade various parts of the body causing abscesses. *Actinomyces* epidural abscesses are virtually unheard of in the paediatric population, and only sparse literature exists in the adult population, with often only a few spinal segments involved. As a slow growing anaerobic gram positive bacteria, it typically spreads through the body via sinus tract formation.

Here we report a 3 year old female with multiple congenital anomalies including scoliosis, repaired tethered cord, history of syrinx and hydrocephalus at birth with a ventriculoperitoneal (VP) shunt, who on MRI was found to have a highly invasive epidural abscess extending from the cervical spine to the sacrum and into the surrounding scalenes and psoas muscles. The patient initially presented with clear signs of meningitis including fever, lethargy and decreased activity and was too ill to undergo imaging on admission.

Cerebrospinal fluid from her VP shunt did not reveal an infectious cause for her symptoms, so a lumbar puncture was performed which collected purulent fluid from her epidural abscess. This fluid grew *actinomyces turicensis* and *actinomyces europaeus*. After clinical improvement, spinal imaging showed a dorsal to dural sinus tract at L4 which is likely the point of initial bacterial invasion.

After thorough literature review, this is the largest epidural abscess that has been reported. While the likelihood of treating another patient with the same complex medical history is low, this case underscores the importance of prompt and repeat imaging in any patient with symptoms of meningitis who does not show clinical evidence of improvement on broad spectrum antibiotics as *Actinomyces* can present this way.

336 A NOVEL *DE NOVO* HETEROZYGOUS MUTATION IN THE *PCDH17* GENE WITH MICROCEPHALY, DEVELOPMENTAL DELAY, AND ACUTE LYMPHOBLASTIC LEUKAEMIA

*KM Gleditsch, R Gardner, Y Lacassie. Louisiana State University Health Science Centre, New Orleans, LA

10.1136/jim-2017-000697.336

Case report We present an 11 year old girl evaluated by genetics at birth due to microcephaly. Chromosomes and a microarray were normal. At the age of 3 she developed pre-B-cell acute lymphoblastic leukaemia (ALL). She completed treatment in 2012 and has been doing well in the interim. During and after treatment she exhibited significant developmental delay and neurocognitive deficits. At age 11 her height and weight were at or below the 5th centile and head circumference was well below the 2nd centile (approximately 6 standard deviations below the mean and corresponding to the 50th centile for a 9-month-old girl). Bone age was appropriate. She had a distinctive triangular face with micrognathia and a pointed nose resembling a Seckel-like syndrome. The patient also had clinodactyly of the fourth toes, zygodactylous triradius involving the 2nd and 3rd left toes, tendency to Sydney line in the right palm and a radial loop in the left middle finger. Whole Exome Sequencing (WES) was performed on the patient as well as her biological parents (trio). A *de novo* heterozygous mutation in the gene *PCDH17* with potential relation to the phenotype was discovered. This c.716dupA variant causes a frameshift starting with codon Asparagine 239, changing this amino acid to a Lysine residue and creating a premature stop codon at position 34 of the new reading frame denoted p. Asn239LysfsX34. This variant is predicted to cause loss of normal protein function via protein truncation or nonsense-mediated mRNA decay. To the best of our knowledge there are no reports of pathogenic variants of this gene in the literature. *PCDH17* is a member of the protocadherins family which is important in synaptic function in the central nervous system. This gene is highly expressed in areas of the brain involved in higher cortical function and speech. Research that has been done with respect to methylation of this gene and correlation with poor prognosis in patients with acute lymphoblastic leukaemia is of great interest in this case. We feel that this is a clinically significant finding that may shed light on the role of this gene in neural and hematologic development.

337 FRACTURED CORPUS CAVERNOSA IN A PAEDIATRIC PATIENT

BC Gruenberg*, D Mortel, A Bogie. University of Oklahoma, OKC, OK

10.1136/jim-2017-000697.337

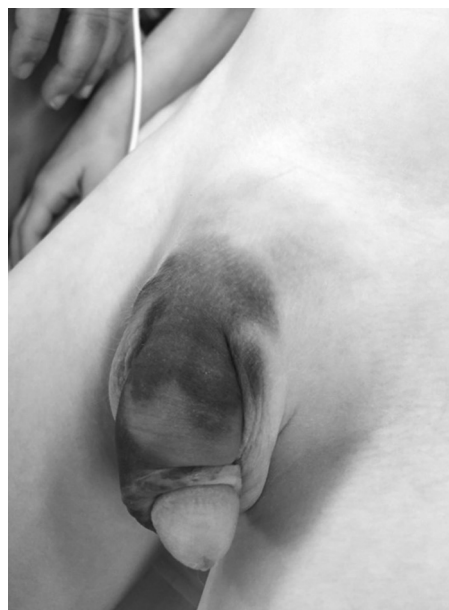Case report Our patient is a 7 year old male who presents with complaints of penile pain. The patient was riding 'piggy back' on his grandmothers back on the morning of the injury when she tripped and fell. The patient fell off of her back and into the staircase, hitting his penis directly on the stair case railing. He reports sudden onset penile pain after the fall. On arrival he denied any difficulty or pain with urination, and reported pain only with movement.

His physical exam was significant only for ecchymosis and swelling of his penile shaft. Urinalysis showed no hematuria.

Penile ultrasound noted an area of discontinuity (6 mm) along the right corpora cavernosa with some soft tissue extrusion, consistent with a fracture of his right corpus cavernosum.

Paediatric Urology was consulted and he was taken to the OR.

In the OR a flexible cystoscopy showed an uninjured urethra and bladder. The penis was then degloved circumferentially all the way down to the base of the penis. An artificial erection was then performed, and extravasation of fluid was noted posterior to the urethra. However, no hole was readily apparent. The urethra was mobilised off the right corpus cavernosum and the corporeal tear was noted in this area, was approximately 7 mm. The corporeal injury was then closed and the shaft skin reapproximated to the preputial collar. Our patient had no postsurgical complications, his pain was well controlled with NSAIDs, and he was discharged home on post-op day one.



Abstract 337 Figure 1 Corporeal injury

338 THE TROUBLE WITH LETTING GO: NEONATE WITH HYPOTONIA

S Gu*, L Barbiero, SL Nelson. *Tulane University, New Orleans, LA*

10.1136/jim-2017-000697.338

Case report A preterm male neonate born to a G2P2 mother presented to the NICU with severe hypotonia from birth. Maternal history included negative maternal labs, adequate prenatal care, unremarkable prenatal ultrasounds throughout pregnancy, and administration of magnesium. Family history was negative for previously diagnosed neurologic, autoimmune, or genetic conditions. Physical exam was remarkable for generalised hypotonia, tenting of upper lip, bilateral talipes equinovarus, arthrogryposis, intact reflexes, and lack of tongue fasciculation. Genetics and Neurology were consulted given exam findings. Work up included initial evaluation for sepsis, measurement of serum electrolytes and ammonia, and meconium drug screen, which were all unremarkable. Head ultrasounds and brain MRI were normal. Initial magnesium level elevated, but despite normalisation, patient remained hypotonic. Creatine kinase, direct bilirubin, and GGT were noted to be elevated. Subsequently, it was noted that the patient's mother had difficulty with release of grasp during a hand-shake, and further elucidation revealed a family history of multiple maternal family members with varying degrees of weakness. The diagnosis was confirmed when DNA testing revealed one expanded DMPK allele of ~1300 CTG repeats.

Congenital Myotonic Dystrophy (CMD) type 1 is an autosomal dominant, multisystem disorder that occurs as a result of CTG repeat expansion in the non-coding region of the DMPK gene on 19q13 that can expand in successive generations, resulting in earlier presentation of the disorder. Patients with greater than 50 CTG repeats have a >99% probability of manifesting signs and symptoms of CMD. The differential for hypotonia in neonates is broad and should include: central or peripheral nervous system abnormalities, myopathies, genetic disorders, endocrinopathies, metabolic diseases, drug-induced, and electrolyte derangements. Our patient was preterm and his mother was given magnesium perinatally, which were initial considerations as etiologies. However, suggestive physical exam findings and a detailed family history were essential to diagnosis and subsequent confirmatory genetic testing. As recent studies have discussed, targeted genomics in critically ill newborns is helpful in diagnosis, anticipatory guidance, and decision-making for parents.

339 20 YEAR OLD WITH ABDOMINAL & FLANK PAIN

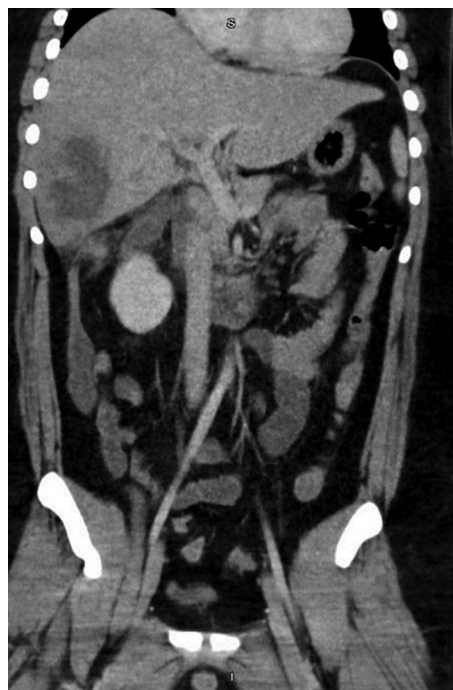K Gutermuth*, J Haupt, A Sorrentino. *University of Alabama, Birmingham, AL*

10.1136/jim-2017-000697.339

Case A 20-year-old male with history of autism and obesity was seen in the ED a week prior for acute right flank pain that improved with ibuprofen. Exam was unremarkable, and he was discharged home. He was seen by his PCP and had a urinalysis significant for hematuria, proteinuria, and hypertension. Later, he developed fever, abdominal pain and diarrhoea, and returned to the ED. Upon arrival, he was well-appearing, and his fever and abdominal pain had resolved. Lab work was notable for elevated leukocytes and inflammatory markers. CT abdomen was obtained, initially non-contrast for possibility of

nephrolithiasis, followed by contrast CT which showed appendicitis in the right upper quadrant adhered to the liver edge, with a large liver fluid collection consistent with an abscess.

Discussion The case stresses the importance of consistent follow-up, return precautions, and clinical acumen. The symptoms of flank pain, progressive hematuria/proteinuria, abdominal pain, nausea, vomiting, diarrhoea, and fevers point to a more insidious pathology. Initial history and resolution of fever and discomfort, combined with outpatient urinary findings suggested possible renal calculi, which were not seen on CT. Surgery evaluated the patient due to concern for perforated appendix and hepatic abscess. IR drained 280 cc dark brown purulent material from the liver, and drain was left in place. Interval appendectomy was performed, and he had an uncomplicated recovery.



Abstract 339 Figure 1 Appendicitis in the right upper quadrant adhered to the liver edge, with a large liver fluid collection consistent with an abscess

340 EARLY CONGENITAL SYPHILIS: COMMON BUT NOT SO MUCH

V Habet*, B Casey, L Powell, C Saylor, KM Gleditsch, C Morrison, G Hescocock, RE Begue, C Sandlin. *Louisiana State University Health Sciences Centre, New Orleans, LA*

10.1136/jim-2017-000697.340

Purpose of study Syphilis, the 'great imitator', can have a wide spectrum of clinical manifestations, ranging from asymptomatic to early infant death. In the United States, the number of congenital syphilis cases is rising with 16 per 1 00 000 live births reported in 2016, a 27.6% increase since 2015. We discuss the case of an infant with congenital syphilis who presented with classical but nonspecific symptoms.

Methods used Retrospective chart review.

Summary of results A 3-month-old full term female was born via C-section to a mother with active herpes and gonorrhoea treated in the third trimester. The patient presented with fever

and discrete, annular, scaly plaques on her trunk and extremities that progressed to desquamation of her hands and feet. She was initially admitted to the Haematology service for severe anaemia. A skeletal survey revealed lytic bone lesions concerning for Langerhans cell histiocytosis. Bone scan, PET scan, and MRI brain/spine confirmed lesions of the axial and appendicular skeleton without involvement of other organs. CT showed inguinal and iliac lymphadenopathy, and repeat skeletal survey 18 days later showed progression of permeated lytic lesions to transverse fractures and periostitis of the bilateral proximal tibias and left radius. Sawtooth appearance of the radial metaphyses and Wimberger's sign of the proximal tibia were highly suggestive of congenital syphilis. RPR, VDRL, and FTA-ABS were all reactive, and the CSF VDRL was nonreactive. Skin biopsy showed spongiform and lichenoid dermatitis, and immunohistochemistry revealed numerous spirochetes in the epidermis. The patient received standard therapy of intravenous Penicillin G for 10 days, and a repeat RPR 3 months after diagnosis had declined eightfold.

Conclusions The mother's RPR was nonreactive early in gestation, but it was reactive when drawn following the patient's diagnosis. This suggests maternal seroconversion and the infant's contraction of syphilis later in gestation. Our case emphasises the importance of having a high index of suspicion for congenital syphilis in infants presenting with a combination of clinical manifestations including fever, rash, rhinitis, jaundice, hepatomegaly, lymphadenopathy, and hematologic or skeletal abnormalities.

341 NEUROBLASTOMA WITH AN INTRIGUING CLINICAL PRESENTATION

RG Hazboun*. *University of Florida, Jacksonville, FL*

10.1136/jim-2017-000697.341

Case report Neuroblastoma is the most common extra-cranial malignant solid tumor in children. Neuroblastoma signs and symptoms vary with the site of the primary tumor presentation and the extent of metastasis. Generally the signs and symptoms include abdominal pain, abdominal mass, anorexia, weight loss and limping. We present a case of a 20-month old boy who presented to the primary care clinic with asymmetry in the back muscles which was noted by the parents 2 months ago and is not resolving. The child also was noted to have a new onset abnormal gait, specifically described as

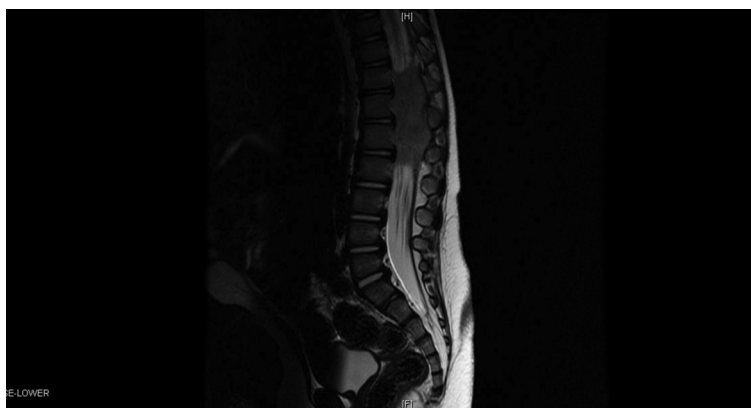
unsteadiness and difficulty to rise up from sitting, although he had achieved this developmental milestone at the expected age previously. On examination the patient had a positive Gower's sign. Examination of the back showed a para spinal mass well defined not tender with no overlying skin changes. He was referred to orthopedics where a spine MRI was ordered and showed a spine mass extending from T12 to L2 with the characteristic dumbbells sign. Since that mass was suspicious for malignancy and more specifically a neuroblastoma, the patient was referred to the Oncology department at our institution. An ultrasound guided biopsy of the para spinal mass was obtained and sent to the pathology lab which showed findings consistent with a ganglioneuroblastoma (intermixed type) with favorable histology.

342 A CURIOUS CASE OF A FOREIGN BODY IN THE APPENDIX OF A PEDIATRIC PATIENT

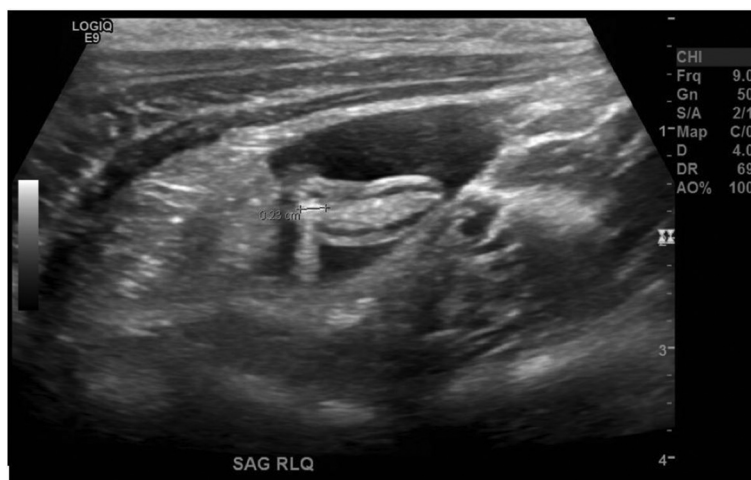^{1,2}MR Hincapie*, ^{1,2}K Chen. ¹University of Florida, Jacksonville, FL; ²Wolfson Children's Hospital, Jacksonville, FL

10.1136/jim-2017-000697.342

Case report A foreign body within the appendix is an entity that has been rarely documented over the years and must be considered by the pediatrician. Foreign bodies ranging from teeth, drill bits, needles, bullets, seeds, and others have been documented. Management is not standardized to date; however, elective appendectomy has proven to be effective as treatment as possible consequences involve secondary infection and appendicitis. Challenges arise as the time course for appendiceal signs may differ from patient to patient. This unique case highlights the importance of the physician recognizing the possibility of a foreign body within the appendix as it may require timely surgical intervention with appendectomy. A 2 year old healthy female presented to an outside ED with two days of worsening oral intolerance, worsening nonspecific abdominal pain, and nonbilious nonbloody vomiting. She otherwise had no complaints of diarrhea, blood in stool, respiratory distress, or chest pain. Her family history and travel history was noncontributory. Forty-eight to 72 hours after admission, she began having worsening right lower quadrant pain and was febrile with a temperature of 38.3 degrees Celsius, possibly indicating appendicitis. There continued to be a lack of foreign body progression on serial plain radiographs. Several confirmatory preoperative ultrasounds confirmed a



Abstract 341 Figure 1 Spine mass extending from T12 to L2 with the characteristic dumbbells sign



Abstract 342 Figure 1 Foreign body within the appendix

foreign body within the appendix. Ultimately, pediatric surgery conducted a laparoscopic appendectomy which successfully confirmed the foreign body within the appendix. She was ultimately discharged in stable condition.

343 AMELOBLASTOMA IN AN ADOLESCENT

BD Hodge*, B Googe, B McIntyre. *University of Mississippi School of Medicine, Jackson, MS*

10.1136/jim-2017-000697.343

Case report Ameloblastoma is a generally benign neoplasm that arises from the odontogenic epithelium and accounts for 1% of all tumors and cysts of the jaw. It presents as a slow-growing, painless mass and appears radiographically as a radiolucent lesion with or without cortical expansion. Although it most commonly presents in the posterior mandible of middle-aged adults, we present a case of anterior mandibular ameloblastoma in an adolescent.

A 14-year-old African-American male with a history of heart murmur, ADHD, and psychosis presented to clinic with a two-month history of facial swelling of the lower left anterior jaw. The patient reported loosening of teeth in the anterior mandible but denied fever, facial pain, trismus, or dysphagia. Physical exam revealed moderate left-sided facial fullness of the anterior mandibular with no associated erythema or warmth. Moderate buccal and lingual involvement was noted from the left midbody to the symphysis with gross displacement of the teeth in the region of expansion. Mucosa remained intact and there was no tenderness to palpation. Radiography revealed a radiolucent expansile mass extending from left distal body to the right of the mandibular midline. Biopsy of the mass confirmed a diagnosis of invasive ameloblastoma with cystic change. The patient was referred to plastic surgery for jaw resection and fibula free flap reconstruction in concordance with oral maxillofacial surgery.

Ameloblastoma is a benign odontogenic neoplasm that can erode bone and adjacent structures with the potential to cause facial deformity, malocclusion, and displacement of teeth. Ameloblastoma has a predilection for the mandible, and in African-Americans, occurs most frequently in the anterior region of the jaw. Incomplete growth of the jaw in a child or adolescent is an important consideration in surgical management as jaw resection can cause future deformity. However, in

cases where the mass causes facial distortion and dysfunction, resection with flap reconstruction will restore aesthetics and function of the jaw. Post-operative follow-up is an important aspect as 50% of ameloblastoma recurrences happen within 5 years. Early diagnosis and referral for wide resection and reconstruction are vital to minimize its destructive effects on local tissue and sequelae from aggressive expansion.

344 A RARE CASE OF DEFECTIVE THYMUS EMBRYOGENESIS IN UNCONTROLLED MATERNAL DIABETES LEADING TO COMPLETE DIGEORGE ANOMALY

AR Jain*, V Linga, R Mattamal, S Parat. *Texas Tech University Health Science Center, Amarillo, TX*

10.1136/jim-2017-000697.344

Case report Complete DiGeorge anomaly (DGA) is characterized by the absence of the thymus, T- B+ NK+ SCID, facial dysmorphism, congenital heart disease and neonatal hypocalcemia. Common etiologies include Chromosome 22 deletion - DiGeorge Syndrome, CHARGE syndrome, and maternal diabetic embryogenesis.

A 35 week large for gestational age preterm male born via c-section to a 33 yo G5P6 woman with poorly controlled type II Diabetes Mellitus presented to the NICU for prematurity. Fetal US findings were positive for septal hypertrophy. Dysmorphic features like abdominal outpouching, rib, and vertebral anomalies were identified. At DOL 10, he had late onset hypocalcemia seizures. Further evaluation showed low parathyroid hormone levels, an absent thymus shadow on chest X-ray and a mild aortic coarctation on TTE. These findings were strongly suggestive of DiGeorge syndrome.

Both newborn screens (NBS) reported low T-cell receptor excision circle (TREC). Additional workup demonstrated low levels of Absolute Lymphocyte Count and low IgG, IgA, IgM, and IgE levels. Lymphocyte Mitogen Panel (LPMGF) was abnormal and lymphocyte subsets showed low CD3, CD4, CD8 NK cells and normal B cells. The comprehensive SCID Panel was grossly abnormal. These findings were consistent with T negative, B positive, NK cell-positive SCID (T-,B+,NK+). Whole exome sequencing, FISH, and chromosomal microarray were negative for DiGeorge Syndrome.

He was discharged on NG tube feeds, a prophylactic antibiotic regimen with oral Fluconazole, trimethoprim-sulfamethoxazole and Azithromycin, and education regarding strict isolation. Currently, he gets subcutaneous immunoglobulin infusions weekly for his hypogammaglobulinemia is closely followed up in the clinic and is waiting to be accepted for thymus transplantation.

Recent studies have shown that the most common etiology for the 'deletion-negative' subset of DGA is diabetic mother embryogenesis.

Although this is a rare disorder, we as pediatricians need to have a high index of suspicion in infants of diabetic mothers and detect this disorder pre-symptomatically, such that effective treatments can be applied. Prophylactic antibiotic use, timely transplant, and close clinical follow are crucial in the management of this condition.

345 INVASIVE HAEMOPHILUS INFLUENZAE TYPE A DISEASE IN A CHILD WITH A COMPLEMENT DEFICIENCY

JD Jones*, B Merritt, M Rendon Bernot, EM Perez García. *University of South Alabama, Mobile, AL*

10.1136/jim-2017-000697.345

Purpose of study 3-year-old African-American male presented with a temperature of 106.1°F, abdominal pain, myalgia, and neck stiffness. His past medical history was non-contributory. Initial laboratory studies revealed an elevated CRP of 18.4 mg/dL. His CSF analysis revealed 118 cells/mL with 80% PMNs, protein of 86 mg/dL, glucose of 11 mg/dL and a positive PCR for *Haemophilus influenzae* (Hi) which was later found to be serotype A (HiA). Treatment with ceftriaxone was initiated in association with a short course of therapy with dexamethasone for HiA meningitis. On hospital day 12, and after discontinuation of his steroid therapy, he developed left elbow septic arthritis which prompted an arthrocentesis. The synovial fluid Gram stain revealed Gram negative rods with a negative culture. Given the development of septic arthritis which was thought to be associated with disseminated Hi infection, he received an additional 14-day course of antibiotic therapy with Ceftriaxone. He underwent an immunologic evaluation which revealed a complement deficiency. Subsequently he was immunized against *Neisseriae meningitides* and *Streptococcus pneumoniae* prior to discharge.

Conclusions The clinical presentation of invasive disease caused by HiA and *Haemophilus influenzae* type B (HiB) is indistinguishable. Given the significant population uptake of Hib vaccine, the possibility of non-type B types of Hib should be considered in children with initial diagnosis of Hi infection by PCR performed in samples from sterile sites. Children with invasive infections caused by HiA should be evaluated for the possibility of associated terminal complement deficiencies. As illustrated by this case, the antibiotic and anti-inflammatory management of patients with HiA invasive disease mirrors the therapeutic approach utilized for patients with HiB infections.

346 WHY SO YELLOW? A CASE OF VANISHING BILE DUCTS

M Kaufman*, E Hauck, P Tyson. *Our Lady of the Lake Regional Medical Center, Baton Rouge, LA*

10.1136/jim-2017-000697.346

Introduction Vanishing bile duct syndrome (VBDS) is a rare cause of cholestatic liver injury resulting in the loss of intrahepatic bile ducts. Typical symptoms include pruritus, fatigue, jaundice, transaminitis, and hyperbilirubinemia. There are several known associations including drug-induced liver injury, infectious causes, Hodgkin's lymphoma, and autoimmune disorders.

Case presentation A 14 y/o M with a history of Hodgkin's lymphoma in ninth year of remission was admitted for jaundice, fatigue, and weight loss associated with transaminitis and direct hyperbilirubinemia. He had recently been prescribed minocycline for acne two weeks prior to the onset of symptoms. Physical exam was most notable for systemic jaundice with scleral icterus. A clinical diagnosis of cholestatic liver dysfunction was made and ursodiol and ADEK were started while further diagnostic workup was in process. Investigations included MRCP, liver biopsy, CMV/EBV antibodies, and autoimmune work up with ANA, anti-smooth muscle antibody, anti-liver kidney microsomal antibody, and anti-mitochondrial antibody. Liver biopsy was consistent with cholestasis with inflammatory damage to bile ducts which were minimally decreased in number. Given the clinical scenario consistent with bile duct damage and loss likely secondary to minocycline use, diagnostic challenges were the non-specific nature of symptoms and unavailability of specific tests to determine etiologic trigger.

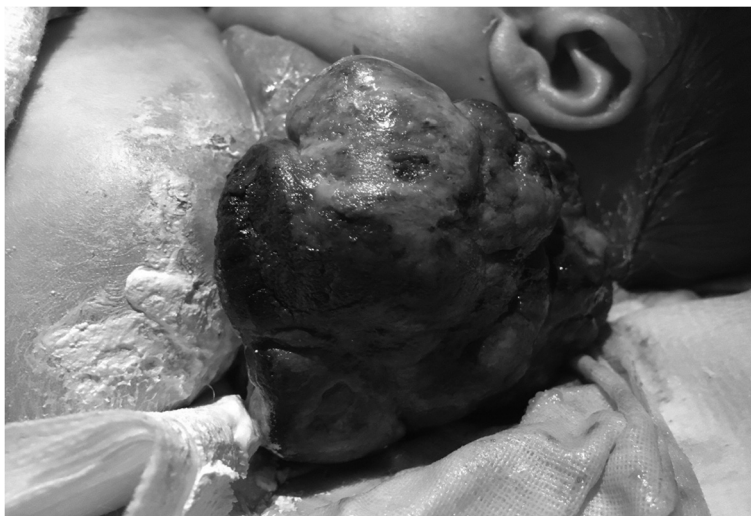Discussion VBDS is an acquired condition with a poorly understood pathogenesis and has varying prognosis depending on the etiologic trigger. It does have the chance of progression with risk of liver failure and death making it an important diagnosis to consider in a patient with cholestatic liver dysfunction. In our patient, additional clinical considerations include his prior history of Hodgkin's lymphoma which has a documented association to VBDS along with his recent use of minocycline which is associated with drug-induced liver injury. Prompt recognition and liver biopsy is necessary in order to establish a preliminary diagnosis and begin attempts to mitigate further bile duct damage.

347 CONGENITAL EXTRA-RENAL NON-CENTRAL NERVOUS SYSTEM METASTATIC RHABDROID TUMOR

¹MA Haynes*, ¹C Rao, ^{1,2}Klawinski D, ²L Mobley, ^{1,2}M Joyce. ¹University of Florida Jacksonville, Jacksonville, FL; ²Nemours, Jacksonville, FL

10.1136/jim-2017-000697.347

Case report Rhabdoid tumors are uncommon and aggressive malignancies that have been documented most commonly in children. These tumors commonly arise from the kidney or central nervous system. When the tumor presents outside the kidney or brain, it is referred to as an extra-renal non-CNS rhabdoid tumor and carries a very poor prognosis. The



Abstract 347 Figure 1 Full term newborn infant with a large neck mass

estimated incidence of an extra-renal non-CNS rhabdoid tumor is 0.15 to 0.6 per million patients. Our case involves a full term newborn infant with a large neck mass. The mass was not detected by ultrasound during his mother's prenatal care. The mass was initially felt to be a vascular tumor/malformation, but biopsy of the tumor confirmed the diagnosis of an extra-renal non-CNS rhabdoid tumor. The child had metastatic disease in the liver, right lung, bilateral adrenal glands and lymph nodes in chest and abdomen. This tumor requires a multimodality approach for treatment including, surgical resection, chemotherapy and radiation therapy. Due to the widespread metastatic disease, his age, and the fact that the primary tumor was not resectable at diagnosis, he was started on multiagent chemotherapy. He received Vincristine/Doxorubicin/Cytosar alternating with Etoposide/Ifosfamide. The case presented many challenges because of his young age, location of tumor, and side effects of chemotherapy. Although treatment is usually not effective in many cases and survival rates are low, our patient showed a good response to initial chemotherapy.

348 PALLISTER-KILLIAN SYNDROME

M Knecht*, R Gupta, A Chau, M Marble. *LSUHSC, New Orleans, LA*

10.1136/jim-2017-000697.348

Case report Pallister-Killian Syndrome (PKS) is a rare sporadic chromosomal disorder caused by the presence of extra copies of the short arm of chromosome 12, which most commonly presents as a supernumerary marker isochromosome 12p. The exact prevalence is unknown. The disorder may be underdiagnosed in those with mild clinical manifestations and can be missed by genetic testing, as isochromosome 12p is present in a tissue-limited mosaic pattern with highly variable levels of mosaicism. The disease is characterized by facial dysmorphism, variable developmental delay, congenital heart disease, and other systemic abnormalities.

We report a case of PKS followed prenatally through the first month of life. In utero, findings included polyhydramnios, shortened long bones, and VSD. The infant delivered without complications via vaginal delivery. Multiple dysmorphic features were noted at birth, including coarse facial

features with a broad nasal bridge and high forehead with sparse temporal hair, high arched palate without cleft, eversion of the lower lip, and broad thumbs. Echocardiogram confirmed the diagnosis of a moderate to large membranous VSD, large PDA with a hypoplastic distal transverse arch, and coarctation. During the first few days of life, the infant developed some seizure-like movements, which did not correlate with EEG changes. Microarray confirmed the diagnosis of Pallister-Killian syndrome.

Our case adds to the growing body of clinical descriptions about this variable disease. We did not observe the characteristic hypotonia that is present in a majority of neonates with this condition. While we did not find changes on EEG, the seizure-like movements observed highlight the variable range of seizure types and common occurrence of non-epileptic paroxysmal events that are described in this syndrome. The prevalence of heart disease in PKS can be up to 40%. To our knowledge, we are the first to report a case of coarctation of the aorta.

349 MYCOBACTERIUM ABSCESSUS PNEUMONIA IN AN IMMUNOCOMPETENT INFANT

A Kosier*, M Joseph, R Dickman, E Klepper, M Bolton. *Our Lady of the Lake Children's Hospital, Baton Rouge, LA*

10.1136/jim-2017-000697.349

Introduction A 2-month-old healthy male was found to have bilateral pneumonia and malnutrition due to *Mycobacterium abscessus*. This patient represents the youngest, and only the third documented, *M. abscessus* pulmonary infection in an immunocompetent infant in the U.S.

Case description The patient presented with cough and respiratory difficulty without fever. Plain films showed bilateral pneumonia with near complete opacification on the right and moderate opacification on the left. The patient was started on ceftriaxone and vancomycin with minimal improvement in symptoms and radiologic findings. A bronchoscopy with lavage and cultures was performed and he was discharged home on cefdinir and clindamycin after mild clinical improvement. After discharge, the culture returned positive for mycobacterium – he was initiated on RIPE therapy for presumed *M.*

tuberculosis (MTB). Additional evaluation for MTB was unremarkable and culture growth obtained from both bronchoscopy samples and gastric aspirates was eventually identified as *M. abscessus*. Therapy was changed to amikacin, clarithromycin, and cefoxitin. A sweat chloride test was negative for cystic fibrosis and all further immunology workup to date has been unremarkable. Since identification of *M. abscessus* and receiving now seven months of various therapy, he has demonstrated slow improvement in respiratory symptoms and radiographic images though he continues to exhibit malnutrition.

Discussion This case represents an unusual presentation of a fairly ubiquitous organism. Previous *M. abscessus* pulmonary infections were noted in immunocompromised children with cystic fibrosis or recipients of organ transplants. Multiple cases of *M. abscessus* causing osteomastoiditis and cutaneous infections have been found in otherwise healthy children and typically resolve without intervention. The diagnostic criteria of nontuberculous mycobacterial (NTM) lung disease include radiographs, at least three culture-positive specimens, and exclusion of other disorders. The two aforementioned *M. abscessus* cases in the literature presented similarly with a pulmonary infection found on imaging and with positive cultures. Our patient is unique given the young age of presentation and no diagnosed immunodeficiency or underlying disease.

350 ALL HYPOXEMIA IS NOT CREATED EQUAL

EA Kubota-Mishra*, AV Agwu, MS Evangelista. *McGovern Medical School, Houston, TX*

10.1136/jim-2017-000697.350

Case report A 3 year old female with cerebral palsy and seizure disorder was admitted to general pediatrics for post-operative management after correction of bilateral hip dysplasia. Her immediate post-op course was complicated by respiratory depression secondary to narcotic use for pain control. On post-operative day 2 she had poor oral intake. On exam, white plaques were seen on the posterior pharyngeal mucosa. To improve oral intake from presumed pain from the lesions, throat sprays and magic mouthwash were ordered for symptomatic relief.

A few hours later, she developed acute desaturation to the mid-80s. On examination, she looked uncomfortable, moaning and crying. She had good air entry on lung auscultation. To treat the hypoxemia, respiratory support was initiated. Additional work-up performed included an unremarkable chest x-ray and a venous blood gas with a pH of 7.48, pCO₂ of 39 mmHg and PaO₂ of 98 mmHg. Despite escalation of support from nasal cannula to high flow to BIPAP with 100% FiO₂, her oxygen saturation did not improve. Due to refractory hypoxemia, she was transferred to the pediatric intensive care unit and an arterial blood gas obtained with a PaO₂ of 372 mmHg and pulse oximetry reading of 75%. Because of the discordance in her condition, cooximetry testing was performed. Her methemoglobin level was immeasurably high. Due to the rapidity of symptom development, methemoglobinemia was likely iatrogenic. Review of medications administered prior to the event showed recent use of a benzocaine-based throat spray. Methylene blue was administered and improved oxygen saturation.

Discussion Acute development of hypoxemia requires a clinician's high index of suspicion to determine its cause.

Iatrogenic causes should be investigated thoroughly, especially if cardiac or respiratory causes are unlikely. The absence of cyanosis and continued desaturation that is discordant with a high PaO₂ on arterial blood gas warrants cooximetry testing. Benzocaine, a common anesthetic, is available in different formulations to treat a variety of ailments. Development of methemoglobinemia after use of benzocaine containing products has been described in the literature. In recent years, the Food and Drug Administration has released a warning against use in pediatric population particularly those who are <2 years of age.

351 A SEVERE CASE OF NEONATAL COW'S MILK PROTEIN ALLERGY MIMICKING SEPSIS

KM Kuehn*, TO Findley. *McGovern Medical School at UT Health, Houston, TX*

10.1136/jim-2017-000697.351

Case report Cow's milk protein allergy is a clinical diagnosis with variable manifestations. In infants, this allergy typically presents through a non-IgE mediated mechanism. One of the most severe forms of this is Food Protein Induced Enterocolitis (FPIES) which can cause vomiting and diarrhea resulting in significant dehydration. Abnormal laboratory findings may include metabolic acidosis, leukocytosis, and neutrophilia, as well as elevation in the inflammatory marker, C-reactive protein (CRP). Due to the clinical and laboratory manifestations of this disease, it may be initially misdiagnosed as sepsis resulting in delayed treatment and further exacerbation of symptoms. Furthermore, there is no diagnostic test for FPIES so diagnosis is based on improvement of symptoms after removal of the offending agent. In this report, we describe the case of a 25 day old Chinese male infant who was transferred from an outside facility for persistent leukocytosis, bandemia, metabolic acidosis, and a marked rise in CRP despite treatment with broad spectrum antibiotics. He also was noted to have copious watery stools and failure to thrive with a weight 150 grams (4.7%) below his birth weight. The patient showed dramatic improvement following cessation of cow's milk formula and transition to an elemental formula. While there have been reported cases describing an elevated CRP in infants with this disease, our case is unique in the degree of CRP elevation (130 mg/L) in an afebrile neonate. Moreover, no cases have described bandemia from FPIES. These two markers are often used as indicators of underlying infection and can delay diagnosis and treatment of FPIES. This case highlights the importance of including FPIES in the differential when presented with a critically ill infant with clinical features of sepsis, diarrhea, and failure to thrive.

352 AUTOIMMUNE ENCEPHALITIS: WHERE CLINICAL PRESENTATION AND LABORATORY RESULTS MAY DISAGREE

S Liu*, D Chrusciel, D Hahn. *University of Oklahoma, Oklahoma City, OK*

10.1136/jim-2017-000697.352

Case report In patients presenting to the general pediatrician with new onset neuropsychiatric symptoms, autoimmune encephalitis or viral encephalitis is commonly on the diagnostic differential. Although both can have corresponding laboratory

results that support the diagnosis, negative lab results do not rule out either condition. We present a previously healthy 5-year-old male with new onset seizures and no prodromal viral symptoms. A few days prior to presentation, he developed neuropsychiatric symptoms. On the day of admission, he developed fatigue, drooling, gasping, and flexion of his neck to the right. He was not responsive to stimulation. He was taken to an emergency room where he developed arm and leg shaking. Head computerized tomography was unremarkable and he was transferred to our hospital for further care. While here, he was transferred between the pediatric intensive care unit and general pediatric ward multiple times. Eventually, his seizures were well-controlled with anti-epileptics, but significant clinical improvement occurred only after starting steroids. He continued to have erratic behaviors, including enuresis, hyperactivity, inability to follow directions, confusion, and emotional lability. Testing for multiple viruses, anti-N-methyl-D-aspartate receptor, and other antibodies were negative. Continuous video electroencephalogram captured complex partial seizures with secondary generalization. Magnetic resonance imaging of the brain was normal. Due to clinical course, lack of infection, and rapid response to steroids, he was diagnosed with autoimmune encephalitis.

Autoimmune encephalitis is an uncommon, but significant diagnosis. Although many pediatric cases of autoimmune encephalitis are seropositive, autoimmune encephalitis is an ever-evolving field, and negative laboratory studies are not unexpected. Although initial lab results and symptoms may be confused with viral encephalitis, with autoimmune encephalitis, delayed therapy may lead to a decreased response. This case highlights the importance of clinically diagnosing autoimmune encephalitis and administering prompt and appropriate therapy for best outcomes.

353 INSPISSATED BILE SYNDROME CAUSING SEVERE CHOLESTASIS IN A NEWBORN

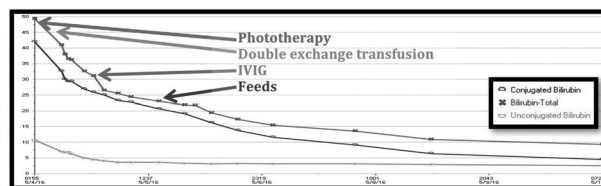
¹RM Turcu, ²AN Lyle*. ¹University of Louisville, Louisville, KY; ²Indiana University, Indianapolis, IN

10.1136/jim-2017-000697.353

Case report 2-day old AGA term male infant presented with lethargy, poor feeding, and generalized jaundice since birth. He had passed one meconium stool. Infant was born at home via SVD to a healthy Amish mother, after a normal pregnancy. Maternal blood type AB neg, prenatal labs not available. Mother is G4P3 (1 miscarriage, 1 stillbirth, 2 healthy term pregnancies. Rhogam was delayed after the miscarriage, but given appropriately after the other pregnancies. Father and 2 yo brother are healthy. Initial workup (table): severe conjugated hyperbilirubinemia, mild liver dysfunction, anemia with reticulocytosis (Rh incompatibility – infant's blood type B+, 4 + DAT). Blood and CSF culture negative. Urine culture: 10–100 k *E. coli* CFUs. Test for genes *ABCB11*, *ABCB4*, *ATP8B1*, *JAG1*, and *TJP2* neg. TSH, FT4, metabolic newborn screen normal, bile acids in normal ranges, TORCH neg. Abdominal

Laboratory Results	Admission	Discharge
TSB, mg/dL	49.4	9.3
Conjugated/Unconjugated	42/10.7	4.5/2.5
Hemoglobin, g/dL/Reticulocyte count, %	12.6/23%	16.8
AST/ALT, IU/L	239/55	81/36

Abstract 353 Table 1



Abstract 353 Figure 1 Bilirubin decline over time

ultrasound: normal-appearing liver and gallbladder, no biliary ductal dilation, patent vessels. CXR, Echo unremarkable. Treatment: phototherapy, double volume exchange transfusion, IVIG, PRBC, phenobarbital, antibiotics for UTI.

Graph: bilirubin decline over time. At discharge all lab values improved. Family declined HIDA scan (normal US, decreasing bilirubin) and brain MRI (normalized neuro exam). Evaluated in the developmental follow up clinic at 2.5 months: appropriate growth, normal PE (incl neurological and development eval) and bilirubin levels.

Discussion This is a full term neonate with hemolytic anemia (Rh incompatibility) and severe conjugated hyperbilirubinemia. Most common cholestasis causes were excluded. *E. coli* UTI could have been a contributor, but unlikely the main cause. Exclusion diagnosis: Rh incompatibility with severe chronic hemolysis, complicated by inspissated bile syndrome. Family declined liver biopsy (rapid resolution of the hyperbilirubinemia and normal hepatic ultrasound).

354 A RARE CASE OF HEMPHAGOCYTIC LYMPHOHISTIOCYTOSIS: OVERCOMING FATAL OUTCOMES

A Madani*. Louisiana State University, Shreveport, Bossier City, LA

10.1136/jim-2017-000697.354

Case report Patient was a 3 month male infant with a previously unremarkable past medical and family history who developed a fever associated with unilateral cervical lymphadenopathy treated with Clindamycin by his primary care provider. When symptoms persisted, he was referred for surgical evaluation of neck mass and later admitted to the hospital when routine labs revealed pancytopenia and elevated liver enzymes of unknown etiology. Over the next several days, he quickly deteriorated, requiring mechanical ventilation, pressors and blood products before he was transferred to the Pediatric Intensive Care Unit at our hospital on February 4, 2017. On arrival, there was high suspicion for Hemophagocytic Lymphohistiocytosis (HLH), a rare but fatal disease characterized by uncontrolled hemophagocytosis and activation of inflammatory cytokines that lead to infiltration of multiple organs. The disease is divided into primary (hereditary) and secondary (acquired) with the latter being triggered by infection or non-infectious causes (such as drugs, autoimmune disease or immunodeficiency states). Diagnosis of HLH is determined by either having a molecular diagnosis consistent with known mutations or second, fulfilling 5 of the 8 signs or symptoms:

- fever,
- splenomegaly,
- cytopenia,
- hypertriglyceridemia and/or hyofibrinogenemia (<150 mg/dl),
- hemophagocytosis in a lymphatic tissue excluding malignancy,

- low or absent natural killer cell cytotoxicity,
- hyperferritinemia, and
- Elevated soluble CD25 levels.

On admission, patient met criteria having 5 of the 8 findings but with a lack of family history or preceding trigger, it was unclear if it was primary or secondary which has implications in treatment. Nevertheless, prognosis is poor and often fatal. Chemotherapy with Etoposide with Decadon was started on admission along with broad spectrum antibiotics and several days of plasmapheresis and IVIG. Patient was in remission by week 2 of treatment and discharged one month later stable. Bone marrow aspirate and genetic testing later proved to be primary HLH with no identifiable agent identified as a trigger as EBV, CMV and Herpes PCR was negative. He is currently awaiting bone marrow transplantation.

355 CONSUMED BY FEVER: A CASE OF PHAGOCYTOSIS GONE WRONG

MJ Magee*, K Schneider. *University of Mississippi Medical Center, Jackson, MS*

10.1136/jim-2017-000697.355

Case report Hemophagocytic lymphohistiocytosis (HLH) is life threatening disease caused by excessive immune activation. Diagnosis can be difficult and failure to diagnose early in the disease process can impede therapies and increase overall mortality. Here we present an interesting case of HLH in a 3-year-old presenting with fever of unknown origin.

A previously healthy 3-year-old white male presented to our Pediatric Emergency Department with a chief complaint of 4 weeks of daily spiking fevers (up to 104°). The fevers were accompanied by an erythematous maculopapular rash, daily vomiting, diarrhea, and occasional complaints of joint pain. On presentation, exam was notable for cervical and inguinal lymphadenopathy, hepatomegaly, and scattered maculopapular rash. Significant labs included anemia, leukocytosis, elevated acute phase reactants, and elevated LDH. Initial differential of infectious, neoplastic, rheumatologic, and inflammatory processes required multiple subspecialty consultation. Ferritin levels were markedly elevated (10420) pointing to a possible diagnosis of HLH with concern for underlying malignancy. CT imaging showed hepatosplenomegaly and diffuse lymphadenopathy throughout the chest, abdomen, and pelvis concerning for lymphoma. Lymph node and bone marrow biopsies were both consistent with hemophagocytosis with no evidence of malignancy. These findings along with fever, hyperferritinemia, splenomegaly, and hypertriglyceridemia satisfied the diagnostic criteria for HLH. Treatment with steroids and Etoposide led to resolution in fevers. He was assumed to have secondary HLH as genetic sequencing for familial HLH was negative though underlying cause is still unknown.

HLH is a reactive process characterized by systemic inflammation due to dysregulation of normal immunological pathways. The predominant clinical features of fever, cytopenias, hepatitis, and splenomegaly reflect the immune disruption, but many conditions can lead to this same clinical picture. Fever of unknown origin carries a broad and non-specific differential that encompasses numerous possible etiologies making it difficult to isolate a specific diagnosis. While HLH may not be high on the differential for fever of unknown origin, it should be considered a possibility due to its mortality risk and need for immediate therapy.

356 A NOT SO SIMPLE CASE OF DEHYDRATION

C Marbrey*, MN Frascogna, T Walker. *University of Mississippi Medical Center, Jackson, MS*

10.1136/jim-2017-000697.356

Case report As the only Children's Hospital in the state, our institution routinely receives transfers from both local and distant locations within the region. History and clinical context are often limited by the absence of caregivers or the emergent need for care. We present a case involving the transport of a child to the pediatric emergency room for presumed dehydration.

An ambulance arrived to the Pediatric ER following the uneventful transport of a 14 year old male after football practice for dehydration. He was unloaded from the ambulance and on transfer to a treatment room, he suddenly became unresponsive and, after a few agonal breaths, became apneic and pulseless. CPR was initiated immediately. Defibrillator pads were placed and showed asystole. He received 3 rounds of epinephrine with return of spontaneous circulation after 6 minutes. The patient was intubated and he was started on a continuous epinephrine infusion. Initial venous blood gas revealed a pH 6.94, ionized calcium (iCa) 0.46, potassium (K) 6.6, and lactate 12.1. He received boluses of calcium gluconate, sodium bicarbonate, and a normal saline bolus. Foley catheter placement produced a large volume of red colored urine. An insulin/dextrose infusion was initiated for hyperkalemia and he was admitted to the PICU for further management.

On arrival to the PICU, notably, his creatine kinase (CK) was >100,000, iCa 0.32, K 7.3, creatinine 3.58, lactate 7.7, and phosphorus 22.2. Dialysis was considered but not initiated. His CK remained >100,000 for 5 days and his electrolytes gradually corrected. His PICU course was complicated by recurrent episodes of ventricular tachycardia which eventually resolved. He was extubated, his CK was down trending and he was ultimately discharged home with a diagnosis of rhabdomyolysis.

Further history revealed that the patient was at football try-outs and had not yet participated in any football or warm-up activity that day, making the diagnosis of rhabdomyolysis in the setting of strenuous activity much less likely. Cardiac arrest in the setting of profound non-traumatic rhabdomyolysis warranted additional genetic and rheumatologic work up which is currently pending.

357 BRONCHIAL CAST WITH BRONCHIECTASIS

L McKinney*, S Gonzalez, E Klepper, A Carrion. *Our Lady of the Lake, Baton Rouge, LA*

10.1136/jim-2017-000697.357

Introduction Bronchiectasis is defined as a permanent dilation of bronchi secondary to structural damage to the bronchial wall. Severe bacterial or viral pneumonia accounts for the majority of bronchiectasis in the post-infectious period of the pediatric population. We present a case of a 4-year-old female who developed bronchiectasis secondary to an endobronchial cast formed by a pneumonic process.

Case description A previously healthy 4-year-old female presented to the pediatrician's office with 3 days of fever, cough, and tachypnea. Chest x-ray (CXR) showed left lower lobe (LLL) pneumonia. The patient was given ceftriaxone and

azithromycin. Two days after, the patient's repeat CXR showed persistent LLL infiltrate, and she was given another dose of ceftriaxone and placed on high-dose amoxicillin after consultation with pulmonology. In pulmonary clinic, clinical improvement was noticed, but the six-week follow-up CXR showed persistent infiltrate with improvement. Spirometry showed possible small airway obstruction, and an inhaled corticosteroid was started. One month later CXR still showed persistent infiltrate. A chest computed tomography showed a mass effect to segmental bronchi on LLL with tubular bronchiectasis and atelectasis. Flexible bronchoscopy revealed a friable endobronchial tissue in the LLL resembling a cast that was removed with rigid bronchoscopy. Pathology showed Charcot-Leiden crystals and mixed inflammatory debris including eosinophils. The patient was continued on inhaled corticosteroids and started on amoxicillin-clavulanate, systemic steroid course, and chest percussion therapy. A repeat CXR noted resolution of the LLL infiltrate.

Discussion This case demonstrates the development of post-infectious bronchiectasis in association with a bronchial cast. Most patients with bronchiectasis have chronic conditions such as cystic fibrosis, recurrent pneumonias, or chronic rhinosinusitis that can lead to lung damage which then leads to bronchiectasis. However, bronchiectasis can be seen after a single case of severe pneumonia. Bronchial casts typically occur in post-Fontan patients; however, our patient did not have any predisposing factors for the development of bronchial casts. Nevertheless, post-obstructive pneumonia could have caused bronchiectasis and promoted the formation of a bronchial cast.

358 MOLLARET'S MENINGITIS DUE TO HERPES SIMPLEX 2 STARTING IN THE NEONATAL AGE GROUP

M Munir*, M Rathore. *University of Florida, Jacksonville, FL*

10.1136/jim-2017-000697.358

Introduction Mollaret's meningitis is a rare condition that is characterized by multiple recurrent but benign episodes of meningitis presenting with or without fever. It is usually considered a disease of adults however, it has also been reported in children.

We report the first case of Mollaret's meningitis without any encephalitis, caused by HSV-2 which started in the neonatal period.

Case report An 11 year-old previously healthy male presented with 2 days history of fever and signs of meningism.

He had a significant past medical history of HSV disease. He was first admitted at the age of 9 days with fussiness and fever and was diagnosed with HSV-2 meningitis based on HSV-2 PCR on the CSF. An MRI of the brain with contrast was normal. He was treated with IV acyclovir and then discharged on oral acyclovir prophylaxis. An audiology screen was normal.

Nine days after discharge, patient was again admitted with one day history of fever, fussiness, vomiting and diarrhea. HSV-2 PCR was again positive in the CSF. Brain MRI with and without contrast was normal. He was again treated with 21 days of IV acyclovir and HSV-2 PCR was negative in the near treatment LP. Patient was discharged on oral acyclovir.

At the time of the current admission patient was ill appearing with meningismus. A CT scan without contrast was

normal. CSF PCR was positive for HSV-2. An MRI with contrast was also normal.

Discussion Mollaret's meningitis is different than the usual recurrent HSV meningoencephalitis in any age group, which is serious and often associated with neurological complications. These episodes can occur with weeks to years asymptomatic intervals between episodes. Our patient had recurrent HSV meningitis which started as a neonate, his presentations were consistent with Mollaret's meningitis and outcomes were benign.

Differentiation between the classic neurological neonatal HSV and first episode of Mollaret's meningitis is impossible. A benign course of neurological HSV infection should not temper with aggressiveness of treatment, however a possibility of Mollaret's meningitis should be entertained.

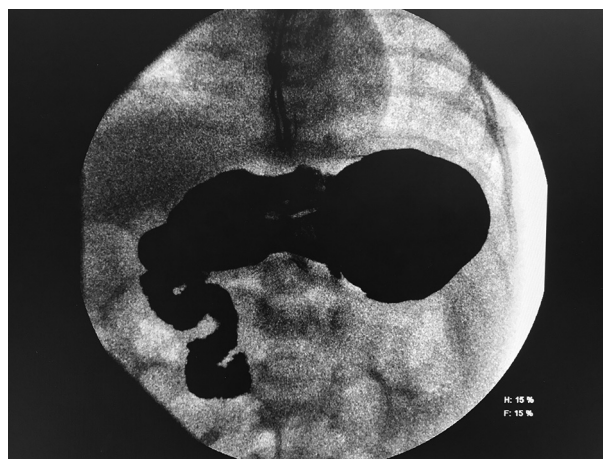
Future questions Recurrent HSV-1 meningitis because of immunological deficiencies have been reported but not for HSV-2.

359 INTESTINAL MALROTATION IN A 4 WEEK OLD MALE: A CASE REPORT AND REVIEW OF THE LITERATURE

DK Nguyen*, B Sessions, J Deitrick, A Olanrewaju, J Meller. *Texas Tech Health Science Center Medical School, Amarillo, TX*

10.1136/jim-2017-000697.359

Case report Intestinal malrotation is a congenital abnormality of the gut which can present as an asymptomatic incidental finding or a life-threatening emergency. Most cases present in infancy once the malrotation has resulted in volvulus (twisting of the small intestine on the superior mesenteric artery). This leads to intestinal obstruction and requires emergency surgical intervention. However, some cases of malrotation are mostly asymptomatic and only detected incidentally following gastrointestinal imaging for other reasons. We present a case of a 4 week old male who presented with intermittent nonbilious vomiting along with failure to thrive and no stools for 1 week. While this patient was diagnosed with gastroesophageal reflux (GER), an upper GI series revealed incidental malrotation. After adequate treatment for GER and subsequent improvement of symptoms, the surgeon still proceeded to correct the malrotation with the Ladd procedure. We use this case to discuss the best treatment for asymptomatic malrotation, which is currently still widely debated among physicians.



Abstract 359 Figure 1 Upper GI series shows abnormal vertical duodenojejunal portion

360 CROUZON SYNDROME: A CLASSIC CASE AND A LOOK INTO WHAT IS AHEAD

A Nuttli*, J Gallois, C Mumphy, J Surcouf. *LSUHSC, New Orleans, LA*

10.1136/jim-2017-000697.360

Case report Crouzon Syndrome is an autosomal dominant disorder that results from a mutation of the fibroblast growth factor receptor-2 (FGFR-2) gene causing the classic features of the disease.

Our patient was born to a 19 yo G1 mother at 34 4/7 WGA and was noted to have dysmorphic features at birth including, turricephaly, proptosis, elevated palatal arch, and low set ears consistent with a craniosynostosis syndrome. Maternal and pregnancy history including prenatal ultrasound screening were unremarkable, and the mother received adequate prenatal care. The patient was transferred to our center for multidisciplinary care. 3-D CT imaging revealed closure of coronal, sagittal, and lambdoid sutures as well as maxillary and ethmoid sinus hypoplasia. These findings along with the absence of long bone abnormalities in our patient are most consistent with Crouzon Syndrome. Without disease reported in either the mother or father of this infant, a de novo mutation was presumed. Other significant findings included PDA, ASD, VSD, and bilateral conductive hearing loss. Our patient required tracheostomy placement due to the severity of her midface hypoplasia. Additionally, due to the restrictive shape of the skull, the patient was monitored for hydrocephalus prior to discharge. She is currently scheduled for shunt placement due to progressive hydrocephalus on follow up. Management of her Crouzon Syndrome involved a variety of subspecialists including genetics, plastic surgery, neurosurgery, ENT, cardiology, and audiology. A team based approach with numerous multidisciplinary family meetings was necessary to coordinate care. Long term treatment currently involves staged craniofacial surgeries. However, new research is looking into attenuating the FGFR cell signaling pathways at the level of coronal sutures to alter osteoblast activity and maintain appropriate suture patency either prenatally or in conjunction with corrective surgeries.

This case highlights the importance of a multidisciplinary approach to the management and treatment of Crouzon Syndrome and explores the opportunity for future research into targeting cell signaling pathways as a component of treatment.

361 FOURTEEN YEAR OLD TRACHEOSTOMY DEPENDENT SECONDARY TO SUBGLOTTIC STENOSIS

J Oakley*, D Lozano. *University of Alabama at Birmingham, Homewood, AL*

10.1136/jim-2017-000697.361

Introduction Respiratory failure associated with stridor suggests obstruction or narrowed airway and differential for underlying cause of stridor can be broad.

Case presentation The patient is a fourteen year old Caucasian male with hearing loss, vocal cord dysfunction and tracheostomy dependent due to severe glottic subglottic stenosis (SGS) who presents for evaluation for weight loss, dyspnea and joint swelling. Emergent tracheostomy was performed one year prior for respiratory failure due to SGS just below the vocal cords preventing intubation. Patient had multiple hospital stays prior for stridor and respiratory distress. Initial direct

laryngoscopy with bronchoscopy (DLB) during episode of stridor showed only a hypoplastic right true vocal cord that did have normal movement followed by repeat DLB a month later for recurrent stridor without concern for worsening subglottic stenosis, diagnosed with vocal cord dysfunction. Admission labs notable for CRP 16 mg/dL, ESR 110 mm/hr and microcytic anemia; diagnosed with relapsing polychondritis as evidenced by nasal and auricular chondritis (resulting in saddle-nose and cauliflower ear), subglottic stenosis, arthralgia, and extreme weight loss secondary to chronic, high-levels of inflammation. On DLB, our patient was diagnosed with grade 3 subglottic stenosis as well as malformed glottic anatomy with no discernible vocal cords.

Discussion Relapsing polychondritis is a rare autoimmune disorder of unknown etiology characterized by recurrent inflammation and destruction of cartilaginous structures, most commonly the upper respiratory tract, ears, nose, and joints. Proposed pathogenesis includes antibodies to type II, IX and XI collagen and matrillin-1. Pulmonary symptoms are present in 20–50% of all patients and can include inflammatory changes anywhere from the subglottis, trachea, including the posterior membranous wall, and bronchi; lung interstitium and pulmonary vasculature are not affected. Presenting symptoms of airway involvement can include dyspnea, cough, hoarseness and stridor. Prior studies have also shown saddle nose deformity to correlate with pulmonary symptoms. Differential for glottic subglottic stenosis in children is broad but not limited to traumatic, infectious, congenital or autoimmune.

362 EXTRAMEDULLARY RELAPSE OF CD19+ ALL DURING BLINATUMOMAB THERAPY

J Onarecker*, D Crawford, Z Yu. *University of Oklahoma Health Sciences Center, Oklahoma City, OK*

10.1136/jim-2017-000697.362

Introduction In pediatric patients with ALL, about 90% will achieve remission. However, those that relapse often have a difficult course and many do not survive. Blinatumomab is one of a new category of immune-based therapies developed to treat relapsed or refractory pre-B cell ALL. It is a bispecific antibody that acts as a T-cell engager binding the CD3 antigen of T-cells with the CD19 antigen of leukemic cells. While many patients are able to achieve a second remission with Blinatumomab, many of those have a subsequent relapse unless they undergo allogeneic stem cell transplant. Most relapses occur as hematologic relapses in the bone marrow or less commonly as extramedullary relapses.

Case presentation Our patient is a 14 year old boy who completed therapy on a high risk COG protocol and achieved remission. He had a CNS and bone marrow relapse at 5 months off therapy. A second remission was quickly achieved, but he relapsed again within a few months. He was treated with Blinatumomab with rapid clearance of blasts from his marrow. However, within 3 weeks of initiation of Blinatumomab, he developed gingival and scalp lesions. Biopsy confirmed the lesions to be CD19⁺ pre-B ALL with the same immunophenotype as the original leukemia. He was then treated unsuccessfully with an additional salvage regimen. His disease progressed and his family requested hospice care.

Conclusions Blinatumomab is a promising option for salvage of relapsed ALL patients, but its efficacy is limited by a high

rate of relapses. Many of these occur because of loss of expression of CD19, allowing the leukemia cells to evade therapy. In other cases, extramedullary relapses occur, often with cells that still express CD19. This suggests that some extramedullary sites are immunologically privileged and do not receive the optimal benefit from anti-CD19 immunotherapy. This finding reinforces that Blinatumomab should generally be used as a bridge to further therapy, preferably to allogeneic stem cell transplant, rather than as definitive treatment.

363 RHEUMATIC HEART DISEASE IN A 6 YEAR OLD

V Pillay*. *Louisiana State University Health Science Center Shreveport, Shreveport, LA*

10.1136/jim-2017-000697.363

Case report 6 yo AAF with no PMH was seen in the ED for fever. Associated symptoms included headache and refusal to swallow. Physical exam only revealed mild pharyngeal erythema. A grade 3/6 systolic murmur was auscultated that had not previously been documented. A rapid strep test was -ve. Reflex throat culture was also -ve. Patient was diagnosed with viral pharyngitis and discharged home. Clinic follow up was scheduled to address her murmur however she was lost to follow up for 2 months. When she returned to clinic she had increased fatigue, decreased activity, and intermittent fever. Heart murmur was still present. Echo was obtained and was significant for severe mitral valve regurgitation, moderate to severe aortic insufficiency with nodular appearance of both valves, moderate dilation of the left ventricle with normal systolic function. She was admitted to hospital. Physical exam showed a well appearing child in no distress. Mucus membranes were moist, with normal tonsils and posterior pharynx. No lymphadenopathy. No arthropathy. Her skin was negative for rashes, nodules, splinter hemorrhages, janeway lesions or osler nodes. Cardiac exam was significant for 2/4 diastolic murmur loudest at the mid sternal border, 3/6 holosystolic murmur at the apex, a slightly displaced PMI to the left, and 3+ bounding pulses in all extremities. Patient was started on prednisone and high dose aspirin to resolve any potential inflammation from a possible rheumatic fever. Lisinopril was added to reduce afterload. Blood cultures were drawn at 0, 6, and 12 hrs. Vancomycin and Gentamicin were started after the 3rd blood culture. Labs were significant for a -ve ANA and elevated DNase B ab and ASO Titer (548 & 401 respectively). The presumed diagnosis was rheumatic heart disease.

Patient remained afebrile with no symptoms of cardiac dysfunction and no change in clinical status. Vancomycin and Gentamicin were discontinued 72 hours after -ve cultures. Cultures were grown for 21 days to rule out HACEK organisms as a cause of subacute endocarditis. She was started on Penicillin therapy until age 40, and likely to be due to increased risk of recurrent attacks of rheumatic fever. Repeat ECHO at discharge showed trivial improvement in mitral regurgitation and minimal improvement in aortic regurgitation. She will likely need valve replacement in the future.

364 STOP THE CLOT: PREVENTING POSTOPERATIVE VENOUS THROMBOEMBOLISM IN HOSPITALIZED CHILDREN

¹M Rabalais*, ²A Byrd, ²MH Roy, ²E Klepper. *¹Louisiana State University Health Sciences Center, Baton Rouge, LA; ²Our Lady of the Lake Children's Hospital, Baton Rouge, LA*

10.1136/jim-2017-000697.364

Case report Hospital-associated venous thromboembolism (VTE) is now the second most common serious hospital-acquired condition in children's hospitals. Although the incidence of VTE in hospitalized adults is considerably higher than in children (0.2% to 0.6% of hospitalizations), the incidence in children has significantly increased recently. Adolescents are at higher risk of VTE due to higher rates of obesity, oral contraceptive use and long bone fractures. We present an adolescent with no previous risk factors who developed VTE following a long bone fracture.

A 14 year old male presented to ED with a traumatic spiral fracture of the left femoral shaft. Post-operatively, the patient was placed on enoxaparin, diazepam, and pain medication. Physical therapy initiated early ambulation, and he achieved adequate pain control. Enoxaparin was discontinued prior to discharge, and he was sent home with aspirin, oxycodone and diazepam. His pain was initially well-controlled allowing continuation of physical therapy. However, on POD6 he grew increasingly weak, pale and refused to ambulate. He presented to the ED febrile, tachycardic and severely anemic. CT showed a large hematoma encircling the femoral shaft, and US showed a DVT in the left distal femoral vein. Enoxaparin was restarted, and the patient was admitted for VTE management.

As the incidence of pediatric hospital-associated VTE continues to rise, further effort is needed to determine the best way to prevent and treat VTE. There is no current consensus on evidence based guidelines for VTE prophylaxis in children. Using a recently published risk assessment algorithm, our patient did not meet criteria for pharmacologic prophylaxis, which likely would have prevented his VTE. Our case highlights the opportunity for the pediatric community to develop more effective risk stratification and prophylaxis algorithms for hospitalized children. Pediatricians need to understand the role of mechanical and pharmacologic prophylaxis and address the importance of early ambulation and pain control. With more research we can improve the prevention of this increasing hospital acquired condition that results in significant harm and expense.

365 THE DIFFICULT AIRWAY: A CASE REPORT IN A NEONATE

P Redmond*, C Faulk, MN Frascogna. *University of Mississippi Medical Center, Jackson, MS*

10.1136/jim-2017-000697.365

Case report The difficult airway is a discovery no provider wishes to make in the emergency department (ED). Here we present a case of a patient who presented with a markedly difficult airway due to an unlikely cause requiring intubation attempts by multiple providers.

A three-week-old presented as a transfer from a tertiary care facility with respiratory distress. She had presented to our ED four days earlier at 15 days of age with chief complaint of wheezing and poor feeding. Radiographs and cultures were obtained, but mother refused additional labwork. She was well appearing at the time and was discharged home. The child subsequently developed neck swelling at home and four days later was brought by EMS to an outside facility for stridor and respiratory distress. Attempts at intubation failed and the patient was transferred by Pediatric Air Transport to our ED. In our unit the patient was lethargic and in respiratory failure. With ED staff, anesthesia, and otolaryngology at the bedside, repeat intubation attempts were made by employing the use of a video laryngoscope without success. Eventually direct laryngoscopy was undertaken resulting in rupture of a large submental mass and copious purulent drainage. Following suctioning and placement of a laryngeal mask airway, an endotracheal tube was successfully placed, the patient stabilized, and was admitted to the ICU.

Further work-up was notable for a significant leukocytosis and bandemia, while imaging revealed a pocket of fluid and air in the posterior floor of the mouth and widespread soft tissue edema. These findings were consistent with a ruptured abscess due to an infected thyroglossal duct cyst. The patient was placed on antibiotics and recovered completely without complications to date. Though rare in newborns, thyroglossal duct cysts are epithelial remnants of embryonic development, and should be considered when evaluating a newborn with stridor and respiratory distress.

366

SEVERE METABOLIC ACIDOSIS IN THE SETTING OF HETEROZYGOUS 3-OXOACID COA-TRANSFERASE 1 GENE MUTATION

PA Ruhlmann*, D Hahn. *University of Oklahoma Health Sciences Center, OKC, OK*

10.1136/jim-2017-000697.366

Case report A previously healthy 4 year old male with mild developmental delay presented to The Children's Hospital of Oklahoma (TCH) as a transfer from a small rural hospital for severe metabolic acidosis and lethargy. He was born at term, fully immunized, with no previous hospitalizations, allergies, or significant family history. After two days of diarrhea, decreased appetite, and emesis, he developed labored tachypnea and was taken to his local emergency room. Labs there revealed only a bicarbonate level <5. After transfer to TCH and receiving a total of 100 cc/kg normal saline, the patient remained acidotic with pH of 7.13 and serum bicarbonate of 6. However, on exam the patient was well-appearing, sleeping but easily awakened, and breathing comfortably 20 times per minute, despite the marked acidosis. Extensive workup ensued. Serum ketones (beta-hydroxybutyrate) were elevated to 8.46 (normal 0.02–0.27) and urine analysis had 2+ ketones. The acidosis ultimately corrected after 24 hours of bicarbonate containing fluids, with no further episodes. He was discharged to follow-up with genetics, and after more specific genetic testing, he was found to have a previously unreported alteration in the 3-oxoacid CoA-transferase 1 gene (OXCT1), consistent with carrier status of succinyl-CoA-3-oxaloacid CoA transferase (SCOT) deficiency.

OXCT1 is located on chromosome 5p13.1 and encodes the mitochondrial SCOT enzyme, which catalyzes the first step of

ketolysis for utilization of ketone bodies as an energy source when blood glucose is low. OXCT1 mutations result in SCOT deficiency, an autosomal recessive disorder that results in the accumulation of unused ketone bodies. SCOT deficiency often presents in the neonatal period with recurrent episodes of ketoacidosis (vomiting, lethargy, tachypnea, and unconsciousness). Patients typically are asymptomatic between episodes, but often have permanent ketosis and ketonuria.

SCOT deficiency has only been documented in a very small number of patients. While SCOT deficiency is generally regarded as a mostly autosomal recessive inheritance pattern, a 2017 study revealed profound metabolic acidosis in a very small subset of heterozygote patients with OXCT1 mutations, similar to our patient.

367

PATIENT WITH PROTEUS SYNDROME AND PARATESTICULAR OVARIAN-TYPE PAPILLARY SEROUS CARCINOMA

^{1,2}A Sadaf*, ³R Berkow, ⁴A Nguyen, ⁵A Meyers, ⁴CK Nguyen, ³M Whery. ¹University of Florida, Pensacola, FL; ²Studer Family Sacred Heart Children's Hospital, Pensacola, FL; ³Nemours Children's Specialty Care, Pensacola, FL; ⁴Sacred Heart Hospital, Pensacola, FL and ⁵Nemours Children's Specialty Care, Orlando, FL

10.1136/jim-2017-000697.367

Introduction Proteus syndrome is a rare genetic disorder characterized by overgrowth and tumor susceptibility. Although there are reports of genitourinary tumors in PS, we describe the youngest case of para-testicular ovarian-type papillary serous carcinoma associated with PS.

Case description A four-year-old male with hemi-hypertrophy, and other features of PS, presented with a painless left scrotal swelling. Ultrasound showed a normal testis, extra-testicular soft tissue thickening, an enlarged epididymis and a complex hydrocele. Left inguinal radical orchiectomy revealed a thickened hydrocele sac and grossly abnormal para-testicular tissue without any obvious lymph nodes. A 1.5 × 1.5 × 1.0 cm nodule in the distal spermatic cord was biopsied for frozen section. Histologically, an unremarkable testicle was surrounded by an intact, thickened tunica albuginea. The tumor had a papillary microarchitecture lined by single cuboidal epithelium with mild to moderate cytological atypia. There was no involvement of the epididymis or rete testis. Frequent psammoma bodies and tumor invasion were appreciated. Tumor cells had strong, diffuse nuclear staining for WT1 and Pax 8 but were focally positive for calretinin and cytokeratin 5/6. A metastatic work up was negative. A diagnosis of stage I para-testicular ovarian-type papillary serous carcinoma was made. Postoperative recovery was unremarkable and chemotherapy was reserved for recurrent disease.

Discussion OTETs are homologous to their ovarian counterparts. They can resemble carcinoma of the rete testis (preserved in this case) and papillary mesothelioma (does not express Pax 8). In the absence of management guidelines, the role of adjuvant therapy is unclear. Fortunately, recurrence is rare in localized disease.

Implications for patients with PS: There are no specific tumor surveillance guidelines for patients with PS. This case highlights the importance of maintaining a high index of suspicion in these patients.

368 AN IMMIGRANT CHILD PRESENTS WITH MULTIPLE AIDS-DEFINING ILLNESSES

A Severio*, A Pogribny, L Raney, C Sandlin, M Murphy, RE Begue. *LSUHSC, New Orleans, LA*

10.1136/jim-2017-000697.368

Case report Human Immunodeficiency Virus (HIV) affects 38.6 million people worldwide. Approximately ten percent of these individuals are younger than 15. If not controlled, infection with HIV may lead to acquired immunodeficiency syndrome (AIDS) where devastating immunosuppression targeting CD4 positive T-cells increases host susceptibility to opportunistic infections and malignancy.

We present the case of an 11-year-old immigrant from Central Asia with a history of failure to thrive, febrile seizures, and a vesicular rash following the varicella vaccination. The patient presented with one week of occipital headaches and hypertensive urgency. She developed fever and vision loss in the left eye two days after admission, with new reports of a partial right visual field deficit for one month. MRI findings were consistent with meningoencephalitis. The cerebrospinal fluid revealed 34 WBC and a positive vaccine strain varicella (VZV) PCR. Serum cytomegalovirus (CMV) IgG was greater than 10,000 u/mL. Ultimately, the patient was diagnosed with meningoencephalitis and left optic neuritis secondary to VZV and right eye CMV retinitis.

Due to the patient's multiple opportunistic infections, an immune work up was initiated. Her HIV antigen and antibody tests were positive, and her CD4 count was 0 cells/mm³ leading to the diagnosis of AIDS. In addition to her presentation with multiple AIDS-defining illnesses, she later developed perforated appendicitis secondary to CMV and Plasmoblastic Non-Hodgkin Lymphoma, an HIV associated malignancy.

Although HIV infrequently progresses to AIDS in the United States due to accessible screening with more rapid diagnosis and treatment, our case highlights the importance of being vigilant in the screening of immigrant populations. The early diagnosis and initiation of treatment for HIV could prevent the progression to AIDS, therefore diminishing the risk of severe opportunistic infections and HIV-related malignancies.

369 MULTIPLE SCLEROSIS

A Shipp*. *LSU, Shreveport, LA*

10.1136/jim-2017-000697.369

Case report 17 y.o. obese AAF s/p MVC 2 months ago, no significant PMH, presented to ED on 9/26/17 for light-headedness, and ongoing, worsening RLE weakness.

MCV July 2017, patient was restrained driver who was hit on the driver's side with +airbag deployment, was ambulatory at scene, seen at OSH for neck and low back pain. Informed it was muscular pain and discharged on Flexeril and NSAIDs. Two weeks after MCV, patient began to feel 'off balance' and 'stiff' throughout her lower body. Since approximately 8/11/17, she experienced difficulty walking: started with R-sided limp and progressed to severe RLE weakness and tingling from the toes to the thigh. Required assistance to ambulate.

Patient denied recent fever, URI sx, incontinence, seizures, LOC, current pain or prior episodes of similar sx.

Neurology Mental status: alert, attentive, oriented x3, intact spontaneous speech.

Cranial Nerves II-XII Intact.

Strength

Upper Motor Strength Exam: unremarkable 5/5

Iliopsoas

R/2

L/4

Quadriceps

R/2

L/4

Hamstring

R/2

L/4

Tibialis ant

R/2

L/4

Gastrocne

R/2

L/4

Sensory:

Reduced sensation to LT, PP on the RLE

Reflex: Babinski upgoing on right

Triceps

R/2

L/2

Knee

R/2

L/2

Biceps

R/2

L/2

Ankle

R/2

L/2

BR

R/2

L/2

Coordination: normal finger to nose, finger tap

Station/Gait: deferred

CRP of 2.14 and ESR of 24.

CBC, CMP, RPR, ANA, UDS, urine pregnancy test, and RLE ultrasound: unremarkable

CSF: nucleated cells 68, protein 65, and mono/macro 3%. Opening pressure: 24. Culture, Gram stain, glucose, RBC, color, lymph, HSV PCR unremarkable.

Ophthalmology: Mild retinal nerve fiber layer thinning of right eye; superior changes on Humphrey visual field testing BL with low reliability

Brain/Cervical spine MRI: Inflammatory changes represented by multiple enhancing lesions with many of them following the periependymal veins and showing open ring sign. Cervical spinal cord lesions also noted. Findings consistent with MS in a stage of relapse.

Diagnosed with MS, patient began PT/OT, and 1 gram of Solu-Medrol daily for 5 days. Mild RLE strength improvements have been noted so far. Blurred vision has been absent since admission. Plasma exchange scheduled.

Differential Diagnosis: Autoimmune (MS, Sarcoidosis, Sjogren's, Behcet, SLE, APS, MG, Vasculitis, NMO), Vascular (Leukoencephalopathy, Stroke, AVM), Infectious (Encephalitis, Syphilis, Lyme), Metabolic (Vit B Deficiency, Mitochondria Diseases), Neoplasm.

370 ARM WEAKNESS IN AN INFANT

C Smith*, E Sales, C Seaton, N Evans. *Our Lady of the Lake, Baton Rouge, LA*

10.1136/jim-2017-000697.370

Case report A previously healthy 4-month-old female with a 2-day history of fever presented to the emergency room with new onset right-sided weakness. Initial work-up was remarkable for a peripheral white blood cell count of 25.9 (1000/ul). A comprehensive metabolic panel and cerebrospinal fluid studies were normal. Head CT showed no acute intracranial abnormalities. MRI/MRA revealed a middle cerebral artery infarction involving the left basal ganglia. Pediatric hematology recommended further coagulation studies including Factor V Leiden, antiphospholipid antibody panel, homocysteine and protein C and S. No abnormalities were detected. The patient was discharged after 3 days of hospitalization at which time focal weakness was improving.

Stroke within the pediatric population was once believed rare but recent studies now estimate the annual incidence of arterial ischemic stroke to range from 1 to 8 per 100,000 children. Risk factors differ somewhat in this population as compared to adults and include cardiac abnormalities, vascular lesions, hematologic abnormalities, viral/bacterial infections, trauma and genetic conditions. Although we did not identify an etiology for our patient, we suspect a viral cause is possible, given her recent fever and leukocytosis. This is supported by previous literature that has established an association between infantile strokes and viral illnesses. At time of presentation, infants often lack appreciable focal weakness. Instead, seizures and altered mental status are common presenting symptoms. CT can be used as an initial screening study but cranial MRI is the preferred imaging study if readily available. After stabilization, all patients should undergo a full diagnostic evaluation. Prognosis is thought to be good with most studies showing greater than ninety percent survival rate. Despite neural plasticity, long-term disability is common and early intervention with specialized therapists is recommended.

Despite its rarity, hospitalists should include ischemic strokes in their working differential when evaluating pediatric patients with new onset focal weakness, seizures or altered mental status. In this case, the hospitalist team included stroke on their differential which lead to the proper evaluation and diagnosis. No underlying cause was identified in this case, which can occur in the pediatric population.

371 WHEN ALL ELSE FAILS: A CASE FOR DOXYCYCLINE IN PERTUSSIS

M¹ Smithson*, ¹R Smalligan, ²D Kimberlin, ³L Eiland, ¹P Abston. ¹UAB Huntsville, Huntsville, AL; ²UAB, Birmingham, AL; ³Auburn Harrison School of Pharmacy, Huntsville, AL

10.1136/jim-2017-000697.371

Case report A 13 yo male with moderate persistent asthma and depression presented with congestion and cough. His cough was spasmodic with post-tussive gagging. No fevers were reported. Physical exam: clear oropharynx, no wheezing and no other abnormalities. Patient's prior physician had advised avoiding pertussis vaccination due to a seizure after DTaP at 7 months. Nasopharyngeal swab was positive for *Bordetella pertussis* by PCR. The patient was on paliperidone, imipramine, and hydroxyzine prescribed by his psychiatrist. There is a black box warning for interaction between

paliperidone and macrolides due to risk of QT prolongation, and imipramine and hydroxyzine may increase this risk. He had a history of severe rash with TMP-SMX and a history of 'allergic reaction' to amoxicillin. His pediatrician considered referral for penicillin skin-testing and rapid desensitization; however the need for timely treatment and concern for exposing others made that option nonviable. Also, amoxicillin has reported in vitro activity against pertussis but in vivo activity is questionable. Both pediatric infectious disease and a PharmD were consulted. Doxycycline 100 mg BID for 10 days was recommended based on historical use and documented in vivo evidence of efficacy. An ECG was obtained to evaluate QT status, considering his multiple medications, and the QT was normal. A follow up nasopharyngeal culture obtained after treatment, 17 days after initial presentation and 24 days after onset of symptoms, was negative. The patient reported improvement in symptoms. A Tdap was strongly advised.

Discussion Pertussis has increased from 4,570 cases in 1990 to 32,971 in 2014. With the increase of pertussis, treatment to shorten duration of symptoms and decrease transmission is important. Due to the rise in polypharmacy, pediatricians may encounter patients unable to use standard recommended treatments. Macrolides have been effective in the treatment of pertussis, but in patients unable to take a macrolide, TMP-SMX is recommended. This case illustrates another alternative when these first two lines cannot be used: doxycycline. This case also reminds physicians of recognizing potential drug-drug interactions such as prolonged QT syndrome.

372 RITSCHER-SCHINZEL SYNDROME

S Staples*, J Phillips. *University of Alabama, Birmingham, AL*

10.1136/jim-2017-000697.372

Introduction Congenital heart disease and Dandy-Walker malformations are common isolated findings, however, when present concurrently and in combination with other dysmorphisms, further evaluation is necessary for a possible unifying diagnosis.

Case presentation This 38 WGA male infant was delivered via Cesarean for breech presentation and new onset oligohydramnios. Multiple congenital anomalies were noted on prenatal ultrasound including Dandy-Walker variant malformation with mild ventriculomegaly and complex cardiac defect. Physical exam noted micrognathia, occipital and left frontal prominence, high, narrow-arched palate, bilateral clubbed feet and III/VI systolic murmur at the left lower sternal border. Head ultrasound was normal, but MRI showed pontine and cerebellar hypoplasia with small fourth ventricle. Echo showed tetralogy of Fallot with double outlet right ventricle, mild pulmonary valve stenosis and PDA. Genetics was consulted and Ritscher-Schinzel (3C – craniocerebello-cardiac) syndrome was suspected. Array CGH, karyotype and FISH for DiGeorge were normal. Specific gene mutation testing is pending.

Discussion Ritscher-Schinzel Syndrome was first diagnosed in 1987 with very few documented cases and unknown prevalence, but it is suspected to be underdiagnosed given overlapping features with other syndromes – Joubert Syndrome as well as Dandy-Walker Syndrome. Diagnosis requires cardiac and cerebellar involvement, generally a Dandy-Walker variant, and craniofacial abnormalities including clefts, colobomas, or

four of the following: prominent occiput, prominent forehead, hypertelorism, micrognathia, depressed nasal bridge, down-slanting palpebral fissures and low set ears. Two gene mutations have been identified including KIAA0196 gene on chromosome 8q24 that has autosomal recessive inheritance and CCDC22, which has also been implicated in x-linked recessive intellectual disability.

Conclusion Cardiac and cerebellar anomalies are non-specific findings and it requires a high index of suspicion to identify some of the subtle craniofacial features and pursue specific gene testing for Ritscher-Schinzel Syndrome. The significant intellectual disability in children with Ritscher-Schinzel Syndrome as well as the autosomal recessive inheritance pattern are important for early intervention and management and have implications for long-term family planning.

373 CONGENITAL DIAPHRAGMATIC HERNIA IN A 16-MONTH-OLD PRESENTING WITH SEVERE IRON DEFICIENCY ANEMIA

S Suhag*J Putman, Ali Z Mohamad, L Campion. *University of Oklahoma School of Community Medicine, Tulsa, OK*

10.1136/jim-2017-000697.373

Case report A 16-month-old female presented to an outside hospital (OSH) with chief complaint of cough, fever, and 'earthy smelling' brownish sputum consistent with a viral respiratory infection. A complete blood count (CBC) four months prior showed a mild normocytic anemia during influenza illness [Hemoglobin (Hgb) 9.7 g/dL; Mean Cell Volume (MCV) 71.5 fL] that resolved 1 week later without intervention [Hgb 11.1 g/dL; MCV 72.3 fL]. On presentation to the OSH, she had severe microcytic anemia [Hgb 4.2 g/dL; MCV 47 fL]. A large hiatal hernia was incidentally found on the patient's chest X-ray (CXR) at this time, however it was not commented on as a source for her anemia. She was transferred to our pediatric intensive care unit (PICU) for stabilization and further management of her anemia. In the PICU, she was RSV positive. At this time, her CXR was re-evaluated and the CDH was noted. Iron studies showed severe iron deficiency with a low ferritin level of 4 ng/mL, low iron saturation of 2.7%, and an elevated total iron binding capacity (TIBC) of 589 ug/dL. She received two units of PRBCs. Upper GI confirmed a large hiatal hernia with associated gastric organoaxial volvulus. She underwent repair of congenital hiatal hernia with no complications. IV Venofer was given to help replete iron stores and she was started on oral iron supplementation upon discharge. Prior to discharge, her Hgb level was 10.5 g/dL. At 2 month follow up, her Hgb was stable at 10.6 g/dL. This study provides support for imaging and other diagnostic studies when the source of refractory IDA is uncertain. CDH is rarely seen as a cause of IDA in pediatric patients. Although the etiology is unclear in children, the theory in adults is the formation of Cameron lesions, linear erosions of stomach mucosa secondary to constriction by the diaphragm, lead to chronic blood loss. Treatment of IDA in the setting of CDH involves surgical correction. This case demonstrates a rare cause of microcytic anemia and the importance of considering GI origins of IDA when the etiology is unclear.

374 A CASE OF JAMESTOWN CANYON ENCEPHALITIS IN LOUISIANA

K¹ Tierling*, ²M Therwhanger, ¹F Laique, ¹A Uzodi. ¹*Our Lady of the Lake Children's Hospital, Baton Rouge, LA;* ²*Our Lady of the Lake Hospital, Baton Rouge, LA*

10.1136/jim-2017-000697.374

Case report Jamestown Canyon virus is a mosquito-vector zoonotic pathogen belonging to the California subgroup of orthobunyavirus. It was first isolated in a pool of mosquitos in Jamestown, Colorado in 1961. Typical vertebrate amplifier hosts include white-tailed deer, but is also significantly associated with large mammals. It has since been determined that although rare, humans can also serve as hosts to this virus causing diseases such as encephalitis or meningitis. In the United States between 2000–2013, there were 31 identified cases of JCV disease in residents of 13 states, with the majority of cases in Wisconsin. In that time, the only state in the South with identified cases was Mississippi. We report the first confirmed case of Jamestown Canyon Encephalitis in Louisiana.

A 13 year old girl living in rural Louisiana experienced sudden onset of symptoms beginning with headache, vomiting and fever in early summer which rapidly progressed to central nervous system involvement with seizures and left thalamic edema vs stroke. The patient was subsequently diagnosed with meningoencephalitis. Serology studies initially resulted positive for California La Crosse Encephalitis. Repeat samples of blood and cerebrospinal fluid were sent to the CDC and the patient was later confirmed to have acute infection of Jamestown Canyon virus rather than California La Crosse virus. Following 8 days of intensive care treatment she was discharged. Over the next 4 months she required subsequent hospitalization due to complications consisting of recurrent seizures, short-term memory loss and headaches.

We believe this to be the first reported case of encephalitis associated with Jamestown Canyon virus infection to be documented in Louisiana. This case supports a prior analysis published in American Journal of Tropical Medicine that this virus may be an under-recognized mosquito-borne viral disease that may be endemic throughout the United States. We recommend that physicians consider JCV disease in patients who develop acute fever, meningitis, or meningoencephalitis in late spring to early fall in the United States when more common etiologies such as enterovirus, herpes simplex virus and West Nile virus are negative.

375 SUBCUTANEOUS FAT NECROSIS FOLLOWING THERAPEUTIC HYPOTHERMIA

E Tucker*, D Lafitte. *LSU Health Science Center, Shreveport, LA*

10.1136/jim-2017-000697.375

Case report Subcutaneous fat necrosis is a rare but potentially serious complication seen in newborns who have undergone therapeutic moderate hypothermia after a hypoxic ischemic event around the time of delivery. Due to the pathophysiology of fat necrosis, patients are at risk of hypercalcemia which could potentially be life threatening. Clinicians need to be aware of this risk factor so they can identify and monitor

patients for this potential complication.

The patient is a term male newborn who was transferred to our NICU from an outside hospital for a higher level of care. He was born at 37 w 4 d to a 37 year old G1P0 mother. Mother received routine prenatal care and labor was complicated by eclampsia. Mother was offered a cesarian section but opted to continue with a vaginal delivery. At birth, patient had APGAR scores of 2 and 3 at 1 min and 5 min respectively. He required extensive resuscitation at the time of delivery including chest compressions, intubation and 2 rounds of epinephrine. His blood gas showed significant acidosis and patient had 2 seizures within 30 min of delivery. Transfer to a higher level of care was arranged and patient was cooled prior to transfer.

Patient was transferred without complication. His temperature at admit to our NICU was 31.1 C. He remained cooled for 72 hours at a temp of 33.5 C and was rewarmed over 6 hours. The patient's neurologic status slowly improved. On day 10 of life, it was noted that patient had some discoloration on his back. Initially the areas were faintly red, diffuse and appeared tender but darkened as time progressed. Firm nodules developed on his buttocks, sacral area, back, arms and the occipital region of his skull. Patients labs at that time revealed thrombocytopenia at 79 K/uL, elevated calcium at 10.5 mg/dl and a CRP of 10.5 mg/dl, all indicative of subcutaneous fat necrosis. Patients calcium was monitored closely for significant hypercalcemia, which he did not develop. His highest calcium was 11.2 mg/dl at the time of discharge. His neurologic status improved and he was discharged home to parents in stable condition with close follow up. At the time of discharge, the patient's fat necrosis was stable and no new nodules had presented.

376 FOOD PROTEIN INDUCED ENTEROCOLITIS SYNDROME (FPIES)

E Tucker*. *LSU Health Science Center, Shreveport, LA*

10.1136/jim-2017-000697.376

Case report Food Protein Induced Enterocolitis Syndrome (FPIES) is a non-IgE mediated type of food allergy that results in significant gastrointestinal symptoms including severe vomiting and diarrhea. Symptoms can lead to dehydration, change in body temperature and shock. Because it is not an IgE mediated response, symptoms may not show up immediately following ingestion of the causative agent which can complicate diagnosis.

The patient is a 7 month old male with no past medical history. He presented to the ED with mother due to severe vomiting and lethargy. Mother stated that patient was in his normal state of health until she picked him up from his aunt's house around 2300. Mother says shortly after he started vomiting, became cool to the touch, clammy, pale and had decreased responsiveness to stimulation. In the ED, patient started to have multiple episodes of watery diarrhea and continued vomiting. He required 2 fluid boluses with improvement in his physical exam and was admitted to the pediatric floor for further treatment and hydration with a suspected diagnosis of FPIES.

He was exclusively breast fed until the age of 6 months when mother started introducing solid foods. On the day of admission, patient ate pureed Banana and applesauce. He had

been introduced to both foods previously. He did not have any reaction to apples when introduced individually. With his first introduction to banana, patient took a single bite and refused further bites. His second exposure about 1 month prior to presentation, patient ate a small amount of banana. Shortly after, he developed coughing, gagging and started to wheeze. His third exposure was a few hours prior to his profuse vomiting and diarrhea. Labs at the time of admission were normal other than a slightly elevated WBC count at 19 K/uL. Patient was evaluated by Pediatric Allergy and Immunology who agreed with the diagnosis of FPIES due to Banana. Patient was discharged in stable condition and advised to avoid bananas and other fruits with similar proteins. An appointment with AI 4 months later measured his IgE levels to selected foods including banana and found that his levels were not elevated which is consistent with FPIES. Patient has continued to do well and is tolerating a variety of table foods.

377 PAINFUL RIGHT INGUINAL LYMPHADENOPATHY – A CASE REPORT OF CAT SCRATCH DISEASE

N Tutak*, R Welliver. *University of Oklahoma, Oklahoma City, OK*

10.1136/jim-2017-000697.377

Case report Our patient is a 9 year old girl with a PMH of repaired bilateral inguinal hernias that presented with fever, RLQ abdominal pain, and pain and bulging in the right inguinal region. Pediatric surgery was originally consulted in the ED for concern for incarcerated hernia which was ruled out. Patient lives on a farm and plays outside barefoot with her goats and farm cats. On physical exam the right inguinal area had a 3 × 4 cm palpable swelling with overlying erythema and was tender. The right lateral lower leg had a small healing red sore, not infected appearing. No other palpable lymphadenopathy was noted. Abdominal and pelvic US showed multiple enlarged lymph nodes and was concerning for cellulitis. *Bartonella* titers were sent due to exposure and were negative. Unasyn was started for likely cellulitis. Patient showed clinical improvement and was sent home on Augmentin.

Patient returned on two more occasions due to return of fever and increased bulging and tenderness in the right groin. Repeat US consistently showed numerous enlarged lymph nodes with the final US showing a small pocket of fluid. Multiple antibiotic courses (Vancomycin, Bactrim, and Clindamycin) were attempted with little improvement.

During the third and final visit *Bartonella* titers were resent. Pediatric surgery was again consulted and the patient was taken to the OR for biopsy of the right inguinal lymph node and I&D of the right inguinal abscess. Dermatology was consulted the day following surgery regarding the lesion on right lateral lower leg for concern that it could be the source of infection.

Surgery thought the lesion could be a staph infection. Dermatology had a wide differential. The epidemiology suggested it could be nontuberculosis mycobacterium due to cyclic response to antibiotics and subsequent worsening. Cat Scratch Disease is unusual on the lower extremity, however, the granulomatous lesion below the regional lymph node and the persistent swelling were suggestive of this diagnosis.

Patient significantly improved on day of discharge and was sent home. *Bartonella* titers came back showing 1:1280 IgG

for *Bartonella henslea* and negative IgM. Biopsy of the lymph nodes showed granulomatous inflammation consistent with cat scratch disease. Punch biopsy of the right lower leg showed granulomatous inflammation as well.

378

CONCOMITANT ACUTE TUBULAR INTERSTITIAL NEPHRITIS AND ACUTE TUBULAR NECROSIS IN A CHILD TREATED WITH VANCOMYCIN AND PIPERACILLIN/TAZOACTAM

¹ Varier*, ¹C Mertens, ²R Steele, ¹Dyke R Van. ¹Tulane University School of Medicine, Metairie, LA; ²Ochsner Medical Center, New Orleans, LA

10.1136/jim-2017-000697.378

Background Recent studies in adults have shown that combination of vancomycin and piperacillin/tazobactam (Vanc-Pip/Tazo) is associated with increased risk of acute kidney injury. There is a paucity of data on the nephrotoxicity of this combination in pediatric patients.

Clinical Case A 2 y/o previously healthy boy was admitted with pneumonia and initially treated with ceftriaxone and azithromycin. Worsening respiratory status on day 4 warranted a repeat CXR that showed moderate sized pleural effusion. Chest tube was placed, and a broncho-alveolar lavage (BAL) was performed. A chest CT showed poorly enhancing lung parenchyma suggesting lung abscess or lung necrosis. On day 5, antibiotics were changed to Pip/Tazo (100 mg/kg every 8 hours) and vancomycin at 15 mg/kg every 8 hours with dose adjustments to maintain a trough concentration of 10–20 mcg/ml, maximum dose administered: 26 mg/kg every 6 hours. BAL samples revealed methicillin sensitive *S. aureus*. Vanc-Pip/Tazo combination was continued for 14 days due to worsening on previous ceftriaxone regimen. On day 14 of the combination antibiotic therapy he developed new onset fevers, decreasing urine output and pedal edema. A complete metabolic panel was performed which showed a creatinine of 6.7 mg/dl. Baseline creatinine was 0.3 mg/dl. Immediately, all antibiotics were stopped and he was aggressively hydrated in the setting of his acute kidney injury (AKI). He met 'failure' criteria on p-RIFLE (urine output <0.3 ml/kg/hr for 24 hours) and was started on hemodialysis. Renal biopsy showed a concomitant acute tubular interstitial nephritis and acute tubular necrosis. He was treated with methylprednisone 10 mg/kg for 3 days followed by oral prednisone 2 mg/kg for 2 weeks. He improved significantly with a downtrending creatinine (1.3 mg/dl) prior to discharge. 10 day post-hospitalization follow-up was unremarkable with a normal creatinine level of 0.5 mg/dl.

Conclusion Vancomycin and Pip/Tazo combination should be judiciously used in the pediatric population with close monitoring of the renal function. Further prospective studies for safety of this combination in the pediatric population are needed.

379

WEAK FOOT ON THE GAS (GROUP A STREPTOCOCCUS)

HV Vashi*, A Miller, A Tanios. Saint Louis University, Saint Louis, MO

10.1136/jim-2017-000697.379

Case report A healthy immunized 13-year-old Caucasian male presents with 3-day history of epigastric pain and fever of

106.1F. Abdominal CT scan was negative. Despite empiric antibiotic therapy, he went into septic shock requiring vasopressors and was intubated for altered mental status. Blood culture grew streptococcus pyogenes, and he was transitioned to IV Clindamycin and Penicillin G. On day 5 of hospitalization, he became agitated and confused and developed poor strength in the left upper and lower extremities with left facial droop. Differential diagnosis included brain abscess, brain empyema, stroke, dural sinus thrombosis, and cerebritis. Head CT showed paranasal sinusitis. Lumbar puncture was negative, and brain MRI revealed right frontoparietal cerebritis with meningitis. ECHO showed normal anatomy with no vegetations. After paranasal surgery, he had prolonged seizures and was started on antiepileptic therapy. EEG was abnormal over right frontal hemisphere indicating lateralized encephalopathy and cerebritis. He completed his 3 weeks of IV Penicillin G at home with physical therapy.

Discussion Streptococcus pyogenes (GAS) is a beta-hemolytic gram-positive bacteria that can cause a wide range of infections leading to more than 500,000 deaths per year. GAS can range from pharyngitis and impetigo to more invasive infections such as toxic shock syndrome, necrotizing fasciitis, bacteremia, acute rheumatic fever, poststreptococcal glomerulonephritis, sinusitis, neuropsychiatric disorders, and central nervous system infections. Cerebritis is an infection of the brain, specifically inflammation of the cerebrum which controls memory and speech. Symptoms range from headache, anxiety, and memory loss to seizures, vision disturbances, dizziness, behavior changes, and stroke. Common causes include an infection (bacterial or viral), lupus systemic erythematous, or when infectious agents enter the brain through the sinus or via trauma. Treatment includes antibiotics if caused by an infection and steroids to reduce brain swelling.

Conclusion GAS has an extensive plethora of organ systems infections ranging from non-invasive skin infections to more serious heart and kidney complications. Of this variety, there are several rare debilitating neurological complications that must be kept in mind when a GAS infection is identified.

380

IT'S JUST A PET. OH RATS!

HV Vashi*, A Tanios. Saint Louis University, Saint Louis, MO

10.1136/jim-2017-000697.380

Case report A previously healthy, immunized 15-year-old Caucasian male presents with 1-week history of fever and rash after his father's pet rat bit him on his 4th left phalanx 3 weeks prior. A small reddish-purple blister initially formed that resolved 2 days later. He then developed back pain, headache, vomiting, bilateral diffuse arthralgias, and a dark purple macular rash on extremities sparing his trunk. His labs revealed: elevated ESR (89) and procalcitonin (0.89). Rabies vaccine and immune globulin were administered, and he was started on IV Penicillin G 3,000,000 units q4 h. ECHO was normal. Blood culture grew Streptobacillus moniliformis. On hospital day 5, patient was discharged on 5 more days of Amoxicillin. Follow-up 1 week later revealed that arthralgias and feeding continuing to improve.

Discussion A patient with the constellation of symptoms including fever, headache, vomiting, arthralgias, and rash in the setting of a rat bite has a wide differential diagnosis including rabies, Rocky Mountain Spotted Fever, Ehrlichiosis,

Tularemia, and rat bite fever. More than 2 million animal bites occur each year in the United States with 1% from rats. Rat bite fever is caused by *Streptobacillus moniliformis* or *Spirillum minus*. *S moniliformis* infection includes fever, headache, migratory polyarthritis, rash, and no lymphadenopathy. It is transmitted by bites or scratches from infected rats, gerbils, or squirrels and accounts for most cases of rat bite fever in the United States. SPS-free media should be used for diagnosis. There are numerous complications of rat bite fever including endocarditis, vasculitis, soft tissue/solid organ abscesses, osteomyelitis, and septic arthritis. Endocarditis will need to be ruled out via ECHO. Vasculitis requires biopsy with histopathology verification for diagnosis. Soft tissue and solid organ abscesses, osteomyelitis, and septic arthritis all must be verified via MRI. Treatment of choice is 7–10 days of penicillin/amoxicillin with the addition of streptomycin/gen-tamicin in cases complicated with endocarditis.

Conclusion There is a large infectious differential diagnosis concerning the symptoms of fever, headache, vomiting, arthralgias, and rash in the setting of a rat bite. Rat bite fever has a wide variety of complications, and with this comes diverse workup strategies and different treatment modality.

381 CONRADI-HÜNERMANN-HAPPLE SYNDROME, X-LINKED DOMINANT CHONDRODYSPLASIA PUNCTATA 2

S Walter*, K Wierenga, J Collinge, H Chaaban. *University of Oklahoma Health Sciences Center, Oklahoma City, OK*

10.1136/jim-2017-000697.381

Case report A term female born at 37 weeks gestation to a 47 year old G1P0 female with prenatal ultrasound findings of multiple anomalies and biometric disproportion, including small for gestational age with severe micromelia of all extremities, bell shaped chest, kyphoscoliosis, and arthrogryposis. Birth weight 2042 grams. Exam was significant for scattered alopecia on scalp, absent red reflex, diffuse skin thickening consistent with ichthyosis, small low-set ears, and shortened neck. Additionally, asymmetric shortening of extremities right versus left with limited spontaneous movement observed. Skeletal survey revealed stippled calcifications at growth plates of extremities and costal cartilaginous junctions of sternum and spine. Ophthalmologic exam revealed bilateral cataracts, microphthalmia, and optic nerve hypoplasia. Exam and skeletal survey indicated X-linked dominant chondrodysplasia punctata 2 (CDPX2). Biochemical sterol quantification showed increased level of 8(9)-cholestenol (71ug/mL, range 0–0.1), consistent with deficiency of (8)- (7) sterol isomerase emopamil-binding protein (EBP), an integral membrane protein located mainly in the endoplasmic reticulum functioning as a key enzyme in the final steps of the sterol biosynthesis pathway. EBP sequencing revealed a c.169_173delCCATT 5 base pair deletion in exon 2. Biochemistry and sequencing findings are consistent with the clinical diagnosis.

CDPX2, also known as Conradi-Hünermann-Happle Syndrome, is a heterogeneous disorder characterized by punctiform calcification of the bones, congenital ichthyosiform erythroderma, cataracts, and optic nerve atrophy. It occurs in 1 of 400,000 infants and predominately affects females.

Diagnosis is clinical and confirmed biochemically with increased concentration of 8(9)-cholestenol in plasma, skin lesions, or cultured lymphoblasts. Molecular genetic testing is used typically when biochemical results are equivocal. Treatment is supportive management of orthopedic and ophthalmologic abnormalities.

In summary, diagnosis of Conradi-Hünermann-Happle syndrome should be suspected when bone stippling on skeletal survey and skin lesions are present in neonates with skeletal anomalies.

382 EARLY INITIATION OF HORMONE THERAPY: LIFE SAVING TREATMENT FOR A TRANSGENDER TEEN WITH ANOREXIA

A Webb*, M Ladinsky. *UAB, Birmingham, AL*

10.1136/jim-2017-000697.382

Case report Transgender teens have an increased risk of disordered eating behaviors compared to traditionally high-risk populations. Conventional thinking has prioritized treating the eating disorder prior to addressing gender dysphoria. This case highlights the interplay between the two entities and the importance of affirming and concurrent therapies for optimal outcome.

Case The patient is a 13-year-old female-to-male transgender teen who was referred to Eating Disorders clinic after his pediatrician noted massive weight loss. On initial presentation, BMI was at the 10th percentile. Patient endorsed over-exercising and caloric restriction to less than 500 calories per day beginning at the onset of puberty. Despite close follow up in Eating Disorders clinic, he continued to have difficulty gaining weight. He endorsed significant anxiety surrounding his body image and the potential for return of feminine ‘curves.’ Pubertal suppression with Lupron was explored but was cost-prohibitive, so Depo-Provera was begun to induce cessation of menses. While he gained incremental weight, the patient’s disordered eating behaviors and depression worsened dramatically with return of female body characteristics. After multiple discussions between the Pediatric Gender Team, patient, and family, a decision was made to start testosterone therapy. Upon initiating testosterone, patient had complete resolution of his disordered eating with marked improvement in depression.

Discussion Gender dysphoria and eating disorders are intricately linked. The suppression of secondary sexual characteristics attained from malnourishment and severe caloric restriction serves to reinforce disordered eating. Fear of regaining body shape that does not match gender identity is a significant barrier to recovery.

Conclusion Heightened public awareness of gender diversity in childhood and adolescence is prompting more youth and families to seek related medical and mental health services. Co-occurring gender dysphoria and disordered eating may be grossly underestimated. Understanding and recognizing the complex interplay between transgender identity, gender dysphoria, and disordered eating patterns allows providers to deliver comprehensive and affirming medical and mental health care for one of our most vulnerable and critically underserved populations.

383 A RARE CAUSE OF LEFT VENTRICULAR DYSFUNCTION IN PATIENT WITH BICUSPID AORTIC VALVE AND MODERATE AORTIC VALVE STENOSIS- LEFT MAIN CORONARY STENOSIS

EA Wiewiorowski*, A Mir. *OU Children's Hospital, Oklahoma City, OK*

10.1136/jim-2017-000697.383

Case report Patient is a 2 yo with a history of circumflex right aortic arch s/p successful arch repair in infancy. He was also noted to have a bicuspid valve and had stable moderate aortic valve stenosis with normal LV ejection fraction. On his routine follow up cardiology visit, he presented with a 3 day history of fever, cough and other symptoms of upper respiratory infection. His echo at that time showed new finding of severe left ventricular systolic dysfunction with ejection fraction below 30%. The patient was found to be Rhino/Enterovirus positive with BNP of 4730 concerning for possible new onset viral myocarditis or congestive heart failure due to secondary left ventricular dysfunction secondary to long standing aortic stenosis although his last echo done 6 months ago had shown preserved ventricular systolic function.

The patient was admitted for medical treatment with diuresis and inotropic support, which did not improve his left ventricular systolic function. A follow up echocardiogram showed increasing flow velocity across proximal left main coronary artery compatible with coronary artery ostial stenosis. A cardiac catheterization was done which confirmed long segment left main coronary artery stenosis however a balloon aortic angioplasty was not successful. The patient was then taken to the operating room where a surgical valvotomy was done and ostial stenosis was confirmed. An ostioplasty was done successfully at that time.

The patient's left ventricular function improved after surgery. At his last follow up 6 months later, he has low normal left ventricular systolic dysfunction with EF in the low 50s with mild to moderate residual aortic valve stenosis with mild aortic valve regurgitation.

Coronary artery ostial stenosis has not been previously reported in patients with bicuspid aortic valve disease and aortic stenosis. This case highlights the importance of a thorough review of all imaging studies and maintaining a broad differential in order to provide successful patient management in patients with a rare combination of defects.

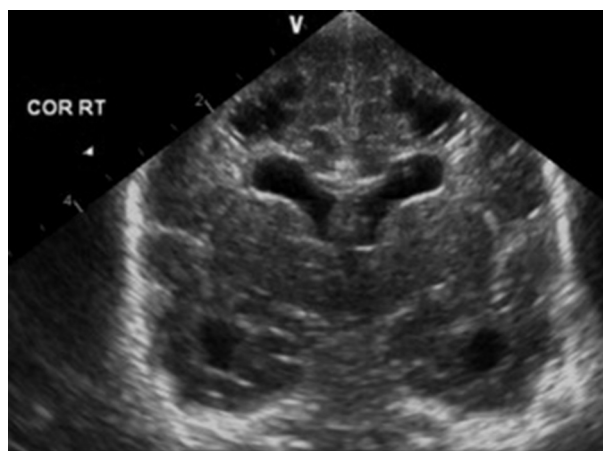
384 NEUROFIBROMATOSIS TYPE 1 WITH VANISHING WHITE MATTER

TJ Wilaisakditipakorn*P Maertens. *University of South Alabama, Mobile, AL*

10.1136/jim-2017-000697.384

Case report Neurofibromatosis type 1 (NF1) is an autosomal dominant neurocutaneous disorder caused by mutation in the Neurofibromin gene (NF1 gene). The oligodendrocyte myelin glycoprotein (OGMP) gene is also embedded within the NF1 gene. OGMP is localized on the surface of myelin and oligodendrocyte processes. Brain MRI of patients with NF1 commonly shows white matter (WM) changes that increase in size in childhood and resolve in adolescence. We report an infant with NF1 with unusual presentation of vanishing WM with sparing of the gray matter. A male infant of a 25 year-old female with known NF1 suffering from hypertension,

preeclampsia and intrauterine growth restriction was born by a cesarean section at 22 weeks gestational age with birth-weight of 329 grams with Apgars score of 6 and 9 at 1 and 5 minutes. Multiple café au lait spots were noted and head circumference was at the 41 percentile. During the first month of his life he required ventilator support then was extubated on day 39 and placed on CPAP. Cranial ultrasounds were normal initially including the one done on day 28. He deteriorated on day 44 which he required reintubation and a chylothorax drainage. Seizures were suspected on day 47. Repeated cranial ultrasound on day 53 showed early subcortical WM changes with small cyst formation. Over time cysts became coalescent involving the entire WM with corpus callosum atrophy consistent with vanishing WM (figure 1). We postulate that under stress at an early phase of the brain development, the dysfunction of the OGMP gene embedded in a mutant NF1 gene may provokes a break-down of the oligodendrocytes leading to vanishing WM in patient with NF1.



Abstract 384 Figure 1 Over time cysts became coalescent involving the entire WM with corpus callosum atrophy consistent with vanishing WM

385 LARGE ABDOMINAL MASS IN AN ADOLESCENT MALE

¹JA Wilkes*, ¹EM Oudin, ²M Huckabee. ¹University of Arkansas for Medical Sciences, Little Rock, AR; ²Arkansas Children's Hospital, Little Rock, AR

10.1136/jim-2017-000697.385

Case report We present the case of a 14-year-old male with complaints of vague abdominal pain and abdominal mass. One month before presentation he noticed decreased appetite, constipation, abdominal pain, and left flank pain when lying flat. During this time he had subjective fevers, night sweats, and an 11 lb weight loss. Two weeks before referral to our hospital his primary care provider gave a diagnosis of constipation and prescribed laxatives. This resolved his constipation, but did not improve the other symptoms. Soon after this, our patient noticed a bulge in his abdomen. His PCP ordered an abdominal non-contrast CT, which revealed a large retroperitoneal mass, presumed to be arising from the kidney. The patient was referred to us for follow-up. On the admission physical exam, he appeared well and in no distress. There was visible protrusion of the left upper abdomen, which was solid, non-mobile, and tender when palpated. A genitourinary exam was not performed initially. The remaining exam was

unremarkable. Labs were normal, except an elevated LDH. Radiologist review of the previously obtained images reported that the mass appeared to be a retroperitoneal lymphadenopathy compressing the left ureter concerning for lymphoma. CT of the head, neck, chest, abdomen, and pelvis was performed. In addition to the abdominal mass, a large testicular mass was seen. Findings were consistent with a primary testicular tumor with metastasis to the para-aortic lymph nodes. AFP and β -HCG levels were elevated. Our patient underwent a left orchiectomy, and tissue biopsy revealed a mixed germ cell tumor comprised of 50% yolk-sac tumor, 40% embryonal tumor, and 10% teratoma. Our patient was transferred to the Hematology-Oncology service for further management.

Testicular cancer is the most common malignancy affecting males age 15–35. Metastasis is responsible for symptoms at presentation in 10% of cases. While treatable with a 5-year survival of 95%, early detection yields better outcomes. In our patient, the tumor was discovered at a later stage via imaging, when a thorough physical exam and broader differential could have allowed earlier discovery. This case is significant because it highlights the importance of a broad differential and thorough physical exam.

386 PROLONGED FEVER WITH HIP ARTHRITIS: INFECTIOUS OR AUTOIMMUNE?

BN Williams*, S Field. UAB Huntsville, Huntsville, AL

10.1136/jim-2017-000697.386

Case report A previously healthy 5-year-old boy presented with fever up to 102.5 F and refusing to bend his right knee for 4 days. He had no other symptoms other than vomiting 4–5 times the first night. Exam was unremarkable other than a slightly red throat. His throat culture was negative and blood count normal, but C-reactive protein (CRP) was 2.2 and sed rate (ESR) was 52. In the next 4 days, he developed right hip pain that coincided with temperature spikes and was admitted for 3 days during which his symptoms continued. With his CRP 0.9 and ESR 44, antibiotics were withheld. ASO, RF, ANA and serologies for CMV, EBV, and parvovirus were negative. Fluid from his right hip had 10,590 nucleated and 5,000 rbc's / uL with 92% neutrophils. Fungal, bacterial, and mycobacterial cultures, as well as amplified nucleic acid tests for 15 bacteria, were negative. He improved with less than a week of anti-inflammatories and was afebrile in less than 2 weeks. Arthritis symptoms also improved, and never involved other joints. Past history was remarkable for over 2 weeks of unexplained fever at 20 months age, and family history included multiple relatives with autoimmune diseases.

Discussion Fever lasting over a week along with a monarticular arthritis in a child could be caused by an infected joint, or could represent a reactive arthritis to a remote (e.g. gastrointestinal or streptococcal) infection, or less likely a post infectious arthritis. Clinical resolution without antimicrobial treatment along with extensive negative cultures and serologies argue against infectious or septic arthritis. Acute onset of monarticular arthritis associated with fever could go with systemic onset juvenile idiopathic arthritis (SOJIA). His previous prolonged unexplained fever and positive family history of autoimmune diseases might support SOJIA. Elevated inflammatory markers are seen with both infections and SOJIA, but his relatively rapid recovery without more than a week of anti-

inflammatories would make a non-rheumatic fever reactive arthritis diagnosis more likely.

387 A DOG SCRATCH MIGHT NOT ABSCESS YOUR LIVER – BUT A CAT SCAN: AN IMAGE-GUIDED DIAGNOSIS OF DISSEMINATED BARTONELLA

KE Wimberly*, AG Lile. University of Kentucky, Lexington, KY

10.1136/jim-2017-000697.387

Case description A previously healthy 11 yo male was admitted to the hospital for evaluation of one month of fever and episodic abdominal pain after multiple visits to his primary pediatrician did not reveal an etiology. Mother reported that he had daily fevers for four weeks with temperatures to 104F and ongoing left-sided abdominal pain that had worsened in the last three days. He endorsed fatigue, night sweats, anorexia, and a 9-lb unintentional weight loss in the last month. He lives on a farm in a rural area, and his family has several outdoor dogs and cats, including a litter of kittens. He had no recent sick contacts, travel history, or tick exposure.

On exam, he was afebrile; vitals were normal except mild hypertension for age. He had nontender lymphadenopathy in anterior and posterior cervical chains, left axilla, and bilateral inguinal regions. His abdomen was soft and nondistended but tender to palpation in the left and right upper quadrants.

Basic labs were unremarkable and blood and urine cultures were negative. CT abdomen and pelvis with contrast revealed multiple low-attenuation lesions within the liver and spleen, the largest measuring 1.9 cm, concerning for infarction, septic emboli, or abscesses. Bartonella henselae titers were strongly positive confirming disseminated cat scratch disease.

Discussion Cat scratch disease (CSD) is an infectious disease usually caused by Bartonella henselae. CSD is most common in the southern United States, with peak incidence in children ages 5 to 9. CSD is typically self-limited and involves local lymphadenopathy near the site of a cat scratch or bite. CSD can rarely present as disseminated disease.

Disseminated disease is most common in those who are immunocompromised, but has been reported in immunocompetent patients. CSD can rarely cause liver or spleen granulomas or microabscesses in immunocompetent children. Hepatosplenic disease has been reported in 0.3–0.7% of patients with CSD. This patient had a classic presentation of this unusual manifestation of CSD. He was treated with 14 days of rifampin and doxycycline and had complete resolution of symptoms by the end of the antibiotic course.

Conclusion Hepatosplenic abscesses are an unusual, but important, manifestation of cat scratch disease in immunocompetent children.

388 AN INFANT WITH ALPHA THALASSEMIA X-LINKED INTELLECTUAL DISABILITY SYNDROME

H Wongprasert*N Sanderson, J Philips. UAB, Birmingham, AL

10.1136/jim-2017-000697.388

Case A former 29 wk male was transferred for management of complex medical problems. He was intubated for respiratory distress and required prolonged mechanical ventilation. He had clinical seizures treated with phenobarbital. EEG

showed diffuse cerebral dysfunction. CBC showed normocytic anemia. PE showed a small, upturned nose, low-set ears with posterior rotation and frontal bossing, post-axial polydactyly of all extremities, and a small area of cutis aplasia over the lumbosacral area. Heart, head, renal and lumbosacral ultrasounds were normal. Maternal history revealed a history of Alpha thalassemia X-linked intellectual disability (ATRX) syndrome. A maternal uncle has a confirmed diagnosis (SC with A to G mutation which creates novel splice in exon7, resulting in a portion of XNP being removed). Maternal GM is a carrier. Given the infant's characteristic dysmorphic features, positive family history and laboratory results consistent with alpha thalassemia, a clinical diagnosis of ATRX syndrome was made. CGH microarray was normal.

Discussion ATRX syndrome is a rare X-linked recessive disorder resulting from mutations of the *ATRX* gene located on the X chromosome. Over 200 cases have been reported but prevalence is unknown. Carrier females almost never have signs of this syndrome. Affected males have distinctive craniofacial features (small head circumference, widely spaced eyes, and short upturned nose), severe developmental delay, hypotonia, intellectual disability, and mild-to-moderate anemia. The diagnosis is made by clinical findings and positive family history. Genetic testing is not indicated unless the patient has an unclear family history or phenotypic findings overlapping with other syndromes. Differential includes alpha-thalassemia mental retardation chromosome16 (ATR-16) and alpha-thalassemia for which CGH array and alpha-globin genotyping can help in differentiating as they have similar clinical presentations. Management requires regular assessment of growth and development, early intervention programs and special education. Anemia is usually mild and rarely requires treatment.

Conclusion Early recognition and diagnosis of this syndrome could help with early developmental intervention and have a positive impact on the affected infants' development.

Perinatal medicine

Joint plenary poster session and reception

4:30 PM

Thursday, February 22, 2018

389

A UNIQUE PRESENTATION OF ACUTE LYMPHOBLASTIC LEUKEMIA WITH AN ELBOW FRACTURE AND LEFT FOOT SWELLING

¹JJ Zorrilla*, ¹A Athanasatos, ¹D Klawinski, ^{1,2}M Joyce. ¹University of Florida College of Medicine, Jacksonville, FL; ²Nemours Children's Clinic, Jacksonville, FL

10.1136/jim-2017-000697.389

Case report The early diagnosis of childhood leukemia is important for prompt initiation of therapy and avoidance of complications such as cytopenias, electrolyte imbalances, infections, and airway obstruction secondary to a mediastinal mass. Although the clinical features are well known, the broad signs and symptoms of leukemia can continue to confound the diagnosis. Particularly, delays in diagnosis may occur when the

main symptom is musculoskeletal in nature as this shares features with many orthopedic pathologies. We introduce the case of a 4 year old boy, who presented following an elbow fracture. Despite treatment, he continued to endorse elbow pain in addition to left foot swelling. Further evaluation of the swelling with MRI imaging revealed a left foot mass, which was biopsied and suggested the presence of leukemic cells. Subsequent bone marrow biopsy confirmed the diagnosis of B-cell acute lymphoblastic leukemia (ALL). This unique case demonstrates the importance for general pediatricians to be suspicious of acute leukemia in the setting of prolonged, multifocal bone pain.

390

RELATIONSHIP BETWEEN INTERMITTENT HYPOXEMIA AND INFLAMMATION IN PRETERM INFANTS: VICIOUS CYCLE

EG Abu Jawdeh*, P Westgate, A Pant, A Stacy, A Patwardhan, H Bada, P Giannone. University of Kentucky, Lexington, KY

10.1136/jim-2017-000697.390

Purpose of study Intermittent Hypoxemia (IH) is defined as episodic drops in blood oxygen saturation (SpO₂). IH have a cumulative effect on impairment in preterm infants. Inflammation worsens apnea and subsequently may increase IH. There is rising evidence from the laboratory suggesting IH is pro-inflammatory itself. Hence, interestingly, the relationship between inflammation and IH may be bidirectional. We wanted to test the hypotheses

1) infants born with perinatal inflammation due to maternal chorioamnionitis (MC) have increased IH and

2) increased cumulative IH is associated with increased inflammation.

Methods used 30 infants <30 wks GA were enrolled in this pilot trial and monitored until 4 wks of life with pulse oximeters (2s averaging time). Primary IH measure was percent time spent/week with SpO₂ below 80% (%time-SpO₂<80). MC was collected from medical charts. Blood samples were collected on day of life (DOL) 1 and 30 to measure high-sensitivity C-Reactive Protein (hsCRP). We adjusted for GA, gender, ethnicity, SNAP-PE scores. Infants with sepsis or NEC were excluded.

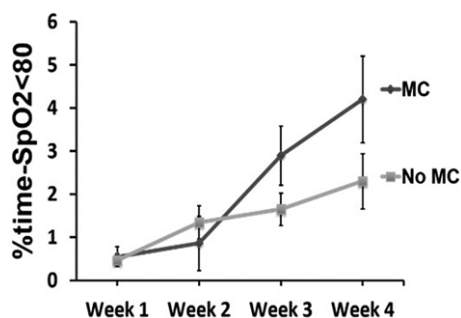
Summary of results Data were available for 26 patients (20 no MC, 6 MC). After adjusting for factors described in Methods

- Patients with MC had significantly increased IH during the study period (figure 1); $p < 0.05$.
- There was a positive correlation between cumulative IH and hsCRP at DOL 30 ($r = 0.6$, $p < 0.05$) (figure 2).

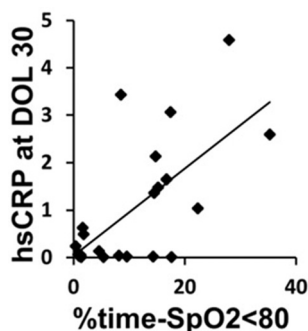
Conclusions Our results show

- the effect of MC on IH persisted beyond the perinatal period
- a positive association between increased IH and hsCRP at end of study period.

Both findings are documented for the first time in preterm infants. We speculate that perinatal inflammation starts or exacerbates a vicious cycle early leading to a snowball effect with persistent IH and increased inflammation.



Abstract 390 Figure 1



Abstract 390 Figure 2

391 RENAL CONSEQUENCES OF LOW-DOSE INDOMETHACIN FOR PREVENTION OF INTRAVENTRICULAR HEMMORHAGE IN EXTREMELY PREMATURE INFANTS

B Adcock*, M Hanna, P Giannone, J Bauer, S Carpenter. *University of Kentucky, Lexington, KY*

10.1136/jim-2017-000697.391

Purpose of study Indomethacin is commonly used in the first days of life in preterm infants to reduce the risk of intraventricular hemorrhage (IVH), but many clinicians avoid this agent due to concerns of renal injury. Our goal was to conduct a retrospective review of patient data at our institution to investigate the renal consequences of the use of indomethacin in the first three days of life in infants born <30 wks for IVH prevention.

Methods used Retrospective chart review was conducted of 102 premature infants <30 weeks (51 males and 51 females) admitted to the University of Kentucky Neonatal Intensive Care Unit from November 2014 to January 2017 with an average gestational age of 26.8 weeks (23.1–29.9 weeks) and average birth weight 913 g (480–1510 g). Daily urine output (ml/kg/hr) and serum creatinine during the first 7 days were reviewed to determine the incidence of AKI as defined by the neonatal modified Kidney Diseases: Improving Global Outcomes (KDIGO) in the first week of life. The incidence of

AKI was compared in those infants who received low-dose indomethacin for IVH prevention and those who did not. Chi squared statistical analysis was used for treatment comparisons. **Summary of results** Overall 52 of the 102 neonates (51%) received low-dose indomethacin for IVH prevention. Of the neonates that received indomethacin, 37% developed AKI and 24% who did not receive indomethacin developed AKI (P=0.2, NS). The incidence of severe AKI, stage 2 or 3, was 9.6% in those that received indomethacin and 10% in those that did not (P=1.00, NS).

Conclusions Low-dose indomethacin for IVH prevention in premature infants <30 weeks did not increase the incidence of severe AKI as defined by the neonatal modified KDIGO criteria.

392 RISKS OF ACUTE KIDNEY INJURY IN PRETERM NEONATES: IMPACT OF GENTAMICIN AND PROPHYLACTIC INDOMETHACIN

B Adcock, M Hanna, P Giannone, S Carpenter. *University of Kentucky, Lexington, KY*

10.1136/jim-2017-000697.392

Purpose of study Acute kidney injury (AKI) is a common morbidity in preterm infants and can have short term and long-term consequences. Immature nephrogenesis, disrupted renal development and toxic drug exposures all play a role in the development of AKI in the preterm neonate. Recently improved definitions of AKI in neonates have improved opportunities for mechanistic insights. We investigated the occurrence of AKI in preterm infants treated with gentamicin (GENT), in the absence or presence of prophylactic indomethacin (INDO) in the first week. Both of these agents are routinely used in most neonatal intensive care units and both have been separately documented to cause AKI. Our goal was to evaluate evidence of an interaction with these two agents with respect to AKI in preterm infants.

Methods used Retrospective chart review was conducted of 102 premature neonates <30 weeks (51 males and 51 females) admitted to the University of Kentucky Neonatal Intensive Care Unit from November 2014 to January 2017 with an average gestational age of 26.8 weeks (23.1–29.9 weeks) and average birth weight 913 g (480–1510 g). Daily urine output (ml/kg/hr) and serum creatinine during the first 7 days were reviewed to determine the incidence of AKI as defined by the neonatal modified Kidney Diseases: Improving Global Outcomes (KDIGO). The incidence of AKI within the first week of life were compared between GENT and GENT +INDO groups. Chi squared statistical analysis was used for treatment comparisons.

Summary of results Overall 34 of the 102 neonates (33%) had AKI in the first 7 days of life. Of the patients that received GENT alone, 22% developed AKI, and 10% were stage 2 or 3. Of the patients that received GENT+INDO treatment in the first week, 36% developed AKI, and 11% were stage 2 or

3. There were no differences in AKI risks between these two groups ($P=0.139$, NS).

Conclusions AKI in the first week of life is a common occurrence in preterm infants. The frequent use of GENT may contribute to these risks in our routine patient care. The combined use of prophylactic INDO in the presence of GENT does not apparently affect AKI risks in the first week of life in this high-risk patient group.

393 SYNDROMIC 46XY DISORDER OF SEX DEVELOPMENT; WORK UP AND GENETIC CONSIDERATIONS

TT Alexander*, CB Atchley. *University of Oklahoma, Oklahoma City, OK*

10.1136/jim-2017-000697.393

Introduction Key features to determine during the work up include of ambiguous genitalia are genotype, external and internal phenotype, and any other associated anomalies. We present a Syndromic 46XY DSD (Disorder of Sex Development) currently without determined genetic etiology.

Case A 40+3/7 weeks infant was admitted to the NICU with prenatal diagnosis of ambiguous genitalia in conjunction with multiple congenital anomalies. Genitalia appeared female however maternal serum fetal DNA test was significant for 46XY karyotype. Exam of infant was significant for micrognathia, low set ears, epicanthal folds, small chest with wide spaced nipples, large labia majora otherwise appears normal female, severe cervical kyphosis requiring intubation, talipes equinovarus, brachydactyly, sandal toe, and bowing of legs. The cervical spine had significant angulation approaching 80 degrees with resulting cord compression and canal stenosis seen on cervical MRI. Abdominal ultrasound displayed grossly normal appearance of ovaries and intact uterus. FISH and chromosomal analysis revealed 46XY genotype. Due to the associated skeletal anomalies SOX9 mutation was at the top of the differential diagnosis however SOX9 was without mutation.

Discussion Based on the clinical presentation and associated abnormalities the most likely causal genes and syndromes for this patient included SOX9, ATRX syndrome, Optiz syndrome, and SRY mutation. With normal 46XY chromosomal analysis, FISH testing, and no abnormalities with SOX9 testing; whole exome sequencing may be useful. Gonadal tissue testing would also be of benefit. If testicular tissue is present then surgical removal of dysgenetic gonads would be suggested to prevent risk of gonadoblastoma.

REFERENCES

1. Kwok C, et al. Mutations in SOX9, the gene responsible for campomelic dysplasia and autosomal sex reversal. *Am J Hum Genet* Nov 1995;57(5):1028–36.
2. Mohnach L, Fechner PY, Keegan CE. Nonsyndromic disorders of testicular development. 2008 May 21 [Updated 2016 Jun 2]. In Adam MP, Ardinger HH, Pagon RA, et al. (Eds.), *GeneReviews*® [Internet]. Seattle (WA): University of Washington, Seattle; 1993–2017.

394 USE OF GENETIC SEQUENCING IN PREMATURE INFANT WITH PERSISTENT RESPIRATORY FAILURE

ME Barbian*, A Piazza, T Gauthier, H Williams. *Emory University, Decatur, GA*

10.1136/jim-2017-000697.394

Background Heterozygous mutations and deletions in the NKX2-1 gene are associated with Brain-Lung-Thyroid Syndrome (BLTS). The NKX2-1 gene encodes thyroid-

transcription factor-1 (TTF1), a nuclear protein expressed in the lung, thyroid, ventral forebrain and pituitary gland during embryonic development. BLTS can cause primary hypothyroidism, respiratory distress and neurological disorders with variable phenotypic severity. NKX2-1 deletion may lead to lethal respiratory failure due to disruption of pulmonary surfactant homeostasis. We report the case of a pre-term infant with persistent respiratory failure, severe persistent pulmonary hypertension of the newborn (PPHN) as well as hypothyroidism who was found to have NKX2-1 gene deletion.

Case presentation Our patient is a female infant born at 30 weeks gestation to a 32 year old G5P0311 woman whose pregnancy was complicated by insulin dependent gestational diabetes and maternal congestive heart failure. She was delivered prematurely for maternal indications. Upon delivery, she was intubated for respiratory failure. She developed severe PPHN, requiring inhaled nitric oxide, inotropic medications and high frequency oscillator ventilation. She was subsequently diagnosed with hypothyroidism. The infant was transferred to our tertiary care facility for worsening PPHN. She was diagnosed with BLTS after a microarray revealed a 3.6 Mb deletion of chromosome 14q13.

Discussion Most documented 14q13 deletions are de novo mutations. The clinical features of 14q13 deletions vary from mild to severe symptoms with clinical features of developmental delay, hypothyroidism, choreoathetosis and respiratory problems. Our patient has required mechanical ventilation since birth, initially presumed to be prematurity related RDS and PPHN; however, throughout her hospitalization she has continued to require mechanical ventilation, pressors and sedation. The patient was too unstable to undergo a lung biopsy, thus she underwent genetic sequencing to determine the cause for her respiratory failure. For infants with hypothyroidism and severe RDS, BLTS should be considered. Additionally, for infants who are unable to undergo invasive diagnostic testing, genetic sequencing may provide valuable information to determine the diagnosis and navigate future care.

395 STREPTOCOCCUS BOVIS IN EARLY ONSET NEONATAL SEPSIS: A NEW PATHOGEN WITH FAMILIAR PHYSIOLOGY

¹A Bradley*, ²SM Marchegiani. ¹Naval Medical Center Portsmouth, Norfolk, VA; ²Naval Medical Center Portsmouth, Portsmouth, VA

10.1136/jim-2017-000697.395

Case report *Streptococcus bovis* is a rare cause of early-onset sepsis (EOS) in neonates. Typically, *S. bovis* manifests with gastrointestinal symptoms including diarrhea, feeding difficulties, and abdominal distention. For EOS, *S. bovis* presents without these features, mimicking the respiratory course observed in group B streptococcal (GBS) sepsis. This overlap includes respiratory presentation, radiographic findings, and evidence of persistent fetal circulation, making them clinically indistinguishable. The severity, course similarity, and impact on maternal health make awareness of this pathogen clinically relevant.

We present a term male infant delivered vaginally following non-reassuring fetal tracings with grunting, retractions, and hypoxia requiring rapid escalation of support with intubation and NICU admission. Chest radiographs demonstrated diffuse opacities and interstitial markings concerning for retained fetal

lung fluid and congenital pneumonia. A blood culture at admission grew *S. bovis* by twelve hours with speciation confirmed by polymerase chain reaction. Of note, the infant had no gastrointestinal symptoms, presenting only with respiratory distress and hypotension requiring pressor support. On day of life three, he developed worsening pulmonary hypertension.

In adults, *S. bovis* is a commensal gut bacterium associated with endocarditis and colorectal cancer (CRC), with gut wall translocation suspected as mode of infection. This etiology is plausible for only neonatal late onset sepsis, as commensal gut colonization is not expected at birth. As with GBS, *S. bovis* in EOS likely represents an ascending infection or intrapartum transmission, which is supported by rapid positive blood culture.

This case highlights the overlap between *S. bovis* and GBS in EOS, which includes clinical pathophysiology and mode of transmission. Further research is needed to understand implications of *S. bovis* in neonatal and maternal health. Research in genetic subtyping of *S. bovis* to predict outcomes and guide therapy will influence recommendations, as there is an association between biotype I *S. bovis* and CRC. Rates of maternal colonization with *S. bovis* are unknown, as are the implications for future pregnancies and CRC screening.

396 INCREASED MORTALITY AND INTRAVENTRICULAR HEMORRHAGE IN EXTREMELY LOW BIRTH WEIGHT OUTBORN NEONATES AT TEXAS CHILDREN'S HOSPITAL NEWBORN CENTER

MI Brasher*, M Gadhia. *Baylor College of Medicine, Houston, TX*

10.1136/jim-2017-000697.396

Purpose of study Healthcare regionalization improves mortality and morbidity of preterm infants born at level III or IV neonatal intensive care units (NICUs). However, in the last decade, Texas has become more de-regionalized due to hospital-based interests. Impacts of de-regionalized care in Texas on extremely low birth weight (ELBW) infants, birthweight (BW) less than 1000 g, are not known. This study determines if there is a significant difference in mortality and morbidities between inborn and outborn ELBW infants recently admitted to Texas Children's Hospital's (TCH) NICU.

Methods used This is a retrospective cross-sectional study. 302 ELBW neonates admitted in the first week of life to the TCH

NICU from January 2015 to December 2016 were categorized as inborn (born at TCH) and outborn (born outside of TCH). Two BW subsets were analyzed (≤ 750 g and 751–1000 g). Primary outcome was mortality at 28 days; secondary outcomes included bronchopulmonary dysplasia, respiratory distress syndrome, early onset sepsis, necrotizing enterocolitis, intraventricular hemorrhage (IVH), retinopathy of prematurity, surgical intervention, and length of hospitalization. De-identified data was obtained from the Vermont Oxford Network Database.

Summary of results 255 inborn and 77 outborn infants were studied. More inborn ELBW infants were born to mothers who received prenatal care (99.6% vs 93.4%, $p=0.004$), received antenatal steroids (95.1% vs 50.6%, $p\leq 0.001$), and were delivered via C-section (78.7% vs 63.6%, $p=0.014$). Mortality before 28 days of life was significantly higher in outborn infants 751–1000 g BW (12.8% vs 2.8%, $p=0.032$) and trended higher in outborn infants ≤ 750 g BW (44.1% vs 27.1%, $p=0.088$). Incidence of severe IVH (grade III/IV) was significantly higher in outborn ELBW infants (for BW ≤ 750 g, 50% vs 16.4%, $p\leq 0.001$; for BW 751–1000 g, 31% vs 12%, $p=0.009$). There were no significant differences between groups in the other secondary outcomes.

Conclusions Mortality in the first 28 days was significantly higher in outborn ELBW infants with BW of 751–1000 g. The incidence of IVH was also significantly higher in outborn compared to inborn ELBW infants. These findings occurred despite TCH being a quaternary referral center for high-risk pregnancies.

397 MISSISSIPPI'S GASTROSCHISIS BURDEN: NEC/ATRESIA IN INFANTS WITH GASTROSCHISIS

¹I Byrd*, ³E Turbeville, ²J Patel, ²M Famuyide. ¹University of Mississippi School of Medicine, Jackson, MS; ²University of Mississippi Medical Center, Jackson, MS; ³University of Mississippi School of Dentistry, Jackson, MS

10.1136/jim-2017-000697.397

Purpose of study Gastroschisis is a common birth defect with an increasing incidence worldwide. Risk factors such as young maternal age and exposure to external agents such as herbicides/pesticides have been associated with gastroschisis. Mississippi, a rural state, has a relatively high and increasing incidence and complexity of gastroschisis. We hypothesized

Abstract 397 Table 1 Shows characteristics of the cohort with gastroschisis with NEC/atresia

	Complex Gastroschisis/NEC/atresia (n=31) Mean(SD) or N (%)	Simple Gastroschisis (n=127) Mean(SD) or N (%)	P-Value
Sepsis	15 (48.39%)	21(16.54%)	0.0002
Non-intestinal abnormalities	8 (25.81%)	26 (20.47%)	0.517
Oxygen at 28 days	3 (9.68%)	4 (3.15%)	0.1391
Oxygen at 36 weeks	6 (19.35%)	18 (14.17%)	0.1765
Staged Closure	3 (9.68%)	5 (4%)	0.2019
Age of Closure	4.2 (2.76)	5.4 (3.12)	0.0537
Day of first feeds	27.79 (20.21)	16.8 (6.8)	0.0001
Times to full feeds	64.05 (68.33)	19.45 (15.4)	<0.0001

that the incidence of sepsis would be higher and time to full feeds will be longer for infants with gastroschisis associated with NEC/atresia.

Methods used A retrospective cohort study was conducted. Using data from our academic 102 bed, level IV NICU database (NeoData[®]) we identified patients with gastroschisis admitted to the NICU from January 1, 2000 to June 30, 2012. Patients with incomplete data and lethal congenital malformations were excluded in the analysis.

Summary of results All 158 infants born with gastroschisis admitted to UMMC's level IV NICU were included in the analysis. 31 of those had complex gastroschisis with NEC/atresia. The incidence of complex gastroschisis in this cohort is higher than previously reported in the literature (17% vs 20%). Table 1 shows characteristics of the cohort with gastroschisis with NEC/atresia. There was a significant difference in the incidence of sepsis between the complex gastroschisis/NEC/atresia cohort vs simple gastroschisis cohort (48.39% vs 16.54%, p -value=0.0002). The number of days to first feeds and the time to full feeds was significantly longer in the NEC/atresia cohort (p -values ≤ 0.0001).

Conclusions Our cohort is novel focusing on cases of NEC/Atresia. The high incidence in our resource limited, rural state, begets further epidemiological evaluation to determine the etiology/associated factors. The economic implications are also significant and will be further explored.

398 CAN WE PREDICT WHICH PREMATURE NICU INFANTS WILL NEED A FEEDING GASTROSTOMY TUBE?

A Chapman* K George, K Morella, A Leshner, A Selassie, RM Ryan. *Medical University of South Carolina, Charleston, SC*

10.1136/jim-2017-000697.398

Purpose of study Some premature infants are unable to take all of their feedings by mouth prior to discharge from the neonatal intensive care unit (NICU) and therefore need a feeding gastrostomy tube (G-tube). Both the process of working with an infant to reach full oral feeds and implementing a G-tube can delay discharge for several weeks. Our goal is to develop a model that can predict which infants will require a G-tube with the ultimate goal of earlier discharge. To do this, baseline data to determine the characteristics of infants requiring G-tubes at our institution were collected and are reported here.

Methods used Infants in the NICU at the Medical University of South Carolina (MUSC) who had G-tubes placed for feeding were identified using the local NICU data base comprised of prospectively collected data by research personnel. All Infants who were born in 2015 or 2016 and had a G-tube placed were identified. Ultimately, a retrospective detailed chart review was performed on 35 NICU patients who were born before 30 weeks (w) gestation and received a G-tube. Comparison data was collected on infants <30 w gestation who did not require a G-tube prior to discharge.

Summary of results After assessment of the medical indication for a G-tube for each infant, it was determined that infants born ≥ 30 w gestation required G-tubes secondary to congenital anomalies or chromosomal abnormalities. For those <30 w gestation at birth, the average weight at the time of G-tube was 4.6 kg, the average corrected gestational age (CGA) was

47.2 w and the average CGA at discharge was 52.0 w. In comparison, the infants who were ≥ 30 w at birth and received a G-tube were 43 w CGA at procedure and 47 w at discharge. Infants who were <30 w ($n=282$) and did not receive a G-tube were discharged much earlier at 35 w CGA and 2.4 kg.

Conclusions In our unit, the average weight at the time of G-tube placement was 4.6 kg, which is well above the minimum 2.8 kg necessary for the procedure. Therefore, a predictive model may be advantageous in identifying infants who will most likely need this procedure, allowing for earlier G-tube placement and possibly expedited discharge home.

399 NEONATAL ABSTINENCE DISCHARGE PLAN OF SAFE CARE: ACCESSING PEDIATRIC PROVIDER PERCEPTIONS

CS Crabtree* LA Devlin. *University of Louisville, Louisville, KY*

10.1136/jim-2017-000697.399

Purpose of study Neonatal abstinence syndrome (NAS) occurs when passive opiate transfer ends at birth. Recently, NAS has increased substantially across the US. Infants with NAS are at high risk for poor outcomes. To ensure the best transition to home, a comprehensive plan of safe care should be a routine part of discharge practices. To understand physicians' perspectives of current practice and to define steps that are needed to improve the process, a survey was developed and sent to primary care physicians (PCPs) in KY.

Methods used Ten-question surveys were distributed via Survey Monkey to pediatricians, family practice and medicine/pediatricians who see NAS patients in follow-up. The survey contained demographic data, assessed their satisfaction with NICU communication, and looked at barriers to effective transition and coordination of care.

Summary of results 53 surveys were returned; 90.5% of respondents were general pediatricians. Eighty-five percent were female. Over half of respondents were within the first 5 yrs of practice. Others were in practice 6–10 yrs (17%) and more than 15 yrs (17%). Practices were equally distributed between urban, suburban, and rural settings.

Responding PCPs preferred written communication (49%) or verbal and written communication (43%) at the time of discharge. They indicated that appointment dates/times were often/always shared. They were generally satisfied (72%) with written discharge summaries but dissatisfied with the quality and timeliness of verbal communication (55%). PCPs felt that maternal involvement with substance abuse treatment programs and CPS were not routinely communicated. PCPs reported that families often/always experience barriers in contacting them, finding/contacting specialty clinics and transportation to appointments. PCPs perceived that families often/always have knowledge deficits in the areas of infant feeding patterns, understanding behavioral cues, infant bonding and parental stress coping mechanisms. PCPs also responded that families were not aware of support services.

Conclusions A safe transition from hospital to home is essential to ensure medical and social support for infants and families affected by NAS. Input from primary care physicians has been utilized to develop a standardized discharge summary and warm hand-off process to provide a more seamless transition.

400

EFFECT OF PHENOBARBITAL ON CONJUGATED BILIRUBIN LEVELS IN INFANTS WITH PARENTERAL NUTRITION ASSOCIATED LIVER DISEASE

^{1,2}B Davenport*^{1,2}S Kona, ^{1,2}S Bai, ^{1,2}T Nienaber. ¹University of Arkansas for Medical Sciences, Little Rock, AR; ²Arkansas Children's Hospital, Little Rock, AR

10.1136/jim-2017-000697.400

Purpose of study Parenteral nutrition associated liver disease (PNALD) is seen in neonatal intensive care units. PNALD is defined as cholestasis occurring in the setting of PN if no other cause of cholestasis is identified. Cholestasis is defined as a serum conjugated bilirubin >2 mg/dL, and is typically seen after prolonged PN administration. Common practice is to use phenobarbital to treat cholestasis as a result of PNALD. In literature there are a few case reports showing improvement in conjugated bilirubin levels after treatment with phenobarbital, but there is limited evidence that supports this finding in other studies. In this study we aimed to assess the efficacy of phenobarbital treatment in PNALD. The primary objective is to compare the time to conjugated bilirubin level normalization, defined as levels <2 mg/dL, in patients treated with phenobarbital vs patients not treated with Phenobarbital.

Methods used This is a retrospective cohort study in which neonates born between 2010 to 2016, with a diagnosis of PNALD were identified using Children's Hospital Network Database along with electronic medical records. Exclusion criteria included a diagnosis of seizure disorder or receiving PN <10 days. A sample size of 114 in each group was required to achieve 80% power to detect the desired effect size with a two-sided test at a significance level of 0.05, and a correlation coefficient of 0.6 between time points.

Summary of results 350 neonates were identified to have PNALD. After exclusion criteria were applied 272 patients remained. 163 received phenobarbital and 109 did not. On preliminary univariate analysis, 56.4% of the phenobarbital group vs 46.5% in the no phenobarbital group achieved conjugated bilirubin level normalization, although this difference was not a statistically significant ($P=0.23$). Time to reach normalization was not significantly different between the two groups ($P=0.19$), with 42.86 ± 34.26 (mean \pm SD) days in the Phenobarbital group and 36.4 ± 27.91 (mean \pm SD) days in the No Phenobarbital group.

Conclusions Based on preliminary results, we speculate that the use of phenobarbital may not be effective for the treatment of cholestasis in PNALD.

401

HOLOPROSENCEPHALY IN A PATIENT WITH 18P DELETION SYNDROME

KA Degatur*. LSUHSC-Shreveport, Shreveport, LA

10.1136/jim-2017-000697.401

Case report The deletion of the 18p chromosome is a chromosomal anomaly first described by de Grouchy *et al*. The clinical features of those with this gene deletion syndrome include predominance in female gender, muscular hypotonia, holoprosencephaly, ptosis, hypertelorism, micrognathia, and pes planus. Seizures and endocrine abnormalities such as panhypopituitarism and growth deficiency have been reported. Little has been reported on 18p deletion syndrome with holoprosencephaly which seems to have the worst prognosis. In the present case, we report on the diagnosis of 18p deletion

in a neonate with holoprosencephaly complicated by diabetes insipidus and seizures. Our patient is a female born at 30 w 1 d to a 24 year old G1P0 mother via spontaneous vaginal delivery. Pregnancy was complicated by poor prenatal care and an ultrasound revealing holoprosencephaly. The mother declined amniocentesis. The delivery was complicated by PPROM and chorioamnionitis. APGARs at birth were 1, 1, and 3 at 1, 5, and 10 minutes respectively. She was bradycardic and was intubated and placed on mechanical ventilation in the NICU. On exam, she had a midline cleft lip extending to the nares, but no cleft palate. Eyes are symmetrical and unaffected. On day one of life, she exhibited seizure like activity and was started on phenobarbital and levetiracetam. An ultrasound of her head showed a large mono ventricle with fused thalami, partial development of a falx, and marked thinning or absence of the occipital cortex, left greater than right, which is consistent with semilobar holoprosencephaly. An EEG on day of life two showed seizure-like activity. Her serum sodium slowly began to rise, peaking at 165 mmol/L on day of life four despite minimal sodium intake. Patient was started on 0.1 mcg DDAVP. Due to increasing serum sodium levels and increased urine output, she was placed on 1 mg/kg hydrochlorothiazide and 10ug/kg/day synthroid due to low TSH and free T4. Serum cortisol was within normal limits. Subsequently, her serum sodium level decreased to 158 mmol/L and the urine volume normalized. Cytogenetic analysis of metaphase cells revealed a deletion of the short p arm of chromosome 18. Parents have been counseled on prognosis and are currently awaiting genetic counseling for subsequent pregnancies. Patient continues to receive treatment in the NICU and is currently 8 weeks old.

402

POSTNATAL GROWTH IN INFANTS WITH NEONATAL OPIATE WITHDRAWAL (NOW) SYNDROME BEFORE AND AFTER A CHANGE IN TREATMENT PROTOCOLS

¹L Devlin*, ²C Alexander, ¹P Radmacher. ¹University of Louisville, Louisville, KY; ²Baptist-East Memphis Neonatology Associates, Memphis, TN

10.1136/jim-2017-000697.402

Purpose of study To compare postnatal growth rates of infants with NOW syndrome before and after a change in treatment protocols.

Methods used Demographic, anthropometric and feeding data were collected for infants hospitalized for NOW between 2011–2015. Growth rates were calculated from return to birth weight to hospital discharge.

Summary of results Charts of 138 infants were reviewed. Infants small for gestational age (BW <10th percentile, n=35) and/or microcephalic (HC <10th percentile, n=32) were excluded from the growth analysis (final group n=89). Admission BW, GA and HC were not different between groups. Infants treated prior to the protocol change returned to BW sooner but had similar rates of growth. Length of treatment and length of stay were shorter in infants treated after the protocol change; weight and HC at discharge were significantly less. The proportion of infants fed hydrolyzed milk was significantly higher after the protocol change as was the proportion of infants receiving calorically enhanced milk products (table 1).

Conclusions This study suggests that coincidentally with a new NOW treatment protocol and a change in commercial milk

products infants demonstrated a slower return to birth weight and experienced more formula changes. Infants also required less pharmacologic therapy and had a shorter length of stay. Differences in weight and HC at discharge may be attributable to the shorter length of stay. The effect of a lower calorie term formula on subsequent growth is not clear but may have impacted outcomes. The developmental impact of early sub-optimal growth in NOW infants is unknown and warrants further study.

Abstract 402 Table 1 Results

	Old protocol N=60	New protocol N=29	P
RTBW (d)	10.2±3.8	14.9±3.9	<0.001
Weight gain (g/d)	38.7±9.5	36.9±15.6	0.098
HC gain (cm/wk)	0.6±0.2	0.5±0.3	0.153
Length of treatment (d)	35.8±14.5	26.7±10.9	0.001
Length of stay (d)	40.6±14.3	30.6±10.9	0.001
Weight @ discharge (g)	4269±613	3636±611	<0.001
HC @ discharge (cm)	37.1±1.1	36.0±1.8	0.004
Fed hydrolyzed milk products (%)	6.7%	37.9%	<0.001
Fed milk >20 kcal/oz	1.7%	13.8%	0.020

403 INCIDENCE OF HYPERINSULINISM IN A NICU POPULATION – A RETROSPECTIVE CHART REVIEW

^{1,2}D Dinu*, ³J Kaiser. ¹Baylor College of Medicine, Houston, TX; ²Texas Childrens Hospital, Houston, TX; ³Milton S. Hershey Medical Center, Hershey, PA

10.1136/jim-2017-000697.403

Purpose of study Hyperinsulinemic hypoglycemia, the most common cause of severe and persistent hypoglycemia in newborns is characterized by inappropriate secretion of insulin during hypoglycemic episodes. Hyperinsulinemia can be congenital or secondary to risk factors including being late preterm (34 0/7–36 6/7 weeks' gestation), an infant of diabetic mother (IDM), small (SGA) or large for gestational age (LGA), and/or perinatal asphyxia.

The goals of this study were to evaluate the incidence of hyperinsulinemic hypoglycemia in a term and late preterm newborn population admitted to Texas Children's Hospital, and to describe risk factors and co-morbidities associated with it.

Methods used Retrospective chart review of inborn and out-born newborns discharged with the diagnosis of hyperinsulinism between January 2011 and December 2016.

Summary of results From 2,737 newborns discharged with a diagnosis of hypoglycemia, 35 (1.3%) were diagnosed with hyperinsulinism. Preliminary analysis of 20 of the 35 cases showed that 81% had a risk factor, with SGA the most common (50%), followed by late preterm (25%), IDM (12.5%), LGA (6.3%), and birth asphyxia (6.3%). Mean gestational age was 36.9±3.2 weeks and most cases were male (75%). There were two cases of congenital hyperinsulinism (10%), which were referred to another hospital and underwent pancreatectomy. Three patients (15%) presented with seizures. Highest glucose infusion rate needed to achieve glucose >60 mg/dL was 15.5±4.9 mg/kg/min and 60% of the babies required a

central venous catheter for 15±9.6 days. 55% of patients had targeted congenital hyperinsulinemia genetic testing. Most were begun on medication (90%); mostly Diazoxide (85%) at 14.2±10.8 days of life. One patient had Diazoxide discontinued for lack of response and was changed to Octreotide. No case had medication discontinued due to adverse reactions. 65% of patients were discharged home on medication, half underwent a glucagon challenge test before discharge, and only 25% had a safety fasting test done.

Conclusions Persistent hypoglycemia beyond 48–72 h of life may suggest an underlying genetic or metabolic cause and requires a comprehensive work-up. Increased awareness among neonatologists of this condition is necessary to expedite the diagnosis and prevent injury.

404 USE OF DIAZOXIDE FOR HYPERINSULINEMIA IN A NICU POPULATION

¹D Dinu*, ²J Placecncis, ³J Kaiser. ¹Baylor College of Medicine, Houston, TX; ²Texas Children's Hospital, Houston, TX; ³Milton S. Hershey Medical Center, Hershey, PA

10.1136/jim-2017-000697.404

Purpose of study Diazoxide, an agonist of the pancreatic beta-cell K_{ATP} channel that inhibits insulin secretion is the only FDA-approved drug for the treatment of hyperinsulinemic hypoglycemia. The most common adverse reactions are hypertrichosis, sodium and water retention, but there have been increasing and concerning reports of infants developing severe pulmonary hypertension.

The goal of the study was to evaluate the use of Diazoxide in a specific newborn population with hyperinsulinemic hypoglycemia and evaluate the incidence of pulmonary hypertension associated with its use.

Methods used Retrospective chart review of newborns discharged from Texas Children's Hospital with a diagnosis of hyperinsulinemic hypoglycemia between January 2011 and December 2016.

Summary of results 35 newborns were diagnosed with hyperinsulinemia. Preliminary analysis of 20 cases showed that 90% of the patients were started on a medication, with 85% of them receiving Diazoxide. The highest dose of Diazoxide was on average 10.7±3.4 mg/kg/day and was started on day of life 14.2±10.8. 60% of babies required central venous access for dextrose infusion with a duration of 15±9.6 days. Glucoses >60 mg/dL were achieved on day of life 18.8±10.9. 89.5% of the patients had an echocardiogram performed during hospital stay, and only two babies had evidence of mild pulmonary hypertension. Only one patient had Diazoxide discontinued, due to lack of response. Length of therapy ranged from 14 to 804 days (mean 174±211). The dose was not adjusted during follow-up appointments, allowing a self-weaning of the drug. There were no documented cases of therapy being discontinued due to adverse reactions, especially pulmonary hypertension.

Conclusions Diazoxide is still the most commonly used drug in hyperinsulinemic hypoglycemia in our NICU. Our patients did not develop pulmonary hypertension, but in almost 30% of cases a smaller dose (<10 mg/kg/day) than the one generally recommended was used, making the interpretation of data difficult. True incidence of pulmonary hypertension in this group of patients is not known and close monitoring of patients is needed. Prolonging central venous access in order

to deliver high-concentration dextrose has its own associated risks of infection and/or thrombosis.

405 CONGENITAL BILATERAL EYELID EVERSION AND CHEMOSIS: A CASE STUDY

EE Dixon*, AL Kirkpatrick, D Ledlow, J Phillips. *University of Alabama, Birmingham, AL*

10.1136/jim-2017-000697.405

Purpose of study Congenital eyelid eversion is a rare condition with approximately 50 cases documented in the medical literature. Here we describe the presentation and medical management of an infant with congenital eyelid eversion to augment knowledge of the condition.

Methods used We conducted a literature review of the incidence of congenital eyelid eversion and the current methods of medical versus surgical management.

Summary of results Conservative medical management described in the literature included antibiotic ointment, lubricating ointment, and patching/padding with or without 5% hypertonic saline gauze. Other interventions reported were combination antibiotic/steroid ointment and eyelid massage. Infants in only two of the reviewed articles required invasive surgical management.

Resolution of eyelid eversion occurred in the left eye of our patient following management with combination antibiotic/steroid ointment and application of regular ocular lubricant, however the right eye failed to respond to the same therapy. We intensified management of the right eye by applying 5% hypertonic saline ointment and administering systemic steroids. We saw marked improvement with these changes and were able to avoid surgical intervention. Photos will be displayed.

Conclusions The prevalence of eyelid eversion is increased in males and black newborns and is almost always bilateral though unilateral cases have been reported. Congenital eyelid eversion may be seen in infants with Down syndrome, or lamellar ichthyosis. It has also been hypothesized that congenital eyelid eversion occurs in multiparous mothers following prolonged labor and/or traumatic delivery. Our specific case refuted this hypothesis as our patient was born to a primiparous mother without any birth trauma noted.

Conservative medical management is the standard of care for congenital eyelid eversion. Our case showed good response to medical management with combination antibiotic/steroid ointment and ocular lubricant with the addition of systemic steroid therapy and 5% hypertonic saline gauze applied to the everted eyelid initially intractable to the aforementioned therapy.

406 EARLY ONSET NEONATAL SEPSIS WITH EXTENDED SPECTRUM BETA-LACTAMASE PRODUCING ESCHERICHIA COLI IN INFANTS BORN TO SOUTH AND SOUTH EAST ASIAN IMMIGRANTS: A CASE SERIES

K Dolma*TL Summerlin, H Wongprasert, J Phillips, L Winter. *University of Alabama, Birmingham, AL*

10.1136/jim-2017-000697.406

Introduction ESBL producing *Enterobacteriaceae* represent a major worldwide threat among drug-resistant bacteria. We present 3 cases of early-onset ESBL *E. coli* sepsis in infants

born to families from South and Southeast Asia to inform the neonatology community about this emerging threat.

Case presentation Patient 1 was born at 34 wks to a 32 y/o Pakistani mother with gestational diabetes. Apgar scores were 6 and 8 and the infant was transferred to a step-down unit. On day 3 the baby developed abdominal distention and was evaluated for sepsis and placed on ampicillin, cefepime and acyclovir. The baby rapidly deteriorated and died despite vigorous resuscitative efforts. Blood and CSF cultures grew ESBL *E. coli*.

Patient 2 was born at 35 wks to a 26 y/o Vietnamese mother after an uncomplicated pregnancy. The infant was stable in a step-down unit for two days, then developed hypothermia and new onset apnea. The baby was evaluated for sepsis and placed on ampicillin and gentamicin but deteriorated rapidly and died 4 hours after onset of symptoms. Blood culture grew ESBL *E. coli*.

Patient 3 was born at 30 wks to a 36 y/o Indian mother with gestational diabetes. The infant had progressive respiratory distress and was intubated and placed on a conventional ventilator and was later placed on a jet ventilator. A sepsis evaluation was performed and ampicillin gentamicin and ceftazidime were started. The baby continued to deteriorate and meropenem was added with a suspicion of ESBL infection. Blood culture grew ESBL *E. coli*. The infant has gradually improved as of this submission on a 21 days course of meropenem with pending LP.

Discussion These 3 cases occurred in a 6 months period in 2017. Infants with suspected sepsis whose mother is from Asia should be suspected of having an infection with an ESBL organism and practitioners should strongly consider adding meropenem to the usual initial antibiotic regimen.

Conclusion Although EOS with ESBL organisms is rare in the United States, it can account for a substantial problem in neonates born to South or South East Asian immigrant mothers. Clinical suspicion with judicious use of antibiotics is required.

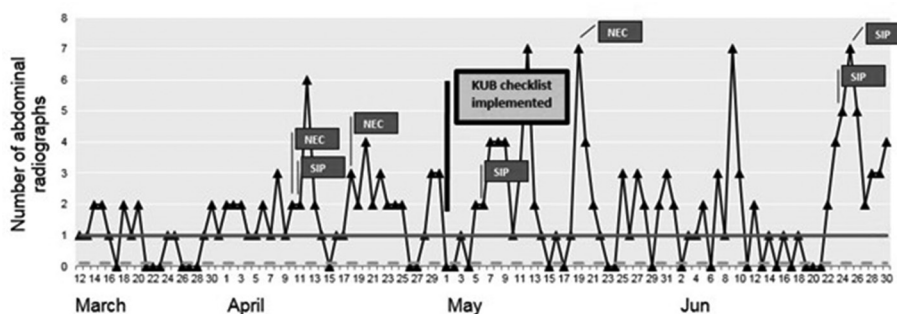
407 QI PROJECT: A CHECKLIST TO ASSESS FEEDING INTOLERANCE AND REDUCE THE NEED FOR ABDOMINAL RADIOGRAPHS IN EXTREMELY PRETERM INFANTS AT RISK FOR NECROTIZING ENTEROCOLITIS

A Freeman*, AA Salas. *University of Alabama, Birmingham, AL*

10.1136/jim-2017-000697.407

Purpose of study The fear of necrotizing enterocolitis (NEC) and its association with feeding intolerance often result in feeding interruptions. Improving consistency in documentation of feeding intolerance could reduce the need for abdominal radiographs in extremely preterm infants at risk for NEC. Within 60 days with 80% compliance, this study aimed to decrease by 50% the amount of abdominal radiographs ordered to rule out NEC in extremely preterm infants with gestational age ≤ 28 weeks.

Methods used Over a period of 8 weeks, we conducted PDSA cycles to improve the process of assessment of feeding intolerance. A paper checklist that included fifteen signs and symptoms considered to be indicative of NEC was implemented in our neonatal unit. The outcome measure was the number of abdominal radiographs performed after implementation of the checklist for risk assessment of NEC. The process measure was compliance measured by comparing the number of



Abstract 407 Figure 1

completed paper checklists with the number of abdominal radiographs ordered during the study period. The balancing measure was the incidence of NEC or spontaneous intestinal perforation (SIP) within the first month after birth.

Summary of results Data on 66 extremely preterm infants were analyzed. GA ranged from 22 to 28 weeks gestation (median: 26 weeks). Median BW was 818 g. We documented low compliance with the intervention (30%), but the number of days without orders of abdominal radiographs for suspected NEC increased from 17% (10 of 60 days) to 28% (17 of 60 days) after implementing a paper checklist (figure 1).

Conclusions Despite reduced compliance, the practice of using a standardized checklist to assess feeding intolerance in extremely preterm infants reduced the number of abdominal radiographs ordered without increasing the incidence of NEC or SIP. Compliance rates could increase if the checklist is incorporated into the electronic medical record system.

408

PERSISTENT RESPIRATORY FAILURE IN THE TERM NEWBORN: A CASE FOR EARLY WHOLE GENOME SEQUENCING

SR Glenn*W Marvin, HJ Murphy, K Vincent, RM Ryan. *Medical University of South Carolina, Charleston, SC*

10.1136/jim-2017-000697.408

Case report A term, male newborn delivered via repeat C-section developed respiratory failure requiring intubation at birth. During subsequent hypothermia treatment for HIE, the patient was extubated but quickly developed respiratory distress characterized by significant retractions, severe bradycardia, and oxygen desaturations. Minimal breath sounds were appreciated despite symmetric chest wall movement, necessitating reintubation. With every subsequent extubation trial similar episodes occurred, often preceded by patient irritability; time to reintubation varied from minutes to weeks. Between events and following re-intubations the patient had no signs of respiratory insufficiency or other abnormalities. The patient needed eight intubations over the course of two months, ultimately requiring tracheostomy. Multiple consultation services were involved. An extensive workup including bronchoscopies, upper GI study, chest CT angiogram, brain MRI/MRA, dynamic airway imaging, VEEG, and impedance probe study, was unable to identify an etiology. Testing for Congenital Central Hypoventilation Syndrome and various metabolic syndromes was negative. The patient was transferred from the NICU to the PICU at four months of age for continued care. A geneticist specializing in brain injury from metabolic disorders was consulted

409

EFFECT OF CHONDROITIN SULFATE ON INTESTINAL BACTERIAL INVASION

L Hannah*K Burge, J Eckert, H Chaaban. *OUHSC, Oklahoma City, OK*

10.1136/jim-2017-000697.409

Purpose of study Necrotizing enterocolitis (NEC) is characterized by intestinal inflammation and necrosis that can lead to perforation, sepsis, and potentially death among premature infants. Intestinal integrity dysfunction and bacterial translocation have been suggested to play important roles in the pathogenesis of NEC. Studies show that breast milk (BM) reduces the incidence of NEC, but the factor(s) responsible for the protective effect are not fully identified. Recent literature highlights the presence of glycosaminoglycans (GAGs) in BM. Levels of GAGs in BM are 7 times higher than in formula, with chondroitin sulfate (CS) having the highest concentration. This study seeks to determine the effects of CS on bacterial invasion, translocation, and proinflammatory cytokine release in intestinal epithelium in vitro.

Methods used T84 cells were treated with antibiotic-free media containing increasing concentrations of CS. After incubation, cells were challenged with 5×10^8 CFU/ml *E coli*. Each set of triplicate wells were harvested; collected cells were diluted serially and plated on LB agar plates. % bacterial invasion was calculated based on cell density, inoculum size, and bacterial plate count. Permeability was assessed through in vitro FITC-dextran flux. IL-8 levels were measured in supernatant by ELISA. % cell viability was determined and compared between groups.

Summary of results CS (750 μ g/ml) was associated with 4 fold decrease in bacterial invasion compared to control

($p=0.0014$). CS treated T84 cells had lower levels of IL-8 compared to control. There was no difference in cell viability between groups. In vitro FITC-dextran flux, together with TER measurements, indicates improved maintenance of epithelial integrity during bacterial translocation experiments by CS compared to control.

Conclusions Our results show that CS was associated with lower bacterial invasion, translocation, and IL-8 levels, without affecting cell viability. These results suggest that CS could be one of the protective factors in BM. Further studies are needed to determine its effects in vivo in NEC models.

410 MULTI-MORBIDITY: MADD AND PYLORIC STENOSIS IN A NEONATE

M Heath*E Smith, D Rivera, S Ollister. *LSU Health Science Center, New Orleans, LA*

10.1136/jim-2017-000697.410

Case report Multi-morbidity is the presence of a number of disorders in a patient not having any connection to each other through any known pathogenetic mechanisms. We present a neonate diagnosed with multiple acyl-CoA dehydrogenase deficiency (MADD) and pyloric stenosis.

A nondysmorphic female delivered at 36 weeks gestation had an abnormal newborn screen reported on day of life 5 concerning for a fatty acid oxidation defect. Follow-up studies, including urine organic acids and plasma acylcarnitine levels, obtained after initial screening were consistent with suspected MADD.

MADD, also known as glutaric aciduria Type 2, is an autosomal recessive metabolic disorder of fatty acid, amino acid, and choline metabolism. The clinical presentation is variable based on age of presentation and concurrent congenital anomalies; features may include nonketotic hypoglycemia, metabolic acidosis, recurrent vomiting, cardiomyopathy, renal and liver anomalies, and early death in the most severe form.

The patient was transitioned to a low fat, low protein, high carbohydrate formula with oral riboflavin and carnitine supplementation. Serial echocardiograms were notable for mild hypertrophic cardiomyopathy. Initial genetic testing was negative for the mutations most often implicated in MADD; an expanded gene panel, including those associated with defects of riboflavin transport, is pending. Progressively worsening nonbilious emesis at one month of age was initially thought to be secondary to the metabolic disorder and/or dietary changes. Subsequent upper gastrointestinal study and abdominal ultrasound showed hypertrophic pyloric stenosis, which was surgically repaired. There are no known reports of an association between MADD and pyloric stenosis. The patient was successfully discharged home on day of life 41 tolerating full feeds with resolution of recurrent emesis.

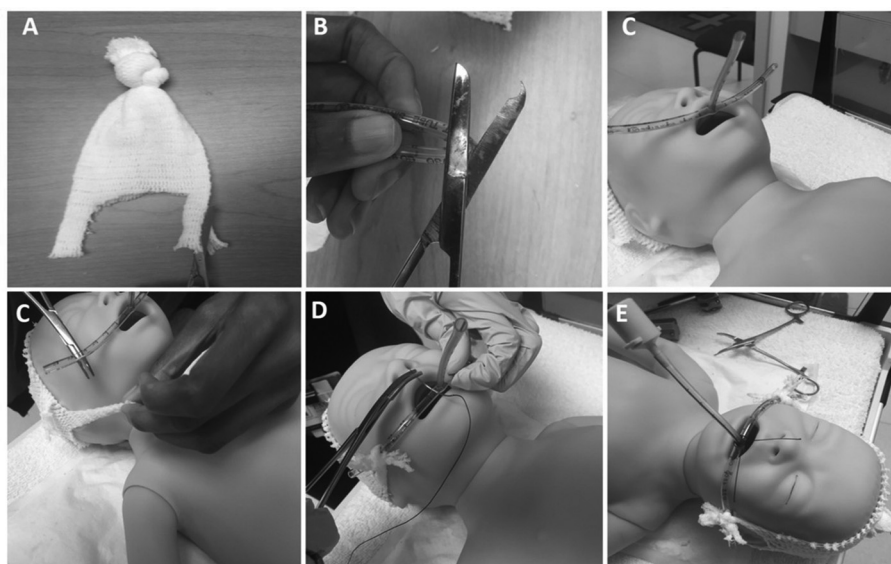
This case highlights the importance of the newborn screening system as a vital tool to identify rare disorders, such as multiple acyl-CoA dehydrogenase deficiency. It is also important to consider multi-morbidity when presented with symptoms in a patient with a known diagnosis.

411 NOVEL APPROACH TO ADHESIVE-FREE ENDOTRACHEAL TUBE SECUREMENT IN A NEONATE WITH EPIDERMOLYSIS BULLOSA

^{1,2}J Hendricks*^{1,2}E Sewell. ¹Emory University, Atlanta, GA; ²Children's Healthcare of Atlanta, Atlanta, GA

10.1136/jim-2017-000697.411

Introduction Epidermolysis Bullosa (EB) is a skin disorder with variable morbidity and mortality but is often lethal in severe forms. Blisters in the oropharynx may cause upper airway obstruction and respiratory failure. Confirmatory tests may take weeks to result, and endotracheal tube (ETT) securement can prove difficult due to skin desquamation. In this case, we present a patient who required intubation for which we



Abstract 411 Figure 1 (A) a stockinet cap with two 1 cm flaps cut on each side cap is placed on the baby who is then intubated. (B) the second ETT is cut to from a which fits from ear to ear across the baby's lips. Slits are placed on opposite each other at the center and 1 cm from each and of the cross bar. (C) the ETT is pulled through the center holes of the cross bar. (D) the Posterior flap of the cap is pulled through the side holes of the cross bar with forceps, then tied in place to the anterior flap on each side. (E) the ETT is pulled through the center holes of the cross bar and sutured on either side with 4.0 silk. (F) the patient is then replaced on the ventilator

developed a method of securing the ETT without traditional adhesives.

Case presentation A term infant born with cutis aplasia and blistering on the fingers was transferred to our quaternary NICU where testing confirmed Herlitz type Junctional EB. He required endotracheal intubation secondary to upper airway obstruction from oropharyngeal blistering. He subsequently developed facial desquamation from conventional ETT adhesives leading to several unintended extubations. Maintaining a secure airway was critical due to the high risk of significant bleeding. Therefore, a novel method of ETT securement without adhesives was utilized by suturing the patient's ETT to a crossbar secured to the patient's cap (figure 1). Suctioning and ventilation remained effective despite ETT suturing, and no further unintended extubation occurred. Furthermore, there was improvement in the epithelization of the cheeks.

Conclusion While several non-adhesive ETT securement devices exist for adults, none are available for neonates. In cases where skin adhesives are unavailable, undesirable, or ineffective, our method of ETT securement may prove beneficial in decreasing unintended extubations.

412 DOES GLUCOSE GEL REDUCE NICU ADMISSIONS FOR NEONATAL HYPOGLYCEMIA?

T Huy*, A Miceli, D Halloran. *Saint Louis University School of Medicine, St. Louis, MO*

10.1136/jim-2017-000697.412

Purpose of study Recent studies suggest that glucose gel is effective for treating neonatal hypoglycemia thus may reduce neonatal intensive care unit (NICU) admissions. The purpose of this study is to compare NICU admissions for hypoglycemia pre- and post-implementation of a glucose gel protocol for the management of neonatal hypoglycemia.

Methods used Subjects include neonates who were at risk for hypoglycemia born between January 2017 and August 2017 at a Midwest, high-risk delivery center and admitted to the newborn nursery. Pre-implementation hypoglycemic neonates (blood glucose ≤ 40 mg/dL at < 4 hours of life and ≤ 45 mg/dL at 4–24 hours of life) were breast and/or bottle fed. Post-implementation hypoglycemic neonates were treated with a glucose gel dose proportional to their birth weight and breast and/or bottle fed. Transfers were indicated for persistent hypoglycemia. The primary outcome was percent of NICU admissions for neonatal hypoglycemia management pre- and post-implementation. Predictors included risk factors for hypoglycemia including late preterm, infant of diabetic mother, and small- or large-for-gestational-age.

Summary of results A total of 132 infants were screened for hypoglycemia (78 pre- and 54 post-intervention). The study sample demographics were 3% Hispanic, 50% Black, and 23% White with 26% unknown. Half of infants were female. The mean birthweight was 2912 grams (± 620) and the mean gestational age was 38 weeks (± 1.6). 21% of subjects' mothers planned to bottle feed, 69% planned to breastfeed, and the remaining 10% planned to do both. There was no statistically significant difference in these characteristics in the pre- versus post-intervention period.

The percent of NICU admissions dropped from 20.5% to 18.5% in the post-intervention period (p-value NS). After adjusting for risk factors, intervention status remained non-significant as a predictor of NICU admissions. However, infant

of diabetic mothers were 1.4 (95% CI: 1.2 to 13.8; $p=0.02$) times more likely and late preterm infants were 1.7 (95% CI: 1.7 to 17.1; $p=0.005$) times more likely to be admitted to the NICU.

Conclusions Glucose gel did not reduce the percent of NICU admissions. Additional outcomes including changes in rates of exclusive breastfeeding will be explored.

413 NEONATAL OUTCOME OF VERY LOW BIRTH WEIGHT INFANTS WITH INTRAUTERINE GROWTH RESTRICTION

¹C Johnson*, ²S Arya, ¹S Joshi, ¹D Burkholder, ¹A Uzoma-Uzo, ¹B Niebuhr, ¹S Jain. ¹University of Texas Medical Branch, Galveston, TX; ²Cincinnati Children's Hospital Medical Center, Cincinnati, OH

10.1136/jim-2017-000697.413

Purpose of study Intrauterine growth restriction (IUGR) is defined as estimated fetal weight < 10 th percentile for gestation and failure to reach the growth potential on serial antenatal ultrasounds with or without abnormal Doppler indexes in the umbilical artery (fetal placental insufficiency – FPI). Very low birth weight (VLBW) infants with IUGR are at the highest risk for poor growth, morbidity, and mortality.

We aim to assess if IUGR with or without FPI, in a high-risk setting of VLBW infants had any effect on feeding outcomes, growth, major neonatal morbidities, and mortality.

Methods used Retrospective case-control study evaluating IUGR VLBW infants born from January 2010 to January 2015 (5 years) in a level IV NICU at UTMB, Galveston. IUGR infants were matched to control infants (1:1) by gestational age, sex and, date of birth (within 6 months). Outcome measures included growth, TPN days, enteral calories, and short and long-term neonatal morbidities. Data analyzed using SPSS v24. IUGR vs control compared using independent sample t-test, stratified groups compared using one-way ANOVA, and Chi square used for categorical variables.

Summary of results Sixty-four infants (32 IUGR and 32 controls) were included in the study. IUGR infants were more likely to be born to mothers with pregnancy induced hypertension or pre-eclampsia (78% versus 50%, $p<0.02$) and had increased incidence of FPI (28% versus 9%, $p<0.05$). IUGR infants reached full feeds (120 kcal/kg/day) later (33 ± 3 versus 31 ± 3 weeks, $p<0.05$). Among all infants with IUGR, infants with FPI compared to infants without FPI had increased mortality (33% compared to 4%, $p<0.03$). There was no significant difference in the incidence of IVH, NEC, ROP, and sepsis between the groups.

Conclusions VLBW IUGR infants versus AGA infants are more frequently born to mothers with PIH/PE and develop FPI. IUGR infants take longer to achieve full feeds. VLBW IUGR infants are not at significantly higher risk for major neonatal morbidities.

414 AN INFANT WITH A 'GREEK WARRIOR HELMET' APPEARANCE

N Kabani*, J Phillips. *University of Alabama, Birmingham, AL*

10.1136/jim-2017-000697.414

Case report 9 d/o ex 33.4 wk male was transferred for evaluation of congenital glaucoma. Baby had known IUGR and

twinning. APGARs were 7 and 9. At OSH, infant received nasal CPAP and transitioned to HFNC. Electrolytes and CBC were normal. Baby was found to have hypospadias, hypertelorism, tags anterior to ears, and down-slanting palpebral fissures. Ocular exam showed enlarged cup to disk ratio, increased IOP, and tearing consistent with glaucoma. Baby was started on 5% NaCl eyedrops and transferred. Due to multiple congenital anomalies, chromosomes and microarray were sent. Due to symmetric SGA, CMV, Toxo, HSV, and CMV were sent which were all negative. Head US, renal US and echo were all normal. Genetics results showed terminal 4p deletion, consistent with Wolf-Hirschhorn syndrome. Ophthalmology and genetics were both consulted. He also was found to have congenital anal strictures on contrast enema and underwent rectal dilations.

Wolf-Hirschhorn syndrome is caused by deletion in the short arm of chromosome 4. Frequency is estimated to be about 1 in 50,000, and it is more prevalent in females than males. The signs and symptoms of Wolf-Hirschhorn are related to the loss of multiple genes on the short arm of chromosome 4: NSD2, LETM1, and MSX1. Most cases result from a random deletion and are not inherited. It is characterized by typical craniofacial features (Greek warrior helmet) such as wide nasal bridge, microcephaly, high anterior hairline with prominent glabella, widely spaced eyes, epicanthus, short filtrum, micrognathia, downturned corners of the mouth, and poorly formed ears with pits and tags. Affected infants have prenatal onset growth deficiency and poor growth after birth. Most have some degree of developmental delay and intellectual disability. Seizures are present in 90–100% of individuals, and many have other congenital anomalies including eye or optic nerve anomalies, skeletal anomalies, hearing loss, congenital heart defects, and structural brain abnormalities. Diagnosis is made based on clinical suspicion and confirmed by genomic tests such as microarray or FISH. Management involves thorough work up of all systems including multiple biochemical studies, head imaging, EEG, echo and renal US. Patients require multi-disciplinary management for their various symptoms. Prognosis depends on the variety of anomalies and their management.

415 A UNIQUE PRESENTATION OF ACROCALLOSAL SYNDROME

MF Khan*, A Pramanik. Louisiana State University Health Sciences Center, Shreveport, LA

10.1136/jim-2017-000697.415

Case report We report the first association of an FGF8 mutation in a patient with clinical features of Acrocallosal syndrome (ACS). Since first described by Schinzel in 1979, approximately 26 cases of ACS have been reported. The features comprise hallux duplications, craniofacial anomalies, macrocephaly, enlarged fontanelle, and mainly hypoplasia or agenesis of the corpus callosum. The majority of ACS patients also have intellectual and psychomotor retardation. Per the Orphanet Journal of Rare Diseases, the diagnosis of ACS is based on the presence of at least three of four physical examination criteria which include: total or partial absence of the corpus callosum, craniofacial anomalies, moderate to severe psychomotor retardation with hypotonia and polydactyly/syndactyly. A term male infant was admitted to the NICU due to respiratory distress and prenatal diagnosis of agenesis of corpus callosum. Family history was significant only for a first trimester spontaneous abortion. On initial evaluation the

patient did not look obviously dysmorphic. However, on closer examination, distinct features of ACS were noted. These included *macrocephaly, large anterior fontanelle, hypertelorism, bilateral down slanting palpebral fissures, micropenis, left cryptorchidism, syndactyly of second and third toes bilaterally, wide space between fourth and fifth toes and hypotonia*. MRI of the brain confirmed agenesis of corpus callosum and also showed absent olfactory bulbs and tracts. Karyotyping showed a normal male genomic profile. However, further microarray genetic testing showed a heterozygous FGF8 mutation. Although individuals with ACS have a variable range and severity of associated findings, our patient met all of the clinical diagnostic criteria for ACS. In addition, our patient has unique features of hypogonadotropic hypogonadism, absent olfactory tracts/bulbs and FGF8 mutation which have not been previously described. The diagnosis of ACS could have been easily missed. In this case, subtle clues to the diagnosis, including syndactyly, craniofacial features, and hypotonia, prompted further genetic workup. Management of ACS includes genetic counseling and supportive treatment by a multidisciplinary team of medical professionals.

416 SURFACTANT PROTEIN A IN RETINAL VASCULARIZATION IN SYSTEMIC INFLAMMATION

^{1,2}J Kung*¹NG Kassa, ^{1,2}F Bhatti. ¹University of Oklahoma – Children's Hospital, Oklahoma City, OK; ²Dean McGee Eye Institute, Oklahoma City, OK

10.1136/jim-2017-000697.416

Purpose of study Retinopathy of prematurity (ROP) is the leading cause of acquired visual impairment in children. Vascular regression is followed by neovascularization (NV) and both stages may be impacted by inflammation. Lipopolysaccharide (LPS) induced systemic inflammation (SI) in mouse pups reduces retinal vascular density but has no impact on overall vascularization. Published data from our lab shows that NV is decreased in Surfactant protein A (SP-A) deficient mice in a ROP model. We hypothesize that SP-A decreases Vascular Area (VA) in a neonatal mouse SI model as well.

Methods used We induced SI in wild type (C57BL6/J, WT) and SPA^{-/-} mice at P4, by intraperitoneal injection of LPS (1 mg/kg) and compared to mice injected with saline solution (NS). Retinas were dissected for flat mounting (FM) at P6, P8 and P10. Retinal blood vessels were visualized via immunohistochemistry (IHC) on FM's with fluorescent antibodies against endothelial CD31. VA was quantified using Adobe Photoshop Software. VEGF mRNA levels from SI mice were compared by RT-PCR.

Summary of results At P6, there was a significant decrease in VA in SPA^{-/-}LPS mice vs WT-NS (58 % vs 74 %, p<0.001). There was a decrease in SPA^{-/-}LPS compared to SPA^{-/-}NS (58 % vs 65 %) and a decrease in VA in SPA^{-/-}NS vs WT-NS (65 % vs 74 %), but both were not statistically significant. At P8, this pattern continued with a significant decrease in VA in SPA^{-/-}LPS vs WT-NS (82 % vs 89 %, p<0.001) as well as in SPA^{-/-}LPS vs SPA^{-/-}NS (82 % vs 92 %, p<0.001). No differences were seen at P10. In the retinas from SPA^{-/-}LPS mice, VEGF levels were decreased to 30 % of WT levels at P6 and 50 % at P10.

Conclusions Both, SI and the absence of SP-A are necessary to decrease VA at P6 and P8. Furthermore, VEGF expression is decreased in LPS injected SPA^{-/-} mice. We conclude that the

negative effect of SI on vessel growth is counteracted by the presence of SP-A. SP-A is also associated with greater expression of VEGF in the retina. This counter measure may not be adequate in preterm infants because of low levels of SP-A, thereby, allowing inflammation to progress. Studying the role of SP-A in the regulation of VEGF or other angiogenic factors is crucial in identifying pathways to target to fight ROP in the future.

417 EVALUATION OF NEONATAL SERVICES PROVIDED IN A LEVEL II NICU UTILIZING HYBRID TELEMEDICINE

A Makkar*, A Foulks, M McCoy, G Hallford, E Szyld. *OUHSC, Lawton, OK*

10.1136/jim-2017-000697.417

Purpose of study Telemedicine use as a primary means of patient contact and management is understudied among neonates. Our recent study showed infants cared for through hybrid telemedicine at Comanche County Memorial Hospital (CCMH) Level II NICU is not inferior to conventional care of similar infants at our Level IV NICU at OU Medical Center (OUMC). Our previous study was retrospective and didn't assess care satisfaction.

Objectives

- Evaluate safety and efficacy of treatment of premature infants managed by hybrid telemedicine vs conventional care.
- Compare the parental satisfaction of infants treated with hybrid telemedicine vs infants treated with conventional care.

Methods used Prospective non-inferiority study compared outcomes of premature infants admitted either to the CCMH or OUMC. All 32–35 weeks GA infants admitted between May 2015 and Sept, 2017 were included. OUMC infants were all transported from areas geographically comparable to CCMH. Infants requiring mechanical ventilation >24 hours or advanced subspecialty care were excluded. Outcome variables: length of stay (LOS), respiratory support and time to full enteral feed. Parents at both centers were surveyed about their satisfaction with the care provided. Between-group comparisons appropriate for the type of data analyzed were done with SAS Software (V9.3).

Summary of results Seventy four neonates at CCMH and 69 at OUMC were analyzed. Compared to OUMC, CCMH neonates had significantly shorter LOS, reached full enteral feeds sooner, had fewer supplemental oxygen days and fewer noninvasive ventilation support days. LOS was not normally distributed so a multivariable regression model, using robust regression was done. Location had a significant independent effect ($p=0.003$) on LOS while controlling for GA, gender, RDS and APGAR. CCMH patients had reduced LOS of 2.8 days (95% CI: 0.91 to 3.6) than OUMC patients. 49 surveys at CCMH and 28 at OUMC were analyzed. Compared to CCMH, OUMC parents reported travel distance difficulties. 90 % respondents rated telemedicine image quality, and 83% rated sound quality as good. 92% reported telemedicine experience as good or excellent, while 3% reported it as poor.

Conclusions Hybrid Telemedicine is an effective way to extend intensive care to neonates in medically underserved areas. Parents at CCMH reported high satisfaction with telemedicine use.

418 USE OF EARLY ONSET SEPSIS CALCULATOR AND INTERVENTION BUNDLE TO REDUCE ANTIBIOTIC USE IN EARLY ONSET SEPSIS

A Makkar*, H Chaaban, E Szyld, J Milam, K Sekar. *OUHSC, Lawton, OK*

10.1136/jim-2017-000697.418

Purpose of study The emergence of antimicrobial resistance in neonatal intensive care units (NICUs) has been linked to the inappropriate use of antibiotics. We initiated the use of an early onset neonatal sepsis (EOS) calculator for choosing antibiotics wisely as part of VON 2017 iNICQ antibiotics stewardship initiative.

Primary objective: To assess the effect of EOS calculator in reducing initiation of antibiotics for suspected EOS in first 48 hours in our level II NICU for infants ≥ 35 weeks GA.

Secondary objective: To evaluate the impact of intervention bundle in collection of optimal blood volume (>1 ml) for culture and continuing antibiotics beyond 48 hours.

Methods used Pre-intervention data was collected retrospectively for all NICU admissions between January and December 2016. Intervention bundle consisted of training on how to use EOS calculator, educating NICU staff on optimal blood volume for culture, and standardizing criterion for antibiotics usage beyond 48 hours, over 2 months (Mar 2017–Apr 2017). Starting May 2017, use of defined interventions were implemented. Inborn infants born ≥ 35 weeks GA admitted to NICU between May, 2017 to Sept, 2017 (post-intervention) were included. Data collected were: antibiotics usage in first 48 hours, blood culture rate and volume, and antibiotics usage beyond 48 hours. Pre and post intervention outcomes were compared using Chi square test, with the SAS Statistical Software (V9.3).

Summary of results Pre intervention ($n=118$) data was compared to post intervention ($n=37$) (table). EOS calculator was used in 97% of eligible infants. Implementation of EOS calculator resulted in reduction of obtaining blood culture from 59.3 to 35.1% ($p=0.01$), antibiotics usage in first 48 hours from 33 to 21.6% ($p=0.15$). Blood culture volume was optimal in 87% of blood cultures drawn.

Conclusions EOS calculator and intervention bundle resulted in significant reduction in blood cultures obtained, antibiotics initiation rate and continuation beyond 48 hours.

Abstract 418 Table 1 Pre intervention ($n=118$) data was compared to post intervention ($n=37$)

Outcome measures	Pre intervention ($n=118$)	Post intervention ($n=37$)	p Value
Blood culture rate	59.3%	35.1%	0.01
Antibiotics initiation rate	33%	21.6%	0.15
Antibiotics beyond 48 hours	41%	25%	0.407
Optimal blood culture volume	N/A	86.4%	
EOS calculator use	N/A	97.2%	

419 OUTCOME DIFFERENCES BASED ON MANAGEMENT OF PATENT DUCTUS ARTERIOSUS IN VERY LOW BIRTH WEIGHT INFANTS IN A LEVEL IV NEONATAL INTENSIVE CARE UNIT

MM Makoni*, J MILAM, A Manfredo, A Chaphekar. *OUHSC, Oklahoma City, OK*

10.1136/jim-2017-000697.419

Purpose of study To compare outcomes between pharmacologically treated versus non-treated Very Low Birth Weight (VLBW) infants with echocardiographic (echo) diagnosis of Patent Ductus Arteriosus (PDA).

Methods used Retrospective analysis of inborn premature neonates weighing <1500 g between 23 and 33 weeks gestation from January 2014 – December 2016. Variables from our electronic medical records (EMR) included PDA diagnosis, use of indomethacin, ibuprofen, acetaminophen and PDA ligation. Antenatal steroids, maternal demographics and the following outcomes were recorded: mortality, severity of intraventricular hemorrhage (IVH)(grade 3 & 4) and retinopathy of prematurity (ROP)(stage 3 & 4), necrotizing enterocolitis (NEC) (medical and surgical), spontaneous intestinal perforation (SIP), broncho pulmonary dysplasia (BPD) and Bayley 1 & 2 scores. We also collected age at initial PDA diagnosis, age at first echo, vasopressors in first 14 days, ventilation in first 3 days, surfactant, and total ventilator days. Data were analyzed in SAS (V 9.3) using ANOVA, non-parametric one way analysis of variance and Chi Square tests as appropriate.

Summary of results Initial analysis of the 2014 data identified 48 babies which met inclusion criteria (treated group n=27 and non-treated group n=21), out of 129 babies. The treated group had lower gestational age (p=0.015) 95% CI: 1.4001 to 1.9599, lower birth weight (p=0.038) 95% CI: 129.9541 to 194.3059 and more males (p=0.048). There was no statistically significant difference for antenatal steroids. Analysis of outcomes revealed significantly higher use of vasopressors in the first 14 days (p=0.002), higher total ventilator days (p=0.0163) 95% CI: 40.5253 to 55.6147, higher SIP (p=0.029), BPD (p=0.0003) and more discharges with home oxygen (p=0.0001). No statistically significant differences in mortality prior to discharge, severity of IVH, ROP, NEC, Bayley 1 and 2 scores, surfactant, age at first echo and age at initial diagnosis of PDA. The remaining data (2015 & 2016) are undergoing statistical analysis.

Conclusions VLBW infants with a treated PDA are of lower gestational age, smaller, sicker and have a tendency develop BPD and require oxygen at discharge. However, there was no difference in mortality prior to discharge and neurodevelopmental outcomes.

420 NEONATAL NON-INVASIVE RESPIRATORY WEANING PROTOCOL IMPLEMENTATION

DN Matlock*, AS Ross. *University of Arkansas for Medical Sciences, Little Rock, AR*

10.1136/jim-2017-000697.420

Purpose of study At the University of Arkansas for Medical Sciences during 2015, the length of neonatal intensive care unit stay was longer than the 75th percentile compared to similar centers in the Vermont Oxford Network. Respiratory weaning protocols have proven to decrease days of respiratory support, oxygen exposure, hospital stay, and rates of

bronchopulmonary dysplasia. We hypothesized that implementing a weaning protocol for non-invasive respiratory support would decrease the time to wean from nasal continuous positive airway pressure (NCPAP) to room air (RA) by 24 hours (30% reduction) over a period of 3 months in infants 30–34 weeks gestation.

Methods used We examined the following outcomes:

Primary outcome

Time to wean from NCPAP to RA.

Secondary outcomes

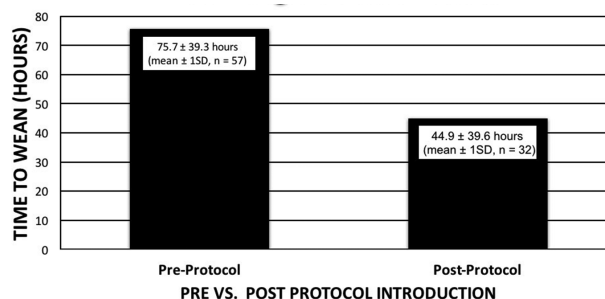
Duration of non-invasive respiratory support, length of stay, and adjusted age at full enteral feeds (120 mL/kg), initiation of oral feeds, and attainment of full oral feeds.

Balance measures

Duration of oxygen exposure and growth velocity.

Summary of results Time to wean decreased from 75.7±39.3 hours (mean±1SD) to 44.9±39.6 hours (n=32), a reduction by 38% or 30.8 hours (p=0.0001). Length of stay decreased from 32.3±13.7 days to 25.5±14.2 days (p=0.02). Growth velocity decreased from 19.1±8.4 grams per day to 15.1±8.0 grams per day (p=0.02) after implementing the protocol. No other outcome variability reached statistical significance. Patient characteristics were similar in both groups.

Conclusions This project illustrates the effectiveness of establishing and implementing a protocol to wean non-invasive respiratory support in neonates at decreasing duration of support and length of stay. This result raises concerns that weaning respiratory support more quickly may impact growth velocity, perhaps by impacting work of breathing and calorie expenditure. This finding warrants further study.



Abstract 420 Figure 1 Average time to wean

421 PULMONARY HEMORRHAGE IN EARLY-ONSET NEONATAL *KLEBSIELLA PNEUMONIAE* SEPSIS

J McAteer*, J Miller, S Buchter. *Emory University, Atlanta, GA*

10.1136/jim-2017-000697.421

Background Early onset sepsis (EOS) is a serious complication in neonates commonly caused by Group B Streptococcus and *Escherichia coli*. The early recognition of other gram-negative organisms such as *Klebsiella pneumoniae* is becoming increasingly important amidst declining GBS rates and the emergence of multidrug resistant organisms. We report that pulmonary hemorrhage may be a distinct clinical symptom of *Klebsiella pneumoniae* distinguishing it from other causes of EOS.

Case presentation A term male was born to a 25 year old primigravida by cesarean section for failure to progress and maternal chorioamnionitis. The mother received ampicillin and clindamycin during labor, and the infant was started on

ampicillin and gentamicin after a sepsis screen was performed. At 24 hours of life, the infant became hypoglycemic requiring intravenous dextrose in the Neonatal Intensive Care Unit. At 52 hours of life, he developed hemoptysis requiring intubation. A PEEP of 10 cm of water was required to tamponade his pulmonary hemorrhage and chest radiograph revealed diffuse patchy opacities bilaterally. He developed profound anemia, thrombocytopenia, and coagulopathy requiring blood product resuscitation. Antibiotics were broadened to ceftazidime and gentamicin. At the same time, the patient's mother developed fever, tachycardia, and abdominal pain. She was diagnosed with endometritis after her culture grew *Klebsiella pneumoniae*. The infant's antibiotic regimen was broadened to meropenem. By day 4 of life, the pulmonary hemorrhage and coagulopathy resolved. His blood culture grew *Klebsiella pneumoniae* that was resistant to ampicillin. He received meropenem for 21 days before being discharged home on oral feedings.

Discussion This is a rare case of *Klebsiella pneumoniae* EOS presenting as diffuse pulmonary hemorrhage in a term infant. The presentation seen in our infant has not been well described previously in the literature but is consistent with *Klebsiella pneumoniae* given the organism's propensity to infect and damage lung tissue. Clinicians should be cognizant of this unusual presentation of EOS as it will help with rapid identification and management of a potentially lethal *Klebsiella pneumoniae* infection. In addition, maternal blood and endometrial cultures are helpful in timely management of a deteriorating neonate.

422 WIDELY METASTATIC CONGENITAL SMALL BLUE CELL MALIGNANCY IN A NEONATE

¹W Mena*, ²D Simmons, ³DR Kelly, ⁴JB Philips. ¹Brookwood Medical Center, Birmingham, AL; ²Cunningham Pathology, Birmingham, AL; ³Children's of Alabama, Birmingham, AL; ⁴Univ of AL at Birmingham, Birmingham, AL

10.1136/jim-2017-000697.422

Introduction Malignancies are rare in neonates. We present a term infant who died shortly after birth with masses in the mouth and neck and widespread malignant lesions in multiple organs.

Case report This term 4 kg female had respiratory failure at delivery and died 1.5 hours after birth. Exam revealed a 2.5 × 2.5 cm mass on the right tongue and a 10 × 10 cm mass in the right submandibular neck. The abdomen was tense and grossly distended. There was generalized edema and a disseminated 'blueberry muffin' rash, with numerous purple-grey skin and soft tissue nodules involving the chest, trunk, back, abdomen, thighs, and lower legs. At autopsy there were bilateral serous pleural effusions (20 mL each), a serous pericardial effusion (10 mL) and a serosanguineous peritoneal effusion (50 mL). Multiple purple-grey tumor nodules were noted in the heart, lungs, liver, gallbladder, spleen, pancreas, kidneys and adrenals. Microscopy showed irregular sheets and nests of small to intermediate round cells exhibiting variable cytologic atypia and mitotic activity ('malignant small blue cells') in all of the above organs. Tumor thromboemboli with hemorrhage and necrosis were noted in many of the organs and tissues. The most common congenital malignancies (neuroblastoma, leukemia, rhabdomyosarcoma) could be ruled out by location, morphologic appearance and lack of typical immunohistochemical staining features. While not definitive, loss of INI-1

nuclear staining suggested a diagnosis of widely metastatic small cell hepatoblastoma.

Discussion Congenital malignancies are rare and can present with aggressive clinical behavior. Extracranial teratomas, neuroblastoma, some soft tissue tumors, CNS tumors, leukemia, renal, hepatic, and cardiopulmonary tumors, and malignant melanoma are most common. Some malignancies may be inherited while others are associated with malformation syndromes or prenatal exposure to environmental agents, maternal medical therapies or tumors. When tumor location, appearance, immunohistochemical staining methods, and laboratory tests can not define the origin, molecular and/or genetic testing may provide crucial diagnostic information.

423 INHIBITION OF EXTRACELLULAR SIGNAL-REGULATED KINASES 1/2 DISRUPTS ANGIOGENESIS IN THE DEVELOPING LUNGS

R Menon*, A Shrestha, B Shivanna. Baylor College of Medicine, Houston, TX

10.1136/jim-2017-000697.423

Purpose of study Bronchopulmonary dysplasia (BPD) is the most common chronic lung disease of human preterm infants. Several insults interrupt angiogenesis and contribute to BPD pathogenesis; however, how these insults dysregulate lung angiogenesis is poorly understood. To fill this knowledge gap, we used a well established hyperoxia-induced lung injury model. Hyperoxia exposure affects the expression of several mitogens, including extracellular signal-regulated kinases (ERK) 1/2. Whether it affects the lung endothelial ERK1/2 signaling in neonatal mice and whether ERK1/2 promotes lung angiogenesis in human infants is unknown. Therefore, we tested the hypothesis that ERK1/2 signaling is necessary to promote lung angiogenesis and to protect against hyperoxic lung injury. **Methods used** *In vivo experiments*: One-day-old WT mice were exposed to 21% O₂ (normoxia) or 70% O₂ (hyperoxia) for up to 14 d, after which lung tissues were harvested to determine vascularization and ERK1/2 activation.

In vitro experiments: Fetal human pulmonary artery endothelial cells (HPAECs) were exposed to air and hyperoxia for up to 48 h, after which the cells were harvested to quantify ERK1/2 activation. Further, to determine if ERK1/2 signaling affects lung angiogenesis, HPAECs treated with varying concentrations of the ERK1/2 inhibitor, PD 98059. Finally, we determined if ERK1/2 inhibition affects hyperoxia-induced cytotoxicity.

Summary of results Hyperoxia exposure increased lung angiogenesis at 7 d, before decreasing it at 14 d, when compared to normoxia exposed animals. Interestingly, the effects of hyperoxia on ERK1/2 activation followed an identical pattern both in neonatal mice and HPAECs, wherein hyperoxia initially increased, but later decreased ERK1/2 activation. At basal conditions, ERK1/2 inhibition significantly decreased HPAEC proliferation, migration, and tubule formation, indicating that ERK1/2 signaling is necessary for lung angiogenesis. Additionally, ERK1/2 inhibition augmented hyperoxia-induced cytotoxicity.

Conclusions We conclude that ERK1/2 signaling is necessary to promote lung angiogenesis and to protect against hyperoxic lung injury. Our results indicate that ERK1/2 signaling pathway is a potential therapeutic target for the management of human BPD infants with decreased lung vascularization.

424 NORMAL TROPONIN T AND NTPROBNP LEVELS IN PRETERM INFANTS WITHIN FIRST 5 DAYS OF LIFE

¹VD Modi*, ¹A Qasim, ^{1,2}P Asrani, ³AM Aly, ¹S Jain. ¹UTMB, Dickinson, TX; ²Utah HSC, Salt Lake City, UT; ³UTMB, Galveston, TX

10.1136/jim-2017-000697.424

Purpose of study Highly sensitive Troponin T (hsTnT) and NTproBNP are biomarkers of myocardial ischemia and stretch, respectively. The purpose of this study was to determine the normal range of hsTnT and NTproBNP levels in preterm infants (PI) in the first 5 days of life.

Methods used PI (≤ 34 weeks and < 1500 gm) were prospectively enrolled in the observational study. ECHO was performed on day 3–5 and blood sample collected (centrifuged and stored at -80°C) within 30 minutes of ECHO. PI were grouped based on PDA diameter. Data was analyzed on SPSS 24.

Summary of results We recruited 76 PI (see table 1 for baseline characteristics). Figure 1 shows the median and interquartile range (IQR) of hsTnT and NTproBNP levels in the 3 groups.

Abstract 424 Table 1 Baseline characteristics

Characteristics	No PDA (44)	PDA (20)	PDA >1.5 (20)	p value
Gestational Age (Mean \pm SD in weeks)	28.3 \pm 2.08	27.6 \pm 2.5	26.8 \pm 2.0	0.024
Sex, Male n(%)	29 (66)	4 (33)	6 (30)	0.011
Birth weight (Mean \pm SD in grams)	1056.3 \pm 226.4	1025.4 \pm 297.4	884.5 \pm 283.3	0.047
Mode of Delivery (C-section) n(%)	33 (75)	10 (83)	20 (100)	0.048
Steroid use n(%)	42 (95)	11 (92)	18 (90)	NS
Respiratory support n(%)				NS
- Nasal cannula	3 (7)	0 (0)	0 (0)	
- CPAP/BiPAP	31 (72)	7 (58)	14 (70)	
- Cont. Mechanical Ventilation	7 (16)	1 (8)	4 (20)	
- HFOV	2 (5)	3 (34)	2 (10)	
Pre-eclampsia n(%)	13 (30)	7 (58)	6 (30)	NS
Diabetes n(%)	12 (27)	2 (17)	4 (20)	NS

1. Continuous/bilevel positive airway pressure, 2. High frequency oscillation ventilation
NS=not significant

Conclusions In PI without PDA, the median \pm IQR levels of hsTnT and NTprBNP are 166 \pm (90–200) pg/mL and 2045 \pm (1045–3753) pg/mL [p1] respectively. HsTnT and

NTproBNP levels were significantly higher in infants with hemodynamically significant PDA (hsPDA).

425 THE EFFECT OF POSTNATAL ADAPTATION AND MECHANICAL VENTILATION ON THE GENE EXPRESSION PROFILE OF ENDOGENOUS LUNG MESENCHYMAL STROMAL CELLS

R Macias*, SB Mustafa, A Moreira, S Sidiqqi, T Johnson-Pais, J Gelfond, D Wilson, SR Seidner. UTHSCSA, San Antonio, TX

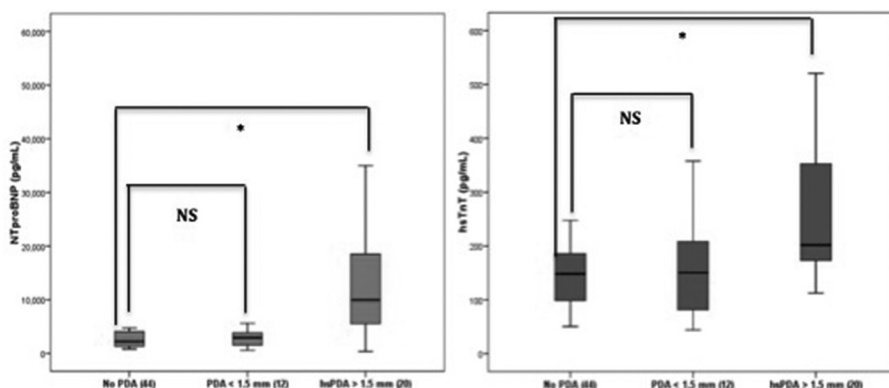
10.1136/jim-2017-000697.425

Purpose of study In preclinical studies, administration of exogenous mesenchymal stromal cells (MSCs) attenuate lung injury. Since engraftment is minimal and transient, the beneficial effects, which are mimicked by conditioned medium, appear to be mediated by a paracrine mechanism to repair/regenerate endogenous lung cells, possibly including endogenous lung MSCs. However, the molecular properties of injured endogenous lung MSCs have yet to be clarified. The objective of this study was to identify genes and/or molecular pathways in endogenous lung MSCs that are altered following MV and postnatal adaptation in a preterm animal model.

Methods used Preterm rabbit pups were delivered at 29 d gestational age (term=31 d). Following delivery, pups were randomized into three groups: sacrificed at birth (fetal), spontaneously breathing with supplemental oxygen (50%) for 4 h (SB), or mechanical ventilated (MV) with supplemental oxygen (50%) for 4 h. Following necropsy, endogenous lung MSCs were isolated by enzymatic digestion followed by Ficoll-purification and cultured using standard cell conditions. Upon confluency, RNA was isolated. Genome-wide transcriptome profiling was performed using the Agilent 44 K rabbit gene expression microarray (n=4 per group). Array data was analyzed with GeneSpring, R software, and Ingenuity pathway analysis (IPA) with significance denoted as a two-fold change in expression and a p value < 0.05 .

Summary of results Of 493 (total number) genes, 458 genes were found to be differentially expressed in the MV vs fetal groups, and 98 genes were differentially expressed between the SB and fetal groups. Overall, the pathways most relevant included cell cycle control of chromosomal replication, DNA damage checkpoint regulation, inhibition of angiogenesis, and embryonic stem cell pluripotency.

Conclusions Postnatal mechanical ventilation with supplemental oxygen alters the gene expression in endogenous preterm



Abstract 424 Figure 1 Median and IQR of NTproBNP and hsTnT in preterm infants*Significant results; NS: not significant

animal lung MSC's. Pathway analysis substantiated the involvement of known genes integral in lung damage and repair.

426 EARLY CONTINUOUS RENAL REPLACEMENT THERAPY DURING NEONATAL EXTRACORPOREAL LIFE SUPPORT DECREASES LUNG OPACIFICATION

HJ Murphy*, M Eklund, J Hill, K Morella, JB Cahill, J Kiger, K Twombly, DJ Annibale. *Medical University of South Carolina, Charleston, SC*

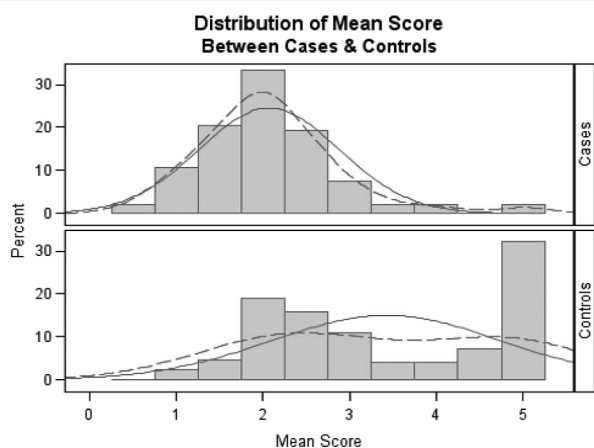
10.1136/jim-2017-000697.426

Purpose of study Continuous renal replacement therapy (CRRT) is used to optimize fluid status during neonatal extracorporeal life support (ECLS), but the effect on lung opacification has not been studied. We hypothesized that early CRRT use during neonatal ECLS decreases lung opacification on chest radiography (CXR).

Methods used We conducted a case-control study comparing CXRs from neonates receiving ECLS and concurrent early CRRT (Cases; n=7) to case-matched neonates who received ECLS alone (Controls; n=7). The CXR obtained prior to ECLS, all CXRs obtained within the first 72 hrs of ECLS, and daily CXRs for the remainder of the ECLS course were analyzed. The outcome measure was the degree of lung opacification, determined by independent assessment of 2 pediatric radiologists using a lung opacification scoring system developed by Edwards *et al.* (score 0: no opacification- score 5: complete opacification).

Summary of results 220 CXRs were assessed (Cases: 93, Controls: 127). Inter-rater reliability was established with a Cohen's weighted $k=0.74$ ($p<0.0001$, good agreement). At baseline, the mean opacification score difference between cases and controls was 1 point (Cases: 1.8, Controls: 2.8; $p=0.049$). Using repeated measures analysis and mixed modeling, accounting for differences at baseline, the average overall opacification score was 1.2 points lower in cases than controls (Cases: 2.1, Controls: 3.3; $p<0.0001$). The overall distribution of scores was lower in cases than controls (figure 1).

Conclusions Early CRRT utilization during neonatal ECLS significantly decreases lung opacification on CXR.



Abstract 426 Figure 1 The overall distribution of scores was lower in cases than controls

427

EXPRESSION DIVERSITY OF BASIC MYELIN-RELEVANT MOLECULES IN MULTIPLE RAT BRAIN REGIONS AFTER PERINATAL METHADONE EXPOSURE

R Oberoi*, N Mellen, T Chu, R Jagadapillai, H Ouyang, L Devlin, R Wu, J Cai. *University of Louisville, Louisville, KY*

10.1136/jim-2017-000697.427

Purpose of study The purpose of this study is to evaluate the effects of pre and postnatal MTD exposure on myelin development in multiple regions of the developing in neonatal rat brain.

Methods used Nine pregnant Sprague Dawley rat dams were randomly assigned into three experimental groups and exposed to drinking water alone (control) or drinking water containing MTD (0.2 ml/L) from 7 days post coitum (dpc) to postnatal day 7 or to postnatal day 19 (P7 or P19). Pups in the treatment groups were exposed to MTD in utero and during the postnatal period via maternal milk. All neonatal rats were terminated at P19. Brain regions including cerebral cortex, hippocampus, cerebellum, and brain stem were dissected and analyzed via Western blot for three myelin specific proteins; CNP, PLP, and MBP.

Summary of results In all perinatal MTD-exposed rat pups, expression of CNP, PLP, MBP were significantly decreased in cerebral cortex and hippocampus ($p<0.05$). In the cerebellum, PLP expression was down-regulated ($p<0.05$) without apparent alteration of CNP and MBP expression. Surprisingly, CNP protein level was boosted although PLP and MBP expression were significantly inhibited in brain stem ($p<0.05$). In addition, prolonged postnatal MTD exposure (7dpc to P19) by maternal milk did not significantly change myelin proteins in all four brain regions compared to short-time postnatal exposure (7dpc to P7).

Conclusions Our results demonstrate decreased expression or downregulation of most myelin specific proteins in four regions of the brain after pre and postnatal exposure of rat pups to maternal methadone. Decreased myelination has been correlated with white matter deficits, which are a known risk factor for developmental delay. As MTD is the cornerstone of medication assisted treatment during pregnancy, the impact of methadone on the developing human brain needs to be further evaluated in both animal models and in the human infant.

428

ANTICOAGULATION ON EXTRACORPOREAL MEMBRANE OXYGENATION IN A PATIENT WITH INTRACEREBRAL HEMORRHAGE

A Pal*, E Gravari. *University of Louisville, Louisville, KY*

10.1136/jim-2017-000697.428

Case report Anticoagulation Strategies vary widely between institutions while on Extracorporeal Membrane oxygenation (ECMO) without current consensus. Despite newer management modalities, anticoagulation related mortality is on the rise.

Case is presented of a newborn boy, born at 36 weeks gestation with a weight of 2100 g and meconium present at delivery. However, on exam, appeared to be 34 weeks gestation and also had hypospadias. He developed severe respiratory distress requiring intubation, surfactant and increasing ventilator support soon after birth. Infant developed severe

persistent pulmonary hypertension and by day 2 of life had an oxygenation index of 54 despite surfactant administration, nitric oxide, aggressive ventilation, multiple pressors and inhaled prostacyclin.

Hence, decision was made to put patient on Venous-Arterial ECMO after discussion with family and evaluating risk factors given lower gestational age and birth weight. He had a normal head ultrasound prior to ECMO initiation, but 12 hours after, revealed a large intra-parenchymal bleed with midline shift. Despite this, and after parental request, ECMO was continued due to continued cardiorespiratory instability.

Anticoagulation was maintained on an unusually very low dose of heparin (10 units/kg/hr) with tighter activated coagulation time (ACT) goals of 160. Other parameters such as anti-factor Xa, antithrombin III (ATIII) and thromboelastograms were monitored that essentially confirmed a minimal heparin effect. Neurological status was closely monitored along with daily head ultrasounds. Infant was successfully decannulated after 3 days of ECMO with a healthy ECMO circuit and no new brain bleed or extension of existing parenchymal hemorrhage.

This case illustrates ECMO related morbidity in infants meeting borderline ECMO criteria and the use of appropriate anti-coagulation management in case of a severe brain bleed, a predictable side effect of ECMO anticoagulation. Heparin dosing in neonates continues to be a challenge however use of an ultra-low dose heparin drip as seen in this patient can be used successfully in infants with severe brain bleeds. Recognition of bleeding while on ECMO is critical for titration of anticoagulation strategies to prevent morbidities.

429 ACTIVE CARE OR COMFORT CARE OF PERIVIAL INFANTS: PARENTAL PERPLEXITY AND DECISION REVERSAL

R Pandey*. *The University of Texas Health Science Center at Houston, Houston, TX*

10.1136/jim-2017-000697.429

Purpose of study The goal of this study is to identify how often the families of periviable infants, who have received individualized antenatal counselling regarding the outcomes of preterm infants, had chosen a prenatal care plan on whether to provide active care or comfort care to the newborn, and how often the decision was reversed from comfort care to active resuscitation after the window to administer antenatal steroids had passed.

Methods used In a retrospective review of all non-anomalous, inborn, single and twins infants born at 23 and 24 weeks of gestational age from January 2012 to December 2016, we reviewed the medical records of mother-infant dyads for prenatal counselling, shared decision on selecting comfort care or active care, exposure to antenatal steroids, delivery room events including the presence or absence of neonatal resuscitation team, performance of neonatal resuscitation and delivery room outcomes including the death of an infant or hospitalization.

Summary of results We found that 4.8% of the infants were born within six hours of maternal hospitalization, and the families did not have enough time to choose a plan for active or comfort care. Active care was chosen for 85% of the periviable infants, and comfort care was opted for 6.5% of the infants. 50% of the families who had initially opted for

comfort care and did not receive antenatal steroids subsequently asked for initiating active resuscitation. After a subgroup analysis, we found that two-thirds of the infants born at 23 weeks who were not exposed to ANS were due to the shared decision to provide comfort care.

Conclusions There is a paucity of literature on how often the decisions are reversed from comfort care to active resuscitation in periviable infants. We found that a large majority of families had a plan for active care or comfort care. However, among those who selected comfort care, half reconsidered their decision after the window to administer antenatal steroids had passed. All cases of decision reversal from comfort to active care occurred in infants born at 23 weeks of gestational age. Future studies should focus on finding factors that lead to decision reversals.

430 ABSTRACT WITHDRAWN

431 BRONCHOPULMONARY DYSPLASIA ASSOCIATED PULMONARY HYPERTENSION – A SURVEY OF CURRENT NATIONAL PRACTICES

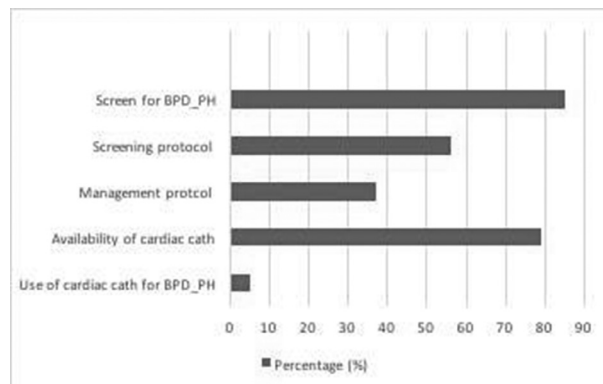
A Qasim*, S Jain. *University of Texas Medical Branch, Galveston, TX*

10.1136/jim-2017-000697.431

Purpose of study Bronchopulmonary dysplasia associated (BPD) pulmonary hypertension (BPD_PH) occurs in >1/3rd of preterm infants with BPD. In 2016, American Heart Association (AHA) recommended cardiac catheterization prior to initiation of long-term therapy for BPD_PH. Since significant differences exist regarding the optimal management of BPD_PH, our aim was to evaluate the current national practices.

Methods used A prospective cross-sectional online survey of neonatal providers was conducted. A 25-item questionnaire was developed and piloted to collect information on the availability of resources, diagnosis, and management of BPD_PH.

Summary of results 103 providers (55% neonatologists, 26% neonatal fellows and 18% neonatal nurse practitioners) participated from level 4 (84%) and level 3 (16%) centers. Most centers take care of infants >23 weeks' gestational age, have maternal-fetal medicine division, pediatric surgeons and pediatric cardiologists (99%). Pediatric cardiac surgeons (81%); ECMO (84%); Pediatric pulmonologist (88%); Neonatal network (62%); cardiac



Abstract 431 Figure 1 Current national practices in the management of BPD_PH

catheterization (79%). The majority use the NICHD definition of BPD (55%) and the most commonly used treatment is hydrochlorothiazide and spironolactone (44%). ECHO is used to screen for BPD_PH (84%) at 36 weeks (38%) and after 36 weeks (22%). For treatment, centers use oxygen to maintain saturations > 95% (4%), Sildenafil (10.5%), iNO (4%), and the combination of all above (81.5%).

Conclusions Wide variation exists in the diagnosis and management of BPD_PH. Despite its availability, cardiac catheterization is not utilized due to lack of practicality. There is an urgent need for appropriate and practical guidelines for the management of BPD_PH.

432 MATERNAL VS DONOR HUMAN MILK-DOES IT MAKE A DIFFERENCE?

CB Ramirez*, DC McCurnin, A Moreira, R Tragus, CL Blanco. *University of Texas Health San Antonio, San Antonio, TX*

10.1136/jim-2017-000697.432

Purpose of study Extrauterine growth restriction (EUGR) affects premature, low birth weight infants due to limitations in the delivery and absorption of calories. Despite optimization of feeding practices and the use of human milk EUGR persists. The purpose of this study was to evaluate growth in preterm infants fed predominantly maternal expressed breast milk (MEBM) or donor human expressed breast milk (DEBM).

Methods used Data was collected on all VLBW infants over a 3-year period. Outborn infants and infants with intrauterine growth restriction, necrotizing enterocolitis, or death/discharge prior to 36 weeks corrected gestational age (CGA) were excluded. Student's *t* test, chi-square and logistic regression analyses were performed as appropriate. Z-scores were calculated and small for gestational age (SGA) was defined per Fenton growth parameters.

Summary of results Of the 437 charts reviewed, 203 VLBW infants were included in the final analysis. Compared to the DEBM group, MEBM infants were younger (GA 28 ± 3 weeks vs 29 ± 2 weeks respectively, $p=0.004$), had a slightly lower BW (1073 ± 259 g vs 1140 ± 248 g, $p=0.06$), but had similar SGA % at birth. Both groups initiated enteral feeds on day of life 3, but DEBM infants reached full feeds 7 days earlier ($p=0.001$). This difference was likely due to GA differences since groups had similar co-morbidities. DEBM infants received higher total caloric intake by 3 weeks of life (118 vs 108 kcal/kg/day, $p=0.005$). Surprisingly, at 36 weeks CGA, DEBM infants trended towards a greater SGA % than those in the MEBM group ($p=0.06$). After adjusting for covariates, we found DEBM was no longer associated with an increased risk of EUGR. However, infants predominantly fed MEBM had a more favorable change in z-score from birth to 36 weeks CGA (OR 0.42, CI: 0.20 to 0.87, $p=0.02$). Exponential growth velocity was similar between groups (OR 0.5, CI: 0.2 to 1.2, $p=0.1$).

Conclusions In this single center study of select VLBW infants, maternal versus donor human milk did not result in differences in EUGR. There were no differences in exponential growth velocity nor SGA status in the two groups studied; however, infants fed predominantly maternal EBM lead to improved z-scores from birth to 36 weeks CGA. Future studies are necessary to determine the body composition effects of human breast milk in preterm infants.

433 SWALLOW-BREATH INTERACTION AND PHASE OF RESPIRATION DURING NUTRITIVE FEEDING IN PRETERM INFANTS

¹EW Reynolds*, ²C Bell. ¹University of Texas, Health Science Center at Houston, Houston, TX; ²University of Texas Health Science Center at Houston, McGovern Medical School, Houston, TX

10.1136/jim-2017-000697.433

Purpose of study We have used our multi-channel graphical method to describe swallow-breath interaction (SwBr) and phase of respiration (POR) during nonnutritive suck in various infants. We found 3 types of SwBr [Central Apnea (CA), Obstructive Apnea (OA) and Attenuated Respiration (AR)] and 5 types of POR [Beginning Expiration (BE), Mid-Expiration (ME), End-Expiration (EE), Mid-Inspiration (MI) and Apnea (AP)]. In this study, we describe SwBr and POR in a single study from the first 10 low-risk preterm infants (LRP) in our library of nutritive feeding (NF) studies.

Methods used LRP infants were born before 35 0/7 weeks with no congenital anomalies, no grade 3 or 4 IVH and at low risk for BPD. Our library includes repeated studies from 20+ babies. Informed consent was obtained. Infants were fitted with a custom assembly of instruments to measure suckle and swallow pressures, nasal airflow and chest movement during up to 15-minutes of NF. Biometric data were displayed as a multi-channel linear graph. As a swallow is identified, the corresponding SwBr and POR are categorized as in our previous work.

Summary of results The median number of swallows was 162 (range: 94–477). There were 4 males and 6 females. Median GA at birth was 27 weeks (range: 24.6–28.9). Median birth-weight was 995 g (range: 520–1160). Median day-of-life at the time of the study was 53 days (range: 40–71) and PMA was 34.4 weeks (range: 4.3–8.6). Studies occurred at median of 1.4 weeks post-first nipple feed (range: 0–3.2). A plurality of swallows occurred during apnea, in particular SwBr=CA (SwBr: CA:49%, OA:25%, AR:27%; POR: ME:4%, MI:6%, BE:14%, EE:29%, AP:46%).

Conclusions In this partial analysis, most swallows occurred with apnea during NF. This is similar to our initial results from our previous study of nonnutritive suck in the same group. In that work, we found a progression of SwBr and POR to a pattern with less apnea, which was influenced by developmental processes and learning. If findings are similar for NF, it would support the idea that interventions designed to influence nonnutritive suck can have a meaningful impact on the development of NF and may simplify research in this area since nonnutritive suck can be easier to study than NF.

434 ULTRASOUND DIAGNOSIS OF NECROTIZING ENTEROCOLITIS: A CASE SERIES

C Roitsch*, S Fallon, C Fernandes. *Baylor College of Medicine, Houston, TX*

10.1136/jim-2017-000697.434

Purpose of study Radiography has historically been the gold standard of diagnosing necrotizing enterocolitis (NEC) in a premature infant. The x-ray findings of NEC range from being largely nonspecific to pathognomonic. Unfortunately, the more specific findings are those which indicate advanced disease, likely requiring surgical intervention. In recent years, abdominal ultrasound (US) has increasingly been used in the

diagnosis of this devastating disease, and has many advantages over radiography.

Methods used With this report, we present clinical vignettes of two infant cases that highlight the benefits of abdominal US in the diagnosis and management of NEC.

Summary of results Our first infant was an 11-week-old ex- 25 5/7 week preterm female who developed sudden onset lethargy, apnea, hypothermia and mild abdominal distention. An evaluation for sepsis was performed, and empiric antibiotics were initiated. Except for a severe lactic acidosis (>20 mmol/L), laboratory investigations were unremarkable. An abdominal ultrasound captured peripherally located branching punctate lucencies consistent with portal venous gas. Our second infant was a one-week-old ex- 27 3/7 week preterm female who developed severe apneic episodes concerning for sepsis; hence, an evaluation for sepsis was performed and empiric antibiotics initiated. Abdominal US revealed pneumatosis intestinalis and portal venous gas. Abdominal x-ray at this time, however, was unremarkable.

Conclusions In preterm infants, pathognomonic signs for NEC include pneumatosis intestinalis and portal venous gas, which were both captured real-time with ultrasonography in our patients. To date, abdominal US has not been widely embraced as a means to diagnose NEC. In this report, we review the literature that supports the use of US for the diagnosis of NEC, highlighting its sensitivity over radiography and its benefits in resource-limited regions.

435 NEONATAL HEPATITIS OF UNKNOWN ETIOLOGY

RS Roland*, DS Shah. *East Tennessee State University, Johnson City, TN*

10.1136/jim-2017-000697.435

Introduction We present a unique case of neonatal hepatitis with rash.

Case description Dichorionic diamniotic AGA twins were born at 37 weeks gestation by C-section to a 27 yo G4P3 with negative prenatal labs. She had *no reported history of genital herpes and a questionable history of an oral cold sore in the distant past.* Within the first 8 hours of life, Twin A had poor feeding, Twin B was noted to have a very faint vesicular erythematous rash around the left shoulder and upper chest; both twins were hypothermic to 96 degrees and required placement in a radiant warmer. On CMP, Twin B had elevated AST to 227 U/L. Twin A's AST was within normal limits at 105 U/L.

Both babies were taken to the NICU, where sepsis work up and HSV work up were done. Attempts to obtain CSF from Twin A were unsuccessful. Empiric IV Acyclovir therapy was promptly initiated for both twins. Twin B's rash disappeared within several hours, and no specimen was obtained from lesions. All cultures and HSV PCRs came back negative, along with negative serology for syphilis. A repeat CMP showed Twin B's AST had fallen to 47 U/L. Acyclovir was discontinued after 5 days for both twins, who were discharged with no plan for Acyclovir suppressive therapy.

Discussion Prompt empiric treatment for suspected neonatal HSV improves mortality and morbidity. However, diagnosis may be challenging due to variability of factors including history, presentation, & lab findings. Also, mothers of >75% of infected infants are asymptomatic or unaware of HSV infection. Vesicular rash with an elevated transaminase makes a

strong case for HSV hepatitis; in our case, AST was elevated, whereas ALT level is included in AAP's HSV diagnosis criteria. There is not a definite etiology for hepatitis with HSV PCR negative and syphilis serology negative in our case. There is no available literature or recommendation for diagnosing neonatal hepatitis or for optimal treatment.

Conclusion Neonatal hepatitis is uncommon but requires extensive investigation. The etiology is usually HSV (especially if skin lesions are present) unless proven otherwise, like in our case. But the return of Twin B's elevated transaminase to normal after beginning HSV treatment raises some concern for the diagnosis, amid no clear guidelines in the perinatal literature.

436 NECROTIZING ENTEROCOLITIS TOTALIS DIFFERS FROM SURGICAL NECROTIZING ENTEROCOLITIS

A Rose*, I Adams-Chapman, A Piazza. *Emory University, Atlanta, GA*

10.1136/jim-2017-000697.436

Purpose of study The study goals are to describe the demographic and laboratory characteristics of necrotizing enterocolitis totalis (*t*NEC); compare *t*NEC to surgical NEC (*s*NEC); and develop a predictive model to distinguish the two.


Methods used Demographics, clinical and admission laboratory values were collected from the Children's Hospital Neonatal Database and chart review for infants diagnosed with *t*NEC or *s*NEC. Bivariate analysis was used for clinical and laboratory characteristics. Logistic regression and backwards selection ($\alpha=0.05$) were used to find the strongest *t*NEC predictors.

Summary of results 126 patients met inclusion criteria (48 *t*NEC, 78 *s*NEC). Table 1 compares the groups' characteristics. The model developed for predicting *t*NEC included paralytic agent on admission, antenatal steroids, and potassium level. Our model, with a probability level cutoff of 0.3, achieved 75% sensitivity and 70% specificity with an AUC of 85% (figure 1).

Abstract 436 Table 1 Compares the groups' characteristics

Characteristic n (%) or median (25–75%)	All (n=126)	<i>t</i> NEC (n=48)	<i>s</i> NEC (n=78)	<i>p</i> -value
Gestational age, wks	27.0 (25.0–30.0)	27.0 (25.0–28.0)	27.5 (26.0–30.0)	0.027
Birth weight, g	912 (720–1300)	827 (678–1095)	958 (740–1400)	0.043
Maternal steroids	90 (73)	40 (85)	50 (66)	0.019
Paralytic agent prior to admission	34 (27)	23 (48)	11 (14)	<0.0001
Potassium	4.8 (3.8–5.7)	5.6 (4.9–6.6)	4.3 (3.7–5.2)	<0.0001
Creatinine	0.7 (0.5–0.9)	0.8 (0.6–1.1)	0.6 (0.4–0.8)	0.002
pH	7.21 (7.10–7.32)	7.13 (7.02–7.26)	7.25 (7.14–7.34)	0.0002
Glucose	97 (63–133)	112 (67–178)	82 (63–118)	0.015

Conclusions *t*NEC patients present smaller, with higher acuity, and greater laboratory derangements than those with *s*NEC. Using factors with the highest predictive value, our model can assist in counseling families whose infants will undergo surgery.



Abstract 436 Figure 1 Our model, with a probability level cutoff of 0.3, achieved 75% sensitivity and 70% specificity with an AUC of 85%

437 MANAGEMENT OF PULMONARY HEMORRHAGE IN NEWBORNS

M Shahid*, P Westgate, S Khan, E Gomez, P Giannone, P Bhandary. *University of Kentucky, Lexington, KY*

10.1136/jim-2017-000697.437

Purpose of study Pulmonary hemorrhage (PH) is a catastrophic complication seen in 3–5% of preterm infants with high mortality. PH has a very high mortality rate and often presents acutely with sudden deterioration. The aim of this study is to determine clinical characteristics and management strategies leading to an increased survival rate during an episode of PH.

Methods used This retrospective case-control study comprised of 63 cases that met the inclusion criteria for PH admitted to the Neonatal Intensive Care Unit at the University of Kentucky from 2010 – 2014. Six cases were not included in final analysis because they meet exclusion criteria (infants receiving comfort care only, congenital heart disease (except patent ductus) and need for extracorporeal membrane oxygenation). Echocardiograms was performed for clinical indications and interpreted by a pediatric cardiologist. Wilcoxon, Chi-square, and Fisher's exact tests were used to compare cases to controls and pulmonary hemorrhage survivors to non-survivors.

Summary of results Analysis of survivors and non-survivors group showed that lower birth weight (920 g vs 745 g, $p=0.02$), hypotension (23% vs 56%, $p=0.02$), endotracheal tube epinephrine use during PH episode (41% vs 78%, $p=0.01$), and fluid resuscitation within 24 hours after PH episode (8% vs 67%, $p\leq 0.0001$) were associated with increased mortality. Switching to high frequency oscillatory ventilation (HFOV) (28% vs 22%, $p=0.75$) was not associated with improved survival. There was a trend towards improved survival with increasing positive end expiratory pressure (PEEP) (61% vs 33%, $p=0.07$) after PH. Use of indomethacin for PDA treatment improved survival in cases of PH (62% vs 22%, $p=0.01$).

Conclusions Our data suggests that Switching to HFOV was not associated with increased survival but increased PEEP can improve survival. Improved survival with PDA treatment in PH cases may warrant early echocardiographic surveillance

and treatment of PDA in high risk infants. Further research is warranted to verify these findings.

438 LEFLUNOMIDE DECREASES OXIDATIVE STRESS IN HYPEROXIA-EXPOSED PRIMARY HUMAN FETAL LUNG CELLS

AK Shrestha*, R Menon, B Shivanna. *Baylor College of Medicine, Houston, TX*

10.1136/jim-2017-000697.438

Purpose of study Hyperoxia-induced oxidative stress contributes to the development of bronchopulmonary dysplasia (BPD) in human preterm infants. We observed that aryl hydrocarbon receptor (AhR) signaling is necessary to protect primary fetal human pulmonary microvascular endothelial cells (HPMEC) against hyperoxic injury. Whether AhR activation is sufficient to protect HPMEC against hyperoxic injury is unknown. To this end, we used leflunomide (LEF), which is an AhR agonist and an immunosuppressive medication used in humans to treat rheumatoid arthritis. We tested the hypothesis that LEF will decrease hyperoxia-induced oxidative stress in HPMEC via AhR activation.

Methods used HPMEC were treated with varying concentrations of LEF and exposed to air or hyperoxia (95%) for up to 24 h, following which the cells were harvested to determine cell viability, hydrogen peroxide (H_2O_2) production and expression of several antioxidant genes, including NAD(P)H quinone dehydrogenase 1 (NQO1), hemoxygenase 1 (HO1), catalase, glutathione transferase (GST) and superoxide dismutase (SOD) -1,-2, and -3 at the mRNA and protein levels. Additionally, HPMEC were transfected with siRNA to knock-down AhR, following which the cells were treated with LEF and exposed to air or hyperoxia to determine the mechanisms by which LEF modulates oxidative stress.

Summary of results LEF did not affect cell viability at 24 h of exposure. Interestingly, LEF increased the expression of NQO1, SOD2, and HO1 and decreased H_2O_2 production in air-exposed cells. In hyperoxic conditions, LEF augmented hyperoxia-induced HO1 and NQO1 expression and decreased H_2O_2 production. Our AhR knockdown studies suggested that LEF decreased H_2O_2 production via AhR-independent mechanisms both in air- and hyperoxia-exposed cells.

Conclusions LEF protects fetal HPMEC against hyperoxia-induced oxidative stress via AhR-independent activation of the anti-oxidant enzymes, NQO1, SOD2, and HO1. Our results indicate that LEF is a potential therapeutic drug for the management of human BPD infants.

439 CUT UMBILICAL CORD MILKING: AN INEFFECTIVE METHOD OF PLACENTAL TRANSFUSION IN PRETERM INFANTS

A Simonin*, A Safarulla, Z Farmer, J Waller, J Bhatia. *Augusta University, Augusta, GA*

10.1136/jim-2017-000697.439

Purpose of study Benefits of umbilical cord milking (UCM) include higher hemoglobin/hematocrit (H/H), less intraventricular hemorrhage (IVH) & improved perfusion. Most literature on UCM involves the intact cord attached to placenta being milked two to four times toward the neonate before it is clamped. Limited literature exists on UCM through a segment

of detached cord while concurrently performing routine resuscitation. We hypothesized that preterm infants receiving UCM by cut umbilical cord milking (C-UCM) technique would have higher H/H and less need for transfusion compared to those who did not.

Methods used In October 2015, C-UCM was enacted at our NICU for in-born babies ≤ 37 wk. A 25 cm length of cord was clamped, cut and milked toward the baby at a rate of 10 cm/sec. We collected data on all neonates receiving C-UCM from 05/16 to 05/17 and used retrospective controls. Infants were divided into three groups: 23–27 wk, 28–32 wk and 33–37 wk.

Summary of results Demographic data represented in table 1 reveals that the groups are comparable. There were no statistically significant differences between control and C-UCM groups in terms of H/H, bilirubin, transfusions, IVH or pressor use.

Conclusions C-UCM is a safe procedure but does not lead to increased H/H or reduced incidence of IVH and transfusions, as per previous literature. This is the first study of its kind in infants ≤ 35 weeks.

Abstract 439 Table 1 Demographic information comparing the cord milking and non-cord milking group

Variable	Level	Cord Milking N=106	Non-Cord Milking N=297	p-value
Gestational Age – n (%)	23-27wks	19 (17.9)	38 (12.8)	0.1323
	28-32wks	23 (21.7)	92 (31.0)	
	33-37wks	64 (60.4)	167 (56.2)	
Sex – n (%)	Female	44 (41.5)	145 (48.8)	0.1953
	Male	62 (58.5)	152 (51.2)	
Delivery n (%)	Cesarean Section	68 (64.2)	184 (62.0)	0.6882
	Vaginal Delivery	38 (35.9)	113 (38.0)	
Birth Weight (g) – mean (SD)	23-27wks	735.79(± 174.14)	796.24(± 213.12)	0.7367
	28-32wks	1620.65(± 332.94)	1464.51(± 380.91)	
	33-37wks	2233.59(± 430.03)	2317.56(± 567.17)	
APGAR 1min – median (IQR)		7.0 (6.0)	7.0 (3.0)	0.0281
APGAR 5min – median (IQR)		7.0 (3.0)	8.0 (2.0)	0.0060
Admit Temperature(°C) – mean (SD)		36.3 (36.3)	36.2 (36.2)	0.2208

Abstract 439 Table 2 Comparison of primary and secondary outcomes between the two groups

Variable	Level	Cord Milking	Non-Cord Milking	p-value
Hemoglobin (gm/dL) – mean (SD)	23-27wks	13.45 (1.92)	12.61 (2.10)	0.8198
	28-32wks	16.20 (3.23)	15.19 (2.23)	0.4711
	33-37wks	16.05 (2.08)	16.41 (2.67)	0.9188
Hematocrit (%) – mean (SD)	23-27wks	40.92 (5.53)	38.20 (6.04)	0.7610
	28-32wks	47.73 (9.59)	45.48 (6.66)	0.7633
	33-37wks	48.01 (6.21)	48.99 (7.89)	0.9409
Bilirubin (mg/dL) – mean (SD)	23-27wks	5.34 (1.77)	5.93 (1.77)	0.9773
	28-32wks	8.05 (2.38)	8.07 (2.50)	1.000
	33-37wks	9.37 (2.94)	9.81 (3.31)	0.9004
Any Transfusion within 30 days – n (%)	Yes	22 (20.8)	55 (18.5)	0.6151
	No	84 (79.3)	242 (81.5)	
IVH – n (%)	Yes	9 (8.5)	31 (10.4)	0.5649
	No	97 (91.5)	266 (89.6)	
Pressors within 72hrs – n (%)	Yes	9 (8.5)	17 (5.7)	0.3196
	No	97 (91.5)	280 (94.3)	

440 NON-IMMUNE HYDROPS DUE TO CONGENITAL NEPHROTIC SYNDROME

TL Summerlin*, J Philips. *University of Alabama at Birmingham, Gardendale, AL*

10.1136/jim-2017-000697.440

Introduction Due to widespread use of Rh (D) immune globulin reducing the prevalence of Rh (D) alloimmunization and associated hydrops, non-immune hydrops fetalis (NIH) now accounts for 90% of reported cases. NIH is associated with a broad differential diagnosis and warrants a thorough evaluation to optimize care.

Case presentation A 39 wga infant was born to a 20 y/o G0P0 via vaginal delivery. Pregnancy was complicated by scalp edema, pericardial effusion without cardiac defects and ascites on ultrasound. Mother was O+ and antibody screen was negative. Maternal serologies were negative, including toxoplasmosis, parvovirus, CMV, HSV I/II, HIV, syphilis and rubella. The Kleihauer–Betke test was negative, and cell-free DNA testing was normal. Newborn exam was significant for mild abdominal distension and ascites with no scalp edema. Further imaging revealed resolution of the pericardial and pleural effusions, but persistent ascites. An extensive work-up on day 1 was largely negative, including urinalysis. At 2 days, the infant developed worsening abdominal distension and was found to have a colonic obstruction requiring surgery. At 6 days, the infant developed severe edema, low urine output, elevated creatinine, hypoalbuminemia and an elevated urine protein/creatinine ratio of 6188 mg/g, consistent with congenital nephrotic syndrome. Prior to initiation of dialysis, the baby developed E. coli sepsis from hypogammaglobulinemia. Despite aggressive volume and antibiotic management along with pressors, septic shock ultimately led to the infant’s demise.

Discussion Congenital nephrotic syndrome is a rare but important disorder. Infants are at high risk for infection from hypogammaglobulinemia, hypercoagulability from loss of anticoagulation factors and functional hypothyroidism from loss of thyroxine-binding globulin. Infants who survive past 3 months may require bilateral nephrectomies to control protein losses.

Conclusion Although congenital nephrotic syndrome causing hydrops is uncommon, NIH as a class accounts for the majority of hydrops fetalis cases seen in clinical practice. The diagnosis NIH is non-specific and requires a comprehensive work-up to determine the etiology. Though many cases remain idiopathic, the course of treatment is ultimately guided by disease-specific processes and sequelae.

441 GASTROSTOMY TUBES IN NEONATES- INDICATIONS AND 2-YEAR OUTCOMES AT A CHILDREN’S HOSPITAL

J Sun*, K Upadhyay, AJ Talati. *UTHSC, Memphis, TN*

10.1136/jim-2017-000697.441

Purpose of study The reasons for poor oral intake in a neonate can vary. Gastrostomy tubes (G-tubes) are commonly used to aid in the feeding of infants who are unable to swallow or do not acquire oromotor coordination. Multiple studies have shown that G-tube placement in neonates can be an indicator of adverse outcomes in the infants’ development and higher risks for neurodevelopmental delay. The objective of our study was to identify the characteristics of infants requiring g-tube and review their post-discharge outcomes.

Methods used We conducted a retrospective chart review of all patients receiving G-tubes from March 2013- December 2016 at our level 4 NICU at LeBonheur Children’s Hospital using the pediatric research database (PRD). Patients were identified using appropriate ICD codes and CPT codes. Demographics, clinical information and outcomes data were collected from patient charts. Means, medians, percentages, ranges, and standard deviations were used as appropriate for each data point.

Summary of results Out of 1928 NICU admissions, total of 225 (12%) patients were identified as having undergone G-

tube placement. Half of this cohort was female gender and 52% were African American. Median age at g-tube placement was 13 (6,24) wk after birth, while 204 (91%) had laproscopic placement. Majority 115 (51%) needed g-tube for dysphagia, followed by failure to thrive in 17 (8%); 63 (28%) infants had multiple indications. Term/near-term non-malformation infants received G-tubes later (53 vs 47 wk, $p=0.001$) than infants with malformations (table). At 1 year post-surgery, 70% of patients still had G-tubes in place, and at 2 years post-surgery, 73/177 (41%) developed normal PO feeding, while the rest still relied on g-tube.

Conclusions Both term and preterm infants needed g-tube placement for variety of reasons, primarily dysphagia. Infant with malformations received g-tube at an earlier age and most infants relied on them for at least 1 year.

Abstract 441 Table 1 Comparison between term-malformation/preterm/term infants

Clinical factor	Malformation (N=163, 63%) median (IQR)	Preterm (median (IQR))	Term/near-term (>32 wk) (N=47, 21%) median (IQR)
EGA	36 (31,38) wk	27 (25,29) wk	38 (36,39) wk
Birth Weight	2326±1373 g	1122±68 g	2860±1062
Age @ g-tube placement	12 (5, 21) wk	19 (13, 28) wk	16 (6,29) wk
Corrected GA @ g-tube placement	47 (43, 52) wk	47 (42, 54) wk	53 (45, 64) wk
G-tube @ 1 year age	112 (73%)	15 (67%)	30 (64%)

442 SEPTO-OPTIC DYSPLASIA PRESENTING AS PROLONGED TACHYPNEA IN A NEONATE

DE Thompson*, C Mumphrey, J Patrick. *LSUHSC, New Orleans, LA*

10.1136/jim-2017-000697.442

Case report Respiratory distress affects up to 7% of term infants and is one of the most common problems seen in the neonatal intensive care unit. Signs of respiratory distress may include grunting, nasal flaring, tachypnea, and chest retractions. Causes of respiratory distress in a newborn can vary and are not always related to the lungs. Evaluation of other systems may be necessary to determine the underlying cause of respiratory distress.

We present a term male with no prenatal care born via Caesarean section secondary to failure to progress and fetal decelerations. Delivery complications included meconium-stained amniotic fluid and maternal fever. In the delivery room, the infant required intubation due to poor respiratory effort. Chest xray was consistent with meconium aspiration syndrome. He was started on a course of antibiotics, and respiratory support was weaned. He was extubated by day of life 2. However due to persistent tachypnea, he required respiratory support until day of life 25. Due to the prolonged tachypnea, a head ultrasound was performed. It revealed dysgenesis of the corpus callosum and absent septum pellucidum. MRI of the brain was consistent with septo-optic dysplasia, showing agenesis of the corpus callosum, pituitary and optic nerve hypoplasia and olfactory bulb agenesis. The infant's

tachypnea eventually resolved. He was discharged home on day of life 38 with multidisciplinary follow-up including neurology, ophthalmology, genetics and pulmonology.

Septo-optic dysplasia is a rare group of disorders due to abnormal early forebrain development. It consists of at least two of the following: optic nerve hypoplasia, abnormal formation of midbrain structures, and pituitary hypoplasia. The incidence is 1 in 10,000 infants, and is typically due to de novo mutations. The most common features are hypopituitarism, visual impairment, and developmental delay. Presenting symptoms can vary from asymptomatic to those that include jitteriness or seizures, apnea, lethargy, hemodynamic instability, or failure to thrive. Because infants with septo-optic dysplasia may initially be asymptomatic or present with respiratory symptoms, medical professionals must have a high index of suspicion for central nervous system causes of respiratory distress.

443 EVALUATION OF SURFACTANT PROTEIN D IN THE MOUSE RETINA

¹F Vieira, ^{1,2}F Bhatti, ¹J Kung*. ¹Oklahoma University, Oklahoma City, OK; ²Dean McGee Eye Institution, Oklahoma City, OK

10.1136/jim-2017-000697.443

Purpose of study Retinopathy of prematurity (ROP) and its associated neovascularization (NV) is the leading cause of acquired childhood blindness worldwide. Surfactant Protein D (SP-D) plays an important role in innate immunity via regulation of inflammation. SP-D protein is known to up-regulate vascular endothelial growth factor in response to inflammation causing NV in lung tissue. Absence of related Surfactant Protein A (SP-A) decreases NV in C57BL6/J (WT) mouse retinas. We therefore hypothesize that SP-D is present in the mouse retina, which may also regulate NV, resulting in ROP.

Methods used Immunolocalization of SP-D was done by immunohistochemistry (IHC), protein expression by Western-Blot (WB) and quantification by ELISA, using commercially available antibodies. Mass Spectrometry (MS) was used as an alternative method to detect SP-D. To reinforce our proteomic results, we used mRNA PCR with primers that would only hybridize with WT SP-D mRNA. SP-D expression was induced by ligand activation with toll-like receptors 2 and 4 (TLR-2 and 4), and by the oxygen induced retinopathy (OIR) model, which is representative of ROP, and tested with our mRNA PCR strategy.

Summary of results IHC showed SP-D in the same distribution as SP-A in the mouse retina. ELISA successfully measured SP-D in the WT lung (positive control), however it failed to identify SP-D in the retina. WB had similar results to the ELISA. MS was then used to compare peptides of WT lung (positive control), SP-D^{-/-} lung (negative control) and WT retinas. Peptides homologous to SP-D were found in WT lung, but not in SP-D^{-/-} lung or WT retina. mRNA PCR showed positive bands in WT lung (positive control) and negative results in SP-D^{-/-} lung (negative control). It failed to identify SP-D mRNA in retinas at developmental time point (P0, P2, P5, P7, P14 and adult) as well as retinas exposed to OIR and TLR-2 and 4 ligands.

Conclusions SP-D was not identified in the mouse retina by proteomic methods dependent or independent of antibodies. In the same manner, the genomic evaluation of SP-D mRNA

failed to detect transcription of SP-D in developing retinas, adults and retinas exposed to noxious stimuli known to up-regulate SP-D. Therefore, we conclude that SP-D is not present in the mouse retina and has no local immuno-regulatory effect in WT mouse retina.

444 **ACUTE KIDNEY INJURY GUIDELINES IMPROVE RECOGNITION AND FOLLOW UP FOR NEONATAL PATIENTS**

K Vincent*, HJ Murphy, K Twombly, J Ross. *Medical University of South Carolina, Charleston, SC*

10.1136/jim-2017-000697.444

Purpose of study Studies demonstrate that neonatal acute kidney injury (AKI) is associated with increased morbidity and mortality. AKI survivors are at risk for renal dysfunction and chronic kidney disease and require long-term follow up. To maximize identification of infants with AKI and ensure appropriate referral, we created guidelines for diagnosis, evaluation and management of neonatal AKI in a single neonatal intensive care unit (NICU).

Methods used We conducted a retrospective cohort study, analyzing data from the electronic medical records (EMR) of infants admitted to the NICU within 48 hours of birth and hospitalized for ≥ 14 days. Neonatal AKI Guidelines were developed and implemented on 7/1/17. Comparisons were made between two Cohorts: Cohort 1-neonates treated prior to guideline implementation (n=175; 7/1/14–12/31/14) and Cohort 2- neonates treated after guideline implementation (n=51; preliminary data 7/1/17–present). Outcome measures included incidence of AKI, documented diagnosis of AKI (modified KDIGO criteria), pediatric nephrology inpatient and outpatient consultation.

Summary of results Based upon chart review, 68 episodes of AKI were found in 52 patients in Cohort 1 and 9 episodes were found in 6 patients in Cohort 2. Of the 68 AKI episodes in Cohort 1, 24 (17%) were diagnosed by the medical team and documented in the EMR. In Cohort 2, there was a significant increase in recognition of AKI with 7/9 (78%) episodes diagnosed and documented (p=0.026). There was a significant increase in the incidence of inpatient pediatric nephrology consultation in Cohort 2 [C1: 12/68 (18%), C2: 7/9 (78%); p=0.001]. In Cohort 1, 3/68 (4%) AKI episodes resulted in outpatient referrals. In Cohort 2, data collection is ongoing and patients have not yet been discharged.

Conclusions Preliminary data analysis suggests neonatal AKI guideline implementation led to statistically significant improvements in recognition and diagnosis of AKI by the medical team with associated documentation in the EMR as well as higher rates of inpatient nephrology consultation. Early recognition and diagnosis along with specialist referral may improve outcomes among neonatal AKI survivors, ensuring appropriate future monitoring and long term follow up.

445 **KLINEFELTER SYNDROME, TETRALOGY OF FALLOT, BILATERAL ANOTIA, CLEFT LIP AND PALATE: A NOVEL CONSTELLATION OF FINDINGS**

T Wang*, J Philips. *University of Alabama at Birmingham, Birmingham, AL*

10.1136/jim-2017-000697.445

Introduction Klinefelter syndrome (KS) is one of the most common sexual chromosome abnormalities leading to primary hypogonadism. However other than secondary sexual physical findings, KS is rarely associated with congenital heart disease or other congenital anomalies. To the authors' knowledge, this is the first case report of major cardiac and ENT anomalies in a patient with KS.

Case presentation The patient was a full-term infant born by C-section at our hospital due to prenatal findings concerning for Tetralogy of Fallot (TOF). Prenatal workup also included cell-free DNA concerning for KS. At delivery, the patient was noted to have bilateral anotia with cleft lip and palate but stable on room air. Upon arrival in NICU, the patient had an echocardiogram that confirmed TOF with moderate valvular stenosis and moderate main pulmonary artery atresia. Genetics was consulted and recommended a head CT, CGH array, and chromosome analysis. Results confirmed KS but without any other microdeletions or duplications. Head CT showed absent external auditory canals but intact inner ear structures. The patient's hospital course became complicated by congenital hypothyroidism (thyroid US showing small midline thyroid tissue), feeding difficulties (requiring gastrostomy tube placement), and TOF correction surgery. The patient was later discharged home with stable medical management. At the time of discharge, the patient's exact diagnosis remains unknown and pending the results of whole exome sequencing.

Discussion This is the fourth case report for a patient with KS and associated TOF. However, there are no reports of associated ENT anomalies in conjunction with congenital heart disease and KS. Although the patient's cleft lip and palate could be secondary to hemifacial microsomia, the patient's novel constellation of findings point in the direction of a currently unknown genetic disorder. Given this suspicion, a broad workup with a multidisciplinary team is needed for proper workup and management.

Conclusion A wide differential remains for this patient with these multiple congenital anomalies. Workup remains pending for this likely genetic disorder.

446 **DISCORDANT CONGENITAL CUTANEOUS CANDIDIASIS IN PRETERM TWINS: A CASE SERIES**

M Khawaja, P Ward*, R Jester, S Fowler, L Wine Lee. *Medical University of South Carolina, Charleston, SC*

10.1136/jim-2017-000697.446

Case report Preterm dichorionic/diamniotic twins were born at 25 5/7 weeks gestation via cesarean section secondary to transverse presentation of Twin B and preterm premature rupture of membranes (PPROM) in Twin B, 2 days prior to delivery. On day of life 5, Twin B developed generalized erythema and desquamation which progressed by day of life 8 to include the trunk, buttocks, perineum and arms, accompanied by acute respiratory failure. There were superficial erosions and maceration in the axillae and groin folds. Pediatric dermatology conducted potassium hydroxide skin scrapings which were positive for yeast and pseudohyphae and blood culture was positive for *Candida albicans*; she was diagnosed with invasive fungal dermatitis. Twin A was noted to have diffuse erythema and fine scale which was positive for yeast and pseudohyphae but blood culture was negative for yeast. Placental pathology for Twin B showed severe acute necrotizing

chorioamnionitis, panvasculitis and funisitis with a Grocott's methenamine silver stain was positive for pseudohyphae, whereas, Twin A only had mild acute chorioamnionitis and no pseudohyphae on silver staining. They were started on IV fluconazole, and completed 6 weeks (Twin B) and 3 weeks (Twin A) of therapy. Both twins had no recurrence of *Candida*, however, Twin B went on to develop erosive reticulated, supple scarring, a rare complication of congenital skin lesions.

Discussion Congenital cutaneous candidiasis (CCC) is an extremely rare disease. Prematurity/very low birth weight is the most significant risk factor for developing CCC. A severe sequelae, invasive fungal dermatitis, presents with widespread desquamating and/or erosive dermatitis leading to fungemia. This case demonstrates the clinical discordance between twins. We attributed this primarily to the PPROM of Twin B which illustrates the importance of intact membranes (amniotic sac) in protecting fetuses from ascending infections. Finally, when one twin is identified with CCC, it is prudent to assess the other twin, given they share the same degree of immaturity and *in utero* environment.

447

NEONATAL ABSTINENCE SYNDROME: A LOOK AT THE MATERNAL-INFANT DYADS AT THE MEDICAL UNIVERSITY OF SOUTH CAROLINA

¹P Ward*, ²S Fields, ³O Kaperka, ¹D Jenkins. ¹Medical University of South Carolina, Charleston, SC; ²Washington and Lee University, Lexington, VA; ³College of Charleston, Charleston, SC

10.1136/jim-2017-000697.447

Purpose of study Neonatal Abstinence Syndrome (NAS) is a withdrawal syndrome experienced by infants after *in utero* exposure to opioids. The NAS birth prevalence rate in South Carolina has increased from 0.9 to 3.9 per 1000 births from 2000 to 2013, respectively. To address this increase, our aims were to describe (i) maternal-infant dyad demographics and (ii) the associated therapeutic approaches for the management of NAS at a Regional Perinatal Center.

Methods used We performed a retrospective chart review using our local database at the Medical University of South Carolina (MUSC) to identify infants born between 02/2012–02/2017, at 35–42 weeks gestation and with a diagnosis of NAS or documented maternal drug use. Of the 111 dyads identified, 32 were excluded (9 with iatrogenic NAS and 23 were drug exposed but untreated).

Summary of results For the 79 maternal-infant dyads we found an average (SD) maternal age of 29 (5.6) years; 93% Caucasian, 4% African American, 3% Hispanic; 81% were Medicaid or self-pay and 49% of mothers had limited prenatal care (≤ 10 prenatal visits). Birth characteristics included: 56% vaginal deliveries; average (SD) gestational age at birth was 37.9 (1.2) weeks; average (SD) birth weight of 2930 (434) grams; 62% male infants and 83% were inborn at MUSC. At MUSC, the standard therapy for NAS treatment is morphine alone, however, clonidine was used as an adjunct in 25% of infants. The median (IQR) length of treatment was 16 (9.5–26) days with a median (IQR) hospital length of stay of 20 (13.5–30) days.

Conclusions Despite our NAS treatment protocol only recommending morphine therapy alone, clonidine was used as an adjunct in 25% of the infants. These data will serve as the basis for a comparative study looking at the infants treated

for NAS with morphine alone versus morphine plus clonidine. Additionally, we will compare these NAS treated infants to infants who were exposed to drugs *in utero* but did not require treatment for NAS to better understand why some infants do not require treatment for NAS. Furthermore, this will allow us to evaluate areas for quality improvement with the goal of refining overall care for these infants and reducing length of treatment and hospital length of stay.

Population health & precision medicine

Joint plenary poster session and reception

4:30 PM

Thursday, February 22, 2018

448

L1 EXPRESSION ANALYSIS IN INDUCED PLURIPOTENT STEM CELLS

T Kaul*, M Morales, P Deininger. Tulane Cancer Center, New Orleans, LA

10.1136/jim-2017-000697.448

Purpose of study Long interspersed element-1s (L1s) are autonomous, mobile elements that are able to copy and insert themselves throughout the genome with their own reverse transcriptase and endonuclease. These elements make up 17% of the human genome with over 500,000 copies, though the vast majority of these elements are defective and only a few dozen are potentially responsible for L1 activity. It is reported that there is increased retrotransposon activity in induced pluripotent stem cells (hiPSCs) and human embryonic stem cells (heESCs). hiPSCs hold the promise of broad application in the biomedical field including regenerative treatment. However, there is an increased risk of tumorigenesis when these reprogrammed cells are implanted. As L1 has the potential to contribute to tumor progression through insertional mutagenesis and increased genomic instability, we investigated its expression in hESCs and hiPSC.

Methods used To better understand the potential of L1-mediated mutagenesis in stem cells, it is imperative to first identify the few culprit L1s at specific loci that are actively transcribing to RNA. Our lab has developed a novel approach in detecting full length L1 expression by PacBio sequencing 5'RACE-selected full length L1 RNAs and mapping sequence results to the reference genome using our in-house bioinformatics pipeline.

Summary of results Here we provide proof of concept with the application of this novel method in characterizing full-length expressed L1s in 2 human cord blood derived endothelial cell lines (hCBEC), 1 fibroblast cell line (hFF), 3 hESC lines, and 8 iPSC lines. We characterized L1 expression patterns at the specific locus level in the four types of cell lines and saw an increase in L1 expression in hESC and iPSC cell lines.

Conclusions As there is an increase in L1 expression in induced pluripotent stem cells, there is greater potential for L1-mediated mutagenesis. This is important when considering induced pluripotent stem cells as potential therapy. Future directions will focus on identifying the functional impact of L1 retrotransposition in induced pluripotent stem cells.

449 OBSTETRIC OUTCOMES IN WOMEN WITH RHEUMATOID ARTHRITIS: RESULTS FROM NATIONWIDE INPATIENT SAMPLE DATABASE

S Kishore*, V Majithia. *University of Mississippi, Flowood, MS*

10.1136/jim-2017-000697.449

Purpose of study Fertility is reduced in patients with Rheumatoid Arthritis (RA) due to unknown cause. Few studies mostly have addressed pregnancy outcomes in RA. This study was undertaken to determine the frequency of complications occurring during pregnancy for women with RA and to compare these outcomes with the general obstetric population.

Methods used By using the 2003–2011 Nationwide Inpatient Sample database, we estimated the number of obstetric hospitalization, deliveries and caesarean deliveries in women between the age group 18–50 years. Then we compared maternal and pregnancy complications for all pregnancy-related admissions for women with and without RA. Multivariate logistic regression analysis was used to obtain adjusted odds ratio (OR).

Summary of results The total number of obstetric hospitalization was 42.32 million of which 31439 were women with diagnosis of RA. The maternal age of RA population was higher (30.5 years) than that in the control group (27 years) ($p < 0.001$). After adjusting for potential confounders, maternal RA population had a significantly higher prevalence of hypertensive diseases, premature rupture of membranes, antepartum hemorrhage, preterm delivery, intrauterine growth retardation and cesarean delivery. However, the prevalence of postpartum hemorrhage and the risk of inpatient mortality were not different between two groups. The frequencies of the above outcomes along with OR are provided in table 1.

Abstract 449 Table 1 Obstetric outcomes for pregnancy related hospitalizations

Variable	All patients	RA	No RA	OR	p-Value
No. of Patients	42317648	31439	42286209	NA	NA
Inpatient Mortality	9628	9	9619	NA	0.490
Hypertensive Diseases	3757992 (8.9%)	4230 (13.5%)	3753762 (8.9%)	1.157 (CI 1.112-1.204)	<0.001
PROM	1456334 (3.4%)	1688 (5.4%)	1454646 (3.4%)	1.548 (CI 1.474-1.628)	<0.001
Antepartum Hemorrhage	863232 (2%)	949 (3.0%)	862284 (2%)	1.229 (CI 1.152-1.312)	<0.001
Preterm Delivery	2798719 (6.6%)	3210 (10.2%)	2795509 (6.6%)	1.459 (CI 1.406-1.514)	<0.001
IUGR	774438 (1.8%)	1113 (3.5%)	773325 (1.8%)	1.931 (CI 1.819-2.051)	<0.001
Cesarean Delivery	11857999 (28%)	11002 (35%)	11846997 (28%)	1.167 (CI 1.139-1.195)	<0.001
Postpartum Hemorrhage	1106420 (2.6%)	750 (2.4%)	1105670 (2.6%)	NA	0.011

Abbreviations: RA = Rheumatoid Arthritis; PROM = Premature Rupture of Membranes; IUGR = Intrauterine Growth Retardation; OR = Odds Ratio (95% Confidence Interval (CI)); NA = Not Applicable

Conclusions Women with RA have a higher risk of adverse outcomes of pregnancy than without RA and thus close antenatal and post delivery monitoring need to be performed in order to reduce complications. The mean maternal age of RA population is higher likely secondary to infertility. Further studies are needed to examine these findings in relation to severity of disease, medication use and the presence of other comorbidities.

450 ASSESSING CONSENTERS ATTITUDES AND OPINIONS OF GENETIC BIOREPOSITORY RESEARCH IN CHILDREN

L Robinson*, E Ellison, R Rooney, C Brown, S Arnold. *University of Tennessee, Memphis, TN*

10.1136/jim-2017-000697.450

Purpose of study Genetic biorepositories are an invaluable resource for investigating the causative and mitigating factors of common and rare diseases. Maximum participation ensures broad applicability of study findings. We aimed to understand attitudes and opinions associated with participation in the Biorepository and Integrative Genomics (BIG) Initiative at Le Bonheur Children’s Hospital in Memphis, TN.

Methods used After families of inpatients watched a brief informational video and agreed or declined participation in the biorepository, we surveyed them about their backgrounds, prior research experience, and motivations for their decisions about participation in BIG. The collected data was analyzed to identify associations between family characteristics and participation, as well as to identify opinions that may be barriers to participation.

Summary of results Among the 333 (39% black, 58% white) families who completed surveys, 290 agreed and 43 declined to participate in BIG. Consenter characteristics associated with participation were: race (92% white vs 81% black, $p = 0.006$), education level (94% with some college or more vs 80% with only high school education, $p < 0.0001$) and prior participation in research (100% with prior participation vs 85% with no prior participation, $p = 0.001$). The most common reasons for participation were: helping the hospital (82%), lack of risk or inconvenience (47%) and desire to help others (46%). The most common reasons for declining to participate were: no personal benefit to participation (77%), concern about receiving unwanted information regarding risk for disease (42%), the child did not have a genetic disease (40%), concern about government or law enforcement obtaining information (40%) and concern that samples would be kept indefinitely (35%). Most (97%) survey participants were satisfied with the white, male physician presenting the study in the consent video.

Conclusions Our results show decision-making about consent for genetic research may be socially contextualized and more often based on preconception rather than the content of the information presented. This information will be used to improve patient education and better inform approaches to maximize participation in genetic research.

Pulmonary and critical care medicine
Joint plenary poster session and reception
4:30 PM
Thursday, February 22, 2018

451 MY BABY GAVE ME HYPOXEMIA

¹D Aponte*, ¹M Farinacci, ^{1,2}M Cruz, ^{1,2}K Rivera. ¹San Juan City Hospital, Caguas; ²San Juan City Hospital, San Juan, PR

10.1136/jim-2017-000697.451

Case report Intrapulmonary shunting of any degree can occur in pregnancy. Its manifestation can be overlooked as side effect of gestation. Analogous to hepato-pulmonary syndrome, intrapulmonary vascular dilatations (IPVDs) can cause intravascular shunting resulting in hypoxemia. Progesterone and estrogen have a direct influence on vasodilation triggered by engaging different pathways.

This is the case of 27 year old woman, G2P1C0A0, at 35 weeks of gestation with asthma, presents with shortness of breath and nonproductive cough without constitutional symptom of two months evolution, worsening. Symptom was overlooked as part of dyspnea of pregnancy since first pregnancy was uneventful. Physical exam showed cyanosis, tachypnea, tachycardia, clear to auscultation. Pulmonary function test (PFTs) and ABGs revealed hypoxemia and low DLCO. Peripheral oxygen saturation decreased to 84% with minimal exertion. EKG showed First Degree AV Block, Chest X-Ray, laboratories including rheumatologic, viral, cardiac enzymes came back normal. Imaging; echocardiogram, lower extremities venous doppler, Chest CT with IV contrast, pulmonary angiography came back negative for pulmonary embolism, pulmonary hypertension or arteriovenous malformation. Work up ruled out common etiologies of hypoxemia. No improvement with respiratory therapies and steroids. ABGs at 21% and 100% oxygen revealed shunt fraction of 17% suggestive of shunt. Echocardiography with bubble contrast positive at the fifth heartbeat, showing unspecified for pulmonary vs cardiovascular shunt. Labor was induced by 37 weeks, symptom persisted. Patient remained oxygen dependent. Cardiac MRI negative for cardiovascular anomalies. However, weeks passed, patient started to feel better. Hypoxemia started to improve and oxygen was no longer required. Repeated ABGs and PFTS normal, only remarkable for low but improved DLCO.

The importance is there's only two reported cases of hypoxemia developed during pregnancy with similar presentation suggestive of intrapulmonary shunting, after all common etiology have been ruled out. This mismatch may occur due reduced diffusion from IPVDs. Hypoxemia severity can be correlated to the degree of intravascular shunting, which in our case was directly related to female hormones during and after pregnancy.

452 THE EVALUATION AND MANAGEMENT OF PLASTIC BRONCHITIS

CE Atkinson*, R Katz. *University of Oklahoma, Oklahoma City, OK*

10.1136/jim-2017-000697.452

Introduction We present a case involving a child with a complex cardiac medical history requiring total anomalous pulmonary venous return repair, subtotal pulmonary ligation, bidirectional Glenn and Fontan procedure which was complicated by plastic bronchitis.

Case report Our patient is a 12-year-old male with history of heterotaxy syndrome with complete atrioventricular septal defect, double outlet right ventricle and total anomalous pulmonary venous return requiring total pulmonary venous return repair, subtotal pulmonary artery ligation, bidirectional Glenn procedure, and completion of fenestrated Fontan with catheter and device closure of fenestration. Six years after his last operation he presented with a two month history of productive cough with expectorant resembling white worms. Given his cardiac history and clinical presentation, plastic bronchitis was diagnosed. He was started on inhaled fluticasone and azithromycin. CXR showed evidence of opacification and volume loss within the right upper lobe. After interventional bronchoscopy, there was improvement in his symptoms and he was discharged home on nebulized albuterol.

In July 2017, he was admitted for nebulized albuterol and tissue plasminogen activator (tPA) every six hours along with vest therapy. Soon after starting nebulized therapy he reported an increase in cough productiveness. He was sent home with nebulized tPA, albuterol, and budesonide along with vest therapy. At his follow-up visit, he reported coughing up casts daily but coughing less frequently and had improvement in appetite. His oxygen saturations were 87–92% at home without oxygen supplementation. He was admitted to the Children's Hospital of Philadelphia in August 2017 for lymphatic occlusion for plastic bronchitis. The procedure involved occluding anomalous lymphatic channels, but the left thoracic duct was left intact in order to drain intestinal channels. Since his surgery, all respiratory treatment has been discontinued without significant cough or cast production.

Discussion This case demonstrates that nebulized tPA can have an immediate effect in patients with plastic bronchitis. In this case, the therapy provided a temporary bridge to definitive lymphatic surgery.

453 ACUTE RESPIRATORY FAILURE FOLLOWING SCORPION STINGS: ANAPHYLAXIS OR SEVERE SYSTEMIC ENVENOMATION?

PK Attaluri*, AC Castillo. *Texas Tech University Health Sciences Center, Lubbock, TX*

10.1136/jim-2017-000697.453

Introduction This is the case of a patient presenting with anaphylaxis after scorpion stings.

Case A 58-year-old woman presented to her local emergency room with difficulty breathing after being stung by a scorpion. She had labored breathing with retractions and was making grunting noises. She had a swollen tongue and throat, stridor, and diminished breath sounds; she had no skin rash. Her husband reported she was allergic to bee stings. Initial vital signs included blood pressure 160/93 mmHg, heart rate 95 beats per minute, respiratory rate 22 breaths per minute. Arterial blood gases included a pH 7.24, PaCO₂62 mmHg, and a PaO₂79 mmHg on a FiO₂100%. Oral intubation failed, and an emergency cricothyrotomy was done. She did not receive corticosteroids or scorpion antivenom. Vital signs after transfer to our hospital included blood pressure 89/63 mmHg, heart rate 90 beats per minute, and respiratory rate 16 breaths per minute. Her oxygen saturation was 96% on a FiO₂ of 45%. The patient received intramuscular epinephrine, norepinephrine, and methylprednisolone followed by prednisone throughout the hospitalization. She also received famotidine, diphenhydramine, and albuterol-ipratropium. A surgical tracheotomy was completed, and she required mechanical ventilation for 8 days. She did not develop pulmonary edema, acute kidney injury, or neurologic complications. The patient was eventually placed on a tracheostomy collar and discharged.

Discussion Scorpion venom contains numerous toxins that target ion channels found in mammals. These toxins can stimulate both sympathetic and parasympathetic autonomic centers and can lead to severe symptoms, such as myocardial injury and cardiogenic shock. The treatment of scorpion envenomation includes symptomatic measures, vital function support, and administration of antivenom. Anaphylaxis is possible if the patient is allergic to scorpion venom, or if the scorpion venom cross reacts with venoms from insects, such as bees

and ants, to which the patient is allergic. We think this patient had an acute anaphylactic reaction to scorpion venom resulting in upper airway obstruction. Patients who are allergic to insect venom should be aware of possible cross reactivity to venom from other species.

454 DERMATOMYOSITIS WITH A RARE LUNG DISEASE

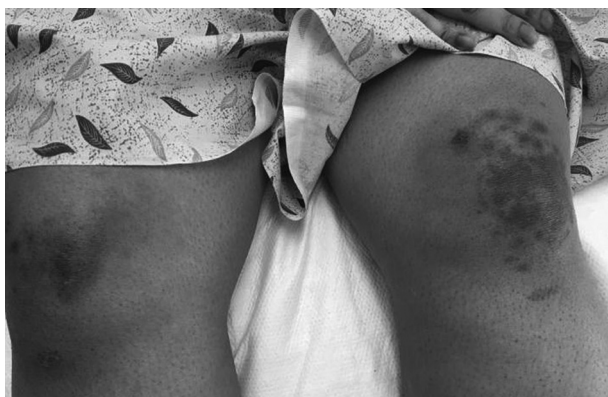CM Baldeo*, Hernandez M Morales, R Sharma, JM Hernandez, K Seegobin, C Monteiro. *UF College of Medicine, Jacksonville, FL*

10.1136/jim-2017-000697.454

Case A 30 y.o. female with amyopathic dermatomyositis presented with dyspnea, chest tightness and dry cough for weeks. She was tachypneic,afebrile, BP121/75 mmHg, pulse130 bpm, SaO₂ 86% on room air and 95% with 2 L O₂. Generalized non-tender hyperpigmented skin lesions were noted. CT chest showed diffuse ground glass opacities and bilateral hilar lymphadenopathy.Bronchoscopy with pathology showed candidal tracheobronchitis. This was treated with fluconazole. VATS biopsy pathology was consistent with pulmonary alveolar proteinosis (PAP). She was treated with Hydroxychloroquine and discharged on prednisone, home oxygen and Atovaquone for PJP prophylaxis,with plans to start azathioprine.Thiopurine methyltransferase (TMPT) activity was normal. Antibodies to MDA5 and TIF were positive. Antibodies against Granulocyte-macrophage colony-stimulating factor (GM-CSF) were pending.

Discussion PAP is an infrequently seen diffuse lung disorder characterized by the accumulation of amorphous, insoluble periodic acid-Schiff (PAS)-positive lipoproteinaceous material in the distal alveolar spaces,causing impairment of gas exchange leading to severe hypoxemia. It is rare with prevalence of 0.1 per 100,000 individuals. Whole lung lavage (WLL) has been the gold standard therapy in PAP until the advent of GM-CSF.

Conclusion The association of dermatomyositis and PAP is not clearly understood.However, correct diagnosis to distinguish ILD, which is more commonly found in dermatomyositis, from PAP is vital since management can prevent life threatening complications that occurred in our case.



Abstract 454 Figure 1 Picture of patient's characteristic rash of dermatomyositis

455 VASCULITIS PRESENTING AS DIFFUSE ALVEOLAR HEMORRHAGE

CM Baldeo*, K Seegobin, A Richardson, J Ruiz. *UF College of Medicine, Jacksonville, FL*

10.1136/jim-2017-000697.455

Introduction Microscopic polyangiitis (MPA) is an uncommon systemic vasculitis of varying severity.The most commonly affected organs are the lungs and kidneys.This is a case of MPA presenting with diffuse alveolar hemorrhage (DAH) and acute renal failure.

Case A 20 y.o female with history of vasculitis diagnosed 8 years earlier,off all medications for 1 year,presented with hemoptysis, dyspnea, pleuritic chest pain for 1 week. She was hypoxic with oxygen saturation (SaO₂) 80% on room air. Auscultation revealed bibasilar rales.Serum creatinine was elevated14.45 mg/dL,BUN of 95 mg/dL.WCC was normal.Hemoglobin was low at 5.5 g/dL,MCV 88fl.Chest x-ray and CT chest showed bilateral opacities.Azithromycin and ceftriaxone were started empirically.Bronchoscopy showed normal mucosa, pink to red secretions throughout left more than right.Bronchoalveolar lavage was negative.Autoimmune workup showed antibodies for ANA, ANCA/MPO,anti RNP, SSA.Complement levels were normal.ESR and CRP were elevated. Methylprednisolone was started. She became progressively hypoxic requiring intubation.She received 7 PLEX (plasma exchange) sessions and hemodialysis for oliguric AKI. Rituximab was started.She was successfully extubated and remained hemodynamically stable off oxygen.Hemodialysis was continued.

Discussion DAH is a rare but frequently life-threatening complication of AAV (ANCA-associated vasculitis).DAH results from injury to the alveolar capillaries, arterioles, and venules leading to red blood cell accumulation in the distal air spaces. The incidence of DAH is between 10–30% in MPA. DAH is an important cause of morbidity and mortality in ANCA-associated vasculitis,the mortality rate may reach 66%.The cornerstone of management of AAV-related DAH consists of remission induction with high-dose pulse methylprednisolone followed by daily oral glucocorticoids in combination with cyclophosphamide.However, rituximab has been recently introduced as an alternative to cyclophosphamide.For patients with respiratory failure and severe renal disease,PLEX has been advocated as an adjunct, even though its therapeutic efficacy is not well supported by the literature.

Conclusion Physicians need to be aware that microscopic polyangiitis can rarely present with diffuse alveolar hemorrhage and acute renal failure requiring dialysis.

456 A CASE OF RESPIRATORY BRONCHIOLITIS-ASSOCIATED INTERSTITIAL LUNG DISEASE

Z Bloomer*, S Burkett. *Eisenhower Army Medical Center, Fort Gordon, GA*

10.1136/jim-2017-000697.456

Introduction Respiratory bronchiolitis-associated interstitial lung disease (RB-ILD) is rare clinicopathologic syndrome found almost exclusively in active cigarette smokers. Unlike other smoking-related diseases, RB-ILD carries a good prognosis

with most patients improving with smoking cessation with or without corticosteroid treatment.

Case presentation A 40 year-old woman with an active, 30 pack-year history of cigarette smoking presented to the emergency department with one week of worsening cough and dyspnea. She denied fever, chills, rigors, hemoptysis, or pleurisy. She denied recent travel or unusual exposures. Vital signs were significant for tachypnea with pulse oximetry dropping to 83 percent breathing ambient air. Physical exam revealed diffuse fine inspiratory crackles without wheezing, jugular venous distention, or lower extremity edema. Computed tomography of the chest revealed diffuse, bilateral ground glass opacities and bronchial wall thickening. Pulmonary function testing revealed a moderate restrictive pattern with a mild decrease in the diffusion capacity of carbon monoxide (DLCO). Bronchoscopy with bronchoalveolar lavage revealed increased cellularity with pigment-laden macrophages comprising 100 percent of white blood cells. Special stains and cultures were negative for viral, bacterial, acid-fast, or fungal organisms. Her clinicoradiologic syndrome was most consistent with RB-ILD and a lung biopsy was not pursued. She received prednisone 40 mg daily for 7 days and was extensively counseled on smoking cessation. At one month follow up, she remained abstinent from smoking and demonstrated complete clinical, spirometric, and radiographic improvement.

Discussion Active cigarette smoking is a well-known cause of chronic obstructive pulmonary disease and lung carcinoma. Less commonly, tobacco smoke is associated with interstitial lung diseases, such as desquamative interstitial pneumonia (DIP), pulmonary Langerhans cell histiocytosis (LCH), acute eosinophilic pneumonia (AEP), and RB-ILD. This case highlights the clinicoradiologic features of RB-ILD which carries a good prognosis with smoking cessation.

457 A CASE OF CONGENITAL PULMONARY LYMPHANGIECTASIA IN A NEONATE

NN Dinh*, L Nuss, S Levine, J Patrick. *LSUHSC, New Orleans, LA*

10.1136/jim-2017-000697.457

Case report Congenital pulmonary lymphangiectasia (CPL) is a rare primary developmental defect of the lung that causes dilatation of the lymphatics and impaired drainage of lymph fluid in the lungs. It may present in utero with hydrops and pleural effusions. Neonates with CPL often develop severe respiratory distress and failure due to pleural effusions, pulmonary hypoplasia, and surfactant deficiency. Recent estimates show that approximately 1 in 1000 stillbirths or neonatal deaths may be due to CPL. It is ordinarily terminal, especially neonatal CPL that is limited to the lungs.

We present a case of a late pre-term male infant born to a mother with gestational hypertension. At delivery, he had no respiratory effort and required positive pressure ventilation and intubation. Empiric antibiotics and nitric oxide for persistent pulmonary hypertension were initiated. He failed a high frequency oscillator trial and multiple extubation attempts. Due to progressive cystic changes on chest radiographs and worsening clinical status, high resolution chest CT showed severe multilobar hyperinflation and emphysema with septal thickening and ground-glass opacities, large cysts and bronchiectasis. An open-lung biopsy showed mixed emphysematous

changes, alveolar simplification, large dilated pleural vessels, and over-distention of complex acini with marked cystic change, which were positive for D2-40, a lymphatic marker. These findings solidified the diagnosis of CPL. Due to the inability to wean off of mechanical ventilation, a tracheostomy was performed as a palliative measure to facilitate discharge home with the family. However, the infant remains on high ventilator support in the neonatal intensive care.

To evaluate for CPL, imaging modalities like CXR, chest CT or MRI, lymphoscintigraphy, and lung biopsy can be used. Treatment is supportive including tracheal intubation and assisted ventilation, maximizing nutritional support with total parenteral nutrition and use of medium-chain triglyceride formulas. The prognosis of CPL is dire, with few reported cases of patient survival. In these few cases, symptoms tend to improve with time if they can survive the neonatal stage and do not have other significant congenital malformations.

458 THE ASSOCIATION BETWEEN BODY MASS INDEX AND DRIVING PRESSURE IN PATIENTS WITH SEPSIS AND ACUTE RESPIRATORY FAILURE

H Edriss*, AA Sanchez, E Juarez Ramirez Tello, M Lear, S Yang, K Nugent. *Texas Tech University Health Science Center, Lubbock, TX*

10.1136/jim-2017-000697.458

Purpose of study A recent multicenter study reported that driving pressure (plateau pressure minus PEEP pressure) provides a good index of respiratory system mechanics and that increases in driving pressure are associated with increased mortality. This study considers the effect of obesity on driving pressure and the association between this pressures and outcomes in sepsis patients.

Methods used The medical records of patients hospitalized between 2010 and 2016 with sepsis who required mechanical ventilation (MV) were reviewed to collect demographic characteristics, clinical information including BMI, pressures required for MV, and outcomes including mortality and length of stay (LOS) in the ICU and in the hospital. Driving pressures were recorded 24 hours after the initiation of MV. This timeframe allowed clinicians to adjust the ventilator and to stabilize the patient.

Summary of results This study included 173 adult patients. The mean age was 58.5 ± 16.7 years; 53.2% were men. The mean BMI was 29.6 ± 11.9 . Pulmonary infections were present in 43.9%; 34.7% had extrapulmonary infections. The overall mortality was 44.5%. The mean LOS was 12.4 ± 11.8 days in the ICU and 16.6 ± 13.6 days in the hospital. The plateau pressure increased from 16.3 ± 4.3 cm of H₂O in underweight patients (BMI <18.5) to 21.3 ± 5.5 cm of H₂O in obese patients (BMI >30). The driving pressure increased from 10.5 ± 3.6 cm of H₂O in underweight patients (BMI <18.5) to 14.8 ± 5.9 cm of H₂O in obese patients (BMI >30). Increasing BMI was significantly associated with increased plateau and driving pressure. Higher pressures were associated with increased mortality in a multivariable analysis adjusted for age, gender, BMI, number of comorbid conditions, and APACHE 2 scores.

Conclusions These results demonstrate relationships among BMI, plateau and driving pressures, and mortality in patients with sepsis requiring MV. Increased driving pressures were associated with an increased risk for mortality. Prospective

studies are warranted to investigate the effect of reducing driving pressure on ICU survival, while taking into account of patient BMI.

459

ACUTE RESPIRATORY DISTRESS SYNDROME DUE TO CHRONIC BC POWDER USE- A RECURRENT MISS

¹H Edriss*, ¹A Shredi, ¹Nawaa SH El, ²B Williams. ¹Texas Tech University Health Science Center, Lubbock, TX; ²Covenant Medical Center, Lubbock, TX

10.1136/jim-2017-000697.459

Background The diagnosis of salicylate overdose, can be challenging due to the lack of an acute insult and the lack of clinicians' awareness that daily use of a relatively safe medication can cause acute pulmonary edema.

Case Summary A 58-year-old woman with history of SLE presented to the ED due to worsening agitation, confusion, and shortness of breath for 2 days. Vital signs: temperature 97°F, blood pressure 108/81 mmHg, heart rate 81 beats/min, respiratory rate 40 breaths/min, SpO₂ 89% on nonrebreather. Physical exam: disorientation to time, date and person, bilateral diffuse crackles. She was intubated for acute respiratory failure. Due to her complicated clinical picture and laboratory results, acute drug toxicity was suspected. Lab: white blood count 13 k/ μ L, sodium 152 mmol/L, potassium 4.3 mmol/L, chloride 102 mmol/L, CO₂ 21 mmol/L, AG 30, creatinine 1.7 mg/dl, salicylate 26 mg/dl (3–20), lactic acid 2.7 mmol/L. Arterial blood gases: pH 7.29, PCO₂ 45, PaO₂ 170 on FiO₂ 80%. Chest x-ray demonstrated diffuse bilateral infiltrates. The patient was managed with ventilation, a bicarbonate infusion, and hemodialysis. Her husband later reported that she had a toothache and had been taking more BC powder (8 packages/day) than usual (2–3 packages /day). He also reported that patient had similar episodes over the past year and that the most recent one was 3 months ago when she required intubation.

Discussion Non-cardiogenic pulmonary edema is more common in patients with long-term ingestion of salicylate than with an acute overdose. In the absence of clear cause for pulmonary edema, salicylates should be suspected as an etiology, especially in presence of an acid-base disorder. Salicylate concentrations should not be the primary method to determine treatment, as concentrations in chronic users may not be considered toxic. Early systemic alkalinization and hemodialysis are essential for treatment.

460

SEVERE REFRACTORY HYPOXEMIA, WHAT NOW?

Vilaro MA Farinacci*, Montano LO Gerena, K Rivera, D Aponte. San Juan City Hospital, San Juan

10.1136/jim-2017-000697.460

Case report Acute respiratory distress syndrome (ARDS) an acute, diffuse, inflammatory lung injury that leads to increased pulmonary capillary permeability and loss of aerated tissue. ARDS occurs within 6 to 72 hours of an inciting event and worsen rapidly. Patients presents with dyspnea, hypoxemia, diffuse crackles and bilateral alveolar patchy infiltrates. With an incidence of 86 per 100,000 person-years for a PaO₂/FiO₂ of <300 mmHg and an incidence of 64 per 100,000 person-year for a PaO₂/FiO₂ <200 mmHg. Treatment is most likely

with invasive mechanical ventilation, volume limited have been more studied and should be prompt to a lung protective ventilation.

36 yo morbidly obese man presents with 1 day of shortness of breath, cough, chills and green sputum production. Physical exam with decreased breath sounds, diffuse crackles, tachycardia and lower extremities edema. ABG's show hypoxemia, respiratory acidosis and oxygen saturation (SO₂) of 77.9% with a non-rebreathing mask, A-a gradient of 587.7 and PaO₂/FiO₂ of 49.2. CXR shows bilateral alveolar infiltrates. Chest CT showed extensive parenchymal consolidations. With severe ARDS secondary to pneumonic process patient was started on invasive mechanical ventilation. After extensive management, recruitment maneuvers with high PEEP/low FiO₂ table by ARDS net patient didn't reached goal saturation of 88%; patient was then started on airway pressure release ventilation (APRV) as a salvage therapy, with immediate improvement on oxygenation reaching SO₂ of >90%. Patient was extubated and discharged home.

ARDS is associated with high mortality, ranging from 26–56%, which increase with disease severity (PaO₂/FiO₂ <100 mmHg). APRV is a relatively new mode of ventilation described as CPAP with brief intermittent release in airway pressure resulting in alveolar ventilation and removal of CO₂, preventing ventilation associated lung injury decreasing shunting due to alveolar collapse maintaining a lower peak pressure and allow patient to perform spontaneous breathing during respiratory cycle. Physician should be aware of ARDS due to high incidence, mortality rate and the availability of another mode of ventilation as APRV that could improve patient oxygenation and be used as a salvage therapy

461

HYPERALDOSTERONISM AIDING THE DIAGNOSIS OF SMALL CELL LUNG CANCER

T Gilotra*, S Arikapudi, H Storer, D Pierce. East Tennessee State University, Johnson City, TN

10.1136/jim-2017-000697.461

Introduction Ectopic adrenocorticotrophic hormone (ACTH) production from small cell lung cancer (SCLC) cells resulting in paraneoplastic Cushing syndrome (CS) is a known phenomenon but only occurs in 1–5% of SCLC cases. Ectopic ACTH syndrome (EAS) usually lacks typical cushingoid features, presenting with findings suggesting hyperaldosteronism including hypokalemia, metabolic alkalosis, and resistant hypertension. These features result from cross-reactivity of excess cortisol on mineralocorticoid (MC) receptors with suppressed aldosterone levels. In this case, respiratory failure with concomitant findings of hyperaldosteronism lead to the diagnosis of SCLC.

Case presentation A 57-year-old smoker with uncontrolled hypertension, diabetes, chronic kidney disease was evaluated for on-going pneumonia with pleural effusion. Chest x-ray confirmed right lung consolidation with moderate pleural effusion. Hypertensive urgency and anasarca were also noted. Further work-up revealed severe hypokalemia, metabolic alkalosis, significant proteinuria, and hypoalbuminemia. Bumetanide was initiated and losartan was increased for nephrotic syndrome, yet hypokalemia worsened despite additional supplemental potassium. Elevated ACTH (175 pg/mL) and urinary cortisol (246 μ g/dL), diminished aldosterone levels (<1 ng/dL) and refractory hypokalemia suggested hyperaldosteronism and CS from EAS. Spironolactone improved blood pressure and

electrolytes. Pleural fluid analysis revealed an exudative effusion with atypical cells. PET CT-chest demonstrated a large hilar mass with mediastinal lymphadenopathy, right lower lobe lymphangitic carcinomatosis, and peritoneal carcinomatosis. Bronchoscopic pathology of lung mass confirmed SCLC. A least nephrotoxic platinum-based chemotherapy for metastatic SCLC was chosen over medical management of EAS alone. Unfortunately, the patient expired from complications of tumor lysis syndrome, neutropenic fever, and respiratory failure.

Discussion EAS results from ectopic secretion of ACTH by SCLC neuro-endocrine cells with consequent overproduction of cortisol, resulting in hyperaldosteronism from cross-reactivity on MC receptors. This case underscores the importance of ancillary findings of hyperaldosteronism from EAS, facilitating early diagnosis of SCLC.

462 A CASE OF RAPIDLY PROGRESSING RESPIRATORY FAILURE

C Horn*, SF Shah, P Staiano, V Seeram. *UF-COM, Jacksonville, FL*

10.1136/jim-2017-000697.462

Case report A 59 year old male with COPD presented to the ER with acute onset dyspnea. He was hypoxic, tachypneic, hypotensive, and tachycardic. He had wheezes and rhonchi and placed on full face BiPAP. He received antibiotics and steroids. A chest Xray showed bilateral pulmonary infiltrates. A CT chest showed nonspecific interstitial pneumonia and ground glass opacities. He was transitioned to high flow nasal canula. Autoimmune workup was negative except a positive ANA. Blood, urine, and respiratory cultures were negative. He became tachypneic with and was emergently intubated. Immediately after intubation became acutely hypotensive but resuscitated with fluids. One day later he again became acutely hypotensive again and required vasopressor support. A bronchoscopy was performed, which showed no organisms or malignant cells. Overnight he developed acute renal failure and severe acidosis. The patient suffered a PEA arrest and CPR was initiated. The patient was made DNR by his health-care surrogate and all heroic efforts were halted.

Acute interstitial pneumonia (AIP) goes by many names and is considered a subtype of interstitial pneumonia. It is rapidly progressing and presents with rapid onset, most often in healthy adults older than forty years old. Tissue microscopy is used to diagnose AIP, showing interstitial fibroblast proliferation with a thickened stroma and collapse of the alveoli. The pathological process is split into two phases: exudative and organizing phase. The clinical manifestations of AIP most often presents as a nonproductive cough for one to two weeks prior to presentation followed by rapidly progressive dyspnea leading to intubation. The diagnosis of AIP is obtained by a high resolution CT showing ground glass opacities, consolidation and traction bronchiectasis, bronchoscopy to exclude other diseases. Treatment for AIP is supportive care, oxygenation and intubation. Steroids and immunosuppressants have an unknown role in treatment, as small studies have had mixed results. The mortality rate of AIP is quite high, with the vast majority of patients deceased within three months.

463 TRIMETHOPRIM SULFAMETHOXAZOLE INDUCED LIVER FAILURE IN AN INFANT

I Justement*, A Shakir, S Palle, HC Allen, AK Gormley. *OUHSC, Oklahoma City, OK*

10.1136/jim-2017-000697.463

Case report Our patient is a 4 month old female with DiGeorge syndrome and Tetralogy of Fallot with absent pulmonary valve, hospitalized with respiratory failure secondary to viral bronchiolitis. She had a complicated course including right ventricle to pulmonary artery conduit. After cardiac surgery, she developed a sternal wound infection treated with broad spectrum antibiotics. Coverage was changed to trimethoprim sulfamethoxazole (TMP-SMX). Three days after starting TMP-SMX, she became coagulopathic, had increased total and conjugated bilirubin, and transaminases consistent with acute liver failure (ALF). TMP-SMX was discontinued after 4 days of therapy and liver function improved. She underwent complete evaluation for etiology of liver failure including biopsy. The work up was negative except for positive serum CMV PCR; however, specific CMV immunostains on the biopsy were negative. Liver biopsy demonstrated centrilobular hepatocellular necrosis, cholestasis and portal inflammation, consistent with drug-induced liver injury. Liver function gradually improved with supportive care.

Drug-induced liver injury (DILI) is an under recognized cause of liver injury and non-acetaminophen drugs have been shown to be the cause of around 5% of the cases of ALF in children. In the general population, TMP-SMX is amongst the top 5–10 causes of drug-induced, idiosyncratic fulminant liver failure. Liver injury appears to be caused by hypersensitivity to an antigenic metabolite of TMP-SMX with toxic and immunologic reaction to these metabolites. TMP-SMX induced liver injury can present in various forms: hepatocellular, hepatocellular and cholestatic, or Vanishing Bile Duct Syndrome. Our patient had mixed presentation with hepatocellular and cholestatic involvement. In general TMP-SMX liver injury occurs a few days after exposure but can present after 1–2 months of treatment. Management is primarily supportive after cessation of the offending agent. This case is unique in that this is the youngest patient with TMP-SMX induced liver failure reported in the literature and due to her DiGeorge syndrome the phenotype of immune dysfunction is similar to HIV infected patients, in whom liver injury with TMP-SMX is frequent.

464 HIV MODULATES PROSTANOID RECEPTOR EXPRESSION IN ALVEOLAR MACROPHAGES

¹EP Knott*, ^{1,2}SK Cribbs, ¹A Kukoyi, ¹X Fan, ^{1,2}D Guidot, ¹BS Staitieh. ¹Emory University, Atlanta, GA; ²Atlanta VAMC, Decatur, GA

10.1136/jim-2017-000697.464

Purpose of study Although the advent of anti-retroviral therapy has dramatically altered the course and prognosis of HIV infection, persons living with HIV (PLWH) continue to suffer from a wide range of complications, particularly bacterial pneumonia. Prior work from our group has demonstrated significant deficiencies in alveolar macrophage (AM) innate immune functions and antioxidant defenses. Recently, we have begun to focus on the prostaglandin E2 pathway, which has

been shown to have a key role in a wide range of innate immune functions through its action on the prostanoid receptors, particularly EP2 and EP4. In this study, we attempt to elucidate the effects of HIV and HIV-related viral proteins on prostanoid receptor expression in AMs.

Methods used Human monocyte-derived-macrophages (hMDM) obtained from volunteer subjects were infected with/without HIV *ex vivo* and taken for EP2 and EP4 gene expression analysis by qRT-PCR. AMs were obtained by whole lung lavage from an HIV transgenic rat model, which produces HIV-related viral proteins in the alveolar space but is not infectious. AMs were then plated and treated with gp-120 and Tat (two HIV-related viral proteins). Twenty-four hours later, samples were taken for EP2 and EP4 analysis by PCR and immunofluorescence.

Summary of results Gene expression of EP2 is increased and EP4 is decreased in HIV-infected hMDMs compared to uninfected controls from the same subject. Both gene and protein expression of EP4 were reduced in AMs obtained from HIV transgenic rats compared to their littermate controls, and EP2 levels were relatively unchanged.

Conclusions The modulation of prostanoid receptor expression in the setting of HIV suggests a fruitful new route of investigation into the innate immune defects seen in PLWH. The divergent expression profiles between the two models studied here raises the possibility that acute HIV infection of hMDMs may result in different effects than the chronic exposure to viral proteins modeled by the HIV transgenic rat. Further studies are needed to verify the consequences of these impairments, but these data nevertheless raise the intriguing possibility of new treatment options that may improve the lung health of PLWH.

465 WHEN AN IMMUNOCOMPETENT PATIENT NEEDS SURGERY FOR FUNGAL LUNG DISEASE

PP Kyaw*, S Milton. *Texas Tech Univ HSC Amarillo, Amarillo, TX*

10.1136/jim-2017-000697.465

Case report 42-year-old Asian man, a recent immigrant, PMH of extensive pulmonary TB 8–10 years prior to arrival in the United States. He received curative treatment prior to arrival. He presented to the hospital with recurrent hemoptysis for more than 2 days. He had a recent admission with similar complaints several months prior. He had been followed by the public health authorities and placed on 4 drugs therapy for presumed recurrent TB. Treatment had been stopped several weeks prior to this admission due to negative workup (sputum cultures).

SocHx -never smoked, no alcohol, no drugs. He works in a meat factory. Never been incarcerated. FH- insignificant. PE- Vitals were WNL, no apparent distress. Chest exam- decreased breath sounds on the right with scattered crackles. The remainder of exam was unrevealing. Lab work was unrevealing including CBC as well as blood cultures and sputum cultures and fungal serologies. Radiology findings showed a large right upper lobe cavitory mass in the posterior segment of the right lung that suggested a malignancy versus fungal infection.

Clinical course- Initially isolated with airborne precautions. He eventually underwent bronchoscopy and was found to have an endobronchial mass in the right upper lobe. Biopsy of this showed extensive fungal elements suggesting *Aspergillus* species. Thoracic surgery evaluated him and successfully

resected the mass by performing a right upper lobe wedge resection. He received voriconazole 200 mg twice daily and was discharged within a short period of time. Follow-up CT 2 months later showed significant improvement and no clinical evidence of active infection.

Discussion Hemoptysis is a common way in which aspergillosis can present in an immunocompetent individual. Recurrent hemoptysis can be problematic and occasionally lead to severe bleeding complications. Bronchoscopy, if feasible, is very useful in making the diagnosis. Patients presenting in this manner should undergo prompt surgical evaluation. Medical therapy is of uncertain value. Effective antifungal therapy such as voriconazole can be useful in cases where persistent infection is suspected. Pertinent lab work such as sed rate and CRP and chest x-ray is important in patients who receive longer courses of antifungal therapy. Differential diagnosis should include recurrent TB and tumor.

466 THE ASSOCIATION BETWEEN BODY MASS INDEX AND AIRWAY PRESSURES IN PATIENTS WITH SEPSIS AND ACUTE RESPIRATORY FAILURE

M Lear*, H Edriss, AA Sanchez, Ramirez Tello E Juarez, S Yang, K Nugent. *Texas Tech University Health Sciences Center, Lubbock, TX*

10.1136/jim-2017-000697.466

Purpose of study Patients with increased body mass indices (BMI) have excessive adipose tissue in the thoracic wall and in the abdomen. This reduces chest wall compliance and creates worse gas exchange secondary to abnormal ventilation/perfusion relationships in the lung bases. This study considers the effect of obesity on the pressures required for mechanical ventilation in patients with sepsis and acute respiratory failure.

Methods used The electronic medical records of patients hospitalized between 2010 and 2016 with sepsis who required mechanical ventilation were reviewed to collect demographic characteristics, clinical information including BMI, pressures required for mechanical ventilation, management requirements, and outcomes including mortality and length of stay in the ICU and in the hospital. Peak pressures and plateau pressures were recorded 24 hours after admission to the medical intensive care unit and the initiation of mechanical ventilation. This timeframe allowed clinicians to adjust the ventilator and to stabilize the patient.

Summary of results This study included 173 adult patients. The mean age was 58.5 ± 16.7 years; 53.2% were men. The mean BMI was 29.6 ± 11.9 . The mean white blood count was 14.3 ± 8.0 k/ μ L, 43.9 % of the patients had pulmonary infections, and 34.7% had extrapulmonary infections. The overall mortality was 44.5%. The mean length of stay was 12.4 ± 11.8 days in the ICU and 16.6 ± 13.6 days in the hospital. The mean peak pressure on day one of mechanical ventilation increased from 19.5 ± 5.1 cm H₂O in underweight patients (BMI < 18.8) to 26.0 ± 8.0 cm H₂O in patients in the obese category (BMI > 30). The mean plateau pressure on day 1 of mechanical ventilation increased from 16.3 ± 4.3 cm H₂O in underweight patients to 21.3 ± 5.5 cm H₂O in obese patients. There is a significant increase in plateau pressure across BMI categories.

Conclusions These results indicate that patients with increased BMI require higher average ventilator pressures to maintain adequate gas exchange. This likely reflects reduced chest wall compliance. This result also suggests that trans-pulmonary pressures are less certain in these patients.

467 AN UNUSUAL OCCURRENCE OF CHYLOTHORAX IN SVC SYNDROME

W Li*, B Madhira. *SUNY Upstate Medical University, Syracuse, NY*

10.1136/jim-2017-000697.467

Introduction Chylous pleural effusion is a collection of chyle in the pleural cavity from accumulation of lymphatic vessel leakage. A condition with multiple etiologies, SVC syndrome related chylothorax is a rare occurrence.

Case Our patient was a 47 year-old male correctional facility resident with a history of COPD and NSCLC presenting with SVC syndrome and left brachiocephalic vein and IVC thrombosis with tumor extension to the right para-tracheal region. With management including therapeutic enoxaparin, chemotherapy and radiation, he developed hemoptysis secondary to radiation induced esophagitis. Vital signs were significant for tachycardia 114 beats/min with blood work revealed hemoglobin of 9.6 g/dL and hematocrit of 28.8% though results one month prior were 12.2 g/dL and 36.5% respective. Because of abdominal discomfort, a CT was performed which revealed incidental pleural effusion confirmed with CTA also to rule out PE. Three thoracenteses were completed for effusion reaccumulation and diagnostic purposes. Lab findings were consistent with exudative effusion (fluid LDH 114 U/L, fluid total protein 2.9 g/dL, serum LDH 224 U/L and serum total protein 5.7 g/dL) with similar findings subsequently. Because of chylomicrons on lipoprotein electrophoresis, elevated triglyceride level 277 mg/dL, cholesterol level <50 mg/dL, negative cultures and no malignant cells on cytology, the effusion was deemed to be chylous secondary to SVC syndrome.

Discussion Chylothorax associated with SVC syndrome is a rare occurrence though it has been reported in pediatrics. To our knowledge only one case of SVC syndrome associated with chylothorax has been reported. The causative mechanism was related to compression of the thoracic duct leading to elevated pressure and rupture or SVC obstruction leading to back pressure on the thoracic duct causing leakage into the pleural space. Chylothorax from non-traumatic etiologies are mostly treated with conservative measures though continuous drainage catheter placement becomes the management of choice in those with high-volumes or who are symptomatic. Other more invasive strategies include thoracic duct ligation, talc pleurodesis, and fluoroscopic percutaneous embolisation.

REFERENCE

1. Talwar A, Lee H. A contemporary review of chylothorax. *Indian J Chest Dis Allied Sci* 2008;**50**:343–351.

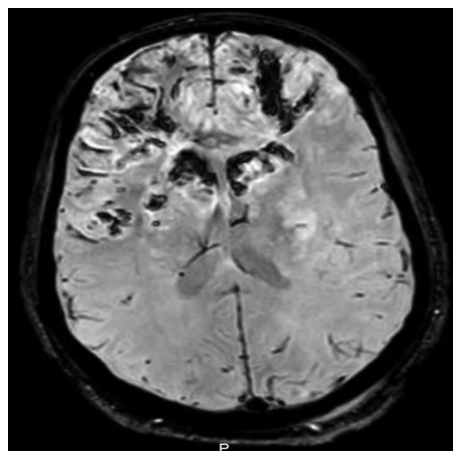
468 MOYAMOYA DISGUISED AS MULTIPLE SCLEROSIS EXACERBATION

S McClelland*, D Nodurft, P Gurram, M Joshi. *University of Arkansas for Medical Sciences, Little Rock, AR*

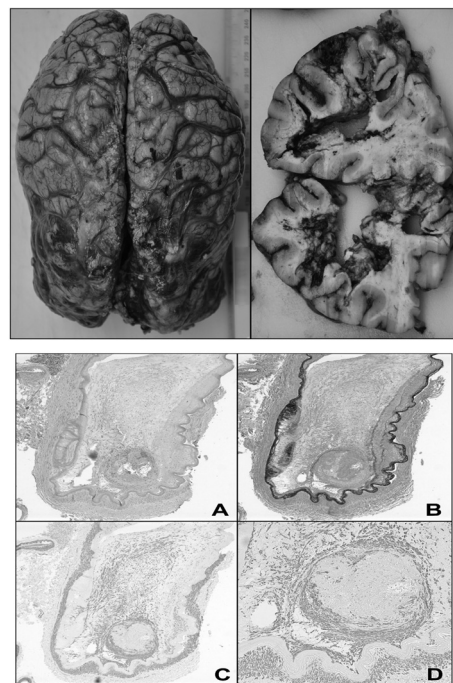
10.1136/jim-2017-000697.468

Case report A 29-year-old African American Man with tumefactive multiple sclerosis (MS) and diabetes presented from an outside hospital for new MS lesions seen on imaging. Patient was started on solumedrol and sent to UAMS for plasma

exchange; however, patient became obtunded and febrile and was transferred to the ICU. An MRI showed small infarcts in the frontal lobes, basal ganglia, and internal carotid arteries (ICA). MRA showed severe reversible cerebral vasoconstriction with occlusion and narrowing of the supraclinoid ICA. Work-up for vasculitis and infection were negative. Repeat imaging showed worsening MS lesions and small infarcts. Patient continued to decline and nimodipine was started to avoid hypotension. Patient's family opted for comfort care measures given the overall poor prognosis. Autopsy revealed sickle cell trait and cause of death was complications from Moyamoya.



Abstract 468 Figure 1 Extensive areas of infarcts in the frontal lobes, basal ganglia, and bilateral ICA



Abstract 468 Figure 2 Left image: brain at autopsy. Right image: histologic sections of the left MCA shows thrombus in the narrow lumen (A, H&E stain) and concentric thickening of the intima (B, Verhoeff-van Gieson stain). The intimal thickening is demonstrated to be proliferation of smooth muscle cells (C&D)

469 MALPLACEMENT OF NUSS BAR INTO RIGHT VENTRICLE

FC Moore*, D Harris, A Ramage, D Dwight. *Eisenhower Army Medical Center, Evans, GA*

10.1136/jim-2017-000697.469

Case report 26 year old active duty sailor presents to the ER with three weeks of nausea, vomiting, and 10 lb weight loss. On exam he was in acute distress, had a mass in his right mid-axillary line and a new 6/6 blowing holosystolic murmur. EKG demonstrated sinus tachycardia, right axis deviation, poor R-wave progression, T-wave inversions in the ant precordial leads, and RSR' in V1. CXR demonstrated presence of an opaque object across the right lower lung field: one end near the right ventricle, the other end protruding between the ribs in his right chest. Further questioning indicated the patient underwent Ravitch procedure at an outside facility 6 months prior for pectus excavatum, and this object was the stabilizing Nuss bar. CT angiography demonstrated bilateral pulmonary emboli and presence of the bar in the right ventricle. Emergent TTE was performed and the echocardiogram definitively proved the bar had come through the right ventricular free wall, caused a ventricular septal defect, and was sitting in the right ventricle. There was a small pericardial effusion, but no evidence of tamponade. CT surgery was consulted and the patient was taken for emergent open-heart surgery with peripheral cardiopulmonary bypass. The bar was removed and his VSD and RV free wall were successfully repaired. Post-op course was complicated by decreasing hgb, inappropriately responding to blood-product transfusion. Patient required a second open-heart surgery to repair a laceration of the internal thoracic artery causing bilateral hemothorax. Small pneumothorax was appreciated on follow-up CXR with removal of pleural drains, the patient remained asymptomatic. After 12 days in the ICU, the patient was discharged on full anticoagulation for provoked pulmonary emboli and expected to make a full recovery.

Conclusion Nuss bar malplacement is a known, though rare, complication following minimally invasive repair of pectus excavatum (MIRPE). Upon review of the literature, we have found one prior case report involving asymptomatic malplacement into the right ventricle. We suspect that our patient experienced an initial right ventricular free wall injury with creation of a VSD over time. This demonstrates an exceptionally rare complication following MIRPE.

470 ROHHAD SYNDROME

^{1,2}VH Nayak*^{1,2}AF Bowman, ^{1,2}JJ Burns. ¹University of Florida, Pensacola, FL; ²Sacred Heart Hospital, Pensacola, FL

10.1136/jim-2017-000697.470

Introduction ROHHAD syndrome is an acronym for rapid-onset obesity (RO) with hypothalamic dysregulation (H), hypoventilation (H), and autonomic dysregulation (AD). It's a rare life threatening syndrome with a mortality rate of 50 to 60%, often due to cardio-resp arrest.

Case 5 year old male with history of cough and congestion for 2 days was admitted to PICU with respiratory failure. Mother noted that she woke up to gurgling sounds made by the child and found him to be unresponsive and cyanotic. Mom denied any history of fever or headache or seizures in the past. His review of systems was positive for throat pain,

intermittent acro-cyanosis, intermittent temperature changes of his extremities and 28-pound weight gain over the past 2 years. His past medical history was significant for an admission to PICU at 4 years of age for cardio-respiratory failure secondary to choking on hotdog, and, unexplained hypernatremia.

His initial labs were as follows- blood gas showed respiratory acidosis (ph-7.255, pco2-75, po2-65), CBC was unremarkable, RPP was positive for Rhino/enterovirus, UDS - negative, CT head - normal, CSF studies were normal, chest x ray was normal, blood culture, urine culture and CSF culture were negative. HSV and enterovirus CSF PCR was negative. EEG was normal. Serum sodium was 136 at admission but rest of his metabolic panel during the stay had hypernatremia. He was initially started on Rocphin, but was stopped after 2 days of negative cultures.

He was extubated to BiPAP on D4 of hospitalization, after one failed attempt. He continued to require high BiPAP settings, which was gradually weaned during the course of hospitalization. He was noted to be hypotonic throughout the admission, had signs of autonomic lability in the form of intermittent tachycardia with cooling of extremities and hyperalgesia of his feet. Further investigations showed growth hormone deficiency (IGF1 - 25 ng/ml (IGFBP- 1640 ng/ml (1843-4968)) and hyperprolactinemia (prolactin - 43.9 ng/ml (2.64-13.3)).

Based on the above findings, clinical diagnosis of ROHHAD syndrome was made.

Conclusion The diagnosis of ROHHAD syndrome can be extremely challenging as there is no single confirmatory diagnostic test, but early recognition and intervention of this syndrome may minimize mortality and morbidity.

471 MONITORING CENTRAL VENOUS PRESSURE AND ITS RELATIONSHIP IN ACHIEVING INITIAL THERAPEUTIC END POINTS IN PEDIATRIC PATIENTS WITH SEPTIC SHOCK

S Nye*, B Palmer, P MacLennan, L Hayes. *University of Alabama at Birmingham, Birmingham, AL*

10.1136/jim-2017-000697.471

Purpose of study Pediatric septic shock is a major cause of morbidity and mortality worldwide. Early goal-directed therapy (EGDT) has been the mainstay for sepsis management for many years, but recent studies suggest EGDT may not lead to improved outcomes. One component of EGDT includes the use of central venous pressure (CVP) monitoring to guide fluid resuscitation in patients with septic shock. Adult recommendations target a goal CVP of 8-12 mmHg achieved within the first six hours of management, but this recommendation is not provided for children. Due to the invasive nature of obtaining a CVP in children, we sought to better understand the need for CVP in the management in pediatric septic shock.

Methods used We performed a retrospective, single-center cohort study to evaluate the monitoring of CVP in pediatric septic shock and its association with meeting other therapeutic end points, including normal blood pressure and heart rate for age, urine output >1 ml/kg/hr, and mixed venous oxygen saturation >70%. We hypothesize that patients with a CVP obtained within the first six hours after admission to the

intensive care unit (ICU) have a decrease in time to achieve the outlined therapeutic end points, compared to patients with a CVP obtained >6 hours after ICU admission and patients with no CVP obtained.

Summary of results A total of 213 patients admitted with the diagnosis of sepsis were reviewed, and 117 patients met inclusion criteria (need for more than 60 ml/kg of fluid resuscitation or pressors within the first six hours of ICU admission). A CVP was obtained in 42 (36%) patients within six hours of admission, while a CVP was obtained in 45 (38%) patients more than 6 hours after admission, and no CVP was obtained in 30 (26%) patients. Complete analysis relating to CVP and therapeutic end points is currently in process and results will be available at time of the conference.

Conclusions The majority of studies regarding the use of CVP come from adult studies. This is the first study that we know of evaluating the relationship of obtaining a CVP and time to achieve other therapeutic targets in pediatric patients with septic shock.

472 MONITORING CENTRAL VENOUS PRESSURE AND ITS RELATIONSHIP TO THE DEVELOPMENT OF FLUID OVERLOAD IN PEDIATRIC PATIENTS WITH SEPTIC SHOCK

S Nye*, B Palmer, P MacLennan, L Hayes. *University of Alabama, Birmingham, AL*

10.1136/jim-2017-000697.472

Purpose of study Pediatric septic shock continues to be a major cause of morbidity and mortality worldwide. Early goal-directed therapy (EGDT) has been the mainstay for sepsis management for many years. However, recent studies suggest EGDT may not lead to improved outcomes. One component of EGDT includes the use of central venous pressure (CVP) monitoring to guide fluid resuscitation in patients with septic shock. Adult recommendations target a goal CVP of 8–12 mmHg achieved within the first six hours of management, but this recommendation is not provided for children. Due to the invasive nature of obtaining a CVP in children, we sought to better understand the need for CVP in the management in pediatric septic shock.

Methods used We performed a retrospective, single-center cohort study to evaluate the monitoring of CVP in pediatric septic shock and its association with the development of fluid overload. We hypothesize that patients with a CVP obtained within the first six hours after admission to the intensive care unit (ICU) will have less fluid overload at 24, 48, and 72 hours after admission compared to patients with a CVP obtained >6 hours after ICU admission and patients with no CVP obtained.

Summary of results A total of 213 patients admitted with the diagnosis of sepsis were reviewed, and 117 patients met inclusion criteria (need for more than 60 ml/kg of fluid resuscitation or pressors within the first six hours of ICU admission). A CVP was obtained in 42 (36%) patients within six hours of admission, while a CVP was obtained in 45 (38%) patients more than 6 hours after admission, and no CVP was obtained in 30 (26%) patients. Complete analysis relating to CVP and fluid overload is currently in process and results will be

available at time of the conference. In addition, groups will be compared in relation to mortality, PICU length of stay (LOS), hospital LOS, duration of mechanical ventilation, lactate level, and need of pressors.

Conclusions The majority of studies regarding the use of CVP come from adult studies. This is the first study that we know of evaluating the relationship of obtaining a CVP and fluid overload in pediatric patients with septic shock.

473 TNF α EFFECTS ON MIR-181A AND MIR-1 IN HUMAN ALVEOLAR EPITHELIAL CELLS

M Pacurari*. *Jackson State University, Jackson, MS*

10.1136/jim-2017-000697.473

Purpose of study Inflammation is the underlying mechanism of many lung pathologies including acute lung injury (ALI). TNF α , a pro-inflammatory cytokine released during ALI, initiates a cascade of signaling pathways. ALI has a high morbidity and mortality rates. MicroRNAs (miRs) are short strands of RNAs that regulate gene expression thus mediating signaling in disease development. Studies have shown that miR-181a regulates inflammatory responses whereas miR-1 acts as a tumor suppressor. To further identify miRs mediated signaling in ALI, we used bioinformatics tools and identified Notch 2 a potential target for miR-181a and miR-1. Notch 2 is a member of the evolutionary conserved Notch family of receptors that regulate cell fate determination and differentiation during lung development and injury. In the present study, we investigated whether TNF α regulates miR-181a and miR-1 and identified target Notch 2 in human alveolar epithelial cells.

Methods used Using A549, the regulation of miR-181a and miR-1 by TNF α and Notch 2 were analyzed using qPCR, western blot, and IHC. A549 cells were exposed to TNF α (1 or 10 ng/ml) for 6 or 24 h. Total RNA was extracted using TRIzol. miR cDNA and cDNA were generated and analyzed by qPCR. Western blot and IHC were performed using specific antibodies.

Summary of results Low concentration of TNF α and short exposure (6 h) slightly decreased miR-181a (0.86- vs 1.0-fold change control). After 24 h, TNF α at low concentration inhibited miR-181a (0.27- vs 1.0-fold change). High concentration of TNF α and short exposure, increased miR-181a (1.86- vs 1.0-fold change). After 24 h, high dose of TNF α had no effect on miR-181a. After 24 h, TNF α potentially increased Notch 2, regardless of dose (4.75 and 35.15-fold change vs control). Notch 2 localized at cell periphery following stimulation with TNF α 24 h. Transfection assays showed decreased Notch 2 level by miR-181a mimic. Ectopic miR-1 181a had no effect on cell morphology whereas inhibition of miR-181a induced cell morphology changes including cell rounding and less cell-cell contact compared to control.

Conclusions These results suggest that TNF α temporally and differentially regulates miR-181a and miR-1 and Notch 2, thus influencing inflammation-mediated signaling in lung injury. These data also suggest that miR-181a may represent a pharmacological target in inflammation mediated-lung injury.

474 ABSTRACT WITHDRAWN

475 OBSTRUCTIVE SLEEP APNEA AND UNCORRECTED ATRIAL SEPTAL DEFECT PROGRESSING TO EISENMENGER SYNDROME

J Ruiz*, JA Carlson, C Horn. *UF Health Jacksonville, Jacksonville, FL*

10.1136/jim-2017-000697.475

Case report A 22 y/o female patient with significant medical history of Down Syndrome, Obstructive Sleep Apnea (OSA) and non-compliance with CPAP, Hypothyroidism and history of PDA closure at young age who was hospitalized due to worsening dyspnea two days post-mastoidectomy. Associated symptoms severe edema of the lower extremities and weight gain. Chest imaging pertinent for cardiomegaly and pulmonary edema. Pro-BNP was elevated at 4225. Patient was placed on non-invasive ventilation and diuresis with good response to in lower extremity edema, but continuous hypoxia. Physical exam significant for systolic murmur around the third intercostal space and severe lower extremity edema. Transthoracic echocardiogram (TTE) with bubble study demonstrated ejection fraction of 50–55% with right ventricle systolic pressure of 57 mmHg with severe right ventricular enlargement and interatrial shunt consistent with newly developed atrial septal defect (ASD). Patient underwent right and left heart catheterization which showed moderate pulmonary arterial hypertension (PAH) and right to left interatrial shunt leading to Eisenmenger phenomenon. Surgical intervention and closure of ASD was not performed because of increased risk of mortality due to right heart failure. Patient was subsequently treated in the intensive care unit with Treprostinil, an analog of prostacyclin for PAH with good clinical response and improvement of hypoxia. Counseling made for strict adherence to medication, weight loss, CPAP and close follow up as an outpatient to monitor symptoms.

Discussion Eisenmenger syndrome is a reversal of pressure gradients from the normally elevated left side to right to left side across a shunt. Uncorrected ASD may lead to pulmonary hypertension and right sided heart failure. As in this case, the compounding effect was the group I PAH secondary to obstructive sleep apnea and non-compliance with the CPAP machine, leading to accelerated progression to Eisenmenger syndrome. Individuals should be treated with diuretics, vasodilators, and supplemental oxygenation with concentration on modifiable risk factors for worsening heart failure and hypoxia. A right heart catheterization must be completed to evaluate for reversibility of pulmonary pressures with vasodilator challenge prior to surgical intervention.

476 NEUTROPHIL ELASTASE BIND TO NEUTROPHIL DERIVED EXOSOMES IN A PASSIVE, CHARGE-MEDIATED FASHION

DW Russell*, K Genschmer, J Blalock. *University of Alabama at Birmingham, Hoover, AL*

10.1136/jim-2017-000697.476

Purpose of study After activation with the neutrophil (PMN) stimulator formyl-methionine-leucine-phenylalanine (fMLP), PMNs are known to secrete exosomes with enzymatically active neutrophil elastase (NE), whereas quiescent PMNs secrete exosomes of similar quantity and size but with

markedly reduced NE activity. Exosomal NE is resistant to the antiprotease A1AT. However, the mechanism by which activated PMNs load NE onto secreted exosomes is unknown.

We hypothesize that NE is not secreted with exosomes but rather binds PMN exosomes passively upon activation and concurrent degranulation.

Methods used PMNs were exposed to either quiescent conditions or stimulation with fMLP; exosomes were then purified by ultracentrifugation and counted by nanotracking analysis. NE activity of these exosomes was measured colorimetrically using the substrate MeOSucc AAPV-Pna. Exosomes from activated PMNs were incubated with positively charged compounds protamine and lysine, the neutral amino acid proline, or PBS control in the presence or absence of A1AT, reisolated by ultracentrifugation, and NE activity was measured. The supernatant of each condition was also measured for levels of the A1AT/NE complex by ELISA.

Summary of results NE activity of activated PMN derived exosomes was diminished by coincubation with A1AT in combination with protamine and lysine, but not proline. A1AT resistant NE activity of quiescent PMN derived exosomes was produced after coincubation with nascent recombinant human NE. This NE activity could then be reduced again by incubation with A1AT in combination with protamine and lysine, but not proline.

Conclusions Activated PMN-derived exosomes are similar in number and size to quiescent PMN-derived exosomes but have increased NE activity. Activated PMN-derived exosomes lose their affiliation with NE in the presence of highly positive charge. Quiescent PMNs secrete NE-poor exosomes but these exosomes are capable of passively binding NE via an apparently similar mechanism. Collectively these results suggest that NE loading onto exosomes is passive and charge-mediated. Further research to identify the putative receptor is merited to explore this novel mechanism of protease secretion.

477 THE ASSOCIATION BETWEEN BODY MASS INDEX AND GAS EXCHANGE IN PATIENTS WITH SEPSIS AND ACUTE RESPIRATORY FAILURE

AA Sanchez*, H Edriss, Ramirez Tello E Juarez, M Lear, S Yang, K Nugent. *TTUHSC, Lubbock, TX*

10.1136/jim-2017-000697.477

Purpose of study Obese patients with reduced chest wall compliance usually have reduced trans-pulmonary pressures, especially at the lung bases, during mechanical ventilation. This likely reduces regional lung volumes during mechanical ventilation and creates more abnormal ventilation/perfusion relationships. This study considers the effect of body mass index (BMI) on gas exchange measured by PaO₂/FiO₂ ratios and required PEEP levels during sepsis.

Methods used The electronic medical records of patients hospitalized between 2010 and 2016 with sepsis who required mechanical ventilation were reviewed to collect demographic characteristics, clinical information including BMI, pressures required for mechanical ventilation, management requirements, and outcomes including mortality and length of stay in the ICU and in the hospital. PEEP pressures and PaO₂/FiO₂ were recorded 24 hours after admission to the medical intensive care unit and the initiation of mechanical ventilation. This

timeframe allowed clinicians to adjust the ventilator and to stabilize the patient.

Summary of results This study included 173 adult patients. The mean age was 58.5 ± 16.7 years; 53.2% were men. The mean BMI was 29.6 ± 11.9 . The mean white blood count was 14.3 ± 8.0 k/ μ L, 43.9 % of the patients had pulmonary infections, and 34.7% had extrapulmonary infections. The overall mortality was 44.5%. The mean length of stay was 12.4 ± 11.8 days in the ICU and 16.6 ± 13.6 days in the hospital. The mean PaO₂/FiO₂ ratio decreased from 251 ± 14 in the underweight patients (BMI <18.5) to 185 ± 11 in the obese patients (BMI >18.5). The mean PEEP level increased from 5.6 ± 1.3 cm H₂O in the underweight patients (BMI < 18.5) to 6.4 ± 2.6 cm H₂O in the obese patients (BMI >30). These trends in PaO₂/FiO₂ ratios PEEP levels across BMI categories were not statistically significant.

Conclusions These results suggest that gas exchange based on PaO₂/FiO₂ ratios is worse in obese patients with acute respiratory failure associated with sepsis, but these differences did not reach statistical significance. On average, obese patients do not require higher FiO₂s or PEEP levels to maintain adequate oxygenation.

478 ACUTE RESPIRATORY FAILURE AS AN INITIAL PRESENTATION OF SYSTEMIC LUPUS ERYTHEMATOSUS

¹P Sankhyan*, ²M Shukla, ¹A Mahajan, ¹C Cook. ¹East Tennessee State University, Johnson City, TN; ²Cooper University Hospital, Camden, NJ

10.1136/jim-2017-000697.478

Case report A 24 year old Asian male with no significant past medical history presented with a diffuse maculopapular rash, epistaxis and diffuse arthralgias. The hospital course was complicated by worsening hypoxia requiring intubation and mechanical ventilation, hypotensive shock requiring multiple blood transfusions and prolonged intensive care unit stay. The admission laboratory (lab) tests were notable for pancytopenia and transaminitis. An extensive infectious disease workup was negative. He was initially started on broad spectrum antimicrobials for neutropenic fever and atypical infections but he failed to respond. He was then started on empiric glucocorticoids based on the clinical presentation and low complements. The results of his auto-immune workup was strongly positive for Lupus. Bone marrow biopsy showed hypocellular marrow with no evidence of dysplasia or malignancy and unremarkable flow cytometry and cytogenetics. Skin biopsy results were consistent with the cutaneous involvement of lupus with necrotizing vasculitis. The patient was treated with mycophenolate & hydroxychloroquine in addition to prednisone, resulting in improvement of symptoms and resolution of pancytopenia.

Discussion Systemic Lupus Erythematosus (SLE or Lupus) primarily affects middle aged and young women with a slightly higher incidence in the Asian population. However, it has been observed that male gender is associated with higher disease activity at the time of diagnosis. A cohort study in 2016 found that there was a much higher chance of acute respiratory failure in men and women with SLE than their age matched non SLE cohort. SLE is known to increase the risk of respiratory disease including obstructive airway disease, pneumonia, pulmonary embolism, pleural effusion and diffuse alveolar hemorrhage. Indicators of poor prognosis include

male sex, younger age, renal disease, hypertension, antiphospholipid syndrome.

Conclusion In cases with fever or rash with pancytopenia with or without acute respiratory failure, undiagnosed autoimmune diseases like SLE must be suspected, even in individuals with no prior history or risk factors as in our patient.

479 METASTATIC LEIOMYOSARCOMA TO THE LUNGS

AJ Shah*, K Durwas, D Manta. State University of New York Upstate Medical Center, Syracuse, NY

10.1136/jim-2017-000697.479

Introduction Leiomyosarcoma is a soft tissue sarcoma derived from smooth muscles cells typically of the uterus. It is typically aggressive with 5-year survival of metastatic disease being 30%. In this case, we present an elderly female with leiomyosarcoma who developed worsening respiratory failure due to AV malformations (AVMs).

Case presentation We present a 71 year old female with past medical history significant for hypertension, hypothyroidism, hyperlipidemia, leiomyosarcoma involving lung for 18 years, and chronic hypoxic respiratory failure requiring 5 L O₂, who presented with worsening shortness of breath.

Chest x-ray showed extensive, multi-focal opacities consistent with widespread metastasis of leiomyosarcoma.

CTA thorax showed extensive tumor in her chest. Multiple AV malformations were noted within these tumors.

A shunt trial was performed with 100% FiO₂ on high flow nasal canula. PaO₂ was 51.

Patient was subsequently evaluated by interventional radiology who performed a pulmonary angiogram and coiled the largest right sided AVM.

Post embolization, repeat shunt trial was performed and her PaO₂ only increased to 55.

Patient was discharged with her saturating in the mid-80s, which was her baseline, with 5 L nasal canula.

Conclusion This is an extremely unusual case of a patient with widespread leiomyosarcoma who lived well past the anticipated life expectancy of 5 years and had an unusual number of AVMs within her tumors. AVMs within metastatic leiomyosarcoma are sparsely documented in case reports. This is an extremely rare case in which therapy was attempted to help with oxygenation. Despite trial of embolization, her PaO₂ did not increase significantly due to the large number of AVMs.

Although we were unsuccessful in elevating the patient's PaO₂ with embolization of AVMs, this is a novel therapy for tumor related AVMs that could be studied further to help oxygenation in patients.

480 FATAL PULMONARY HEMORRHAGE FROM S. MALTOPHILIA IN A CHILD

FD Sifers*, R Gallant, HC Allen. University of Oklahoma, Oklahoma City, OK

10.1136/jim-2017-000697.480

Case report *Stenotrophomonas maltophilia* is a multidrug-resistant gram-negative bacillus that causes opportunistic infection. This pathogen is an important cause of morbidity and mortality in immunocompromised patients. There are reports of

adults with neutropenia that develop pulmonary hemorrhage from *S. maltophilia*, no pediatric cases have been reported. We present a pediatric patient with relapsed acute lymphoblastic leukemia (ALL) and fatal pulmonary hemorrhage secondary to *S. maltophilia* infection.

A two-year-old female undergoing induction therapy was admitted for neutropenic fever. Initial lab work revealed pancytopenia with severe neutropenia, WBC 0.03 K/mm³, absolute neutrophil count (ANC) 30. Standard empiric antibiotic, cefepime, was started. Initial blood culture from her infusaport on hospital day (HD) 1 was positive for *P. aeruginosa*, so tobramycin was added. Subsequent cultures remained negative until HD 10, then her infusaport culture was positive for MSSA. On HD 11 the culture was positive for *S. maltophilia*. Her antibiotics were tailored to ceftazidime, nafcillin, and tobramycin. Daily cultures remained positive for only *S. maltophilia* leading to infusaport removal on HD 17. She remained profoundly neutropenic with maximum WBC 0.04 K/mm³(ANC 0) and thrombocytopenic.

Shortly after infusaport removal she acutely decompensated developing tachycardia, hypotension, and increased work of breathing. She was fluid resuscitated, given stress dose hydrocortisone, placed on high flow nasal cannula and transferred to the PICU. On the morning of HD 18 she developed worsening respiratory distress, desaturations and frank hemoptysis, requiring intubation. Her chest x-ray revealed a right upper lobe infiltrate representing pulmonary hemorrhage. She was thrombocytopenic (platelets 13 K) and coagulopathic (INR 3.4) which were corrected with transfusions of platelets, FFP, and factor VII. She continued to copiously hemorrhage from the ETT despite correction and aggressive ventilator support with high PEEP and mean airway pressure. She was given epinephrine and factor VII through the ETT in an effort to tamponade her hemorrhage. Despite these interventions she ultimately died on HD 18. To our knowledge this is the first case report of a pediatric patient with fatal pulmonary hemorrhage secondary to *S. maltophilia* infection.

481 HIGH-FLOW NASAL CANNULA USE IN BRONCHIOLITIS AT A TERTIARY CHILDRENS HOSPITAL

FD Sifers*, H Patel, HC Allen. *University of Oklahoma, Oklahoma City, OK*

10.1136/jim-2017-000697.481

Purpose of study High-flow nasal cannula (HFNC) is a noninvasive method of respiratory support that is frequently used in children and infants with acute respiratory distress for viral bronchiolitis despite a lack of high-grade evidence. The location of initiation of HFNC, PICU vs general ward, and the maximal liter/min flow or liter/kg/min flow varies among institutions with no evidence to guide clinical decisions.

The objective of this study was to evaluate the use of HFNC in infants and children with viral bronchiolitis at a tertiary children's hospital in both the general wards and PICU.

Methods used Retrospective chart review was conducted of infants and children less than 24 months of age admitted with viral bronchiolitis that required HFNC during their stay between January and March 2017. Patients were excluded for prematurity <34 weeks gestation and underlying congenital heart disease. HFNC failure was defined as the clinical decision to escalate to non-invasive ventilation (NIV) or need for mechanical ventilation.

Summary of results A total of 90 patients met inclusion criteria: 53 had PICU admission, 37 remained on the general wards for the entirety of their hospital stay. Median age of all patients was 2.3 months and 63% were males. Comparing the two groups, patients who were RSV positive were more likely to be admitted to the PICU (47 vs 26, $p=0.03$). The maximum HFNC (L/min) mean for the general ward was 8.9 L/min, median 10 L/min and the maximum HFNC mean for the PICU was 12.6 L/min, median 12 L/min ($p<0.001$). The mean HFNC per weight (kg) for ward patients was 1.5 L/min/kg and the mean HFNC per weight (kg) for PICU patients was 2.5 L/min/kg ($p<0.001$). Of the 90 patients, 9 failed HFNC therapy (10%). Seven required NIV and 2 required mechanical ventilation. All of the patients that failed HFNC were admitted to the PICU prior to failure of HFNC. No patients in the study died.

Conclusions The mean HFNC flow rate per kilogram was higher at our hospital compared to previously reported values with a failure rate comparable to published literature. The use of HFNC for viral bronchiolitis in infants and children less than 24 months without significant comorbid conditions was safe on the general wards although at lower flow rates compared to the HFNC flow use in the PICU.

482 ASSESSING THE IMPACT OF NEOINTIMAL LESIONS ON ELASTICITY AND BLOOD FLOW THROUGH PULMONARY ARTERIES

JE Smith*, C Zhou, T Stevens. *University of South Alabama, Mobile, AL*

10.1136/jim-2017-000697.482

Purpose of study Pulmonary arterial hypertension (PAH) is a defined as a chronic increase in blood pressure of the pulmonary artery (>25 mmHg). Medial hypertrophy and hyperplasia, and adventitial thickening occur in early stages of the disease process. With progression, neointimal lesions develop in pulmonary arterioles, leading to narrowed vessel lumens and vascular occlusion. It was originally thought that the lesions are uncommon, and contribute little to increases in pulmonary artery pressure (Ppa). However, recent 3-D reconstruction of hypertensive arterioles suggests that lesion density is more widespread than previously thought. Presently, physiological approaches do not discriminate whether or not neointimal lesions impact Ppa. Here, we test the hypothesis that retrograde perfusion will enable quantitative assessment of the impact of neointimal lesions on pulmonary arterial pressure.

Methods used PAH was induced in male Fischer rats via a single injection of SUGEN 5416 (20 mg/kg) followed by hypoxia exposure (10% O₂). The animals were studied after 1 and 3 weeks in hypoxia, and after 3 weeks of hypoxia plus 2 additional weeks in normoxia. To examine pulmonary vascular resistance and elastic recoil, the heart and lungs were isolated, ventilated, and perfused with 6% whole blood in forward and retrograde orientations at 8 mL/min. Thereafter, flow rates were increased by 8 mL/min every 5 minutes until tracheal edema occurred. Pulmonary artery and venous pressures were measured continuously via physiograph recorder, and double occlusion pressures were measured following each 5-minute interval. Note that double occlusion pressures were used as a surrogate for pulmonary capillary wedge pressure.

Summary of results In experimental PAH, Ppa, Fulton Index, and elastic recoil of pulmonary arteries increase with disease

progression. PAH lungs accommodated forward perfusion over the entire 5-week time course. However, only 1 and 3 week lungs accommodated retrograde flow. Retrograde flow was unsuccessful in 5 week animal, indicating that neointimal lesions had become prominent.

Conclusions Experimental PAH is a progressive disease due to medial and adventitial remodeling and neointimal lesion formation. These occlusive lesions appear to prevent retrograde perfusion, suggesting they are more prominent than previously thought.

483

BOERHAAVE SYNDROME: A RARE COMPLICATION OF INTRACTABLE VOMITING

K Iwuji, X Solis*, A Ismail, E Islam. *TUHS, Lubbock, TX*

10.1136/jim-2017-000697.483

Case report An 85-year-old male was brought to the emergency center after his daughter found him slumped over and covered in coffee ground emesis. The patient complained of two weeks of generalized weakness, fatigue, and nausea. After multiple episodes of emesis, with very little oral intake, he was noted to have dry heaves the morning of admission. On presentation, he had tachypnea, tachycardia, lethargy, and altered mental status.

Relevant laboratory revealed severe lactic acidosis with pH 7.0, lactate 19.5 mmol/L, leukocytosis of 15 K/uL, acute renal failure with BUN/Cr of 54/4.1, and negative gastro-occult blood. Mean arterial pressure dropped to 40s despite proper intravenous fluid resuscitation, requiring two vasopressors to keep his mean arterial pressure greater than 65 mmHg. A few hours after arrival to the hospital, he developed acute hypoxic respiratory failure requiring intubation. Empiric antibiotics with piperacillin-tazobactam and metronidazole were initiated.

A computerized tomographic scan of the chest and abdomen without contrast revealed pneumomediastinum with esophageal perforation and bilateral pleural effusions, consistent with Boerhaave syndrome due to repeated vomiting.

The patient was evaluated by cardiothoracic surgery and deemed a poor surgical candidate due to age, comorbidities, and hemodynamic instability. After extensive discussion with his family regarding his diagnosis, treatment options and prognosis, they decided on comfort measures and the patient was terminally extubated, dying the same day.

484

SELENIUM ENHANCES AURANOFIN-MEDIATED NRF2 ACTIVATION IN LUNG EPITHELIAL CELLS

RL Tindell*, S Wall, Q Li, R Li, K Dunigan, TE Tipple. *University of Alabama, Birmingham, AL*

10.1136/jim-2017-000697.484

Purpose of study Bronchopulmonary dysplasia (BPD) is common in preterm infants and acute lung injury (ALI) is associated with significant mortality in critically ill patients. Thioredoxin reductase-1 (TrxR1) inhibition by auranofin (AFN) activates Nrf2-dependent responses in murine transformed club cells (mtCC), decreases lung damage, and improves survival in murine models of BPD and ALI. TrxR1 activity is selenium (Se) dependent and Se deficiency is common in preterm infants and critically ill patients. We tested the hypothesis that Se supplementation would enhance Nrf2 induction and transcriptional activation by AFN.

Methods used MtCCs, supplemented with 0, 25, or 100 nM Se, were treated with 0.5 mM AFN or vehicle for 1 h. TrxR1 activity was assessed and nuclear Nrf2 protein amounts determined. Data (mean±SEM) were analyzed by ANOVA or t-test as indicated.

Summary of results We detected a concentration-dependent effect of Se supplementation on TrxR1 activity in control-treated mtCCs ($R^2=0.97$, $p<0.0001$). AFN inhibited TrxR1 activity in control and Se-treated groups ($p<0.0001$ vs vehicle). Nuclear Nrf2 protein was increased in all AFN-treated groups compared to respective vehicle-treated controls (0 nM: 2.7 ± 0.1 vs 1.0 ± 0.2 ; 25 nM: 5.6 ± 0.6 vs 1.5 ± 0.4 ; 100 nM: 4.6 ± 0.4 vs 0.6 ± 0.1 ; all $p<0.05$). The magnitude of AFN-induced increases in nuclear Nrf2 was greatest in Se-supplemented mtCCs (25 nM: 13.9 ± 2.3 vs 5.8 ± 0.2 ; and, 100 nM: 13.5 ± 1.5 vs 5.8 ± 0.2 , $p=0.02$). To evaluate transcriptional activation, antioxidant response element (ARE)-luciferase activity was measured in Se-supplemented mtCCs. ARE-luciferase activity was not different between vehicle and AFN-treated 0 nM and 10 nM supplemented mtCCs. In contrast, AFN increased ARE-luciferase activity by 2.3 times in 25 nM and 5.4 times in 100 nM supplemented mtCCs.

Conclusions Collectively, our findings support the hypothesis that Se supplementation enhances Nrf2 activation by TrxR1 inhibition. We speculate that Se status may modulate the efficacy of TrxR1 inhibitors as therapeutic agents to prevent or treat BPD and/or ALI. Optimization of Se status could enhance the therapeutic efficacy of TrxR inhibition.

485

VEIN OF GALEN MALFORMATION MASQUERADING AS PULMONARY HYPERTENSION

¹C Tran*, ²A Nagpal. ¹OUHSC, Edmond, OK; ²OUHSC, Oklahoma City, OK

10.1136/jim-2017-000697.485

Case report We describe a 6 day old neonate, born full-term and with uncomplicated pregnancy, who presented to our emergency department (ED) with increase work of breathing and decrease oral intake. Physical exam was significant for a 3/6 holosystolic murmur. Cardiomegaly was seen on initial roentogram in the ED concerning for congenital heart disease. Initial echocardiogram (ECHO) revealed evidence of pulmonary hypertension (PHTN) and a patent ductus arteriosus. Serial measurements of brain natriuretic peptide (BNP) were greater than 5000. Cardiology was consulted and the neonate was started on Sildenafil to treat PHTN. In addition, he was found to be rhino/enterovirus positive on respiratory panel by polymerase chain reaction from a nasopharyngeal swab. The patient was stable on nasal cannula and subsequently transferred to the regular ward. He developed a single episode of supraventricular tachycardia (SVT) that resolved after administration of adenosine. He was then transferred to the pediatric intensive care unit due to respiratory insufficiency necessitating escalation to high flow nasal cannula. Differential diagnosis included myocarditis from rhino/enterovirus infection resulting in heart failure. Follow up ECHO revealed dilated head and neck vessels, flow reversal of proximal descending aorta, and dilated LV and RV (normal function) suggestive of atriovenous malformation (AVM). Head ultrasound revealed a vein of Galen aneurysmal malformation (VGAM) confirmed by MRI/MRA with mass effect on cerebral aqueduct resulting in mild obstructive hydrocephalus. The patient was taken for

diagnostic and therapeutic angiogram and underwent successful coil embolization. Despite coiling, BNP continued to be greater than 5000, and he was started on inhaled nitric oxide (iNO) in addition to sildenafil for PHTN. Serial ECHOs revealed improvement of PHTN and iNO was weaned off. The patient was initiated on lasix and digoxin and subsequently transferred to the floor.

This case emphasizes that alternative diagnoses should be sought in a previously healthy full-term neonate presenting with signs of PHTN. VGAMs are formed by arteriovenous shunts and constitute less than 1% of intracranial vascular malformations. If left untreated, VGAMs have been reported to have a mortality rate of greater than 50% in neonates.

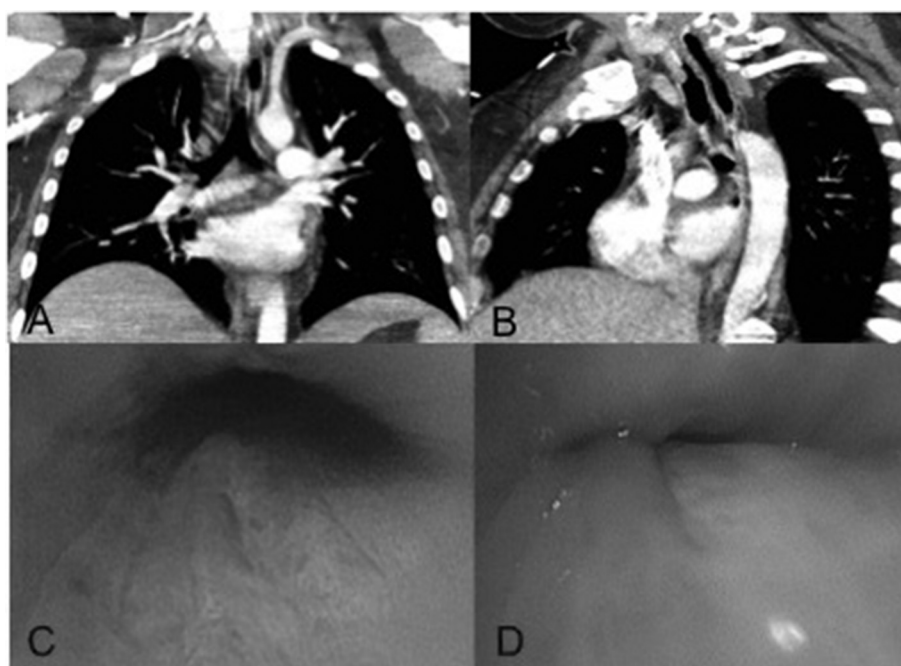
486 POST-INTUBATION TRACHEOBRONCHOMALACIA IN A YOUNG ADULT: A RARE CASE REPORT

¹Y Vorakunthada*, ²W Lilitwat. ¹Texas Tech University Health Sciences Center Lubbock, Lubbock, TX; ²University of Iowa Hospitals and Clinics, Iowa City, IA

10.1136/jim-2017-000697.486

Case report Tracheobronchomalacia (TBM) is characterized by weakness of cartilaginous supporting structures of tracheal and bronchial walls, resulting in central airway obstruction. It is a rare condition after prolonged intubation.

Here, we report a 26-year-old male who had TBM, mild subglottic, and severe tracheal stenosis. He had a history of intubation for 2 weeks from ARDS as well as septic shock, and was extubated successfully without upper airway obstruction. Two weeks later, he developed 90% occlusion of tracheal stenosis and TBM (figure). Balloon dilation was performed with 50% dilation of lumen size by CRE balloon. Argon plasma coagulation cautery, cryotherapy, and mitomycin C injections were also used. Oral steroids and amoxicillin/clavulanic acid were completed for two weeks.



Abstract 486 Figure 1 (A) and (B) chest CT showing severe tracheal stenosis. (C) and (D) bronchoscopic view of tracheomalacia

Subglottic and tracheal stenosis can occur after extubation but TBM is uncommon. We have ruled out other causes of TBM such as vascular ring, goiter and esophageal disorders. In our case, prolonged intubation and gastroesophageal reflux are risk factors.¹ Prolonged internal compression of trachea can predispose degeneration of normal cartilage as well as acid reflux. However, the exact mechanism is still unknown.

Post-intubation TBM is a life-threatening condition if left untreated. Early detection and timely management can improve the outcome of patients.

REFERENCE

1. Kandaswamy C, *et al.* Severe tracheomalacia in the ICU: Identification of diagnostic criteria and risk factor analysis from a case control study. *Respir Care* 2013;**58** (2):340–7.

487 PARAVALVULAR HEMOLYSIS MASKING A PLEURAL TRANSUDATE

RA Williams*, B Malhotra, C Milner, G Abraham. University of Mississippi Medical Center, Ridgeland, MS

10.1136/jim-2017-000697.487

Introduction In patients with pleural effusions, Light's criteria is used to classify the fluid as transudative or exudative. An elevated pleural fluid lactate dehydrogenase (LDH) alone is sufficient to classify the fluid as exudative. Serum LDH, used by Light's criteria in the fluid to serum ratio, can be elevated by the rare phenomenon of paravalvular hemolysis, which causes significant anemia in <1% of valve replacements. We present a case of an apparent exudative effusion by LDH in the setting of significant hemolysis without any identified exudative pathology.

Case description A 73 year old woman with aortic stenosis and a mechanical mitral valve presented with progressive dyspnea. Her exam revealed decreased breath sounds at the right base and a systolic murmur at the right upper sternal border. Imaging revealed a

right pleural effusion. Pleural fluid studies were exudative by LDH of 549 U/L. On a subsequent sample with concomitant serum studies, neither fluid to serum total protein ratio, fluid to serum LDH ratio, fluid to serum albumin gradient, nor fluid cholesterol met exudative criteria. Serial cytology and computed tomography (CT) of the thorax were not indicative of malignancy. Further workup of her dyspnea revealed a hemoglobin of 6.6 g/dL, a drop from 13.5 g/dL one year prior, and a serum LDH of 1820 U/L. Schistocytes were present, and a direct Coombs test was negative. An echocardiogram revealed a moderate mitral paravalvular leak and severe aortic stenosis. Her symptoms improved with transfusion, and her valvular disease is being managed conservatively.

Discussion In this patient, paravalvular hemolytic anemia and aortic stenosis were likely the source of her dyspnea and effusion. Light's criteria, an important screening tool, has a sensitivity of 98% for identifying an exudate at the expense of increased false positives. Light's criteria includes the pleural fluid to serum protein ratio, which acknowledges the known correlation between the two. However, also included is the pleural fluid to serum LDH ratio, despite the current belief that there is no correlation between the two. This case suggests that extreme serum LDH elevation could influence pleural fluid LDH, leading to a pseudoexudate, in which a transudative effusion meets Light's criteria for exudates.

Renal, electrolyte and hypertension

Joint plenary poster session and reception

4:30 PM

Thursday, February 22, 2018

488 EVALUATION OF PROTEINURIA LIMITATION OF URINARY PROTEIN TO CREATININE RATIO

NM Alqurini*, N Karakala, G Hobby. *University of Arkansas Uams, Little Rock, AR*

10.1136/jim-2017-000697.488

Introduction Urinary protein to creatinine ratio (UPCR) is widely used for evaluation of proteinuria. A measurement of urinary protein and creatinine are usually done on a first, or second, voided urine sample. The ratio of these two numbers yields an estimation of the 24-hour excretion of protein. Spot urine protein to creatinine ratio is relatively easy and less time consuming compared to 24-hour urine collection and is becoming the preferred test. However, there are limitations to urine protein creatinine ratio in measuring the degree of proteinuria. We are presenting a case where the spot UPCR poorly correlated with the 24-hour urine protein, and would have led to missed diagnosis of nephrotic range proteinuria.

Case A 27 year-old male patient presented with a four-week history of fever, weight loss, and intermittent right groin pain. He has history of multiple unprotected sexual encounters. Physical exam was positive for diffuse cervical, axillary, and inguinal lymphadenopathy along with right leg swelling.

Serum creatinine was 3 mg/dl (unknown baseline) with a low serum albumin (1.8 g/dl).

A spot urine protein concentration was 99 mg/dl, and creatinine concentration was 47 mg/dl, the UPCR was 2.1 grams/gram.

The patient's 24-hour urine protein measurement was 10.9 grams and creatinine excretion was 1.5 grams, and total urine volume was 2800 ml.

Doppler examination ruled out testicular torsion, and the patient was found to have dilated left femoral, common femoral and popliteal veins with loss of augmentation and respiratory variation. There was no thrombus identified, suggesting a proximal obstruction. It was identified on computer tomography scan as an acute left common iliac vein thrombus.

The patient's absolute CD4 count was 249 cells/uL. He tested positive for HIV-1.

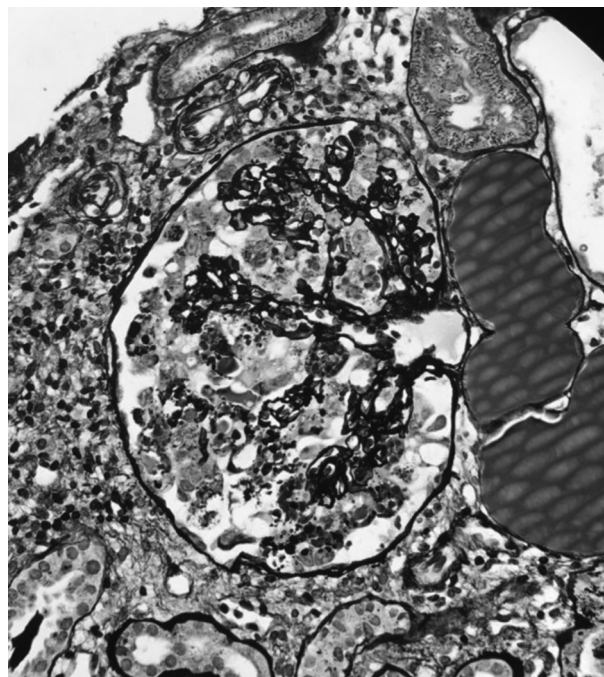
Conclusion If we used only UPCR for the assessment of this patient we would have missed the diagnosis of nephrotic range proteinuria in this patient with a low serum albumin and a deep venous thrombosis, the UPCR of 2.1 grams dramatically underestimates his degree of proteinuria. Clinicians must take into consideration that spot UPCR is affected by many renal and non-renal factors including acute tubular injury, muscle mass and serum albumin level.

489 COLLAPSING FSGS IN AN HIV-NEGATIVE PATIENT

B Birkelo*, H Whiteside, S Nahman, P Fall, N Belayneh. *Medical College of Georgia at Augusta University, Augusta, GA*

10.1136/jim-2017-000697.489

Case report A 25-year old morbidly obese African-American male with no known medical history presented with a one-week history of intermittent headaches, constant diplopia, and dysconjugate gaze. He reported normal kidney function during blood work done two weeks prior to current presentation. He has no family history of renal disease or illicit IV drug use.



Abstract 489 Figure 1 Renal biopsy showed wrinkling of capillary walls with collapsed lumens

Initial workup was remarkable for pseudotumor cerebri and severe renal insufficiency (serum creatinine 9.28 mg/dL, BUN

58 mg/dL). Urinalysis demonstrated 4+ proteinuria (4 gm/day on spot urine protein-creatinine ratio) with bland sediment and no hematuria. Serologic work up was negative for infection including HIV, parvovirus, CMV, and EBV. Renal biopsy showed wrinkling of capillary walls with collapsed lumens in every glomerulus, without endothelial tubuloreticular inclusions.

The patient was subsequently diagnosed with idiopathic collapsing FSGS. Therapy was initiated with prednisone 120 mg po q48 hr and the patient discharged without need to initiate dialysis. Three months following discharge, renal function had improved further with labs showing BUN 17 and Cr 1.67.

490 PATIENT CHARACTERISTICS FOR BK POLYOMAVIRUS IN RENAL TRANSPLANT RECIPIENTS AT AUGUSTA UNIVERSITY (AU) TRANSPLANT CENTER

S Dhanani*, F Yang, L Mulloy, A Lee. *Medical College of Georgia, Augusta, GA*

10.1136/jim-2017-000697.490

Purpose of study BK Virus (BKV) is a renal transplant complication which can threaten transplant graft survival and is a consequence of required immunosuppression post-transplant. Data on risk factors for BKV varies between studies and populations. Our aim was to characterize the BKV patients at AU transplant center and review the degree of heterogeneity between donors and recipients.

Methods used AU renal transplant recipients from January 2006 to December 2016 were reviewed for evidence of serum BKV copies >500 and urine BKV copies >10,000. Included patients (n=183) were divided into four groups:

- serum negative, urine positive (reference),
- serum positive, urine negative,
- serum positive, urine positive, and
- biopsy-proven BKV.

A multinomial logistic regression model was used to calculate the relative risk of being in groups 2–4 compared to reference group 1 for each patient characteristic.

Summary of results There are significant characteristics, compared to the reference group 1, for groups 2 and 4. Those who were older (RR=1.05, 95% CI: 1.01 to 1.09), White (RR=10.22, 95% CI: 1.02 to 102.12) or Black (compared to other groups, RR=15.82, 95% CI: 1.76 to 141), received thymoglobulin (RR=6.09, 95% CI: 1.63 to 22.69), and had increased most-recent creatinine levels (RR=1.25, 95% CI: 0.998 to 1.58) had a higher relative risk of being in group 2 than group 1. However, for every increase in one unit change of creatinine levels from baseline there was a 41% lower relative risk (95% CI: 0.37 to 0.95), of being in group 2 compared to group 1. Increased change in creatinine levels from baseline (RR=7.00, 95% CI: 1.72 to 28.56) and increased recent creatinine levels (RR=1.56, 95% CI: 1.12 to 2.17) show a higher risk of being in group 4 compared to group 1. All p's are ≤0.05.

Conclusions We were able to identify patient profiles for the BKV outcome groups compared to the serum negative, urine positive group. The serum positive, urine negative group was significantly associated with age, race, thymoglobulin regimen, most recent creatinine levels, and creatinine change from baseline. Though there were no significant differences with the serum positive, urine positive group, the patient characteristics

for the biopsy proven group were associated with both increased creatinine change and most recent creatinine level.

491 AN UNEXPECTED CAUSE OF ACUTE RENAL FAILURE

C Gregg*, J Bruno, M Laskey, J Gaines, LS Engel, J Amoss. *LSU Health Sciences Center, New Orleans, LA*

10.1136/jim-2017-000697.491

Introduction Acute Renal Failure is a common cause of hospital admissions and a frequent diagnosis in hospitalized patients. Pre-renal Azotemia is caused by states of low arterial perfusion to the kidneys, often due to hypovolemia, heart failure with reduced ejection fraction, or acutely decompensated liver disease. Frequently, renal failure that requires dialysis is caused by irreversible insults to the renal parenchyma.

Case A 54-year-old woman with a history of hepatic cirrhosis secondary to right heart failure, atrial fibrillation, hypertension, and diabetes mellitus presented to our hospital with a complaint of bilateral leg swelling and pain. She was found to have an elevated creatinine of 11 mg/dl from a baseline of 1, elevated potassium of 7.7 mEq/L, and she was admitted to the internal medicine team with an initial diagnosis of acute renal failure and emergency dialysis was initiated. Of note, she was seen in the emergency department 10 days prior for lower extremity cellulitis and she had refused admission for elevated creatinine at that time. She was discharged with seven days of clindamycin. She was also found to be in rate-controlled atrial fibrillation, although she was not anticoagulated at home due to non-compliance with anticoagulation. On day 6 of hospitalization, she began to complain of coldness in her right foot without pain. Bedside Doppler ultrasound was unable to demonstrate arterial blood flow to the right lower extremity. Angiography revealed a large thrombus at the bifurcation of the aorta, with complete occlusion of the right iliac artery, and near-complete occlusion of the left iliac artery. Tissue plasminogen activator was directed via catheter directly into the clot, and she regained lower extremity pulses several hours later. She remained in renal failure and was discharged home on anticoagulation and regular dialysis.

Discussion Embolic disease is a rare cause of acute renal failure and can result from atrial fibrillation. In a patient with normal renal function, an embolus must occlude both renal arteries or separate emboli must occlude each renal artery. Acute thrombotic or embolic disease should be considered as a cause of acute renal failure, particularly in those patients that are at high risk of thrombosis.

492 DOXYCYCLINE ASSOCIATED OXALATE NEPHROPATHY

¹M Malik*, ^{1,2}T Naguib. ¹Texas Tech Univ HSC Amarillo, Amarillo, TX; ²VA Medical Center, Amarillo, TX

10.1136/jim-2017-000697.492

Case report Doxycycline is a safe antibiotic in patients with impaired renal function. Unlike earlier tetracyclines, tetracycline and chlortetracycline, doxycycline has not been implicated in causing acute kidney injury (AKI). Likewise, there is no reported association between doxycycline and oxalate nephropathy. We report a case of biopsy proven oxalate nephropathy precipitating severe AKI in a previously healthy

person who received oral doxycycline and propose a mechanism for this renal insult.

58 year old man presented with progressive anorexia and nausea for few days. Vital signs were stable. Exam revealed mild symmetrical pitting edema of bilateral lower extremities extending up to mid thighs. He had normal CBC, sodium 135, potassium 5.1, chloride 102, bicarbonate 20, BUN 42, creatinine 4.7 and negative urinalysis with pH of 5.5. Bilateral renal ultrasound was inconclusive. He was given intravenous fluids and dismissed at that point.

He was later admitted to the hospital for further evaluation of his worsening symptoms and elevation of creatinine to 5.2 mg/dl. Due to lack of initial improvement, CT guided renal biopsy was performed. However, his renal function slowly improved on its own and he never required any form of dialysis. His functional status improved and his creatinine dropped to 1.3 mg/dl over the next 12 months. Renal biopsy showed acute tubular injury with accumulation of calcium oxalate crystals in the tubules and his final diagnosis was oxalate nephropathy subsequent to doxycycline use.

As seen above, doxycycline may lead to AKI from oxalate nephropathy. The association itself, *let alone* the mechanism, is nowhere to be found in literature. We propose that doxycycline may lead to oxalate nephropathy from suppressing *Oxalobacter formigenes* in human gut. By doing so, it leads to enhanced oxalate absorption from the intestine resulting in hyperoxaluria and subsequently predisposing an individual to oxalate nephropathy, even without nephrolithiasis as seen in our case. Incidence of this event would be higher in individuals who have other risk factors for hyperoxaluria such as volume depletion, malabsorption and hypocitraturia.

In summary, doxycycline may cause oxalate nephropathy by causing enhanced oxalate absorption from the gut likely due to its antimicrobial effect on *Oxalobacter formigenes*.

493 ACUTE RENAL INFARCTION; A DIAGNOSTIC CHALLENGE

D Markabawi*, H Singh Gambhir. SUNY Upstate, Syracuse, NY

10.1136/jim-2017-000697.493

Introduction Acute renal infarction is a scarcely reported condition. Clinical suspicion for this condition is usually low given its rarity and how its presentation can mimic other more common pathologies. Contrast enhanced CT scan is essential for diagnosis. The most common etiology of this condition is cardio-embolic, however at least one study found that up to 59% of cases had what was classified as idiopathic acute renal infarction.

Case A 41-year-old male with history of alpha-1 antitrypsin deficiency, was transferred to our hospital from an outside hospital, where he was admitted for acute onset right flank pain and fever. A CT Abdomen with contrast done there showed findings concerning for right pyelonephritis or renal infarction. Urinalysis was performed twice and was negative. Patient was treated with antibiotics for 2 days without improvement; he was transferred to our hospital given concern for renal infarction.

At our hospital, he complained of right flank and right upper quadrant abdominal pain. Physical exam was remarkable for a temperature of 38° C and right upper quadrant tenderness. Laboratory workup was remarkable for leukocytosis and a serum creatinine of 1.5 mg/dl (baseline of 1.2). A CTA

abdomen showed infarction of the right kidney's upper and lower poles. Vascular surgery did not recommend any intervention and the patient was started on Enoxaparin. Work-up was negative for all autoimmune markers of vasculitis. It was also negative for Factor V Leiden and Prothrombin mutations. A TEE was negative for cardiac emboli. Telemetry did not detect any dysrhythmia. Visceral angiogram was incompatible with PAN. Patient was thus diagnosed with idiopathic acute renal infarction. He was discharged on Enoxaparin.

Discussion Diagnosing acute renal infarction can be challenging. Our patient was diagnosed with pyelonephritis initially before a CTA of the abdomen confirmed the diagnosis of renal infarction. Testing for the most common etiologies (cardio-embolic, local renal artery involvement and hypercoagulable states) in this patient was negative. There is little data guiding treatment, we elected to treat with Enoxaparin.

Conclusion In conclusion, acute renal infarction, although rare, should be suspected in patients presenting with acute flank/abdominal pain in whom the more common etiologies have been ruled out.

494 IS DIETARY PROTEIN INTAKE PREDICTIVE OF ONE-YEAR MORTALITY IN DIALYSIS PATIENTS?

¹DP Murray*, ¹L Young, ¹J Waller, ¹S Wright, ¹R Colombo, ^{1,2}S Baer, ¹V Spearman, ¹R Garcia-Torres, ¹K Williams, ¹M Kheda, ^{1,2}S Nahman. ¹Augusta University, Augusta, GA; ²VA Medical Center, Augusta, GA

10.1136/jim-2017-000697.494

Purpose of study Mortality is high in dialysis patients and may be associated with protein-energy wasting (PEW) syndrome characterized by progressively depleted protein and energy stores. While early diagnosis and treatment of PEW can reduce mortality, clinically practical measures for its detection are lacking. Poor dietary protein intake (DPI) is associated with risk of malnutrition and PEW. However, the impact of DPI on mortality is unclear. The purpose of this study is to examine the ability of DPI to predict one year mortality in dialysis patients.

Methods used This retrospective, secondary study using data from the Comprehensive Dialysis Study (CDS) and United States Renal Data System examined risk factors associated with one year mortality in new dialysis patients. The CDS data used for this study included sociodemographic, clinical, dialysis-related and dietary variables.

Summary of results Seventeen (7.5%) of the 227 subjects died within one year following baseline data collection. One year survivors were significantly younger (60±13.6 vs 71±12.8; p=0.0043), had a lower Charlson Comorbidity Index (CCI) score (1.6±2.3 vs 4.0±3.6; p=0.0157), higher serum albumin level (3.5±0.5 vs 3.3±0.4; p=0.0173), and had higher DPI (63±33.7 vs 49.5±21.5 g/day; p=0.0386) than those who died. In multivariable Cox proportional hazards model analyses, the CCI adjusted hazard ratio for death (1.24) was significantly associated with an increased risk of one-year all-cause mortality. The CDS data showed no association between DPI and one year mortality in new dialysis patients.

Conclusions Future studies using more precise measures are needed to examine the predictability of DPI on mortality given the definitive link between DPI and PEW syndrome and survival in dialysis patients.

495

ANTI-GLOMERULAR BASEMENT MEMBRANE GLOMERULONEPHRITIS WITH CHRONIC HEPATITIS C — A RARE COMBINATION

S Patil*, N Karakala, G Hobby. *University of Arkansas for Medical Sciences, Little Rock, AR*

10.1136/jim-2017-000697.495

Purpose of study Anti-GBM disease is a rare autoimmune disease caused by the deposition of the circulating antibodies against noncollagenous C terminal (NC1) domain of the α 3 chain of collagen type IV of the GBM. It is a rapidly progressing condition with very high mortality if not timely identified and treated. Viral infections such as influenza A2 have been implicated as triggers, other infections like HIV and EBV have been reported. We could not find any reports of Hepatitis C infection associated with anti-GBM disease.

Methods used We present a 49 year old white male with PMH of HCV and HTN with nausea, emesis and AKI. He had history of aortic and mitral valve regurgitation due to infective endocarditis 1 year ago. He was a former smoker and intravenous drug abuser. Labs on admission were significant for Hb of 9.7 g/dL, serum creatinine of 3.4 mg/dL (normal baseline creatinine). UA showed moderate blood, 10–25 RBCs, 0–2 WBCs. No dysmorphic RBCs on microscopy. Serum anti-GBM antibodies were present. Serologic workup was negative. Patient was on treatment for HCV infection with recent negative HCV viral loads. A kidney biopsy obtained showed diffuse crescentic GN (95%) with linear IgG staining along the GBM, consistent with anti-GBM GN.

Summary of results Our patient had renal limited anti-GBM disease with no pulmonary symptoms and normal CT Chest. He received 7 plasmapheresis sessions with 3 pulse doses of solumedrol. Immunosuppression with cytoxan and prednisone was started. however renal function worsened to the point of dialysis dependence. Severe pancytopenia, GI tract ulcers and bleeding occurred. As biopsy showed 95% crescentic glomeruli and no renal recovery signs, we chose to stop immunosuppression in a risk-benefit analysis.

Conclusions Anti-GBM GN incidence is less than 1 case per 1 million so few studies present to draw associations. On literature review, there is 1 case report each in a patient with acute Hepatitis A and hepatitis B infection. An explanation for this viral hepatitis association is due to immune complexes production inciting glomerular injury and exposing sequestered GBM antigens. Our patient lacked pulmonary symptoms. Smoking is a risk factor, but there is also a possibility that his risk was increased in the setting of chronic hepatitis C infection, making him more susceptible.

496

RARE CASE OF RENAL TUBULAR ACIDOSIS TYPE IV AS A COMPLICATION OF LUPUS NEPHRITIS

S Ravula*. *UAMS, Little Rock, AR*

10.1136/jim-2017-000697.496

Case report Renal Tubular Acidosis often poses diagnostic challenge more so in setting of renal insufficiency, hence prompt recognition and treatment of condition is necessary.

On review of literature, it is understood that renal tubular acidosis occurs as a complication of lupus nephritis in setting of high SLE disease activity index score.

We hereby present an interesting case of lupus nephritis with high SLE DAI index score associated with type 4 RTA.

This is a 21 year old african american female with recent diagnosis of renal biopsy proven class 4 and 5 lupus nephritis. Renal biopsy showed diffuse proliferative lupus nephritis with crescents and membranous features as well. As defined by the NIH criteria, the findings in biopsy corresponded to an activity index of 18 -scale 0–24 and a chronicity index of 6 -scale 0–12.

Patient received three days of solumedrol as pulse steroids followed by oral prednisone along with mycophenolate as part of induction regimen. Renal function had improved from presenting GFR of around 30 ml/min/m² to 40 ml/min/m² at time of hospital discharge.

However, one week later on routine lab work, it was noted that patient had severe hyperkalemia with no worsening of renal function. Hyperkalemia persisted despite patient being on adequate dose of lasix and laxatives for regular bowel movements.

Pseudohyperkalemia was ruled out with concurrent elevation of plasma potassium as well.

Other causes like ongoing hemolysis was ruled out too with stable hematocrit, normal haptoglobin, LDH and peripheral smear. After negative workup for hyperkalemia thus far in clinical course, hyporeninemic hypoaldosteronism associated type IV RTA was suspected with normal anion gap metabolic acidosis, severe hyperkalemia with stable renal function and urinary pH of 5.1. Trans Tubular Potassium Gradient when calculated was 1.9 in setting of high serum potassium that indicated hypoaldosteronemic state with urine osmolality being 357 mosm/kg and urine sodium was 87 mmol/L at time of calculation.

Subsequently patient was started on fludrocortisone 0.1 mg OD along with sodium bicarbonate supplements for acidosis and this led to normalisation of serum potassium levels.

497

A UNIQUE CASE OF RENAL ONCOCYTOSIS IN A VETERAN EXPOSED TO AGENT ORANGE

A Reddy*, M Sessums, JC Henegan, V Manucha. *University of Mississippi Medical Center, Jackson, MS*

10.1136/jim-2017-000697.497

Case report More than 3 million veterans during the Vietnam War had exposure to Agent Orange, an herbicide containing dioxin that has been linked to increased cancer risk. There is sufficient evidence for an association between Agent Orange and hematological disorders, but only a few cases have been reported in relation to renal neoplasms. Here we present a case of right-sided renal oncocytosis (RO) with Agent Orange exposure in a patient with chronic kidney disease (CKD).

A 68-year-old Caucasian male with hypertension, CKD, and previous Agent Orange exposure was noted to have elevated serum creatinine 1.9 mg/dL and blood urea nitrogen 36 mg/dL which triggered further evaluation. He had no recent hematuria, flank pain, or weight loss. Renal ultrasound showed multiple renal masses, and MRI confirmed these to be concerning for renal cell carcinoma with one mass in the upper pole of right kidney measuring up to 3.3 cm and a second mass in the interpolar region of left kidney measuring 2.3 cm. All nodules were completely confined to the kidney.

Preoperative germline testing of a panel of genes in which variants are associated with hereditary renal carcinoma syndromes revealed no pathogenic mutations. Right partial nephrectomy was performed which noted multiple oncocytic nodules ranging in size from microscopic collection of a few cells to large, grossly visible nodules. Immunostains were negative for AMACR and CK7 and positive for CAM5.2 and CD117, consistent with a diagnosis of RO.

Discussion RO – multiple oncocytic nodules of renal parenchyma – is an extremely rare disorder with an incidence of about 4.3% of all solid renal masses. It is associated with CKD and Birt-Hogg-Dube Syndrome. The diagnosis of RO remains a challenge due to the difficulty in distinguishing between benign and malignant lesions with imaging. As with this case, partial nephrectomy allowed for definitive diagnosis. RO, in this case, could be related to CKD and any link to previous exposure to Agent Orange will require further follow-up of patients with this history to determine if it is a risk factor for RO. According to literature, there have been only 4 similar cases reported of oncocytosis with Agent Orange exposure but there has been no definitive link.

498 NOVEL PHARMACOMECHANICAL TREATMENT OF A LARGE ARTERIAL ANASTOMOSIS THROMBUS OF AN ARTERIOVENOUS GRAFT

DS Rees*, H Ho-Pham, RB Varelzdis, MV Naljayan, EA Aguilar, S Barry, F Yazdi, SA Morse, E Reisin. *LSU Health Sciences Center, New Orleans, LA*

10.1136/jim-2017-000697.498

Case report A 70-year-old male with medical history of end stage renal disease, coronary artery disease, peripheral artery disease, recurrent bilateral foot ulcers, and atrial fibrillation was referred for percutaneous thrombectomy of a clotted right femoral arteriovenous graft (AVG). He was on no chronic anticoagulation except aspirin 81 mg daily. He had multiple thrombosed accesses previously. Current right femoral graft was placed two years prior and had required thrombectomy, and revision due to pseudoaneurysm.

Percutaneous thrombolysis was attempted with tissue plasminogen activator (tPa) and balloon angioplasty; then thrombectomy was attempted with a Fogarty catheter. A large thrombus remained at the arterial anastomosis extending into the juxta-anastomosis segment of the graft and into the femoral artery. Typically, Fogarty aspiration, direct aspiration, or injection of tPa would be used to resolve the thrombus. Due to the extent of the thrombus, we felt that it would not easily be removed with those techniques; instead an infusion catheter was placed with its tip in the femoral artery proximal to the anastomosis and tPa was infused overnight.

The patient was monitored in the ICU overnight with no complications. Arteriogram showed patent femoral artery but residual clot in the graft. Mechanical thrombectomy was performed restoring flow through the graft allowing for dialysis use the same day. Two months post procedure, the graft remained usable and had not re-thrombosed.

AVG failure is a cause of morbidity and mortality in ESRD patients and is commonly caused by thrombosis. AVG thrombosis can be treated surgically or percutaneously with no difference in success rate, complications, or patency. Percutaneous methods of resolving AVG thrombus include mechanical thrombectomy and pharmacomechanical thrombolysis. There is

risk of creating emboli with these procedures that can result in pulmonary embolism or arterial embolism. The majority of emboli are retrievable by percutaneous techniques and some may be observed without intervention if they are asymptomatic.

499 A COMPLICATED ILLNESS SCRIPT

M Touchy*, MV Naljayan, EA Aguilar, S Barry, F Yazdi, SA Morse, E Reisin. *LSU Health Sciences Center, New Orleans, LA*

10.1136/jim-2017-000697.499

Case report A 55 year old African American woman with past medical history of coronary artery disease with multiple myocardial infarcts with seven stents, heart failure, peripheral artery disease, type 2 diabetes mellitus (on metformin), hypertension, hyperlipidemia, and tobacco abuse was brought to emergency department by family members secondary to altered mental status for approximately one day. One week prior, she was treated for flash pulmonary edema secondary to NSTEMI and underwent cardiac catheterization, which revealed 50–70% in-stent re-stenosis, and a sub-total occlusion of the circumflex artery, successfully intervened with balloon angioplasty. On admission, the patient was unable to communicate secondary to intubation. However, her family divulged that two days prior to admission, the patient began to experience worsening hallucinations and vomiting. She was hypotensive with systolic pressures ranging from 60–70; temperature of 93 °F; BUN/Cr 77/10.1 mg/dL; potassium 8.2 mEq/L; bicarbonate of <5 mEq/L; anion gap 41; lactic acid 15 mmol/L; negative toxicology screen; BNP 4042 pg/ml; arterial blood gas with pH 6.8 and pCO₂ 23. She coded a total of four times, with each episode lasting no longer than five minutes before a pulse returned. She was transferred to ICU in critical condition on two vasoactive agents and a bicarb infusion; emergent CRRT was initiated for severe acidosis in setting of acute kidney injury. Over the next twelve hours, she was able to move all four extremities and follow simple commands; over the next two days, her hemodynamic status, electrolytes, and acidosis and renal function improved. By hospital day four, she was extubated.

Discussion This is a great example of a complicated illness script with multiple organs involved, including lungs, kidneys, heart, and brain. Our working diagnosis was that the patient had incurred a kidney injury, possibly from recent coronary angiogram, which was further exacerbated by the patient's continued use of metformin, resulting in a severe lactic acidosis. This contributed to patient's hypotension and hemodynamic collapse.

500 AN INTERESTING CASE OF HYPONATREMIA IN HEAD AND NECK CANCER CAUSED BY PEMBROLIZUMAB

RB Varelzdis*, T deSilva, MV Naljayan, EA Aguilar, S Barry, F Yazdi, SA Morse, E Reisin. *LSU Health Sciences Center in New Orleans, New Orleans, LA*

10.1136/jim-2017-000697.500

Case report A 62 old male with stage IV Squamous cell carcinoma (SqCC) of the proximal esophagus diagnosed in 2010 received cisplatin base chemotherapy, radiation and resection in 2011. He was then diagnosed with SqCC of the tongue in

2015, which he refused resection. He elected to initiate radiation & chemotherapy instead. He was then found to have a right upper lung and left lower lung masses concerning for metastatic disease.

A diagnostic biopsy was performed and revealed SqCC. He was started on pembrolizumab (keytruda™) 200 mg IV every 3 weeks in 10/2016 in outpatient setting. On routine outpatient blood work, he was found to have severe hyponatremia. Patient was hospitalized, his serum sodium was 117 mmol/L, urine osmolality 158 mosm/kg, urine analysis specific gravity <1.005, serum osmolality 241 mosm/kg, urine sodium 62 mEq/L, Thyroid stimulating hormone 80.6 mIU/L. After initiating Levothyroxine and Tolvaptan his urine osmolality 383 mosm/kg and serum sodium improved to 130 mmol/L by hospital day five. Hyponatremia is the most common electrolyte abnormality in cancer patients. In the US the direct costs of treatment hyponatremia annually are estimated to be \$1.6-\$3.6 billion.

Hyponatremia is an independent predictor of poor outcome in cancer patients. Pembrolizumab could play a role in causing immune mediated hypothyroidism especially in patients who suffer from head and neck SqCC. Hypothyroidism leads to decrease cardiac output, increase ADH release, decrease free water excretion by up regulating V2 receptors expression in principle cells similar to Syndrome of inappropriate ADH. Treatment with Levothyroxine and Tolvaptan improved free water excretion, allowed a safe hyponatremia correction, decreased hospital stay and permitted chemotherapy future administration.

Southern Society for Clinical Investigation and Southern American Federation for Clinical Research

Plenary session

SSCI young investigator award finalists

SSCI poster award finalists

SAFMR/SSCI/ young faculty award

SAFMR/SSCI/ trainee research award

8:00 AM

Friday, February 23, 2018

501 IMPAIRED ARTERIAL BAROREFLEX SENSITIVITY IN PREHYPERTENSION

IT Fonkoue*, ML Kankam, J Park. *Emory University, Decatur, GA*

10.1136/jim-2017-000697.501

Purpose of study Prehypertension is associated with increased risk of hypertension and cardiovascular disease (CVD), the mechanisms of which remain unclear. Prior studies have shown increased resting sympathetic nerve activity (SNA), and augmented blood pressure (BP) responses during mental stress, suggesting autonomic dysregulation at rest and during stress.

We hypothesized that compared to normotensives ($\leq 120/80$ mmHg), prehypertensives (120/80–139/89 mmHg) have impaired arterial baroreflex sensitivity (BRS) leading to autonomic dysregulation, and increased neurocardiovascular reactivity to mental stress.

Methods used 22 participants were studied: 12 otherwise healthy prehypertensives (35 ± 6 years) and 10 matched normotensive controls (32 ± 6 years). We recorded muscle SNA (MSNA) using microneurography, beat-to-beat BP, and continuous EKG during 5 minutes of supine rest and 3 minutes of stress via mental arithmetic. Arterial baroreflex sensitivity (BRS) was measured via *modified oxford technique* using IV boluses of nitroprusside and phenylephrine to manipulate arterial BP. The slope of the linear relationship between diastolic BP and MSNA (sympathetic BRS), and systolic BP and R-R interval (cardiovagal BRS) were assessed.

Summary of results As expected, baseline systolic BP (130 ± 7 vs 117 ± 8 mmHg) and diastolic BP (87 ± 7 vs 74 ± 8 mmHg) were significantly higher in prehypertensives ($p < 0.001$). Resting MSNA (25 ± 12 vs 18 ± 10 bursts/min) tended to be higher in prehypertensives ($p = 0.08$). Sympathetic BRS was comparable between the groups, but cardiovagal BRS (13 ± 10 vs 22 ± 10 ms/mmHg) was significantly lower in prehypertensives ($p = 0.03$). During mental arithmetic, minute by minute increases in BP and MSNA did not differ between the groups. However, there was a significant correlation between diastolic BP reactivity to mental stress and resting cardiovagal BRS ($r = 0.703$, $p = 0.016$), as well as with resting sympathetic BRS ($r = 0.795$, $p = 0.010$) in the prehypertensive group. In contrast, in normotensive controls, there was no correlation between BP responses to stress and cardiovagal ($r = 0.126$, $p = 0.766$) or sympathetic BRS ($r = 0.287$, $p = 0.581$).

Conclusions These findings suggest that early impairment of arterial BRS may be present in prehypertension and may modulate BP responses to stress, contributing to increased hypertension and CVD risk.

502 NATIONAL TRENDS OF SICKLE CELL DISEASE RELATED ADULT HOSPITALIZATIONS

¹N Jain*, ²M Agarwal, ¹M Kalliny, ¹F Syed. ¹Meharry Medical College, Nashville, TN; ²University of Tennessee Health Sciences, Memphis, TN

10.1136/jim-2017-000697.502

Purpose of study Sickle cell disease (SCD) is an increasing global health problem. Data pertaining to contemporary trends of patient characteristics with SCD is limited. Hence, we studied national trends of patient characteristics admitted with a primary diagnosis of SCD from 2003 to 2014 across United States.

Methods used Using 2003 to 2014 Nationwide Inpatient Sample (NIS) database of the Healthcare Cost Utilization Project (HCUP), we examined the contemporary trends for patient demographics, hospitalization characteristics, in-hospital complications and healthcare resource utilization of SCD related hospitalizations in the US.

Summary of results Overall there were 770,000 SCD hospitalizations between 2003 and 2014 with an increase in annual frequency from 52,741 in 2003 to 72,930 in 2014, p trend < 0.001 . There was a significant decrease in mean age (31.94 to 31.53, years) and proportion of females (55.0% to 53.8%) (all p trend < 0.001). While the frequency of hospitalizations for