

Recombinant tissue plasminogen activator treatment of pulmonary embolism also improves deep venous thrombosis

Mukremin Er

Correspondence to

Dr Mukremin Er, Pulmonary Diseases Department, Ankara Atatürk Training and Research Hospital, Ankara, 06800, Turkey; mukreminer@hotmail.com

Accepted 10 May 2018
Published Online First
6 June 2018

ABSTRACT

Anticoagulants are the standard form of treatment used in deep vein thrombosis (DVT). Thrombolytic therapy is another method to treat thromboembolism by using intravenous administration of streptokinase, urokinase and recombinant tissue plasminogen activator (r-tPA). We have investigated the effect of r-tPA, a systemic thrombolytic used for the treatment of pulmonary emboli, on DVT in the same patients. 130 patients who were diagnosed with both pulmonary embolism and DVT were included in this study. Lower extremity Doppler ultrasonography (DUS) was conducted on all of the patients upon admission and then on the 6th month. The patients were divided into two groups. Patients in Group 1 were initially given 100 mg thrombolytic (r-tPA) intravenously and then standard anticoagulation therapy (enoxaparin sodium and warfarin). Patients in Group 2, however, were given only standard anticoagulation therapy (enoxaparin sodium and warfarin). In the 6th month DUS follow-up control for Group 1, out of 66 cases, the venous thrombosis of 54 patients were completely resolved, and the remaining 12 patients had residual vein occlusion (RVO). In Group 2, out of 64 cases, 41 patients were found to have complete resolution, while 23 patients continued to have RVO. This difference was statistically significant ($p=0.029$). OR was calculated to be 2.47. In other words, the risk of RVO was increased by 2.47 times in the patients who were not treated with r-tPA. Thrombolytic therapy of DVT should be considered more frequently to avoid complications of thrombosis, and DUS monitoring should be recommended before discontinuing anticoagulant therapy.

INTRODUCTION

Pulmonary embolism (PE) mostly occurs when the clots, which have originated from deep leg veins, break up and move to the lungs. Anticoagulants are the standard treatment of deep vein thrombosis (DVT) to dissolve venous thrombus and to reduce further new clot formation in order to prevent PE. Thrombolysis is another treatment that can be applied by using thrombolytic agents such as streptokinase, urokinase and recombinant tissue plasminogen activator (r-tPA) for dissolving the thrombus in the vein.^{1–3} These thrombolytic agents can be administered systemically by

Significance of this study

What is already known about this subject?

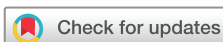- ▶ Pulmonary embolism (PE) mostly occurs when the clots, which have originated from deep leg veins, break up and then get transported to the lungs.
- ▶ Anticoagulants are the standard form of treatment used in deep vein thrombosis (DVT) to reduce the risk of developing a new thrombus and to prevent PE.
- ▶ Thrombolysis is another treatment that can be applied by using streptokinase, urokinase and recombinant tissue plasminogen activator (r-tPA) in order to dissolve the thrombus either by applying directly to thrombotic vein via catheter or by intravenous infusion to systemic circulation.

What are the new findings?

- ▶ The patients who had thrombolytic treatment showed statistically better improvement than the patients treated only by anticoagulants as per the lower extremity Doppler ultrasonography (DUS) results, which was conducted on the 6th month.
- ▶ Nearly one-third of the patients who were treated only by anticoagulants had residual vein obstruction in the lower extremities as observed on the DUS results on the 6th month.
- ▶ r-tPA, which was applied through the peripheral vein for the treatment of PE, also had a healing effect on the venous thrombosis.

infusing through a peripheral vein, regionally via a vein close to the clot or directly via a catheter to the occluding thrombus.^{2,3}

Thrombolytic drugs dissolve blood clots by activating plasminogen. This forms an enzyme called plasmin that breaks the links between the fibrin molecules, which make up the blood clots. Studies have shown the benefits of thrombolysis achieved mostly by using streptokinase and urokinase, and a few studies have reported the results of r-tPA treatment for DVT.^{4–7}



To cite: Er M. *J Investig Med* 2018;**66**:1045–1049.

Significance of this study

How might these results change the focus of research or clinical practice?

- ▶ The application of systemic thrombolytic treatment for DVT should be considered more often due to these promising positive results.
- ▶ Low extremity DUS monitoring should be conducted before stopping the anticoagulant treatment.
- ▶ Further studies with higher number of participants are needed to show and to compare the long-term effects of the thrombolytic treatment versus anticoagulant treatments such as warfarin or new oral anticoagulants.

To the best of our knowledge, there is no study investigating the effects of thrombolytic therapy of PE on the venous thrombosis in scientific literature. In our study, we aimed to investigate the effect of r-tPA on venous thrombosis, which was used during the treatment of PE.

MATERIALS AND METHODS**Study design**

This case-controlled retrospective clinical study was conducted on patients having PE besides DVT. Out of the 219 patients who were treated for PE, 130 patients who met the inclusion criteria were included in the study. The inclusion criterion was having a diagnosis of DVT besides PE. The study used clinical registrations of the patients who were enrolled in Ataturk Training and Research Hospital between the dates of May 2015 and May 2016. Before conducting the study, permission was obtained from the ethics committee of Ankara Yildirim Beyazit University. Patients who were under the age of 18, as well as those with renal impairment and those who did not have CT angiography (for any other reason) were excluded from the study.

Patients

Patients were diagnosed with PE by conducting CT pulmonary angiography. Lower extremity Doppler ultrasonography (DUS) monitoring was applied to all of the patients. During a follow-up check-up on the 6th month of the treatment, lower extremity DUS was repeated on most of the patients and the results were recorded.

Patients were divided into two groups according to their treatment. Sixty-six patients who were given thrombolytic therapy were classified as Group 1 and 64 patients having conventional treatment were classified as Group 2.

Implementation of the treatments

In Group 1, 100 mg r-tPA was administered from the forearm vein for over 2 hours and patients were monitored during the implementation of the treatment. Twelve hours after the treatment, weight-adjusted dose of enoxaparin sodium was started. Enoxaparin sodium was given for at least 5 days and warfarin was also started during this time. When the value of international normalized ratio (INR) had reached within the range of 2.0–3.0, the enoxaparin sodium treatment was stopped, and then the treatment was continued only with warfarin.

In Group 2, enoxaparin sodium was given to the patients without thrombolytic therapy. Patients received enoxaparin sodium for at least 5 days and warfarin was started at this time. When INR values reached the 2.0–3.0 range, the enoxaparin sodium treatment was stopped and the treatment was continued with only warfarin. Patients in both groups continued to receive warfarin up to 6 months while within the INR range of 2.0–3.0.

Imaging techniques

CT imaging was performed using multi-slice CT device (Aquillion 64, Toshiba, Tokyo, Japan), with 64×0.5 mm collimation, a 0.5 s rotation time and 3.5 cm/s gantry rotation table movement, with an average of 200 mAs and 120 kV parameters. The injection of contrast material was performed by Automatic CT Injector (Tyco OptiVantage CT Injection System). In all patients, 80 mL of contrast medium was given from the forearm vein under medical supervision with the injection rate of 4 mL/s. For all patients, 75% iohexol (Omnipaque 350, Amersham Health, Cork, Ireland) was used as the contrast material. Diagnostic imaging was performed using 'SureStart' software (Toshiba, Tokyo, Japan) and automated bolus triggering method. Diagnostic imaging was started automatically when the attenuation value had reached 150 Hounsfield unit at the region of interest in the main pulmonary artery.

Bilateral lower extremity DUS was conducted by using Toshiba Power Vision 6000 (Japan) device and the results were recorded. DUS was conducted with the patient in the supine position, and then both lower extremities, greater saphenous vein, femoral, deep femoral, superficial femoral and popliteal veins were viewed. Distal popliteal venous structures were evaluated indirectly by augmentation test. Any increase in the diameter in gray-scale, as well as non-compressibility, filling defect and reduction in the augmentation test were considered as signs for diagnosing DVT.⁸

The findings of residual vein obstruction (RVO) were evaluated by DUS, which was conducted on the 6th month of the treatment. If there was a sequel lesion with obstruction, then it was considered as RVO.

Statistical calculations

Demographic characteristics of the patients were calculated with basic statistics. Mean, SD, median, minimum and maximum values were applied for continuous variables, whereas for categorical variables, numbers and percentages were used. Independent sample t-test was used for calculation of significance between two independent groups. Limit of statistical significance was set as $p < 0.05$. To evaluate the possible effects on RVO development besides thrombolytic use, adjusted ORs were calculated with logistic regression analysis.

RESULTS

Out of the 219 patients with PE, only 130 of them were included in the study. The inclusion criterion was being diagnosed with DVT besides having PE. Thus, 59.4% of the patients diagnosed with PE in our clinic also were diagnosed with DVT. Patients were divided into two groups according to their treatment. The first group was comprised

of 66 patients having diagnosed with both PE and DVT and they were treated with thrombolytic agent alteplase (r-tPA). The second group included 64 patients being diagnosed with both PE and DVT and they were treated with anticoagulants (enoxaparin and warfarin). The mean ages of patients in Groups 1 and 2 were 59.0 and 61.5, respectively. The male to female rate of the patients was 32/34 in Group 1 and 30/34 in Group 2. There were no statistically significant differences between the age and gender characteristics of the two groups (table 1).

After 6 months of treatment, before deciding to stop the anticoagulant therapy, DUS monitoring was repeated on the lower extremities. According to the DUS results, in the first group, 12 patients (18%) who were allocated for systemic thrombolytic treatment had developed RVO. On the other hand, 23 patients (36%) who were allocated to the second group developed RVO ($p=0.029$). RVO was significantly lower in Group 1, compared with Group 2. OR about the presence of RVO on the 6th month was found as 2.47 (95% CI: (1.10 to 5.58)) in the anticoagulant group. In other words, the risk of having RVO after 6 months of anticoagulant treatment for DVT increased by 2.47 times without thrombolytic therapy. The results have been summarized in table 2.

None of the patients developed post-thrombotic syndrome (PTS) and there was no major bleeding in any groups. The difference of RVO between the groups has been shown with bar graphics in figure 1.

DISCUSSION

Lower extremity DVT is a common illness with an annual incidence rate of 1 per 1000 adults.⁹ Virchow's triad is still used to explain the mechanism of the formation of the thrombus in the venous system.^{10 11} Hypercoagulability, stasis and endothelial damage are the components of the triad.

The major immediate outcomes of acute DVT include thrombus progression, PE, phlegmasia alba dolens, phlegmasia cerulea dolens, venous gangrene and death. The standard treatment of acute DVT is with oral anticoagulation, which aims to prevent thrombus propagation and to reduce the risk of PE. The major long-term complication of DVT is PTS. PTS is a chronic illness characterized by limb swelling, pruritus, hyperpigmentation, pain and ulcers. It is thought to result from chronic venous hypertension, which results from damage to the venous valves by thrombosis. PTS may occur in up to 60% of patients within 2 years of an episode of DVT.¹⁰ It is traditionally managed conservatively with graded compression stockings and limb elevation.

If DVT is not resolved after traditional treatment, then RVO occurs. RVO is the presence of residual thrombus at

the site of an initial DVT after 3–6 months of anticoagulation treatment.^{12 13} A meta-analysis demonstrated that RVO was associated with a 1.3-fold increased risk of recurrent venous thromboembolism (VTE) (95% CI: 1.06 to 1.65) among patients with unprovoked DVT. RVO measured at the 3rd month was associated with a higher risk of recurrent VTE (HR: 2.17; 95% CI: (1.1 to 4.25)), while RVO detected beyond 6 months was not a significant predictor of recurrence risk (HR: 1.19; 95% CI: (0.87 to 1.61)).¹⁴ So, DUS evaluation seems to be important to establish a baseline at the end of therapy in case the patient reports symptoms that are potentially attributable to a new DVT. Since the symptoms of DVT and PTS can be difficult to differentiate, it is essential as well as useful to obtain baseline duplex studies at the end of therapy in patients who are at high risk for recurrence.¹⁵

Anticoagulants are the standard treatment for DVT, while thrombolysis is another treatment method by using streptokinase, urokinase and r-tPA to dissolve the thrombus in the vein. Thrombolytic agents can be administered systemically by infusing through a peripheral vein, locoregionally via a vein close to the clot or directly with a catheter to the occluding thrombus.^{2 16–18}

Catheter-directed thrombolysis (CDT) seems more reliable than systemic anticoagulation, because of low PTS scores such as less bleeding. The CaVenT (catheter-directed thrombolysis for deep vein thrombosis) trial has shown that CDT is associated with a 26% relative risk (RR) PTS reduction over 2 years (41.1% vs 55.6%, $p=0.04$) as compared with anticoagulation alone. There were no intracranial bleeds or deaths, but 3.2% of patients had major bleeding.^{19 20}

For patients with acute iliofemoral DVT, it remains unclear whether the addition of intravascular high-frequency, low-power ultrasound energy facilitates the resolution of thrombosis during CDT. In a study of 48 patients with acute iliofemoral DVT, the patients were randomly chosen to receive ultrasound-assisted CDT ($n=24$) or conventional CDT ($n=24$) with a regimen of 20 mg r-tPA over 15 hours for all patients. The difference of thrombus load reduction was not found to be significant between the groups ($p=0.91$). So, it is shown that the addition of intravascular ultrasound to fixed-dose catheter thrombolysis regimen did not facilitate thrombus resolution.²¹

Since our clinic functions as a department of pulmonary diseases, 219 patients with PE were treated in our clinic within a 1-year period and 59.4% of these patients were also diagnosed with deep venous thrombosis. Patients with PE having massive or high mortality risk for

Table 1 Demographic characteristics of the groups

	Thrombolytic (Group 1) n=66	Anticoagulant (Group 2) n=64	P
Age			
Mean	59.0	61.5	0.330
SD	14.4	15.3	
Median (range)	57.5 (30–87)	61.5 (32–89)	
Female gender n (%)	34 (51.5)	34 (53.1)	0.854

Table 2 RVO difference between two groups on 6th month Doppler ultrasonography control

	Thrombolytic (Group 1) n (%)	Anticoagulant (Group 2) n (%)	Adj OR (95% CI)	P
RVO (–)	54 (82)	41 (64)		
RVO (+)	12 (18)	23 (36)	2.47 (1.10 to 5.58)	0.029
Total	66 (51)	64 (49)		

Adj. OR, adjusted OR (adjusted for age and gender); RVO, residual vein obstruction.

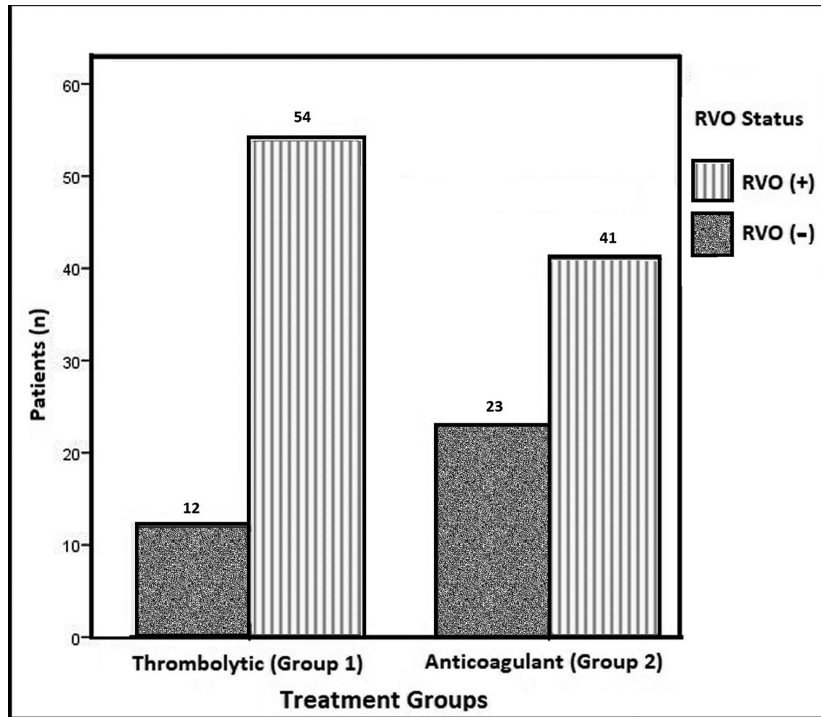


Figure 1 Residual vein obstruction (RVO) seen in the groups by Doppler ultrasonography on the 6th month.

submassive PE were treated by r-tPA 100 mg in 2 hours. This retrospective study showed that r-tPA given through the peripheral vein for the treatment of PE also had a healing effect on the venous thrombosis. Monitoring with DUS on the 6th month revealed that the patients who had thrombolytic treatment showed statistically better improvement compared with patients in Group 2, who were treated by anticoagulants only ($p=0.029$). Nearly one-third of the patients in Group 2 had RVO observed during the DUS monitoring (conducted at the 6th month) of lower extremities. In the logistic regression analysis, OR was calculated as 2.47 in our study by comparing group using anticoagulants versus group using thrombolytic in terms of RVO development risk. In other words, it was observed that the risk of RVO had been increased by 2.47 times in the patients who had not undergone thrombolytic therapy.

In our clinic, the patients who have DVT are routinely evaluated by DUS on the 6th month of their treatment in order to continue the treatment of DVT, in case the DUS finding shows RVO.

CONCLUSION

Thrombolysis has advantages over anticoagulation since by dissolving the thrombus in the acute phase, venous valvular function may be preserved, thus reducing the risk of post-thrombotic complications in the long term. Although thrombolysis has become the established treatment for acute myocardial infarction and for massive PE, it is rarely used for acute DVT.

However, this study may be regarded as a preliminary study; it may lead the way for further studies that can be planned for future.

As a result, we recommend thrombolytic treatment (r-tPA) of DVT more frequently and also we recommend DUS check-up before stopping the anticoagulant treatment. More studies are needed to show and compare the long-term effects of the thrombolytic treatment versus anticoagulant treatments such as warfarin or new oral anticoagulants.

Acknowledgements The author especially thanks to H Canan Hasanoglu for encouraging and inspiring him to perform the study and also thanks to Adem Koyuncu for registration of the patients on computer.

Funding The author has not declared a specific grant for this research from any funding agency in the public, commercial or not-for-profit sectors.

Competing interests None declared.

Patient consent Obtained.

Ethics approval Ethics committee of Ankara Yildirim Beyazit University, Turkey.

Provenance and peer review Not commissioned; externally peer reviewed.

© American Federation for Medical Research (unless otherwise stated in the text of the article) 2018. All rights reserved. No commercial use is permitted unless otherwise expressly granted.

REFERENCES

- Vedantham S, Piazza G, Sista AK, *et al.* Guidance for the use of thrombolytic therapy for the treatment of venous thromboembolism. *J Thromb Thrombolysis* 2016;41:68–80.
- Mazzolai L, Aboyans V, Ageno W, *et al.* Diagnosis and management of acute deep vein thrombosis: a joint consensus document from the European Society of Cardiology working groups of aorta and peripheral circulation and pulmonary circulation and right ventricular function. *Eur Heart J* 2017;00:1–14.
- Wang KL, Chu PH, Lee CH, *et al.* Management of venous thromboembolism: part I. The consensus for deep vein thrombosis. *Acta Cardiol Sin* 2016;32:1–22.
- Watson L, Broderick C, Armon MP. Thrombolysis for acute deep vein thrombosis. *Cochrane Database of Systematic Reviews* 2014;23:CD002783.
- Goldhaber SZ, Hirsch DR, MacDougall RC, *et al.* Bolus recombinant urokinase versus heparin in deep venous thrombosis: a randomized controlled trial. *Am Heart J* 1996;132:314–8.

- 6 Hirsh J, Turpie AG. Use of plasminogen activators in venous thrombosis. *World J Surg* 1990;14:688–93.
- 7 Leary SE, Harrod VL, de Alarcon PA, *et al.* Low-dose systemic thrombolytic therapy for deep vein thrombosis in pediatric patients. *J Pediatr Hematol Oncol* 2010;32:97–102.
- 8 Zierler BK. Ultrasonography and diagnosis of venous thromboembolism. *Circulation* 2004;109:9–14.
- 9 White RH. The epidemiology of venous thromboembolism. *Circulation* 2003;107:41–8.
- 10 Sundar G, Keshava SN, Moses V, *et al.* Outcomes of catheter-directed treatment of lower extremity deep vein thrombosis of patients presenting to a tertiary care hospital. *Indian J Radiol Imaging* 2016;26:73–80.
- 11 Ventura HO. Profiles in cardiology. Rudolph Virchow and cellular pathology. *Clin Cardiol* 2000;23:55–2.
- 12 Janakiram M, Sullivan M, Shcherba M, *et al.* Research article a systematic review of the utility of residual vein obstruction studies in primary and secondary venous thrombosis. Hindawi Publishing Corporation. *Thrombosis* 2013;247913:1–9.
- 13 Carrier M, Rodger MA, Wells PS, *et al.* Residual vein obstruction to predict the risk of recurrent venous thromboembolism in patients with deep vein thrombosis: a systematic review and meta-analysis. *J Thromb Haemost* 2011;9:1119–25.
- 14 Donadini MP, Ageno W, Antonucci E, *et al.* Prognostic significance of residual venous obstruction in patients with treated unprovoked deep vein thrombosis: a patient-level meta-analysis. *Thromb Haemost* 2014;111:172–9.
- 15 Siragusa S, Malato A, Anastasio R, *et al.* Residual vein thrombosis to establish duration of anticoagulation after a first episode of deep vein thrombosis: the Duration of Anticoagulation based on Compression UltraSonography (DACUS) study. *Blood* 2008;112:511–5.
- 16 Tichelaar VY, Brodin EE, Vik A, *et al.* A retrospective comparison of ultrasound-assisted catheter-directed thrombolysis and catheter-directed thrombolysis alone for treatment of proximal deep vein thrombosis. *Cardiovasc Intervent Radiol* 2016;39:1115–21.
- 17 Streiff MB, Agnelli G, Connors JM, *et al.* Guidance for the treatment of deep vein thrombosis and pulmonary embolism. *J Thromb Thrombolysis* 2016;41:32–67.
- 18 Alesh I, Kayali F, Stein PD. Catheter-directed thrombolysis (intrathrombus injection) in treatment of deep venous thrombosis: a systematic review. *Catheter Cardiovasc Interv* 2007;70:145–50.
- 19 Enden T, Haig Y, Kløw NE, *et al.* Long-term outcome after additional catheter-directed thrombolysis versus standard treatment for acute iliofemoral deep vein thrombosis (the CaVenT study): a randomised controlled trial. *Lancet* 2012;379:31–8.
- 20 Haig Y, Enden T, Grøtta O, *et al.* Post-thrombotic syndrome after catheter-directed thrombolysis for deep vein thrombosis (CaVenT): 5-year follow-up results of an open-label, randomised controlled trial. *Lancet Haematol* 2016;3:e64–71.
- 21 Engelberger RP, Spirk D, Willenberg T, *et al.* Ultrasound-assisted versus conventional catheter-directed thrombolysis for acute iliofemoral deep vein thrombosis. *Circ Cardiovasc Interv* 2015;8:e002027.