



Utility of serum neuropilin-1 and angiopoietin-2 as markers of hepatocellular carcinoma

Muhammad Tarek Abdel Ghafar ¹, Reham A Elkhoully,²
Mohammed H Elnaggar,³ Mohamed M Mabrouk,³ Sara A Darwish,⁴
Reham L Younis,⁵ Rasha A Elkholy ¹

► Additional material is published online only. To view, please visit the journal online (<http://dx.doi.org/10.1136/jim-2020-001744>).

¹Clinical Pathology, Tanta University Faculty of Medicine, Tanta, Egypt

²Tropical Medicine, Tanta University Faculty of Medicine, Tanta, Egypt

³Internal Medicine, Tanta University Faculty of Medicine, Tanta, Egypt

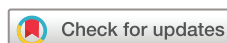⁴Clinical Oncology and Nuclear Medicine, Tanta University Faculty of Medicine, Tanta, Egypt

⁵Physiology, Tanta University Faculty of Medicine, Tanta, Egypt

Correspondence to

Dr Muhammad Tarek Abdel Ghafar, Clinical Pathology, Tanta University Faculty of Medicine, Tanta 31511, Egypt; mohammedtarek5514@yahoo.com

Accepted 9 March 2021
Published Online First 8 April 2021



© American Federation for Medical Research 2021. No commercial re-use. See rights and permissions. Published by BMJ.

To cite: Abdel Ghafar MT, Elkhoully RA, Elnaggar MH, et al. *J Invest Med* 2021;**69**:1222–1229.

ABSTRACT

This study aimed to assess the diagnostic value of two serum angiogenetic markers neuropilin-1 (NRP-1) and angiopoietin-2 (ANG-2) in patients with hepatocellular carcinoma (HCC) and their relation to tumor characteristics. 149 subjects were recruited and divided into 50 patients with recently diagnosed HCC, 49 patients with cirrhosis on top of hepatitis C virus infection, and 50 healthy subjects. Serum NRP-1 and ANG-2 were estimated by ELISA. Alpha-fetoprotein (AFP) levels were measured using fluorescence immunoassay. Serum NRP-1 and ANG-2 levels were significantly higher in patients with HCC (2221.8 ± 1056.6 pg/mL and 3018.5 ± 841.4 pg/mL) than healthy subjects (219.3 ± 61.8 pg/mL and 2007.7 ± 904.8 pg/mL) and patients with cirrhosis (1108.9 ± 526.6 pg/mL and 2179.1 ± 599.2 pg/mL), respectively. In multivariate logistic regression analysis, NRP-1 and AFP were the only independent factors of HCC development and correlated positively with each other ($r=0.781$, $p<0.001$). Receiver operating characteristic curve analysis showed that the area under the curve (AUC) of NRP-1 was higher than that of ANG-2 in discriminating HCC from patients with cirrhosis (0.801 vs 0.748, $p=0.250$) and healthy subjects (0.992 vs 0.809, $p<0.001$). The AUC of NRP-1 was detected to be increased (0.994) when combined estimation with AFP was performed. Elevated serum NRP-1 and ANG-2 levels were detected in patients with HCC with tumor numbers >3 , tumor size ≥ 5 cm, tumor stages B/C according to the Barcelona Clinic Liver Cancer staging system, vascular invasion, and distant metastasis. In conclusion, NRP-1 is a potential serological marker for HCC diagnosis and is better than ANG-2. It is feasible to be estimated in combination with AFP to enhance its diagnostic power. High serum NRP-1 and ANG-2 levels are associated with advanced HCC tumor characteristics.

INTRODUCTION

Hepatocellular carcinoma (HCC) is the sixth most common malignancy and the fourth leading cause of cancer-related mortality

Significance of this study

What is already known about this subject?

- Angiogenesis is a crucial factor in promoting tumor growth and metastasis of various malignancies including hepatocellular carcinoma (HCC).
- Several angiogenic pathways are dysregulated in HCC and involved in HCC pathogenesis.

What are the new findings?

- The diagnostic efficacy of serum neuropilin-1 (NRP-1) is higher than that of serum angiopoietin-2 (ANG-2) for HCC.
- The diagnostic power of NRP-1 is enhanced when estimated in combination with alpha-fetoprotein (AFP).
- Elevated serum NRP-1 and ANG-2 were associated with increased tumor number, tumor size, advanced HCC clinical stages, vascular invasion, and distant metastasis.

How might these results change the focus of research or clinical practice?

- NRP-1 is a potential serological marker for the diagnosis of HCC and should be measured in combination with AFP.
- Also, NRP-1 and ANG-2 are associated with advanced HCC characteristics.

worldwide in 2018.¹ Most cases of HCC had developed on top of chronic hepatitis infections caused by either hepatitis B virus (HBV) or hepatitis C virus (HCV). In Egypt, due to the high prevalence of HBV and HCV chronic infections, HCC came on top of solid malignancies.²

Due to the absence of symptoms of early HCC and the lack of its effective screening strategies, most patients with HCC are diagnosed with late-stage disease after metastasis has occurred, resulting in a very poor prognosis and a low overall 5-year survival rate of $<16\%$.³ Therefore, early detection of HCC is essential to improve patients' survival.⁴ The American Association for the Study of Liver Diseases (AASLD) once recommended serum alpha-fetoprotein (AFP) as

a screening test for HCC surveillance in patients with hepatic cirrhosis.⁵ However, one major disadvantage is that AFP levels can be falsely elevated in patients who have active hepatitis with no evidence of HCC. Also, about one-third of HCC cases have normal serum AFP especially when tumor size is less than 2 cm.⁶ The role of biomarkers in various malignancies has emerged,^{7–11} and thus searching for novel serological biomarkers is needed for screening HCC to reduce its high mortality.

Hepatic tumorigenesis is a multistep complicated process characterized by uncontrolled cellular proliferation and increased angiogenesis to enhance tumor growth. There is evidence that angiogenesis plays a vital role in the development and progression of HCC.¹²

Neuropilin-1 (NRP-1) is a transmembrane glycoprotein that is primarily found to play a role in neuronal axon guidance and embryonic angiogenesis.¹³ It was described as a coreceptor for vascular endothelial growth factors (VEGFs) and for secreted semaphorins in association with VEGF receptors or plexins, respectively. However, it was shown that NRP-1 also interacts with epidermal growth factor receptor (EGFR) on the cell surface, enhancing ligand-induced EGFR clustering and intracellular signaling.¹⁴ Additional growth factor-induced signaling cascades have been associated with NRP-1, although the implicated molecular mechanisms remain largely unclear.¹⁵ Thus, NRP-1 seems to act as a receptor hub on the cell surface, promoting multiple signaling cascades.¹⁶ NRP-1 can encourage different aspects of tumorigenesis, such as angiogenesis, cell survival, migration, invasion, and chemoresistance.¹⁷ NRP-1 is reported to be upregulated in several tumors including astrocytomas, breast, prostate, lung, pancreas, bile duct, gastric, and colon cancers. Overexpression of NRP-1 is closely correlated with the infiltration and migration of tumors.¹⁸ The contribution of NRP-1 and its ligands to tumor growth and metastasis has spurred a strong interest in NRP-1 antagonists used in combination with anti-VEGF chemotherapy as novel antiangiogenesis therapies.¹⁹ Previous studies have reported that NRP-1 is overexpressed in HCC tissue compared with normal tissue,^{20,21} but the use of serum NRP-1 as a diagnostic marker for HCC continues to be a subject of interest especially when compared with AFP.

Angiopoietins have been identified as ligands for vascular endothelial-specific Tie2 receptor tyrosine kinase and may be important growth factors in the generation of new blood vessels.²² Angiopoietin-2 (ANG-2), a member of the angiopoietins, is thought to have a remarkable role in angiogenesis.²³ A previous study¹⁸ showed that increased ANG-2 can result in persistent disruption of the cellular crosstalk between endothelial cells and pericytes. Furthermore, high concentrations of ANG-2 are considered to function as antiapoptotic factors in endothelial cells by activating the phosphatidylinositol 3'-kinase/Akt signaling pathway.²⁴ Levels of ANG-2 mRNA expressions have been reported to be significantly increased in HCC,²⁵ non-small cell lung cancer,²⁶ and gastric cancer²⁷ compared with adjacent non-cancerous components. This increased expression may play a critical role in promoting tumor angiogenesis and progression.²⁵

The purpose of the current study was to measure serum levels of NRP-1 and ANG-2 to determine its potential diagnostic utility in patients with HCC and to determine their relation to the tumor characteristics in these patients.

PATIENTS AND METHODS

Patients and samples

This is a retrospective study carried out in the internal medicine, tropical medicine, clinical oncology and nuclear medicine, physiology and clinical pathology departments of Tanta University Hospitals, Egypt. A total of 149 subjects were included in our study in a convenience series, and they were divided into three groups: group I: 50 patients recently diagnosed with HCC; group II: 49 patients suffering from liver cirrhosis on top of HCV infection; and group III: 50 apparently healthy individuals matched in age and sex, which served as the control group. The diagnosis of HCC was made on histopathological confirmation of hepatic focal lesions, or if not available clinical and radiological HCC diagnosis based on the guidelines of the AASLD.²⁸ The staging was made according to the Barcelona Clinic Liver Cancer (BCLC) staging system.²⁹ Patients suffering from any malignant diseases other than HCC or those with HCC who received treatment were excluded from the study. Patients' flow throughout this study is demonstrated in online supplemental figure S1.

Informed consent was obtained from both the patients and the control group.

All patients were subjected to the following: full history taking, thorough clinical examination, and radiological investigations including abdominal ultrasonography and CT. Lower limb edema was examined clinically, whereas ascites was assessed by physical examination and abdominal ultrasonography and graded according to the European Association for the Study of the Liver³⁰ as follows: grade 1 was defined as mild ascites only detectable by ultrasound, grade 2 was defined as moderate ascites evident by moderate symmetrical distension of the abdomen, and grade 3 was defined as large or gross ascites with marked abdominal distension. The Child-Pugh-Turcotte class was determined and the Model for End-Stage Liver Disease (MELD) score was calculated for patients with HCC and cirrhosis according to published guidelines.^{31,32}

Blood collection for patients and control groups

Whole blood was collected by standard venipuncture in VACUETTE Blood Collection Tubes (Greiner Bio-One, Kremsmuenster, Austria) containing 0.109 mol/L (3.2%) buffered sodium citrate solution for prothrombin time determination using fully automated blood coagulation analyzer (Sysmex CA 1500, Siemens Healthcare Global, Erlangen, Germany), K₂EDTA for complete blood picture (complete blood count) on fully automated cell counter (Erma, PCE 210N, Tokyo, Japan), and a tube containing clot activator/Sep; after centrifugation, one part of the serum samples was stored at –20°C for assay of NRP-1 and ANG-2, and the other part was immediately used for routine laboratory investigations including liver function tests (LFT) on fully automated chemistry analyzer (Konelab Prime 60i, Vantaa, Finland) and AFP on automated fluorescence immunoassay

analyzers (Tosoh AIA 1800 ST, Tokyo, Japan). The results were interpreted separately by independent investigators, who were blinded to other laboratory results as well as clinical, radiological, and diagnostic findings of the study subjects.

Serum NRP-1 determination

Serum NRP-1 level was measured using a commercially available, quantitative sandwich enzyme immunoassay technique (Human Neuropilin-1, Abcam ELISA Kit, catalog number ab227901, Minneapolis, USA) in accordance with the manufacturer's instructions. The sensitivity is 7 pg/mL. The intra-assay coefficient of variation (CV%) and inter-assay CV% were 1.9% and 3%, respectively.

Serum ANG-2 determination

Serum ANG-2 level was measured using a commercially available, quantitative sandwich enzyme immunoassay technique (Human Angiopoietin-2, Quantikine ELISA Kit, catalog number DANG20, R&D Systems, Minneapolis, USA) in accordance with the manufacturer's instructions. The sensitivity is 8.29 pg/mL. The intra-assay CV% and interassay CV% were 4.2%–6.9% and 7.4%–10.4%, respectively.

Statistical analysis

The analyses and graphs of the current study results were performed using IBM SPSS V.24, MedCalc V.18, and GraphPad Prism. Shapiro-Wilk test was conducted to check for normal distribution of dependent variables. Normally distributed numerical results were compared between the studied groups by Student's t-test. One-way analysis of variance with post-hoc test was used to compare the results among more than two groups. Non-parametric numerical results were compared by Mann-Whitney U test. Univariate

and multivariate logistic regression analyses were used to determine the related covariables with HCC development. Pearson correlation was used for correlating serum AFP with NRP-1 and ANG-2 levels. These markers were combined using binary logistic regressions, and their diagnostic characteristics were determined by receiver operating characteristic (ROC) curve analyses. The optimal cut-off value for each marker was assessed via Youden's index. P values were considered significant if they are less than 0.05.

Sample size calculation

We conducted a power analysis (G Power V3.1 statistical software, Franz Faul, Universität Kiel Germany) based on a previous study.³³ The findings indicated a minimum sample size of 66 samples (22 samples for each group) based on an α of 5% and a power of 95%. Considering a possible loss of about 10% of patients, we should use a minimum of 75 samples (25 samples for each group).

RESULTS

Clinicopathological characteristics of study subjects

A total of 149 subjects were recruited to this study as follows: 50 patients recently diagnosed with HCC, 49 patients with cirrhosis on top of HCV infection, and 50 healthy subjects as the control group. There was no significant difference in age and sex among the three groups ($p=0.422$, $p=0.720$), respectively. Regarding the laboratory data, there was a statistically significant difference in LFT and international normalized ratio (INR) among the three groups. Serum AFP, NRP-1, and ANG-2 levels were significantly higher in the HCC group than in the control and cirrhotic groups ($p<0.001$) (table 1). Patients with cirrhosis have a mean MELD score of 18.4 ± 5.4 . There were six cases with Child A, 28 with Child B, and 15 with Child C. Patients with HCC have a mean MELD score of 16.9 ± 6.0 , with no significant

Table 1 Demographic, clinical and laboratory characteristics of the studied groups

Characteristics	Group I (HCC) (n=50)	Group II (cirrhosis) (n=49)	Group III (healthy control) (n=50)	P value
Age (years)	59.2 \pm 6.7	58.8 \pm 6.3	57.5 \pm 7.1	0.422
Gender, n (%)				0.720
Male	27 (54.0)	23 (46.9)	27 (54.0)	
Female	23 (46.0)	26 (53.1)	23 (46.0)	
Ascites, n (%)	26 (52.0)	33 (67.3)	–	0.120
Lower limb edema, n (%)	34 (68.0)	39 (79.6)	–	0.190
Total bilirubin (mg/dL)	2.2 \pm 1.2†	2.4 \pm 0.9†	0.6 \pm 0.2	<0.001*
ALT (U/L)	76 \pm 32†	68 \pm 19†	20 \pm 6	<0.001*
AST (U/L)	95 \pm 43†	79 \pm 25†	24 \pm 7	<0.001*
ALK (U/L)	96 \pm 29†	106 \pm 27†	64 \pm 19	<0.001*
Albumin (g/dL)	2.7 \pm 0.8†	2.5 \pm 0.4†	4.0 \pm 0.4	<0.001*
INR	1.9 \pm 0.7†	2.1 \pm 0.7†	1.0 \pm 0.1	<0.001*
AFP (ng/mL)	356.1 \pm 257.3†‡	155.2 \pm 65.6†	4.9 \pm 2.0	<0.001*
NRP-1 (pg/mL)	2221.8 \pm 1056.6†‡	1108.9 \pm 526.6†	219.3 \pm 61.8	<0.001*
ANG-2 (pg/mL)	3018.5 \pm 841.4†‡	2179.1 \pm 599.2	2007.7 \pm 904.8	<0.001*

Data are expressed as mean \pm SD.

*P<0.05 significant.

†Significant with group III.

‡Significant with group II.

AFP, alpha-fetoprotein; ALK, alkaline phosphatase; ALT, alanine transaminase; ANG-2, angiopoietin-2; AST, aspartate transaminase; HCC, hepatocellular carcinoma; INR, international normalized ratio; NRP-1, neuropilin-1.

Table 2 Relationship between HCC and demographic and biochemical variables

	P value	Univariate analysis		Multivariate analysis	
		OR (95% CI)	P value	OR (95% CI)	
Age (years)	0.389	–	–	–	
Gender (male vs female)	0.687	–	–	–	
Total bilirubin (mg/dL)	0.001*	1.688 (1.243 to 2.293)	0.242	–	
ALT (U/L)	<0.001*	1.036 (1.022 to 1.051)	0.923	–	
AST (U/L)	<0.001*	1.030 (1.018 to 1.041)	0.270	–	
ALK (U/L)	0.044*	1.012 (1.000 to 1.023)	0.121	–	
Albumin (g/dL)	<0.001*	0.434 (0.278 to 0.679)	0.152	–	
INR	0.029*	1.067 (1.055 to 2.641)	0.137	–	
AFP (ng/mL)	<0.001*	1.012 (1.007 to 1.016)	0.001*	1.016 (1.006 to 1.026)	
NRP-1 (pg/mL)	<0.001*	1.002 (1.001 to 1.003)	0.002*	1.002 (1.001 to 1.003)	
ANG-2 (pg/mL)	<0.001*	1.001 (1.001 to 1.002)	0.122	–	

*P<0.05 significant.

AFP, alpha-fetoprotein; ALK, alkaline phosphatase; ALT, alanine transaminase; ANG-2, angiopoietin-2; AST, aspartate transaminase; HCC, hepatocellular carcinoma; INR, international normalized ratio; NRP-1, neuropilin-1.

differences in MELD score detected between the cirrhotic and HCC groups ($p=0.186$). There were seven cases with Child A and 43 cases with Child B. All patients with HCC have HCV infection with no history of HCV eradication until the time of recruitment. Additionally, we investigated the characteristics of patients with liver cancer, including tumor stage, tumor numbers, tumor size, vascular invasion, and distant metastasis. Thirty-three patients (66%) had tumor numbers >3, 19 (38%) had tumor size ≥ 5 cm, 20 (40%) had vascular invasion, and 5 (10%) had distant metastasis. Moreover, 4 patients (8.0%) were presented in stage 0, 13 patients (26%) in stage A, 12 patients (24%) in stage B, and 21 patients (42%) in stage C according to the BCLC staging system.

Demographic and biochemical covariables in relation to HCC

Logistic regression analyses were performed to detect the related covariables for HCC development. In univariate analysis, total bilirubin, aspartate transaminase, alanine transaminase, albumin, INR, AFP, NRP-1, and ANG-2 were significantly associated with HCC development, while age and sex were non-significant variables. In multivariate analysis, AFP and NRP-1 remained the only significant independent factors with HCC (table 2).

Diagnostic value of NRP-1 and ANG-2

As serum NRP-1 and ANG-2 levels were significantly higher in patients with HCC than in healthy subjects and patients with cirrhosis, we used ROC curve analysis to evaluate the diagnostic efficacy of both markers in discriminating HCC from healthy subjects or patients with cirrhosis compared with AFP.

The area under the ROC curve (AUC) indicated that NRP-1 had the highest diagnostic efficacy in differentiating HCC from healthy subjects (AUC 0.992), which is slightly higher than that of AFP (AUC 0.983) with no significant AUC difference (0.009, $p=0.431$) and that of ANG-2 (AUC 0.809) with significant AUC difference (0.183, $p<0.001$) (table 3, figure 1). Moreover, the diagnostic efficacy of NRP-1 (AUC 0.801) in discriminating HCC from patients with cirrhosis was higher than that of AFP (AUC 0.762) with no significant AUC

difference (0.039, $p=0.465$), and also higher than that of ANG-2 (AUC 0.748) with no significant AUC difference (0.053, $p=0.250$) (table 3, figure 1).

Using Pearson correlation analysis, serum NRP-1 and ANG-2 correlated positively with each other and with AFP ($p<0.001$) (figure 2). Linear regression analysis revealed that NRP-1 is independently related to AFP ($p<0.001$), whereas no significant relation was detected between ANG-2 and AFP ($p=0.225$). Therefore, we suggested that NRP-1 and AFP be considered as the best combination. Based on these results, the combined analysis of NRP-1 and AFP revealed that the AUC of combined AFP and NRP-1 (AUC 0.825) was slightly higher than that of NRP-1, AFP, and ANG-2 in differentiating HCC from patients with cirrhosis, with no significant AUC differences. Also, the AUC of combined AFP and NRP-1 (AUC 0.994) was slightly higher than that of NRP-1, AFP, and ANG-2 in differentiating HCC from healthy controls, with no significant AUC differences except with ANG-2 (0.184, $p<0.001$) (table 3, figure 1).

Biomarkers correlation with clinicopathological features in HCC

In patients with HCC, serum NRP-1 and ANG-2 levels were significantly higher in BCLC stages B and C than stages 0 and A. Moreover, serum NRP-1 and ANG-2 levels were significantly higher in patients with HCC with tumor numbers >3 ($p<0.001$, $p<0.001$), tumor size ≥ 5 cm ($p=0.001$, $p=0.032$), as well as the presence of vascular invasion ($p=0.001$, $p<0.001$) and distant metastasis ($p=0.008$, $p=0.033$), respectively (figure 3).

DISCUSSION

In the present study, we studied two serum angiogenetic markers, NRP-1 and ANG-2, in patients with newly diagnosed HCC, searching for their role in the early diagnosis of HCC and their relationship with tumor characteristics. Accordingly, 50 untreated patients with HCC were enrolled and their serum levels of NRP-1 and ANG-2 were estimated and compared with that of 49 patients with liver cirrhosis on top of HCV infection

Table 3 ROC curve analysis of serum NRP-1 and ANG-2 performance characteristics among the studied groups

	AUC	95% CI	P value	Cut-off	Sensitivity	Specificity
Serum NRP-1						
Patients with HCC (group I) vs patients with liver cirrhosis (group II)	0.801	0.709 to 0.875	<0.001*	>1418	72.0	87.8
Patients with HCC (group I) vs healthy controls (group III)	0.992	0.949 to 1.000	<0.001*	>367	96.0	98.0
Serum ANG-2						
Patients with HCC (group I) vs patients with liver cirrhosis (group II)	0.748	0.651 to 0.830	<0.001*	>2780	60.0	73.5
Patients with HCC (group I) vs healthy controls (group III)	0.809	0.719 to 0.881	<0.001*	>2679	66.0	84.0
Serum AFP						
Patients with HCC (group I) vs patients with liver cirrhosis (group II)	0.762	0.666 to 0.842	<0.001*	>188.0	74.0	75.5
Patients with HCC (group I) vs healthy controls (group III)	0.983	0.934 to 0.998	<0.001*	>7.9	96.0	90.0
Combined analysis (serum NRP-1+AFP)						
Patients with HCC (group I) vs patients with liver cirrhosis (group II)	0.825	0.736 to 0.894	<0.001*	–	64.0	100.0
Patients with HCC (group I) vs healthy controls (group III)	0.994	0.952 to 1.000	<0.001*	–	96.0	100.0

*P<0.05 significant.

AFP, alpha-fetoprotein; ANG-2, angiopoietin-2; AUC, area under the curve; HCC, hepatocellular carcinoma; NRP-1, neuropilin-1; ROC, receiver operating characteristic.

and 50 apparently normal healthy individuals comparable in age and sex as the control group.

This study showed that serum NRP-1 levels were significantly higher in patients with HCC compared with the healthy subjects and patients with cirrhosis. Our results are in agreement with Lin *et al*³⁴ and Abugabal *et al*,³⁵ who reported that serum NRP-1 levels in patients with HCC were significantly higher than that of patients with cirrhosis and healthy control subjects. Moreover, our study revealed that patients with cirrhosis have significantly increased serum NRP-1 levels compared with healthy subjects. The same findings were reported by Lin *et al*'s study.³⁴

In addition, patients with HCC showed significantly higher serum ANG-2 levels than patients with cirrhosis and healthy subjects in the present study. In agreement with our

findings, Chen *et al*,³³ Scholz *et al*,³⁶ and Sharma *et al*³⁷ reported that serum ANG-2 levels in patients with HCC were significantly higher than that in patients with cirrhosis and healthy subjects. However, Pestana *et al*³⁸ reported no difference in serum ANG-2 levels between HCC and cirrhosis. Moreover, no significant differences in serum ANG-2 levels between patients with cirrhosis and healthy controls were observed in this study, as also reported by Sharma *et al*'s study.³⁷ Contradictory to our results, Chen *et al*,³³ Scholz *et al*,³⁶ and Pestana *et al*³⁸ reported statistically significant differences in serum ANG-2 levels between patients with cirrhosis and healthy subjects.

Among the demographic and biochemical variables, NRP-1, ANG-2, and AFP were significantly associated with HCC development in univariate analysis. However, NRP-1 and AFP were the only independent factors for HCC development in the multivariate logistic regression analysis and correlated positively with each other. These results highlight the value of NRP-1 compared with ANG-2 as an independent factor of HCC. In the same context, Lin *et al*³⁴ reported a significant positive correlation between serum levels of NRP-1 and AFP. Pestana *et al*³⁸ and Chen *et al*³³ reported that serum ANG-2 levels were positively correlated with AFP.

In this study, we found that elevated serum NRP-1 and ANG-2 levels were detected in patients with HCC with increased tumor numbers >3, tumor size ≥5 cm, advanced tumor BCLC stages (B and C), and the presence of vascular invasion and distant metastasis. Similar findings were reported by many previous studies. For instance, Abugabal *et al*³⁵ detected that higher plasma levels of NRP-1 were significantly associated with advanced BCLC stages and the presence of vascular invasion. Lin *et al*³⁴ also reported that high serum NRP-1 levels were significantly associated with advanced HCC stages. Moreover, Zhang *et al*²⁰ reported that high NRP-1 expression was significantly associated with portal vein invasion, and Chen *et al*²¹ reported that TNM (tumor, node, metastasis) staging and vascular

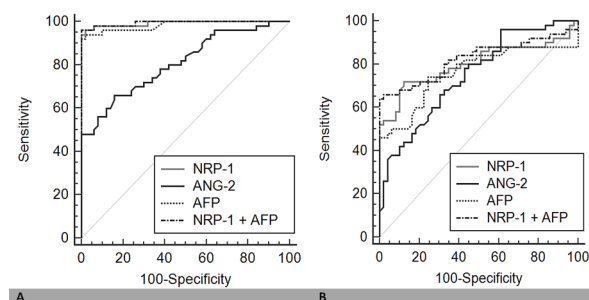


Figure 1 ROC curve analysis of the performance characteristics of the studied serological markers (NRP-1, ANG-2, and AFP), either solely or combined, in differentiating HCC from cirrhosis and healthy subjects: (A) NRP-1, ANG-2, AFP, and combined NRP-1+AFP in differentiating patients with HCC from healthy subjects; and (B) NRP-1, ANG-2, AFP, and combined NRP-1+AFP in differentiating patients with HCC from patients with liver cirrhosis. AFP, alpha-fetoprotein; ANG-2, angiopoietin-2; HCC, hepatocellular carcinoma; NRP-1, neuropilin-1; ROC, receiver operating characteristic.

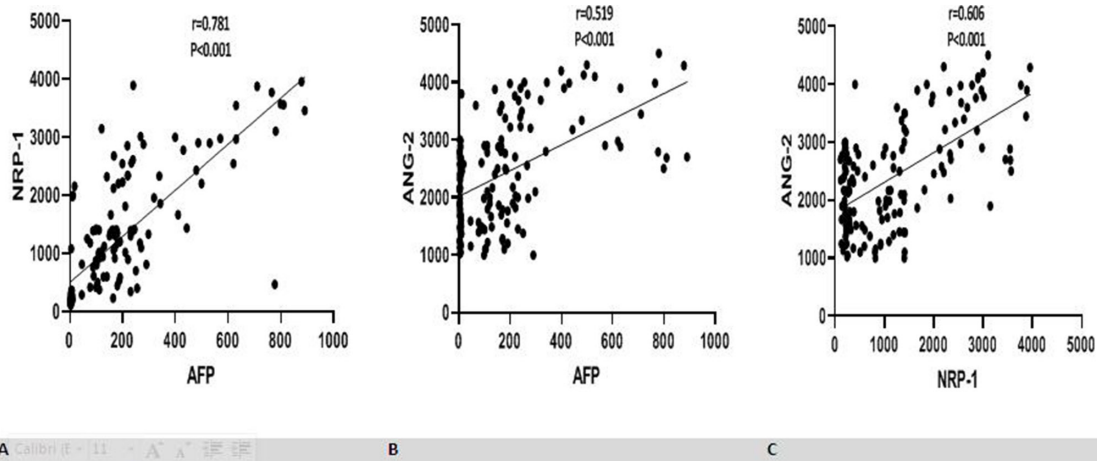


Figure 2 Pearson correlation analyses between the studied serological markers (NRP-1, ANG-2, and AFP). (A) Positive significant correlation between serum AFP and NRP-1 ($r=0.781$, $p<0.001$); (B) positive significant correlation between serum AFP and ANG-2 ($r=0.519$, $p<0.001$); and (C) positive significant correlation between serum NRP-1 and ANG-2 ($r=0.606$, $p<0.001$). AFP, alpha-fetoprotein; ANG-2, angiopoietin-2; NRP-1, neuropilin-1.

and portal vein invasion are significantly associated with NRP-1 expression. Functionally, Bergé and his colleagues³⁹ reported that NRP-1 expression in the liver of transgenic HCC mice is increased with disease progression, in both vascular and tumor compartments. On the other hand, Pestana *et al*³⁸ reported that higher ANG-2 levels were significantly associated with vascular invasion and high TNM stages. Also, Diaz-Sanchez *et al*⁴⁰ found that ANG-2 levels were correlated with vascular invasion and advanced BCLC stages. Moreover, Kuboki *et al*⁴¹ demonstrated that

high ANG-2 levels in the hepatic vein significantly were correlated with portal vein invasion. Furthermore, Llovet and his colleagues⁴² reported that baseline concentration of ANG-2 positively correlated with variables associated with poor outcomes in HCC, such as vascular invasion and distant metastasis. On the contrary, Sharma *et al*³⁷ reported that serum levels of ANG-2 had no association with portal vein invasion, tumor number, or tumor localization.

Unfortunately, the majority of the aforementioned studies have assessed NRP-1 expression in liver tissues that require

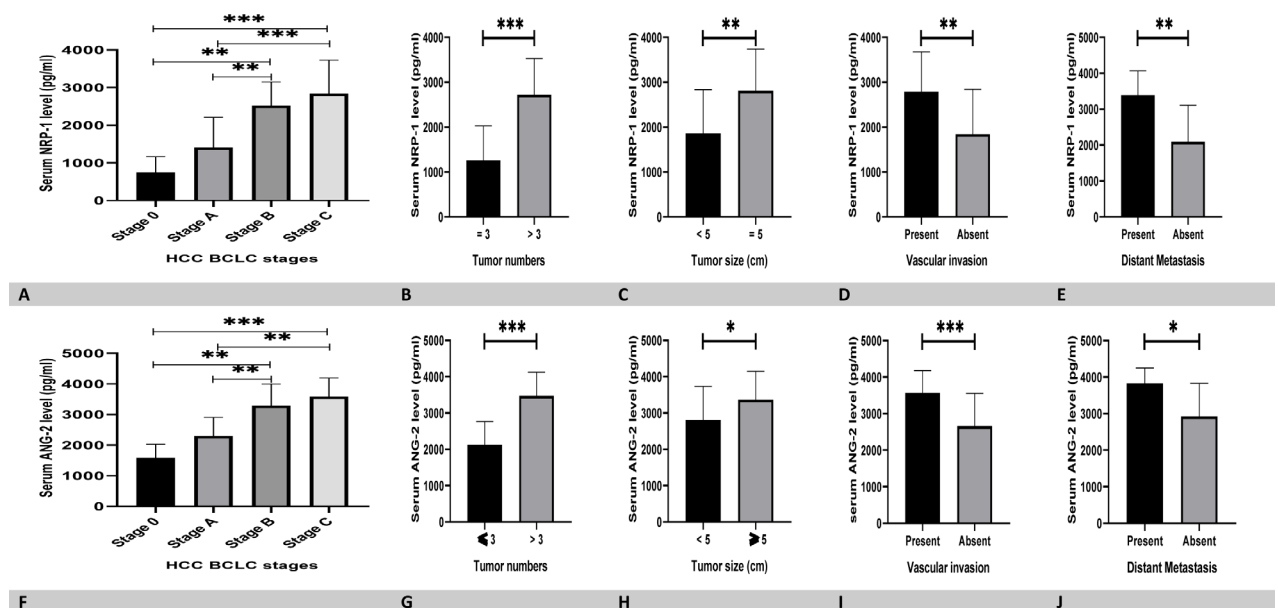


Figure 3 Distribution levels of serum NRP-1 and ANG-2 in patients with HCC showed significantly higher levels of serum NRP-1 and ANG-2 levels in (A, F) patients with HCC with BCLC stages B and C than those with BCLC stages 0 and A; (B, G) patients with HCC with tumor numbers >3 compared with those with tumor numbers ≤ 3 ($p<0.001$, $p<0.001$); (C, H) patients with HCC with tumor size ≥ 5 compared with those with tumor size <5 ($p=0.001$, $p=0.032$); (D, I) patients with HCC with vascular invasion compared with those with no vascular invasion ($p=0.001$, $p<0.001$); and (E, J) patients with HCC with distant metastasis compared with those with no distant metastasis ($p=0.008$, $p=0.033$); * $p<0.05$, ** $p<0.01$, *** $p<0.001$. ANG-2, angiopoietin-2; BCLC, Barcelona Clinic Liver Cancer; HCC, hepatocellular carcinoma; NRP-1, neuropilin-1.

a liver biopsy, which is not applicable in the majority of patients with HCC. Hence, by estimating these markers in the serum, our study presents these markers as applicable non-invasive screening facility for HCC. However, the results of this study should be interpreted with caution and lead time bias should be considered when applying these biomarkers for screening purposes in HCC. The HCC cases included in this study were diagnosed from those seeking medical advice due to clinical manifestations of HCC; however, there is a period of time before the onset of clinical manifestations in which HCC has developed with no clinical manifestations, called the detectable preclinical phase of the disease (DPCD).⁴³ The efficacy of these biomarkers may be changed whenever estimated during this period. Thus, further studies are required to investigate the efficacy of these biomarkers during DPCD.

In this study, the diagnostic efficacy of both angiogenic markers has been assessed using the ROC curve analysis. The AUC-ROC indicated that the diagnostic efficacy of NRP-1 is higher than AFP in differentiating HCC from patients with cirrhosis and healthy individuals. Similar findings were reported by Lin *et al*,³⁴ who detected that the AUC of NRP-1 was 0.971 and higher than that of AFP (AUC=0.862). On the contrary, ANG-2 had a lower diagnostic efficacy than AFP in discriminating HCC from patients with cirrhosis and healthy subjects. However, Chen *et al*³³ revealed some contradictions in this regard and reported that the AUC for ANG-2 was 0.924 and better than that of AFP (AUC=0.902). For the first time, the diagnostic accuracy of both markers was compared in this study and the results revealed a higher diagnostic efficacy for NRP-1 over ANG-2 in discriminating HCC from patients with cirrhosis (0.801 vs 0.748, $p=0.250$) and healthy subjects (0.922 vs 0.809, $p<0.001$). Moreover, combined analysis of both NRP-1 and AFP was performed and revealed that its diagnostic power is slightly better than NRP-1 or AFP alone in differentiating HCC from healthy subjects, with much more significant difference detected with ANG-2.

There are some limitations to this study. First, it included a relatively small number of subjects; however, the G power analysis indicated the adequacy of our sample. Second, the measurement of NRP-1 and ANG-2 was performed by ELISA, which is a non-standardized method; however, the precision and sensitivity of the kits were acceptable. Third, lead time bias should be considered whenever applying these results for screening purposes in HCC. Fourth, the subjects were selected from a single center and certain criteria were applied, such as HCV infection, which may confer ascertainment bias. Therefore, it is recommended to extend this research to a large cohort and investigate the efficacy of these biomarkers during DPCD. In conclusion, the results of this study suggested that NRP-1 is a better marker for the diagnosis of HCC than AFP and ANG-2, and it is feasible to be estimated in combination with AFP to enhance its diagnostic power. Also, higher levels of NRP-1 and ANG-2 were associated with advanced HCC tumor characteristics.

Contributors MTAG, RAE: study design, methodology, laboratory investigations, original draft writing. RAE: methodology, resources, patient selection and clinical evaluation, original draft writing. MHE, MMM: methodology, clinical evaluation. SAD: methodology, resources, patient

selection and clinical evaluation. RLY: data analysis. All authors revised and approved the final manuscript version.

Funding The authors have not declared a specific grant for this research from any funding agency in the public, commercial or not-for-profit sectors.

Competing interests None declared.

Patient consent for publication Obtained.

Ethics approval This study was approved by the local ethics committee of the Faculty of Medicine, Tanta University (approval code: 34090) and was carried out according to the principles of the Declaration of Helsinki.

Provenance and peer review Not commissioned; externally peer reviewed.

Data availability statement All data relevant to the study are included in the article or uploaded as supplementary information.

Supplemental material This content has been supplied by the author(s). It has not been vetted by BMJ Publishing Group Limited (BMJ) and may not have been peer-reviewed. Any opinions or recommendations discussed are solely those of the author(s) and are not endorsed by BMJ. BMJ disclaims all liability and responsibility arising from any reliance placed on the content. Where the content includes any translated material, BMJ does not warrant the accuracy and reliability of the translations (including but not limited to local regulations, clinical guidelines, terminology, drug names and drug dosages), and is not responsible for any error and/or omissions arising from translation and adaptation or otherwise.

ORCID iDs

Muhammad Tarek Abdel Ghafar <http://orcid.org/0000-0002-0621-4291>

Rasha A Elkholy <http://orcid.org/0000-0001-6538-6598>

REFERENCES

- Bray F, Ferlay J, Soerjomataram I, *et al*. Global cancer statistics 2018: GLOBOCAN estimates of incidence and mortality worldwide for 36 cancers in 185 countries. *CA Cancer J Clin* 2018;68:394–424.
- Miller FD, Abu-Raddad LJ. Evidence of intense ongoing endemic transmission of hepatitis C virus in Egypt. *Proc Natl Acad Sci U S A* 2010;107:14757–62.
- Siegel R, Naishadham D, Jemal A. Cancer statistics, 2012. *CA Cancer J Clin* 2012;62:10–29.
- El-Serag HB. Hepatocellular carcinoma. *N Engl J Med* 2011;365:1118–27.
- Bruix J, Sherman M, American Association for the Study of Liver Diseases. Management of hepatocellular carcinoma: an update. *Hepatology* 2011;53:1020–2.
- Balogh J, Victor D, Asham EH, *et al*. Hepatocellular carcinoma: a review. *J Hepatocell Carcinoma* 2016;3:41–53.
- Abdel Ghafar MT, Gharib F, Abdel-Salam S, *et al*. Role of serum Metadherin mRNA expression in the diagnosis and prediction of survival in patients with colorectal cancer. *Mol Biol Rep* 2020;47:2509–19.
- El-Guindy DM, Wasfy RE, Abdel Ghafar MT, *et al*. Oct4 expression in gastric carcinoma: association with tumor proliferation, angiogenesis and survival. *J Egypt Natl Canc Inst* 2019;31:3.
- Habib EM, Nosiar NA, Eid MA, *et al*. Circulating miR-146a expression predicts early treatment response to imatinib in adult chronic myeloid leukemia. *J Invest Med* 2021;69:333–7.
- Abdel Ghafar MT, Gharib F, Al-Ashmawy GM, *et al*. Serum high-temperature-required protein A2: a potential biomarker for the diagnosis of breast cancer. *Gene Reports* 2020;20:100706.
- AbdelGhafar M, Allam A, Darwish S. Serum Hox transcript antisense RNA expression as a diagnostic marker for chronic myeloid leukemia. *Egypt J Haematol* 2019;44:91–7.
- Morse MA, Sun W, Kim R, *et al*. The role of angiogenesis in hepatocellular carcinoma. *Clin Cancer Res* 2019;25:912–20.
- Soker S, Takashima S, Miao HQ, *et al*. Neuropilin-1 is expressed by endothelial and tumor cells as an isoform-specific receptor for vascular endothelial growth factor. *Cell* 1998;92:735–45.
- Rizzolio S, Rabinowicz N, Rainero E, *et al*. Neuropilin-1-dependent regulation of EGF-receptor signaling. *Cancer Res* 2012;72:5801–11.
- Li L, Jiang X, Zhang Q, *et al*. Neuropilin-1 is associated with clinicopathology of gastric cancer and contributes to cell proliferation and migration as multifunctional co-receptors. *J Exp Clin Cancer Res* 2016;35:16.
- Rizzolio S, Tamagnone L. Neuropilins as signaling hubs, controlling tyrosine kinases and other cell surface receptors. In: Neufeld G, Kessler O, eds. *The neuropilins: role and function in health and disease*. New York, NY: Springer International Publishing, 2017: 23–39.
- Tse BWC, Volpert M, Rattner E, *et al*. Neuropilin-1 is upregulated in the adaptive response of prostate tumors to androgen-targeted therapies and

- is prognostic of metastatic progression and patient mortality. *Oncogene* 2017;36:3417–27.
- 18 Cheng W, Fu D, Wei Z-F, *et al.* NRP-1 expression in bladder cancer and its implications for tumor progression. *Tumour Biol* 2014;35:6089–94.
 - 19 Geretti E, Klagsbrun M. Neuropilins: novel targets for anti-angiogenesis therapies. *Cell Adh Migr* 2007;1:56–61.
 - 20 Zhang Y, Liu P, Jiang Y, *et al.* High expression of neuropilin-1 associates with unfavorable clinicopathological features in hepatocellular carcinoma. *Pathol Oncol Res* 2016;22:367–75.
 - 21 Chen Y, Ji H, Cao DY. Expression and clinical value of NRP-1 in hepatocellular carcinoma. *Int J Oncol* 2017;44:428–32.
 - 22 Tanaka S, Mori M, Sakamoto Y, *et al.* Biologic significance of angiopoietin-2 expression in human hepatocellular carcinoma. *J Clin Invest* 1999;103:341–5.
 - 23 Fagiani E, Christofori G. Angiopoietins in angiogenesis. *Cancer Lett* 2013;328:18–26.
 - 24 Kim I, Kim JH, Moon SO, *et al.* Angiopoietin-2 at high concentration can enhance endothelial cell survival through the phosphatidylinositol 3'-kinase/Akt signal transduction pathway. *Oncogene* 2000;19:4549–52.
 - 25 Mitsuhashi N, Shimizu H, Ohtsuka M, *et al.* Angiopoietins and Tie-2 expression in angiogenesis and proliferation of human hepatocellular carcinoma. *Hepatology* 2003;37:1105–13.
 - 26 Takanami I. Overexpression of Ang-2 mRNA in non-small cell lung cancer: association with angiogenesis and poor prognosis. *Oncol Rep* 2004;12:849–53.
 - 27 Sun X-D, Liu X-E, Wu J-M, *et al.* Expression and significance of angiopoietin-2 in gastric cancer. *World J Gastroenterol* 2004;10:1382–5.
 - 28 Chalasani N, Younossi Z, Lavine JE, *et al.* The diagnosis and management of non-alcoholic fatty liver disease: practice guideline by the American association for the study of liver diseases, American College of gastroenterology, and the American gastroenterological association. *Hepatology* 2012;55:2005–23.
 - 29 Llovet JM, Brú C, Bruix J. Prognosis of hepatocellular carcinoma: the BCLC staging classification. *Semin Liver Dis* 1999;19:329–38.
 - 30 European Association for the Study of the Liver. EASL clinical practice guidelines on the management of ascites, spontaneous bacterial peritonitis, and hepatorenal syndrome in cirrhosis. *J Hepatol* 2010;53:397–417.
 - 31 Pugh RN, Murray-Lyon IM, Dawson JL, *et al.* Transection of the oesophagus for bleeding oesophageal varices. *Br J Surg* 1973;60:646–9.
 - 32 Kamath PS, Wiesner RH, Malinchoc M, *et al.* A model to predict survival in patients with end-stage liver disease. *Hepatology* 2001;33:464–70.
 - 33 Chen Y, Wu Y, Zhang X, *et al.* Angiopoietin-2 (Ang-2) is a useful serum tumor marker for liver cancer in the Chinese population. *Clin Chim Acta* 2018;478:18–27.
 - 34 Lin J, Zhang Y, Wu J, *et al.* Neuropilin 1 (NRP1) is a novel tumor marker in hepatocellular carcinoma. *Clin Chim Acta* 2018;485:158–65.
 - 35 Abugabal YI, Hassan M, Abdel-Wahab R, *et al.* Utility of neuropilin-1 in predicting survival in patients with hepatocellular carcinoma. *Journal of Clinical Oncology* 2018;36:e16142.
 - 36 Scholz A, Rehm VA, Rieke S, *et al.* Angiopoietin-2 serum levels are elevated in patients with liver cirrhosis and hepatocellular carcinoma. *Am J Gastroenterol* 2007;102:2471–81.
 - 37 Sharma BK, Srinivasan R, Kapil S, *et al.* Serum levels of angiogenic and anti-angiogenic factors: their prognostic relevance in locally advanced hepatocellular carcinoma. *Mol Cell Biochem* 2013;383:103–12.
 - 38 Pestana RC, Hassan MM, Abdel-Wahab R, *et al.* Clinical and prognostic significance of circulating levels of angiopoietin-1 and angiopoietin-2 in hepatocellular carcinoma. *Oncotarget* 2018;9:37721–32.
 - 39 Bergé M, Allan D, Bonnin P, *et al.* Neuropilin-1 is upregulated in hepatocellular carcinoma and contributes to tumour growth and vascular remodelling. *J Hepatol* 2011;55:866–75.
 - 40 Diaz-Sanchez A, Matilla A, Nuñez O, *et al.* Serum angiopoietin-2 level as a predictor of tumor invasiveness in patients with hepatocellular carcinoma. *Scand J Gastroenterol* 2013;48:334–43.
 - 41 Kuboki S, Shimizu H, Mitsuhashi N, *et al.* Angiopoietin-2 levels in the hepatic vein as a useful predictor of tumor invasiveness and prognosis in human hepatocellular carcinoma. *J Gastroenterol Hepatol* 2008;23:e157–64.
 - 42 Llovet JM, Peña CEA, Lathia CD, *et al.* Plasma biomarkers as predictors of outcome in patients with advanced hepatocellular carcinoma. *Clin Cancer Res* 2012;18:2290–300.
 - 43 Black WC, Ling A. Is earlier diagnosis really better? the misleading effects of lead time and length biases. *AJR Am J Roentgenol* 1990;155:625–30.