

Complications of nasal SARS-CoV-2 testing: a review

James H Clark , Sharon Pang, Robert M Naclerio, Matthew Kashima

Department of
Otolaryngology–Head
and Neck Surgery, Johns
Hopkins University School
of Medicine, Baltimore,
Maryland, USA

Correspondence to

Dr James H Clark,
Department of
Otolaryngology–Head
and Neck Surgery, Johns
Hopkins University School
of Medicine, Baltimore, MD
21224, USA;
jclark79@jhmi.edu

Accepted 7 July 2021
Published Online First
4 August 2021

ABSTRACT

Transnasal swab testing for the detection of SARS-CoV-2 is well established. The Centers for Disease Control and Prevention advocates swabbing either of the anterior nares, middle turbinate, or nasopharynx for specimen collection depending on available local resources. The purpose of this review is to investigate complications related to transnasal SARS-CoV-2 testing with specific attention to specimen collection site and swab approach. The literature demonstrates that while nasopharyngeal swabbing is associated with an increased risk of complications, it should remain the gold-standard test due to greater diagnostic accuracy relative to anterior nasal and middle turbinate swabs.

INTRODUCTION

A patient in their 30s presented to the otolaryngology clinic with a retained nasal foreign body. Seven days prior, the patient underwent screening nasopharyngeal testing for SARS-CoV-2. The procedure was intensely uncomfortable and attempted swab withdrawal was noted to require added force by test operator due to increased resistance. On withdrawal, the tip was noted to have separated from the shaft, and remained in situ. After transfer to the emergency room, the swab tip was visualized, but attempted retrieval proved unsuccessful. The absence of otolaryngology coverage resulted in the patient being discharged home with oral analgesics, a prophylactic antibiotic, and an outpatient subspecialty care referral. At time of presentation to the otolaryngology clinic, the foreign body was not visible on clinical examination. The medial aspect of the middle turbinate, however, was noted to be inflamed and was suspicious for site of the retained swab tip. Nasal endoscopy under general anesthesia was urgently performed, during which the swab tip was discovered anchored tightly between the middle turbinate and septum (figure 1A). The swab tip was removed without complication and the patient was discharged home (figure 1B).

The detection of SARS-CoV-2 infection in both symptomatic and asymptomatic patients has largely relied on using reverse transcription-PCR to detect the virus within respiratory tract secretions.¹ Since the start of the pandemic, the transnasal approach to the nasopharynx has been the gold standard for specimen collection.² The Centers for Disease Control and Prevention (CDC) guideline for SARS-CoV-2

testing recognizes that either the anterior nares, middle turbinate, or nasopharynx can be used for specimen collection depending on available testing kits, although the sensitivity of the test is significantly less than collection from the nasopharynx.³

Our case led us to review the literature regarding complications from transnasal SARS-CoV-2 testing with specific attention to specimen collection site and swab approach.

METHOD

Data sources and searches

A literature search was conducted using Pub Med (1953–2021), EMBASE (1974–2021), CINAHL (1982–2021), PsychInfo (1887–2021), and Web of Science (1945–2021) using the search strings: Nasal [AND] COVID Testing [AND] SARS-CoV-2 Testing [AND] Complications. Databases were searched on March 4, 2021, with an update on March 23, 2021.

Study selection

After removing duplicated cases, the search results were imported into a reference management tool (Zotero, V.5.0.96). The first author screened all titles and abstracts. Inclusion criteria were titles and/or abstracts related to complications from transnasal SARS-CoV-2 testing. The exclusion criterion included was non-English language. The references of all included articles were reviewed for any relevant citations not discovered with our search strategy.

Data extraction and quality assessment

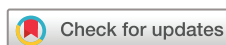Full and comprehensive review was sequentially completed by the first and second authors of all articles meeting criteria for inclusion.

Data synthesis and analysis

Each article was summarized in a Microsoft Word table detailing article type, transnasal swab method, reported complications and reported outcomes. The ad hoc nature of reported outcomes prevented further analysis beyond description.

RESULTS

The literature search strategy yielded 199 citations, of which 11 articles were eligible for review (figure 2).^{4–14} All included articles related to complications from transnasal swab testing for SARS-CoV-2 (table 1).



© American Federation for
Medical Research 2021.
No commercial re-use. See
rights and permissions.
Published by BMJ.

To cite: Clark JH,
Pang S, Naclerio RM,
et al. *J Investig Med*
2021;**69**:1399–1403.

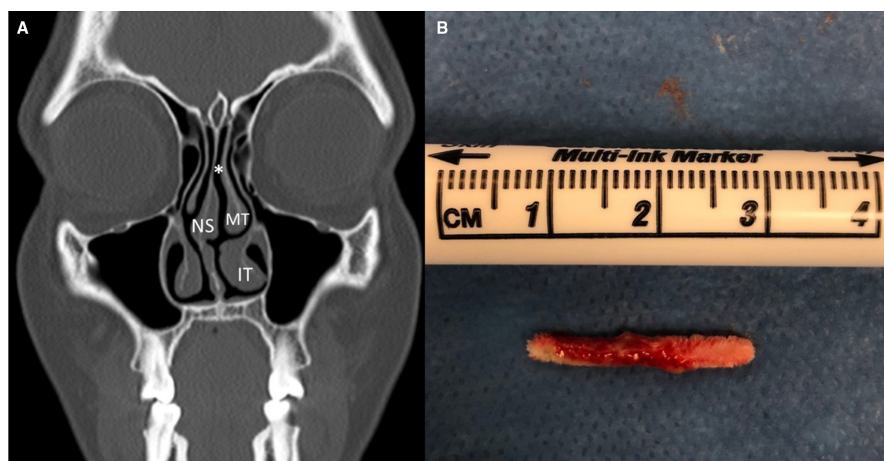


Figure 1 (A) Illustrated on this coronal view of a normal CT scan of the sinus are the nasal septum (NS), inferior turbinate (IT), and middle turbinate (MT). The asterisk (*) depicts the location of the retained swab tip in our case with it being anchored between the MT and NS (Imaging was not performed for presented case as not indicated. If it were performed it would have shown nasal edema and possible evidence of sinusitis.). (B) The nasal swab tip, which was removed from the patient's left naris.

Epistaxis

Three letters to the editor addressed the risk of epistaxis after SARS-CoV-2 transnasal testing. Gupta and colleagues reported a rate of epistaxis after nasopharyngeal swabs of 8.3% and 5% for a commercial 3D printed nasopharyngeal swab testing. With the exception of 1 case requiring an emergency department visit, the cases of epistaxis were self-limited.⁴ Fabbri and colleagues report that out of 4876 consecutive oro/nasopharyngeal swabs, 4 patients required otolaryngology intervention for epistaxis. Three of the cases required nasal packing, and the fourth case necessitated endoscopic cauterization prior to nasal packing.⁵ All cases were performed under local anesthesia.⁵ Pagella and colleagues do not provide data related to the incidence of epistaxis after nasal swabbing for SARS-CoV-2, but highlight the increased risk of significant hemorrhage in patients with hereditary hemorrhagic telangiectasia (HHT).⁶

Retained foreign body

Nine occurrences of a retained swab tip after nasal SARS-CoV-2 testing have been reported.^{5,7-11} One case was associated with a middle turbinate swab,⁷ the remaining occurred after nasopharyngeal testing.^{5,8-11} In 2 of the reported cases, the tip separated from the swab secondary to increased torque encountered during testing of uncooperative and combative patients.^{8,10} No cause for tip separation was provided in the remaining cases.^{7,9,11} In 6 cases, the nasal foreign body was removed urgently at bedside or in an otolaryngology clinic.^{5,7-10} In 3 cases, the foreign body was not found on nasal endoscopy and was assumed to have been swallowed.^{5,7,11} In one case, this led to a hospital admission and an esophagogastroduodenoscopy, during which the retained swab was located in the stomach and removed using grasping forceps.¹¹

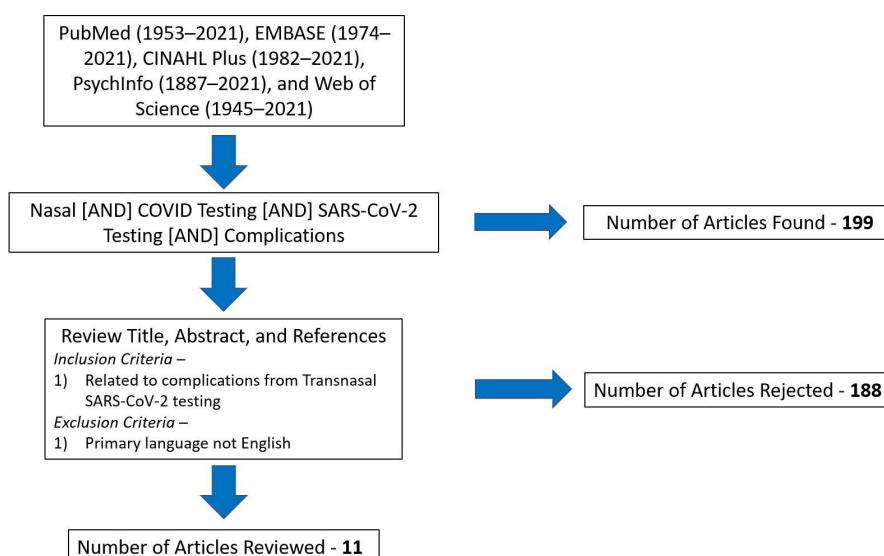


Figure 2 Flow chart of article selection from the literature search strategy.

Table 1 A summary of all included articles

First author	Article type	Transnasal swab method	Reported complications (n)	Reported outcome(s)
Gupta ⁴	LTE	Nasopharyngeal	Epistaxis ¹² Nasal discomfort ¹⁰ Headache ⁷ Ear discomfort ⁶ Rhinorrhea ⁶	<ul style="list-style-type: none"> ► Majority of complications mild and self-limiting ► A single case of epistaxis required presentation to the emergency department
Fabbri <i>et al</i> ⁶	LTE	Nasopharyngeal	Epistaxis ⁴ Retained swabs ³ Nasal septal abscess ¹	<ul style="list-style-type: none"> ► Three cases of epistaxis required nasal packing under local anesthesia ► Endoscopic cauterization and nasal packing under local anesthesia were required in the case of one epistaxis ► Two retained swabs retrieved with nasal endoscopy ► One retained swab was not located on nasal endoscopy and assumed swallowed ► Nasal abscess incised and drained under local anesthesia
Pagella <i>et al</i> ⁶	LTE	Not applicable	Not applicable	<ul style="list-style-type: none"> ► Patients with hemorrhagic telangiectasia should undergo non-transnasal SARS-CoV-2 testing
Föh ⁷	LTE	Nasopharyngeal middle turbinate	Retained swabs ² TMJ dislocation ^{1*}	<ul style="list-style-type: none"> ► Adverse events were reported in 3 out of 11,476 swab procedures performed ► One retained swab was endoscopically removed ► One retained swab was not located on nasal endoscopy and assumed swallowed
Mughal ⁸	Case report	Nasopharyngeal	Retained swabs ¹	<ul style="list-style-type: none"> ► Retained swab retrieved with nasal endoscopy
Azar <i>et al</i> ⁹	Case report	Nasopharyngeal	Retained swabs ¹	<ul style="list-style-type: none"> ► Retained swab retrieved with nasal endoscopy
Gaffuri <i>et al</i> ¹⁰	Case report	Nasopharyngeal	Retained swabs ¹	<ul style="list-style-type: none"> ► Retained swab retrieved under general anesthesia using a bronchoscope with an operative channel and flexible endoscopy forceps
Medas ¹¹	Case report	Nasopharyngeal	Retained swabs ¹	<ul style="list-style-type: none"> ► Retained swab not located on nasal endoscopy ► An esophagogastroduodenoscopy was performed and swab located in stomach ► Retrained swab removed using endoscope-grasping forceps
Sullivan <i>et al</i> ¹²	Case report	Nasopharyngeal	CSF leak ¹	<ul style="list-style-type: none"> ► Required surgical repair of skull base defect
Alberola-Amores <i>et al</i> ¹³	Case report	Nasopharyngeal	CSF leak complicated by meningitis ¹	<ul style="list-style-type: none"> ► Meningitis managed with antibiotics and steroids ► Skull base defect closed spontaneously
Rajah ¹⁴	Case report	Nasopharyngeal	CSF leak ¹	<ul style="list-style-type: none"> ► Required surgical repair of skull base defect

*Local protocol required both transnasal and oropharynx testing with the swab. There was a reported case of mandibular dislocation due to mouth opening for oropharynx swabbing.

CSF, cerebrospinal fluid; LTE, letter to editor; TMJ, temporomandibular joint.

Skull base complications

Three patients developed a cerebrospinal fluid (CSF) leak after undergoing nasopharyngeal SARS-CoV-2 swab testing.^{12–14} Of the 3 cases, only 1 patient had known risk factors: history of sinus surgery, idiopathic intracranial hypertension, and a known skull base defect.¹² Surgical endoscopic repair of the CSF leak was performed in 2 cases.^{12,14} The third case was further complicated by septic meningitis in a patient without known infectious risk factors.¹³

Nasal septal infection

One immune compromised patient developed a septal abscess that required incision and drainage by an otolaryngologist under local anesthesia.⁵

DISCUSSION

Considering the millions of transnasal testing performed for SARS-CoV-2, the procedure should be considered relatively safe. The literature does suggest that nasopharyngeal swabs are at increased risk of complications compared with other types of transnasal swabs. The risk of nasopharyngeal testing complication can be reduced by a basic understanding of nasal anatomy and stopping the procedure in the event of pain or increased resistance. Both the operator and patient should have proper expectations that although the test is uncomfortable, it should not cause intense pain.¹⁵

The most common complication of epistaxis is due to the fragile nature of the nasal mucosa combined with its rich vascular supply originating from branches of the internal

and external carotid arteries.⁵ The majority of resulting epistaxis are mild and resolve without intervention.⁴ When encountering epistaxis, the patients should be instructed to tilt their head forward to avoid blood ingestion or aspiration and then to apply continuous, firm pressure to the lower third of the external nose for 15 minutes.^{16,17} If bleeding persists, the patient should be transferred to the nearest emergency room.

A number of patient factors can increase the severity of epistaxis. Local intranasal variables include septal deviations, septal spurs, neoplasms, or vascular malformation such as HHT. Systemic risk factors include primary or secondary coagulopathy due to anticoagulation therapy.^{5,18} Equally important is the anatomical location of the bleeding source. Whereas most anterior bleeds can be managed with simple application of external nasal pressure, posterior located bleeds frequently necessitate interventions such as endoscopic cauterization and packing.⁵ The likelihood of epistaxis episodes requiring intervention can be minimized by screening patients for risk factors, and by performing the nasal swab on the ipsilateral side reported by the patient as being most open during nasal breathing. Additionally, if increased resistance is encountered, the procedure should promptly be stopped.

There were 9 reported incidences of retained foreign body after transnasal SARS-CoV-2 testing with all cases associated with middle turbinate or nasopharyngeal testing. In 2 cases, the design of the nasal swab likely contributed to the problem.^{8,10} The majority of nasal swabs include a 'break-point' along their shaft to ease separation of the swab tip

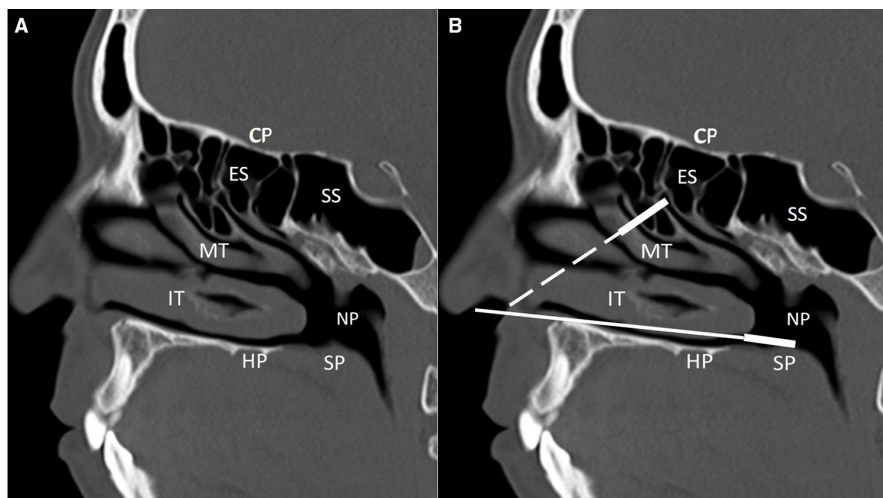


Figure 3 (A) This sagittal view of the CT of the sinus demonstrates the nasal anatomy encountered when performing a transnasal swab. The floor of the nasal cavity and nasopharynx (NP) is constituted by the hard palate (HP) and soft palate (SP). Within the nasal cavity, there are 3 shelves like projection from the lateral wall, inferior turbinate (IT), middle turbinate (MT) and superior turbinate (not demonstrated). The cribriform plate (CP), ethmoid sinus (ES) and sphenoid sinus (SS) form the nasal cavity roof. (B) As demonstrated by the solid line swab when performing transnasal testing, the swab should either not be advanced beyond a depth of 2 cm or if deeper testing is being performed, the swab should be advanced along the floor of the nasal cavity. The dash swab demonstrates a swab advanced following the exterior projection of the nose, which is a common misconception of the direction of the NP.

from the shaft making sterile transportation of the sample more convenient.^{79 11} When considering performing middle turbinate or nasopharyngeal swabs in patients unlikely to either tolerate or cooperate with testing, alternative testing should be considered.

The retained swab in our case illustrates how the swab was advanced in the wrong direction despite the pain felt by the patient. This technique resulted in the swab tip becoming anchored in the narrow space between the nasal septum and middle turbinate (figure 1A). Advancing the swab in a direction that does not follow the floor of the nose is believed to be the mechanism of injury in the 3 reported cases of CSF leak.^{12–14} Nasopharyngeal swabs can safely be advanced along the floor of the nasal cavity (figure 3).¹⁴ This concept is reflected within the CDC guidelines for SARS-CoV-2 testing, which state that swabs should be advanced parallel to the palate.¹⁹

All incidences of retained nasal foreign body reported, except that of Gaffuri and colleagues¹⁰ and our case, were successfully managed in a clinic setting. The prolonged foreign body retention of 7 days in our case, triggered a significant inflammatory response. Beyond obstructing visualization, this inflammation prevented effective delivery of topical anesthesia to the middle and posterior nasal cavity making clinic retrieval of foreign body impossible. If a retained foreign body is suspected, the patient should be evaluated by an otolaryngologist urgently to prevent inflammation and increase the likelihood of successful bedside or clinic retrieval.

In the case of CSF leak described by Sullivan and colleagues, the patient had a known history of sinus surgery and a skull base defect.¹² Due to the potential to harm and an abundance of caution, patients with a history of sinus surgery, transsphenoidal pituitary surgery or concern for a skull base injury, an alternative diagnostic method to nasopharyngeal swab should be considered.²⁰

The diagnostic reliability of nasopharyngeal swab testing decreases in cases when the procedure is improperly executed.²¹ Nasopharyngeal testing requires a basic understanding of nasal anatomy to ensure that the correct anatomical site is swabbed. Li and colleagues demonstrated that nurses performing SARS-CoV-2 screening on average answered only 50% of basic nasal anatomy questions correctly.²² Although less technically challenging to perform, anterior nasal and middle turbinate diagnostic capacity have lower predictive value compared with nasopharyngeal swabs.³ Despite some risk of causing iatrogenic complications, the nasopharyngeal swab remains the gold-standard test for SARS-CoV-2 detection.³

New approaches to the detection of SARS-CoV-2 are being developed with testing specimen including saliva, blood, urine and feces.^{23 24} Saliva testing demonstrates diagnostic accuracy similar to that of nasopharyngeal swab.²⁵ Saliva testing advantages include ease of sample procurement, increased patient comfort, greater safety and reduced exposure risk for personnel collecting samples.^{23 25}

LIMITATIONS

All studies included in the review were either small retrospective studies or simple case reports. The rate of adverse outcomes, particularly in relation to anterior nares and middle turbinate testing, is likely under-reported due to the self-limiting nature of the complications of epistaxis and pain. Further, there is an absence of patient-centered data related to the experience of transnasal testing and perhaps the bigger complication of individuals avoiding SARS-CoV-2 screening due to a fear of transnasal testing.

CONCLUSION

This review of the literature demonstrates that although transnasal SARS-CoV-2 testing is safe, it has the potential

to cause significant morbidity. The majority of complications reported relate to nasopharyngeal swabbing, particularly due to lack of understanding of nasal anatomy. Despite some risk of complications, nasopharyngeal swabbing should remain the gold-standard test due to greater diagnostic accuracy relative to anterior nasal and middle turbinate swabs. Further, the risk of nasopharyngeal testing is largely mitigated with an understanding of nasal anatomy, patient screening, and stopping the procedure if increased pain or pressure is noted.

Contributors All authors were involved in designing and writing of the manuscript.

Funding The authors have not declared a specific grant for this research from any funding agency in the public, commercial or not-for-profit sectors.

Competing interests JHC, SP and MK declare they have no relevant conflicts of interest. RMN is part of the Medical Advisory Board for GlaxoSmithKline, Lira, Sanofi, Regeneron, and AstraZeneca.

Patient consent for publication Not required.

Ethics approval Signed patient consent for publication and exempt from Johns Hopkins University institutional ethics review as a single case report.

Provenance and peer review Not commissioned; externally peer reviewed.

This article is made freely available for use in accordance with BMJ's website terms and conditions for the duration of the covid-19 pandemic or until otherwise determined by BMJ. You may use, download and print the article for any lawful, non-commercial purpose (including text and data mining) provided that all copyright notices and trade marks are retained.

ORCID iD

James H Clark <http://orcid.org/0000-0002-8841-3402>

REFERENCES

- Liu R, Han H, Liu F, et al. Positive rate of RT-PCR detection of SARS-CoV-2 infection in 4880 cases from one hospital in Wuhan, China, from Jan to Feb 2020. *Clin Chim Acta* 2020;505:172–5.
- Bwire GM, Majigo MV, Njiro BJ, et al. Detection profile of SARS-CoV-2 using RT-PCR in different types of clinical specimens: a systematic review and meta-analysis. *J Med Virol* 2021;93:719–25.
- Lee RA, Herigon JC, Benedetti A, et al. Performance of saliva, oropharyngeal swabs, and nasal swabs for SARS-CoV-2 molecular detection: a systematic review and meta-analysis. *J Clin Microbiol* 2021;59. doi:10.1128/JCM.02881-20. [Epub ahead of print: 20 Apr 2021].
- Gupta K, Bellino PM, Charness ME. Adverse effects of nasopharyngeal swabs: three-dimensional printed versus commercial swabs. *Infect Control Hosp Epidemiol*;42:641–2.
- Fabbris C, Cestaro W, Menegaldo A, et al. Is oro/nasopharyngeal swab for SARS-CoV-2 detection a safe procedure? complications observed among a case series of 4876 consecutive swabs. *Am J Otolaryngol* 2021;42:102758.
- Pagella F, Lizzio R, Ugolini S, et al. Diagnostic testing for SARS-CoV-2 infection in HHT patients: nasopharyngeal versus oropharyngeal swab. *Orphanet J Rare Dis* 2020;15:350.
- Föh B, Borsche M, Balck A. Complications of nasal and pharyngeal swabs – a relevant challenge of the COVID-19 pandemic? *European Respiratory Journal* 2020 <https://erj.ersjournals.com/content/early/2020/11/26/13993003.04004-2020>
- Mughal Z, Luff E, Okonkwo O. Test, test, test – a complication of testing for coronavirus disease 2019 with nasal swabs. *J Laryngol Otol* 2020;1–4. doi:10.1017/S0022215120001425
- Azar A, Wessell DE, Janus JR, et al. Fractured aluminum nasopharyngeal swab during drive-through testing for COVID-19: radiographic detection of a retained foreign body. *Skeletal Radiol* 2020;49:1873–7.
- Gaffuri M, Capaccio P, Torretta S, et al. An unusual retained choanal foreign body: a possible complication of COVID-19 testing with nasopharyngeal swab. *Ear Nose Throat J* 2021;145561321993933.
- Medas R, Coelho R, Macedo G. An unusual collateral damage of COVID-19 pandemic. *Gastrointest Endosc* 2020;92:1261–2.
- Sullivan CB, Schwalje AT, Jensen M, et al. Cerebrospinal fluid leak after nasal swab testing for coronavirus disease 2019. *JAMA Otolaryngol Head Neck Surg* 2020;146:1179.
- Alberola-Amores FJ, Valdeolivas-Urbel E, Torregrosa-Ortiz M, et al. Meningitis due to cerebrospinal fluid leak after nasal swab testing for COVID-19. *Eur J Neurol* 2021. doi:10.1111/ene.14736. [Epub ahead of print: 21 Jan 2021].
- Rajah J, Lee J. CSF rhinorrhoea post COVID-19 swab: a case report and review of literature. *J Clin Neurosci* 2021;86:6–9.
- Higgins TS, Wu AW, Ting JY. SARS-CoV-2 nasopharyngeal swab Testing-False-Negative results from a pervasive anatomical misconception. *JAMA Otolaryngol Head Neck Surg* 2020;146:993.
- Kucik CJ, Clenney TL. Management of epistaxis. *AFP* 2005;71:305–11.
- Schlosser RJ. Epistaxis. *N Engl J Med Overseas Ed* 2009;360:784–9.
- Fatakia A, Winters R, Amedee RG. Epistaxis: a common problem. *Ochsner J* 2010;10:176–8.
- CDC. Coronavirus Disease 2019 (COVID-19) [Internet]. Centers for Disease Control and Prevention, 2020. Available: <https://www.cdc.gov/coronavirus/2019-ncov/hcp/guidance-hcf.html> [Accessed 11 Aug 2020].
- Fish T, Issa K, Levine CG, et al. Assessment of available online information about nasopharyngeal swab testing in patient Instructions for sinus and pituitary surgery. *JAMA Otolaryngol Head Neck Surg* 2021;147:572.
- Torretta S, Zuccotti G, Cristofaro V, et al. Diagnosis of SARS-CoV-2 by RT-PCR using different sample sources: review of the literature. *Ear Nose Throat J* 2021;100:1315–8.
- Li L, Shim T, Zapanta PE. Optimization of COVID-19 testing accuracy with nasal anatomy education. *Am J Otolaryngol* 2021;42:102777.
- Asselah T, Durantel D, Pasmant E, et al. COVID-19: discovery, diagnostics and drug development. *J Hepatol* 2021;74:168–84.
- Dhama K, Khan S, Tiwari R, et al. Coronavirus disease 2019-COVID-19. *Clin Microbiol Rev* 2020;33. doi:10.1128/CMR.00028-20. [Epub ahead of print: 16 Sep 2020].
- Butler-Laporte G, Lawandi A, Schiller I, et al. Comparison of saliva and nasopharyngeal swab nucleic acid amplification testing for detection of SARS-CoV-2: a systematic review and meta-analysis. *JAMA Intern Med* 2021;181:353.