

CNS findings in chronic fatigue syndrome and a neuropathological case report

Kimberly Ferrero,¹ Mitchell Silver,¹ Alan Cocchetto,² Eliezer Masliah,³ Dianne Langford¹

¹Lewis Katz School of Medicine at Temple University, Philadelphia, Pennsylvania, USA

²State University of New York at Alfred, Engineering Technologies, Alfred, New York, USA

³University of California San Diego, La Jolla, California, USA

Correspondence to

Dianne Langford, Lewis Katz School of Medicine at Temple University, 3500 North Broad Street, MERB 750, Philadelphia, PA 19140, USA; tdl@temple.edu

Accepted 14 March 2017

Copyright © 2017 American Federation for Medical Research

ABSTRACT

Chronic fatigue syndrome (CFS) is characterized as a persistent, debilitating complex disorder of unknown etiology, whereby patients suffer from extreme fatigue, which often presents with symptoms that include chronic pain, depression, weakness, mood disturbances, and neuropsychological impairment. In this mini review and case report, we address central nervous system (CNS) involvement of CFS and present neuropathological autopsy findings from a patient who died with a prior diagnosis of CFS. Among the most remarkable pathological features of the case are focal areas of white matter loss, neurite beading, and neuritic pathology of axons in the white matter with axonal spheroids. Atypical neurons displaying aberrant sprouting processes in response to injury are observed throughout cortical gray and white matter. Abundant amyloid deposits identical to AD plaques with accompanying intracellular granular structures are observed as well. Neurofibrillary tangles are also present in the white matter of the frontal cortex, thalamus and basal ganglia. Taken together, these neuropathological findings warrant further studies into CNS disease associated with CFS.

CNS FINDINGS IN CFS

A central theme in chronic fatigue syndrome (CFS), as the name implies, is a chronic state of energy deficit experienced by patients. CFS is defined as 6 months or more of persistent cognitive and physical fatigue, with brain-related symptoms varying among patients. Along with headache or vision problems, patients with CFS may experience cognitive and behavioral alterations. An excellent review by Ocon¹ describes the 'brain fog' associated with CFS as slow thinking, difficulty focusing, lack of concentration, forgetfulness or haziness in thought processes. Clinically, reduced cerebral blood flow, increased activity in cortical/subcortical activation during mental tasks, deficits in processing information, impaired attention, and working memory are reported.¹ In the central nervous system (CNS), the onset of CFS may be triggered by deleterious factors such as exposure to radionuclides, viral or microbial infection, seizure, trauma, genetic mutations and/or other factors. This manuscript will present a survey of literature reporting CNS abnormalities and studies related to potential mechanisms that

Significance of this study

What is already known about this subject?

- ▶ Chronic fatigue syndrome (CFS) is 6 months or more of persistent cognitive and physical fatigue, with brain-related symptoms varying among patients
- ▶ CFS is classified as a neurological disorder and increasing evidence supports CFS as a disease of the nervous and immune systems
- ▶ In the central nervous system (CNS), CFS may be triggered by exposure to radionuclides, viral or microbial infection, seizure, trauma, genetic mutations and/or other factors.

What are the new findings?

- ▶ Neuropathological autopsy findings from a patient who died with a prior diagnosis of CFS report focal areas of white matter loss, neurite beading, and neuritic pathology of axons in the white matter with axonal spheroids.
- ▶ Atypical neurons displaying aberrant sprouting processes in response to injury are observed throughout cortical gray and white matter. Abundant amyloid deposits identical to AD plaques with accompanying intracellular granular structures are observed as well.
- ▶ Neurofibrillary tangles are also present in the white matter of the frontal cortex, thalamus and basal ganglia.

How might these results change the focus of research or clinical practice?

- ▶ Taken together, these neuropathological findings warrant further studies into CNS disease associated with CFS.

may contribute to CNS disturbances in patients with CFS. For a more comprehensive review of CNS involvement, please see Fischer *et al.*² We will also present neuropathological findings from a recent case study that illustrate vascular pathology, demyelination in focal areas and diffuse reactive astrogliosis, as well as the presence of A β plaques and axonal and

To cite: Ferrero K, Silver M, Cocchetto A, *et al.* *J Invest Med* Published Online First: [please include Day Month Year] doi:10.1136/jim-2016-000390

neurofibrillary pathology. Robust tauopathy was also observed, with evidence of aberrant sprouting and the presence of abundant A β + plaques in frontal cortex white matter.

Although the etiology and pathogenesis of CFS have not been fully elucidated, the WHO classifies CFS as a neurological disorder (IDC10 (international statistical classification of disease and health related problems), G93.3) and increasing evidence supports CFS as a disease of the nervous and immune systems.³ In fact, as early as 1959, Acheson⁴ described the clinical syndrome as having cerebral damage. Among the most striking evidence supporting CNS involvement are hundreds of imaging studies that point to brain abnormalities in patients with CFS. Neuroanatomically, reductions in gray and white matter are reported.^{2 5-10} Neural perfusion impairments have also been reported in some, but not all, patients with CFS.^{2 11-14} Several studies used blood oxygen level-dependent functional MRI (BOLD fMRI) and reported abnormal activities in patients with CFS compared with control participants.^{2 7 15 16} Among the chief neurocognitive alterations in CFS are poor concentration, short-term memory loss, word-finding inability, delayed information processing and reaction times, and short attention span.¹⁷ Conflicting reports exist as to whether these deficiencies are distinguishable from those observed in depression, or whether they correlate with fatigue severity.^{2 17-20} Finally, as described in a review by Fischer *et al*, neurochemical abnormalities in CFS include hypothalamic pituitary axis disruptions.²¹⁻²⁷ While it is well beyond the scope of this survey to address all previous studies, we wish to highlight some of these studies that illustrate CNS involvement in CFS.

Numerous neuroanatomical imaging studies have shown volumetric changes in patients with CFS (for a review, see ref. ⁵). For example, a voxel-based morphometric study by Okada *et al*⁶ reported significantly reduced gray matter volume in the bilateral prefrontal cortex of patients with CFS compared with normal controls. Conversely, another study reported an 8% reduction in gray matter; however, regional focal loss was not observed.⁷ Other studies reported reduced gray matter in occipital lobes and parahippocampal gyrus with reduced white matter volume in the left occipital lobe.⁸ Using 3.0-T volumetric T1-weighted MRI with two diffusion tensor imaging (DTI) acquisitions and arterial spin labeling, Zeineh *et al*⁹ identified increased fractional anisotropy in the right arcuate fasciculus that correlated with disease severity and reduced bilateral white matter volumes in CFS. Studies from Barnden *et al*¹⁰ report white matter volume decrease with increasing fatigue. These studies also showed a strong correlation between brainstem gray matter volume and pulse pressure, suggesting impaired cerebrovascular autoregulation.¹⁰ Taken together, these data support the hypothesis that significant neuroanatomical changes accompany CFS.

Along with mitochondrial dysfunction and low levels of ATP that manifest as systemic energy deficit, it is proposed that CFS impacts both resting and activity-dependent use of energy. Many imaging studies support CNS involvement in CFS and show abnormal activity profiles. Recent imaging studies comparing resting state functional connectivity in patients with CFS to normal controls indicated a decrease in resting state functional connectivity that

correlated with severity of the fatigue state.²⁸ In other studies, fMRI was used to determine the association between BOLD brain responses and mental fatigue as determined by a variety of mood state tests including the State-Trait Anxiety Inventory, the Beck Depression Inventory and visual analog scales.¹⁵ Results showed that mental fatigue tasks caused changes in brain activity in CFS participants compared with controls. Specifically, observed changes included positive correlations in cerebellar, temporal, cingulate and frontal regions, with negative correlations in the left posterior parietal cortex.¹⁵ Similar studies with BOLD fMRI analyses indicated that during working memory tasks, patients with CFS process challenging auditory information as accurately as controls, but exerted greater effort to process the information than controls.¹⁶ In fact, other studies reported reduced blood flow in middle cerebral arteries in patients with CFS compared with controls.²⁹ fMRI studies have also reported decreased basal ganglia activity in patients with CFS compared with normal controls during a reward processing task.³⁰ From these studies, it appears that patients with CFS have attenuated task-driven activity levels compared with normal controls and may be required to expend more energy to complete mental tasks than control participants.

Metabolic system dysfunction has long been proposed to contribute to CFS³¹ and imaging studies support these hypotheses. Studies by Shungu *et al*³² reported elevated ventricular lactate, decreased cortical glutathione, and lower regional cerebral blood flow, which taken together point to increased oxidative stress as a potential contributor to CFS. Normal fatigue involves increases in blood levels of tryptophan, the amino acid precursor of 5-HT.³³ In turn, brain levels of 5-HT increase, leading to the feeling of fatigue. In studies with patients with CFS, increased levels of 5-HIAA, the breakdown product of 5-HT, were observed in cerebrospinal fluid of patients with CFS. This suggests that patients with CFS experience an increased central turnover of 5-HT in the CNS.³⁴ Recently, Cleare *et al*³⁵ reported decreased 5-HT 1A receptor expression or affinity in the brains of patients with CFS as determined by a specific radioligand and positron emission tomography (PET) scanning, which may contribute to fatigue. PET studies by Kuratsune *et al*³⁶ showed hypoperfusion and reductions in neurotransmitters including glutamate, aspartate and γ -aminobutyric acid through acetylcarnitine in frontal, cingulate, temporal and occipital cortices, basal ganglia and hippocampus in CFS. Other studies report decreased serotonin transporter expression in the rostral anterior cingulate cortex in patients with CFS.³⁷

Neuroimmune dysfunction is likely a key component of the CFS phenotype, and is central to many CNS diseases including multiple sclerosis, HIV-associated neurocognitive disorder, Parkinson's disease, substance abuse disorder, traumatic brain injury and others. Studies report increased levels of proinflammatory cytokines in blood and CSF of patients with CFS that may indicate CNS inflammation.^{38 39} In these studies, Natelson *et al*³⁹ reported higher serum protein concentration, white cell count and cytokine levels in some patients with CFS. Specifically, levels of interleukin (IL)-8 and IL-10 were higher in patients with CFS with disease onset accompanied by influenza-like symptoms. Moreover, granulocyte colony-stimulating factor, a factor that promotes

maturation of myeloid cells and their proper functioning, was reduced in patients with CFS, suggesting dysregulation of immune function.³⁹ To further address potential neuroimmune disruptions in CFS, activation of microglia and astrocytes was assessed in patients with CFS. Nakatomi and colleagues used a PET ligand, ¹¹C-(R)-PK11195, that is specific for a translocator protein on activated glia. Results from these studies consistently showed widespread inflammation present in the cingulate, hippocampus, thalamus, midbrain and pons with higher levels in the amygdala that correlated positively with fatigue severity score.⁴⁰ Even though various neurophysiological findings in CFS have been reported and include reduced blood flow,^{11 29 41 42} increased ventricular lactate,⁴³ increased hypothalamic pituitary axis (HPA) axis feedback with decreased corticosteroid,^{44–46} decreased grain derived neurotrophic factor (BDNF),⁴⁷ altered serotonergic^{35 37 48} and muscarinic^{49 50} neurotransmitter systems and activated glia with neuroinflammatory cytokine profile increase, the mechanisms responsible for CNS involvement in CFS remain elusive.

Alterations in biochemical characteristics in CFS include decreased serum acetyl-L-carnitine⁵¹ with decreased uptake in prefrontal, temporal, anterior cingulate and cerebellum.³⁶ These results point to potential dysregulation of mitochondrial oxidation of fatty acids as well as glutamate synthesis. In other studies, increased autoantibodies against the muscarinic cholinergic receptor (mAChR) that is involved in cognitive functioning, motor control and rapid eye movement sleep were reported.⁴⁹ Postmortem studies show reductions in central mAChR in Alzheimer's-type dementia, Parkinson's disease, Huntington's disease, and schizophrenia.^{52–60} Recent studies assessed the effects of mAChR autoantibody on the muscarinic cholinergic system in the brains of patients with CFS via PET. However, these studies found that serum autoantibody against mAChR can indeed affect brain mAChR without altering acetylcholinesterase activity and cognition in patients with CFS.⁵⁰ These studies indicate reduced neurotransmitter receptor binding in the brain of patients with CFS and propose that disrupted blood brain barrier functioning may accompany high levels of autoantibody in the brain.

Taken together, results from these and other studies point to the complex and multifactorial nature of CFS and illustrate the need for more investigations addressing potential mechanistic contributors to CNS dysfunctions in CFS. Given the numbers of brain imaging studies conducted on patients suffering from CFS and the CNS-related signs and symptoms associated with CFS, the relative paucity of post-mortem neuropathological analyses is surprising. In fact, a technical note provided a protocol to establish a post-mortem tissue bank to study CFS in 2014.³ The discussion presented gives an overview of current literature on CFS from a macro perspective (anatomical and imaging studies) and narrowed down to analyses of its more microscopic elements (neurotransmitter levels, neuroimmune, etc). Some of the main issues surrounding CFS diagnoses, as discussed, include the similarity of presentations to known comorbidities, possibly blinding clinical identification of CFS in patients. As researchers discover more about CFS, a goal will be to help differentiate symptoms into etiological subtypes of the disease (immunological, trauma, etc) from those symptoms common to an overarching CFS

phenotype. This case review will allow for a specific perspective on CFS by examining the syndrome in an individual who suffered from the disease.

In a comprehensive study in 2003, Kang and colleagues reported significantly higher rates of CFS and post-traumatic stress disorder (PTSD) in 15,000 Gulf War veterans compared with the general population. In fact, many veterans fulfill the diagnostic criteria for CFS^{61 62} and several studies report significantly higher rates among veterans compared with non-veterans.^{63–65} Two main etiological factors are suggested: either an environmental factor and/or battlefield stress conditions. Etiological agents suggested to be contributors to CFS in this population include exposure to multiple vaccines, pyridostigmine bromide, toxic chemicals, chemical and biological warfare agents or depleted uranium. Battlefield environments, moreover, present distinct conditions which are inarguably powerful physiological and psychological stressors. One case report from Omalu *et al*⁶⁶ described chronic traumatic encephalopathy (CTE) in a war veteran suffering from PTSD. This landmark report opened lines of thought to consider PTSD as part of the CTE spectrum of disease whereby stressors in certain conditions may contribute to pathologies such as tauopathy in some cases. Given the wide range of possible etiologies for PTSD and CFS, and the triggers for formation of tauopathy in non-Alzheimer's disease (AD) diseases such as CTE, we propose that several possible mechanistic links exist among these diseases. In fact, chronic stressors such as PTSD, repeated mild traumatic brain injury and CFS associated with Persian Gulf War veterans show overlapping neurobehavioral symptoms including mood disturbances, learning and executive function complications, sleep disturbances and impaired social interactions.^{67–71} Patients with CFS in the general population also suffer from these debilitating symptoms,⁷² pointing to a set of shared characteristics among these seemingly diverse disorders.

NEUROPATHOLOGICAL FINDINGS FROM A CFS CASE

Here, we present neuropathological findings from a case of CFS from a 72-year old Caucasian woman who died from aspiration pneumonia due to hypertensive cerebrovascular disease.

According to the patient's daughter, prior to 1974, the patient led an active life managing all household duties including finances. She worked as a volunteer in the local hospital's emergency department and managed a concession stand at local sporting events. Beginning in 1974–1975, the patient began to repeat herself and have cognitive problems such as confusion. In 1975, she participated in a golf tournament but could not remember the event or how she got home. The patient then continued to decline and suffered from malaise, headache, joint and muscle pain, swollen lymph nodes and 'brain fog' that persisted for over 6 months. Rest did not alleviate these problems. Other significant medical history included a diagnosis of CFS made in 1987, fibromyalgia, celiac disease and hypothyroidism. The diagnosis of CFS was made according to the Holmes criteria,⁷³ whereby the patient met both major clinical criteria 1 and 2, and 6 or more of the 11 symptom criteria and 2 or more of the 3 physical criteria, or 8 or more of the 11 symptom criteria.⁷³ Criterion 1 is defined as "new onset of

persistent or relapsing, debilitating fatigue in a person who has no previous history of similar symptoms that does not resolve with bed rest, and that is severe enough to reduce or impair average daily activity below 50% of the patient's pre-morbid activity level for a period of at least 6 months."⁷³ Criterion 2 is the exclusion of other clinical conditions that may produce similar symptoms. For a detailed list of these conditions, see reference⁷³. In 1987, she was admitted to hospice 10 days prior to death with a diagnosis of general decline. Within the previous week, she had acute psychotic episodes that included persecutory and somatic delusions and delusions of reference where the patient said, "There is something wrong in my brain. I am dying. People are trying to kill me." She also experienced auditory hallucinations where the patient reported that voices said they were going to kill her. Three days prior to death, she was in a coma after suffering a presumed stroke.

Examination of the frontal cortex, basal ganglia and thalamus revealed numerous hallmarks of neurodegeneration. Extensive astrogliosis was observed in the frontal cortex (figure 1, anti-glial fibrillary acidic protein (GFAP) green), with few microglia present (anti-Iba-1, red). Microvasculature showed disruption with hyalinization, atherosclerosis and vessel wall thickening likely associated with hypertension (figure 1, inset and asterisks). In addition, focal areas of white matter loss were observed in the frontal cortex as indicated by Luxol fast blue staining (arrowheads; figure 2). To assess neuronal abnormalities, sections were labeled with antibodies against neurofilament

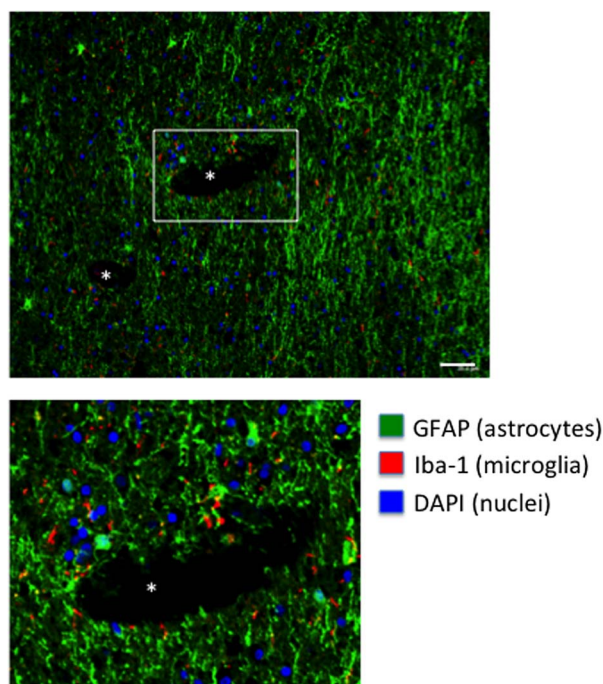


Figure 1 Immunolabeling of brain tissues from the frontal cortex of a patient with CFS indicates robust reactive astrogliosis. Sections from white matter in the frontal cortex were immunolabeled with GFAP (green) for astrocytes and Iba-1 (red) for microglia. Asterisks indicate the lumen of blood vessels showing hyalinization, vessel wall thickening and atherosclerosis. Nuclei are stained with DAPI in blue. Scale bar is ~40 μ m. CFS, chronic fatigue syndrome.

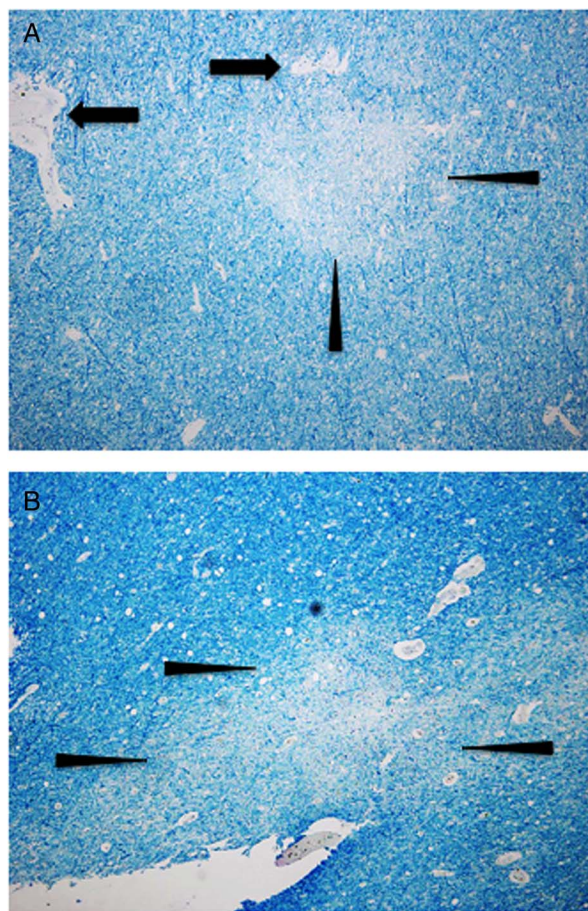


Figure 2 Myelin loss in the frontal cortex. (A, B) Frontal cortex white matter tissue sections are stained with luxol fast blue with a cresyl violet counterstain. Arrowheads indicate areas of focal demyelination showing myelin pallor. Arrows indicate blood vessel architecture disruption. Magnification is $\times 100$.

and the paired helical filaments (PHFs) of hyperphosphorylated Tau (hp Tau). Immunolabeling with antineurofilament (figure 3A, B) and PHF (figure 3D) antibodies identified axonal spheroids (arrows) indicating axonal swelling. In addition, atypical neurons with neuritic beading and aberrant sprouting were present (figure 3C, arrowheads) and may represent response to damage. Silver staining revealed numerous neuronal neurofibrillary-like tangles in the basal ganglia, thalamus and white matter of the frontal cortex (figure 4A–C, respectively). However, more detailed characterization is needed using other Tau antibodies, thio-S and electron microscopic analyses.

The hp Tau was observed in association with neuronal cells and with microtubule associated protein 2 (MAP2)-negative cells (figure 5A). On the other hand, diffuse hp Tau immunolabeling showed co-localization with MAP2-positive cellular structures (figure 5B, arrowhead). To assess if hp Tau was also associated with astrocytes, double immunolabeling with GFAP and hp Tau was conducted. Results indicated no co-localization of hp Tau with GFAP-positive astrocytes (figure 6A–C). Microvessels displayed abundant hp Tau accumulations (figure 6A, B, arrowheads). Likewise, hp Tau labeling was observed in cellular processes that were GFAP-negative (figure 6C, arrows).

Figure 3 Axonal spheroids and abnormal neuronal architecture is observed in the frontal cortex. (A, B) Neurofilament immunolabeling with arrowheads indicates probable axonal spheroids in white matter. (C) Neurofilament immunolabeling shows abnormal sprouting and neuronal architecture in gray matter (arrowheads). (D) Immunolabeling with paired-helical filament Tau antibody shows a probable axonal spheroid (arrow) in white matter. Sections are immunolabeled with antibodies and reacted with 3, 3'-DAB and counterstained with hematoxylin. Images are $\times 100$ magnification. DAB, diaminobenzidine.

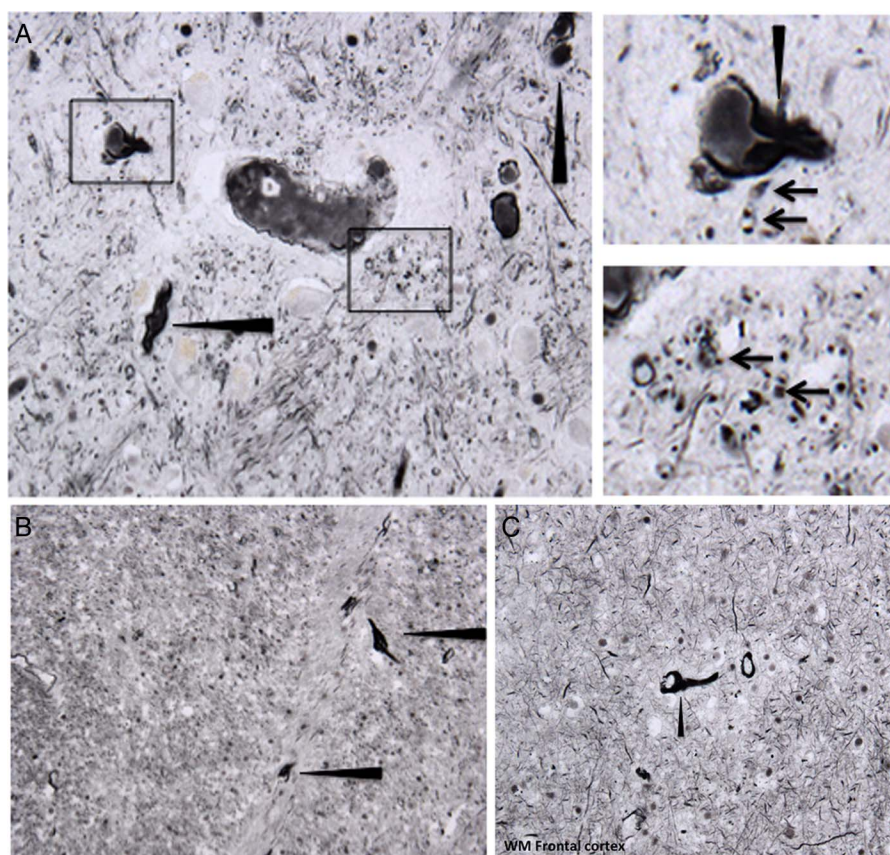
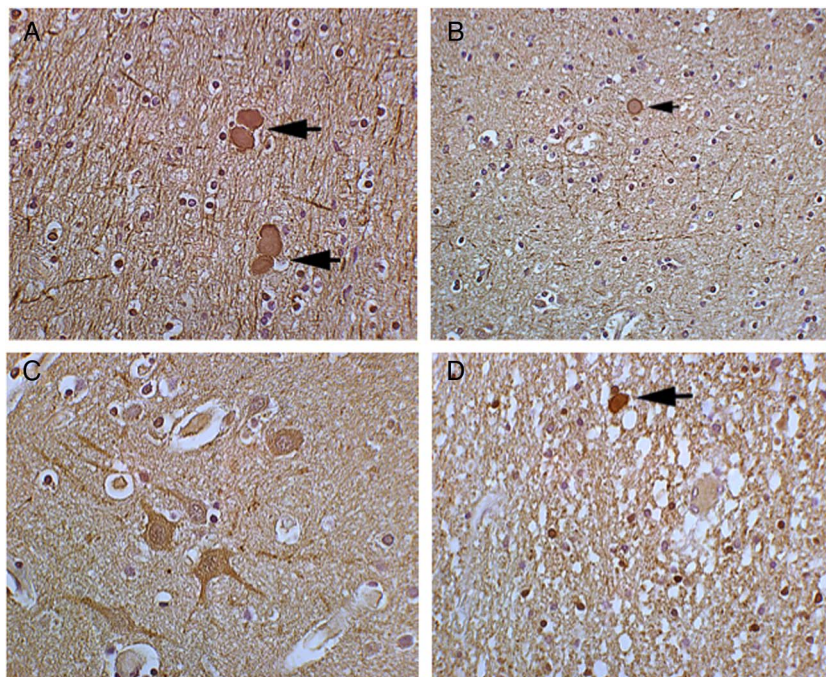


Figure 4 Tangles are observed in the thalamus, basal ganglia and frontal cortex. Silver staining of the (A) thalamus showing numerous tangles (inset and arrowheads), (B) basal ganglia with neurofibrillary-like tangles (inset and arrowheads) and (C) frontal cortex with neurofibrillary-like tangle (arrowhead). Magnification is $\times 200$. WM, white matter.

Numerous amyloid plaques were detected around blood vessels and in the neuropil, some with a diffuse appearance and others condensed (figure 7A, insets, arrowheads). In addition, there was strong intracellular A β immunoreactivity

that had a granular appearance, with A β aggregates observed in neuronal and non-neuronal cells (figure 7B, C, insets). Immunolabeling for CD3 for cytotoxic T cells, CD20 for B cells or CD68 for macrophages was consistent with

Figure 5 The hp Tau accumulation and dendritic disruption shown via double immunofluorescent labeling. (A–B) The hp Tau is detected by anti-s396 antibody (red) as intracellular and extracellular accumulations. Abnormal dendritic arborization detected by anti-MAP2 antibody (green) is evident in focal nodular-like accumulations. (B) Inset shows co-localization of hp Tau with MAP2 (arrowheads). Nuclei are labeled with DAPI in blue (bar=40 μ m, $\times 200$ magnification). hp Tau, Hyperphosphorylated Tau.

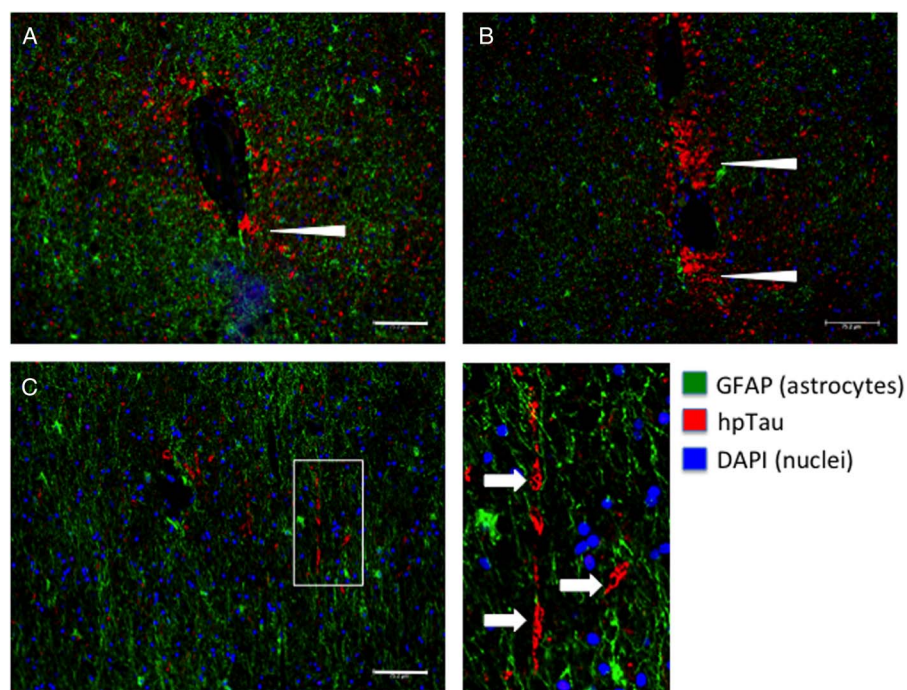
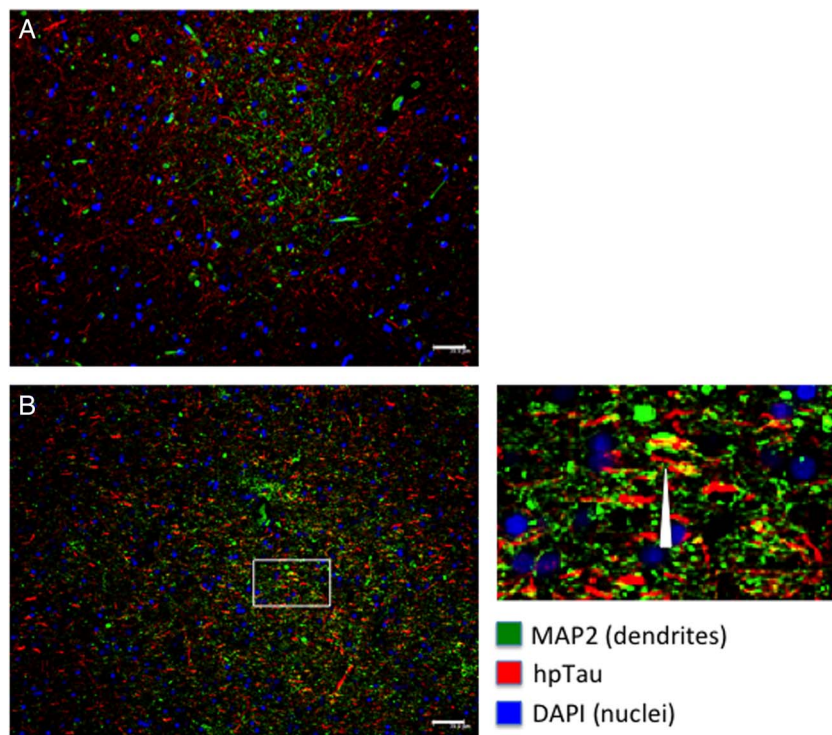



Figure 6 Double immunofluorescent labeling shows no overlap between hp Tau and astrocytes. (A, B) Accumulations of hp Tau (red, arrowheads) are observed surrounding vessels with reactive astrocytes in green. No co-localization is observed. (C) Double immunolabeling for hp Tau (red) and astrocytes (green). Inset (red, arrows) shows neuronal process damage. Nuclei are labeled with DAPI in blue (bar=40 μ m, $\times 200$ magnification). hp Tau, Hyperphosphorylated Tau.

expected findings for the patient's age and state of hypertensive cerebrovascular disease (data not shown).

In summary, atypical neurons displaying aberrant sprouting processes in response to injury are observed throughout cortical gray and white matter. Abundant amyloid deposits

reminiscent of AD plaques, with accompanying intracellular granular structures, are observed as well. On the other hand, amyloid plaques from this case do not show typical dystrophic neurites associated with AD pathology. Neurofibrillary-like tangles are also present in the white



J Investig Med: first published as 10.1136/jim-2016-000390 on 6 April 2017. Downloaded from [file:/](#) on April 10, 2024 by guest. Protected by copyright.

J Investig Med: first published as 10.1136/jim-2016-000390 on 6 April 2017. Downloaded from [file:/](#) on April 10, 2024 by guest. Protected by copyright.

J Investig Med: first published as 10.1136/jim-2016-000390 on 6 April 2017. Downloaded from [file:/](#) on April 10, 2024 by guest. Protected by copyright.

this case may be a by-product of a compensatory secondary mechanism in response to disruption of lipid homeostasis.^{77–80} There are several alternative explanations and potential contributors to the neuropathology that we have reported. First of all, AD-like pathology and vascular changes were observed. However, unlike AD, this case does not show typical dystrophic neurites. On the other hand, the tauopathy observed may not necessarily explain the mechanisms of cellular dysfunction but rather serves as a useful (pathological or phenotypic) marker for CFS. Taken together, holistic analysis of the neuropathological findings from this case point to severe neuronal dysfunction with hallmarks characteristic of neurodegeneration. This being the first neuropathological report of a CFS case points to the need for more extensive large-scale investigations into the neuropathologies associated with CFS in order to establish a consistent rubric for identification, diagnosis and scoring of the syndrome as part of a greater class of CNS diseases with similar clinical presentation.

MATERIALS AND METHODS

Brain tissue

Brain tissue was obtained from the National Chronic Fatigue Immune Dysfunction (CFIDS) Foundation in accordance with Temple University Human Subjects Protections. Formalin-fixed tissues were embedded in paraffin and sectioned into 4 µm sections with a microtome and mounted onto glass slides. Sections were deparaffinized in xylene and rehydrated through descending grades of ethanol up to water.

Immunolabeling

Non-enzymatic antigen retrieval in 10 mM citrate buffer, pH 6.0 was conducted for 30 min at 97°C in a vacuum oven. Sections were washed in 1X phosphate buffered saline (PBS) and placed in 5% normal goat or horse serum supplemented with 0.1% bovine serum albumin (BSA) for 2 hours. Sections were then incubated with primary antibodies overnight at room temperature in a humidified chamber. Primary antibodies included GFAP for astrocytes (1:200, Abcam, Cambridge, Massachusetts, USA); Iba-1 for microglia (1:200, Abcam); hp Tau (s396; 1:200, Abcam); PHF (1:200, Thermo Scientific, Grand Island, New York, USA); neurofilament (SMI312, 1:200, Abcam) and MAP2 for dendrites (1:200, Cell Signaling, Temecula, California, USA). After incubation with primary antibodies, sections for immunofluorescence were washed in 1X PBS and incubated with fluorescein isothiocyanate-conjugated secondary antibody (1:500) and Texas-redisothiocyanate-tagged secondary antibodies (1:500; Thermo-Scientific) for 2 hours at room temperature and dark conditions. Finally, sections were cover-slipped with an aqueous-based mounting media containing 4,6-diamidino-2-phenylindole, dihydrochloride (DAPI) for nuclear labeling (Vector Laboratories), and visualized with a Leica Advanced Wide field imaging system (Leica Microsystems; Buffalo Grove, Illinois, USA). Sections for diaminobenzidine (DAB) staining were incubated in biotinylated secondary antibody (1:200; Vector Laboratories, Burlingame, California, USA), followed by Avidin D-HRP (ABC Elite; Vector) and reacted with DAB (0.2 mg/mL) in 50 mM Tris buffer (pH 7.4) with 0.001% H₂O₂.

Silver staining

Tissue sections were mounted on glass slides as for immunohistochemistry (IHC) and silver stained according to Bielschowsky's method as previously described.⁸¹ Briefly, sections were rehydrated up to water, stained with 20% silver nitrate solution and washed in water. Concentrated ammonium hydroxide was added dropwise to the silver nitrate solution while stirring to dissolve the dark initial precipitate. Sections were then incubated in 0.1% ammonium hydroxide and developed by incubating slides in developing solution (0.2 mL 37% formaldehyde, 12 mL dH₂O, 12.5 µL 20% nitric acid and 0.05 g citric acid) added to the silver hydroxide solution. Sections were washed again in 0.1% ammonium hydroxide followed by water, toned in 0.2% gold chloride and fixed in 5% sodium thiosulfate. After washing again in water, sections were dehydrated through alcohols to xylene and mounted with glass coverslips.

Contributors DL conducted experiments, analyzed data, and wrote the manuscript. MS assisted with data generation and edited the manuscript. AC assisted with data collection and manuscript preparation. EM reviewed all neuropathological findings, analyzed the slides, and assisted with writing the manuscript.

Funding This work was supported by funding from the National Chronic Fatigue and Immune Dysfunction Syndrome Foundation to DL.

Competing interests None declared.

Ethics approval Temple University IRB Human Subjects Committee.

Provenance and peer review Not commissioned; externally peer reviewed.

REFERENCES

- Ocon AJ. Caught in the thickness of brain fog: exploring the cognitive symptoms of chronic fatigue syndrome. *Front Physiol* 2013;4:63.
- Fischer DB, William AH, Strauss AC, et al. Chronic fatigue syndrome: the current status and future potentials of emerging biomarkers. *Fatigue* 2014;2:93–109.
- Nacul L, O'Donovan DG, Lacerda EM, et al. Considerations in establishing a post-mortem brain and tissue bank for the study of myalgic encephalomyelitis/chronic fatigue syndrome: a proposed protocol. *BMC Res Notes* 2014;7:370.
- Acheson ED. The clinical syndrome variously called benign myalgic encephalomyelitis, Iceland disease and epidemic neuromyasthenia. *Am J Med* 1959;26:569–95.
- Tang LW, Zheng H, Chen L, et al. Gray matter volumes in patients with chronic fatigue syndrome. *Evid Based Complement Alternat Med* 2015;2015:380615.
- Okada T, Tanaka M, Kuratsune H, et al. Mechanisms underlying fatigue: a voxel-based morphometric study of chronic fatigue syndrome. *BMC Neurol* 2004;4:14.
- de Lange FP, Kalkman JS, Bleijenberg G, et al. Gray matter volume reduction in the chronic fatigue syndrome. *Neuroimage* 2005;26:777–81.
- Puri BK, Jakeman PM, Agour M, et al. Regional grey and White matter volumetric changes in myalgic encephalomyelitis (chronic fatigue syndrome): a voxel-based morphometry 3 T MRI study. *Br J Radiol* 2012;85:e270–273.
- Zeineh MM, Kang J, Atlas SW, et al. Right arcuate fasciculus abnormality in chronic fatigue syndrome. *Radiology* 2015;274:517–26.
- Barnden LR, Crouch B, Kwiatek R, et al. A brain MRI study of chronic fatigue syndrome: evidence of brainstem dysfunction and altered homeostasis. *NMR Biomed* 2011;24:1302–12.
- Biswal B, Kunwar P, Natelson BH. Cerebral blood flow is reduced in chronic fatigue syndrome as assessed by arterial spin labeling. *J Neurol Sci* 2011;301:9–11.
- Costa DC, Tannock C, Brostoff J. Brainstem perfusion is impaired in chronic fatigue syndrome. *QJM* 1995;88:767–73.
- Tirelli U, Chierichetti F, Tavio M, et al. Brain positron emission tomography (PET) in chronic fatigue syndrome: preliminary data. *Am J Med* 1998;105:545–85.

- 14 Razumovsky AY, DeBusk K, Calkins H, *et al.* Cerebral and systemic hemodynamics changes during upright tilt in chronic fatigue syndrome. *J Neuroimaging* 2003;13:57–67.
- 15 Cook DB, O'Connor PJ, Lange G, *et al.* Functional neuroimaging correlates of mental fatigue induced by cognition among chronic fatigue syndrome patients and controls. *Neuroimage* 2007;36:108–22.
- 16 Lange G, Steffener J, Cook DB, *et al.* Objective evidence of cognitive complaints in chronic fatigue syndrome: a BOLD fMRI study of verbal working memory. *Neuroimage* 2005;26:513–24.
- 17 Michiels V, Cluydts R. Neuropsychological functioning in chronic fatigue syndrome: a review. *Acta Psychiatr Scand* 2001;103:84–93.
- 18 Michiels V, de Gucht V, Cluydts R, *et al.* Attention and information processing efficiency in patients with chronic fatigue syndrome. *J Clin Exper Neuropsych* 1999;21:709–29.
- 19 Hawk C, Jason LA, Torres-Harding S. Differential diagnosis of chronic fatigue syndrome and major depressive disorder. *Intern J Behav Med* 2006;13:244–51.
- 20 DeLuca J, Johnson SK, Beldowicz D, *et al.* Neuropsychological impairments in chronic fatigue syndrome, multiple sclerosis, and depression. *J Neurol Neurosurg Psychiatr* 1995;58:38–43.
- 21 Demitrack MA, Dale JK, Straus SE, *et al.* Evidence for impaired activation of the hypothalamic-pituitary-adrenal axis in patients with chronic fatigue syndrome. *J Clin Endocrinol Metab* 1991;73:1224–34.
- 22 Wood B, Wessely S, Papadopoulos A, *et al.* Salivary cortisol profiles in chronic fatigue syndrome. *Neuropsychobiology* 1998;37:1–4.
- 23 Roberts AD, Wessely S, Chalder T, *et al.* Salivary cortisol response to awakening in chronic fatigue syndrome. *Br J Psychiatry* 2004;184:136–41.
- 24 MacHale SM, Cavanagh JT, Bennie J, *et al.* Diurnal variation of adrenocortical activity in chronic fatigue syndrome. *Neuropsychobiology* 1998;38:213–17.
- 25 Nater UM, Maloney E, Boneva RS, *et al.* Attenuated morning salivary cortisol concentrations in a population-based study of persons with chronic fatigue syndrome and well controls. *J Clin Endocrinol Metab* 2008;93:703–9.
- 26 Nater UM, Youngblood LS, Jones JF, *et al.* Alterations in diurnal salivary cortisol rhythm in a population-based sample of cases with chronic fatigue syndrome. *Psychosom Med* 2008;70:298–305.
- 27 Papadopoulos AS, Cleare AJ. Hypothalamic-pituitary-adrenal axis dysfunction in chronic fatigue syndrome. *Nature Rev Endo* 2012;8:22–32.
- 28 Gay CW, Robinson ME, Lai S, *et al.* Abnormal resting-state functional connectivity in patients with chronic fatigue syndrome: results of seed and data-driven analyses. *Brain Conn* 2016;6:48–56.
- 29 Yoshiuchi K, Farkas J, Natelson BH. Patients with chronic fatigue syndrome have reduced absolute cortical blood flow. *Clin Physiol Funct Imaging* 2006;26:83–6.
- 30 Miller AH, Jones JF, Drake DF, *et al.* Decreased basal ganglia activation in subjects with chronic fatigue syndrome: association with symptoms of fatigue. *PLoS ONE* 2014;9:e98156.
- 31 Morris G, Maes M. Oxidative and nitrosative stress and immune-inflammatory pathways in patients with myalgic encephalomyelitis (ME)/chronic fatigue syndrome (CFS). *Curr Neuropsychopharmacol* 2014;12:168–85.
- 32 Shungu DC, Weiduschat N, Murrrough JW, *et al.* Increased ventricular lactate in chronic fatigue syndrome. III. Relationships to cortical glutathione and clinical symptoms implicate oxidative stress in disorder pathophysiology. *NMR Biomed* 2012;25:1073–87.
- 33 Blomstrand E, Celsing F, Newsholme EA. Changes in plasma concentrations of aromatic and branched-chain amino acids during sustained exercise in man and their possible role in fatigue. *Acta Physiol Scand* 1988;133:115–21.
- 34 Demitrack MA, Gold PW, Dale JK, *et al.* Plasma and cerebrospinal fluid monoamine metabolism in patients with chronic fatigue syndrome: preliminary findings. *Biol Psychol* 1992;32:1065–77.
- 35 Cleare AJ, Messa C, Rabiner EA, *et al.* Brain 5-HT_{1A} receptor binding in chronic fatigue syndrome measured using positron emission tomography and [¹¹C]WAY-100635. *Biol Psychol* 2005;57:239–46.
- 36 Kuratsune H, Yamaguti K, Lindh G, *et al.* Brain regions involved in fatigue sensation: reduced acetylcholine uptake into the brain. *Neuroimage* 2002;17:1256–65.
- 37 Yamamoto S, Ouchi Y, Onoe H, *et al.* Reduction of serotonin transporters of patients with chronic fatigue syndrome. *Neuroreport* 2004;15:2571–4.
- 38 Natelson BH, Haghighi MH, Ponzio NM. Evidence for the presence of immune dysfunction in chronic fatigue syndrome. *Clin Diag Lab Immunol* 2002;9:747–52.
- 39 Natelson BH, Weaver SA, Tseng CL, *et al.* Spinal fluid abnormalities in patients with chronic fatigue syndrome. *Clin Diag Lab Immunol* 2005;12:52–5.
- 40 Nakatomi Y, Mizuno K, Ishii A, *et al.* Neuroinflammation in patients with chronic fatigue syndrome/myalgic encephalomyelitis: an ¹¹C-(R)-PK11195 PET Study. *J Nucl Med* 2014;55:945–50.
- 41 Schmalzing KB, Lewis DH, Fiedelak JL, *et al.* Single-photon emission computerized tomography and neurocognitive function in patients with chronic fatigue syndrome. *Psychosom Med* 2003;65:129–36.
- 42 Lewis DH, Mayberg HS, Fischer ME, *et al.* Monozygotic twins discordant for chronic fatigue syndrome: regional cerebral blood flow SPECT. *Radiology* 2001;219:766–73.
- 43 Mathew SJ, Mao X, Keegan KA, *et al.* Ventricular cerebrospinal fluid lactate is increased in chronic fatigue syndrome compared with generalized anxiety disorder: an in vivo 3.0 T (1)H MRS imaging study. *NMR Biomed* 2009;22:251–8.
- 44 Jerjes WK, Taylor NF, Peters TJ, *et al.* Urinary cortisol and cortisol metabolite excretion in chronic fatigue syndrome. *Psychosom Med* 2006;68:578–82.
- 45 Jerjes WK, Taylor NF, Wood PJ, *et al.* Enhanced feedback sensitivity to prednisolone in chronic fatigue syndrome. *Psychoneuroendocrinology* 2007;32:192–8.
- 46 Cleare AJ. The HPA axis and the genesis of chronic fatigue syndrome. *Trends Endocrinol Metab* 2004;15:55–9.
- 47 Tang SW, Chu E, Hui T, *et al.* Influence of exercise on serum brain-derived neurotrophic factor concentrations in healthy human subjects. *Neurosci Lett* 2008;431:62–5.
- 48 Katafuchi T, Kondo T, Take S, *et al.* Brain cytokines and the 5-HT system during poly I:C-induced fatigue. *Ann N Y Acad Sci* 2006;1088:230–7.
- 49 Tanaka S, Kuratsune H, Hidaka Y, *et al.* Autoantibodies against muscarinic cholinergic receptor in chronic fatigue syndrome. *Intern Mol Med* 2003;12:225–30.
- 50 Yamamoto S, Ouchi Y, Nakatsuka D, *et al.* Reduction of [¹¹C](+)-3-MPB binding in brain of chronic fatigue syndrome with serum autoantibody against muscarinic cholinergic receptor. *PLoS ONE* 2012;7:e51515.
- 51 Kuratsune H, Yamaguti K, Takahashi M, *et al.* Acylcarnitine deficiency in chronic fatigue syndrome. *Clin Infect Dis* 1994;18(Suppl 1):S62–67.
- 52 Reinikainen KJ, Riekkinen PJ, Halonen T, *et al.* Decreased muscarinic receptor binding in cerebral cortex and hippocampus in Alzheimer's disease. *Life Sci* 1987;41:453–61.
- 53 Rinne JO, Laakso K, Lonnberg P, *et al.* Brain muscarinic receptors in senile dementia. *Brain Res* 1985;336:19–25.
- 54 Enna SJ, Bird ED, Bennett JP Jr, *et al.* Huntington's chorea. Changes in neurotransmitter receptors in the brain. *N Engl J Med* 1976;294:1305–9.
- 55 Lange KW, Javoy-Agid F, Agid Y, *et al.* Brain muscarinic cholinergic receptors in Huntington's disease. *J Neurol* 1992;239:103–4.
- 56 Wastek GJ, Yamamura HI. Biochemical characterization of the muscarinic cholinergic receptor in human brain: alterations in Huntington's disease. *Mol Pharmacol* 1978;14:768–80.
- 57 Ahlskog JE, Richelson E, Nelson A, *et al.* Reduced D₂ dopamine and muscarinic cholinergic receptor densities in caudate specimens from fluctuating parkinsonian patients. *Ann Neurol* 1991;30:185–91.
- 58 Crook JM, Tomaskovic-Crook E, Copolov DL, *et al.* Decreased muscarinic receptor binding in subjects with schizophrenia: a study of the human hippocampal formation. *Biol Psychiatry* 2000;48:381–8.
- 59 Dean B, McLeod M, Keriakous D, *et al.* Decreased muscarinic₁ receptors in the dorsolateral prefrontal cortex of subjects with schizophrenia. *Mol Psychiatry* 2002;7:1083–91.
- 60 Zavitsanou K, Katsifis A, Mattner F, *et al.* Investigation of m1/m4 muscarinic receptors in the anterior cingulate cortex in schizophrenia, bipolar disorder, and major depression disorder. *Neuropsychopharmacol* 2004;29:619–25.
- 61 Fukuda K, Straus SE, Hickie I, *et al.* The chronic fatigue syndrome: a comprehensive approach to its definition and study. International Chronic Fatigue Syndrome Study Group. *Ann Intern Med* 1994;121:953–9.
- 62 Pollet C, Natelson BH, Lange G, *et al.* Medical evaluation of Persian Gulf veterans with fatigue and/or chemical sensitivity. *J Med* 1998;29:101–13.
- 63 Bourdette DN, McCauley LA, Barkhuizen A, *et al.* Symptom factor analysis, clinical findings, and functional status in a population-based case control study of Gulf War unexplained illness. *J Occup Environ Med* 2001;43:1026–40.
- 64 Jason LA, Richman JA, Rademaker AW, *et al.* A community-based study of chronic fatigue syndrome. *Arch Intern Med* 1999;159:2129–37.
- 65 Kipen HM, Hallman W, Kang H, *et al.* Prevalence of chronic fatigue and chemical sensitivities in Gulf Registry Veterans. *Arch Environ Health* 1999;54:313–18.
- 66 Omalu B, Hammers JL, Bailes J, *et al.* Chronic traumatic encephalopathy in an Iraqi war veteran with posttraumatic stress disorder who committed suicide. *Neurosurg Focus* 2011;31:E3.

- 67 Chen Y, Huang W. Non-impact, blast-induced mild TBI and PTSD: concepts and caveats. *Brain Inj* 2011;25:641–50.
- 68 Jaffee MS, Meyer KS. A brief overview of traumatic brain injury (TBI) and post-traumatic stress disorder (PTSD) within the Department of Defense. *Clin Neuropsych* 2009;23:1291–8.
- 69 Peterson AL, Luethcke CA, Borah EV, *et al.* Assessment and treatment of combat-related PTSD in returning war veterans. *J Clin Psych Med Settings* 2011;18:164–75.
- 70 Binder LM, Storzbach D, Campbell KA, *et al.* Neurobehavioral deficits associated with chronic fatigue syndrome in veterans with Gulf War unexplained illnesses. *J Intern Neuropsychol Soc* 2001;7:835–9.
- 71 Storzbach D, Rohlman DS, Anger WK, *et al.* Neurobehavioral deficits in Persian Gulf veterans: additional evidence from a population-based study. *Environ Res* 2001;85:1–13.
- 72 Griffith JP, Zarrouf FA. A systematic review of chronic fatigue syndrome: don't assume it's depression. *Prim Care Companion J Clin Psychiatry* 2008;10:120–8.
- 73 Holmes GP, Kaplan JE, Gantz NM, *et al.* Chronic fatigue syndrome: a working case definition. *Ann Intern Med* 1988;108:387–9.
- 74 Ferrer I. Stress kinases involved in tau phosphorylation in Alzheimer's disease, tauopathies and APP transgenic mice. *Neurotox Res* 2004;6:469–75.
- 75 Puig B, Gomez-Isla T, Ribe E, *et al.* Expression of stress-activated kinases c-Jun N-terminal kinase (SAPK/JNK-P) and p38 kinase (p38-P), and tau hyperphosphorylation in neurites surrounding betaA plaques in APP Tg2576 mice. *Neuropath Appl Neurobiol* 2004;30:491–502.
- 76 Duka V, Lee JH, Credle J, *et al.* Identification of the sites of tau hyperphosphorylation and activation of tau kinases in synucleinopathies and Alzheimer's diseases. *PLoS ONE* 2013;8:e75025.
- 77 Koudinov A, Kezlya E, Koudinova N, *et al.* Amyloid-beta, tau protein, and oxidative changes as a physiological compensatory mechanism to maintain CNS plasticity under Alzheimer's disease and other neurodegenerative conditions. *J Alzheimers Dis* 2009;18:381–400.
- 78 Lee HG, Perry G, Moreira PI, *et al.* Tau phosphorylation in Alzheimer's disease: pathogen or protector? *Trends Mol Med* 2005;11:164–9.
- 79 Moreira PI, Zhu X, Lee HG, *et al.* The (un)balance between metabolic and oxidative abnormalities and cellular compensatory responses in Alzheimer disease. *Mech Ageing Dev* 2006;127:501–6.
- 80 Moreira PI, Zhu X, Liu Q, *et al.* Compensatory responses induced by oxidative stress in Alzheimer disease. *Biol Res* 2006;39:7–13.
- 81 Stevens BA. *Theory and practice of histological techniques*. 2nd edn. Churchill Livingstone, 1982.