

Continuous low-dose everolimus shrinkage tuberous sclerosis complex-associated renal angiomyolipoma: a 48-month follow-up study

Chang-Ching Wei,^{1,2} Jeng-Daw Tsai,^{3,4,5,6} Ji-Nan Sheu,^{7,8} Sung-Lang Chen,^{7,9} Teng-Fu Tsao,^{7,10} Sheng-Hui Yang,¹¹ Jeng-Daw Tsai^{7,8}

For numbered affiliations see end of article.

Correspondence to

Dr Jeng-Daw Tsai,
Department of Paediatrics,
Chung Shan Medical
University Hospital, Taichung
402, Taiwan;
fernand.tsai@msa.hinet.net

Accepted 20 October 2018

ABSTRACT

Tuberous sclerosis complex (TSC) is a rare disease that causes multisystem benign neoplasm, induced by dysregulation of the mammalian target of the rapamycin pathway (mTOR). This study aimed to examine the effects of continuous low-dose everolimus, a potent and selective inhibitor of mTOR, on the treatment of TSC-associated renal angiomyolipoma (AML). Between July 2013 and August 2017, 11 patients with TSC-AML were enrolled for an everolimus therapy protocol. An oral everolimus dose starting at 2.5 mg daily was gradually increased to 5.0 mg daily. All patients were evaluated using MRI or CT scanning at baseline, 12, 24, 36 and 48 months after the start of treatment for measuring changes of renal AML mass volume. Everolimus therapy resulted in significant shrinkage of TSC-AML volume after 48 months follow-up. Serum levels of everolimus were subdivided into group I (<8 ng/mL, n=6) and group II (>8 ng/mL, n=5). The volume reduction rates were 10.6%–65.2% in group I and 42.5%–70.6% in group II. To evaluate the response to treatment, three of six (50%) were responders in group I, and all the patients in group II (5/5, 100%) were responders. The differences in AML volume reduction between the groups were statistically significant at 12 months (p=0.011), 24 months (p=0.006), 36 months (p=0.014) and 48 months (p=0.05). These results suggest that continuous low-dose everolimus therapy (2.5–5 mg daily) might be effective in shrinking TSC-AML volume and minimizes adverse effects and subsequent reducing medical costs.

INTRODUCTION

Tuberous sclerosis complex (TSC) is a systemic and progressive disease caused by mammalian target of rapamycin (mTOR) dysregulation, which results in multisystem neoplasm. Angiomyolipoma (AML) is the most frequent benign renal tumor. AML is observed in approximately 75% of patients with TSC. AML in TSC often appears as multiple and bilateral, with rapid growth during childhood and adolescence that stabilizes throughout adulthood. The majority of the patients at risk face significant morbidities with increasing age.¹ The vascular component of these neoplasms makes them susceptible

Significance of this study

What is already known about this subject?

- ▶ Tuberous sclerosis complex (TSC) is a systemic disease caused by mammalian target of rapamycin (mTOR) dysregulation, which results in multisystem neoplasm.
- ▶ Angiomyolipoma (AML) is the most frequent benign renal tumor, which is observed in approximately 75% of patients with TSC.
- ▶ Everolimus, a potent and selective inhibitor of mTOR, has been used to treat TSC-associated subependymal giant cell astrocytoma in some recent studies.

What are the new findings?

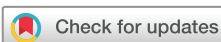- ▶ Everolimus therapy resulted in significant shrinkage of TSC-AML volume after 48 months follow-up.
- ▶ Maximum AML volume reduction was achieved around 6–12 months of everolimus treatment and the AML volume remain stable during study period.
- ▶ Adverse effects of everolimus included oral ulcers (72.7%), acne-like skin lesions (27.3%) and hyperlipidemia (36.4%), which were well tolerated by the patients.

How might these results change the focus of research or clinical practice?

- ▶ Continuous low-dose everolimus therapy is safe and effective to reduce TSC-AML volume.

to bleeding, and larger AML often develop aneurysms that may complicate renal vascular rupture.² It may be more rational to use an mTOR inhibitor to minimize associated complications of AML.³ One of the concerns associated with mTOR therapy is the requirement for continuous use to maintain the derived benefit from the treatment.

Everolimus is derivative of rapamycin and being a potent and selective inhibitor of mTOR. It is currently used as an immunosuppressant to prevent rejection of organ transplants and in the treatment of renal cell cancer and a number of



© American Federation for Medical Research 2018. No commercial re-use. See rights and permissions. Published by BMJ.

To cite: Wei C-C, Tsai J-D, Sheu J-N, et al. *J Investig Med* Epub ahead of print: [please include Day Month Year]. doi:10.1136/jim-2018-000865

other cancers. The exact requirements for ongoing treatment with everolimus for individual with TSC have been published recently.⁴ Although everolimus is indicated for TSC-AML, the majority of experience of using the drug for TSC comes from TSC-associated subependymal giant cell astrocytoma (SEGA).^{5,6} To shrink the volume in the brain, a higher dosage may be required than for lesions due to the blood–brain barrier. It may be eventually possible to use lower maintenance doses of everolimus for non-neurological comorbidities.⁷ Once patients have stabilized, it is then possible to reduce the likelihood of adverse events developing in long-term everolimus users.

The purpose of the current study was to evaluate the potential efficacy of low-dose everolimus for AML in Taiwanese patients.

METHODS

Patient selection and study design

All the patients with TSC were prescribed everolimus therapy due to large SEGA, lymphangioliomyomatosis-associated pneumothorax, and large AML. Diagnosis criteria of TSC followed the 2012 International TSC Consensus Conference Guidelines.⁸ The initial dose of everolimus started from 2.5 mg per day of all the participants. Dose was titrated up to 5.0 mg per day determined clinically based on the tolerance to the adverse effects of everolimus. To follow-up the efficacy, baseline and annual abdomen MR images for individuals were performed after the beginning of the protocol. TSC-AML was defined as an identifiable AML in the renal parenchyma of the patients with TSC. The maximal volume of TSC-AML was calculated for dominant renal lesions according to the volume equation. The volume equation = $(4/3 \times \pi \times a \times b \times c)$. a, b, and c represent the respective three-dimensional radii (centimeter) of the maxima, with each volume being treated as an ellipsoid. The volume reduction rates of TSC-AML were calculated by using the equation $(V_{\text{Pre-Therapy}} - V_{\text{Post-Therapy}}) / V_{\text{Pre-Therapy}} \times 100\%$; where $V_{\text{Pre-Therapy}}$ represents pre-everolimus therapy tumour volume and $V_{\text{Post-Therapy}}$ represents post-everolimus therapy tumor volume.

MR image analysis

Abdominal studies of MR images were conducted by using a 1.5-Tesla scanner (Magnetom Sonata, Siemens Medical Solutions, Erlangen, Germany, or Signa Horizon Echo-speed, General Electric Medical Systems, Milwaukee, Wisconsin, USA) equipped with a high-performance three-axis gradient system. The images scan protocol included T1-weighted, T2-weighted, fluid attenuation inversion recovery and diffusion-weighted imaging, and contrast-enhanced MRI was used if indicated. All MR images were performed with the patient in supine position, and coronal, sagittal and axial scans were acquired with T1-weighted fast spoiled gradient echo and T2-weighted fast spin echo protocols with and without fat suppression. In patients with multiple renal lesions, only the largest one was analyzed.

Statistical methods

Descriptive statistics were used to report the change of volumes size at baseline and annual follow-up. Data of volume sized were presented as medians and ranges for non-parametric data. Wilcoxon signed-rank test, Mann-Whitney U test, or the Friedman test were used to compare statistically significant differences of continuous variables. Statistical significance was defined as $p < 0.05$. All statistical analyses were conducted using SPSS for Windows, V.14.0.

RESULTS

During the study period, there were 11 patients including 1 male and 10 females, aged 13–44 years, enrolled into this study (table 1). Of the patients, five patients received 2.5 mg oral everolimus daily and six received 5.0 mg daily. Administration dose of everolimus was calculated as $\mu\text{g}/\text{kg}$, and serum through levels are showed as ng/mL. The calculation of the correlation is shown in figure 1 ($p = 0.159$). Serum levels were subdivided into group I ($< 8 \text{ ng/mL}$, $n = 6$) and group II ($> 8 \text{ ng/mL}$, $n = 5$). The volume reduction rates were 10.6%–65.2% in group I and 42.5%–70.6% in group II. To evaluate the response, three of six (50%) were responders in group I, and all the patients in group II (5/5, 100%) were responders (table 2). Adverse effects were presented in all the participants, included oral ulcers ($n = 8$, 72.7%),

Table 1 Demographic data of genotypes, everolimus level in patients with tuberous sclerosis complex-associated renal angiomyolipoma (TSC-AML)

Patient, n	Age (years)	Gender	Gene	Body weight (kg)	Dose ($\mu\text{g}/\text{kg}/\text{day}$)		Mean trough level (ng/mL)
					(mg/day)	($\mu\text{g}/\text{kg}/\text{day}$)	
1	14	M	TSC2	80	2.5	31	3.14
2	20	F	TSC2	54		46	2.2
3	22	F	ND	55		45	1.5
4	27	F	TSC1	62		40	7.7
5	24	F	TSC2	41		61	2.0
6	26	F	TSC2	53	5.0	94	8.3
7	31	F	TSC1	49		100	15.4
8	39	F	TSC2	64		78	13.9
9	44	F	TSC1	58		86	11.7
10	17	F	TSC2	52		96	2.0
11	13	F	ND	69		72	9.0

F, female; M, male; ND, not done/not identified.

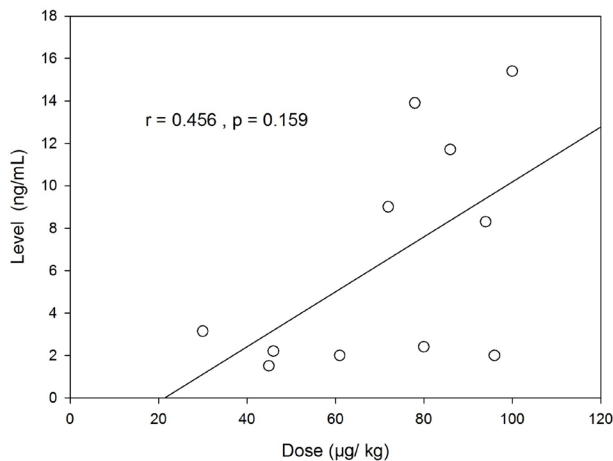


Figure 1 The correlation of everolimus concentration ($\mu\text{g}/\text{kg}$) and serum through level (ng/mL).

acne-like skin lesions ($n=3$, 27.3%) and hyperlipidemia ($n=4$, 36.4%). All the adverse effect were well tolerated by the patients without further serious adverse events during the observation period.

The long-term efficacy of everolimus for TSC-AML volume reduction during the 48 month follow-up period is shown in figure 2. AML volume reduction was achieved around 6–12 months after starting everolimus and subsequent volume size appeared to remain stable on maintenance everolimus during the studied period. In cases 2, 3 and 5, the AML mass volume regrew up to 120%, 101.2% and 77.5% after withdrawal from the treatment protocol. The AML volume between the groups was significantly reduced at 12 months ($p=0.011$), 24 months ($p=0.006$), 36 months ($p=0.014$) and 48 months ($p=0.05$) (figure 3).

DISCUSSION

The current study results provide evidence of acceptable dose-dependent responses with tolerable side effects for

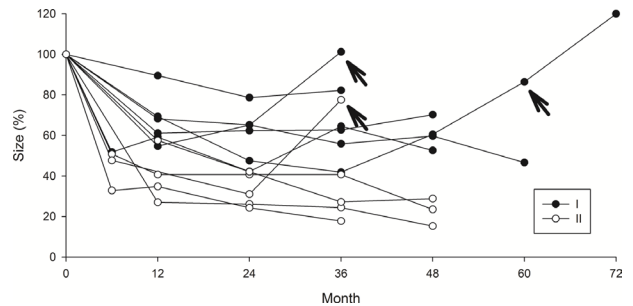


Figure 2 The long-term effect of everolimus on associated renal angiomyolipoma (AML) volume reduction was achieved around 6–12 months after treatment and subsequent volume size seemed remain stable during follow-up up to 48 months. In cases 2, 3 and 5, the AML mass volume regrew up after withdrawal from the treatment protocol (arrow).

TSC-associated renal AML to mTOR therapy. The usual starting dose of the everolimus for TSC-AML is 10 mg for indications. The current study displayed the daily low-dose 2.5–5 mg for this population of TSC-AML and also shrinkage volumes. This is clinically important because it is potentially better tolerated, less toxicity and potentially can be used for longer periods of time. The study also serves a basis for a larger study with longer phase of treatment designed in the future.

Embolization had previously been proposed as first-line treatment for AML aneurysms with acute hemorrhage; however, mTOR inhibitors constitute a new therapy for TSC-AML. Everolimus, a mTOR inhibitor, is now recommended as a first-line treatment for TSC-AML considering their effect on vascularity and avoiding risks of embolization.⁹ The size of aneurysm could be reduced due to shrinkage of vasculature by mTOR inhibitor therapy, and it might explain why the marked shrinkage of TSC-AML is associated with a very low incidence of hemorrhage.¹⁰ The only mTOR inhibitor approved for the treatment of

Table 2 Results of sizes reduction of patients with tuberous sclerosis complex-associated renal angiomyolipoma (TSC-AML) treated with everolimus for 2 years, $n=11$

Patients	Group	Size (cm^3)		RR (%)	Long-term PR (months)	Side effect
		Before	After			
1	I	84.5	51.6	38.9	–	Acne
2	I	2.3	1.2	47.8	–	Oral ulcers/acne
3	I	2.0	1.4	30.0	+ (24)	Oral ulcers/cellulitis
4	I	367.7	328.9	10.6	–	Hyperlipidemia
5	I	79.1	27.5	65.2	+ (6)	Oral ulcer
6	II	2497.0	793.6	68.2	+ (12)	Oral ulcers
7	II	94.8	35.2	62.9	+ (12)	Diarrhea
8	II	544.5	159.9	70.6	+ (24)	Oral ulcers
9	II	2473.7	1421.9	42.5	+ (60)	Oral ulcers, hyperlipidemia/DM/HTN
10	I	77.2	45.7	40.8	+ (24)	Oral ulcer, hyperlipidemia, amenorrhea, proteinuria
11	II	66.1	31.5	52.3	+ (6)	Oral ulcer, acne, hyperlipidemia, hyperglycemia amenorrhea, liver function impairment

Mean trough level ($\mu\text{g}/\text{kg}$) <8: group I; >8: group II.

DM, diabetes mellitus; HTN, hypertension.; PR, partial response; RR, reduction rate.

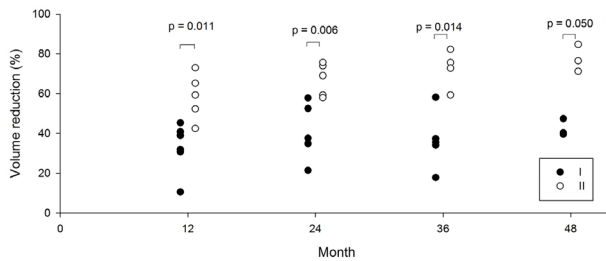


Figure 3 There is statistical significance between dosage groups of associated renal angiomyolipoma volume reduction from 12 to 48 months.

TSC-AML is everolimus, which is indicated in the treatment of patients with AML who are at risk of complications but do not need immediate surgery.¹¹ The International TSC Consensus Conference Guidelines (2012) recommend initiating mTOR inhibitor therapy in patients with TSC who have at least one growing, asymptomatic AML >3 cm in diameter.¹² Everolimus demonstrates reduction tumor size, and no kidney bleeding in long-term therapy.¹³

The mTOR inhibitors have been used for more than a decade in transplantation medicine and oncology.^{11,14} As a trial, standard dosages were reasonably higher than those recommended for TSC-AML treatment, and patients with the highest trough concentrations of everolimus had faster initial AML shrinkage. However, the ideal dosing in TSC-AML remains uncertain, although for a first induction treatment phase, higher doses can be followed by long-term maintenance treatment with reduced dosages. The dose of everolimus is recommended to be titrated to attain trough plasma concentrations of 5–15 ng/mL.¹⁵ In the EXIST-2 trial, which is the largest placebo controlled randomized trial to date, 10 mg everolimus per day was recommended in patients with AML, with a mean dose of 8.6 mg in the treatment group and 9.6 mg in the placebo group.¹⁶ The experience of previous trials is that 10 mg is often associated with adverse effects and that blood serum levels of everolimus are frequently very high (>15 ng/mL). When everolimus is proven to reduce the volume of AML in patients with TSC, the adverse effect are often overriding.¹⁷

It should be noted that in clinical trials trough concentrations below this range were often effective, and some patients tolerated levels above this range without experiencing additional adverse effects. Thus, targeted dosing may need to be individualized for some patients.^{18,19} The doses used in our current study are lower than those used in the EXIST-2 trial, and all patients achieved some degree of reduction in AML volume. In a subgroup analysis of EXIST-2 study, patients with AML under anticonvulsant presented mean everolimus trough levels of 3.8 ng/mL compared with 8.2 ng/mL for patients without anticonvulsants. In both groups, a significant response of AML was observed.²⁰

Regular monitor the efficacy of everolimus by performing image annually to investigate the size of AML is crucial for patients with TSC seem clinically stable on everolimus treatment. In clinical practice, many clinicians may start the dose of 5 mg everolimus for TSC-AML and adjust the dose according to monitored serum drug level, response of AML volume reduction, and the adverse drug effects. The dose is

titrated to achieve a trough concentration of 5–15 ng/mL; however, responses have been reported at trough concentrations as low as 3 ng/mL. Despite the fact that patients received dose reductions to 2.5–5 mg daily, almost all of them experienced sustained reduction in AML size.²¹ Further studies are therefore warranted to evaluate this approach. Trough levels between 3 and 8 ng/mL have been reported to be effective and tolerable, but eventually lower trough levels may be effective.¹⁷ Hence titration may not be necessary once acceptable efficacy has been achieved. The potential reason of AML response to low-dose everolimus is a lack of the blood–brain barrier effect, and consequently a better response than that observed for SEGA, although the efficacies of SEGA and AML have never been compared. Franz *et al*²² confirmed using the long-term efficacy and safety data from the completed EXIST-1 study that everolimus is a safe and effective therapeutic option for patients with TSC-associated SEGA. Moreover, when comparing the reduction percentage and response rate, TSC-AML presented a better response than TSC-SEGA in volume reduction over the study period. This implied that a blood-rich supply organ without blood–brain barrier effect leads to TSC-AML being more susceptible than SEGA.

The indications of everolimus in TSC were very restricted in the study population, which resulted in the small number of enrolled cases number in the current study. Besides it was conducted at a single center, and only 48 months of follow-up duration. There is no control group to compare the change of volume mass which could also be considered as a limitation in this study.

In conclusion, this study showed that continuous low-dose therapy of everolimus for patients with TSC-AML was effective. The significant reduction of lesion size was maintained on a dose of 2.5–5 mg, with contraction at 8–15 ng/mL with a consequent good responder rate. During the 48 month follow-up period, the mass volume reduction remained stable. We recommend the dose may adjust based on the serum levels and adverse effect. The current study will recommend the response of TSC-AML patients treated with everolimus are likely to be durable, although patients may require maintenance therapy to continue to derive benefit. The study also serves a basis for a larger study, longer phase of treatment in the future. Therefore, low everolimus therapy should be considered as a non-invasive therapy for the management of patients with large lesions of TSC-AML.

Author affiliations

- ¹Children's Hospital, China Medical University Hospital, Taichung, Taiwan
- ²School of Medicine, China Medical University, Taichung, Taiwan
- ³Division of Nephrology, Department of Pediatrics, MacKay Children's Hospital, Taipei, Taiwan
- ⁴Department of Medicine, MacKay Medical College, New Taipei City, Taiwan
- ⁵Department of Pediatrics, Taipei Medical University Hospital, Taipei, Taiwan
- ⁶Department of Pediatrics, School of Medicine, College of Medicine, Taipei Medical University, Taipei, Taiwan
- ⁷School of Medicine, Chung Shan Medical University, Taichung, Taiwan
- ⁸Department of Paediatrics, Chung Shan Medical University Hospital, Taichung, Taiwan
- ⁹Department of Urology, Chung Shan Medical University Hospital, Taichung, Taiwan
- ¹⁰Department of Medical Imaging, Chung Shan Medical University Hospital, Taichung, Taiwan
- ¹¹Department of Life Sciences, National Chung Hsing University, Taichung, Taiwan

Funding The authors have not declared a specific grant for this research from any funding agency in the public, commercial or not-for-profit sectors.

Competing interests None declared.

Patient consent Obtained.

Ethics approval The hospital's Institutional Review Board of Chung Shan Medical University Hospital approved this study (CSMUH No. CS12245) and the study was performed according to the Declaration of Helsinki.

Provenance and peer review Not commissioned; externally peer reviewed.

REFERENCES

- 1 Tsai JD, Wei CC, Chen SM, *et al.* Association between the growth rate of renal cysts/angiomyolipomas and age in the patients with tuberous sclerosis complex. *Int Urol Nephrol* 2014;46:1685–90.
- 2 Seyam RM, Alkhdair WK, Kattan SA, *et al.* The Risks of Renal Angiomyolipoma: Reviewing the Evidence. *J Kidney Cancer VHL* 2017;4:13–25.
- 3 Flum AS, Hamoui N, Said MA, *et al.* Update on the Diagnosis and Management of Renal Angiomyolipoma. *J Urol* 2016;195:834–46.
- 4 Tran LH, Zupanc ML. Long-term everolimus treatment in individuals with tuberous sclerosis complex: A review of the current literature. *Pediatr Neurol* 2015;53:23–30.
- 5 Yalon M, Ben-Sira L, Constantini S, *et al.* Regression of subependymal giant cell astrocytomas with RAD001 (Everolimus) in tuberous sclerosis complex. *Childs Nerv Syst* 2011;27:179–81.
- 6 Krueger DA, Care MM, Holland K, *et al.* Everolimus for subependymal giant-cell astrocytomas in tuberous sclerosis. *N Engl J Med* 2010;363:1801–11.
- 7 Curran MP. Everolimus: in patients with subependymal giant cell astrocytoma associated with tuberous sclerosis complex. *Paediatr Drugs* 2012;14:51–60.
- 8 Northrup H, Krueger DA. International Tuberous Sclerosis Complex Consensus Group. Tuberous sclerosis complex diagnostic criteria update: Recommendations of the 2012 international tuberous sclerosis complex consensus conference. *Pediatr Neurol* 2013;49:243–54.
- 9 Curatolo P, Moavero R. mTOR Inhibitors in tuberous sclerosis complex. *Curr Neuropharmacol* 2012;10:404–15.
- 10 Curatolo P, Bjørnsvold M, Dill PE, *et al.* The role of mtor inhibitors in the treatment of patients with tuberous sclerosis complex: Evidence-based and expert opinions. *Drugs* 2016;76:551–65.
- 11 Brakemeier S, Bachmann F, Budde K. Treatment of renal angiomyolipoma in tuberous sclerosis complex (TSC) patients. *Pediatr Nephrol* 2017;32:1137–44.
- 12 Krueger DA, Northrup H. International tuberous sclerosis complex consensus group. Tuberous sclerosis complex surveillance and management: Recommendations of the 2012 International tuberous sclerosis complex consensus conference. *Pediatr Neurol* 2013;49:255–65.
- 13 Robles NR, Peces R, Gómez-Ferrer Á, *et al.* Everolimus safety and efficacy for renal angiomyolipomas associated with tuberous sclerosis complex: a Spanish expanded access trial. *Orphanet J Rare Dis* 2016;11:128.
- 14 Ventura-Aguilar P, Campistol JM, Diekmann F. Safety of mTOR inhibitors in adult solid organ transplantation. *Expert Opin Drug Saf* 2016;15:303–19.
- 15 Kingswood JC, Jozwiak S, Belousova ED, *et al.* The effect of everolimus on renal angiomyolipoma in patients with tuberous sclerosis complex being treated for subependymal giant cell astrocytoma: subgroup results from the randomized, placebo-controlled, Phase 3 trial EXIST-1. *Nephrol Dial Transplant* 2014;29:1203–10.
- 16 Bissler JJ, Kingswood JC, Radzikowska E, *et al.* Everolimus for angiomyolipoma associated with tuberous sclerosis complex or sporadic lymphangiomyomatosis (EXIST-2): a multicentre, randomised, double-blind, placebo-controlled trial. *Lancet* 2013;381:817–24.
- 17 Hatano T, Chikaraishi K, Inaba H, *et al.* Outcomes of everolimus treatment for renal angiomyolipoma associated with tuberous sclerosis complex: A single institution experience in Japan. *Int J Urol* 2016;23:833–8.
- 18 Bissler JJ, Franz DN, Frost MD, *et al.* The effect of everolimus on renal angiomyolipoma in pediatric patients with tuberous sclerosis being treated for subependymal giant cell astrocytoma. *Pediatr Nephrol* 2018;33:101–9.
- 19 Bissler JJ, Kingswood JC, Radzikowska E, *et al.* Everolimus long-term use in patients with tuberous sclerosis complex: Four-year update of the EXIST-2 study. *PLoS One* 2017;12:e0180939.
- 20 Budde K, Zonnenberg BA, Frost M, *et al.* Pharmacokinetics and pharmacodynamics of everolimus in patients with renal angiomyolipoma and tuberous sclerosis complex or lymphangiomyomatosis. *Br J Clin Pharmacol* 2016;81:958–70.
- 21 Tsai JD, Wei CC, Yang SH, *et al.* Effects of everolimus on tuberous sclerosis complex-associated renal angiomyolipoma: A preliminary report. *Nephrology* 2017;22:1017–22.
- 22 Franz DN, Belousova E, Sparagana S, *et al.* Long-term use of everolimus in patients with tuberous sclerosis complex: Final results from the EXIST-1 study. *PLoS One* 2016;11:e0158476.