


# Remitting seronegative symmetrical synovitis with pitting edema: a review

Mounika Lakhmalla <sup>1</sup>, Dushyant Singh Dahiya,<sup>2</sup> Asim Kichloo <sup>3,4</sup>,  
Tehreem Fatima,<sup>5</sup> Ehizogie Edigin,<sup>6</sup> Farah Wani<sup>7</sup>

<sup>1</sup>Department of Internal Medicine, Johns Hopkins, Baltimore, Maryland, United States

<sup>2</sup>Internal Medicine, Central Michigan University, Saginaw, Michigan, USA

<sup>3</sup>Department of Internal Medicine, Central Michigan University, Mount Pleasant, Michigan, USA

<sup>4</sup>Department of Internal Medicine, Samaritan Medical Center, Watertown, New York, United States

<sup>5</sup>Department of Medicine, California Institute of Behavioral Neurosciences and Psychology, Fairfield, California, USA

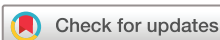<sup>6</sup>Department of Medicine, John H Stroger Hospital of Cook County, Chicago, Illinois, USA

<sup>7</sup>Department of Family Medicine, Samaritan Medical Center, Watertown, New York, USA

## Correspondence to

Dr Asim Kichloo, Samaritan Medical Center, Watertown, New York 13601, USA; kichlooasim@gmail.com

Accepted 13 October 2020



© American Federation for Medical Research 2020. No commercial re-use. See rights and permissions. Published by BMJ.

**To cite:** Lakhmalla M, Dahiya DS, Kichloo A, et al. *J Investig Med* Epub ahead of print: [please include Day Month Year]. doi:10.1136/jim-2020-001613

## ABSTRACT

Remitting seronegative symmetrical synovitis with pitting edema (RS3PE) is a rare benign rheumatological condition characterized by sudden-onset symmetrical distal extremity edema. It can present as an isolated disease process or could be associated with other conditions. Rheumatoid factor and anticitrullinated protein antibodies are negative by definition. In current literature, there is paucity of data about the disease process. We performed a literature search using the PubMed database to identify 38 articles that met our inclusion and exclusion criteria. Our literature review focuses on the clinical picture and its diverse associations. Role of various acute phase reactants has also been outlined. There is a generalized consensus among clinicians on using moderate dose steroids for treatment. Other management options for refractory cases have also discussed. Value of several imaging modalities in diagnostic evaluation of this disease entity is touched on. Since RS3PE can be associated with other diseases, specifically cancer, timely diagnosis of this condition is necessary.

## INTRODUCTION

Remitting seronegative symmetrical synovitis with pitting edema (RS3PE), first portrayed by McCarty in 1985, is a rare inflammatory syndrome characterized by sudden-onset swelling and pitting edema involving distal extremities. The current prevalence RS3PE is 0.09% and has more predilection towards elderly male population.<sup>1</sup> It is also known by other names such as ‘puffy edematous hand syndrome’ or ‘distal extremity swelling with pitting edema’.<sup>2</sup> There exists some degree of heterogeneity of RS3PE in terms of clinical presentations, diagnostic markers and management. Physical exam and MRI findings are commonly used to support the diagnosis in the current clinical setting and potential of other imaging studies have been discussed. Although isolated cases of RS3PE have been reported, it is most of the times associated with an inciting event/condition.

There are currently no diagnostic tests for RS3PE. However, diagnostic criteria proposed by Olivé in 1997 have been used by physicians for many years.<sup>3</sup> This includes the following features:

- I. Patients over 50 years of age.
- II. Painful edema of both hands.
- III. Acute onset of polyarthritis.
- IV. Rheumatoid factor (RF) negative and radiological evidence showing absence of articular destruction or alteration.

Due to a paucity of knowledge about the disease condition, many cases tend to be undiagnosed and there is a lag in management leading to severe disability and distress for the patients as shown by Okumura *et al.*<sup>4</sup> Hence, more awareness is needed among physicians regarding this disease entity. There are several case reports and case series written. But no updated review article exists on the disease process which points to a need for a detailed review of the pathology. Our aim is to present all the available literature about RS3PE in a review article for easy access. This article focuses more on literature from the past 10 years. We have done a comparative analysis of all the diseases it presents with.

## METHODS

Literature search was performed through PubMed using the keyword RS3PE. Studies were selected after applying the following inclusion and exclusion criteria.

### Inclusion criteria

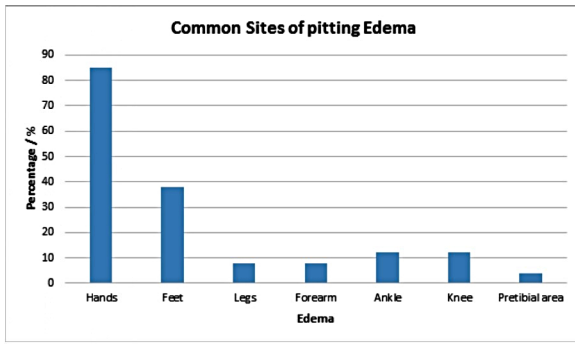
- ▶ Human subjects;
- ▶ Paper published in the English language;
- ▶ All study types were included;
- ▶ Only studies done over the past 10 years were included.

### Exclusion criteria

- ▶ Animal studies;
- ▶ Non-English literature;
- ▶ Studies >10 years old.

## Results

After applying the keyword RS3PE, a total of 49 articles were obtained. Out of these articles, 10 were removed as the literature was incomplete. We analyzed 27 case reports, 1 meta-analysis, 2 review articles, 2 letters to the Editor, 6 cohort and multicenter studies and 1 comparative study. The total number of participants in our study with respect to the case reports and series were 33.



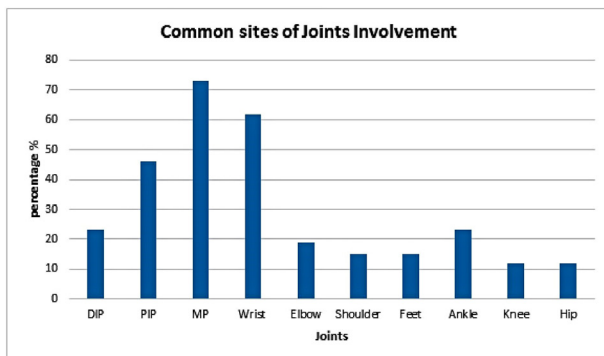
**Figure 1** Typical and atypical sites of pitting edema in remitting seronegative symmetrical synovitis with pitting edema (RS3PE).

**DISCUSSION**

RS3PE is a rare inflammatory condition characterized by distal symmetric synovitis, pitting edema which is sudden in onset. This condition typically affects elderly men.<sup>1</sup> Pitting edema most commonly involves the dorsum of hands and feet. However, bilateral edema at other sites such as ankle, knee, arms and legs has also been reported (figure 1). Symmetrical polyarthralgia generally involves the metacarpophalangeal and wrist joints yet pain at several other joints like distal interphalangeal and proximal interphalangeal has been documented (figure 2). Furthermore, skin manifestations like urticarial rash have also been observed in some patients.<sup>5</sup>

**RS3PE and laboratory abnormalities**

Like other inflammatory disease pathology, patients with RS3PE can show significant elevations in acute phase reactants like erythrocyte sedimentation rate (ESR), C reactive protein (CRP), matrix metalloproteinase-3 (MMP-3) and vascular endothelial growth factor (VEGF). In our study, ESR was elevated in 88% of the cases while CRP was raised in 100% of the cases. These serological markers play a supportive role in diagnosis, and help in predicting the prognosis of the syndrome. Tani *et al* reported a significantly higher initial CRP level in patients with poor disease control.<sup>6</sup> Serum MMP-3 level (median 437.3 ng/mL) in the patients with paraneoplastic RS3PE was significantly higher than that in patients without neoplasia (median 114.7 ng/mL)



**Figure 2** Sites of joint involvement in remitting seronegative symmetrical synovitis with pitting edema (RS3PE). DIP, distal interphalangeal; MP, metacarpophalangeal; PIP, proximal interphalangeal.

( $p < 0.05$ ).<sup>7</sup> Hence, it is believed that a high serum MMP-3 is highly characteristic of a paraneoplastic syndrome. VEGF, which was measured by seven case reports in our dataset, was elevated in a 100% of the patients. Arima *et al* reported VEGF to be specifically associated with RE3PE, relative to other connective tissue diseases.<sup>8</sup> However, a study in 2016 (n=80) showed that VEGF should not be associated with any specific rheumatological disorder, rather it is a marker of inflammatory rheumatological disease.<sup>9</sup> Nevertheless, it is routinely measured in clinical practice as a marker for an inflammatory pathology. In our study, anemia, most commonly anemia of chronic disease, was reported in half of the cases.

**RS3PE and radiological imaging**

In a clinical setting, both inpatient and outpatient, the most common initial imaging modality used for RS3PE is X-ray due to its easy access and wide availability. The X-ray findings are usually non-specific for RS3PE, but may help rule out other pathologies with joint involvement. There are no joint erosions with RS3PE on X-ray. MRI may prove to be helpful in establishing a diagnosis but its use has been limited due to cost and availability. The imaging modality of choice for RS2PE is a color Doppler ultrasound and is considered superior to other imaging modalities due to its ability to detect hypervascularity in tendons and joints, thus facilitating the differentiation of synovial proliferation or effusion. It is also a reliable, easily accessible and cost-effective modality of radiological evaluation.<sup>10</sup> The imaging modalities are summarized in table 1.

**Standard treatment and case-specific treatment strategies for RS3PE**

The standard treatment regimens for RS3PE could typically include agents such as non-steroidal anti-inflammatory drugs, salicylates, hydroxychloroquine, gold salts and corticoids.<sup>11</sup> Current literature and the generalized consensus among physicians extensively supports the use of oral glucocorticoids as the initial and most effective treatment modality. However, depending on the clinical presentation, other therapeutic options may provide symptomatic relief and help induce remission.<sup>12</sup> From our analysis, all isolated cases responded positively to steroids. Similar results were shown in a study by Karmacharya *et al*, where most patients responded well to medium-dose glucocorticoids (16.12 ± 9.5 mg/day).<sup>13</sup> The cases of RS3PE associated with malignancies can be treated either with higher dose of glucocorticoids or curative treatment of the underlying malignancy might be needed to provide symptomatic relief. A meta-analysis with 331 patients has shown that patients with RS3PE and concurrent malignancy required significantly higher doses of prednisone (18.12 vs 15.76 mg, p value of 0.304).<sup>13</sup> During our analysis, we found that two patients with lung cancer with RS3PE could not achieve complete remission when treated with steroids alone. However, significant improvement was seen when one of the patients was started on chemotherapy with pembrolizumab.<sup>14</sup> The other patient responded only partially to steroids but complete remission was achieved 4 days after surgical treatment of cancer.<sup>15</sup> We also report a similar finding in two patients with prostate adenocarcinoma with RS3PE. The first patient did respond

**Table 1** Imaging modalities in RS3PE

Imaging modality	Characteristics that help to establish a diagnosis of RS3PE	Comments
X-ray	Erosions are classically absent.	Most commonly used. Easily available. Cost-effective.
Ultrasonography	Tenosynovitis.*	Easily available and cost-effective.
Contrast-enhanced color Doppler ultrasound	Hypervascularity in tendons and joints. Useful for inflammatory edema, synovitis and effusion.*	Reliable, easily accessible, cost-effective.
MRI	Best method for detection of small amounts of effusion.	Availability and costs may limit its use.

\*Extensor>flexor.

RS3PE, remitting seronegative symmetrical synovitis with pitting edema.

to steroids but gradual taper of the steroids dosing to below 5 mg/day caused immediate relapse of the symptoms and therefore, the dose was tapered off after 18 months of therapy.<sup>16</sup> The second patient had only a partial response to glucocorticoids and complete resolution of symptoms occurred after initiation of anti-androgenic therapy.<sup>17</sup> On the contrary, we observed complete remission of RS3PE with 2 weeks of glucocorticoid treatment in a case of myelodysplasia.<sup>18</sup>

RS3PE triggered by pharmacotherapy responds well to withdrawal of the drug or by addition of corticosteroid. We observed two cases of dipeptidyl peptidase-4 inhibitors-induced RS3PE, one of which subsequently improved on stopping the therapy which the other required short-term corticosteroid therapy.<sup>11</sup> The newer agents such as immune checkpoint inhibitors like nivolumab have also been

reported to trigger RS3PE, which was seen in two cases.<sup>19 20</sup> Corticosteroids were administered for one of the patients but there was a sudden relapse of symptoms when the dose was tapered off to below 10 mg/day. Overall, significant improvement was seen when the drug was discontinued as the patients were treated with corticosteroids.

### RS3PE presenting with other conditions

Most literature reports association of RS3PE with malignancies and other rheumatological diseases. However, we observed associations of RSPE with non-malignant and non-rheumatological condition disease entities such as diabetes mellitus type 2, pleural and pericardial effusions and autoimmune conditions like systemic lupus erythematosus and myasthenia gravis.<sup>21–25</sup> Infectious disease processes have

**Table 2** Cancer and cancer therapy associated with RS3PE

Association	Timeline for the occurrence of RS3PE	Treatment	Prognosis	Comment
1. Lung cancer	Before	Pembrolizumab	Good	In this case, RS3PE developed as paraneoplastic diseases.
2. Pembrolizumab therapy Treatment: low-dose prednisolone	After initiation of treatment	Pembrolizumab	Good	Baseline use of corticosteroid equivalent to 10 mg of prednisone shown to be associated with a decreased overall response rate, progression-free survival and overall survival after PD-1/PD-L1 treatment. Use of steroids may be suitable for paraneoplastic RS3PE syndrome if needed; however, the risk-benefit balance of steroids should be considered carefully during ICI therapy.
3. Nivolumab therapy: a patient-specific report	After initiation of therapy	Continued nivolumab and managed RS3PE with corticosteroids	Good	Side effect of immune checkpoint inhibitor use is the higher incidence of immune-mediated side effects that can prompt discontinuation of therapy.
4. Nivolumab therapy: a patient-specific report	After initiation of therapy	Nivolumab discontinued Corticosteroids initiated	Good	In some cases, the discontinuation of immune checkpoint inhibitors may be needed for disease regression.
5. Adenocarcinoma of the prostate	After 3 years of prostate adenocarcinoma diagnosis	Prednisolone 15 mg/day was started resulting in rapid resolution of the symptoms	Good	Presence of RS3PE in relation with PMR and prostate cancer.
6. Phyllodes tumor of breast	Unknown	Unknown Corticosteroids may help	Unknown	A quarter of the cases recur after definitive treatment. This is an unusual association of RS3PE with recurrent phyllodes tumor of the breast.
7. Prostate adenocarcinoma	Before the diagnosis is established	Diclofenac, oral prednisolone, anti-androgen therapy	Good	In a clinical setting of RS3PE syndrome, clinicians should consider malignancies in the absence of other associated rheumatic diseases, in the presence of systemic signs and symptoms and if the response to corticosteroids is poor.

ICI, immune checkpoint inhibitor; PD-1, programmed cell death 1; PD-L1, programmed cell death ligand 1; PMR, polymyalgia rheumatica; RS3PE, remitting seronegative symmetrical synovitis with pitting edema.

**Table 3** Miscellaneous association of RS3PE

Case	Treatment	Recommendation	
1	RS3PE during course of toxic shock syndrome (TSS)	Steroids	An increase in serum VEGF due to TSS might trigger RS3PE syndrome.
2	Bilateral pleural and pericardial effusions during the course of the illness leading to respiratory failure and atrial fibrillation	Intravenous methylprednisolone 1000 mg/day for 3 days	Elevated VEGF and IL-6 may be associated with the underlying cause of pleural and pericardial effusions in this case.
3	RS3PE associated with iliopsoas bursitis	Oral corticosteroids	Iliopsoas bursitis in a patient with RS3PE syndrome may resemble an iliopsoas abscess on MRI.
4	RS3PE with additional dermatological manifestations	Prednisone	An increased awareness of RS3PE syndrome among dermatologists may be warranted.
5	RS3PE after dipeptidyl peptidase-4 (DPP-4) inhibitor use	Discontinuation of the agent Corticosteroids	Awareness of the association of RS3PE as an adverse effect of DPP-4 inhibitors is warranted.
6	RS3PE with rifampicin use	Discontinuation of rifampicin	A possible direct etiological link between rifampicin and RS3PE may exist.

IL, interleukin; RS3PE, remitting seronegative symmetrical synovitis with pitting edema; VEGF, vascular endothelial growth factor.

also been found to precipitate RS3PE.<sup>26</sup> Associations with inflammatory conditions such as iliopsoas bursitis have also been described.<sup>27</sup>

**RS3PE associated with cancers**

Based on the current literature, RS3PE may be a paraneoplastic presentation of an underlying malignancy. Some studies report a presentation of RS3PE before a cancer diagnosis was established but others note the specific presentation during the course of the malignancy. Nevertheless, a timely diagnosis and treatment of the condition address the morbidity associated with the disease and it may guide the clinician for a workup for an underlying disease pathology. In our analysis, we found associations of RS3PE with certain malignancies such as lung cancer, adenocarcinoma of the prostate, myelodysplastic syndrome, adenosquamous lung carcinoma.<sup>14-18</sup> A thorough clinical investigation, a strong clinical suspicion and awareness associations of the musculoskeletal syndromes associated with tumor entities is of utmost importance in diagnosing paraneoplastic rheumatological diseases such as RS3PE.<sup>28</sup> Hence, clinicians should be actively aware of the association of malignancies and the selective influence of tumors on the musculoskeletal tissue through alteration of the periosteum, synovial membrane, subcutaneous connective tissue, fascia, muscles and bones.<sup>7</sup> The cancers associated with RS3PE are summarized in table 2.

**RS3PE associated with rheumatological conditions**

RS3PE has clinical features which overlap with other rheumatological conditions such as rheumatoid arthritis (RA) and polymyalgia rheumatica (PMR). Initially, some clinicians believed RS3PE to be a subset of RA, while others thought of it as a variant of PMR.<sup>1</sup> However, Horai *et al* concluded that RS3PE is a distinct entity rather than a subset of other rheumatological conditions as it always presents with pitting edema, negative RF, the absence of bony erosion, an absence of the human leukocyte antigen-DRB1 genotype (commonly seen in RA) and has an excellent therapeutic response to small doses of glucocorticoids.<sup>25</sup> RS3PE has not been proven to be a variant of PMR but does share some similarities such as presentation in an elderly population, abrupt onset, symmetrical manifestations and a good

responses to low-dose glucocorticoid therapy.<sup>29</sup> RS3PE occurrence with gout and psoriatic arthritis has also been reported.<sup>30 31</sup>

**RS3PE and miscellaneous associations**

In our analysis, we observed RS3PE to have associations with other conditions such as toxic shock syndrome, intracranial hemorrhages and initiation of drugs such as rifampicin.<sup>3 11 27 32 33</sup> Infections such as tuberculosis, parvovirus B19, *Streptobacillus moniliformis*, *Escherichia coli*, *Campylobacter jejuni* and *Mycoplasma pneumoniae* have also been found to have associations with RS3PE.<sup>3 26</sup> Table 3 sums up the miscellaneous associations of RS3PE.

**CONCLUSION**

RS3PE is a rare inflammatory condition characterized by distal symmetric synovitis, pitting edema of sudden in onset commonly seen in elderly males. It most commonly involves the wrist and metacarpophalangeal joints (MCP) but other joint involvement such as the hip and knee can also be seen. RS3PE is also characterized by pitting edema most commonly seen on the dorsum of the hands. Although RS3PE may share a clinical picture with other rheumatological conditions such as RA and PMR, it is believed to be a distinct clinical entity. Markers of inflammation are usually found to be elevated in a majority of the patients, with higher initial CRP levels pointing to poor disease control. The treatment options for RS3PE which may provide symptomatic relief and may induce regression of the disease include initiation of corticosteroids or the treatment of the underlying pathology. Due to the paucity of literature on the disease pathology, there is often delay in diagnosis and the initiation of treatment leading to substandard care for the patients.

**Contributors** All authors have contributed to the manuscript and agree with the final version of the manuscript. ML, DSD and AK are credited with substantial contribution to the design of the work, literature review of all the sections discussed, the revision of critically important intellectual content, final approval of the published version and agreement of accountability for all aspects of the work. TF is credited with significant design of the figures and graphs, literature review of all sections, revision of important intellectual content for the discussion, and agreement of



accountability for all parts of the work. EE and FW are credited with literature review, initial content write up and agreement of accountability for all aspects of the work.

**Funding** The authors have not declared a specific grant for this research from any funding agency in the public, commercial or not-for-profit sectors.

**Competing interests** None declared.

**Patient consent for publication** Not required.

**Ethics approval** Our institution does not require ethical approval for reviews.

**Provenance and peer review** Not commissioned; externally peer reviewed.

#### ORCID iDs

Mounika Lakhmalla <http://orcid.org/0000-0001-9602-5525>

Asim Kichloo <http://orcid.org/0000-0003-4788-8572>

#### REFERENCES

- Varshney AN, Singh NK. Syndrome of remitting seronegative symmetrical synovitis with pitting edema: a case series. *J Postgrad Med* 2015;61:38–41.
- McCarty DJ, O'Duffy JD, Pearson L, et al. Remitting seronegative symmetrical synovitis with pitting edema. RS3PE syndrome. *JAMA* 1985;254:2763–7.
- Kyotani M, Kenzaka T, Nishio R, et al. RS3PE syndrome developing during the course of probable toxic shock syndrome: a case report. *BMC Infect Dis* 2018;18:174.
- Okumura T, Tanno S, Ohhira M, et al. The rate of polymyalgia rheumatica (PMR) and remitting seronegative symmetrical synovitis with pitting edema (RS3PE) syndrome in a clinic where primary care physicians are working in Japan. *Rheumatol Int* 2012;32:1695–9.
- Nygaard U, Vestergaard C, Koppelhus U. Remitting seronegative symmetrical synovitis with pitting oedema (RS3PE) of hands and feet in an 83-year-old man. *Acta Derm Venereol* 2013;93:491–2.
- Tani K, Kawaminami S, Okura Y, et al. Predictive factors associated with the therapeutic response in patients with polymyalgia rheumatica and remitting seronegative symmetrical synovitis with pitting edema syndrome. *J Med Invest* 2019;66:112–8.
- Origuchi T, Arima K, Kawashiri S-Y, et al. High serum matrix metalloproteinase 3 is characteristic of patients with paraneoplastic remitting seronegative symmetrical synovitis with pitting edema syndrome. *Mod Rheumatol* 2012;22:584–8.
- Arima K, Origuchi T, Tamai M, et al. RS3PE syndrome presenting as vascular endothelial growth factor associated disorder. *Ann Rheum Dis* 2005;64:1653–5.
- Smets P, Devauchelle-Pensec V, Rouzairi P-O, et al. Vascular endothelial growth factor levels and rheumatic diseases of the elderly. *Arthritis Res Ther* 2016;18:283.
- Klauser A, Fauscher F, Halpern EJ, et al. Remitting seronegative symmetrical synovitis with pitting edema of the hands: ultrasound, color Doppler ultrasound, and magnetic resonance imaging findings. *Arthritis Rheum* 2005;53:226–33.
- Yamauchi K, Sato Y, Yamashita K, et al. RS3PE in association with dipeptidyl peptidase-4 inhibitor: report of two cases. *Diabetes Care* 2012;35:e7.
- Eguia HA, Parodi Garcia JF, Ramas Diez C, et al. Remitting seronegative symmetrical synovitis with pitting oedema (RS3PE) case presentation and comparison with other polyarthritides affecting older people. *Age Ageing* 2017;46:333–4.
- Karmacharya P, Donato AA, Aryal MR, et al. RS3PE revisited: a systematic review and meta-analysis of 331 cases. *Clin Exp Rheumatol* 2016;34:404–15.
- Aoshima Y, Karayama M, Sagisaka S, et al. Synchronous occurrence of Bazex syndrome and remitting seronegative symmetrical synovitis with pitting edema syndrome in a patient with lung cancer. *Intern Med* 2019;58:3267–71.
- Ferrao C, Faria RM, Farrajota P, et al. Lucky to meet RS3PE. *BMJ Case Rep* 2013;2013:bcr2013010363.
- Emamifar A, Hess S, Gildberg-Mortensen R, et al. Association of remitting seronegative symmetrical synovitis with pitting edema, polymyalgia rheumatica, and adenocarcinoma of the prostate. *Am J Case Rep* 2016;17:60–4.
- Marto G, Klitna Z, Biléu MC, et al. Remitting seronegative symmetrical synovitis with pitting oedema syndrome, associated with prostate adenocarcinoma: a case report. *Acta Reumatol Port* 2010;35:358–60.
- Matsunaga T, Izumi Y, Iwanaga N, et al. Myelodysplastic syndrome precedes the onset of remitting seronegative symmetrical synovitis with pitting edema (RS3PE) syndrome. *Tohoku J Exp Med* 2015;235:47–52.
- Ngo L, Miller E, Valen P, et al. Nivolumab induced remitting seronegative symmetrical synovitis with pitting edema in a patient with melanoma: a case report. *J Med Case Rep* 2018;12:48.
- Gauci M-L, Baroudjian B, Laly P, et al. Remitting seronegative symmetrical synovitis with pitting edema (RS3PE) syndrome induced by nivolumab. *Semin Arthritis Rheum* 2017;47:281–7.
- Oyama K, Taniguchi J-I, Goto R, et al. Remitting seronegative symmetrical synovitis with pitting edema syndrome in individuals with type 2 diabetes mellitus or impaired glucose tolerance. *Diabetes Res Clin Pract* 2015;110:e5–8.
- Sakoda H, Ito S, Kanda H, et al. Association between type 1 diabetes mellitus and remitting seronegative symmetrical synovitis with pitting edema: a case report. *Diabetes Res Clin Pract* 2011;91:e43–4.
- Yanamoto S, Fukae J, Fukiyama Y, et al. Idiopathic remitting seronegative symmetrical synovitis with pitting edema syndrome associated with bilateral pleural and pericardial effusions: a case report. *J Med Case Rep* 2016;10:198.
- Hegazi MO, Saleh F, Al Rashidi A, et al. Synovitis with pitting edema as the presenting manifestation of systemic lupus erythematosus. *Lupus* 2014;23:1069–72.
- Horai Y, Honda M, Nishino A, et al. Anti-citrullinated protein antibody-positive rheumatoid arthritis associated with RS3PE syndrome-like symptoms and an elevated serum vascular endothelial growth factor level in a patient with myasthenia gravis. *Intern Med* 2014;53:895–8.
- Drago F, Ciccarese G, Agnoletti AF, et al. Remitting seronegative symmetrical synovitis with pitting edema associated with parvovirus B19 infection: two new cases and review of the comorbidities. *Int J Dermatol* 2015;54:e389–93.
- Fukui S, Iwamoto N, Tsuji S, et al. RS3PE syndrome with iliopsoas bursitis distinguished from an iliopsoas abscess using a CT-guided puncture. *Intern Med* 2015;54:1653–6.
- Manger B, Schett G. Paraneoplastic syndromes in rheumatology. *Nat Rev Rheumatol* 2014;10:662–70.
- Olivé A, del Blanco J, Pons M, et al. The clinical spectrum of remitting seronegative symmetrical synovitis with pitting edema. The Catalán group for the study of RS3PE. *J Rheumatol* 1997;24:333–6.
- Hakozaki M, Fukuda H, Tajino T, et al. Remitting seronegative symmetrical synovitis with pitting edema syndrome caused by crystal-induced arthritis of the wrist: a case report. *Med Princ Pract* 2013;22:307–10.
- Kardes S, Karagulle M, Erdogan N. Remitting seronegative symmetrical synovitis with pitting oedema (RS3PE) associated with psoriatic arthritis. *Scand J Rheumatol* 2015;44:339–40.
- Yang D-H, Chang D-M, Lai J-H, et al. Remitting seronegative symmetrical synovitis with pitting edema following acute intracranial hemorrhage. *Rheumatol Int* 2011;31:101–4.
- Smyth D, Rehman R, Remund K, et al. Remitting seronegative symmetrical synovitis with pitting oedema associated with rifampicin. *Ir J Med Sci* 2011;180:585–6.