


Predictive role of ultrasound remission for progressive ultrasonography-detected structural damage in patients with rheumatoid arthritis

Feifei Liu, Wenxue Li , Jiaan Zhu, Fang Liu, Wenting Fan, Zheng Chen

► Additional supplemental material is published online only. To view, please visit the journal online (<http://dx.doi.org/10.1136/jim-2021-001885>).

Department of Ultrasound, Peking University People's Hospital, Beijing, China

Correspondence to

Professor Jiaan Zhu, Department of Ultrasound, Peking University People's Hospital, Beijing 100044, China; zhujiaan@pkuph.edu.cn

FL and WL contributed equally.

Accepted 27 July 2021

ABSTRACT

Regarding the persistence of subclinical synovitis, the concept of ultrasound remission has been proposed in addition to clinical remission. However, there have been no studies that explored the different time points of ultrasound remission to predict non-progressive structural damage. Given this, the aim of our study is to explore whether early ultrasound remission in patients with rheumatoid arthritis (RA) has predictive value for non-progressive structural damage in the subsequent 12 months. Sixty-one patients with RA were prospectively studied. Synovial hypertrophy, power Doppler (PD) signal, and bone erosions of bilateral wrists, metacarpophalangeal joints I–V, and proximal interphalangeal joints II–III were assessed by ultrasonography at baseline and at 3, 6, and 12 months. Ultrasound remission was defined as no PD signal. Clinical remission was defined as Disease Activity Score in 28 Joints <2.6. Ultrasonography-detected joint damage progression was defined as increase in bone erosion score of ≥ 1 in the subsequent 12 months. Baseline ultrasonographic factors were not significantly correlated with progressive ultrasonography-detected joint damage in patients with RA at 12 months (all $p > 0.05$). Ultrasound remission at 3 and 6 months was significantly correlated with non-progressive ultrasonography-detected structural damage at 12 months ($p = 0.006$ and $p = 0.004$), with relatively low sensitivity and high specificity. Clinical remission at 3 months was significantly correlated with non-progression of ultrasonography-detected structural damage at 12 months ($p = 0.029$), with relatively low sensitivity and moderate specificity. Ultrasound remission at 3 and 6 months has high specificity in predicting non-progressive structural damage in patients with RA at 12 months; however, the sensitivity is limited.

INTRODUCTION

Rheumatoid arthritis (RA) is a chronic inflammatory joint disease that leads to structural damage and functional limitation.¹ The primary target of RA treatment is to achieve remission or low disease activity.² There are various definitions for clinical remission in patients with RA which had been shown to be associated with less structural damage.³ However, progressive joint damage could still be detected even when

Significance of this study

What is already known about this subject?

- There are various definitions for clinical remission in patients with rheumatoid arthritis (RA) which has been proven to be correlated with less structural damage.
- Regarding the persistence of subclinical synovitis, the concept of ultrasound remission has been proposed in addition to clinical remission.
- Earlier ultrasound remission is a predictor of good therapeutic efficiency; however, the time point and the efficiency of ultrasound remission in predicting good structure outcome remain unknown.

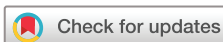What are the new findings?

- In this study, we explore the time point of ultrasound remission after treatment and its predictive value in determining good structure outcome of patients with RA during the subsequent 12 months.
- Ultrasound remission at 3 and 6 months has predictive value in determining non-progression of ultrasonography-detected structural damage in patients with RA at 12 months.
- Ultrasound remission at 3 and 6 months has high specificity and limited sensitivity in predicting non-progression of structural damage in patients with RA at 12 months.

How might these results change the focus of research or clinical practice?

- The use of ultrasound remission in predicting structural outcomes need not be overemphasized.

clinical remission has been achieved in patients with RA,⁴ which might be explained by the ongoing subclinical inflammation detected by ultrasound and MRI. There has been a large number of evidence supporting that ultrasound-detected subclinical synovitis is correlated with high-risk structural damage progression.^{5–7} As for persistent subclinical synovitis and limitations of clinical remission, the concept of ultrasound remission has been proposed.^{8,9}



© American Federation for Medical Research 2021. No commercial re-use. See rights and permissions. Published by BMJ.

To cite: Liu F, Li W, Zhu J, et al. *J Investig Med* Epub ahead of print: [please include Day Month Year]. doi:10.1136/jim-2021-001885

Table 1 Ultrasound scores of patients with rheumatoid arthritis at different time points

Ultrasonographic appearances	Baseline	3 months	6 months	12 months
Synovial hypertrophy	12.66±9.579	9.33±8.107	8.84±7.267	8.34±7.618
Power Doppler signal	4.00 (1.00–8.00)	2.00 (0.00–5.00)	2.00 (0.00–5.00)	2.00 (0.00–6.00)
Bone erosions	1.00 (0.00–5.00)	1.00 (0.00–5.00)	2.00 (0.00–5.50)	2.00 (0.00–6.00)

Musculoskeletal ultrasound (MSKUS) has proved to be a highly reproducible imaging technique for detecting joint synovitis and bone erosions sensitively. It has been proven that ultrasound assessments were superior to clinical examination in detecting subclinical joint inflammation,¹⁰ predicting the progression to RA of at-risk individuals,¹¹ disease monitoring, and defining remission.¹² The European League Against Rheumatism (EULAR) recommendations suggest that ultrasound can be used to detect subclinical synovitis and predict subsequent structural damage in patients with RA reaching clinical remission.¹³

Paulshus Sundlisæter *et al*¹⁴ found that patients with RA on ultrasound remission at 6 months had a significantly higher odds of non-progressive radiographic damage during the subsequent year. Furthermore, based on our previous animal experiments¹⁵ and clinical experience, earlier ultrasound remission has predictive value for non-progressive structural damage. However, according to our literature search, no study has explored the different time points of ultrasound remission to predict non-progression of ultrasonography-detected structural damage. Hence, the aim of this study is to explore whether early ultrasound remission has potential predictive value for non-progressive structural damage in patients with RA in the subsequent 12 months.

PATIENTS AND METHODS

Patients

Eligible patients aged >18 years fulfilling the 2010 American College of Rheumatology/EULAR RA classification criteria¹⁶ were recruited from Peking University People's Hospital. Exclusion criteria were patients who were pregnant/planning to get pregnant during the study, patients with deformity, injury, or surgery of examined joints, and those lost to follow-up. Written informed consent was obtained from all patients. Patients' general information such as age, gender, duration of disease and laboratory parameters—C reactive protein level, erythrocyte sedimentation rate (ESR), rheumatoid factor (RF), and anticyclic citrullinated peptide (ACCP)—as well as treatments were recorded.

Ultrasound assessment

Ultrasound assessment was performed using an Aixplorer ultrasound machine (Supersonic Imagine, Paris, France) with 15 MHz linear array transducer at baseline and at 3, 6, and 12 months. The ultrasound examination was conducted by a radiologist (WL) with 6 years' MSKUS experience according to the EULAR guidelines for MSKUS in rheumatology.¹⁷ Bilateral wrists, metacarpophalangeal (MCP) joints I–V, and proximal interphalangeal (PIP) joints II–III were examined to assess for synovitis by gray scale, power Doppler (PD), and bone erosion using a semiquantitative scale (0–3).¹⁸ PD settings were optimized to detect synovial blood signal to

the level just below the random noise. Longitudinal and transverse scanning were performed from the dorsal to the palmar side of each joint. To study interobserver agreement, ultrasound images at baseline of 24 patients with RA were randomly selected for scoring by another radiologist with 3 years' MSKUS experience. Investigators were blind to patients' clinical information and previous ultrasound results. Ultrasound remission was defined as no PD signal. Ultrasonography-detected structural damage progression was defined as an increase in score of ≥ 1 during the subsequent 12 months.

Definitions of clinical remission

Disease Activity Score in 28 Joints (DAS28) is a composite outcome measure of disease activity in RA. It comprises a 28-tender joint count, a 28-swollen joint count, ESR, and a Visual Analogue Scale (range 0–100). Twenty-eight joints were evaluated by experienced rheumatologists for swelling and/or tenderness, including bilateral PIPs, MCPs, wrist, elbow, shoulder, and knee joints. DAS28 score was assessed at baseline and every follow-up visit. Clinical remission was defined as DAS28 <2.6.¹⁹

Statistical analysis

Quantitative data were annotated by mean±SD and qualitative data by percentages. Interobserver agreement was calculated by overall agreement, kappa value, and intraclass correlation coefficient (ICC). To analyze possible ultrasonographic factors of ultrasound-detected structural damage, univariate and multivariate analyses were performed. For the multivariate analysis, prognostic factors were selected according to previous literature. The predictive values of ultrasound and clinical remission in detecting non-progressive damage were determined by χ^2 test. Finally, the sensitivity, specificity, positive predictive value (PPV), and negative predictive value (NPV) of remission status were also calculated. Statistical analysis was performed using SPSS V.20.0. A p value <0.05 was considered statistically significant.

RESULTS

Patient characteristics

A total of 61 patients with RA (50 women, 11 men) were consecutively included, and 47 patients with RA were excluded during the follow-up period. The mean age of the enrolled 61 patients with RA was 57.51 years, the mean disease duration was 6.50 years, and the mean DAS28 was 5.51. Forty-five patients (73.77%) showed RF-positive results and 45 patients (73.77%) showed ACCP-positive results. The basic characteristics of the whole cohort are shown in online supplemental table S1.

Table 2 Interobserver agreement

Ultrasonographic factors	Kappa	ICC	Overall agreement
Synovial hypertrophy	0.78	0.91	88.9
Power Doppler signal	0.75	0.82	87.4
Bone erosions	0.67	0.86	79.8

ICC, intraclass correlation coefficient.

Ultrasonographic findings

The ultrasound appearances consisted of synovial hypertrophy, PD signal, and bone erosion. Details of the scoring system and ultrasonographic features of the MCPs and wrists in patients with RA can be found in online supplemental figure S1–S6. Ultrasonographic scores in patients with RA at different time points are given in [table 1](#).

Interobserver agreement

The kappa value and ICC for the ultrasonographic scores showed good correlation (0.67–0.78 and 0.82–0.91, respectively). Overall agreement between the ultrasound investigators was high (79.8%–88.9%) ([table 2](#)).

Ultrasonographic factors at baseline for predicting ultrasound-detected structural damage

In patients with RA, baseline synovial hypertrophy, PD signal, and bone erosion were not significantly correlated with progressive ultrasonography-detected joint damage at 12 months ($p=0.071$, $p=0.566$, and $p=0.502$, respectively) ([table 3](#)).

Ultrasound and clinical remission to predict non-progressive ultrasonography-detected structural damage

In patients with RA, ultrasound remission at 3 and 6 months was significantly correlated with non-progression of ultrasonography-detected structural damage at 12 months ($p=0.006$ and $p=0.004$, respectively). Clinical remission at 3 months was significantly correlated with non-progression of ultrasonography-detected structural damage at 12 months ($p=0.029$), while clinical remission at 6 months was not found to be significantly correlated with non-progression of ultrasonography-detected structural damage at 12 months ($p=0.153$). The sensitivity, specificity, PPV, and NPV of ultrasound and clinical remission criteria in predicting non-progressive ultrasonography-detected structural damage are shown in [table 4](#).

DISCUSSION

We found that ultrasound remission at 3 and 6 months in patients with RA has high specificity in predicting non-progressive structural damage at 12 months; however, the sensitivity is limited. To the best of our knowledge, this is

the first study to assess the use of ultrasound remission in predicting good structure outcome at different time points in patients with RA.

Our study revealed that no ultrasonographic factors at baseline could predict progressive joint damage in patients with RA. Similarly, in our preclinical studies using animal models, we found that no ultrasonographic factors were significantly correlated with good structural outcome in collagen-induced arthritis (CIA) rats.¹⁵ These negative results are in line with the finding of Ten Cate *et al.*²⁰ They found that baseline ultrasound assessment could not bring additional predictive value for radiographical progression in patients with newly diagnosed RA at 12 months. However, previous studies have shown that the presence of synovitis at baseline increased the risk of structural deterioration in the subsequent year in patients with RA.^{10 21} Funck-Brentano *et al.*²² reported that baseline ultrasound-detected bone erosions in patients with early RA could predict radiographic erosions at 1 year.

Dougados *et al.*²¹ indicated that patients with RA with persistent synovitis after 4 months of treatment had higher tendency of developing subsequent radiological progression. They only evaluated the therapeutic parameters at the first 4 months, but did not investigate additional time points. Moreover, Paulshus Sundlisæter *et al.*¹⁴ considered that ultrasound remission at 6 months in patients with RA had a significant association with non-progressive radiographic damage at 12 months. However, whether patients with RA on ultrasound remission at different time points could predict no ultrasonography-detected joint damage remains unknown.

Akdemir *et al.*²³ found that the timing of clinical remission also affected the prognosis; patients who achieved early remission had better clinical outcomes, since those with early remission will more probably achieve drug-free clinical remission in the coming 5 years. It was shown that response at 3 months is an indicator of future remission.²⁴ Our study revealed that clinical remission at 3 months has moderate specificity in predicting non-progressive structural damage in patients with RA at 12 months; however, the sensitivity is limited. Clinical remission had been proven to be relevant with less structural damage; however, one in six patients with RA who have reached sustained clinical remission still had progressive structural damage,²⁵ which may be explained by the ongoing subclinical inflammation detected by ultrasonography and MRI.²⁶ Therefore, our study explored the predictive value of ultrasound remission for progressive ultrasonography-detected structural damage in patients with RA.

Our study demonstrated that ultrasound remission at 3 and 6 months has potential value in predicting good structural outcome in patients with RA at 12 months. However,

Table 3 Univariate and multivariate analyses of baseline ultrasonographic factors for predicting ultrasound-detected structural damage

Ultrasonographic factors at baseline	Univariate		Multivariate	
	OR (95% CI)	P value	OR (95% CI)	P value
Synovial hypertrophy	0.931 (0.875 to 0.991)	0.024	0.910 (0.822 to 1.008)	0.071
Power Doppler signal	0.937 (0.862 to 1.019)	0.128	1.040 (0.910 to 1.188)	0.566
Bone erosions	0.960 (0.852 to 1.081)	0.502		

Table 4 Performance of clinical and ultrasound remission in identifying patients with non-progressive ultrasonography-detected structural damage

	Prevalence of non-progressive ultrasonography-detected structural damage		P value	OR (95% CI)	Sensitivity	Specificity	PPV	NPV
	Patients in remission n/N (%)	Patients not in remission n/N (%)						
Ultrasound remission at 3 months	17/19 (89.47)	20/42 (47.62)	0.006	9.350 (1.916 to 45.638)	45.95	91.67	89.47	52.38
Ultrasound remission at 6 months	19/22 (86.36)	18/39 (46.15)	0.004	7.389 (1.876 to 29.100)	51.35	87.50	86.36	53.85
Clinical remission at 3 months	18/23 (78.26)	19/38 (50.00)	0.029	3.600 (1.109 to 11.684)	48.65	79.17	78.26	50.00
Clinical remission at 6 months	15/20 (75.00)	23/41 (56.10)	0.153	2.348 (0.718 to 7.681)	39.47	78.26	75.00	43.90

NPV, negative predictive value; PPV, positive predictive value.

our data suggested that ultrasound remission has limited sensitivity (45.95%–51.35%). Our previous animal experiments also showed that early ultrasound remission could predict non-progression of ultrasonography-detected structural damage in CIA rats.¹⁵ Thus, we recommend that the use of ultrasound remission in predicting structural outcomes should not be overemphasized. Recently, the additional use of ultrasound during follow-up of patients with early RA was not justified on the basis of two multicenter randomized controlled strategy trial (Aiming for Remission in rheumatoid arthritis: a randomised trial examining the benefit of ultrasound in a Clinical Tight Control regimen (ARCTIC) and Targeting Synovitis in Early Rheumatoid Arthritis (TaSER)).^{27, 28} Namely, use of ultrasound remission to predict better outcome in patients with RA was not superior to clinical remission. However, both studies only enrolled patients with early RA, and the treatment in both cohorts was already optimized. Use of ultrasound in this situation was unlikely to show additional value, while ultrasound might have potential effects in real clinical scenario. D'Agostino *et al*²⁹ claimed that robust assessment of ultrasound in RA clinical practice is still needed due to the different design schemes and outcome indexes of the current studies.

The present study has several limitations. First, patients with RA are a heterogeneous population and these individuals might be at different stages; however, this study did not differentiate early and long-standing patients with RA. Second, there are several clinical remission criteria; as DAS28 is the most widely used in clinical trials, this study only used DAS28 to measure disease activity, and other indicators were not included. Third, we only evaluated non-progression of ultrasonography-detected structural damage at 1 year. The value of ultrasound remission in predicting structural damage in 2 or more years will be fully discussed in our subsequent study. Fourth, we focused on the predictive value for progressive structural damage in patients with RA and did not investigate the relationship between ultrasound remission or absent damage progression and patients' outcome.

In conclusion, ultrasound remission at 3 and 6 months has high specificity in predicting non-progressive structural damage in patients with RA at 12 months; however, the sensitivity is limited. Therefore, the use of ultrasound remission in predicting structural outcomes need not be overemphasized.

Contributors Conception and design: FFL, WL, JZ. Data analysis and interpretation: FL, ZC, WF. Drafting and revision of the article: FFL, WL, JZ, FL, ZC, WF. Final approval of the manuscript: FFL, WL, JZ, FL, ZC, WF. Critical review of the manuscript: FFL, WL, JZ, FL, ZC, WF. JZ acts as guarantor and responsible for the whole study.

Funding This work was supported by the National Natural Science Foundation of China (no. 82071930 and 81571684).

Competing interests None declared.

Patient consent for publication Obtained.

Ethics approval This study was approved by the ethics committee of the Peking University People's Hospital (2015PHB206-01).

Provenance and peer review Not commissioned; externally peer reviewed.

Data availability statement Data are available upon reasonable request.

Supplemental material This content has been supplied by the author(s). It has not been vetted by BMJ Publishing Group Limited (BMJ) and may not have been peer-reviewed. Any opinions or recommendations discussed are solely those of the author(s) and are not endorsed by BMJ. BMJ disclaims all liability and responsibility arising from any reliance placed on the content. Where the content includes any translated material, BMJ does not warrant the accuracy and reliability of the translations (including but not limited to local regulations, clinical guidelines, terminology, drug names and drug dosages), and is not responsible for any error and/or omissions arising from translation and adaptation or otherwise.

ORCID iD

Wenxue Li <http://orcid.org/0000-0001-7237-7788>

REFERENCES

- Smolen JS, Aletaha D, McInnes IB. Rheumatoid arthritis. *Lancet* 2016;388:2023–38.
- Smolen JS, Breedveld FC, Burmester GR, *et al*. Treating rheumatoid arthritis to target: 2014 update of the recommendations of an international Task force. *Ann Rheum Dis* 2016;75:3–15.
- Klarenbeek NB, Koevoets R, van der Heijde DMFM, *et al*. Association with joint damage and physical functioning of nine composite indices and the 2011 ACR/EULAR remission criteria in rheumatoid arthritis. *Ann Rheum Dis* 2011;70:1815–21.
- Sewerin P, Vordenbaeumen S, Hoyer A, *et al*. Silent progression in patients with rheumatoid arthritis: is DAS28 remission an insufficient goal in RA? Results from the german remission-plus cohort. *BMC Musculoskelet Disord* 2017;18:163.
- Kawashiri S-ya, Suzuki T, Nakashima Y, *et al*. Ultrasonographic examination of rheumatoid arthritis patients who are free of physical synovitis: power doppler subclinical synovitis is associated with bone erosion. *Rheumatology* 2014;53:562–9.
- Vreju FA, Filippucci E, Gutierrez M, *et al*. Subclinical ultrasound synovitis in a particular joint is associated with ultrasound evidence of bone erosions in that same joint in rheumatoid patients in clinical remission. *Clin Exp Rheumatol* 2016;34:673–8.
- Ramírez J, Narváez JA, Ruiz-Esqueda V, *et al*. Clinical and sonographic biomarkers of structural damage progression in RA patients in clinical

- remission: a prospective study with 12 months follow-up. *Semin Arthritis Rheum* 2017;47:303–9.
- 8 Peluso G, Michelutti A, Bosello S, *et al*. Clinical and ultrasonographic remission determines different chances of relapse in early and long standing rheumatoid arthritis. *Ann Rheum Dis* 2011;70:172–5.
 - 9 Dejaco C, Duftner C, Wipfler-Freissmuth E, *et al*. Ultrasound-defined remission and active disease in rheumatoid arthritis: association with clinical and serologic parameters. *Semin Arthritis Rheum* 2012;41:761–7.
 - 10 Stein M, Vaillancourt J, Rampakakis E, *et al*. Prospective observational study to evaluate the use of musculoskeletal ultrasonography in rheumatoid arthritis management: the echo study. *Rheumatology* 2020;59:2746–53.
 - 11 van Beers-Tas MH, Blanken AB, Nielen MMJ, *et al*. The value of joint ultrasonography in predicting arthritis in seropositive patients with arthralgia: a prospective cohort study. *Arthritis Res Ther* 2018;20:279.
 - 12 D'Agostino M-A, Wakefield RJ, Berner-Hammer H, *et al*. Value of ultrasonography as a marker of early response to abatacept in patients with rheumatoid arthritis and an inadequate response to methotrexate: results from the appraise study. *Ann Rheum Dis* 2016;75:1763–9.
 - 13 Colebatch AN, Edwards CJ, Østergaard M, *et al*. EULAR recommendations for the use of imaging of the joints in the clinical management of rheumatoid arthritis. *Ann Rheum Dis* 2013;72:804–14.
 - 14 Paulshus Sundlisæter N, Aga A-B, Olsen IC, *et al*. Clinical and ultrasound remission after 6 months of treat-to-target therapy in early rheumatoid arthritis: associations to future good radiographic and physical outcomes. *Ann Rheum Dis* 2018;77:1421–5.
 - 15 Li W, Liu Y, Zhu J, *et al*. Ultrasound remission can predict future good structural outcome in collagen-induced arthritis rats. *Sci Rep* 2019;9:13294.
 - 16 Aletaha D, Neogi T, Silman AJ. Rheumatoid arthritis classification criteria: an American College of Rheumatology/European League against rheumatism collaborative initiative. *Ann Rheum Dis* 2010;20:10:1580–8.
 - 17 Backhaus M, Burmester GR, Gerber T, *et al*. Guidelines for musculoskeletal ultrasound in rheumatology. *Ann Rheum Dis* 2001;60:641–9.
 - 18 Szkudlarek M, Court-Payen M, Jacobsen S, *et al*. Interobserver agreement in ultrasonography of the finger and toe joints in rheumatoid arthritis. *Arthritis Rheum* 2003;48:955–62.
 - 19 Fransen J, van Riel PLCM. The disease activity score and the EULAR response criteria. *Rheum Dis Clin North Am* 2009;35:745–57.
 - 20 Ten Cate DF, Jacobs JWG, Swen WAA, *et al*. Can baseline ultrasound results help to predict failure to achieve DAS28 remission after 1 year of tight control treatment in early RA patients? *Arthritis Res Ther* 2018;20:15.
 - 21 Dougados M, Devauchelle-Pensec V, Ferlet JF, *et al*. The ability of synovitis to predict structural damage in rheumatoid arthritis: a comparative study between clinical examination and ultrasound. *Ann Rheum Dis* 2013;72:665–71.
 - 22 Funck-Brentano T, Gandjbakhch F, Etchepare F, *et al*. Prediction of radiographic damage in early arthritis by sonographic erosions and power doppler signal: a longitudinal observational study. *Arthritis Care Res* 2013;65:896–902.
 - 23 Akdemir G, Heimans L, Bergstra SA, *et al*. Clinical and radiological outcomes of 5-year drug-free remission-steered treatment in patients with early arthritis: improved study. *Ann Rheum Dis* 2018;77:111–8.
 - 24 Smolen JS, Landewé RBM, Bijlsma JWJ, *et al*. EULAR recommendations for the management of rheumatoid arthritis with synthetic and biological disease-modifying antirheumatic drugs: 2019 update. *Ann Rheum Dis* 2020;79:685–99.
 - 25 Cohen G, Gossec L, Dougados M, *et al*. Radiological damage in patients with rheumatoid arthritis on sustained remission. *Ann Rheum Dis* 2007;66:358–63.
 - 26 Haavardsholm EA, Lie E, Lillegraven S. Should modern imaging be part of remission criteria in rheumatoid arthritis? *Best Pract Res Clin Rheumatol* 2012;26:767–85.
 - 27 Haavardsholm EA, Aga A-B, Olsen IC, *et al*. Ultrasound in management of rheumatoid arthritis: arctic randomised controlled strategy trial. *BMJ* 2016;354:i4205.
 - 28 Dale J, Stirling A, Zhang R, *et al*. Targeting ultrasound remission in early rheumatoid arthritis: the results of the TaSER study, a randomised clinical trial. *Ann Rheum Dis* 2016;75:1043–50.
 - 29 D'Agostino MA, Boers M, Wakefield RJ, *et al*. Is it time to revisit the role of ultrasound in rheumatoid arthritis management? *Ann Rheum Dis* 2017;76:7–8.