

## Effect of Pioglitazone Therapy on Myocardial and Hepatic Steatosis in Insulin-Treated Patients with Type 2 Diabetes

Ivana Zib, Aris N. Jacob, Ildiko Lingvay, Karin Salinas, Jonathan M. McGavock, Philip Raskin, and Lidia S. Szczepaniak

High levels of myocardial and hepatic triglyceride are common in obesity and type 2 diabetes. Monotherapy with thiazolidinedione agents reduces hepatic steatosis by up to 50% in patients with type 2 diabetes. It is not known if treatment with a thiazolidinedione added to insulin has a similar beneficial antisteatotic effect. The aim of our study was to determine whether the addition of pioglitazone to insulin treatment in patients with type 2 diabetes has antisteatotic action in the heart and the liver. Thirty-two patients were randomized to 6 months of treatment with insulin or insulin plus pioglitazone. In addition to blood tests, we evaluated myocardial and hepatic triglyceride content, as well as subcutaneous and visceral fat mass at the L2 level, by magnetic resonance spectroscopy and imaging, respectively. Despite weight and subcutaneous fat mass gain, hemoglobin A<sub>1c</sub> was significantly reduced by both treatments. Myocardial and hepatic triglyceride contents were reduced by the treatment with pioglitazone plus insulin ( $p = .02$  and  $.03$ , respectively) but not by the treatment with insulin. Systolic and diastolic blood pressure and heart function remained unchanged in both groups. The addition of pioglitazone to insulin therapy reduced myocardial and hepatic steatosis, consistent with the reported ability of the thiazolidinedione agents to redistribute fat from nonadipose to subcutaneous adipose depots.

**Key words:** myocardial and hepatic steatosis, pioglitazone/insulin therapy, type 2 diabetes

---

From the Department of Internal Medicine, Division of Hypertension (J.M.M., L.S.S.), Division of Endocrinology, Diabetes and Metabolism (I.Z., A.N.J., I.L., K.S., P.R.), and Department of Radiology (L.S.S.), University of Texas Southwestern Medical Center at Dallas, Dallas, TX.

L.S.S. was supported by K25 HL-68736 from the National Institutes of Health (NIH), Innovative Methodologies Award #7-04-IN-27 from the American Diabetes Association, and Takeda Pharmaceuticals North America Inc. I.Z. was supported by NIH Training Grant 5T3 DK 007307-25. I.L. was supported by a Departmental Clinical Scholars Award. J.M.M. was supported by a Target Obesity Postdoctoral Fellowship, the Heart and Stroke Foundation of Canada, the Canadian Institutes for Health Research, and the Canadian Diabetes Association.

Address correspondence to: Dr. Lidia S. Szczepaniak, University of Texas Southwestern Medical Center at Dallas, 5323 Harry Hines Blvd, Dallas, TX 75390-8899; e-mail: lidia.szczepaniak@utsouthwestern.edu.

*Journal of Investigative Medicine* 2007;55:230–236.

DOI 10.2310/6650.2007.00003

Excessive lipid accumulation in nonadipose tissues takes place in settings of high plasma free fatty acids (FFAs) and/or high triglyceride (TG) levels.<sup>1,2</sup> When nonadipose cells accumulate more FFAs than is required for metabolic processes, the excess is esterified and stored as TG droplets within the cytosol, leading to tissue steatosis.<sup>3</sup> Fatty acids from this lipid compartment may be mobilized when needed through the actions of cellular lipases. However, unlike adipocytes, cells of nonadipose tissues have a limited capacity for TG storage. Intracellular TGs are not harmful per se, but metabolic by-products of excessive TG accumulation in nonadipose tissues may impair normal cellular signaling and cause cellular dysfunction, a process called lipotoxicity.<sup>4</sup> Evidence from animal models suggests that accumulation of lipid in nonadipose tissues plays an important role in the pathogenesis of obesity, type 2 diabetes, steatohepatitis, and heart failure.<sup>5,6</sup>

High serum TG levels and primary dyslipidemias are common in obesity<sup>7,8</sup> and in type 2 diabetes.<sup>9,10</sup> Previous studies suggest that high levels of hepatic TG

are also common in obese individuals and in patients with type 2 diabetes.<sup>7,11–13</sup> This population is at increased risk of lipotoxic organ dysfunction. Intracellular TG levels provide a convenient marker of tissue steatosis<sup>3</sup> and allow for quantitative evaluation of changes in tissue steatosis induced by an antisteatotic regimen. The most powerful way to correct energy imbalance and efficiently reverse the cytosolic fat accumulation is lifestyle adjustment intervention.<sup>14,15</sup> Unfortunately, the compliance with lifestyle strategies is difficult and frequently fails. The alternative is a treatment with agents known to reduce tissue TG levels. Several pharmacologic agents have been evaluated for their antisteatotic effect. The peroxisome proliferator-activated receptor  $\gamma$  (PPAR- $\gamma$ ) agonist class, the thiazolidinediones, is known to improve insulin sensitivity and to reduce plasma TG and very low-density lipoprotein levels.<sup>16,17</sup> The mechanisms of action of these agents are not entirely understood, but it is known that the thiazolidinediones promote peripheral preadipocyte differentiation into new adipocytes, which have the capacity to store TG and divert fat from nonadipose tissue to subcutaneous adipose tissue.<sup>18,19</sup> It has been documented that treatments with thiazolidinedione agents reduce hepatic steatosis by up to 50% in patients with type 2 diabetes.<sup>11</sup> The effect of the thiazolidinedione agents on myocardial TG accumulation has not been studied.

Insulin treatment is commonly required in patients with type 2 diabetes, but insulin is thought to promote ectopic TG accumulation owing to its lipogenic actions. It has been reported that 3 days of insulin infusion mediated near-normal glycemia-stimulated lipid accumulation in the liver,<sup>20</sup> but the effect of insulin therapy on myocardial and hepatic steatosis in patients with type 2 diabetes has not been studied in vivo.

It is not known if the addition of a thiazolidinedione agent to an insulin-based treatment regimen in patients with type 2 diabetes would be able to counteract the lipogenic effects of insulin and sustain an antisteatotic action. The aim of our study is to determine whether pioglitazone treatment has antisteatotic action in the heart and the liver in insulin-treated patients with type 2 diabetes.

## Research Design and Method

The Institutional Review Board at the University of Texas Southwestern Medical Center approved the protocol, and all volunteers provided written informed consent prior to participation in the study. We conducted a prospective, randomized, open-label study to compare pioglitazone plus insulin versus insulin-

only treatment on cardiac and hepatic TG contents in patients with type 2 diabetes. The study had a 2-week lead-in period, followed by randomization and a 6-month treatment period. We recruited patients from the Diabetes Clinic in Parkland Memorial Hospital at Dallas County. We included patients older than 18 years with a hemoglobin A<sub>1c</sub> (HbA<sub>1c</sub>)  $\geq$  7.5% who were willing to comply with the study interventions. We excluded patients who previously used thiazolidinedione agents; reported to have more than two alcoholic drinks a day; had congestive heart failure classed as New York Heart Association III and IV, kidney failure requiring dialysis, or liver transaminases over three times the upper limit of normal; and were unwilling to practice safe contraception. We also excluded patients with severe claustrophobia, metallic implants within the body, and a weight or a body shape that would preclude positioning in the magnetic resonance imaging (MRI) system. None of the patients studied had a history of hepatitis B and C, and none were on medications for human immunodeficiency virus (HIV).

## Randomization and Treatment Protocol

Enrolled patients were asked to stop all oral hypoglycemic agents and were initiated on or had intensification of their insulin treatment for 2 weeks prior to the evaluation. The insulin dose was titrated if needed, based on home capillary blood glucose monitoring results, targeting normoglycemia (fasting glucose level  $<$  110 mg/dL and postprandial glucose  $<$  140 mg/dL).

A stratified blocked randomization was performed 2 weeks after enrolment (strata cutoffs: body mass index 35 kg/m<sup>2</sup> and HbA<sub>1c</sub> 10%). At the end of the run-in period, patients were randomized to continue insulin or to the addition of pioglitazone to the insulin regimen. Patients randomized to pioglitazone were initiated at 15 mg once daily for 1 week followed by 30 mg once daily for the rest of the study. If side effects related to pioglitazone occurred, the dosage was reduced to 15 mg daily. Compliance was assessed by drug count and review of home capillary blood glucose monitoring.

All evaluations were performed at the end of run-in period just prior to randomization and were repeated at the end of the study.

## Magnetic Resonance System

Magnetic resonance data were acquired using a 1.5-Tesla Philips Intera Clinical System (Philips Medical Systems, Best, the Netherlands). Images were processed using a commercially available workstation (MASS,

Philips Medical Systems) to establish heart geometry and function, as well as subcutaneous and visceral fat mass. Magnetic resonance spectra were analyzed with a line-fit procedure and commercial software (NUTS-ACORNNMR, Fremont, CA). Signal decay owing to spin-spin relaxation in spectra from the heart and liver was calculated using  $T_2$ -weighted relaxation times specific for TG and water in myocardial and hepatic tissues as previously reported.<sup>21,22</sup>

### Localized Spectroscopy

Localized spectroscopy can distinguish between TG droplets localized to the cytosol of nonadipose cells (ie, an aqueous microenvironment) and TG stored in adipocytes (ie, a lipid microenvironment). During  $^1\text{H}$  magnetic resonance spectroscopy (MRS), these different microenvironments cause TG to resonate at different frequencies: 1.4 ppm for TG droplets within cytosol nonadipose cells versus 1.6 ppm for TG in adipocytes relative to resonance from tissue water at 4.8 ppm.<sup>3,7</sup> The validation and reproducibility of the method measuring TG within the liver and the heart have been published.<sup>12,19</sup>

### Myocardial Imaging, Function, and Spectroscopy

Left ventricular morphology, function, and myocardial TG content were determined as previously described.<sup>21,22</sup> Briefly, we used cardiac cine images collected during breath-hold at end-expiration to select a volume of interest of 6 cc within the interventricular septum. Spectra were acquired with respiratory gating at end-expiration and cardiac triggering at end-systole; hence, patients breathed freely during data acquisition. The following parameters were used for acquisition of myocardial resonances: interpulse delay ( $T_r$ ) defined by breathing rate ( $\approx$  4 seconds), spin echo  $T_e = 27$  milliseconds, 64 acquisitions per spectrum, and 1,024 data points over a 1,000 Hz spectral width.

Axial, cine images covering the heart from apex to base were used to quantify left ventricular volume.<sup>23–25</sup> Endocardial and epicardial left ventricular borders were traced manually at end-diastole and at end-systole using the short-axis plane, whereas the papillary muscles were excluded from the left ventricular cavity volume.

Left ventricular mass was computed as a product of end-diastolic left ventricular volume and myocardial density (1.05 g/mL).<sup>25</sup> Ejection fraction was used as an index of global left ventricular function.

### Hepatic Spectroscopy

Hepatic TG content was determined by MRS as previously described.<sup>12,21</sup> In short, sagittal, coronal,

and axial images through the right liver lobe were acquired with the patient in the prone position. In this setup, the patient's own weight suppresses respiratory motion, eliminating the need for the respiratory gating. A spectroscopic volume of interest of 27 cc was selected carefully, avoiding major blood vessels, intrahepatic bile ducts, and the lateral margin of the liver. The voxel position was also optimized to prevent contamination of the signal from intrahepatic fat by the signal from abdominal adipose fat. A relatively large voxel was used to collect good-quality data in a short time. Spectra were collected using a Q-body coil for radiofrequency transmission and signal reception, with the following parameters: interpulse delay  $T_r = 3$  seconds, spin echo  $T_e = 25$  milliseconds, 16 acquisitions per spectrum, and 1,024 data points over a 1,000 Hz spectral width.

### Abdominal Imaging

Subcutaneous and visceral abdominal fat masses were determined from high-resolution abdominal axial images at the L2 level.<sup>26</sup> During data acquisition, patients were in the prone position. Image analysis involved computer-assisted mapping of subcutaneous and intra-abdominal adipose tissue compartments. Data are reported as fat area in cubic centimeters.

### Anthropometric Measurements

Anthropometric measurements were performed in the morning, with patients in a fasting state. Height and weight were measured using a calibrated height rod and a calibrated Physician's Scale with patients wearing light clothing and no shoes.

### Laboratory Evaluations

Laboratory tests were performed after an overnight fast. Patients were instructed to withhold insulin for 24 hours prior to testing. Lipid panel and chemistry, including glucose level, were measured by Quest Diagnostics (Plano, TX). Adiponectin and leptin were measured by radioimmunoassay kits from Linco Research Inc. (St. Charles, MO); insulin was measured by a radioimmunoassay kit from the Diagnostic Product Corporation (Los Angeles, CA); and  $\text{HbA}_{1c}$  was measured by high-performance liquid chromatography (Primus Corporation, Kansas City, MO) at the University of Texas Southwestern Medical Center Diabetes Laboratory.

### Statistical Evaluations

Our primary hypothesis was that the addition of pioglitazone to an insulin-based treatment will significantly reduce the myocardial TG contents com-

pared with an insulin-only treatment. The results for myocardial and hepatic TG were non-normally distributed; therefore, we used nonparametric methods, the Wilcoxon rank sum test and Spearman correlation, for myocardial and hepatic TG data analysis. All data are reported as mean and standard deviation. For myocardial and hepatic TG levels, the median values are reported additionally. SAS statistical software version 9.1 (SAS Institute, Cary, NC) and SPSS version 14.0 (SPSS Inc, Chicago, IL) were used for data analysis.

## Results

Fifty-one patients with type 2 diabetes were enrolled. Magnetic resonance spectra of the heart and/or liver were distorted by patient-related motion in 15 participants. Additionally, the internal dimensions of our magnet could not accommodate 4 patients.

The remaining 32 participants were randomized and completed the study procedures. Two patients in the pioglitazone group developed lower extremity edema. The characteristics of the study participants are provided in Table 1. At baseline, the characteristics for both treatment groups were comparable, except for low-density lipoprotein and total cholesterol levels that were higher for the pioglitazone plus insulin group.

Patients in both treatment groups gained weight:  $7.16 \pm 5.47$  kg and  $6.07 \pm 4.99$  kg in the pioglitazone plus insulin and insulin treatment groups, respectively ( $p$

$= .67$  between groups). Subcutaneous fat mass and leptin levels also increased after both treatments ( $p = .56$  and  $p = .52$ , respectively, between groups). Visceral fat mass and adiponectin levels remained unchanged. Despite weight gain, HbA<sub>1c</sub> was significantly reduced by  $-4.00 \pm 2.86\%$  and by  $-3.46 \pm 2.07\%$  in the pioglitazone plus insulin group and in the insulin treatment group, respectively ( $p = .84$  between groups).

The average intramyocardial TG content decreased from  $0.82 \pm 0.42\%$  to  $0.62 \pm 0.48\%$  ( $p = .017$ ) after the pioglitazone plus insulin treatment and did not change after exclusive insulin treatment ( $1.08 \pm 0.68\%$  and  $1.6 \pm 2.42\%$ ,  $p = .346$ ) (Figure 1). The large standard deviation value in this group is caused by exaggerated elevation of myocardial TG levels in two patients after insulin treatment. Median intramyocardial TG content decreased after the pioglitazone plus insulin treatment from  $0.72$  to  $0.48\%$  and from  $0.89$  to  $0.67\%$  after insulin treatment. The between-group analysis revealed no difference between treatments ( $p = .491$ ). Systolic and diastolic blood pressure, heart rate, heart mass, and ejection fraction (Table 2) did not change during treatment with either therapy.

The average hepatic TG content decreased from  $9.47 \pm 10.48\%$  to  $4.54 \pm 4.65\%$  ( $p = .03$ ) after the pioglitazone plus insulin treatment and remained unchanged after exclusive insulin treatment ( $6.14 \pm 7.55\%$  to  $4.66 \pm 4.76\%$ ,  $p = .393$ ). The median hepatic TG content decreased in the pioglitazone plus insulin group from  $5.21$  to  $2.76\%$  and remained

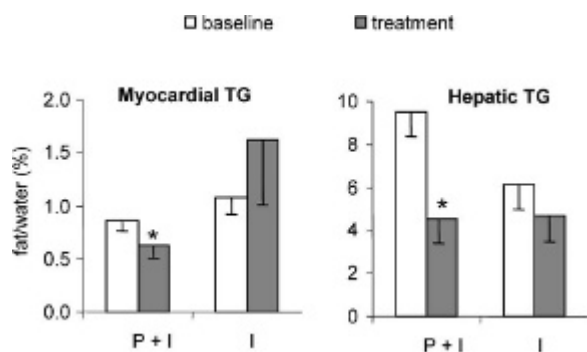
**Table 1** Study Participants' Characteristics

Variable	Insulin and Pioglitazone (n = 16)		Insulin (n = 16)	
	Baseline	Treatment	Baseline	Treatment
Male/female	7/9		8/8	
Ethnicity (AA/C/H)	7/4/5		5/7/4	
Age (yr)	$51 \pm 9$		$47 \pm 11$	
Duration of diabetes (yr)	$5.6 \pm 4.1$		$6.6 \pm 5.2$	
Body mass index (kg/m <sup>2</sup> )	$32 \pm 8$	$35 \pm 9^*$	$33 \pm 7$	$35 \pm 7^{**}$
Hemoglobin A <sub>1c</sub> (%)	$11.0 \pm 2.8$	$7.0 \pm 1.10^*$	$10.6 \pm 1.4$	$7.1 \pm 1.5^*$
Cholesterol (g/L)	$204 \pm 32$	$162 \pm 30^*$	$173 \pm 28$	$172 \pm 21$
Low-density lipoprotein (g/L)	$131 \pm 30$	$93 \pm 32^*$	$103 \pm 27$	$94 \pm 18$
High-density lipoprotein (g/L)	$45 \pm 9$	$48 \pm 10$	$45 \pm 16$	$46 \pm 14$
Triglycerides (g/L)	$136 \pm 66$	$112 \pm 58^{**}$	$143 \pm 70$	$175 \pm 101$
Leptin (μU/L)	$19 \pm 16$	$24 \pm 17^{**}$	$17 \pm 11$	$28 \pm 22^{***}$
Adiponectin (mg/L)	$28 \pm 10$	$28 \pm 14$	$29 \pm 10$	$22 \pm 11$
Aspartate transaminase (U/L)	$19 \pm 9$	$18 \pm 6$	$16 \pm 7$	$17 \pm 8$
Alanine transaminase (U/L)	$26 \pm 14$	$21 \pm 10$	$21 \pm 12$	$21 \pm 12$
Subcutaneous fat (cm <sup>2</sup> )	$275 \pm 107$	$331 \pm 136^{**}$	$225 \pm 101$	$275 \pm 130^{**}$
Visceral fat (cm <sup>2</sup> )	$147 \pm 44$	$164 \pm 40$	$137 \pm 46$	$147 \pm 54$

AA = African American; C = Caucasian; H = Hispanic; TG = triglyceride.

\* $p < .001$ ; \*\* $p < .01$ ; \*\*\* $p < .05$  compared with the same group at baseline.

Results are reported as mean  $\pm$  SD except as indicated.



**Figure 1** Myocardial and hepatic triglyceride (TG) content before and after 6-month treatment with pioglitazone plus insulin (P + I) and insulin alone (I). The results are mean and standard error. \* $p < .05$  compared with baseline within group.

unchanged in the insulin group (2.92–2.12%). The between-group analysis revealed that hepatic TG nearly reached the statistically significant difference between groups ( $p = .08$ ) (see Figure 1).

## Discussion

Our study evaluated the therapeutic intervention of pioglitazone in combination with insulin on myocardial and hepatic steatosis in patients with type 2 diabetes. Our major finding is that pioglitazone reduces myocardial and hepatic steatosis in patients with type 2 diabetes treated with insulin, despite the associated weight gain. The pioglitazone plus insulin treatment reduced myocardial TG content by 33% and hepatic TG by 52% from baseline.

Our group previously validated the hepatic and cardiac  $^1\text{H}$  MRS technique by comparing TG content in myocardial tissue extracts against standard biochemical techniques.<sup>12,21</sup> In human subjects, we demonstrated a high degree of within-subject reproducibility and sensitivity for detecting small amounts of myocardial TG even in lean individuals with normal glucose tolerance.<sup>4,22</sup> The present study extends our

work to diabetes treatment to determine if cardiac and hepatic steatosis are reduced when pioglitazone is added to insulin therapy.

Previous studies have shown that accumulation of fat in the myocardium is an unwanted consequence of obesity and might significantly contribute to cardiac dysfunction.<sup>3,27</sup> Thiazolidinedione agents are PPAR- $\gamma$  agonists that increase insulin action through several mechanisms, including stimulation of the gene expressions that increase fat oxidation and lower plasma FFA levels<sup>28</sup>; increased expression, synthesis, and release of adiponectin<sup>29</sup>; and stimulation of adipocyte differentiation, resulting in additional smaller fat cells.<sup>30</sup> Treatment with pioglitazone is known to improve insulin-mediated suppression of endogenous glucose production and to augment splanchnic and peripheral tissue glucose uptake in type 2 diabetes, which explains the hypoglycemic action of these agents.<sup>20,31</sup> These insulin-sensitizing agents are widely prescribed to patients with type 2 diabetes<sup>32</sup> and have been found effective in reducing hepatic steatosis in patients with nonalcoholic fatty liver disease.<sup>19,20,31</sup> It was previously shown that pioglitazone monotherapy reduces hepatic steatosis in patients with type 2 diabetes by up to 51%.<sup>18</sup> We extended this work to diabetes treatment to determine if cardiac and hepatic steatosis is reduced when pioglitazone is added to insulin therapy.

No data have been available to support a beneficial action of pioglitazone in the myocardium. A high rate of myocardial metabolism is needed to generate energy to sustain cardiac contractile activity. Typically, myocardial energy generation occurs through the metabolism of FFAs, glucose, and lactate. However, in individuals with impaired glucose tolerance or who have type 2 diabetes, FFAs are metabolized at a higher rate.<sup>33</sup> Previous studies suggest that thiazolidinedione agents, aside from exerting insulin-sensitizing effects on fat and skeletal muscle, also act on the myocardium as a result of reducing circulating FFA concentrations.<sup>34</sup> Additionally, it has been indicated that pioglitazone reduces oxidative stress in the myocardium.<sup>35</sup> The

**Table 2** Hemodynamic Parameters in the Two Groups

Variable	Insulin and Pioglitazone		Insulin	
	Baseline	Treatment	Baseline	Treatment
SBP (mm Hg)	132 $\pm$ 20	133 $\pm$ 17	131 $\pm$ 30	134 $\pm$ 29
DBP (mm Hg)	80 $\pm$ 8	81 $\pm$ 10	78 $\pm$ 16	79 $\pm$ 16
HR (bpm)	85 $\pm$ 16	83 $\pm$ 16	80 $\pm$ 18	80 $\pm$ 17
LV mass (g/m <sup>2</sup> )	74 $\pm$ 18	74 $\pm$ 17	78 $\pm$ 12	82 $\pm$ 10
LVEF (%)	67 $\pm$ 7	67 $\pm$ 6	63 $\pm$ 13	63 $\pm$ 15

DBP = diastolic blood pressure; HR = heart rate; LV = left ventricular; LVEF = left ventricular ejection fraction; SBP = systolic blood pressure. Results are reported as mean  $\pm$  SD.

results of our study suggest that pioglitazone, even when added to insulin, an agent believed to cause lipogenesis, carries out antisteatotic benefits in the myocardium of patients with type 2 diabetes.

It is well recognized that in patients with poorly controlled type 2 diabetes, treatment with insulin provides fast and effective improvement of hyperglycemia and leads to better general well-being.<sup>36</sup> In our study, treatment with insulin lowered fasting glucose and HbA<sub>1c</sub> despite a concomitant gain of weight and subcutaneous fat mass. The response to insulin was, however, heterogeneous. Insulin therapy alone lowered hepatic TG levels but not significantly. Insulin therapy in two patients elevated myocardial TG levels, leading to very high data variability. Overall, our data suggest that insulin therapy alone may not worsen hepatic steatosis as previously suggested. However, in some individual cases, insulin therapy may elevate myocardial steatosis.

In our study, treatment with a combination of pioglitazone and insulin or with insulin alone also lowered fasting glucose and HbA<sub>1c</sub> to the same extent, despite gain of weight and subcutaneous fat mass. We suspect that at least part of the fat gained during combination therapy may be attributed to preadipocyte differentiation and development of small adipocytes efficient in a gradual reversal of hepatic and myocardial steatosis.<sup>37</sup> In contrast, elevated subcutaneous fat mass in patients treated with insulin monotherapy occurred, perhaps owing to insulin's fat-sparing effects.<sup>21</sup>

Adiponectin, an adipocyte-secreted protein, has been reported to increase fat oxidation and improve insulin sensitivity.<sup>38</sup> Several studies demonstrated that thiazolidinedione treatment increases adiponectin levels in obese and diabetic patients, along with reducing hepatic TG and visceral fat mass.<sup>11,19,38,39</sup>

In our study, hepatic TG content was reduced, but levels of adiponectin and visceral fat mass did not change after insulin plus pioglitazone treatment. This is surprising in view of the existing body of literature, but on the other hand, the combined effect of thiazolidinedione and insulin on adiponectin levels was not studied. Perhaps the lack of changes in adiponectin levels in our study is associated with the simultaneous actions of insulin and thiazolidinedione. More studies will be required to confirm this finding.

We recognize several limitations inherent in our study. Given that this was the first study evaluating change in myocardial TG levels owing to antisteatotic therapy in patients with type 2 diabetes, we calculated sample size based on our existing results in nondiabetic individuals. We did not expect the variability of data in patients with type 2 diabetes to be so much higher than

in control individuals, and we underestimated the sample size for this study. Even though the improvements in myocardial and hepatic TG content were evident and significant after treatment with the pioglitazone plus insulin, the groups were not different based on the between-group analysis. Another limitation of this study is the concomitant therapy with statin agents in some patients. It has been suggested, but not confirmed in controlled studies, that statin therapy might have a beneficial effect on hepatic steatosis.<sup>40</sup> If this is true, the use of statins would represent a confounder for our findings, and we can draw no conclusions on the changes of the lipid profile components.

## Conclusions

We conclude that the addition of pioglitazone to an insulin-based treatment regimen lowers myocardial and hepatic TG content. This research extends our previous studies to the treatment of type 2 diabetes and leads us to the conclusion that the combination of pioglitazone and insulin therapy, in addition to lowering blood glucose levels, adds benefits in terms of an antisteatotic action in the heart and in the liver. This observation is consistent with the reported ability of thiazolidinediones to redistribute fat from nonadipose tissues to subcutaneous adipose depots. Larger clinical trials of longer duration are needed to confirm these findings.

## Acknowledgments

We would like to thank the staff at Roger's MRI Center and Naomi Salas for assistance with the MRI/MRS sessions and Beverley Adams-Huet, MS, and David Leonard, PhD, for their statistical expertise.

## References

- Schaffer JE. When tissue overeat. *Curr Opin Lipidol* 2003; 14:281–7.
- Unger RH. Longevity, lipotoxicity and leptin: the adipocyte defense against feasting and famine. *Biochimie* 2005;87:57–64.
- McGavock JM, Victor RG, Unger RH, Szczepaniak LS. Adiposity of the heart, revisited. *Ann Intern Med* 2006;144: 517–24.
- Unger RH. Minireview: weapons of lean body mass destruction: the role of ectopic lipids in the metabolic syndrome. *Endocrinology* 2003;144:5159–65.
- Zhou YT, Grayburn P, Karim A, et al. Lipotoxic heart disease in obese rats: implications for human obesity. *Proc Natl Acad Sci U S A* 2000;97:1784–9.
- Sharma S, Adroque JV, Golfman L, et al. Intramyocardial lipid accumulation in the failing human heart resembles the lipotoxic rat heart. *FASEB J* 2004;18:1692–700.

7. Szczepaniak LS, Babcock EE, Schick F, et al. Measurement of intracellular triglyceride stores by H spectroscopy: validation in vivo. *Am J Physiol* 1999;276(5 Pt 1):E977–89.
8. Campbell PJ, Carlson MG, Nurjhan N. Fat metabolism in human obesity. *Am J Physiol* 1994;266:E600–5.
9. Halgren B, Stenhagen S, Svaborg A, Svennenholm L. Gas chromatographic analysis of the fatty acid composition of the plasma lipids in normal and diabetic subjects. *J Clin Invest* 1960;39:1424–34.
10. Lakso M, Voutilainen E, Sarlundt H. Serum lipids and lipoproteins in middle-aged non-insulin-dependent diabetics. *Atherosclerosis* 1985;56:271–81.
11. Bajaj M, Suraamornkul S, Piper P, et al. Decreased plasma adiponectin concentrations are closely related to hepatic fat content and hepatic insulin resistance in pioglitazone-treated type 2 diabetic patients. *J Clin Endocrinol Metab* 2004;89:200–6.
12. Szczepaniak LS, Nurenberg P, Leonard D, et al. Magnetic resonance spectroscopy to measure hepatic triglyceride content: prevalence of hepatic steatosis in the general population. *Am J Physiol Endocrinol Metab* 2005;288:E462–8.
13. Browning JD, Szczepaniak LS, Dobbins R, et al. Prevalence of hepatic steatosis in an urban population in the United States: impact of ethnicity. *Hepatology* 2004;40:1387–95.
14. Raz I, Eldor R, Cernea S, Shafir E. Diabetes: insulin resistance and derangements in lipid metabolism. Cure through intervention in fat transport and storage. *Diabetes Metab Res Rev* 2005;21:3–14.
15. Tuomilehto J, Lindstrom J, Eriksson JG, et al. Prevention of type 2 diabetes mellitus by changes in lifestyle among subjects with impaired glucose tolerance. *N Engl J Med* 2001;344:1343–50.
16. Freed MI, Ratner R, Marcovina SM. Effects of rosiglitazone alone and in combination with atorvastatin on the metabolic abnormalities in type 2 diabetes mellitus. *Am J Cardiol* 2002;90:947–52.
17. Buchanan TA, Xiang AH, Peters RK, et al. Preservation of pancreatic  $\beta$ -cell function and prevention of type 2 diabetes by pharmacological treatment of insulin resistance in high-risk Hispanic women. *Diabetes* 2002;51:2796–803.
18. Yki-Jarvinen H. Thiazolidinediones. *N Engl J Med* 2004;351:1106–18.
19. Belfort R, Harrison SA, Brown K, et al. A placebo-controlled trial of pioglitazone in subjects with nonalcoholic steatohepatitis. *N Engl J Med* 2006;355:2297–307.
20. Anderwald C, Bernroider E, Krssak M, et al. Effects of insulin treatment in type 2 diabetic patients on intracellular lipid content in liver and skeletal muscle. *Diabetes* 2002;51:3025–32.
21. Szczepaniak LS, Dobbins RL, Metzger GJ, et al. Myocardial triglycerides and systolic function in humans: in vivo evaluation by localized proton spectroscopy and cardiac imaging. *Magn Reson Med* 2003;49:417–23.
22. Reingold JS, McGavock JM, Kaka S, et al. Determination of triglyceride in the human myocardium by magnetic resonance spectroscopy: reproducibility and sensitivity of the method. *Am J Physiol Endocrinol Metab* 2005;289:E935–9.
23. Katz J, Milliken MC, Stray-Gundersen J, et al. Estimation of human myocardial mass with MR imaging. *Radiology* 1988;169:495–8.
24. Riley-Hagan M, Peshock RM, Stray-Gundersen J, et al. Left ventricular dimensions and mass using magnetic resonance imaging in female endurance athletes. *Am J Cardiol* 1992;69:1067–74.
25. Robotham JL, Takata M, Berman M, Harasawa Y. Ejection fraction revisited. *Anesthesiology* 1991;74:172–83.
26. Abate N, Garg A, Peshock RM, et al. Relationships of generalized and regional adiposity to insulin sensitivity in men. *J Clin Invest* 1995;96:88–98.
27. Kankaanpaa M, Lehto HR, Parkka JP, et al. Myocardial triglyceride content and epicardial fat mass in human obesity: relationship to left ventricular function and serum free fatty acid levels. *J Clin Endocrinol Metab* 2006;91:4689–95.
28. Browning JD, Horton JD. Molecular mediators of hepatic steatosis and liver injury. *J Clin Invest* 2004;114:147–52.
29. Kaser S, Moschen A, Cayon A, et al. Adiponectin and its receptors in non-alcoholic steatohepatitis. *Gut* 2005;54:117–21.
30. Ravussin E, Smith SR. Increased fat intake, impaired fat oxidation, and failure of fat cell proliferation result in ectopic fat storage, insulin resistance, and type 2 diabetes mellitus. *Ann N Y Acad Sci* 2002;967:363–78.
31. Shulman GI. Unraveling the cellular mechanism of insulin resistance in humans: new insights from magnetic resonance spectroscopy. *Physiology* 2004;19:183–90.
32. Bajaj M, Suraamornkul S, Pratipanawatr T, et al. Pioglitazone reduces hepatic fat content and augments splanchnic glucose uptake in patients with type 2 diabetes. *Diabetes* 2003;52:1364–70.
33. Opie LH. Heart physiology: from cell to circulation. 4th ed. Lippincott Williams and Wilkins: Philadelphia, Baltimore, New York, London, Buenos Aires, Hong Kong, Sydney, Tokyo. 2004.
34. Young LH. Insulin resistance and the effects of thiazolidinediones on cardiac metabolism. *Am J Med* 2003;115 Suppl 8A:75S–80S.
35. Gumieniczek A. Modification of oxidative stress by pioglitazone in the heart of alloxan-induced diabetic rabbits. *J Biomed Sci* 2005;12:531–7.
36. Insulin in type 2 diabetes: a useful alternative despite limited assessment based on surrogate endpoints. *Prescrire Int* 2005;14:187–93.
37. Sharma AM, Janke J, Gorzelniak K, et al. Angiotensin blockade prevents type 2 diabetes by formation of fat cells. *Hypertension* 2002;40:609–11.
38. Yu JG, Javorschi S, Hevener AL, et al. The effect of thiazolidinediones on plasma adiponectin levels in normal, obese, and type 2 diabetic subjects. *Diabetes* 2002;51:2968–74.
39. Tiikkainen M, Hakkinen AM, Korshennikova E, et al. Effects of rosiglitazone and metformin on liver fat content, hepatic insulin resistance, insulin clearance, and gene expression in adipose tissue in patients with type 2 diabetes. *Diabetes* 2004;53:2169–76.
40. Siebler J, Galle PR. Treatment of nonalcoholic fatty liver disease. *World J Gastroenterol* 2006;12:2161–7.