

Rapid Diagnosis of Mediastinal Tuberculosis With Polymerase Chain Reaction Evaluation of Aspirated Material Taken by Endobronchial Ultrasound–Guided Transbronchial Needle Aspiration

Aysegul Senturk, MD,* Emine Arguder, MD,* Habibe Hezer, MD,* Elif Babaoglu, MD,* Hatice Kilic, MD,* Aysegul Karalezli, MD,* and H. Canan Hasanoglu, MD†

Background: Endobronchial ultrasound–guided transbronchial needle aspiration (EBUS-TBNA) is a diagnostic method for tuberculosis (TB). This study was conducted to determine the efficiency of polymerase chain reaction (PCR) testing for detecting TB lymphadenitis in samples obtained by EBUS-TBNA.

Materials and Methods: A total of 93 consecutive patients with hilar/mediastinal lymphadenopathies and diagnosed with granulomatous diseases through histopathological evaluation were included in the study. The specimens provided by EBUS-TBNA were evaluated through pathological, microbiological, and molecular tests.

Results: Eighty-nine (95.7%) of the 93 patients had histopathologically granulomatous diseases by EBUS-TBNA. Tuberculosis was diagnosed in 27 (30.3%) patients and sarcoidosis was diagnosed in 62 (69.7%) patients. Four (4.3%) patients were diagnosed through mediastinoscopy. Endobronchial ultrasound–guided transbronchial needle aspiration had an overall diagnostic efficiency in TB of 96.9%, a sensitivity of 90.9%, and a specificity of 100%. *Mycobacterium tuberculosis* PCR was positive in 17 of the 30 patients. The sensitivity of PCR was 56.7%, the specificity was 100%, and the general efficiency of the test was 96.4%.

Conclusions: As a result, the use of *M. tuberculosis* PCR in the EBUS-TBNA specimens provides a rapid and an accurate diagnosis of TB. Therefore, we recommend the use of *M. tuberculosis* PCR in the EBUS-TBNA specimens as a rapid diagnostic method for mediastinal lymphadenopathies in patients with suspected TB.

Key Words: *Mycobacterium tuberculosis* polymerase chain reaction, endobronchial ultrasound–guided transbronchial needle aspiration

(*J Investig Med* 2014;62: 885–889)

The differential diagnosis of granulomatous lung diseases can be challenging in the clinical settings. In developing countries, the most common cause of granulomatous diseases is tuberculosis (TB). Tuberculosis is caused by the bacteria *Mycobacterium tuberculosis*, which primarily affects the lungs but can also extend to the extrapulmonary systems or organs. Tuberculosis lymphadenitis is the most common type of extrapulmonary TB.

Tuberculosis causes 30% to 52% of all lymphadenopathies (LAPs) in developing countries and 1.6% in developed

countries. In addition, in Turkey, extrapulmonary TB accounts for 30.6% of all TB cases.^{1,2} Furthermore, mediastinal tuberculous LAPs constitute 4.3% of all extrapulmonary TB cases.³ Conventional bronchoscopic specimens (bronchial lavage and/or transbronchial needle aspiration [TBNA] and/or sputum examinations) generally do not provide enough information for the diagnosis of isolated mediastinal LAPs. A definitive diagnosis of TB lymphadenitis depends on the detection of TB bacilli by culture and/or identification of a granulomatous reaction with caseification necrosis at the pathological specimens of the lymph node. Some patients with mediastinal LAP in our country cannot have an exact TB diagnosis, but they were given empirical TB treatment. New diagnostic methods such as endobronchial ultrasound–guided TBNA (EBUS-TBNA) will decrease the ratio of redundant TB treatment. Endobronchial ultrasound–guided TBNA provides tissue specimens from mediastinal LAPs in real time. In addition, EBUS-TBNA ensures safe sampling of LAPs as little as 5 mm without causing vascular damage.⁴

Polymerase chain reaction (PCR) for TB is faster than culture but is not as sensitive as culture. Culture tests remain as the criterion standard test for the definitive diagnosis of *M. tuberculosis* but take several weeks to get the results and demand specialized materials to support the virulent microbacteria in the culture. As a result, clinicians tried to find faster molecular tests, and the use of PCR for detecting *M. tuberculosis* was introduced.⁵ These tests are less time-consuming than the other methods. Rapid diagnosis can expedite the delivery of TB treatment.

The aim of this study was to determine the ability of *M. tuberculosis* PCR tests to make differential diagnosis between TB and sarcoidosis as well as other granulomatous diseases. Mediastinal tuberculous LAPs are difficult for the pathologists to discriminate caseification or noncaseification. A microbiological rapid result such as *M. tuberculosis* PCR tests would be useful for this evaluation; hence, this study was planned to determine the diagnostic value of TB PCR tests in the material taken by EBUS-TBNA.

MATERIALS AND METHODS

Patients who were investigated for hilar/mediastinal LAPs between January 2009 and December 2012 at the Ankara Atatürk Training and Research Hospital were included in the study retrospectively. Written informed consent for EBUS-TBNA was obtained from all patients. The study was approved by the local institutional ethics committee (2011-09-88).

The tests were conducted to collect clinical information about the following: blood cell count, biochemical and coagulation parameters, serology of human immunodeficiency virus (HIV), serum calcium, 24-hour urine calcium, and serum angiotensin-converting enzyme. A tuberculin skin test (TST) was also conducted in all patients. The patients with a platelet

From the *Department of Pulmonary Diseases, Ankara Atatürk Training and Research Hospital; and †Department of Pulmonary Diseases, Faculty of Medicine, Yildirim Beyazıt University, Ankara, Turkey.

Received January 3, 2013, and in revised form April 3, 2014.

Accepted for publication April 8, 2014.

Reprints: Aysegul Senturk, MD, Department of Pulmonary Diseases, Atatürk Training and Research Hospital, Bilkent St Number 3 06800 Ankara, Turkey. E-mail: asenturk1967@yahoo.com.

There is no conflict of interest.

Copyright © 2014 by The American Federation for Medical Research

ISSN: 1081-5589

DOI: 10.1097/01.JIM.0000446837.75352.3b

count of less than 20,000/mm³ and/or an international normalized ratio of more than 1.3 were excluded from the study. A TST reaction of greater than or equal to 15 mm was considered as positive in patients who had received BCG vaccination, whereas a reaction of greater than or equal to 10 mm was considered as positive in those who had not received the vaccination.

Sputum examination for acid-fast bacilli (AFB) using the Ehrlich-Ziehl-Neelsen (EZN) staining technique and PCR was performed 3 times in all patients who could expectorate sputum. Fiber-optic bronchoscopy and bronchial lavage were performed in all patients before endobronchial ultrasound. Endobronchial ultrasound-guided TBNA was performed in those with negative PCR and pathological results for bronchial lavage. Thorax computed tomographic (CT) scan was performed in all patients, and the availability of the lymph nodes for endobronchial ultrasound sampling was evaluated. The locations of the mediastinal and hilar lymph nodes were determined (Fig. 1A). The patients with isolated mediastinal lesions of granulomatous diseases without parenchymal lung abnormalities were identified and included in the study. The patients with lung cancer and those with other parenchymal lung lesions were excluded from the study.

The mediastinal/hilar lymph nodes were sampled via 7.5-MHz (BF-UC160F-OL8; Olympus Medical Systems, Tokyo, Japan) convex probe EBUS-TBNA in real time under local anesthesia and conscious sedation using Dormicum and/or propofol. During this procedure, a 22-gauge aspirating needle with a syringe model Olympus NA-201SX-4022 was used. Doppler imaging was performed to avoid damage to vascular structures. The sampling was attempted at least 3 times (Fig. 1B). A portion of the sample inside the needle was spread onto glass slides and dried at room temperature for EZN staining and cytologic examination. Another portion of the preparation was put in a mixture of alcohol and formaldehyde. In addition, another portion was put in formaldehyde to form cell blocks and another portion in saline before being placed in formaldehyde was sent for culture in Löwenstein-Jensen (LJ) medium. The rest of the material was placed in a saline solution and sent to the molecular laboratory for PCR examination.

TB PCR Examination Methods

The tissue specimens were stored at 3°C to 8°C in a molecular laboratory. They were transformed into paraffin tissue blocks, and 4- to 7- μ m-thick sections were obtained. They were then deparaffinized with octane, placed in Eppendorfs, and washed with alcohol. *Mycobacterium tuberculosis* DNA isolation was performed using a QIAamp DNA (QIAGEN, Belgium) commercial mini kit. The isolated DNA samples were PCR amplified in real time using a Cornett device and an Artus *M. tuberculosis* RG PCR kit (QIAGEN). In this study, negative controls were used along with both internal and external positive controls.⁶

TABLE 1. Number of Cases and the Criteria of TB Diagnosis

	Frequency	%
Histopathology + PCR + AFB/culture	5	16.7
Histopathology + PCR + clinical findings	11	36.7
Histopathology + AFB	1	3.3
Histopathology + clinical findings	13	43.3

The detection of any of the following was accepted as microbiologically positive: AFB in EZN staining, TB bacilli reproduction, and *M. tuberculosis* DNA by PCR. A histopathologically positive result was identified by a granulomatous reaction, which included epithelioid histiocytes, Langerhans cells, and/or caseification necrosis (Fig. 1C). The pathological findings were classified into 5 and these are the following: granuloma with necrosis, only granuloma, necrosis, nonspecific, and inadequate sample. The following diagnoses were made histopathologically: PCR, AFB, clinical findings, and clinical follow-up. The patients with TB were diagnosed with 2 definitions, which are as follows: (1) TB: granuloma with or without necrosis or necrosis only, positive for AFB, or granuloma with necrosis; and (2) the presence of a positive TST and/or a history of household contact with TB (Table 1). Tuberculosis was also considered in the differential diagnosis of granulomatous reaction without caseification necrosis. Granuloma without necrosis and microbiology test with negative findings combined with typical bilateral hilar lymph nodes was suggestive of sarcoidosis. A clinical diagnosis of sarcoidosis was confirmed when the patients met the following criteria: stability or regression during follow-up and demonstration of extrapulmonary manifestations of sarcoidosis (uveitis, erythema nodosum, neurologic or cardiac involvement).

The patients with mediastinal TB received TB treatment for 6 months. One year after the diagnosis, their symptoms had improved and CT indicated a reduction in the size of their lymph nodes.

Analysis of TB PCR Performance

The sensitivity, specificity, and diagnostic accuracy of the PCR test were studied. The results of the histopathological and microbiological examinations as well as PCR correlated with the clinical outcome, which is considered as the criterion standard. *Sensitivity* is the ability of the test to identify correctly those who have the disease from all individuals with the disease. *Specificity* is the ability of the test to identify correctly those who do not have the disease from all individuals free from the disease. *Accuracy* was defined by the total number of true-positive and true-negative tests divided by the total number of patients that were

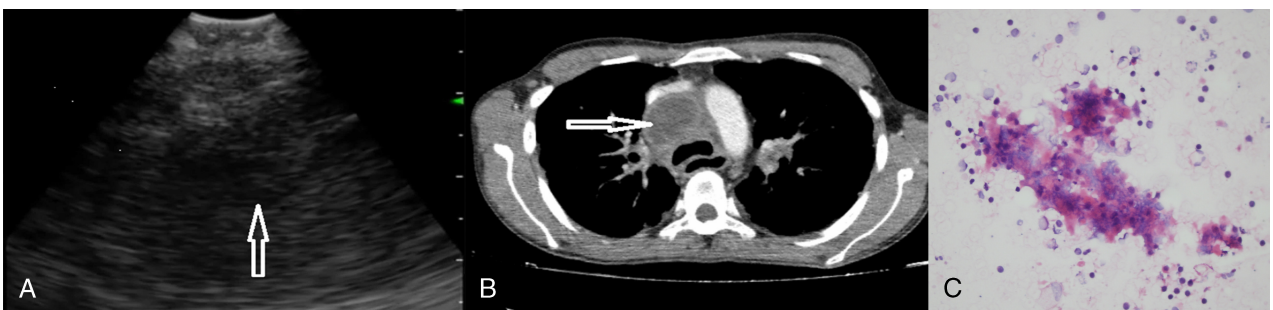


FIGURE 1. A, A right paratracheal lymph node in a patient with TB by EBUS-TBNA. The lymph node was characterized as heterogeneous. B, The thorax CT scan demonstrates a right paratracheal lymph node. C, Photomicrograph of smear showing caseification necrosis, epithelioid histiocytes, and lymphocytes (hematoxylin-eosin, original magnification $\times 400$).

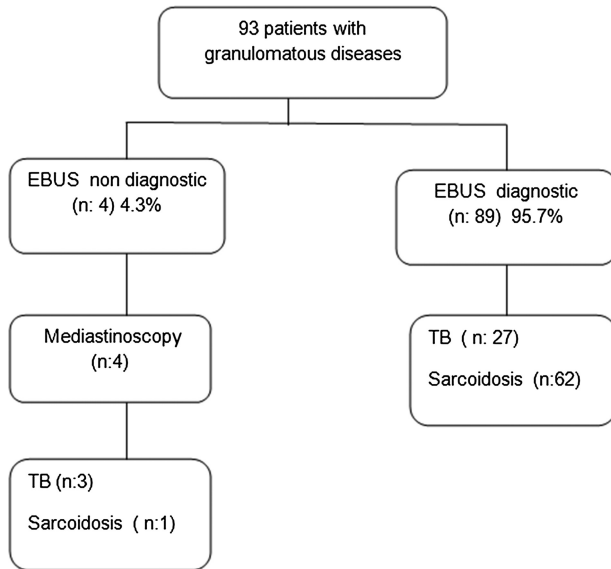


FIGURE 2. Flow chart of patients with intrathoracic granulomatous lymph nodes in whom EBUS-TBNA was applied.

calculated with the software package Statistical Package for the Social Sciences version 17 (SPSS Inc, Chicago, IL). The χ^2 test was done along with the *P* value to see the presence of associations or agreement. A *P* value of less than 0.05 was considered statistically significant.

RESULTS

Ninety-three patients (62 women and 31 men) who underwent EBUS-TBNA for isolated hilar and/or mediastinal LAPs and were diagnosed with granulomatous diseases were examined. The mean (SD) age of the patients was 49.31 (13.9) (range, 23–78) years. There were no AFB-positive results in the sputum tests, and all of the patients were HIV-negative. EBUS-TBNA and mediastinoscopic biopsies were used for pathological diagnosis.

The use of EBUS-TBNA resulted in the diagnosis of histopathological granulomatous diseases in 89 (95.7%) patients, whereas the use of mediastinoscopy resulted in a diagnosis for an additional 4 (4.3%) patients. After the clinical, radiologic, and laboratory evaluations, 30 (32.3%) patients were diagnosed with TB and 63 (67.7%) patients were diagnosed with sarcoidosis (Fig. 2).

The specimens provided by EBUS-TBNA were evaluated in the pathological, microbiological, and molecular (*M. tuberculosis* PCR) examinations, which led to 17 of the 30 patients being positive for mediastinal TB LAPs (Table 2). The sensitivity of the PCR test was 56.7%, whereas the specificity was 100%. Furthermore, the general efficiency of the test was 96.4%. The AFB and the *M. tuberculosis* culture were positive in only 6 patients. The sensitivity of the culture test was 20%. The combined results of the culture and PCR in the LAP specimens provided an even better rate of TB detection of 60% (18/30 patients; Table 3). Sixteen (53.3%) patients had a history of contact with TB; the

TABLE 2. Number of Cases and the Criteria of TB Diagnosis

		AFB Positive	Culture Positive
PCR	Negative	1	1
	Positive	4	5
Total		5	6

TABLE 3. Polymerase Chain Reaction Was Compared Against the Combination of Both the Conventional Methods

	Frequency	%
PCR	17/30	56.7
AFB	5/30	16.7
PCR + culture	17 + 6/30	60
Culture	6/30	20

TST result was positive in 19 (63.3%) patients. Tuberculosis was confirmed in 18 (17 PCR-positive patients and only 1 culture-positive patient) patients by laboratory results, whereas the remaining 12 patients were diagnosed on the basis of just clinical manifestation and histopathological results.

On EBUS-TBNA cytology, necrotizing granulomatous inflammation was exhibited in 53.3% (16/27 patients); necrosis without granuloma, in 33.3% (10/27 patients); and necrosis only, in 3.3% (1/27 patients). Necrotizing granulomatous inflammation was shown in 6.7% (2/3 patients) through histologic evaluation of the biopsy specimen, which yielded through mediastinoscopy, and only granuloma was shown in 3.3% (1/3 patients). A total of 18 patients had a granuloma with necrosis; 11 patients were PCR positive and 5 patients were AFB positive. A total of 11 patients had a granuloma without necrosis, 5 of whom were AFB positive (Table 4).

The PCR was false negative for the 13 patients with TB LAPs. In these patients, the cultures were negative and TB was diagnosed histopathologically and clinically.

Mediastinoscopy was required for diagnosing the remaining 4 patients when EBUS-TBNA was not diagnostic; 3 patients had TB and 1 patient had sarcoidosis. The sensitivity value of EBUS-TBNA for the diagnosis of TB was 90.9%, the specificity was 100%, and the general efficiency of the test was 96.9%.

DISCUSSION

The aim of this study was to determine the ability of *M. tuberculosis* PCR tests to discriminate between TB and sarcoidosis as well as granulomatous diseases. Of the patients, 30 (32.3%) were diagnosed with TB. Mediastinal LAPs were identified as TB positive in 17 patients using *M. tuberculosis* PCR, whereas the results of the *M. tuberculosis* culture were negative in those 12 patients. These results indicate that a positive PCR helped to establish a definitive diagnosis in 17 patients whose differential diagnosis for TB or sarcoidosis could not be made by clinical or pathological means. Therefore, *M. tuberculosis* PCR may contribute to a faster TB diagnosis using EBUS-TBNA specimens.

Mediastinal LAPs are frequently observed in a range of granulomatous diseases such as infections, TB, tularemia, fungal

TABLE 4. The Final Clinical Diagnosis for Cytologic Diagnosis by EBUS-TBNA and Mediastinoscopy

	Frequency	%
EBUS-TBNA		
Only granulomas	10	33.3
Necrosis + granulomas	16	53.3
Necrosis	1	3.3
Mediastinoscopy		
Necrosis + granulomas	2	6.7
Only granulomas	1	3.3
Total	30	100

infections (*Histoplasma capsulatum*, *Coccidioides immitis*, *Cryptococcus neoformans*, and *Blastomyces dermatitidis*), vasculitis (Wegener granulomatosis, Churg-Strauss syndrome), environmental or occupational diseases (chronic berylliosis or hypersensitivity pneumonitis), and malignancies. The infectious etiology of the mediastinal granuloma changes according to countries. For example, fungal infections (especially *H. capsulatum*) are the main cause of mediastinal granulomatous LAPs in America. However, TB is the most common cause of mediastinal LAPs, especially in immunocompromised patients, in developing countries.⁷ The diagnosis of tuberculous LAPs remains a challenge despite the availability of various diagnostic tools. The conventional TBNA is the diagnostic method generally recommended for granulomatous mediastinal LAPs that has proven to be useful for diagnosing TB. However, it is a blind technique, has low sensitivity, and can only access certain lymph node stations in the mediastinum. The diagnostic value of this method is poor when compared with EBUS-TBNA. On the other hand, EBUS-TBNA is considered to be a safer and more sensitive procedure than the conventional TBNA.⁸

Computed tomography-guided biopsy, mediastinoscopy, and video-assisted thoracoscopic surgery are the other methods that can be used to collect samples from the mediastinal lymph nodes. However, CT-guided biopsy is associated with a high risk for pneumothorax and surgical methods require anesthetic equipment and hospitalization. As an alternative method, the use of EBUS-TBNA is increasing. It has generally been used for mediastinal staging in lung cancer. Although studies have reported the use of EBUS-TBNA for the identification of sarcoidosis in patients with granulomatosis, there is limited evidence about its use in patients with TB.^{9,10}

Çağlayan et al.¹¹ demonstrated that the diagnostic accuracy of EBUS-TBNA was 84.2% in TB and 83.3% in granuloma in a study involving 72 patients. In the study of Çağlayan et al.¹¹ with EBUS-TBNA among the 72 patients, 35 were diagnosed with sarcoidosis and 16 were diagnosed with tuberculous lymphadenitis. This result is similar to that of our study. In another study of 321 patients, Cetinkaya et al.¹² reported that the diagnostic rate of EBUS-TBNA was 79% for TB. In the current study, EBUS-TBNA established the histopathological diagnosis of granulomatous diseases in 89 (95.7%) patients. This is in accordance with Navani et al.,¹³ who documented the diagnosis of TB in 146 (94%) patients by EBUS-TBNA. Further, 86% of these patients were diagnosed histopathologically, whereas 47% of these patients were diagnosed microbiologically. Polymerase chain reaction examination was not used for diagnostic purposes in these studies. Instead, the diagnosis of TB was based on the clinical findings, the EZN staining, and the results of the LJ cultures.

The quality of pathological specimens is very important for the diagnosis of granulomatous diseases. A definitive diagnosis in TB lymphadenitis obtained from the lymph nodes can be made through histopathological examination, detection of AFB by EZN staining, or demonstration of positive TB cultures. The sensitivity and specificity of these methods for diagnosing TB LAPs have not been firmly established yet. The presence of granuloma with/without caseification necrosis in pathology cannot be considered an exact finding for TB. In addition, granuloma with/without caseification necrosis is not always found in smears from TB LAPs. Thus, radiologic, histopathological, and bacteriologic evaluation should be performed in such patients.⁵

The conventional EZN technique, which involves direct application of the stain on smears for AFB, is widely used and plays a key role in diagnosis. However, it has low sensitivity, ranging from 20% to 43%, because of the low number of mycobacterial cells present in the LAP specimens. In EZN staining,

to detect AFB in tissue or fluid, at least 10^4 to 10^6 bacilli per milliliter must be present (in culture, at least 10^1 - 10^2 bacilli per milliliter) and 4 to 8 weeks are required. Traditionally, culturing has been recommended as the most appropriate criterion standard. A definite diagnosis of mycobacterial lymphadenitis is made by recovery of the bacterium from the LAP material. However, this is not always possible.^{14,15} Löwenstein-Jensen cultures are less sensitive for growing mycobacteria from the clinical specimens as compared with the liquid culture systems.¹⁶ However, most of the laboratories in Turkey still routinely use LJ culture and not the liquid culture systems. This might explain why only 6 (20%) patients had positive results using EZN staining and LJ cultures in the current study.

Because the control of TB is important, fast and reliable diagnostic methods are needed. Molecular methods provide the speed and accuracy required. The sensitivity and specificity of PCR are high, and they may be able to detect as few as 2 bacilli in a sample. When the clinician is in need of evidence, this will provide a more dependable evidence, especially to end the dilemma of whether to begin the TB treatment.¹⁷ Similar to our results, Hanif et al.¹⁸ demonstrated that PCR had a high specificity. The sensitivity in that study, however, was lower than what was reported here. Using higher quality material could potentially improve the sensitivity. This has been demonstrated by Derese et al.,¹⁹ who reported a PCR sensitivity of 61% to 78% in samples obtained by needle aspiration from the cervical lymph node.

Obtaining cell blocks from the samples helps to diagnose malignancies, facilitates the study of PCR, and provides cultures for TB. The use of cell blocks in the current study helped to improve the diagnosis.²⁰

Polymerase chain reaction, which is a nucleic acid amplification method, is promising for an early and accurate diagnosis of TB. Ersöz et al.²¹ performed fine-needle aspiration in peripheral LAPs in 63 patients, resulting in the determination of a granulomatous reaction in 51.6% ($n = 32$) of the patients with no indication of AFB when EZN staining was conducted. Polymerase chain reaction was used in 23 patients who were suspected of having TB, and 82.6% ($n = 19$) had positive results. Another study reported that the diagnostic rate of fine-needle aspiration was 68.0% in 25 patients. The microbiological results were positive in 8 (32.0%) patients, whereas the PCR results were positive in 24 (96.0%) patients.²² Amin et al.¹⁴ demonstrated that the use of PCR resulted in 46.5% with positive results in patients with AFB-negative extrapulmonary TB. Pahwa et al.²³ also reported that the PCR tests resulted in positive findings for 81.8% in granuloma only, 57.1% in granuloma with necrosis, and 10.0% in necrosis only. In the current study, the PCR returned positive results for 53.3% of the patients with granuloma with necrosis, 33.3% of the patients with granuloma without necrosis, and a lower rate of 3.3% in those with necrosis, which is similar to the results by Pahwa et al.²³

To our knowledge, this is the first study to investigate the use of PCR in EBUS-TBNA samples other than a case study of 2 patients with HIV that reported positive results with the use of PCR in mediastinal LAPs.²⁴ Song et al.²⁵ investigated a similar method in 24 patients using esophageal ultrasound-guided TBNA and detected granulomas in 16 (66.7%) patients. In addition, they reported 3 AFB-positive patients using EZN staining, 5 (20.8%) patients with positive LJ cultures, and 5 (20.8%) other patients with positive PCR results. Berzosa et al.²⁶ reported positive TB cultures in 16 (80.0%) patients and positive PCR in only 1 (5.0%) of the 20 patients who had undergone esophageal ultrasound-guided TBNA because of suspected TB. The use of EBUS-TBNA in yet another study resulted in the diagnosis of TB in 20.0% of the patients.²⁷

In this study, the positive PCR results helped to establish a definitive diagnosis in 17 patients whose differential diagnosis for TB or sarcoidosis could not be made by clinical and pathological means, and comparing LJ cultures with PCR results have demonstrated higher sensitivities for the latter. Therefore, PCR testing was responsible for an improvement in TB diagnosis from 20% to 56.7% when compared with AFB smear and culture methods performed on LAP specimens. In addition, the combined results of culture and PCR in LAP specimens provided an even better rate of TB detection of 60% (18/30 patients). As a result, surgical procedures were not required, an early diagnosis could be made, and timely treatment could be initiated. After TB treatment, significant improvement was observed in mediastinal LAPs at the 12-month follow-up. Although the therapeutic response is a very important gauge of the true disease status, we found a complete correlation between the PCR and the clinical diagnosis in all of the 17 patients. The difficulties in the microbiological diagnosis of mediastinal TB LAPs or the nonavailability of a criterion standard has made the researchers to use various combinations of criteria or parameters such as a combined reference standard in the evaluation of the diagnostic tests. In the current study, the histopathological and microbiological examinations as well as PCR have to be used and the results need to be carefully correlated with the clinical outcome of disease.²⁸

As a conclusion, this is the first study to demonstrate the feasibility and high diagnostic yield of PCR in EBUS-TBNA specimens when investigating hilar/mediastinal LAPs in patients who have TB. Polymerase chain reaction has a potentially important role in improving the diagnostic accuracy of mediastinal LAPs. Hence, EBUS-TBNA sampling for EZN staining, culture, and PCR tests should be performed for the diagnosis of mediastinal TB. A combination of conventional techniques and PCR must be applied for the rapid and early diagnosis of mediastinal TB to achieve maximum sensitivity.

REFERENCES

- Sloane MF. Mycobacterial lymphadenitis. In: Rom WN, Garay S, eds. *Tuberculosis*. New York: Little Brown and Co; 1995:577–583.
- Karagöz T, Şenol T, Bekçi TT. Tuberculous lymphadenitis. *Turk Thorac J*. 2001;2:74–79.
- Türkkan MH, Musaonbaşıoğlu S, Güllü U, et al. WHO global tuberculosis control report 2009 in Turkey. In: Bozkurt H (Ed). *Fight against Tuberculosis in Turkey*. 1st ed. Ankara Turkey: 2010:1–5.
- Yasufuku K, Chiyo M, Sekine Y, et al. Real-time endobronchial ultrasound-guided transbronchial needle aspiration of mediastinal and hilar lymph nodes. *Chest*. 2004;126:122–128.
- Annam V, Karigoudar MH, Yelikar BR. Improved microscopical detection of acid-fast bacilli by the modified bleach method in lymphnode aspirates. *Indian J Pathol Microbiol*. 2009;52:349–352.
- QIAamp. *DNA Mini and Blood Mini Handbook*. 3rd ed. Quiagen; 2010.
- El-Zammar OA, Katzenstein AL. Pathological diagnosis of granulomatous lung disease: a review. *Histopathology*. 2007;50:289–310.
- Herth F, Becker HD, Ernst A. Conventional vs endobronchial ultrasound-guided transbronchial needle aspiration: a randomized trial. *Chest*. 2004;125:322–325.
- Garwood S, Judson MA, Silvestri G, et al. Endobronchial ultrasound for the diagnosis of pulmonary sarcoidosis. *Chest*. 2007;132:1298–1304.
- Tremblay A, Stather DR, Maceachern P, et al. A randomized controlled trial of standard vs endobronchial ultrasonography-guided transbronchial needle aspiration in patients with suspected sarcoidosis. *Chest*. 2009;136:340–346.
- Çağlayan B, Salepci B, Fidan A, et al. Sensitivity of convex probe endobronchial sonographically guided transbronchial needle aspiration in the diagnosis of granulomatous mediastinal lymphadenitis. *J Ultrasound Med*. 2011;30:1683–1689.
- Cetinkaya E, Gunluoglu G, Ozgul A, et al. Value of real-time endobronchial ultrasound-guided transbronchial needle aspiration. *Ann Thorac Med*. 2011;6:77–81.
- Navani N, Molyneaux PL, Breen RA, et al. Utility of endobronchial ultrasound-guided transbronchial needle aspiration in patients with tuberculous intrathoracic lymphadenopathy: a multicentre study. *Thorax*. 2011;66:889–893.
- Amin I, Idrees M, Awan Z, et al. PCR could be a method of choice for identification of both pulmonary and extra-pulmonary tuberculosis. *BMC Res Notes*. 2011;4:332–338.
- Chawla K, Gupta S, Mukhopadhyay C, et al. PCR for *M. tuberculosis* in tissue samples. *J Infect Dev Ctries*. 2009;3:83–87.
- Shinnick TM, Iademarco MF, Ridderhof JC. National plan for reliable tuberculosis laboratory services using a systems approach. Recommendations from CDC and the Association of Public Health Laboratories Task Force on Tuberculosis Laboratory Services. *MMWR Recomm Rep*. 2005;15:1–12.
- Gupta D, Agarwal R, Aggarwal AN, et al. Sarcoidosis and tuberculosis: the same disease with different manifestations or similar manifestations of different disorders. *Curr Opin Pulm Med*. 2012;18:506–516.
- Hanif F, Ikram A, Satti L, et al. Utility of polymerase chain reaction in diagnosis of tuberculosis in our setup: a ten years experience. *J Coll Physicians Surg Pak*. 2012;22:298–301.
- Dereş Y, Hailu E, Assefa T, et al. Comparison of PCR with standard culture of fine needle aspiration samples in the diagnosis of tuberculosis lymphadenitis. *J Infect Dev Ctries*. 2012;6:53–57.
- Sanz-Santos J, Serra P, Andreo F, et al. Contribution of cell blocks obtained through endobronchial ultrasound-guided transbronchial needle aspiration to the diagnosis of lung cancer. *BMC Cancer*. 2012;12:34.
- Ersöz C, Polat A, Serin MS, et al. Fine needle aspiration (FNA) cytology in tuberculous lymphadenitis. *Cytopathology*. 1998;9:201–207.
- Aljafari AS, Khalil EA, Elsididg KE, et al. Diagnosis of tuberculous lymphadenitis by FNAC, microbiological methods and PCR: a comparative study. *Cytopathology*. 2004;15:44–48.
- Pahwa R, Hedau S, Jain S, et al. Assessment of possible tuberculous lymphadenopathy by PCR compared to non-molecular methods. *J Med Microbiol*. 2005;54:873–878.
- Steinfort DP, Johnson DF, Connell TG, et al. Endobronchial ultrasound-guided biopsy in the evaluation of intrathoracic lymphadenopathy in suspected tuberculosis: a minimally invasive technique with a high diagnostic yield. *J Infect*. 2009;58:309–311.
- Song HJ, Park YS, Seo DW, et al. Diagnosis of mediastinal tuberculosis by using EUS-guided needle sampling in a geographic region with an intermediate tuberculosis burden. *Gastrointest Endosc*. 2010;71:1307–1313.
- Berzosa M, Tsukayama DT, Davies SF, et al. Endoscopic ultrasound-guided fine-needle aspiration for the diagnosis of extra-pulmonary tuberculosis. *Int J Tuberc Lung Dis*. 2010;14:578–584.
- Kuo CH, Lin SM, Lee KY, et al. Algorithmic approach by endobronchial ultrasound-guided transbronchial needle aspiration for isolated intrathoracic lymphadenopathy: a study in a tuberculosis-endemic country. *J Formos Med Assoc*. 2013 Jul 12. [Epub ahead of print].
- Ajantha GS, Shetty PC, Kulkarni RD, et al. PCR as a diagnostic tool for extra-pulmonary tuberculosis. *J Clin Diagn Res*. 2013;7:1012–1015.