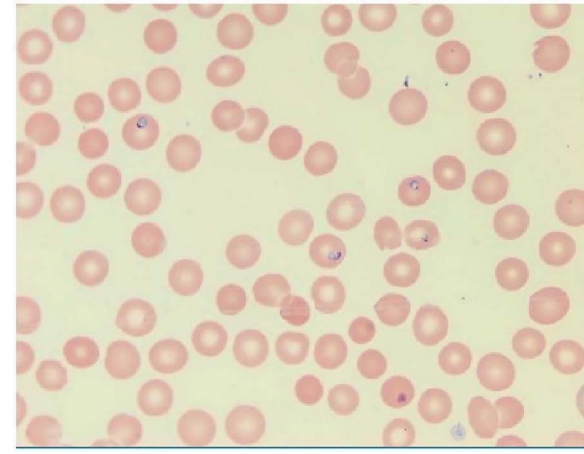

Abstract ID: 53 Figure 1

ID: 53 **SEVER SYMPTOMATIC BABESIOSIS CO-INFECTION WITH LYME DISEASE**

H Alkhawam, F Zaiem, S Lee, M Fabisevich, A Ashraf. *Internal Medicine, Icahn School of Medicine at Mount Sinai (Elmhurst), Corona, New York, United States*

10.1136/jim-2016-000120.92

Case Presentation A 70-year-old male with known history of controlled hypertension, presented with sudden onset of headaches, fevers, vomiting and low urine output for the past 4 days. The patient had recently emigrated from Bangladesh 6 months ago and had been staying in Eastern Long Island, NY. On admission, the patient found to have anemia, thrombocytopenia and acute kidney injury. Significant labs include hemoglobin of 10.2 g/dl, platelets of 39 109/L, BUN of 87 mg/dl, creatinine of 4.48 mg/dl, prothrombin time of 14.8, AST 55 U/l and ALT 65 U/l, LDH of 359 U/l, fibrinogen of 637 mg/dl, CRP of 17.8 mg/l and ESR of 92 mm/h. Haptoglobin was within normal limits. Peripheral blood smear revealed intracellular ovoid rings resembling both Plasmodium sp. and B. microti rings. The patient was started on a 7-day treatment with doxycycline and quinine to cover either infection. Later on, PCR test for B. microtii came back positive. He showed improvement in both symptoms and laboratory findings. On the day of planned discharge, the patient began to complain of right-sided numbness and difficulty closing the mouth and right eye. The diagnosis of Bell palsy had been established. Borrelia burgdorferi serology then sent and it turned out to be positive. Doxycycline had been restarted for another 2 weeks and the patient was symptoms-free after the new course.

Discussion Humans are opportunistic hosts to Babesia when bitten by nymph or adult ticks; the most known ticks are Ixodes. Babesiosis should be considered in patients who have a malaria-like illness in areas endemic for Babesia infection. The symptoms usually begin 2–4 weeks after a tick bite. The presentation includes constitutional symptoms, abdominal pain and dark urine. Labs finding include hemolytic anemia and elevated liver enzymes. Urinalysis reveals hemoglobinuria without red blood cells. The diagnosis of Babesiosis is usually established by microscopic examination of Giems or Wright-stained blood smears, indirect immunofluorescent antibody tests and PCR. In healthy individuals with intact spleens, the symptoms resolve spontaneously without treatment. For mild to moderate babesiosis, combination therapy with atovaquone and azithromycin for 7 days. However, in patients who are asplenic or immunocompromized, babesiosis is quite severe and is associated with higher mortality, the preferred treatment is intravenous clindamycin and oral quinine. In patients who are refractory to pharmacological treatment, red blood cells exchange transfusion has been shown to improve mortality. It is very important to consider other tick-borne agents that may be co-transmitted with Babesia such as B. burgdorferi; the agent of Lyme disease. Co-infection should be considered in patients with a poor response to conventional antimicrobial therapy or atypical clinical presentations. When co-infection is suspected, as in our patient, physicians should consider treating Lyme disease empirically for 2–3 weeks.