

# Safety of percutaneous endoscopic gastrostomy tube placement in patients with continuous-flow ventricular assist devices

Hesam Keshmiri,<sup>1</sup> Tariq Yousuf,<sup>1</sup> Rasha Issa,<sup>1</sup> Sudha Kurien,<sup>2</sup> Roeglio Silva<sup>3</sup>

<sup>1</sup>Department of Cardiology, Advocate Illinois Masonic Medical Center, Chicago, Illinois, USA

<sup>2</sup>Advocate Christ Medical Center, Oak Lawn, Illinois, USA

<sup>3</sup>Department of Gastroenterology, Advocate Christ Medical Center, Oak Lawn, Illinois, USA

**Correspondence** to Dr Tariq Yousuf, Department of Medicine, Advocate Christ Medical Center, 4440 W. 95th St. Oak Lawn, IL 60453, USA; tmyousuf614@gmail.com

Accepted 31 March 2016  
Published Online First  
21 April 2016

Copyright © 2016 American Federation for Medical Research

## ABSTRACT

In this retrospective study, the safety of percutaneous endoscopic gastrostomy (PEG) tube placement was evaluated as maintaining adequate nutritional support for patients with left ventricular assist devices is crucial. Nineteen patients who underwent PEG tube placement were followed for an average of 40 days. Overall, minor complications such as infections, bleeding, and PEG tube malposition occurred in just 19% of patients while the rate of major complications such as perforation was 5%. Further randomized control trials are necessary to validate this assertion that the safety of PEG placement in patients with left ventricular assist devices is similar to that of the general population.

## INTRODUCTION

Left ventricular assist devices (LVADs) are now standard of care and Food and Drug Administration (FDA) approved for use in bridge-to-transplantation therapy (BTT) and destination therapy (DT) for patients with advanced heart failure. Obtaining adequate nutrition in these patients can be challenging due to associated anorexia, delayed gastric emptying and early satiety from the bulk of the intra-abdominally implanted device.<sup>1–3</sup> Nutritional support is essential in the perioperative management of patients with LVADs to optimize outcomes. Malnourishment has been shown to be associated with increased morbidity and mortality after cardiac operations.<sup>4</sup>

In situations where oral feeding is either not possible or is insufficient for providing adequate nutrition, alternative forms of nutritional support should be considered. Feeding through a percutaneous endoscopic gastrostomy (PEG) tube may be a viable option in these situations. This is particularly true in patients in whom long-term mechanical ventilation is required, necessitating a more durable and reliable enteral access. However, studies evaluating feasibility and safety of placing a PEG tube for nutritional support in patients with LVADs are limited to a few case reports. In a retrospective analysis at our tertiary care center along with a comprehensive review of the literature, we sought to evaluate the safety of PEG tube placement in patients with LVADs

## Significance of this study

### What is already known about this subject?

There are currently no publications regarding the safety of percutaneous endoscopic gastrostomy (PEG) tube placement in patients with left ventricular assist devices (LVADs).

### What are the new findings?

In our study, we found that the PEG tubes can be considered a safe procedure in patients with LVADs. There is a very small rate of major and minor complications that one should be aware of.

### How might these results change the focus of research or clinical practice?

This will impact clinical practice drastically in the foreseeable future in that it will give gastroenterologists the peace of mind and comfort to proceed with PEG tube placement earlier in patients with LVADs, which allows for better nutritional status.

and to describe the unique technical aspects of PEG insertion.

## METHODS

Patients with LVADs who underwent PEG tube placement with the Cook Medical 20 French PEG tube kit at our center between 2005 and 2013 were retrospectively reviewed (n=19). Using electronic medical records, all procedures that each subject had undergone was reviewed and a total of 19 patients with PEG placement after LVAD were noted. These patients had either the second-generation CF-LVAD HeartMate II (HMII) or the third-generation CF-LVAD HeartWare HVAD (HW HVAD) placed. Approximately 200 LVADs were placed over the same time span at our tertiary care center. Only these 19 select patients necessitated nutritional support via enteral feeding. Many of these patients with LVADs were able to maintain nutritional status on their own and did not require any intervention.



CrossMark

**To cite:** Keshmiri H, Yousuf T, Issa R, et al. *J Investig Med* 2016;**64**:1012–1015.

Preprocedural data related to patient demographics, laboratory values including international normalized ratio (INR), hemoglobin, albumin and platelet count, antibiotics, anticoagulant, preprocedural imaging and complications that occurred from PEG tube placement were collected via paper and electronic medical record chart review. Institutional Review Board (IRB) approval was obtained prior to start of data extraction from medical charts. Patients were followed until the PEG tube was removed. No patient deaths occurred in our study. The PEG tube was removed after an average of 41 days due to the patient's ability to achieve the nutritional goal.

## RESULTS

Nineteen patients who underwent PEG tube placement were followed for an average of 41 days. Seventy nine per cent were male with a mean age of 64. Baseline body-weight was 86.5 kg with an average reported BMI of 29. Anticoagulation was held 2 days prior to PEG insertion with a median INR of 1.3. The average hemoglobin, platelet count, and albumin were 9.5, 264, and 2.7, respectively. All patients except one had an abdominal X-ray (figure 1). One patient had fluoroscopy prior to PEG placement to assess the position of the driveline.

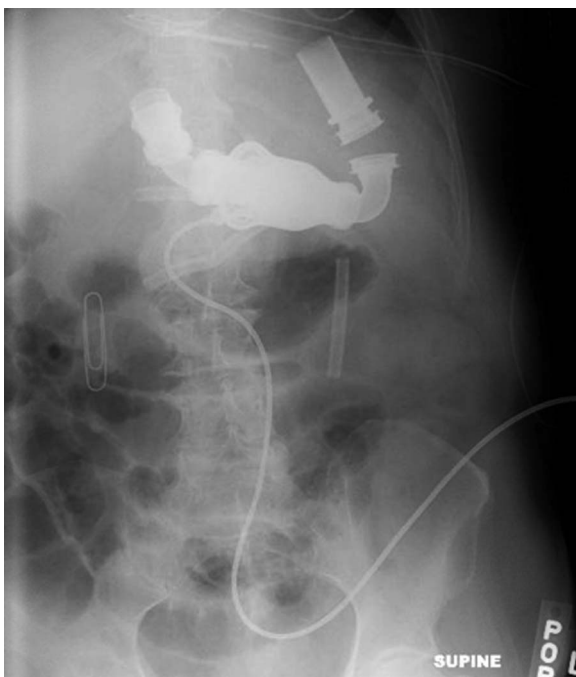
Some of the complications following PEG placement included two patients who developed infection, one who had minor bleeding at the PEG tube insertion site, and one patient who had inadvertent colonic perforation. This patient underwent emergent surgery and received intravenous antibiotics. No portions of his bowel were removed

and the patient had a successful recovery. The PEG tube was removed because of its close proximity to the driveline in another patient. Overall, minor complications (infections, bleeding, PEG tube malposition) occurred in 19% of patients while the rate of major complications (perforation) was 5%. There was no procedure-related mortality (figure 2).

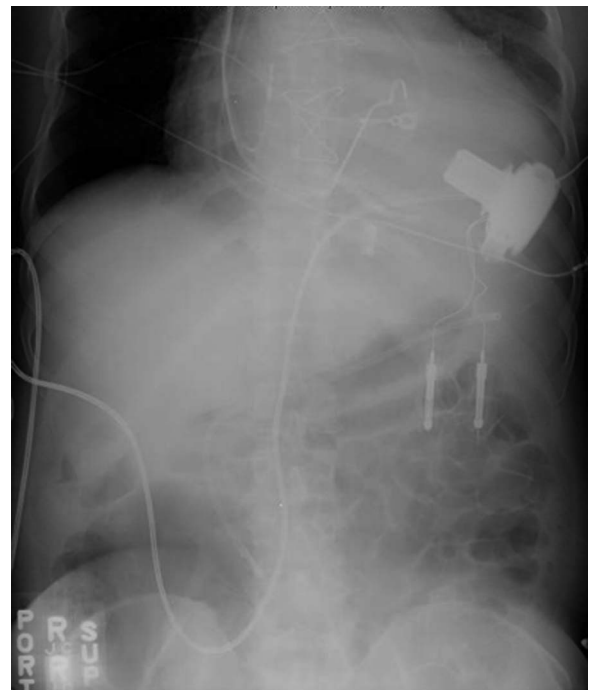
## DISCUSSION

Patients with advanced heart failure are at increased risk for malnutrition. When long-term enteral nutrition is required for heart failure patients with LVAD, PEG access can offer a comfortable and easy delivery of nutrition and medications. However, in this special population of patients with VAD implants, an invasive procedure such as PEG placement can increase risk of bleeding as these patients are on chronic anticoagulation. Anticoagulation therapy is required during support with LVADs, especially in continuous-flow LVADs to avoid thrombotic complications. On the other hand, bleeding is a major complication in patients with implanted LVADs. Most commonly reported sources of bleeding are epistaxis, gastrointestinal bleeding, bleeding of the mediastinum, and thorax and intracranial hemorrhage.<sup>5</sup>

Recent clinical trials revealed that the incidence of thrombotic events is very low, in fact much lower than bleeding.<sup>6–9</sup> Thus, the current recommendations are to adjust the warfarin dose to achieve a target INR of 1.5 to 2.5.<sup>5 6 10</sup> One should keep in mind that the optimal INR goal in patients with LVADs with other indications for anticoagulation such as atrial fibrillation or prior thromboembolic stroke has not been established. In our study, warfarin was held on an average of 2 days prior to PEG tube



**Figure 1** Portable anterior-posterior abdominal X-ray with a HeartMate II left ventricular assist device (wide arrow) is shown. Through endoscopy, the area of transillumination is tagged with a paper clip (broken arrow). Prior to PEG tube insertion, an abdominal radiograph is then taken to ensure that the marked area is clear from the driveline (narrow arrow). PEG, percutaneous endoscopic gastrostomy.



**Figure 2** A portable anterior-posterior abdominal X-ray with a HeartWare left ventricular assist device (wide arrow) is shown. The driveline (narrow arrow) exits the right side of the abdomen.

placement with the mean INR of 1.3 and highest INR of 2.0 prior to PEG placement. Antiplatelet medications such as aspirin were not held. One patient in our study developed minor bleeding at the PEG insertion site, and his pre-procedural INR was 1.6.

No thrombotic events occurred in any of our patients that could have been attributed to holding warfarin. Given the current recommendations combined with our experience, we suggest that it may be safe to hold anticoagulation with a target INR from 1.5 to 2.0 before PEG placement.

Another known complication of PEG placement is infection. This can be especially problematic in patients with VADs due to the proximity of the PEG tube insertion to implanted VAD, which could potentially result in device infection with catastrophic consequences. All the subjects in the study either received prophylactic antibiotics prior to PEG tube placement or were already on antibiotics for other active infections. This was done to help prevent infection related to PEG tube insertion. Despite this, two patients developed local infection at the PEG tube insertion site. Neither patient had systemic spread or contiguous device infection.

Placing PEG tubes in patients with LVADs can be technically challenging due to the position of the LVAD within the abdominal cavity. When placing a PEG tube in these patients, the abdominally implanted LVAD, the driveline that crosses the midline, and the immediate space surrounding the device should be avoided. Also, the position of the pump and the driveline may vary depending on the type of LVAD. Therefore, an LVAD technician may aid in determining the position of the LVAD, the position of the driveline within the abdominal cavity, and its exit site, which may help delineate the potential G-tube insertion site. It can be visually estimated and marked with a radio-opaque marker, for example, a paperclip.

Alternatively, the G-tube insertion area can be chosen at the site of transillumination through endoscopy and marked with a radio-opaque marker. An abdominal radiograph can then be used to confirm the position of the marker in relation to the VAD and the driveline; if deemed suitable, the PEG tube is then inserted at the marked site using a conventional technique.

Alternatively, the PEG tube can be inserted under fluoroscopy, which was successfully done for one of our patients. Using fluoroscopy, however, may not be feasible and practical in all patients with LVADs due to the critical situation of these patients at the time of PEG placement, which may make it challenging to move the patient to a fluoroscopy suite. This can be obviated by using a portable abdominal X-ray at the time of the procedure to assess the driveline position in relation to the PEG insertion site. Using a paperclip as a radio-opaque marker in the area of transillumination during PEG placement and then confirming the proximity of this marker to the driveline with a portable X-ray is simple, safe, and readily available at the patient's bedside.

There are only a few published single case studies that have reported successful placement of percutaneous feeding tubes in patients with a VAD. Slaughter *et al*<sup>11</sup> reported a case of a 72-year-old male with an extracorporeal LVAD (outside of body cavity) who required a prolonged period (6 months) of enteral nutritional support

that was provided through a PEG tube, which was successfully inserted with no reported complications. Simmons *et al*<sup>12</sup> described a case of a 76-year-old male with an LVAD who underwent a successful placement of a direct percutaneous endoscopic jejunostomy (PEJ) due to inaccessibility for PEG placement because of the LVAD position within the abdomen. There were no reported complications from PEJ placement, and the patient was discharged from the hospital after 2 weeks with PEJ intact. Finally, Page *et al*<sup>13</sup> reported the successful PEJ tube placement under fluoroscopic guidance in a 39-year-old female with a biventricular assist device. The patient was able to achieve the target caloric needs and remained on enteral feeds for 71 days before expiring from acute heart failure.

With the above successful examples, one must also consider the bad. Complications of gastrostomy tube placement may be minor (wound infection, minor bleeding, ileus) or major (perforation, necrotizing fasciitis, fistula). In our retrospective review, the rate of minor complications from PEG placement was 19% while major complications occurred in 5% of the patients. Comparably, in studies evaluating complications of PEG tube placement in the general population, the rate of minor complications ranged from 10% to 62% with the majority of studies reporting complication rates between 10% and 30%.<sup>14–17</sup> Major complications occurred in 3–11% of the patients.<sup>14–17</sup>

## CONCLUSION

In patients with LVADs, the rate of major and minor complications from PEG placement is comparable to that of the general population without LVADs. Preprocedural imaging to localize the driveline position using a radio-opaque marker as a reference point and discontinuation of anticoagulation prior to the procedure are important safety precautions that should be taken prior to PEG placement. INR of less than 2.0 appears to be safe with a minimal risk of complications. Keeping the driveline position away from the PEG insertion point is important to prevent infection of the LVAD driveline and also to prevent inadvertent injury of the driveline during trocar insertion. Overall, our experience suggests that PEG placement is a feasible and safe procedure in patients with implanted LVAD.

**Competing interests** None declared.

**Ethics approval** Advocate Christ IRB.

**Provenance and peer review** Not commissioned; externally peer reviewed.

## REFERENCES

- 1 Montgomery TD, Cohen, AE, Garnick J, *et al*. Nutrition assessment, care, and considerations of ventricular assist device patients. *Nutr Clin Pract* 2012;27:352–62.
- 2 Vega JD, Poindexter SM, Radovancevic B, *et al*. Nutritional assessment of patients with extended left ventricular assist device support. *ASAIO Trans* 1990;36:M555–8.
- 3 Holdy K, Dembitsky W, Eaton LL. Nutrition assessment and management of left ventricular assist device patients. *J Heart Lung Transplant* 2005;24:1690–6.
- 4 Engleman DT, Adams DH, Byrne JG, *et al*. Impact of body mass index and albumin on morbidity and mortality after cardiac surgery. *J Thorac Cardiovasc Surg* 1999;118:866–73.
- 5 Suarez J, Patel CB, Felker GM, *et al*. Mechanisms of bleeding and approach to patients with axial-flow left ventricular assist devices. *Circ Heart Fail* 2011;4:779–84.
- 6 Slaughter MS, Pagani FD, Rogers JG, *et al*, HeartMate II Clinical Investigators. Clinical management of continuous-flow left ventricular assist

- devices in advanced heart failure. *J Heart Lung Transplant* 2010;29(Suppl): S1–39.
- 7 Slaughter MS, Rogers JG, Milano CA, *et al.*, HeartMate II Investigators. Advanced heart failure treated with continuous-flow left ventricular assist device. *N Engl J Med* 2009;361:2241–51.
  - 8 Miller LW, Pagani FD, Russell SD, *et al.* Use of a continuous-flow device in patients awaiting heart transplantation. *N Engl J Med* 2007;357:885–96.
  - 9 Pagani FD, Miller LW, Russell SD, *et al.* Extended mechanical circulatory support with a continuous-flow rotary left ventricular assist device. *J Am Coll Cardiol* 2009;54:312–21.
  - 10 Boyle AJ, Russell SD, Teuteberg JJ, *et al.* Low thromboembolism and pump thrombosis with the HeartMate II left ventricular assist device: analysis of outpatient anti-coagulation. *J Heart Lung Transplant* 2009;28:881–7.
  - 11 Slaughter MS, Pappas P, Tatroles A. Percutaneous endoscopic gastrostomy tube in a patient with a left ventricular assist device. *ASAIO J* 2003;49:611–12.
  - 12 Simmons DT, Daly RC, Baron TH. Direct percutaneous endoscopic jejunostomy placement in a patient with intracorporeal left ventricular assist device. *ASAIO J* 2006;52:115–16.
  - 13 Page S, Cecere R, Valenti D. Percutaneous gastrojejunostomy placement in a heart failure patient with biventricular assist devices. *JPEN J Parenter Enteral Nutr* 2009;33:721–3.
  - 14 Taylor CA, Larson DE, Ballard DJ, *et al.* Predictors of outcome after percutaneous endoscopic gastrostomy: a community-based study. *Mayo Clin Proc* 1992;67:1042.
  - 15 Larson DE, Burton DD, Schroeder KW, *et al.* Percutaneous endoscopic gastrostomy. Indications, success, complications, and mortality in 314 consecutive patients. *Gastroenterology* 1987;93:48.
  - 16 Blomberg J, Lagergren J, Martin L, *et al.* Complications after percutaneous endoscopic gastrostomy in a prospective study. *Scand J Gastroenterol* 2012;47:737–42.
  - 17 Keung EZ, Liu X, Nuzhad A, *et al.* In-hospital and long-term outcomes after percutaneous endoscopic gastrostomy in patients with malignancy. *J Am Coll Surg* 2012;215:777–86.

## **Erratum: *Safety of percutaneous endoscopic gastrostomy tube placement in patients with continuous-flow ventricular assist devices***

---

Keshmiri H, Yousuf T, Issa R, *et al.* Safety of percutaneous endoscopic gastrostomy tube placement in patients with continuous-flow ventricular assist devices. *Journal of Investigative Medicine*. doi: 10.1136/jim-2016-000124

The author's name Roeglio Silva has been published incorrectly. It should read Rogelio Silva.

*J Investig Med* 2016;**64**:1147. doi:10.1136/jim-2016-000124corr1



CrossMark