

Resolution of abnormal cardiac MRI T2 signal following immune suppression for cardiac sarcoidosis

Elliott D Crouser, Emily Ruden, Mark W Julian, Subha V Raman

Department of Internal Medicine, The Ohio State University, Columbus, Ohio, USA

Correspondence to
Dr Elliott D Crouser, Department of Internal Medicine, The Ohio State University, Columbus, OH 43210, USA; elliott.crouser@osumc.edu

EDC and ER contributed equally to the manuscript.

This case series was presented in abstract form at the American Thoracic Society International Conference in San Francisco, CA on May 17, 2016.

Accepted 3 June 2016
Published Online First 27 June 2016

Copyright © 2016 American Federation for Medical Research

ABSTRACT

Cardiac MR (CMR) with late gadolinium enhancement is commonly used to detect cardiac damage in the setting of cardiac sarcoidosis. The addition of T2 mapping to CMR was recently shown to enhance cardiac sarcoidosis detection and correlates with increased cardiac arrhythmia risk. This study was conducted to determine if CMR T2 abnormalities and related arrhythmias are reversible following immune suppression therapy. A retrospective study of subjects with cardiac sarcoidosis with abnormal T2 signal on baseline CMR and a follow-up CMR study at least 4 months later was conducted at The Ohio State University from 2011 to 2015. Immune suppression treated participants had a significant reduction in peak myocardial T2 value (70.0 ± 5.5 vs 59.2 ± 6.1 ms, pretreatment vs post-treatment; $p=0.017$), and 83% of immune suppression treated subjects had objective improvement in cardiac arrhythmias. Two subjects who had received inadequate immune

suppression treatment experienced progression of cardiac sarcoidosis. This report indicates that abnormal CMR T2 signal represents an acute inflammatory manifestation of cardiac sarcoidosis that is potentially reversible with adequate immune suppression therapy.

INTRODUCTION

Cardiac sarcoidosis (CS) is the second leading cause of sarcoidosis-related mortality, and the rate of CS-related death appears to be rising.¹ Reliance on patient-reported symptoms and screening ECG to initiate testing for CS is an inadequate strategy, as many cases of CS are undetected and sudden cardiac death may be the presenting clinical manifestation.²⁻³ Recent advances in imaging technology, such as cardiac MR (CMR) and positron emission tomography scan, markedly improve the detection of CS, but the implications of improved detection are

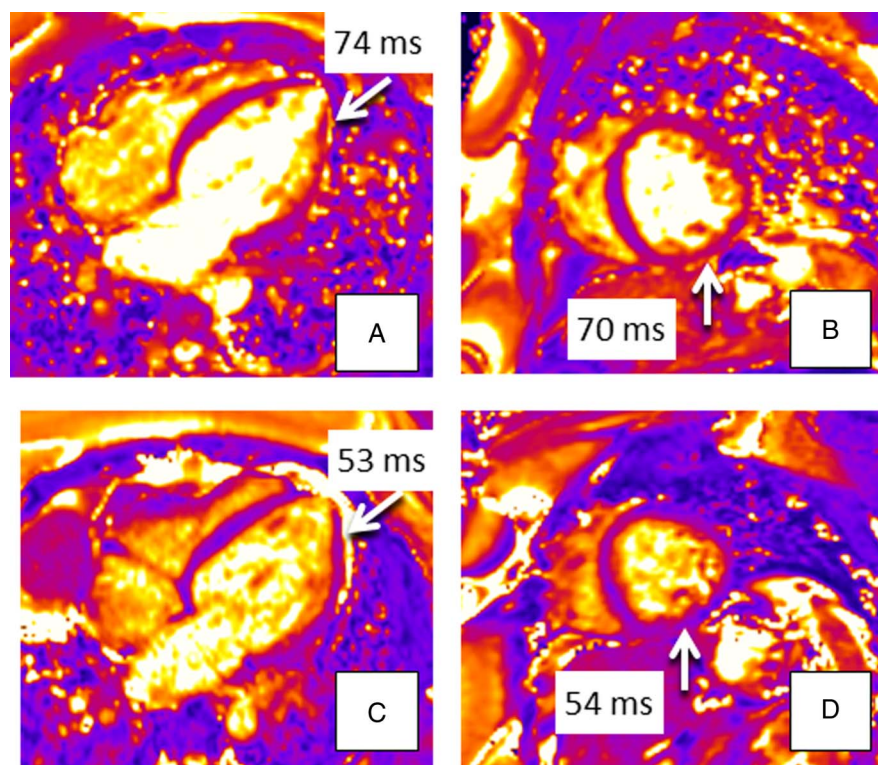


Figure 1 Comparison of pretreatment horizontal long axis (HLA) (A) and mid short axis (SAX) (B) and post-IS treatment HLA (C) and mid SAX (D) T2 maps for a patient receiving adequate immune suppression. IS, immune suppression.



To cite: Crouser ED, Ruden E, Julian MW, et al. *J Investig Med* 2016;**64**:1148–1150.

unclear. CMR is unique in that it is capable of discriminating injured myocardium, as detected by late gadolinium enhancement (LGE), from inflamed and presumably viable cardiac tissue, manifesting as increased T2 signal intensity. Just as increased T2 in patients presenting with acute myocarditis has been used to identify acutely inflamed myocardium,⁴ it follows that increased T2 in the myocardium of patients with sarcoidosis may represent CS-related inflammation that is responsive to immune suppression (IS) therapy. Thus, we sought to determine if IS therapy results in reversal of CMR T2 abnormalities and improved cardiac function in patients with CS.

MATERIALS AND METHODS

With local IRB approval, we conducted a retrospective analysis of a CMR database between January 2011 and September 2015 to identify consecutive cases fulfilling the following criteria: CS diagnosis based on current consensus criteria,⁵ presence of abnormal CMR T2 signal (≥ 60 ms⁶), and availability of two consecutive CMR studies. Patients with non-MR compatible implantable cardioverter defibrillators (ICDs) or pacemakers, representing a majority of the cases in the CMR database, do not undergo serial CMR at our institution and were excluded from this analysis. All CMR studies were conducted on a 1.5 T scanner (Avanto, Siemens Healthcare). The following images were obtained: (1) precontrast myocardial single-shot balanced steady state-free progression (SSFP) sequence T2 maps in long and short axis planes (3 images in each plane) according to previously published methods,⁶ (2) LGE imaging in long and short axis planes and (3) standard cine imaging to compute left ventricular volumes and ejection fraction (LVEF). T2 maps were interpreted on standard workstations (Leonardo, Siemens). The source images for each T2 map were reviewed first to evaluate for motion and to determine suitability for map interpretation. For each T2 map, the LV myocardium was divided into equal segments using the standard 17-segment model. Within each segment, multiple regions of interest were drawn with an estimated average sample size of 10-20 pixels. Abnormal segments were corroborated in short axis and long axis views in all patients. Average and peak myocardial T2 values for each segment, with normal T2 values defined as < 60 ms,⁶ and presence or absence of myocardial injury by LGE were recorded. Available clinical information relating to subjective cardiac symptoms, including palpitations, near-syncope or syncope and objective detection of arrhythmias were recorded at the time of the baseline and follow-up CMR studies.

RESULTS

The effects of IS treatment on serial CMR findings were dramatic (figure 1). As shown in table 1, six of the eight patients received sustained and adequate IS treatment (a minimum of 4.8 months duration; and at least 20 mg prednisone every other day \pm methotrexate 10–15 mg/week) following the initial CMR, which was associated with a significant reduction in the peak myocardial T2 value (70.0 ± 5.5 vs 59.2 ± 6.1 ms, pretreatment vs post-treatment; $p=0.017$). Five of the six IS-treated patients had complete resolution of T2 abnormalities, including regional and global T2 values, and there was no significant progression

Table 1 Characteristics of study population

Age (years)	Gender (M/F)	Extracardiac involvement	Pre and post scan interval (months)	IS Treatment	Pre-EF (%)	Post-EF (%)	Pre-peak T2 (ms)*	Post-peak T2 (ms)	Pre-Avg T2 (ms)	Post-Avg T2 (ms)	Pre-LGE (number of segments)	Post-LGE (number of segments)	Interval cardiac status
54	F	Lung	7.7	+	68	67	56	56	51	52	6	7	Resolved SVT, NSVT
41	F	Lung	14.9	+	29	35	54	54	62	49	1	0	Resolved palpitations
45	M	Lung	10.3	+	50	55	59	59	57	54	2	3	Resolved near syncope, 80% \downarrow PVCs
41	M	Lung, LN, skin	6.0	+	54	52	56	56	57	49	7	7	Resolved LBBB
60	F	LN, spleen	4.8	+	70	69	59	59	56	52	9	10	Resolved palpitations, 65% \downarrow PVCs
58	M	Lung, eye	28.9	+	82	67	17	17	55	56	7	6	Resolved palpitations and NSVT
52	F	Lung	18	-	50	35	-	-	-	-	1	4	Near syncope, ICD placement
28	M	Lung, LN	5.6	Low dose	58	59	80	80	58	58	5	5	Stable PVCs

*T2 values above 59 ms are abnormal.

EF, ejection fraction; ICD, implantable cardioverter defibrillator; IS, immune suppression; LBBB, left bundle branch block; LGE, late gadolinium enhancement; LN, lymph nodes; NSVT, non-sustained ventricular tachycardia; PVC, premature ventricular contraction; SVT, supraventricular ventricular tachycardia.

of LGE in this group. All six of the patients receiving adequate IS treatment experienced improvement in clinical cardiac parameters; five of six had subjective improvement of palpitations or near syncope and five of six had objective improvement of cardiac arrhythmias. One patient presented with asymptomatic left bundle branch block (LBBB) which resolved after IS treatment. Two of six IS-treated CS subjects had >5% improvement in LVEF; whereas the remaining four in the IS treatment group had no significant change in LVEF. One patient received low-dose IS treatment (prednisone 10 mg every other day, a dose previously shown to be associated with CS progression⁷), and demonstrated no change in T2, LGE or LVEF. One patient received no IS and was noted to have progression of LGE and a 15% reduction in LVEF over a period of 18 months complicated by an episode of syncope, and leading to placement of an ICD.

DISCUSSION

This case series demonstrates the effectiveness of CMR with T2 mapping to detect and quantify active CS and to guide IS therapy. Although the diagnostic utility of T2 mapping for the detection of myocardial edema has been well-established in patients with myocarditis and other inflammatory cardiomyopathies, the literature is sparse with respect to the use of T2 mapping or T2-weighted imaging to evaluate changes in myocardial inflammation in systemic inflammatory or autoimmune disorders.^{8–9} To the best of our knowledge, this is the first study to utilize T2 mapping in this capacity in patients with CS. A similar observation was recently reported in one patient with anti-synthetase syndrome, whereby myocardial edema as detected by T2 mapping resolved following oral corticosteroid therapy.¹⁰

The potential implications of reversible T2 changes in response to IS treatment in CS are significant. The presence of myocardial CMR T2 abnormalities is associated with more adverse cardiac events, as reflected by significant arrhythmias¹¹ and related symptoms, and adequate IS treatment is shown here to improve subjective and objective manifestations of cardiac arrhythmias in conjunction with resolution of T2 abnormalities. Furthermore, normalization of LVEF during IS treatment has implications for reducing the risk of sudden cardiac death and the need for ICD placement.³ The commitment to place an ICD is not without risk: in addition to being costly, ICDs are associated with significant complications, including inappropriate defibrillation events, displacement or fracture of intra-cardiac leads, or development of severe infections.¹²

Limitations of our study include its small sample size and retrospective design. Treatment by the clinician was neither standardized nor mandated by imaging findings, thus there was some heterogeneity in therapeutic management.

Additionally, follow-up imaging was performed at varying intervals following IS therapy. These factors may have impacted the degree to which myocardial tissue changes occurred, thereby potentially limiting comparisons made between subjects.

Further study is needed to determine if CMR is useful for predicting the risk of serious adverse cardiac events (eg, sudden cardiac death) and for guiding ICD placement.

Contributors EDC contributed to study design, data acquisition, data interpretation and revision of the work for important intellectual content. ER contributed to study design, data acquisition, data analysis and interpretation, and creating an original draft of the work. MWJ contributed to data interpretation, and revision of the work for important intellectual content. SVR contributed to study design, data interpretation, and revision of the work for important intellectual content.

Competing interests SVR receives institutional research support from Siemens.

Ethics approval The Ohio State University Institutional Review Board.

Provenance and peer review Not commissioned; externally peer reviewed.

Data sharing statement Additional data relating to this study is retained in a cardiac sarcoidosis registry. Access to the data is limited to those who have IRB approval to access the data through The Ohio State University's IRB.

REFERENCES

- Swigris JJ, Olson AL, Huie TJ, *et al.* Sarcoidosis-related mortality in the United States from 1988 to 2007. *Am J Respir Crit Care Med* 2011;183:1524–30.
- Rosenthal DG, Bravo PE, Patton KK, *et al.* Management of arrhythmias in cardiac sarcoidosis. *Clin Cardiol* 2015;38:635–40.
- Zipse MM, Sauer WH. Cardiac sarcoidosis and consequent arrhythmias. *Card Electrophysiol Clin* 2015;7:235–49.
- Wassmuth R, Schultz-Menger J. Cardiovascular magnetic resonance imaging of myocardial inflammation. *Expert Rev Cardiovasc Ther* 2011;9:1193–201.
- Birnie DH, Sauer W, Bogun F, *et al.* Heart Rhythm Society expert consensus statement on the diagnosis and management of arrhythmias associated with cardiac sarcoidosis. *Heart Rhythm* 2014;11:1–24.
- Thavendiranathan P, Walls M, Giri S, *et al.* Improved detection of myocardial involvement in acute inflammatory cardiomyopathies using t2 mapping. *Circ Cardiovasc Imaging* 2012;5:102–10.
- Nagai S, Yokomatsu T, Tanizawa K, *et al.* Treatment with methotrexate and low-dose corticosteroids in sarcoidosis patients with cardiac lesions. *Intern Med* 2014;53:427–33.
- Zhang Y, Corona-Villalobos CP, Kiani AN, *et al.* Myocardial T2 mapping by cardiovascular magnetic resonance reveals subclinical myocardial inflammation in patients with systemic lupus erythematosus. *Int J Cardiovasc Imaging* 2015;31:389–97.
- Mavrogeni S, Bratis K, Markussis V, *et al.* The diagnostic role of cardiac magnetic resonance imaging in detecting myocardial inflammation in systemic lupus erythematosus. Differentiation from viral myocarditis. *Lupus* 2013;22:34–43.
- Sado DM, Kozor R, Corr L, *et al.* Global myocardial edema in antisynthetase syndrome detected by cardiovascular magnetic resonance mapping techniques. *Circulation* 2016;133:e25–26.
- Crouser ED, Ono C, Tran T, *et al.* Improved detection of cardiac sarcoidosis using magnetic resonance with myocardial T2 mapping. *Am J Respir Crit Care Med* 2014;189:109–12.
- Betensky BP, Tschabrunn CM, Zado ES, *et al.* Long-term follow-up of patients with cardiac sarcoidosis and implantable cardioverter-defibrillators. *Heart Rhythm* 2012;9:884–91.