

# Characterization of *PABPN1* expansion mutations in a large cohort of Mexican patients with oculopharyngeal muscular dystrophy (OPMD)

Marisa Cruz-Aguilar,<sup>1</sup> Caroline Guerrero-de Ferran,<sup>2</sup> Jose Luis Tovilla-Canales,<sup>2</sup> Angel Nava-Castañeda,<sup>2</sup> Juan C Zenteno<sup>1,3</sup>

► Additional material is published online only. To view please visit the journal online (<http://dx.doi.org/10.1136/jim-2016-000184>).

<sup>1</sup>Department of Genetics-Research Unit, Institute of Ophthalmology "Conde de Valenciana", Mexico City, Mexico

<sup>2</sup>Department of Oculoplastics, Institute of Ophthalmology "Conde de Valenciana", Mexico City, Mexico

<sup>3</sup>Faculty of Medicine, Department of Biochemistry, UNAM, Mexico City, Mexico

## Correspondence to

Dr Juan C Zenteno, Department of Genetics, Institute of Ophthalmology "Conde de Valenciana", Chimalpopoca 14, Col. Obrera, Cuauhtemoc, Mexico City 06800, Mexico; [jzenteno@institutodeoftalmologia.org](mailto:jzenteno@institutodeoftalmologia.org)

Accepted 26 November 2016  
Published Online First  
15 December 2016

Copyright © 2017 American Federation for Medical Research

## ABSTRACT

Oculopharyngeal muscular dystrophy (OPMD) is an autosomal-dominant, adult-onset disorder defined by blepharoptosis, dysphagia, and proximal muscle weakness. OPMD arises from heterozygous expansions of a trinucleotide (GCN) tract situated at the 5' region of the polyadenylate RNA binding protein 1 (*PABPN1*) gene. The frequency of a particular (GCN) expansion in a given population of patients with OPMD is largely influenced by the occurrence of founder mutations. Analysis of large groups of patients with OPMD from different ethnic origins will help to estimate the relative contribution of each expanded allele to the disease. The purpose of this study was to characterize the type of *PABPN1* expanded alleles in a large cohort of OPMD individuals from Mexico. Molecular analysis procedures included genomic DNA extraction from blood leukocytes in each patient followed by PCR amplification of *PABPN1* exon 1, and direct nucleotide sequencing of PCR products. A total of 102 patients with OPMD were included in the study. Expanded *PABPN1* gene alleles were demonstrated in all patients: 65% (66 out of 102) had a (GCN)15 expansion while the remaining 35% (36 out of 102) exhibited a (GCN)13 expansion. This is one of the largest series of molecularly confirmed patients with OPMD in a non-Caucasian population. Ethnic-specific differences in the prevalence of specific *PABPN1* expansions must be considered for genetic screening of patients with OPMD.

## INTRODUCTION

Blepharoptosis (ptosis of the upper eyelid) is an abnormally low-lying upper eyelid margin in primary gaze, causing narrowing of the palpebral opening and fissure and covering part of the eye.<sup>1</sup> Blepharoptosis can either be congenital or acquired, may affect one or both eyes, and may occur as an isolated sign or as an accompanying anomaly of a systemic disease. Oculopharyngeal muscular dystrophy (OPMD) is a distinct inherited, late-onset myopathy characterized by a clinical triad of progressive blepharoptosis, dysphagia (swallowing difficulties), and proximal limb weakness. The disease has substantial variations in incidence among different populations,

## Significance of this study

### What is already known about this subject?

- Oculopharyngeal muscular dystrophy (OPMD) is a disorder frequently diagnosed in patients with adult-onset ptosis.
- It is an inherited disease caused by short (GCN) expansions in the polyadenylate RNA binding protein 1 (*PABPN1*) gene.
- Prevalence of specific (GCN) expansions can vary among ethnic groups.

### What are the new findings?

- We describe one of the largest series of molecularly confirmed non-Caucasian patients with OPMD.
- All patients carried either a (GCN)15 or a (GCN)13 *PABPN1* expansion.
- Two independent founder effects most probably account for this expansion pattern.

### How might these results change the focus of research or clinical practice?

- Clinicians must be aware of OPMD as a common cause of adult-onset ptosis.
- Molecular testing offers a cheap and fast definitive OPMD diagnosis.
- Different OPMD genotypes are probably related to variability in disease course.

fluctuating from 1 in 1000 in Quebec to 1 in 200,000 in France.<sup>2–3</sup> Usually, the onset of symptoms occurs during the fourth or fifth decade of life and the vast majority of affected subjects report bilateral palpebral ptosis as the first noticed clinical manifestation.<sup>4–5</sup> In late stages of disease, extraocular muscles may also be involved. The disorder is transmitted as an autosomal-dominant and fully penetrant trait. OPMD belongs to the group of triplet expansion diseases and results from short expansions of a GCN repeat at the 5' end of polyadenylate RNA binding protein 1 (*PABPN1*), a gene situated at chromosome 14q11.1.9 and encoding



**To cite:** Cruz-Aguilar M, Guerrero-de Ferran C, Tovilla-Canales JL, et al. *J Investig Med* 2017;**65**:705–708.

poly(A) binding protein nuclear 1 protein.<sup>6</sup> Non-OPMD subjects exhibit a tract of 10 uninterrupted GCN triplets, (GCG)6(GCA)3(GCG), whereas individuals with the disease carry extended alleles ranging from 12 to 17 (GCN) triplets. Molecular analysis of *PABPN1* in patients with OPMD from various ethnicities has demonstrated that (GCG)9 (GCA)3(GCG) or (GCN)13 is the most common allele, followed in frequency by (GCG)10 (GCA)3(GCG) or (GCN)14 and (GCG)11(GCA)3 (GCG) or (GCN)15.<sup>7–11</sup> The frequency of a particular (GCN) expansion in a given OPMD ethnic group appears to be determined by the presence of a founder (ie, derived from a common ancestor) mutation, as has been demonstrated in several populations. Molecular confirmation of an expanded *PABPN1* (GCN) tract is currently considered a definitive diagnosis in patients with clinical suspicion of the disease. OPMD is a common cause of adult-onset blepharoptosis and should be suspected in patients with ptosis of onset by the fifth or sixth decade of life.<sup>12</sup>

In this work, we describe the results of *PABPN1* screening in a large cohort of OPMD subjects from Mexico. This is one of the largest series of molecularly confirmed patients with OPMD in a non-Caucasian population and our results indicate that two different *PABPN1* expansions account for the disease in this cohort of OPMD subjects.

## MATERIALS AND METHODS

### Subjects

Patients included in the study were evaluated between the years 2005 and 2014 at the Oculoplastic and Genetics Departments of the Institute of Ophthalmology ‘Conde de Valenciana’, Mexico City. The protocol was approved by the Institutional Ethics and Research Board. All patients had adult-onset ( $\geq 40$  years of age) bilateral blepharoptosis and all of them underwent ophthalmological examination by an oculoplastic and orbit surgery specialist, including measurement of palpebral fissure height, margin-reflex distance, function of the palpebral levator muscle, and evaluation of ocular movements. Ptosis was graded, considering the margin reflex distance, as minimal or mild (1–2 mm of drooping), moderate (3–4 mm), or severe ( $> 4$  mm).<sup>13</sup> A complete familial history was recorded in each patient. An extensive physical inspection was carried out by a clinical geneticist in order to identify additional anomalies as dysphagia and muscle weakness.

### Genetic screening of the *PABPN1* gene

Genomic DNA was isolated from blood leucocytes by means of the QIAmp DNA blood mini kit on a Qiacube automated system (Qiagen, Carlsbad, California, USA). A 245bp *PABPN1* region (exon 1) encompassing the OPMD-related (GCN) triplet was PCR-amplified using oligonucleotides and conditions described elsewhere.<sup>14</sup> Direct Sanger sequencing of *PABPN1* amplicons was achieved using the BigDye Terminator Cycle Sequencing kit (Applied Biosystems, Foster City, California, USA). Samples were run in either a 310 or a 3130 Genetic Analyzer (Applied Biosystems) and sequence traces were manually examined.

## RESULTS

A total of 102 subjects were included in the study. All of them had moderate or severe ( $> 3$  mm) bilateral

blepharoptosis with onset after the age of 40 years accompanied by progressive dysphagia in 91% (93 out of 102) of individuals and limb weakness in 60% (61 out of 102) of them.

All patients were Mexican Mestizos and arose mainly from the central area of the country. Mexican Mestizos are individuals who were born in Mexico and whose last two ascending generations were also born in the country. No history of ancestor immigration from other countries was documented in any case. From the group of patients, 74% reported at least one relative with OPMD while 26% were apparently unique cases within their respective families. Table 1 summarizes molecular findings in the entire sample.

As shown, 65% (66 out of 102) of patients had a (GCN)15 expansion while the remaining 35% (36 out of 102) harbored a (GCN)13 expansion. Representative electropherogram traces from a (GCN)15 DNA and from a (GCN)13 DNA are shown in figure 1. The group with identified expansions consisted of 83 index cases and of 19 subjects who were relatives from several of such probands. The age at first evaluation of patients with (GCN)15 expansions ranged between 43 and 79 years (mean 55.8 years) while the age at evaluation of patients with a (GCN)13 allele was 42–82 years (mean 62.3 years). Differences at ages of evaluations were significantly different between the groups by t-test ( $p=0.003459$ ). There were 47 women and 19 men in the (GCN)15 group and 21 women and 15 men in the (GCN)13 group. In all patients with confirmed *PABPN1* mutation, the expansion occurred in a heterozygous state, with (GCN)10 being the normal allele in all instances.

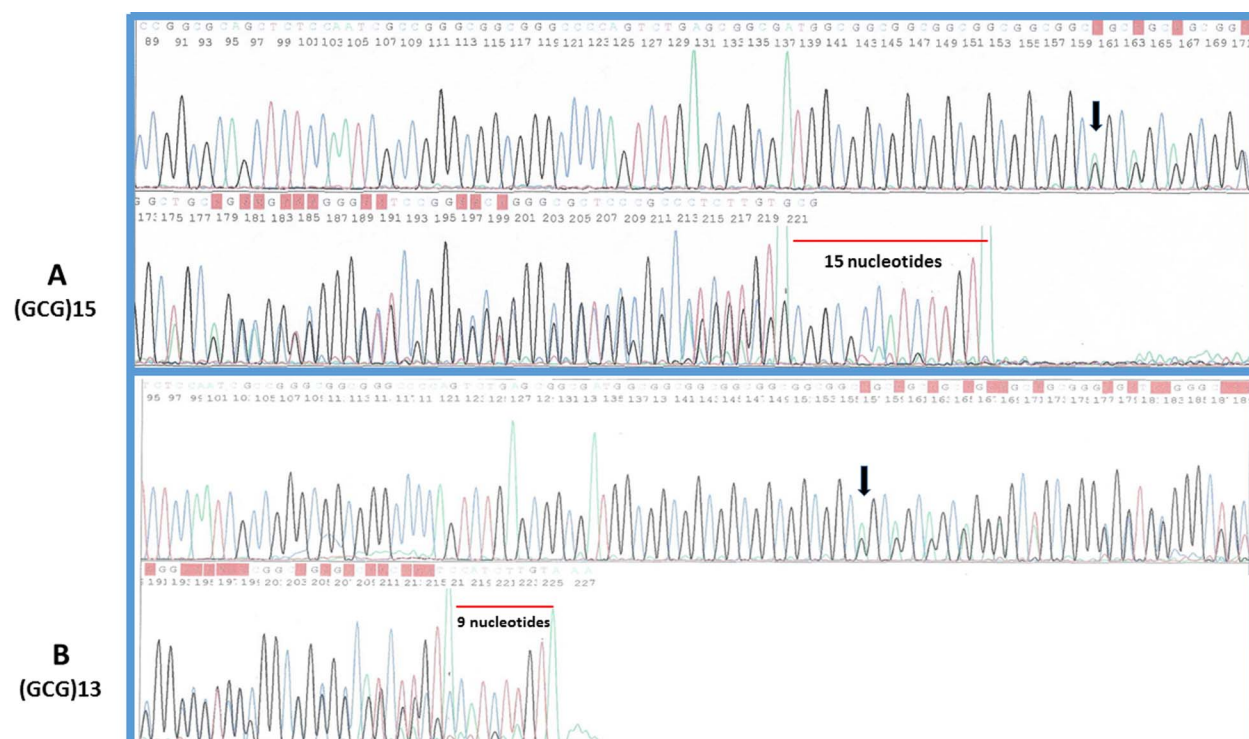
## DISCUSSION

Adult-onset blepharoptosis can be related to a number of pathological entities and it can arise from myogenic, neurogenic, mechanical, or traumatic causes. Myogenic blepharoptosis can be observed as an initial pathological sign in a number of genetic diseases and it presents with a weak or absent upper eyelid crease, poor levator function, and eyelid lag on downgaze.<sup>15</sup> A well-known cause of myogenic ptosis is OPMD, an autosomal-dominant condition which typically initiates during the fourth or fifth decade of life and also features dysphagia and proximal limb muscle weakness. In OPMD, eyelid ptosis results from weakness of

**Table 1** *PABPN1* (GCN) expansions and ages at evaluation in a cohort of Mexican patients with OPMD

Subjects with <i>PABPN1</i> expansions	n=102
(GCN)15	n=66 (65%)
Females	n=47
Males	n=19
(GCN)13	n=36 (35%)
Females	n=21
Males	n=15
Mean ages at first evaluation (years)	
(GCN)15	55.8
(GCN)13	62.3

OPMD, oculopharyngeal muscular dystrophy; *PABPN1*, polyadenylate RNA binding protein 1.



**Figure 1** Direct DNA sequencing of the PABPN1 gene OPMD. Heterozygosity for the (GCG)*N* expansion allows the recognition of additional nucleotides at the end of the amplicon (red bars). Note that (GCN)15 expansions are characterized by an additional tract of 15 nucleotides in the PCR amplicon (A), while (GCN)13 expansions exhibit a tract of 9 nucleotides at the end of the amplicon (B). Black arrows point to the site of the heterozygous expansions indicated by the overlapping pattern of peaks. OPMD, oculopharyngeal muscular dystrophy; PABPN1, polyadenylate RNA binding protein 1.

the levator palpebrae muscle while dysphagia is secondary to weakness of pharyngeal muscles. Additional symptoms in OPMD comprise an inexpressive face, weakness of the neck muscles, palatal weakness, dysarthria, gait disturbances, and hyper-reflexia.<sup>3</sup> The disease is caused by an expansion of a GCN tract at the 5' region of the *PABPN1* gene. The abnormal repeat originates the expansion of a tract of alanines located at the amino-terminal end of PABPN1 (see online supplementary figure), a protein with a role in polyadenylation of messenger RNAs.<sup>16</sup> Other human diseases caused by polyaniline expansions includes synpolydactyly,<sup>17</sup> cleidocranial dysplasia,<sup>18</sup> congenital central hypoventilation syndrome,<sup>19</sup> X linked mental retardation and epilepsy,<sup>20</sup> and blepharophimosis/ptosis/epicanthus inversus syndrome type II.<sup>21</sup> In these disorders, the polyaniline expansions result from an unequal allelic homologous meiotic and/or mitotic recombination, which in turn originates mutant proteins that form aggregates.<sup>22</sup> In OPMD, cellular effects caused by aggregation of expanded PABPN1 protein are not fully understood, but it is suggested that as in other late-onset neurodegenerative disorders, protein aggregation and accumulation caused by repeat expansion of a single amino acid are toxic.<sup>23</sup> A possible mechanism by which nuclear aggregates could produce muscle pathology is the inability of mutant PABPN1 to interact with critical transcripts or protein partners essential for muscle cell function.<sup>24</sup>

In this work, the results of genetic screening of *PABPN1* in a cohort of 102 patients with OPMD from Mexico are presented. In our series, (GCN)15 was the most prevalent

expanded allele (65%) followed by the (GCN)13 allele (35%). These results differ from data in other OPMD populations where (GCN)13 is the most common pathogenic allele,<sup>6, 8, 25</sup> but are in agreement with a previous report from Mexican patients with OPMD showing independent founder effects for (GCN)15 and (GCN)13 expansions.<sup>14</sup> Although the predominance of a specific (GCN) expansion in a particular OPMD ethnic group relies on the occurrence of a founder mutation in general,<sup>25–27</sup> the existence of several independent founder effects producing different expanded alleles in the same ethnic group has also been demonstrated.<sup>14, 28–30</sup>

Contrasting with other trinucleotide-related disorders in which longer repeats characteristically result in a more severe or earlier onset of disease, OPMD has not been conclusively demonstrated to be clinically distinct in subjects with larger *PABPN1* expansions. Owing to the subtle start of acquired blepharoptosis, the actual age of onset of this sign could not be noticed precisely in our group of patients and this is a limitation of the present work. However, mean ages for (GCN)15 and (GCN)13 *PABPN1* allele carriers were very different (55.8 vs 62.3 years;  $p < 0.5$ , by t-test), suggesting that patients with (GCN)15 expansions have a worse course of the disease and look for medical help earlier than (GCN)13 carriers.

Molecular analysis of *PABPN1* constitutes an efficient, rapid and cheap test for diagnosing OPMD and differentiating it from other adult-onset causes of ptosis as chronic progressive external ophthalmoplegia or other mitochondrial DNA disorders. In patients with adult-onset

blepharoptosis, a positive genetic test confirming OPMD can avoid additional invasive tests such as muscle biopsy, electromyography, edrophonium or chloride (Tensilon) tests, or more complex genetic analyses such as mitochondrial DNA mutation tests.

In summary, this is one of the largest series of molecularly confirmed patients with OPMD in a non-Caucasian population. Genetic screening of additional cohorts of OPMD subjects from diverse ethnicities will be required to establish the relative frequency of particular *PABPN1* expansions causing OPMD.

**Competing interests** None declared.

**Ethics approval** Institutional Review Board on Ethics 'Conde de Valenciana'.

**Provenance and peer review** Not commissioned; externally peer reviewed.

## REFERENCES

- Finsterer J. Ptosis: causes, presentation, and management. *Aesthetic Plast Surg* 2003;27:193–204.
- Blumen SC, Nisipeanu P, Sadeh M, *et al.* Epidemiology and inheritance of oculopharyngeal muscular dystrophy in Israel. *Neuromuscul Disord* 1997;7 (Suppl 1):S38–40.
- Brais B. Oculopharyngeal muscular dystrophy: a late-onset polyalanine disease. *Cytogenet Genome Res* 2003;100:252–60.
- Brais B. Oculopharyngeal muscular dystrophy. *Handb Clin Neurol* 2011;101:181–92.
- Witting N, Mensah A, Køber L, *et al.* Ocular, bulbar, limb, and cardiopulmonary involvement in oculopharyngeal muscular dystrophy. *Acta Neurol Scand* 2014;130:125–30.
- Brais B, Bouchard JP, Xie YG, *et al.* Short GCG expansions in the PABP2 gene cause oculopharyngeal muscular dystrophy. *Nat Genet* 1998;18:164–7.
- Mirabella M, Silvestri G, de Rosa G, *et al.* GCG genetic expansions in Italian patients with oculopharyngeal muscular dystrophy. *Neurology* 2000;54:608–14.
- Hill ME, Creed GA, McMullan TF, *et al.* Oculopharyngeal muscular dystrophy: phenotypic and genotypic studies in a UK population. *Brain* 2001;124:522–6.
- Müller T, Schröder R, Zierz S. GCG repeats and phenotype in oculopharyngeal muscular dystrophy. *Muscle Nerve* 2001;24:120–2.
- Robinson DO, Hammans SR, Read SP, *et al.* Oculopharyngeal muscular dystrophy (OPMD): analysis of the PABPN1 gene expansion sequence in 86 patients reveals 13 different expansion types and further evidence for unequal recombination as the mutational mechanism. *Hum Genet* 2005;116:267–71.
- Tondo M, Gámez J, Gutiérrez-Rivas E, *et al.* Genotype and phenotype study of 34 Spanish patients diagnosed with oculopharyngeal muscular dystrophy. *J Neurol* 2012;259:1546–52.
- Wong VA, Beckingsale PS, Oley CA, *et al.* Management of myogenic ptosis. *Ophthalmology* 2002;109:1023–31.
- Kan ND, Weinberg DA. Myogenic ptosis. In: Cohen AJ, Weinberg DA, eds. *Evaluation and management of blepharoptosis*. Springer, 2010:79–106.
- Rivera D, Mejia-Lopez H, Pompa-Mera EN, *et al.* Two different PABPN1 expanded alleles in a Mexican population with oculopharyngeal muscular dystrophy arising from independent founder effects. *Br J Ophthalmol* 2008;92:998–1002.
- Lim JM, Hou JH, Singa RM, *et al.* Relative incidence of blepharoptosis subtypes in an oculoplastics practice at a tertiary care center. *Orbit* 2013;32:231–4.
- Banerjee A, Apponi LH, Pavlath GK, *et al.* PABPN1: molecular function and muscle disease. *FEBS J* 2013;280:4230–50.
- Goodman FR, Mundlos S, Muragaki Y, *et al.* Synpolydactyly phenotypes correlate with size of expansions in HOXD13 polyalanine tract. *Proc Natl Acad Sci USA* 1997;94:7458–63.
- Mundlos S, Otto F, Mundlos C, *et al.* Mutations involving the transcription factor CBFA1 cause cleidocranial dysplasia. *Cell* 1997;89:773–9.
- Amiel J, Laudier B, Attié-Bitach T, *et al.* Polyalanine expansion and frameshift mutations of the paired-like homeobox gene PHOX2B in congenital central hypoventilation syndrome. *Nat Genet* 2003;33:459–61.
- Strømme P, Mangelsdorf ME, Shaw MA, *et al.* Mutations in the human ortholog of Aristaless cause X-linked mental retardation and epilepsy. *Nat Genet* 2002;30:441–5.
- Crisponi L, Deiana M, Loi A, *et al.* The putative forkhead transcription factor FOXL2 is mutated in blepharophimosis/ptosis/epicanthus inversus syndrome. *Nat Genet* 2001;27:159–66.
- Lavoie H, Debeane F, Trinh QD, *et al.* Polymorphism, shared functions and convergent evolution of genes with sequences coding for polyalanine domains. *Hum Mol Genet* 2003;12:2967–79.
- Bhattacharjee RB, Zannat T, Bag J. Expression of the polyalanine expansion mutant of nuclear poly(A)-binding protein induces apoptosis via the p53 pathway. *Cell Biol Int* 2012;36:697–704.
- Davies JE, Sarkar S, Rubinstein DC. Wild-type PABPN1 is anti-apoptotic and reduces toxicity of the oculopharyngeal muscular dystrophy mutation. *Hum Mol Genet* 2008;17:1097–108.
- Blumen SC, Korczyn AD, Lavoie H, *et al.* Oculopharyngeal MD among Bukhara Jews is due to a founder (GCG)<sup>9</sup> mutation in the PABP2 gene. *Neurology* 2000;55:1267–70.
- Rodríguez M, Camejo C, Bertoni B, *et al.* (GCG)<sup>11</sup> founder mutation in the PABPN1 gene of OPMD Uruguayan families. *Neuromuscul Disord* 2005;15:185–90.
- Blumen SC, Kesler A, Dabby R, *et al.* Oculopharyngeal muscular dystrophy among Bulgarian Jews: a new cluster? *Isr Med Assoc J* 2013;15:748–52.
- Scacheri PC, Garcia C, Hébert R, *et al.* Unique mutations in “Cajuns” suggest multiple founders of oculopharyngeal muscular dystrophy in populations with French ancestry. *Am J Med Genet* 1999;86:477–81.
- Müller T, Deschauer M, Kolbe-Fehr F, *et al.* Genetic heterogeneity in 30 German patients with oculopharyngeal muscular dystrophy. *J Neurol* 2006;253:892–5.
- Shan J, Chen B, Lin P, *et al.* Oculopharyngeal muscular dystrophy: phenotypic and genotypic studies in a Chinese population. *Neuromolecular Med* 2014;16:782–6.