

Intramyocardial block in patients with atrioventricular block

Guoliang Li,^{1,2} Ardan M Saguner,³ Deniz Akdis,³ Guy H Fontaine¹

¹Unité de Rythmologie, Institut de Cardiologie, Hôpital de la Salpêtrière, Paris, France

²Department of Cardiovascular Medicine, Xi'an Jiaotong University Medical College, Xi'an, Shaanxi, China

³Department of Cardiology, University Heart Center Zürich, Zürich, Switzerland

Correspondence to

Prof Guy H Fontaine, Unité de Rythmologie, Institut de Cardiologie, Hôpital de la Salpêtrière, Paris, France; guy.fontaine2@numericable.fr

GL and AMS contributed equally.

Accepted 4 February 2018
Published Online First 7 March 2018

ABSTRACT

Atrioventricular (AV) block has been extensively studied. However, conduction inside the myocardium in patients with AV block has not been reported. In this study, we aimed to demonstrate the presence of intramyocardial block in patients with AV block. Five consecutive patients with spontaneous high-grade AV block and Torsades de pointes (TdP) were prospectively studied with standard United States Catheter Instruments (USCI) endocardial temporary catheter located at the right ventricle (RV) apex. The morphology of endocardial potentials observed in the basic QRS complexes as well as during episodes of TdP was studied. The electrogram (EGM) of the basic rhythm showed a sharp deflection of high amplitude preceded and/or followed by a smooth potential of low amplitude interpreted as far-field potentials in all patients. The sharp potential can be observed at the beginning, in the middle or at the end of the smooth potential. All these potentials were reproduced from beat to beat and were falling inside the QRS complex of the surface ECG. Therefore, these aspects are zones of electrically depressed or silent myocardium larger than the interelectrode distance of 12 mm. This situation is in agreement with recent genetic factors. In this study, we demonstrated for the first time that patients with spontaneous AV block also have trouble in ventricular activation located on the AV conduction system and inside the myocardium. It is then possible to speculate that the presence of diffuse non-conducting myocardium explains why most TdPs do not degenerate into ventricular fibrillation (VF) and generally stop spontaneously.

“There is a thing which is difficult in Science which is to see something absolutely obvious”
GF 2017

INTRODUCTION

Atrioventricular (AV) blocks have been extensively studied.^{1–3} The best treatment is to accelerate the rhythm by ventricular stimulation by pacemakers.^{4,5} However, conduction inside the myocardium in patients with AV block has not been reported. Temporary cardiac stimulation in patients with spontaneous AV block and Torsades de pointes (TdP) provided the record of endocardial signals in AV block and during episodes of TdP. This work will demonstrate intramyocardial conduction blocks which could also explain why most TdPs do not degenerate into VF and are self-terminating.

Significance of this study

What is already known about this subject?

- ▶ The best treatment for Torsades de pointes (TdP) in the atrioventricular (AV) block is to accelerate the rhythm by pacemakers.
- ▶ During AV block, TdP is rare but can be fatal. Little is known about conduction inside the myocardium in patients with atrioventricular block (AVB).

What are the new findings?

- ▶ This study demonstrated for the first time that patients with spontaneous AV block also have trouble in ventricular activation on the AV conduction system and inside the myocardium.
- ▶ Sharp potentials demonstrate the presence of normal activation restricted to some fibers with the absence of activation of adjacent fibers suggesting a form of a silent zone of electrically depressed myocardium.
- ▶ It is then possible to speculate that the presence of diffuse non-conducting myocardium explains why most TdPs do not degenerate in ventricular fibrillation (VF) and generally stop spontaneously.

How might these results change the focus of research or clinical practice?

- ▶ Help people better understand the mechanisms underlying AVB-induced TdP.
- ▶ Promote the management of TdP in patients with AVB.

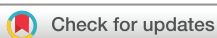MATERIAL AND METHODS

Study population

Five consecutive patients with high-grade AV block and TdP episodes were prospectively studied between 1964 and 1975 in the Department of Cardiology, Hôpital de la Salpêtrière, Paris, France. No ethical committee existed at that time, but the protocol was accepted by the chief of the department. Informed consent was obtained from each patient before starting the recordings of endocardial signals.

Study group

Five patients were eligible when they had short episodes of TdP (less than 5 s) and minor risk to degenerate into VF. These patients



To cite: Li G, Saguner AM, Akdis D, et al. *J Investig Med* 2018;**66**:912–915.

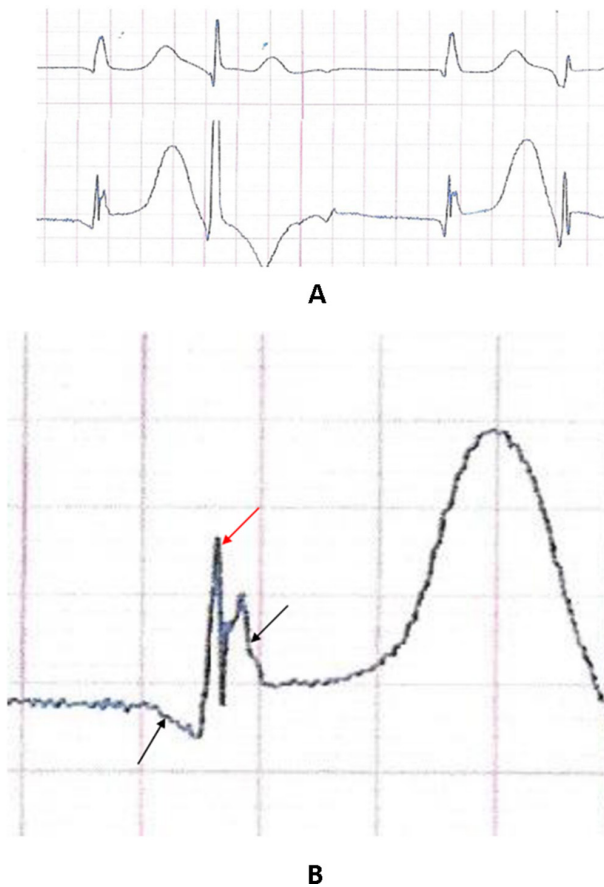


Figure 1 The upper tracing is a bipolar chest lead V1–V4 showing a 2:1 atrioventricular (AV) block with bigeminy (hiding the P wave). The lower tracing shows a sharp deflection falling inside the surface QRS complexes. Note that the PVCs are producing a larger ECG. The black arrows indicate the start of endocardial activation of the PVCs. All these potentials are reproducible from beat to beat. The lower tracings show the endocardial recordings in two patients in whom the sharp signal is observed inside a smooth potential at the beginning and at its end suggesting the activation of a strand of myocardial fibers surrounded by inert tissue which is able to transmit the activation of distal myocardium (far-field potentials). A color version of this figure is available in the online version.

were >65 years old; four women and one man. They had no structural heart disease, AV block was spontaneous, none was taking drugs known to prolong the QT interval. All of them were waiting for pacemaker implantation, replacement or repair at a time when these devices were not readily available.

Method

A temporary pacing system using a standard USCI bipolar catheter with electrodes 12 mm apart was positioned at the apex of the right ventricle. The catheter was disconnected from the external stimulator and connected to a recording apparatus. Here, we concentrate on the morphology of endocardial potentials observed on the basic QRS complexes in spontaneous high degree AV block.

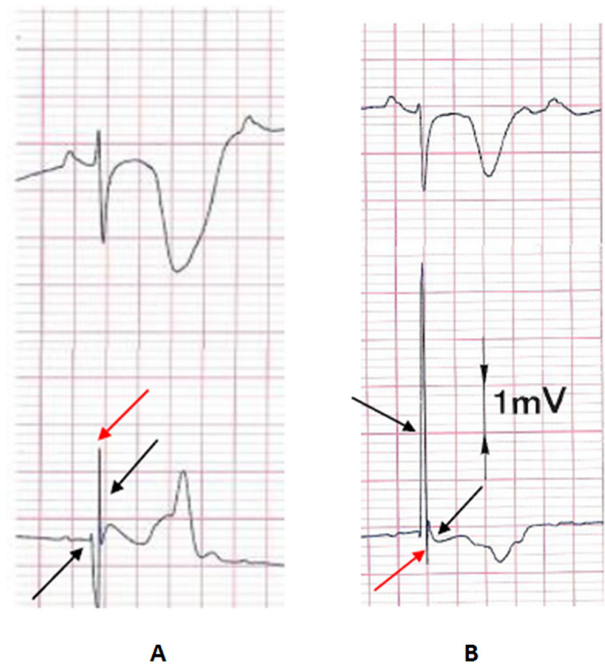


Figure 2 Tracings from two patients with atrioventricular (AV) blocks showing a sharp potential (duration around 20 ms) stressed by a red arrow and a smooth potential stressed by a black arrow. The same is true for the other figures when appropriate. A color version of this figure is available in the online version.

RESULTS

Morphology of endocardial signals varied from patient to patient leading to the description of several patterns:

Figure 1 shows ventricular bigeminy in complete AV block on the surface ECG. The ECG of the basic rhythm is enlarged on the lower panel of this figure. It shows a sharp deflection preceded and followed by a smooth potential of low amplitude. All these potentials are falling inside the QRS complex of the surface ECG. This aspect is reproducible from beat to beat. There is an ST segment elevation of 0.2 mV in the ECG. These images are displayed on two beats but were also stable from beat to beat on long recordings. Note that the ECGs during premature ventricular contractions (PVCs) do not show the same pattern.

The two patients in **figure 2** have a sharp potential occurring at the end of the ECG, the smooth potential is negative in the left ECG and the right ECG has a large positive smooth potential.

The patient in **figure 3** has a sharp negative potential occurring at the beginning of the ECG immediately after a smaller positive potential. However, the amplitude of the negative potential is smaller on beats 1 and 3 as compared with the other beats as opposed to the sharp positive initial potential which has a constant amplitude. The same distortion of the summit of the T wave is also visible on beats 1 and 3. There is a major ST segment elevation in all ECGs. Also, there is a progressive increase in phase IV of the ECG, identical from beat to beat.

A pure image (**figure 4**) of smooth far-field potential was recorded by a decapolar catheter with the two extremities' electrodes giving a composite tracing of both atrial and

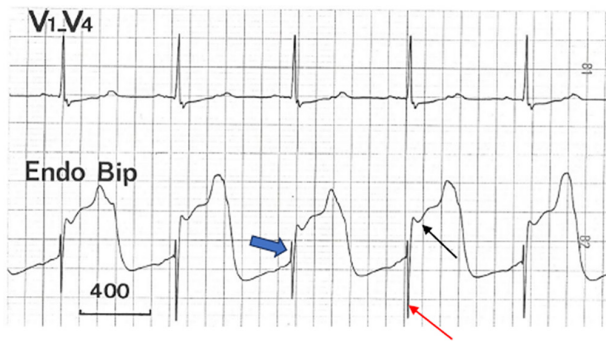


Figure 3 Surface tracing showing a 2:1 atrioventricular (AV) conduction block presented on the upper tracing (the blocked P wave is visible on the T waves). On the lower tracing, the endocardial signal shows a huge susdenivelation of the repolarization phase probably due to myocardial ischemia after long episodes of Torsades de pointes (TdP). The positive part of the sharp signal is constant in amplitude all over the five beats and can be considered as produced by the distal His-Purkinje system. This agrees with the progressive repolarization phase leading to activation of the myocardium when the critical diastolic threshold is attained. However, the negative part is smaller in beats 1 and 3 as compared with the other beats suggesting a Mobitz type 2 block in adjacent myocardial cells. A color version of this figure is available in the online version.

ventricular potentials. The PVC which can be considered as the first beat of an aborted TdP exhibits a smooth potential without a sharp deflection.

DISCUSSION

In all these patients it was possible to record the same pattern associating both sharp and smooth potentials on the

Silent zone on the first PVC before TdP

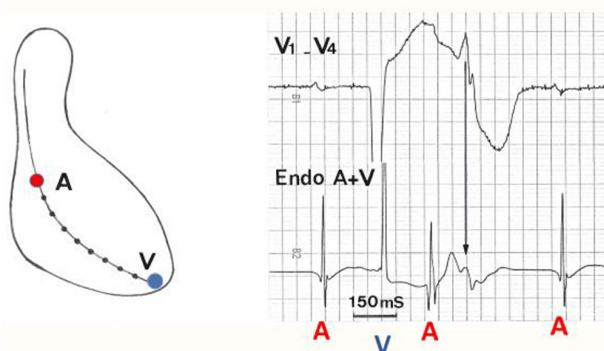


Figure 4 Smooth far-field potential recorded by a decapolar catheter with the two extremities' electrodes giving a composite tracing of both atrial and ventricular potentials. Therefore, the endocardial tracing is recording atrial and ventricular potentials (light gray letter 'A' and gray letter 'V') on the same line. The remarkable phenomenon is that PVC is producing only a smooth far-field potential of low amplitude. This represents a myocardial zone around the ventricular electrode, which is silent. Tdp, Torsades de pointes. A color version of this figure is available in the online version.

ECGs. However, because of its variable position the sharp potential represents a near-field potential that looks superimposed on a second smooth potential of low amplitude and of longer duration which represents a far-field potential. In all the cases these images are reproducible from beat to beat.

The sharp potential suggests the activation of strands of fibers located along the bipolar endocardial lead (near-field potential). The variable amplitude of the sharp potentials 1 and 3 on figure 3 shows the intermittent loss of activation of some strands of fibers. However, as all the sharp as well as smooth potentials remain inside the QRS complex duration on the surface ECG there is no delayed conduction or postexcitation phenomenon as in arrhythmogenic right ventricular dysplasia (ARVD) producing the ϵ wave.⁶ This is because in ARVD there is a structural disease with delayed conduction in strands of myocardium interspersed with fat and fibrosis as opposed to TdP in the AV block. The alternative is that the smooth potential represents far-field potentials detected because a significant zone of electrically inert myocardium is surrounding the bipolar recording system. In figure 2 right tracings, the high amplitude of both potentials represents a double near-field potential. This can be explained because a small band of inert myocardium is separating the two stands or normally activated myocardial fibers. Conversely, when the smooth potential is of small amplitude and long duration there is a large zone of inert myocardium.

The position of the sharp potential located at the beginning in the middle or at the end of the smooth potential indicates that the distribution of zones of electrically depressed myocardium is variable from patient to patient. The high amplitude of the 'smooth' potential presented in figure 2 can be explained by two activations of opposite directions in two adjacent isolated fibers. However, the large amplitude (5.5 mV) of the positive potential suggests normal myocardium and confirms the non-homogenous distribution of electrically depressed myocardium in the other patients. In addition, the sharp and smooth pattern of two different signals is not observed on the PVCs of figure 1 because the activation comes in a different direction which can be related to the orientation of myocardial fibers at the apex of the right ventricle. Minor and major ST segment elevation observed in two patients is probably the result of an injury current recorded shortly after insertion of the catheter (this was ascertained in the patient presented in figure 3). The progressive phase IV increase of the potential in figure 3 suggests recording of the activation of the distal His-Purkinje ramifications. This is in agreement with the positive sharp potential of stable amplitude located at the beginning of the endocardial signal which looks to be the activation of distal His-Purkinje ramifications. This phenomenon can be further demonstrated in detail when data of electrograms alternans in patients with ICDs are available.^{7,8}

Signals recorded during TdP show a spectrum of abnormal conduction with multiple sharp potentials reinforcing the weakness of myocardial activation which can occupy all the diastole and looks similar to VF. The behavior of the myocardium demonstrating abnormal myocardial activation has been understood recently on a genetic basis for the AV conduction system. The same concept can therefore

be extended to the behavior of the common myocardium. However, the extension of this concept to the totality of the heart is unknown; and this may explain why most episodes of TdP are self-terminating and the rare degenerescence into VF. To the best of our knowledge up to now nobody has explained the mechanism of these two features of TdP. Of note no early afterdepolarization (EAD) or similar signals have been recorded in this investigation.

LIMITATIONS

This study is based on a small number of patients; however, the ECG pattern is observed in 100% of this short series. The calibration of the endocardial signal can be ascertained only on one tracing (figure 2, right panel). We do not know if the same phenomenon is present in patients with common high-grade AV block without TdP. Presence of the same patterns in other parts of the heart such as left ventricle (LV) is highly probable because of the genetic basis of the AV conduction block, but is also unknown.

CONCLUSION

The mechanism of endocardial activation of the basic rhythm in patients with a high-degree AV block is now explainable. Sharp potentials demonstrate the presence of normal activation restricted to some fibers with the absence of activation of adjacent fibers suggesting a form of a silent zone of electrically depressed myocardium.

We demonstrate for the first time that patients with spontaneous AV block also have trouble in ventricular activation located on the AV conduction system and inside the myocardium with a reduction in the safety factor of propagation of activation. It is then possible to speculate that the presence of diffuse zones of electrically depressed myocardium explains why most episodes of TdP do not degenerate into VF or even VT and explain why TdPs are ending spontaneously with return to the basic rhythm.

Contributors All authors participated in the data analysis, manuscript preparation and review.

Funding This research received no specific grant from any funding agency in the public, commercial or not-for-profit sectors.

Competing interests None declared.

Patient consent Not required.

Provenance and peer review Not commissioned; externally peer reviewed.

© American Federation for Medical Research (unless otherwise stated in the text of the article) 2018. All rights reserved. No commercial use is permitted unless otherwise expressly granted.

REFERENCES

- 1 Roden DM. Clinical practice. Long-QT syndrome. *N Engl J Med* 2008;358:169–76.
- 2 Liu JF, Jons C, Moss AJ, *et al*. Risk factors for recurrent syncope and subsequent fatal or near-fatal events in children and adolescents with long QT syndrome. *J Am Coll Cardiol* 2011;57:941–50.
- 3 Kurita T, Ohe T, Marui N, *et al*. Bradycardia-induced abnormal QT prolongation in patients with complete atrioventricular block with torsades de pointes. *Am J Cardiol* 1992;69:628–33.
- 4 Epstein AE, DiMarco JP, Ellenbogen KA, *et al*. 2012 ACCF/AHA/HRS focused update incorporated into the ACCF/AHA/HRS 2008 guidelines for device-based therapy of cardiac rhythm abnormalities: a report of the American College of Cardiology Foundation/American Heart Association Task Force on Practice Guidelines and the Heart Rhythm Society. *Circulation* 2013;127:e283–352.
- 5 Epstein AE, DiMarco JP, Ellenbogen KA, *et al*. ACC/AHA/HRS 2008 Guidelines for Device-Based Therapy of Cardiac Rhythm Abnormalities: a report of the American College of Cardiology/American Heart Association Task Force on Practice Guidelines (Writing Committee to Revise the ACC/AHA/NASPE 2002 Guideline Update for Implantation of Cardiac Pacemakers and Antiarrhythmia Devices): developed in collaboration with the American Association for Thoracic Surgery and Society of Thoracic Surgeons. *Circulation* 2008;117:e350–408.
- 6 Fontaine GH, Duthoit G, Li G, *et al*. Epsilon wave on an electronic loop in a case of arrhythmogenic right ventricular dysplasia with myocarditis: an updated definition of the Epsilon wave. *Europace* 2017;19:1084–90.
- 7 Barold SS, Kucher A, de Meester A, *et al*. Alternans of the Ventricular Electrogram in Patients with an Implanted Cardioverter-Defibrillator. *Pacing Clin Electrophysiol* 2015;38:1470–80.
- 8 Van Heuverswyn FE, Timmers L, Stroobandt RX, *et al*. Undersensing by an ICD due to alternans of the ventricular electrogram. *Ann Noninvasive Electrocardiol* 2013;18:84–9.

Correction: *Intramyocardial block in patients with atrioventricular block*

Li G, Saguner AM, Akdis D, *et al.* Intramyocardial block in patients with atrioventricular block. *J Investig Med* 2018;**66**:912–15. doi:10.1136/jim-2017-000682.

The legend to figure 4 should read as follows:

Recording of an endocardial signal in a patient who had an abnormal QTU and a spontaneous extrasystole occurring at the end of the T wave, a precursor of TdP. The endocardial tracing is a composite tracing obtained from 2 distal electrodes (ventricular) in parallel with 2 proximal (atrial) electrodes of a decapolar (Electrodyne, USA) catheter with electrodes 1 cm apart. The atrial as well as the ventricular deflections are clearly seen on the lower tracing and could be related to the surface ECG. The most important point of this figure is to show that during the extrasystole there is no rapid deflection on the endocardial signal suggesting an electrically silent zone under the electrode bipolar recording system. This original figure is from Guy Fontaine's work (Fontaine G. A new look at Torsades de Pointes. *Annals of the New York Academy of Sciences* 1992;**644**:157–77).

© American Federation for Medical Research 2018. No commercial re-use. See rights and permissions. Published by BMJ.

J Investig Med ;**66**:1068. doi:10.1136/jim-2017-000682corr1

