

Gastrointestinal implications in COVID-19

Dushyant Singh Dahiya,¹ Asim Kichloo ,² Michael Albosta ,¹ Sukrut Pagad,³ Farah Wani⁴

¹Internal Medicine, Central Michigan University, Saginaw, Michigan, USA

²Department of Internal Medicine, CMU Medical Education Partners, Saginaw, Michigan, USA

³Department of Internal Medicine, Larkin Community Hospital Graduate Medical Education, South Miami, Florida, USA

⁴Department of Family Medicine, Samaritan Medical Center, Watertown, New York, USA

Correspondence to

Dr Asim Kichloo, CMU Medical Education Partners, Saginaw, MI 48602, USA; kichloosim@gmail.com

Accepted 8 September 2020
Published Online First
14 September 2020

ABSTRACT

Believed to have originated from a local Huanan Seafood Wholesale Market in Wuhan, Hubei Province in China, the COVID-19 has had an unprecedented and catastrophic impact on humanity, with the WHO declaring it a global pandemic. Although the first case of COVID-19 was reported in December 2019, the primary source and intermediate host have not been confirmed, but human-to-human transmission has been universally accepted. The main mode of transmission of the virus is through respiratory droplets along with prominent respiratory system involvement. However, fecal-oral transmission due to the shedding of the virus in the gastrointestinal (GI) tract may continue for up to 10 weeks after respiratory clearance and is fast becoming important. SARS-CoV-2 shows a high affinity to ACE2 receptors, making sites of high ACE2 receptor expression, such as lungs, GI tract, brain, kidneys, heart, liver and immune system, a prime target for infection. Through this literature review, we aim to summarize the current knowledge of immunological pathways that contribute to the disease with a focus specifically on the GI tract involvement. We direct attention to the pathophysiological mechanism of involvement of the GI tract leading to symptomatic manifestations, track GI organ-specific viral loads to compare and contrast with other organ systems. We briefly detail specific treatment strategies from a GI disease standpoint and mention special considerations when there is involvement of the GI tract.

INTRODUCTION

With the rapid emergence and spread of the SARS-CoV-2 and the resultant COVID-19, scientists around the world have focused their efforts on understanding pathophysiology, transmission and immunology of the disease. SARS-CoV-2 belongs to the Coronaviridae family of viruses, which is further subdivided into Coronavirinae and Torovirinae subfamilies. Coronaviruses are large, enveloped, non-segmented, single-stranded, positive-sense RNA viruses about 26–32 kb in length.¹ They have mainly been identified in zoonotic hosts, that is, birds, camels, bats, masked palm civets, mice, dogs, and cats.^{1,2} However, about 7 strains of the coronavirus are pathogenic to humans, with most leading to mild symptoms. Exceptions to this are the case of the SARS coronavirus, which emerged in November 2002 in Guangdong, southern China, resulting in 744 deaths

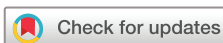and the Middle East respiratory syndrome coronavirus, first detected in Saudi Arabia in 2012 leading to 858 deaths.³ It is believed that SARS-CoV-2 causing COVID-19 originated from a zoonotic spillover, resulting in human infections and eventual human-to-human transmission through respiratory droplets. Clinical symptoms of the virus vary significantly over a wide spectrum ranging from mild fever, cough, dyspnea to respiratory failure and eventual death.⁴

Viral structure and cellular entry

Coronaviruses are large, enveloped, non-segmented, single-stranded, positive-sense RNA viruses.¹ They are spherical in shape and consist of 4 key structural components, including: spike (S), envelope, membrane and nucleocapsid (N) proteins.⁵ The S protein is the main determinant of pathogenicity and host specificity, and it is also a prime target for neutralizing antibodies. This makes it of immense interest to scientists in the development of potential vaccines. Random mutations and recombination, both homologous and non-homologous, allow the virus to easily cross the species barrier and lead to cross-species infection. A substantial pool of animal reservoirs, especially bats, genetic recombination and the ability to exploit multiple receptors, make coronaviruses highly infective across wide taxonomic distances.⁶

Viral cell entry requires the binding of the S protein with the transmembrane ACE2 host receptor. ACE2 receptor is expressed by almost all cells of the body. The S protein consists of 2 subunits: S1 which is involved in the recognition of the ACE2 receptor and S2 which anchors the protein to the viral membrane and facilitates viral fusion.^{7–9} SARS-CoV-2 has a high-binding affinity to the ACE2 receptor and activity of the ACE is not necessary for successful binding and endocytosis of the virus. After completion of endocytosis, the virus takes over the cellular machinery to produce viral RNA and viral-specific proteins. Within the cells, the virus is assembled followed by secretion. In the gastrointestinal (GI) tract, viral secretion is accompanied by the release of cytokines, which in turn is responsible to the associated symptoms.

High ACE2 receptor expression is observed in ciliated, goblet and surfactant-producing type 2 alveolar cells, thereby providing a portal of entry of the virus into the body.^{10,11} High



© American Federation for Medical Research 2020. No commercial re-use. See rights and permissions. Published by BMJ.

To cite: Dahiya DS, Kichloo A, Albosta M, et al. *J Investig Med* 2020;**68**:1397–1401.

ACE2 expression is also observed on the intestinal epithelium¹² and cardiac and vascular endothelium, offering an explanation to the complication of COVID-19 in these organ systems.¹³

Clinical presentation of COVID-19

The clinical course of COVID-19 is highly variable and is usually represented on a spectrum from very mild symptoms to critical illness. The incubation period for COVID-19 is thought to extend to 14 days, with a median incubation time of about 5 days from exposure to symptoms onset.^{14 15} One study reported that about 97.5% of patients who develop symptoms will do so in 11.5 days.¹⁵ Some of the common symptoms of COVID-19 include: fever or chills, cough, shortness of breath or difficulty breathing, fatigue, muscle or body aches, headache, new loss of taste or smell, sore throat, congestion or runny nose, nausea, vomiting, anorexia or diarrhea. Each symptom may differ in severity. Elderly patients and those with underlying comorbidities such as cardiovascular disease, diabetes mellitus, chronic respiratory disease, decompensated cirrhosis, prior stroke, HIV or other immunosuppressed states are at increased risk of adverse outcomes.

Pathophysiology of GI tract involvement in COVID-19

ACE2 receptor has been identified as the target receptor for entry of SARS-CoV-2 into the cell, initiating the first step of viral infection. Immunofluorescence data revealed abundant expression of ACE2 receptor in the glandular

cells of gastric, duodenal, and rectal epithelia but esophageal epithelium, mainly composed to stratified squamous cells, expresses less ACE2 receptor than glandular cells.¹⁶ Hence, on RNA detection and intracellular staining for viral N protein, gastric, duodenal and rectal epithelia show high intracellular viral concentration, whereas the esophageal mucosa demonstrates low intracellular viral concentration.¹⁶ Furthermore, ACE2 receptor is also expressed in cholangiocytes and hepatocytes implicating a direct infection of the liver.¹⁷ During the second step of viral infection, the positive-strand viral RNA starts synthesizing viral-specific RNA and proteins to assemble new virions inside the cell, which are released into the GI tract. Real-time reverse transcriptase PCR (rRT-PCR) can be used to detect the virions in the feces. According to the Centers for Disease Control and Prevention (CDC) guidelines, transmission-based precautions can be discontinued if the rRT-PCR testing from 2 sequential respiratory tract specimens is negative, collected ≥ 24 hours apart.¹⁸ However, viral RNA can remain positive in the feces in more than 20% of the patients even after the rRT-PCR results converted to negative in the respiratory tract, indicating that viral infection and fecal-oral transmission can last after respiratory clearance.¹⁶ Hence, the fecal-oral route is an important mode of transmission of the virus and should be taken into consideration while devising strategies to prevent the spread of the virus. [figure 1](#) presents a systemic and graphical representation of the effect of SARS-CoV-2 on the GI epithelium.

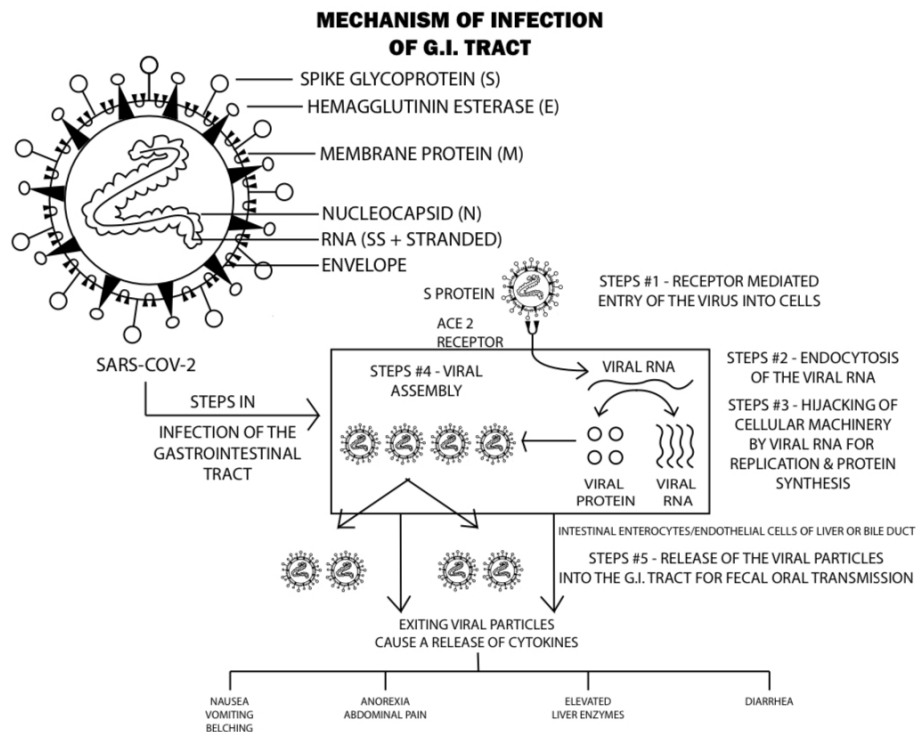


Figure 1 Systemic representation of the effect of SARS-CoV-2 on the intestinal epithelium. The virus enters the cell through interaction of its spike protein with ACE2 receptor (ACE2R). After endocytosis, the positive-sense RNA hijacks cellular machinery for viral RNA and viral-specific protein synthesis. Viral particles are then assembled in the cellular cytoplasm and released into the gastrointestinal (GI) tract. Exiting viral particles lead to release of cytokines responsible for GI symptoms.

Clinical presentation of patients with GI tract involvement

ACE2 receptor is abundantly expressed in the glandular cells of gastric, duodenal, and rectal epithelia. It has now been established that SARS-CoV-2 can still be shed through the GI tract even after the resolution of pulmonary symptoms,¹⁶ making fecal-oral route an important mechanism of transmission of the virus. A recent study suggests that the GI symptoms can be present in as high as 50% of the patients (39.6%–50%) with symptoms including¹⁹:

- ▶ Nausea (17.3%).
- ▶ Diarrhea (12.9%).
- ▶ Anorexia (12.2%).
- ▶ Abdominal pain (5.8%).
- ▶ Belching (5%).
- ▶ Emesis (5%).

An interesting symptom of practical significance in COVID-19, which may allow for easier identification of asymptomatic or presymptomatic individuals, is new-onset taste disturbance.²⁰ These taste disturbances include complete loss (ageusia), partial loss (hypogeusia) or altered taste sensations (dysgeusia). Most recent literature reports a prevalence range of 71%–88.8% for taste disturbances in patients with COVID-19.²¹ The exact mechanism of the taste disturbance is poorly understood but it is worth noting that new-onset taste disturbance has been reported as an early or lone symptom of COVID-19 before involvement of the lungs or other organs.²¹

Elevated liver enzymes have also been found to be closely associated with COVID-19. Abnormal levels of aspartate aminotransferase and alanine aminotransferase along with mildly elevated total bilirubin levels have been found in 14.8%–53% of the cases.²² At initial presentation, pooled elevated liver chemistries were seen in 23.1% of patients, but during the illness elevated liver enzymes and severe liver injury occurred in 14.4% and 10.7% of patients, respectively.²³ Presence of hypoalbuminemia indicates severe infection.²³ The development of liver injury in patients with COVID-19 depends on the severity of the disease, with increasing severity leading to increased incidence of liver injury. In addition, it is now known that the endothelial cells of the liver and bile duct express high quantities of ACE2 receptor, making them a potential target for cellular injury. Bile duct endothelial cells express higher quantities of ACE2 receptor than the liver endothelial cells, thereby indicating that the damage to the bile duct may be the cause of liver impairment.²² Another proposed mechanism of liver injury could be drug induced during the treatment of COVID-19. In a recent autopsy analysis of liver tissue from a patient with COVID-19, moderate microvesicular steatosis and mild inflammation in the lobular and portal areas was observed, which is not specific for 1 particular etiology but can also be observed during sepsis or drug-induced liver injury.²⁴ Despite the availability of all the current data, there still exists a knowledge gap in determining the full spectrum of GI involvement. Hence, we advocate for keeping a high clinical suspicion of COVID-19 in patients with GI symptoms.

Patients with inflammatory bowel disease (IBD) have similar susceptibility to COVID-19 as the general population. The composite outcomes of hospitalizations or

mortality after COVID-19 in patients with IBD are similar to patients without IBD.²⁵ Medication adherence is strongly advised to prevent an acute flare-up but where possible high-dose corticosteroids should be avoided in case of an infection with COVID-19, immunosuppressants should be withheld until the resolution of the infection or during trials of medication for COVID-19.²⁶ CDC guidelines on prevention of the infection should be followed.

GI organ viral loads on COVID-19 and comparisons with other organ systems

Viral loads play an important role in assessing the disease severity in viral infections such as SARS-CoV-2 and can be measured by rRT-PCR. Increasing viral loads means increasing viral particles in the body, which in turn points to a more severe disease. Low or down trending viral load reflects a milder infection or gradual recovery, respectively. The viral load in respiratory tract samples peaks around symptom onset and gradually decreases over 1–3 weeks, with viral RNA generally undetectable about 2 weeks after symptom onset (median 14.5 days).²⁷ Although there is evidence of viral shedding in the stool even after respiratory clearance, it is often erratic and may continue for up to 10 weeks after initial symptoms.¹⁹ More literature is still needed to quantify the viral loads in different organs to determine the severity and progression of the disease with corresponding viral load values. In current clinical practice, viral load for COVID-19 is not routinely measured.

Laboratory investigations and imaging in COVID

As with any infectious etiology, routine laboratory investigations become essential to determine the presence, assess the severity, guide further investigation and plan treatment strategies for the infection. With COVID-19, white cell counts lie on the spectrum of leucopenia or leucocytosis, with lymphopenia being the most common white cell counts derangement.²⁸ Elevated markers of inflammation, that is, lactate dehydrogenase, ferritin, and aminotransferase, have also been observed.²⁸ Procalcitonin levels may be normal during the infection; however, elevated procalcitonin levels correspond to severe disease and increase intensive care unit admission.²⁹ C-reactive protein (CRP), an acute-phase protein responsible for clearance of pathogens through the complement system and enhanced phagocytosis, has been linked to a worse prognosis in COVID-19 infections. Patients who died of COVID-19 infections displayed significantly higher concentrations of CRP as compared with survivors.³⁰ Interleukin-6 (IL-6), one of the main mediators of inflammatory and immune response, has been associated with the mortality risk in COVID-19 infections and seems to be the best prognosticator for a negative outcome.³¹ Recent literature reports that the mean IL-6 levels were more than 3 times higher in patients with complicated COVID-19 compared with those with non-complicated disease.³² Chest CT scans, which typically show bilateral ground-glass opacification with or without consolidations, together with RT-PCR, have a high sensitivity of 97% but low specificity of 25% in detecting COVID-19.^{33 34} Analysis of stool samples in patients with GI symptoms may be the best test for COVID-19; however, more studies are needed to establish specific protocols.¹⁹

GI-specific treatment guidelines

The current management of the disease is focused around disease prevention, supportive care in hospital through the use of oxygen and ventilators, and management of the symptoms. However, on May 1, 2020, the US Food and Drug Administration (FDA) has issued an authorized emergency use of the drug remdesivir for the treatment of suspected or laboratory-confirmed COVID-19 in adults and children hospitalized with severe disease.³⁵ From a strictly GI standpoint, no specific treatment guideline exists. However, due to the potential risk of spread of the virus through the fecal-oral route, all major American gastroenterological societies including the American Association for the Study of Liver Diseases, the American Gastroenterological Association, the American College of Gastroenterology, and the American Society of Gastrointestinal Endoscopy (ASGE) have made recommendations for managing COVID-19 in the patients both in outpatient and endoscopy settings. They advise deferring non-urgent endoscopic procedures to a later date. For patients in need of emergent endoscopic procedures, where the procedure becomes essential, the physicians should take precautionary measures by screening patients arriving for the procedure and wearing the full personal protective equipment (PPE) as advised by the CDC. After the procedure, no changes are recommended to the reprocessing procedures for endoscopes and accessories by the ASGE. Standard bedside precleaning, followed by manual cleaning and high-level disinfection in the reprocessing facility, should continue.

CONCLUSION

Organs such as of the respiratory tract, GI tract and liver have a high expression of ACE2 receptors making them a definite target for infection. With an incubation period of about 2 weeks, the most common GI symptoms include: nausea, vomiting, belching, anorexia, abdominal pain and diarrhea. It has now been established that SARS-CoV-2 can still be shed through the GI tract even after the resolution of pulmonary symptoms, highlighting the fecal-oral route an important mechanism of transmission. Elevated liver enzymes at presentation, during hospitalization and progression to severe liver injury have also been noted. Severe decompensated liver disease increased the severity of COVID-19 and vice versa. Major American gastroenterological societies advocate against non-emergent endoscopic interventions and use of PPE and screening on the patients before emergent endoscopies. No literature currently exists on acute IBD flare-up due to COVID-19. However, immunosuppressants should be withheld until resolution of symptoms or during trial of medication for COVID-19. For very severe disease, the US FDA has issued an authorized emergency use of the drug remdesivir for the treatment of suspected or laboratory-confirmed COVID-19. But, from a GI standpoint, no specific treatment protocol exists, the management is primarily focused on prevention and supportive care. CDC guidelines are an absolute must for prevention.

Contributors All authors have contributed to the manuscript and agree with the final version of the manuscript. DSD and AK are credited with substantial contribution to the design of the work, literature review of all the sections discussed, the revision of critically important intellectual

content, final approval of the published version, and agreement of accountability for all aspects of the work. MA is credited with significant design of the figures and graphs, literature review of all sections, revision of important intellectual content for the discussion, and agreement of accountability for all parts of the work. SP and FW are credited with literature review, initial content write-up and agreement of accountability for all aspects of the work.

Funding The authors have not declared a specific grant for this research from any funding agency in the public, commercial or not-for-profit sectors.

Competing interests None declared.

Patient consent for publication Not required.

Provenance and peer review Not commissioned; externally peer reviewed.

This article is made freely available for use in accordance with BMJ's website terms and conditions for the duration of the covid-19 pandemic or until otherwise determined by BMJ. You may use, download and print the article for any lawful, non-commercial purpose (including text and data mining) provided that all copyright notices and trade marks are retained.

ORCID iDs

Asim Kichloo <http://orcid.org/0000-0003-4788-8572>

Michael Albosta <http://orcid.org/0000-0003-4187-4911>

REFERENCES

- 1 Su S, Wong G, Shi W, *et al.* Epidemiology, genetic recombination, and pathogenesis of coronaviruses. *Trends Microbiol* 2016;24:490–502.
- 2 Cavanagh D. Coronavirus avian infectious bronchitis virus. *Vet Res* 2007;38:281–97.
- 3 Lu R, Zhao X, Li J, *et al.* Genomic characterisation and epidemiology of 2019 novel coronavirus: implications for virus origins and receptor binding. *Lancet* 2020;395:565–74.
- 4 Vabret N, Britton GJ, Gruber C, *et al.* Immunology of COVID-19: current state of the science. *Immunity* 2020;52:910–41.
- 5 Fehr AR, Perlman S. Coronaviruses: an overview of their replication and pathogenesis. *Methods Mol Biol* 2015;1282:1–23.
- 6 Felsenstein S, Herbert JA, McNamara PS, *et al.* COVID-19: immunology and treatment options. *Clin Immunol* 2020;215:108448.
- 7 Tortorici MA, Veesler D. Structural insights into coronavirus entry. *Adv Virus Res* 2019;105:93–116.
- 8 Tortorici MA, Walls AC, Lang Y, *et al.* Structural basis for human coronavirus attachment to sialic acid receptors. *Nat Struct Mol Biol* 2019;26:481–9.
- 9 Walls AC, Xiong X, Park Y-J, *et al.* Unexpected receptor functional mimicry elucidates activation of coronavirus fusion. *Cell* 2019;176:1026–39.
- 10 Hamming I, Timens W, Bultuis MLC, *et al.* Tissue distribution of ACE2 protein, the functional receptor for SARS coronavirus. A first step in understanding SARS pathogenesis. *J Pathol* 2004;203:631–7.
- 11 Sims AC, Baric RS, Yount B, *et al.* Severe acute respiratory syndrome coronavirus infection of human ciliated airway epithelia: role of ciliated cells in viral spread in the conducting airways of the lungs. *J Virol* 2005;79:15511–24.
- 12 Xu H, Zhong L, Deng J, *et al.* High expression of ACE2 receptor of 2019-nCoV on the epithelial cells of oral mucosa. *Int J Oral Sci* 2020;12:8.
- 13 Zhang W, Zhao Y, Zhang F, *et al.* The use of anti-inflammatory drugs in the treatment of people with severe coronavirus disease 2019 (COVID-19): the perspectives of clinical immunologists from China. *Clin Immunol* 2020;214:108393.
- 14 Li Q, Guan X, Wu P, *et al.* Early transmission dynamics in Wuhan, China, of novel coronavirus-infected pneumonia. *N Engl J Med* 2020;382:1199–207.
- 15 Lauer SA, Grantz KH, Bi Q, *et al.* The incubation period of coronavirus disease 2019 (COVID-19) from publicly reported confirmed cases: estimation and application. *Ann Intern Med* 2020;172:577–82.
- 16 Xiao F, Tang M, Zheng X, *et al.* Evidence for gastrointestinal infection of SARS-CoV-2. *Gastroenterology* 2020;158:1831–3.
- 17 Sultan S, Altayar O, Siddique SM, *et al.* AGA Institute rapid review of the gastrointestinal and liver manifestations of COVID-19, meta-analysis of international data, and recommendations for the consultative management of patients with COVID-19. *Gastroenterology* 2020;159:320–34.
- 18 Centers for Disease Control and Prevention. Discontinuation of Transmission-Based precautions and disposition of patients with COVID-19 in healthcare settings (interim guidance), 2020. Available: <https://www.cdc.gov/coronavirus/2019-ncov/hcp/disposition-hospitalized-patients.html>
- 19 Kopel J, Perisetti A, Gajendran M, *et al.* Clinical insights into the gastrointestinal manifestations of COVID-19. *Dig Dis Sci* 2020;65:1932–9.

- 20 World Health Organization. Q&A on Coronaviruses (Covid-19). Available: <https://www.who.int/emergencies/diseases/novel-coronavirus-2019/question-and-answers-hub/q-a-detail/q-a-coronaviruses> [Accessed 25 Aug 2020].
- 21 Lozada-Nur F, Chainani-Wu N, Fortuna G, *et al.* Dysgeusia in COVID-19: Possible Mechanisms and Implications [published online. *Oral Surg Oral Med Oral Pathol Oral Radiol* 2020;31075.
- 22 Jamwal S, Gautam A, Elsworth J, *et al.* An updated insight into the molecular pathogenesis, secondary complications and potential therapeutics of COVID-19 pandemic. *Life Sci* 2020;257:118105.
- 23 Kulkarni AV, Kumar P, Tevethia HV, *et al.* Systematic review with meta-analysis: liver manifestations and outcomes in COVID-19. *Aliment Pharmacol Ther* 2020;52:584–99.
- 24 Alqahtani SA, Schattenberg JM. Liver injury in COVID-19: the current evidence. *United European Gastroenterol J* 2020;8:509–19.
- 25 Singh S, Khan A, Chowdhry M, *et al.* Risk of severe COVID-19 in patients with inflammatory bowel disease in United States. A multicenter research network study. *Gastroenterology* 2020;S0016-5085:34755–7.
- 26 Al-Ani AH, Prentice RE, Rentsch CA, *et al.* Review article: prevention, diagnosis and management of COVID-19 in the IBD patient. *Aliment Pharmacol Ther* 2020;52:54–72.
- 27 Walsh KA, Jordan K, Clyne B, *et al.* SARS-CoV-2 detection, viral load and infectivity over the course of an infection. *J Infect* 2020;81:357–71.
- 28 Chen N, Zhou M, Dong X, *et al.* Epidemiological and clinical characteristics of 99 cases of 2019 novel coronavirus pneumonia in Wuhan, China: a descriptive study. *Lancet* 2020;395:507–13.
- 29 Huang C, Wang Y, Li X, *et al.* Clinical features of patients infected with 2019 novel coronavirus in Wuhan, China. *Lancet* 2020;395:497–506.
- 30 Sahu BR, Kampa RK, Padhi A, *et al.* C-Reactive protein: a promising biomarker for poor prognosis in COVID-19 infection. *Clin Chim Acta* 2020;509:91–4.
- 31 Grifoni E, Valoriani A, Cei F, *et al.* Interleukin-6 as prognosticator in patients with COVID-19. *J Infect* 2020;81:452–82.
- 32 Aziz M, Fatima R, Assaly R. Elevated interleukin-6 and severe COVID-19: A meta-analysis [published online. *J Med Virol* 2020.
- 33 Ai T, Yang Z, Hou H, *et al.* Correlation of chest CT and RT-PCR testing for coronavirus disease 2019 (COVID-19) in China: a report of 1014 cases. *Radiology* 2020;296:E32–40.
- 34 Ai T, Yang Z, Hou H, *et al.* Correlation of chest CT and RT-PCR testing for coronavirus disease 2019 (COVID-19) in China: a report of 1014 cases. *Radiology* 2020;296:E32–40.
- 35 U.S. Food and Drug Administration. Coronavirus (COVID-19) update: FDA issues emergency use authorization for potential COVID-19 treatment. Available: <https://www.fda.gov/news-events/press-announcements/coronavirus-covid-19-update-fda-issues-emergency-use-authorization-potential-covid-19-treatment>