

# Anti-inflammatory effects of simvastatin during the resolution phase of experimentally formed venous thrombi

Yaping Feng,<sup>1</sup> Bo Lei,<sup>2</sup> Fuxian Zhang,<sup>1</sup> Luyuan Niu,<sup>1</sup> Huan Zhang,<sup>1</sup> Mingyi Zhang<sup>1</sup>

<sup>1</sup>Department of Vascular Surgery, Beijing Shijitan Hospital, Capital Medical University, Beijing, China  
<sup>2</sup>Anesthesia Department, Beijing Haidian Maternal & Child Health Hospital, Beijing, China

## Correspondence to

Dr Fuxian Zhang, Department of Vascular Surgery, Beijing Shijitan Hospital, Capital Medical University, Beijing 100038, China; leibo1977@163.com

Accepted 25 March 2017

Copyright © 2017 American Federation for Medical Research

## ABSTRACT

Deep venous thrombosis (DVT) is a common vascular disease and is closely linked to inflammation. Over the past decade, the potential antithrombotic effect of statins has been elucidated by clinical studies, primarily through focusing on DVT prevention. The effects of statins on DVT resolution and its underlying mechanisms have been rarely addressed. We established a rabbit model of the *inferior vena cava* (IVC) venous thrombosis. After 48 hours, the rabbits were treated with saline, heparin, simvastatin, or simvastatin combined with heparin, respectively, for 14 days. The migration of inflammatory cells (neutrophils, monocytes, lymphocytes) in the thrombi and injured venous wall, the plasma levels of interleukin (IL)-6, monocyte chemoattractant protein 1 (MCP-1) and P-selectin, and local expression of MCP-1 and P-selectin in the venous wall were evaluated by histology, immunohistochemistry, and ELISA examinations. Our data showed that compared with saline and heparin controls, monotherapy of simvastatin and the adjunctive therapy with simvastatin and heparin significantly improved the thrombus resolution and reduced inflammatory cells migration into the venous wall, the release of the inflammatory cell adhesion molecule (P-selectin), inflammatory chemokine (MCP-1) and pleiotropic proinflammatory cytokines (IL-6) into the blood, and the local expression of P-selectin and MCP-1 in the venous wall. Simvastatin targets anti-inflammatory pathways during the resolution phase of a thrombus, providing a therapeutic potential in DVT resolution and post-thrombotic syndrome prevention.

## INTRODUCTION

Venous thrombosis (VT) is a common vascular disease. The incidence of deep vein thrombosis (DVT) is estimated at 465 715 cases per year in the European Union and 56/100 000 in the USA.<sup>1</sup> In the acute stage of DVT, patients may develop pulmonary embolism (PE), which can lead to sudden death. The mortality rate of PE varies from 1% to 95%, depending on the patient's condition.<sup>2</sup> In later stages, ~23–60% of patients may develop post-thrombotic syndrome (PTS),<sup>3</sup> causing repeated or progressive limb swelling, stasis dermatitis, refractory skin ulceration or limb necrosis, which can seriously

## Significance of this study

### What is already known about this subject?

- ▶ Deep venous thrombosis (DVT) is related to inflammation.
- ▶ Statins are able to prevent DVT.
- ▶ Currently available therapies are not very effective for the resolution of DVT.

### What are the new findings?

- ▶ Simvastatin has effect on the resolution of DVT.
- ▶ Simvastatin reduces the migration of inflammatory cells.
- ▶ Simvastatin reduces the release and local expression of inflammation relevant molecules, such as interleukin-6, monocyte chemoattractant protein 1 and P-selectin.

### How might these results change the focus of research or clinical practice?

- ▶ These results indicate the value of simvastatin in the treatment of DVT in clinical practice.

affect the survival and quality of life of patients.<sup>4</sup> Therefore, prevention of PTS has become a very important issue for public health and clinical research. The currently available therapies for DVT including anticoagulant treatment, pharmacomechanical thrombolysis, and inferior vena cava (IVC) filter placement can prevent the propagation and extension of the thrombus but are less effective for the resolution of the thrombus. Other therapies such as catheter-directed thrombolysis and percutaneous mechanical thrombectomy can remove the thrombus rapidly but can also cause side effects such as hemorrhage. Therefore, a better treatment that can prevent thrombosis and also accelerate the resolution of the thrombus without hemorrhage is desired.

Previously, vessel wall injury, venous stasis, and blood hypercoagulability have been considered to contribute to the development of VT. In recent years, the role of inflammation in the development of DVT and PTS has attracted

**To cite:** Feng Y, Lei B, Zhang F, et al. *J Investig Med* Published Online First: [please include Day Month Year] doi:10.1136/jim-2017-000442

more attention. Studies have shown that the development of DVT is closely linked to inflammation,<sup>5</sup> which may exacerbate the damage to the veins, leading to the occurrence of PTS.<sup>6</sup> Clinical and animal studies have demonstrated a prothrombotic effect of interleukin (IL)-6, P-selectin, and monocyte chemoattractant protein 1 (MCP-1), and tumor necrosis factor  $\alpha$ .<sup>7–9</sup> The underlying mechanisms have been investigated using animal models, showing that the inhibition of P-selectin reduced VT and venous wall inflammation in rats<sup>10</sup> and primates.<sup>11</sup> The inhibition of IL-6 also reduced the effects of PTS following DVT in a mouse model of DVT.<sup>12</sup> Therefore, an effective clinical treatment targeting inflammation in DVT may improve the outcome of therapy significantly as well as the patients' quality of life.

Within a decade, the potential antithrombotic effect of statins was elucidated by clinical studies. A hospital-based case–control study reported the influence of statin use on the risk of venous thromboembolism.<sup>13</sup> In 2009, the effect of rosuvastatin on the prevention of DVT was proved by the JUPITER Trial in relatively healthy individuals.<sup>14</sup> Other clinical studies also showed that statins decreased the incidence of VT.<sup>14</sup> The underlying mechanism is not clear. Apart from 3-hydroxy-3-methylglutaryl-coenzyme A reductase inhibition, statins also have pleiotropic effects by inhibiting the production of specific prenylated proteins. Therefore, they may be involved, at least partially, in the improvement of endothelial function and the modulation of immune function.<sup>15–18</sup> Until now, most studies describing the beneficial effect of statins mainly focus on DVT prevention. The effects of statins on DVT resolution and underlying mechanisms have rarely been addressed. We therefore conduct the present study, using a rabbit model of the IVC VT, to investigate the role of simvastatin in DVT resolution. On the basis of our preliminary data, we hypothesized that statin treatment may improve the stability or resolution of the thrombus via anti-inflammatory effects.

## MATERIALS AND METHODS

### Animals

Forty-eight quarantine-certified, healthy adult male New Zealand white rabbits, 4 months of age and 2.0–2.5 kg in weight (purchased from Xinglong experimental animal center, Beijing, China), were reared in single cages with free access to rabbit pellets and water for 1 week of the adaptive period prior to surgery. The animal studies were performed in accordance with the institution guidelines for laboratory animal research; it has been approved by the Ethics Committee of Beijing Shijitan Hospital, Capital Medical University.

### The establishment of a rabbit model of VT

The IVC VT was produced using the protocol adapted from the method published previously.<sup>19</sup> The rabbit was anesthetized with 3% pentobarbital sodium (30 mg/kg, injected via the ear vein) and placed on a thermostatically controlled heating pad. A midline laparotomy was performed, and the intestines were lifted to one side and covered with saline-moistened gauze sponges. A 5 cm segment of the abdominal vena cava immediately distal to the left renal vein was cleared of adherent tissue by blunt dissection. All small branches draining the abdominal wall were tied off with a

#0 silk suture. The free vena cava was then ligated with a size 0.035" ultrasmooth guidewire (TERUMO, Japan) at the proximal, middle and distal points with #1 silk suture. Thereafter, the guidewire was withdrawn to produce incomplete occlusion. The vena cava was clipped using microvascular clips (at the distal and proximal ends). The abdomen was closed. After 1 hour, the peritoneal cavity was opened once again. The clips were removed to observe the formation of the thrombus in the IVC. After the incision was closed, the observation was continued until the rabbits recovered completely from anesthesia.

### Drug treatment

Forty-eight hours after the DVT was established, rabbits were randomly divided into four groups. Group 1: rabbits receive saline (5 mL/day) by daily gavages; group 2: rabbits receive a subcutaneous injection of FraxiParine (low molecular weight heparin sodium, Glaxo 0.03 mL/kg/day); group 3: rabbits receive simvastatin (Guangzhou Nan Xin Pharmaceutical Co, China) by daily gavages (5 mg/kg/day in 5 mL of distilled water) as prescribed in previous reports;<sup>20 21</sup> group 4: rabbits receive combination therapy with simvastatin (5 mg/kg/day) and FraxiParine (0.03 mL/kg/day).

### Specimen collection

After 3, 7 and 14 days of treatment, four rabbits in each group were anesthetized with a 3% pentobarbital sodium (30 mg/kg) intravenous injection. The original incision on the abdomen was opened again. The injured IVC containing the thrombus was excised and the rabbits were sacrificed. Since intact specimens were needed to examine the inflammatory cells migration as well as MCP-1 and P-selectin expressions in the venous wall and thrombus, isolated thrombi were not available. Therefore, the weight/length ratio (mg/mm) of the whole specimen (including the injured vessel and thrombus) was used to roughly assess the size of the thrombus. Following the measurement of weight and length, the specimens were fixed in 4% paraformaldehyde for histology and immunohistochemistry examinations.

In addition, blood samples were withdrawn from the auricular artery of rabbits before the establishment of VT, 48 hours after DVT establishment, that is, predrug treatment, and 3, 7, or 14 days postdrug treatment. Blood samples were centrifuged after 4 hours to get 1.5 mL plasma, kept at  $-80^{\circ}\text{C}$  for later examinations.

### Histological analysis of injured veins and thrombosis

Fixed specimens of the vena cava with thrombus were embedded in paraffin and sectioned at 4  $\mu\text{m}$  thickness. H&E staining was performed using standard procedures. Under a light microscope (BX41TF, OLYMPUS, Japan), five fields of 1000-fold magnification (oil immersion) were selected from each slide and the number of inflammatory cells (neutrophils, monocytes, lymphocytes) were counted.

### Lipid analysis

Lipid analysis was performed automatically on a Hitachi 7600 Automatic Biochemistry Analyzer (Hitachi, Tokyo, Japan) with the following enzymatic methods: total cholesterol: CHOD-PAP (Boehringer Mannheim); triglycerides: GPO-PAP (Boehringer Mannheim).

### ELISA for the measurement of plasma cytokines

Plasma levels of IL-6, soluble P-selectin and MCP-1 were determined using IL-6, soluble P-selectin and MCP-1 ELISA kits (RnSystems) and a light absorption microplate reader (Tecan Sunrise, TECAN, Switzerland) following the manufacturers' instructions. All kits were specifically developed for rabbit cytokines without cross-reactivity. The coefficient of variation was 10.0% for the IL-6 kit, 14.3% for the P-selectin kit and 13.9% for the MCP-1 kit.

### Immunohistochemistry for the detection of P-selectin and MCP-1 on the venous wall and thrombus

Immunohistochemistry was performed on paraffin sections of the vena cava and thrombus. Following the standard protocol, the endothelial cells were stained with rabbit anti-MCP-1 (Abcam) and anti-P-selectin/CD62P monoclonal antibodies (Abcam) as primary antibodies, followed by an avidin-horseradish peroxidase conjugate (Thermo Scientific, Germany) and color reaction (3,3'-diaminobenzidine paraffin immunohistochemistry staining module, Ventana Medical Systems, Tucson, Arizona, USA). For P-selectin detection, three fields from each slide were selected randomly under a light microscope (200 $\times$ ) and the density of P-selectin-positive cells and the mean optical density of positive cells (IOD) were measured by an IPP V7.0 image analysis software (Media Cybernetics). For MCP-1 detection, three fields from the junction of the venous wall and thrombus on each slide were selected randomly under a light microscope (200 $\times$ ) and the density of MCP-1-positive cells and the mean IOD were measured by an IPP V7.0 image analysis software (Media Cybernetics).

### Statistical analysis

Data are expressed as mean $\pm$ SEM and analyzed using SPSS V19.0 software (SPSS, Chicago, Illinois, USA). Two-tail Student's t-test was used for the comparisons between the two groups, and one-way analysis of variance (ANOVA) followed by Bonferroni corrected post hoc t-test was used for the comparisons among multiple groups. Bivariate correlation analysis was conducted to determine whether there was any correlation between the anti-inflammatory effects of simvastatin and the changes in lipid levels following simvastatin treatment.  $p$  Value  $<0.05$  was considered statistically significant.

## RESULTS

### The effect of simvastatin on the size of the thrombus

As shown in [figure 1](#), the weight/length ratio was significantly reduced with the treatment combined simvastatin and heparin from day 3 until day 12 (all  $p<0.05$  compared with controls) and the reduction was also significantly more than that with heparin treatment on day 7 ( $p<0.05$ ). A similar effect was also seen with simvastatin treatment ( $p<0.05$  on days 3 and 14 compared with controls) but the reduction was not significantly different on day 7 ( $p=0.09$ ), probably due to the variation in the small sample size. However, the weight/length ratio was not significantly reduced with heparin treatment until day 14 ( $p<0.01$  compared with controls).

These data suggest that simvastatin may affect the resolution of the thrombus; the effect was more quickly than

that of heparin and was more consistent when combined with heparin.

### The effect of simvastatin on inflammatory cells migration in the injured venous wall and thrombus

As shown in [figure 2](#), in the control group, the normal structure of the venous wall was destroyed with a swelling from day 3 to 14 after the treatment was initiated. There was significant migration of inflammatory cells into the venous wall adjacent to the thrombus. In the heparin group, the migration of inflammatory cells was reduced slightly with the treatment. In the simvastatin group, the thrombus became smaller and the migration of inflammatory cells was significantly reduced compared with controls and the heparin group after 3 days of treatment. These effects were time-dependent and more profound after 14 days of treatment. The combined treatment with simvastatin and heparin was more effective than simvastatin monotherapy in reducing inflammatory cells migration and restoration of venous structure.

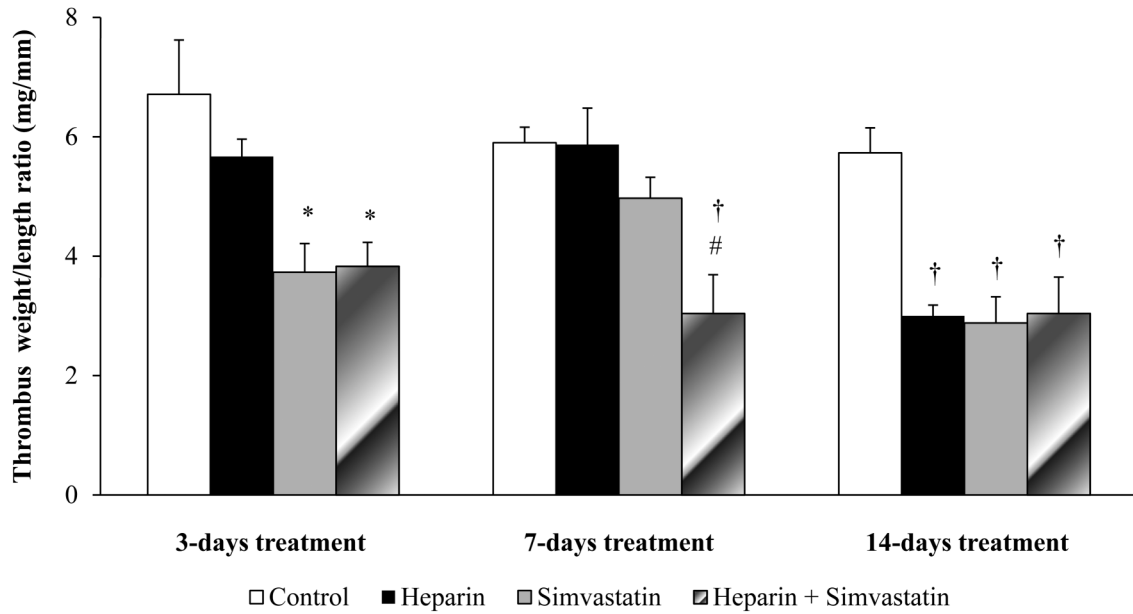
The actual changes in the number of neutrophils, monocytes and lymphocytes are shown in [table 1](#). In the control group, the number of neutrophils did not change significantly but the number of monocytes and lymphocytes increased significantly with time. The treatment with heparin mildly but significantly reduced the number of neutrophils and lymphocytes (all  $p<0.05$ ,  $n=4$  per group) but not monocytes ( $p=NS$ ). The treatments with simvastatin alone or combined with heparin significantly reduced the number of all inflammatory cells and such effects were time-dependent, more profound on day 14 compared with days 3 and 7 (all  $p<0.0001$ ). Overall, the effect of combination therapy with simvastatin and heparin was the best, followed by simvastatin and then heparin monotherapy.

### The effect of simvastatin on plasma levels of cytokines

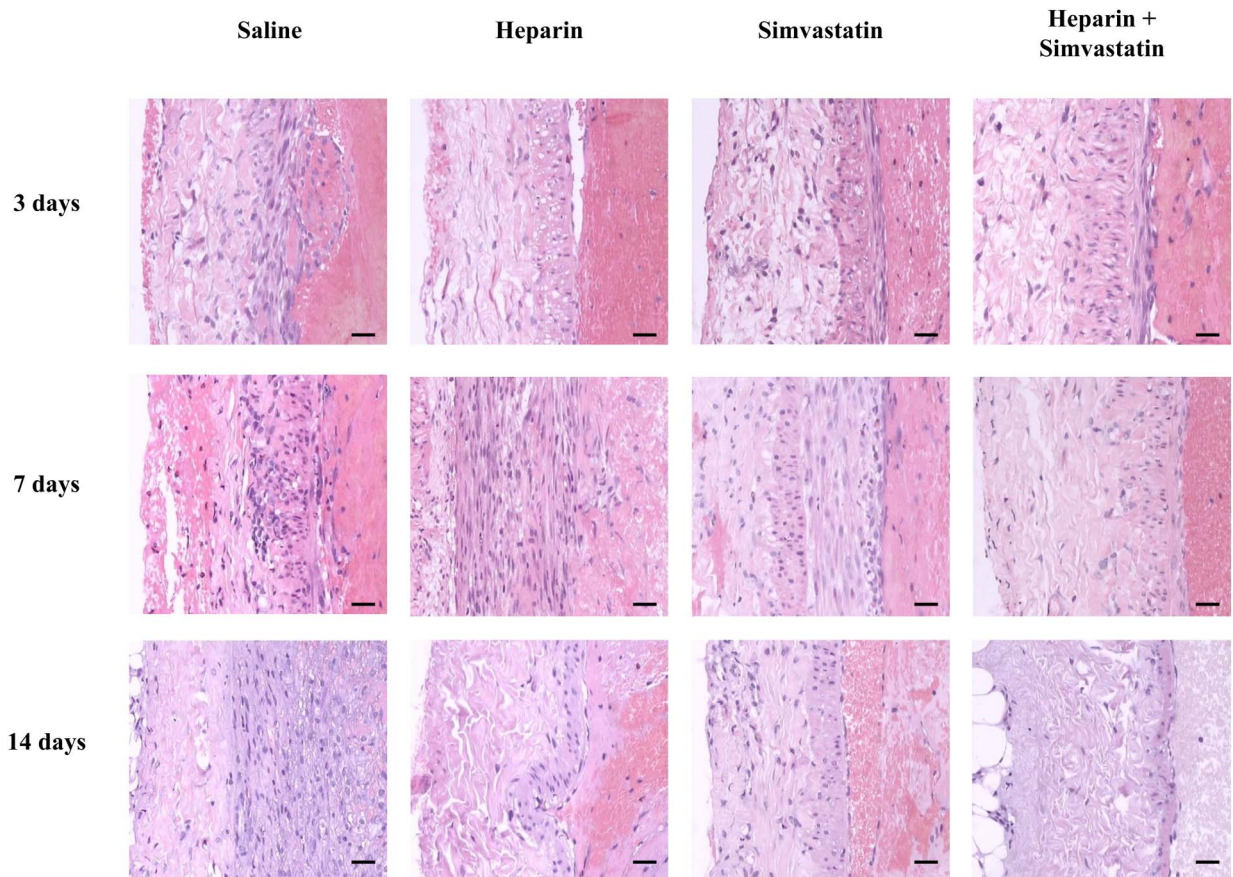
IL-6 is an IL that acts both as a proinflammatory cytokine and as an anti-inflammatory myokine. P-selectin and MCP-1 play essential roles in the migration of inflammatory cells. We therefore examined the plasma levels of these inflammatory biomarkers to investigate the anti-inflammatory effect of simvastatin. A significant increase in the plasma levels of IL-6, P-selectin and MCP-1 was observed 48 hours after DVT formation compared with their baseline levels (all  $p<0.05$ ; [figure 3](#)). IL-6 levels in the saline and heparin groups reached the peak 5 days post-operatively and then gradually decreased but were still significantly higher on day 14 than baseline levels (all  $p<0.05$ ,  $n=4$  per group). In the simvastatin group, the plasma level of IL-6 was significantly lower than that in the saline and heparin groups after 3, 7 and 14 days of treatment (all  $p<0.001$ ). In the combination therapy group, the plasma level of IL-6 was also significantly lower than the saline and heparin groups at all time points of treatment (all  $p<0.001$ ) and was also lower than that in the simvastatin group on day 3 of treatment ( $p<0.05$ ; [figure 3A](#)).

As shown in [figure 3B](#), the plasma level of P-selectin was gradually increased with time after DVT formation in the saline controls and the heparin group but it was significantly lower with 14 days of heparin treatment ( $p<0.0001$ ,  $n=4$  per group). The increase in P-selectin was retarded significantly by 3–14 days of simvastatin treatment





**Figure 1** Simvastatin improved the resolution of the established thrombus in a rabbit model of deep vein thrombosis. N=4 per group. \*p Value <0.05 compared with the control group. †p Value <0.01 compared with the control group. #p Value <0.05 compared with the heparin group.



**Figure 2** Simvastatin reduced inflammatory cell migration in the injured venous wall and thrombus in a rabbit model of deep vein thrombosis. Representative H&E sections showed a decrease in inflammatory cells in the injured venous wall and thrombus in simvastatin alone or combined with heparin-treated animals compared with saline and heparin treated animals. N=4 per group. Scale bars, 25  $\mu$ m.

**Table 1** The changes of inflammatory cells with heparin, simvastatin, or combined treatment

|                    | Saline   | Heparin   | Simvastatin | Heparin+simvastatin | p Value |
|--------------------|----------|-----------|-------------|---------------------|---------|
| <b>Neutrophils</b> |          |           |             |                     |         |
| 3 days             | 11.7±1.3 | 8.5±1.6*  | 5.6±1.1*†   | 4.0±0.6*†‡          | <0.0001 |
| 7 days             | 12.2±1.5 | 10.5±1.7* | 6.2±1.5*†   | 2.5±0.6*†‡          | <0.0001 |
| 14 days            | 11.4±1.4 | 7.8±2.2*  | 3.3±0.5*†   | 1.1±0.6*†‡          | <0.0001 |
| p Value            | NS       | <0.0001   | <0.0001     | <0.0001             |         |
| <b>Monocytes</b>   |          |           |             |                     |         |
| 3 days             | 5.9±0.6  | 5.7±1.1   | 3.8±0.7*†   | 3.5±0.6*†           | <0.0001 |
| 7 days             | 6.7±0.6  | 7.0±1.0   | 3.9±1.1*†   | 2.3±0.7*†‡          | <0.0001 |
| 14 days            | 7.5±0.7  | 5.0±1.3*  | 2.2±0.4*†   | 1.2±0.4*†‡          | <0.0001 |
| p Value            | <0.0001  | <0.0001   | <0.0001     | <0.0001             |         |
| <b>Lymphocytes</b> |          |           |             |                     |         |
| 3 days             | 9.4±1.0  | 5.2±2.4*  | 8.3±1.9†    | 6.5±1.4*‡           | <0.0001 |
| 7 days             | 15.5±1.3 | 7.9±1.5*  | 9.3±1.8*†   | 4.6±1.6*†‡          | <0.0001 |
| 14 days            | 26.4±1.7 | 5.9±1.9*  | 5.5±1.8*    | 3.1±1.5*†‡          | <0.0001 |
| p Value            | <0.0001  | <0.0001   | <0.0001     | <0.0001             |         |

Data are expressed as mean±SE, n=4 per group.

\*p Value <0.001 compared with saline control.

†p Value <0.001 compared with heparin treatment.

‡p Value <0.001 compared with Simvastatin treatment.

but the levels on days 7 and 14 were still significantly higher than baseline level (all  $p < 0.05$ ). However, after 14 days of treatment, the plasma level of P-selectin was lowered to baseline level by the combination treatment (all  $p < 0.0001$  compared with other groups at the same time point and  $p = NS$  compared with baseline level,  $n = 4$  per group).

As shown in figure 3C, the change in plasma level of MCP-1 was similar to IL-6 in the controls. It increased to a peak 5 days postoperatively and then gradually decreased. Heparin had no effect on MCP-1; however, simvastatin significantly lowered the plasma level of MCP-1 to baseline level after 14 days of treatment (All  $p < 0.0001$  compared with the saline and heparin groups at each time point and  $p = NS$  compared with baseline level,  $n = 4$  per group).

As shown in table 2, no change was observed in terms of plasma levels of total cholesterol and triglycerides with simvastatin or heparin treatment. Furthermore, bivariate correlation analysis showed that the changes in plasma levels of P-selectin, MCP-1 and IL-6 following simvastatin treatment were not correlated with the changes in plasma levels of total cholesterol and triglycerides (all  $p = NS$ ; table 3), suggesting that the anti-inflammatory effects of simvastatin was independent of its lipid-lowering effect in this VT model.

### The effect of simvastatin on the tissue expression of cytokines

In order to test whether simvastatin actually has an effect on MCP-1 and P-selectin expressions in vessels and thrombi, cross-sections of the segment of IVC adjacent to the thrombus were examined by immunohistochemistry staining. The cell density and optical density of P-selectin and MCP-1-positive cells were determined. A representative vessel with a thrombus is presented in figure 4A. Intense P-selectin staining was seen in the lesion area of the vein and thrombus in the controls. The staining was mildly

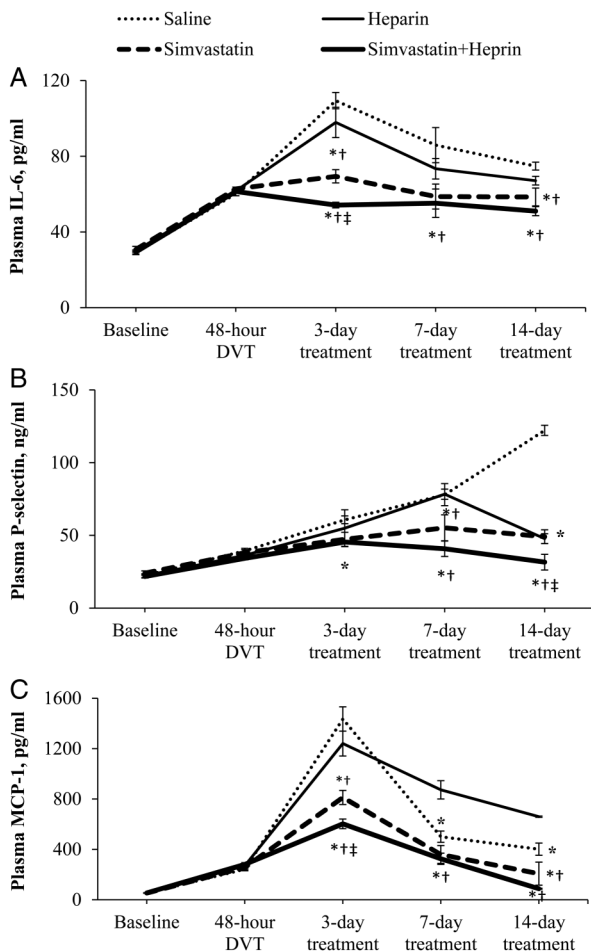
reduced in the heparin group but significantly reduced in the simvastatin group, showing the staining mainly on the surface of the inner venous wall. As shown in figure 4B, C, the cell density and optical density of P-selectin-positive cells were significantly reduced by simvastatin treatment. Such reduction was even more significant when simvastatin was combined with heparin. Similar effects were seen in the expression of MCP-1. A representative vessel with a thrombus is presented in figure 5A. Intensive MCP-1 staining was seen in the thrombus and adjacent venous wall in the control group. In saline controls, the expression of MCP-1 decreased significantly on day 14 compared with day 3.

The number of positive cells and the density of staining decreased significantly with simvastatin treatment and even more when simvastatin treatment was combined with heparin. As shown in figure 5B, C, simvastatin monotherapy was effective in decreasing MCP-1 expression in the venous wall and thrombus (all  $p < 0.0001$  compared with controls and the heparin group). The treatment was even more effective with combination therapy of simvastatin and heparin (all  $p < 0.001$  compared with other groups). Of note, the effect of simvastatin on the expression of MCP-1 and P-selectin was not time-dependent.

In summary, our data suggest that simvastatin plays an important role on inflammatory cells migration and the release and expression of cytokines. The former is time-dependent and the latter is time-independent. Such effects were ameliorated when simvastatin was combined with heparin.

### DISCUSSION

Inflammation has been linked to the development of DVT and PTS in clinical and animal studies. In particular, IL-6, MCP-1 and P-selectin were elevated in patients suffering from DVT for the first time or recurrently.<sup>7 22 23</sup> Wakefield and Henke<sup>24</sup> found an acute-to-chronic inflammatory



**Figure 3** The change in plasma levels of IL-6, P-selectin, and MCP-1 on treatment with saline, heparin, simvastatin, or conjunctive treatment of simvastatin and heparin. The treatment was initiated 48 hours after DVT establishment. Data are expressed as mean±SE, n=4 per group. \*p Value <0.001 compared with saline control, †p<0.001 compared with heparin treatment, ‡p<0.001 compared with simvastatin treatment. DVT, deep venous thrombosis; IL, interleukin; MCP, monocyte chemotactic protein.

**Table 3** The correlation between the total cholesterol and triglycerides and the anti-inflammatory effects of simvastatin evaluated by bivariate correlation analysis

|                   | R     | p Value |
|-------------------|-------|---------|
| Total cholesterol |       |         |
| P-selectin        | 0.541 | 0.070   |
| MCP-1             | 0.291 | 0.359   |
| IL-6              | 0.387 | 0.213   |
| Triglycerides     |       |         |
| P-selectin        | 0.467 | 0.126   |
| MCP-1             | 0.072 | 0.823   |
| IL-6              | 0.076 | 0.814   |

IL, interleukin; MCP, monocyte chemotactic protein.

response in the venous wall in a mouse model of DVT. Other investigators also reported that using a virus to inhibit IL-6 and P-selectin could reduce inflammation and the development of thrombosis.<sup>12 25</sup> Statins exert multiple anti-inflammatory actions<sup>26</sup> but direct evidence about the role of such anti-inflammatory effects in the development and resolution of DVT is lacking. Studies have demonstrated that statins can improve VT resolution via profibrinolytic, anticoagulant, antiplatelet, and antivein wall scarring effects<sup>27</sup> or reduce thrombin formation via delaying factor V activation (FVa) and accelerating the activated protein C-mediated FVa inactivation.<sup>28</sup> For the first time, we focus on anti-inflammatory effects of statins during DVT development and resolution.

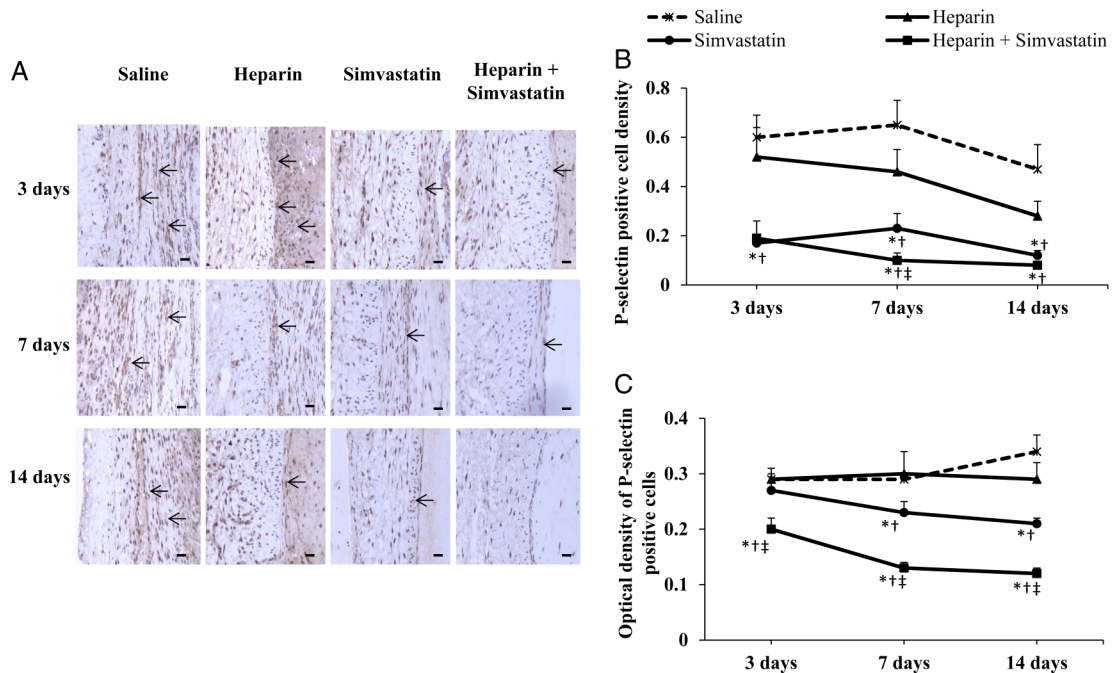
Our data showed that simvastatin affected the migration of neutrophils, monocytes, and lymphocytes in the thrombus and injured venous wall. It also reduced the plasma level and local expression of cytokines such as IL-6, P-selectin and MCP-1. We measured the weight/length ratio of specimens including the injured vessel and thrombus to roughly assess the size of the thrombus. It was significantly reduced with simvastatin treatment, indicating that simvastatin may improve the resolution of thrombi, most likely via its anti-inflammatory effects. However, we did measure fibrinolytic

**Table 2** The changes of total cholesterol and triglycerides with heparin, simvastatin, or combined treatment

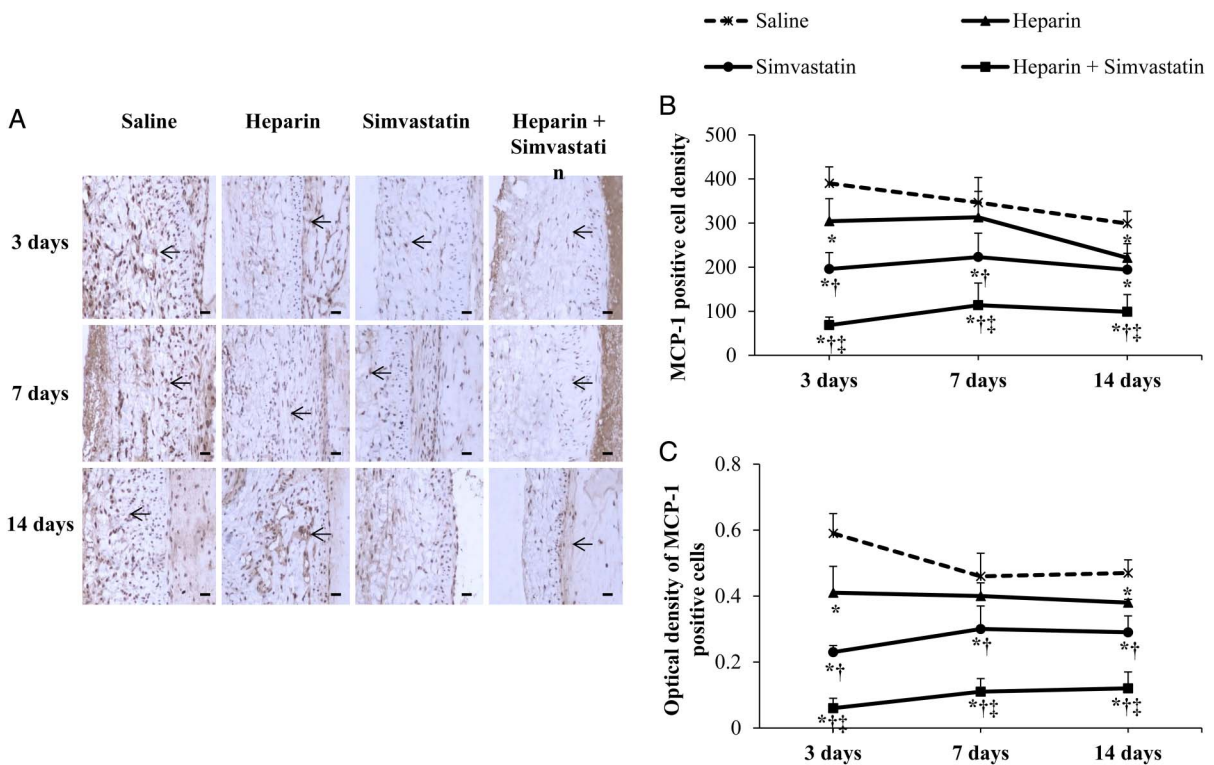
|                            | Saline    | Heparin   | Simvastatin | Heparin+simvastatin | p Value |
|----------------------------|-----------|-----------|-------------|---------------------|---------|
| Total cholesterol (mmol/L) |           |           |             |                     |         |
| Preoperative               | 1.65±0.08 | 1.76±0.07 | 1.73±0.06   | 1.69±0.07           | NS      |
| 3 days                     | 1.58±0.11 | 1.78±0.04 | 1.69±0.08   | 1.60±0.09           | NS      |
| 7 days                     | 1.69±0.09 | 1.83±0.12 | 1.50±0.07   | 1.72±0.10           | NS      |
| 14 days                    | 1.68±0.11 | 1.72±0.15 | 1.65±0.06   | 1.61±0.11           | NS      |
| p Value                    | NS        | NS        | NS          | NS                  |         |
| Triglycerides (mmol/L)     |           |           |             |                     |         |
| Preoperative               | 1.14±0.06 | 1.20±0.04 | 1.21±0.06   | 1.18±0.07           | NS      |
| 3 days                     | 1.12±0.14 | 1.28±0.07 | 1.11±0.09   | 1.16±0.09           | NS      |
| 7 days                     | 1.30±0.14 | 1.31±0.10 | 1.26±0.10   | 1.12±0.06           | NS      |
| 14 days                    | 1.12±0.06 | 1.24±0.09 | 1.10±0.06   | 1.12±0.05           | NS      |
| p Value                    | NS        | NS        | NS          | NS                  |         |

Data are expressed as mean±SE, n=4 per group. NS, not significant.





**Figure 4** The changes in vascular expression of P-selectin detected by immunohistochemistry following treatment with saline, heparin, simvastatin, or a combination of heparin and simvastatin. (A) Representative immunohistochemically stained pictures (P-selectin-positive cells shown in brown color, indicated by arrows), scale bars=25  $\mu$ m. (B) P-selectin-positive cell density. (C) The optical density of P-selectin-positive cells. Data are expressed as mean $\pm$ SE, n=4 per group. \*p Value <0.001 compared with saline control, †p<0.001 compared with heparin treatment, ‡p<0.001 compared with simvastatin treatment.



**Figure 5** The changes in vascular expression of MCP-1 detected by immunohistochemistry following treatment with saline, heparin, simvastatin, or a combination of heparin and simvastatin. (A) Representative immunohistochemically stained pictures (MCP-1-positive cells shown in brown color, indicated by arrows), scale bars=25  $\mu$ m. (B) MCP-1-positive cell density. (C) The optical density of MCP-1-positive cells. Data are expressed as mean $\pm$ SE, n=4 per group. \*p Value <0.001 compared with saline control, †p<0.001 compared with heparin treatment, ‡p<0.001 compared with simvastatin treatment. MCP, monocyte chemotactic protein.

breakdown products, such as D-dimer. Whether this treatment will improve the stability and reduce the fragility of a thrombus will require further studies.

Regarding the underlying mechanism of anti-inflammatory effects of simvastatin, there is some evidence from other disease models. In endothelial cells, simvastatin was reported to be able to suppress the effect of IL-17-induced IL-6 expression<sup>29,30</sup> and reduce the expression of proinflammatory cytokines such as IL-6, IL-8 and MCP-1 in vivo.<sup>30</sup> In a small cohort of patients with hypercholesterolemia, 6 weeks of simvastatin treatment significantly affected 24 genes, including upregulation of apoptosis-related genes, such as APAF1, BAX, IER3, CSF1R, and downregulation of cellular proliferation-related genes, such as PTN and CD69.<sup>31</sup> This study provides direct evidence related to the anti-inflammatory effect of simvastatin in a rabbit model of VT. Simvastatin reduced the migration of neutrophils, monocytes and lymphocytes into the venous wall as well as the release of cytokines such as IL-6, P-selectin and MCP-1 into blood and the local expression of P-selectin and MCP-1 in the venous wall. As we know, P-selectin plays an essential role in the recruitment of platelets and leukocytes at areas of vascular injury, thereby promoting VT formation. MCP-1 is one of the key chemokines that regulate migration and infiltration of monocytes/macrophages, which is important for thrombus resolution. Therefore, simvastatin may control thrombus formation and also improve thrombus resolution, at least partially via the anti-inflammatory pathway. Kessinger *et al*<sup>27</sup> found that the effect of statins on the reduction of VT was comparable to the therapeutic anticoagulant effects of low molecular weight heparin. We found that simvastatin was more effective than low molecular weight heparin. It started to affect the thrombus from day 3, whereas the effects of heparin on the size of the thrombus and the plasma P-selectin level were only observed on day 14. Interestingly, the adjunctive therapy with simvastatin and heparin was better than the solo treatment with simvastatin. It is probably because heparin and simvastatin target different pathways in thrombogenesis; thus, the combination of the two can extend the benefit of treatment. From a clinical perspective, the combination of low-molecular heparin and a statin is appealing. However, the bleeding effect of low molecular weight heparin should be taken into consideration.

The lipid levels could be considered as normal ranges in the rabbit model of VT in this study. The simvastatin treatment had no effect on total cholesterol and triglyceride levels but reduced plasma level and tissue expression of P-selectin and MCP-1. Therefore, this model is good to investigate the anti-inflammatory effects of statins because the lipid-lowering effect can be excluded, which is also confirmed by bivariate correlation analysis.

In this study, the baseline plasma level of IL-6 is slightly higher than in other studies.<sup>32,33</sup> Since the results were consistent in all animals in each group, the elevation may be due to a higher sensitivity of the ELISA kit we used compared to that used by others. Nevertheless, the whole picture of the changes in plasma IL-6 levels did reflect the different effect of each kind of treatment.

This study has certain limitations. First, the number of animals in each group is small, which may reduce the

power of the study; however, the effect of simvastatin can still be observed because the differences between the simvastatin groups and the controls are so significant. Second, we did not measure the size of the thrombus. However, the focus of this study is the anti-inflammatory effects of simvastatin during thrombus resolution. Our data have provided important information in this regard.

In conclusion, simvastatin targets anti-inflammatory pathways during the resolution phase of a thrombus, providing a therapeutic potential in DVT resolution and PTS prevention.

**Contributors** The authors declare that all the listed authors have participated actively in the study and all meet the requirements of authorship. YF and FZ designed the study and wrote the protocol, YF, BL and LN performed the research/study; YF and HZ managed the literature searches and analyses; YF and MZ undertook the statistical analysis; and YF wrote the first draft of the manuscript.

**Competing interests** None declared.

**Ethics approval** The animal studies were performed in accordance with the institution guidelines for laboratory animal research; it has been approved by the Ethics Committee of Beijing Shijitan Hospital, Capital Medical University.

**Provenance and peer review** Not commissioned; externally peer reviewed.

## REFERENCES

- Silverstein MD, Heit JA, Mohr DN, *et al*. Trends in the incidence of deep vein thrombosis and pulmonary embolism: a 25-year population-based study. *Arch Intern Med* 1998;158:585–93.
- Janata K, Holzer M, Domanovits H, *et al*. Mortality of patients with pulmonary embolism. *Wien Klin Wochenschr* 2002;114:766–72.
- Ashrani AA, Heit JA. Incidence and cost burden of post-thrombotic syndrome. *J Thromb Thrombolysis* 2009;28:465–76.
- Henke PK, Comerota AJ. An update on etiology, prevention, and therapy of postthrombotic syndrome. *J Vasc Surg* 2011;53:500–9.
- Wakefield TW, Myers DD, Henke PK. Mechanisms of venous thrombosis and resolution. *Arterioscler Thromb Vasc Biol* 2008;28:387–91.
- Wakefield TW, Strieter RM, Prince MR, *et al*. Pathogenesis of venous thrombosis: a new insight. *Cardiovasc Surg* 1997;5:6–15.
- Roumen-Klappe EM, den Heijer M, van Uum SH, *et al*. Inflammatory response in the acute phase of deep vein thrombosis. *J Vasc Surg* 2002;35:701–6.
- Roumen-Klappe EM, Janssen MC, Van Rossum J, *et al*. Inflammation in deep vein thrombosis and the development of post-thrombotic syndrome: a prospective study. *J Thromb Haemost* 2009;7:582–7.
- Ramacciotti E, Blackburn S, Hawley AE, *et al*. Evaluation of soluble P-selectin as a marker for the diagnosis of deep venous thrombosis. *Clin Appl Thromb Hemost* 2011;17:425–31.
- Wakefield TW, Strieter RM, Downing LJ, *et al*. P-selectin and TNF inhibition reduce venous thrombosis inflammation. *J Surg Res* 1996;64:26–31.
- Meier TR, Myers DD Jr, Wroblewski SK, *et al*. Prophylactic P-selectin inhibition with PSI-421 promotes resolution of venous thrombosis without anticoagulation. *Thromb Haemost* 2008;99:343–51.
- Wojcik BM, Wroblewski SK, Hawley AE, *et al*. Interleukin-6: a potential target for post-thrombotic syndrome. *Ann Vasc Surg* 2011;25:229–39.
- Lacut K, Oger E, Le Gal G, *et al*. Statins but not fibrates are associated with a reduced risk of venous thromboembolism: a hospital-based case-control study. *Fundam Clin Pharmacol* 2004;18:477–82.
- Ridker PM. The JUPITER trial: results, controversies, and implications for prevention. *Circ Cardiovasc Qual Outcomes* 2009;2:279–85.
- Laufs U, Custodis F, Bohm M. HMG-CoA reductase inhibitors in chronic heart failure: potential mechanisms of benefit and risk. *Drugs* 2006;66:145–54.
- Greenwood J, Steinman L, Zamvil SS. Statin therapy and autoimmune disease: from protein prenylation to immunomodulation. *Nat Rev Immunol* 2006;6:358–70.
- Lahera V, Goicoechea M, de Vinuesa SG, *et al*. Endothelial dysfunction, oxidative stress and inflammation in atherosclerosis: beneficial effects of statins. *Curr Med Chem* 2007;14:243–8.
- Blum A, Shamburek R. The pleiotropic effects of statins on endothelial function, vascular inflammation, immunomodulation and thrombogenesis. *Atherosclerosis* 2009;203:325–30.



- 19 Spokas EG, Wun TC. Venous thrombosis produced in the vena cava of rabbits by vascular damage and stasis. *J Pharmacol Toxicol Methods* 1992;27:225–32.
- 20 Zhang L, Liu Y, Lu XT, *et al.* Traditional Chinese medication Tongxinluo dose-dependently enhances stability of vulnerable plaques: a comparison with a high-dose simvastatin therapy. *Am J Physiol Heart Circ Physiol* 2009;297:H2004–14.
- 21 Arora R, Hare DL, Zulli A. Simvastatin reduces endothelial NOS: caveolin-1 ratio but not the phosphorylation status of eNOS in vivo. *J Atheroscler Thromb* 2012;19:705–11.
- 22 van Aken BE, den Heijer M, Bos GM, *et al.* Recurrent venous thrombosis and markers of inflammation. *Thromb Haemost* 2000;83:536–9.
- 23 Ay C, Jungbauer LV, Sailer T, *et al.* High concentrations of soluble P-selectin are associated with risk of venous thromboembolism and the P-selectin Thr715 variant. *Clin Chem* 2007;53:1235–43.
- 24 Wakefield TW, Henke PK. The role of inflammation in early and late venous thrombosis: Are there clinical implications? *Semin Vasc Surg* 2005;18:118–29.
- 25 Myers D Jr, Farris D, Hawley A, *et al.* Selectins influence thrombosis in a mouse model of experimental deep venous thrombosis. *J Surg Res* 2002;108:212–21.
- 26 Rodríguez AL, Wojcik BM, Wroblewski SK, *et al.* Statins, inflammation and deep vein thrombosis: a systematic review. *J Thromb Thrombolysis* 2012;33:371–82.
- 27 Kessinger CW, Kim JW, Henke PK, *et al.* Statins improve the resolution of established murine venous thrombosis: reductions in thrombus burden and vein wall scarring. *PLoS ONE* 2015;10:e0116621.
- 28 Undas A, Celinska-Lowenhoff M, Brummel-Ziedins KE, *et al.* Simvastatin given for 3 days can inhibit thrombin generation and activation of factor V and enhance factor Va inactivation in hypercholesterolemic patients. *Arterioscler Thromb Vasc Biol* 2005;25:1524–5.
- 29 Hot A, Lavocat F, Lenief V, *et al.* Simvastatin inhibits the pro-inflammatory and pro-thrombotic effects of IL-17 and TNF-alpha on endothelial cells. *Ann Rheum Dis* 2013;72:754–60.
- 30 Rezaie-Majid A, Maca T, Bucek RA, *et al.* Simvastatin reduces expression of cytokines interleukin-6, interleukin-8, and monocyte chemoattractant protein-1 in circulating monocytes from hypercholesterolemic patients. *Arterioscler Thromb Vasc Biol* 2002;22:1194–9.
- 31 Sternberg Z, Chichelli T, Sternberg D, *et al.* Quantitative and qualitative pleiotropic differences between Simvastatin single and Vytorin combination therapy in hypercholesterolemic subjects. *Atherosclerosis* 2013;231:411–20.
- 32 Jambrik Z, Gyongyosi M, Hegyi P, *et al.* Plasma levels of IL-6 correlate with hemodynamic abnormalities in acute pancreatitis in rabbits. *Intensive Care Med* 2002;28:1810–18.
- 33 Gumieniczek A, Hopkala H, Rolinski J, *et al.* Interleukin-6 and oxidative stress in plasma of alloxan-induced diabetic rabbits after pioglitazone treatment. *Immunopharmacol Immunotoxicol* 2006;28:81–91.