

# Prevalence of human papilloma virus in oropharyngeal, tongue and lip squamous cell carcinoma: an experience from the Egyptian National Cancer Institute

Safy Hosny Tealab,<sup>1</sup> Nevine F H Sedhom,<sup>1</sup> Ashraf Hassouna,<sup>2</sup> Iman Gouda,<sup>1</sup> Hoda Ismail<sup>1</sup>

<sup>1</sup>Surgical Pathology, National Cancer Institute, Cairo, Egypt  
<sup>2</sup>Radiation Oncology, National Cancer Institute, Cairo, Egypt

## Correspondence to

Dr Safy Hosny Tealab, Surgical Pathology, National Cancer Institute, Cairo, 11311, Egypt; safyahmad2@gmail.com

Accepted 7 February 2019

## ABSTRACT

Human papilloma virus (HPV) is now a well-known risk factor for head and neck cancer besides smoking and alcohol. Most studies mentioned that patients affected with high-risk HPV cancers have a better outcome, and many clinical trials are trying to prove that such group of patients can receive a different and less aggressive treatment than the HPV-negative group. Although such field has received great interest within different countries and continents, African and Egyptian populations are not yet well studied within the literature. Our aim was to detect the prevalence of HPV in oropharyngeal (OP), lip and tongue squamous cell carcinoma (SSC) and correlate the viral prevalence with different clinicopathologic parameters as well as patients' outcome. HPV detection was done on 99 cases from the lip (29), tongue (38) and oropharynx (32) diagnosed at the Pathology Department of the National Cancer Institute, Cairo University. p16 immunohistochemistry was performed on all cases, followed by HPV DNA in situ hybridization (ISH) for p16-positive cases. The prevalence of HPV in OPSSC was 28% and in lip and tongue cancers lumped together was 37%. There was more than 90% concordance between p16 and HPV DNA ISH results. HPV positivity showed a statistically significant correlation with better disease-free survival (DFS), which was also maintained for OP cases. HPV is highly prevalent in OP and common oral cavity cancers in the Egyptian population. HPV positivity correlated significantly with better DFS, especially in OP cancers.

## INTRODUCTION

Head and neck squamous cell carcinoma (HNSCC) is a common and frequently fatal malignancy. It is considered the sixth most common cancer in the world, with an incidence of about 600 000 cases per year and mortality rate of about 50%.<sup>1</sup> The main risk factors for HNSCC are smoking, alcohol as well as human papilloma virus (HPV) infection.<sup>2</sup>

Oncogenic high-risk (HR) subtypes of HPV in HNSCC have received increasing interest as differences in clinical outcome data as

## Significance of this study

### What is already known about this subject?

- ▶ Human papilloma virus (HPV) is now a well-known risk factor for head and neck squamous cell carcinoma (SCC).
- ▶ HPV-positive SCC cases have a better prognosis than HPV-negative ones.
- ▶ The prevalence of HPV varies greatly from one continent to another and from one country to another.

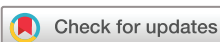### What are the new findings?

- ▶ To our knowledge, our work is the first in Egypt and one of the very few studies in Africa that shed information on HPV prevalence and its effect on survival in head and neck cancer.
- ▶ HPV is highly prevalent in oropharyngeal (OP) cancers within the Egyptian population.
- ▶ We also investigated common oral cavity cancer (lip and tongue), which is much less investigated within the literature.

### How might these results change the focus of research or clinical practice?

- ▶ In Egypt, routine use of p16 immunohistochemistry (IHC) for head and neck cancer is not yet applied.
- ▶ Our study highlighted the high prevalence of HPV, with the importance of p16 IHC application including the markers panel done on metastatic cervical lymph nodes of unknown origin for hidden sides as OP.
- ▶ The important segregation of head and neck cancers as HPV-positive and HPV-negative cases with subsequent prognostic significance will be applied within our population.

well as epidemiologic data are highlighted. HPV-associated oropharyngeal squamous cell carcinoma (OPSCC) shows wide geographic variation (<20%–80%).<sup>3</sup> Other authors reported HPV-associated oral cavity SCC cases



© American Federation for Medical Research 2019. No commercial re-use. See rights and permissions. Published by BMJ.

**To cite:** Tealab SH, Sedhom NFH, Hassouna A, et al. *J Investig Med Epub ahead of print*. [please include Day Month Year]. doi:10.1136/jim-2018-000968

to be 23.5% and laryngeal cases to be 24%. HPV16 is the HR subtype in most (>90%) of HPV-associated SCC cases.<sup>4</sup>

Most of the previously done work mentioned that patients affected with HR-HPV-related OPSCC have better prognosis, while others are still discussing that a specific treatment approach is required.<sup>5</sup> The classic OPSCC treatment is through intensive doses of radiotherapy/chemotherapy with its subsequent complications. HPV-positive OPSCC may not require this intense therapy; therefore, many clinical trials are now investigating the possibility of decreasing such aggressive treatment.<sup>6</sup>

Quantitative PCR techniques show accurate testing of viral DNA or mRNA in a sample, but laser capture microdissection is mandatory to detect the exact tumor origin of the virus. These methods are also complicated in the clinical practice.<sup>7</sup> In situ hybridization (ISH) for HR-HPV is more feasible and specific as the virus is seen within the tumor cells using ordinary light microscope. The latter's main drawback is that it is not completely sensitive.<sup>8</sup> HPV ISH sensitivity is 93%.<sup>9</sup>

HR-HPV-related cancers show overexpression of the p16 antigen. CDKN2A tumor-suppressor gene encodes the p16 protein as a result of E7 viral oncogene transcription. p16 slows down cell proliferation by inactivating the pRb protein, which binds to the E2F transcription factor with subsequent functional suppression. This strong correlation between p16 and HPV has led many authors to suggest that p16 immunohistochemistry may be used independently for HPV detection.<sup>10</sup>

## MATERIALS AND METHODS

### Patients and samples

We performed a retrospective study which included 99 patients with primary oral (lip and tongue) and OP SCC diagnosed at the Surgical Pathology Unit, National Cancer Institute, Cairo University during the period from January 2008 to December 2015. Cases with insufficient tissue material or unavailable blocks and cases with missed clinical files were all excluded.

The clinicopathologic parameters (age, sex, date of diagnosis, type of surgical resection, TNM [tumor, node, metastases] stage, stage group, date of recurrence, history of smoking, radiotherapy and chemotherapy details, and patients' outcome data) were collected from patients' files. Phone calls with the patient or a first-degree relative were done to update the follow-up data on patients' survival.

H&E-stained slides were screened to confirm diagnosis, histologic type (keratinizing or non-keratinizing) and tumor grade. Diagnosis was confirmed by two pathologists in case of discrepancy between screening and the documented diagnosis.

### HPV evaluation

We followed the diagnostic algorithm for HPV detection that is well established as mentioned in the Royal College Data Sets and agreed on by many authors, which is screening by p16 antibody then only the positive cases are further subjected to HPV DNA ISH.<sup>4,6</sup>

### p16 immunostaining

Unstained sections were cut at 4 μm and immunostaining was done on VENTANA BenchMark autostainer (Ventana Medical Systems) using CINtec p16 Histology (705–4713, Tucson, Arizona) mouse monoclonal primary antibody. Processing was done after the automated run to ensure proper dehydration, then coverslips were placed. A case of uterine cervix SCC was taken as a positive control.

p16 immunostaining was evaluated as being positive if diffuse strong cytoplasmic and nuclear reaction was identified in 70% or more of the tumor area.<sup>9</sup> Positive reaction within individual or small cell clusters was considered negative.

### DNA in situ hybridization

INFORM HPV III Family 16 Probe (B) (800–4295, Roche Diagnostics, Mannheim Germany) was used based on the producer's guidelines in association with the ISH iVIEW Blue Plus Detection Kit to stain the tissue sections (cut at 4 μm) using the automated slide-staining system VENTANA BenchMark ULTRA machine (Ventana Medical Systems). Postrun slide processing was done to ensure proper dehydration, then coverslips were placed. INFORM HPV III Family 16 Probe (B) harbor a mixture of labeled HPV genomic probes. The goal is the common HR-HPV genotypes. The probe cocktail includes the following genotypes: 16, 18, 31, 33, 35, 45, 52, 56, 58, and 66.

The control slides used showed three different cell lines on each slide (HPV 3 in 1 System Control Slide, Ventana Medical Systems), one with a high copy number, one with a low copy number and one without HPV copies which was used as a negative control. A control slide was inserted with each run.

Regular light microscopy was used to detect the staining reaction. Nuclear blue reaction was considered a positive HPV DNA test regardless of the intensity. The reaction was detected either as a diffuse (episomal) signals that are condensed in the nucleus or punctate (integrated) signals that are small granular blue dots in the nucleus; both patterns were considered positive. Absence of nuclear blue dots was considered a negative result.<sup>8,11</sup>

### Statistical analysis

Data were analyzed and described as mean±SD, median and range, or frequencies (number of cases) and percentages. Comparison of numerical variables between different study groups was done using Student's t-test for independent samples. For comparing categorical data,  $\chi^2$  test was done. Exact test was used instead when the expected frequency is less than 5.

Survival analysis was done for overall survival (OS) and disease-free survival (DFS) using Kaplan-Meier statistics, calculating the mean and median survival time for each group with their 95% CI and the corresponding survival graphs. Comparison was done between the different factors by log-rank method.

P values less than 0.05 was labeled statistically significant. All statistical calculations were done using the computer program IBM SPSS (Statistical Package for the Social Science V.22) for Microsoft Windows.

**Table 1** Clinicopathologic data of the cases according to p16-positive results (n=99)

Clinicopathologic variable	n (%)	p16-positive (n=33) (%)	P value
<b>Age</b>			
<60	48 (48.5)	17 (51.5)	0.728
≥60	51 (51.5)	16 (48.5)	
<b>Sex</b>			
Male	55 (55.6)	16 (29.1)	0.317
Female	44 (44.4)	17 (38.6)	
<b>Smoking (n=96)</b>			
Yes	72 (75)	17 (23.6)	<0.001*
No	24 (25)	16 (66.7)	
<b>Site</b>			
OP	32 (32.3)	9 (28.1)	0.126
Tongue	38 (38.4)	10 (26.3)	
Lip	29 (29.3)	14 (48.3)	
<b>Histology</b>			
Keratinizing SCC	85 (85.9)	27 (31.8)	0.415
Non-keratinizing SCC	14 (14.1)	6 (42.9)	
<b>Tumor grade</b>			
GI	17 (17.2)	9 (52.9)	0.117
GII	57 (57.6)	15 (26.3)	
GIII	25 (25.3)	9 (36)	
<b>Tumor stage</b>			
T1	27 (27.3)	9 (33.3)	0.905
T2	36 (36.4)	12 (33.3)	
T3	24 (24.2)	7 (29.2)	
T4	12 (12.1)	5 (41.7)	
<b>Lymph node stage</b>			
N0	59 (59.6)	22 (37.3)	0.476
N1	23 (32.2)	6 (26.1)	
N2	14 (14.1)	5 (35.7)	
N3	3 (3)	0 (0)	
<b>Stage group</b>			
I	21 (21.2)	7 (33.3)	0.898
II	21 (21.2)	8 (38.1)	
III	32 (32.3)	9 (28.1)	
IVA	20 (20.2)	8 (40)	
IVB	4 (4)	1 (25)	
IVC	1 (1)	0 (0)	

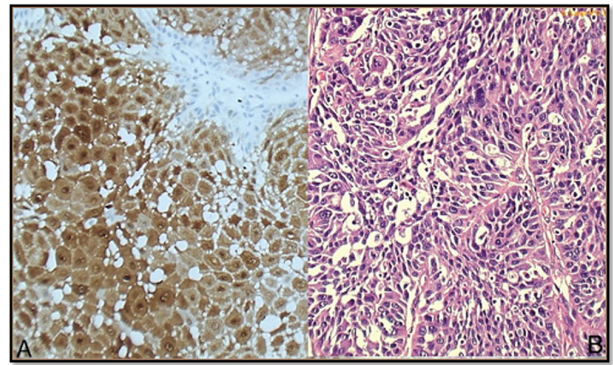
\* A highly significant negative correlation was found between p 16 and smoking; positive p 16 cases were mainly non-smokers (67%), while negative p16 cases were mainly smokers (76%)  
OP, oropharynx; SCC, squamous cell carcinoma.

## RESULTS

### Clinicopathologic features

The study included 99 cases, 55 men and 44 women (ratio 1.25:1). Their ages ranged from 22 to 87 years, with a median of 60 years and  $\pm$ SD of 14.2 years.

Seventy-two cases underwent radical surgery, while 27 did not. Forty-five cases received radiotherapy, while the remaining 54 did not. Radical dose for early stages (I and II) was 66 Gy/33 F/6.5 W, and for late stages (III and IV) was 70 Gy/35 F/7 W. Only 22 cases received chemotherapy, mainly combined with radiotherapy, while the remaining



**Figure 1** (A) p16 immunostaining shows diffuse positive nuclear and cytoplasmic reaction for non-keratinizing squamous cell carcinoma (200 $\times$ ). (B) H&E photo for the same case (100 $\times$ ).

77 cases did not. Patients and tumor characteristics of the 99 cases according to p16 results are summarized in [table 1](#).

### HPV results

Thirty-three cases (33.3%) of the studied group were positive for p16 ([figure 1](#)). When subjected to DNA ISH study, 30 out of the 33 p16-positive cases were positive for ISH ([figures 2 and 3](#)), with 91% concordance between the two tests (sensitivity=91%).

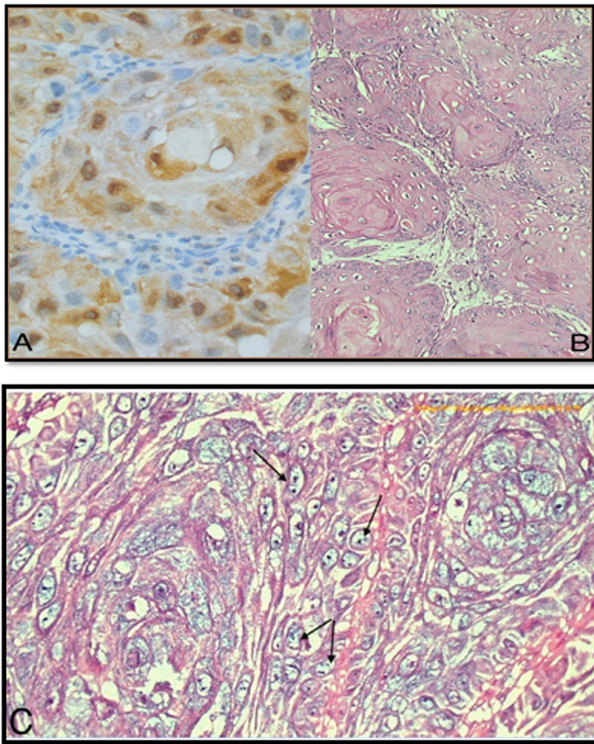
p16-positive cases were most prevalent in the lip (48%), and it was 28% within oropharyngeal (OP) cases and 26% within tongue cases ( $p=0.1$ ). A negative correlation was highly significant ( $p<0.001$ ) between p16 and smoking; positive p16 cases were mainly non-smokers (67%), while negative p16 cases were mainly smokers (76%). We found that grade 1 tumors were more likely to be p16-positive (53%) compared with grade 2 (26%) and grade 3 (36%) ( $p=0.1$ ).

### Patient outcomes

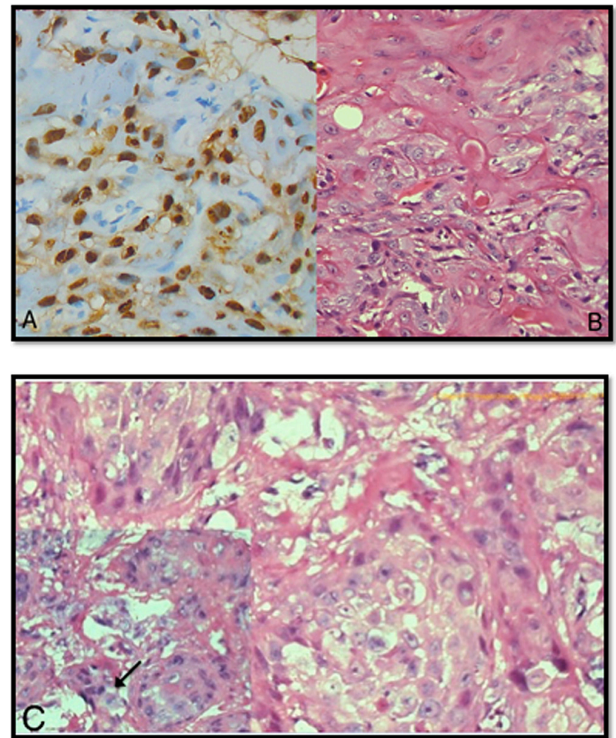
The median follow-up was 39.5 months (range, 2–113 months). Fifty-three cases (53.5%) were still alive, 39 (39.4%) died and 7 (7.1%) lost to follow-up. Metastasis was seen in only 1 OP case (1%), while 98 cases were metastasis-free (99%). Recurrence was seen in 26 cases (26.3%), while 62 cases (62.6%) were free from recurrence. Eleven cases were lost to follow-up (11.1%). Recurrence type was either local recurrence (16 cases, 16.2%) or nodal recurrence (10 cases, 10.1%).

p16-positive cases (HPV-positive) showed longer median OS time than p16-negative ones; also, the mean OS time for positive p16 OP cases was 71.4 months, while that for negative cases was 51.1 months, yet the difference was not statistically significant ( $p=0.2$ ). Among the clinicopathologic characteristics examined, a highly significant relation was found between poor OS and smoking ([figure 4](#)), higher T stage, higher N stage and higher stage group ( $p<0.001$ ).

p16-positive cases as a group as well as the OP p16-positive cases showed longer DFS than the negative ones ( $p=0.045$  and  $p=0.02$ , respectively) ([figures 5 and 6](#)). There were no recurrences detected within all positive OP cases, while negative cases showed eight recurrences. Among the clinicopathologic characteristics examined, a



**Figure 2** (A) p16 immunostaining (400×). (B) Corresponding H&E slide, oropharyngeal keratinizing squamous cell carcinoma, grade 1 (200×). (C) Human papilloma virus in situ hybridization for the same case with the arrows pointing to the nuclear blue dots indicating positive reaction (integrated form) (400×).



**Figure 3** (A) p16 immunostaining (400×). (B) Corresponding H&E slide, tongue keratinizing squamous cell carcinoma, grade 2 (200×). (C) Human papilloma virus in situ hybridization for the same case (40×). Left-sided inset showing another field with the arrow pointing to episomal form (400×).

highly significant relation was found between worse DFS and N stage, as well as stage group ( $p < 0.001$ ).

According to Cox multivariate regression, smoking was a significant predictor of OS ( $p = 0.018$ ), independent of age, site, histology, grade, T stage, N stage, stage groups and p16 (table 2). Multivariate analysis also showed stage group as a significant predictor of DFS ( $p = 0.027$ ), independent of age, site, histology, grade, T stage, N stage and p16.

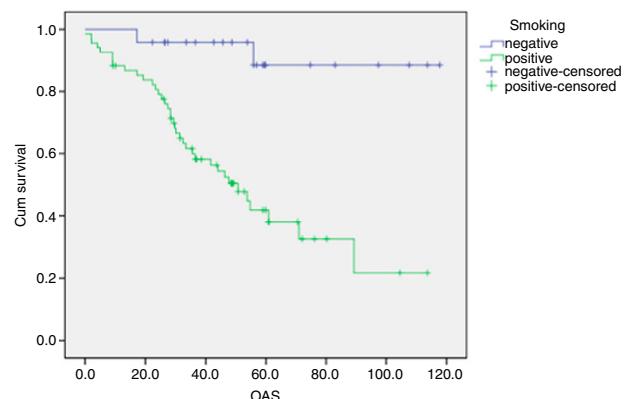
### DISCUSSION

The role of HPV in the development of HNSCC especially those arising from the oropharynx is now well established within Western Europe, North America and Asian countries.<sup>9, 12</sup> This finding is not yet well studied within the African or Egyptian population. Our aim was to provide information about the prevalence of HPV in oral and OP SCC within the Egyptian population and its relation to patients' outcome.

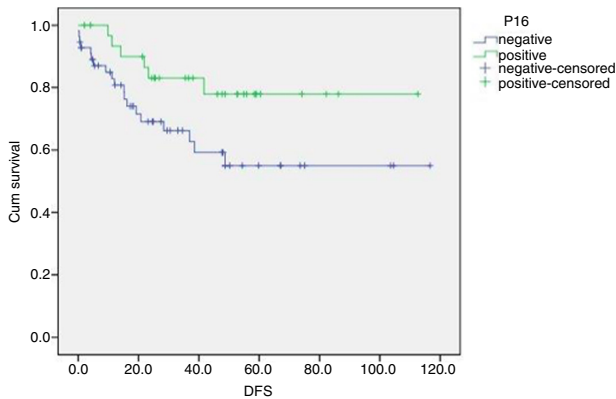
HPV-positive OP cases in our study were 28%, almost identical to the results of Toman and colleagues,<sup>12</sup> who studied 43 OP cases in Japan and found that 29.5% of them were HPV-positive.<sup>13</sup> In USA, the study proposed by Posner and colleagues<sup>13</sup> who worked on 111 OP cases showed a higher prevalence (50%), and Singhi and Westra<sup>9</sup> detected 81% positive HPV OP cases from 143 cases. The highest prevalence was found in Europe, 93% in a Swedish study.<sup>14</sup> This may be attributable to different cultural and social backgrounds as HPV is a sexually transmitted disease. Other explanation may be false-negative results in our study

due to inappropriate storage of some of our paraffin blocks especially the old ones (the average percentage of positive cases/year was 20% for years 2008 and 2009, while it was 50% for years 2014 and 2015).

In our series, the prevalence of HPV in tongue and lip lumped together was 37%, a percentage higher than that expected in the literature. Most of the work on oral cavity, which is much less than that on OP, showed lower prevalence reaching 0% from some authors.<sup>10</sup> In contrast a bibliographic search in the PubMed databases reviewing all related studies found that the oral cavity HPV prevalence



**Figure 4** Overall survival (OAS) curve in relation to smoking. Cum, cumulative.



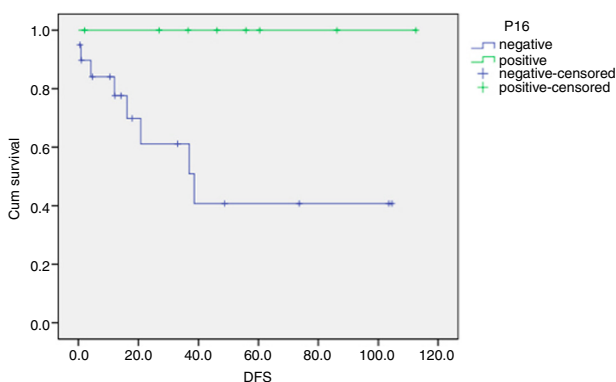
**Figure 5** Disease-free survival (DFS) curve in relation to p16. Cum, cumulative.

within 21 studies was 13.5%, while that within 11 studies was 45%.<sup>15</sup>

Another series by Witt and colleagues<sup>16</sup> showed an oral cavity HPV prevalence of 22.8%. These wide variations, as shown in table 3, may also be attributed to different detection methods for HPV for each study with the absence of a single gold standard test. In addition, some studies targeted only HPV type 16, ignoring other HR oncogenic types.

The sensitivity of p16 in our work was almost similar to that in the literature (>90%). Ang and colleagues<sup>17</sup> found 93.2% concordance between p16 and HPV DNA ISH testing (192 positive ISH cases out of 206 p16-positive cases). Doxtader and Katzenstein<sup>18</sup> detected slightly higher percentage (96%) between the former two tests (24 positive ISH cases out of 25 p16-positive cases) and Lewis and colleagues<sup>7</sup> concluded a slightly lower percentage (88%).

p16 immunostaining is an available marker, easy to perform, easy to interpret and the cheapest when compared with other detection methods.<sup>19</sup> It will be overexpressed when there is HPV infection through the role of E7 oncoprotein in degrading the Rb protein. In contrast, the non-HPV-related cancers show a negative reaction as p16 is a cell cycle regulator which will be absent as the gene is deleted, mutated or methylated.<sup>7</sup> This is why p16 is now considered a stand-alone test for HPV detection.



**Figure 6** Disease-free survival (DFS) curve in relation to oropharyngeal p16. Cum, cumulative.

**Table 2** Logistic regression equation for overall survival in relation to smoking

	Coefficient	SE	95% CI		P value
			Upper	Lower	
Smoking	-1.97	0.83	0.027	0.711	0.018

Smoking, which is the main popular etiologic factor for HNSCC, was an important clinical variable in our work. We found a significant inversely proportional relation between smoking and HPV status. HPV-positive cases were mainly non-smokers (67%), a finding similar to other reports on head and neck cancer,<sup>7,20</sup> which confirms that HPV is another separate risk factor for the occurrence of HNSCC even in the absence of smoking.

Similar to most of the published work, we detected a significant difference between better DFS and HPV-positive cases. When comparing with the head and neck subsites, DFS in OP cases also showed statistically significant difference.<sup>16,21</sup> The biological explanation of such slower disease progression within the HPV positive group is, to a large extent, not yet known, but it is possibly secondary to host immune response against the viral infection and that the immunologic evasion is damaged as a consequence of viral treatment.<sup>22</sup>

We could not find statistically significant relation between HPV-positive cases and OS, although there was an obvious longer median survival time in the positive cases as a group and in the subgroups as well. Only few authors showed similar results to ours.<sup>23,24</sup>

Comparison of HPV-positive and HPV-negative subgroups showed no significant differences in OS, in contrast to most of the published data showing better OS in HPV-positive cases, and this difference is more pronounced in the OP subsite,<sup>5,25,26</sup> the latter studied 517 OPSCC and 845 non-OP HNSCC cases across three continents: USA,

**Table 3** Prevalence of HPV in HNSCCs by cancer site and geographic location

Continent	Studies (n)	Cases (n)	HPV prevalence (%)
Europe			
OP	17	529	28.2
OC	15	744	16
North America			
OP	7	285	47
OC	8	577	16.1
Asia			
OP	4	54	46.3
OC	13	133	22.3
Others*			
OP	2	101	36.6
OC	2	188	18.1
Our Egyptian study			
OP	1	32	28
OC	1	67	37

\*Includes Central and South America, Australia, and Africa.<sup>29</sup>

HNSCC, head and neck squamous cell carcinoma; HPV, human papilloma virus; OC, oral cavity; OP, oropharynx.

Europe and Brazil. The controversy may be due to the relatively small sample size in the current study. Another explanation could be the high percentage of smokers in our studied cases (75%). Smoking masks the good effect of HPV on survival through widespread genetic alterations (ie, field cancerization) that worsen the prognosis.<sup>27</sup>

Similar to our multivariate analysis findings, D'Souza and colleagues<sup>26</sup> did not find that HPV positivity is an independent predictor for both overall and disease-free survival. They found that age, stage and alcohol consumption were independent factors. In contrast Sarkar and colleagues<sup>21</sup> found that HPV negativity is an independent factor for worse OS, besides grade and stage. Huang and colleagues<sup>28</sup> also confirmed that HPV status showed a reduced risk of death after adjusting for other variables. These discrepancies may be attributed to the different populations under study. Further studies in a similar population with standardization of test techniques are needed.

This study has several strengths and limitations. One of the best strengths is that, to our knowledge, our work is the first in Egypt and one of the very few studies in Africa that shed information on HPV prevalence and its effect on survival in head and neck cancer.

One of the limitations was that we did not have the opportunity to study other subsites of the oral cavity and hypopharynx due to limited resources, which prohibited us from increasing our sample size. We also had some cases with lost follow-up, which further decreased the sample size as regards survival results. We also followed the established guidelines of performing ISH only to cases with positive p16 reaction, and this did not allow us to calculate the sensitivity and the positive predictive value of p16 compared with the ISH as a gold standard.

Further larger studies are highly recommended to provide a complete idea about the true prevalence of HPV within the Egyptian population as well as the whole African population.

**Acknowledgements** Dr Magdy Ibrahim (Director, Research & Biostatistics Unit, MEDC, Cairo University) analyzed the data.

**Contributors** IG, NFHS, AH and HI conceived and designed the study. SHA performed the laboratory work. IG and SHA wrote the paper.

**Funding** The authors have not declared a specific grant for this research from any funding agency in the public, commercial or not-for-profit sectors.

**Competing interests** None declared.

**Patient consent for publication** Not required.

**Provenance and peer review** Not commissioned; externally peer reviewed.

## REFERENCES

- 1 Ferlay J, Shin HR, Bray F, et al. Estimates of worldwide burden of cancer in 2008: GLOBOCAN 2008. *Int J Cancer* 2010;127:2893–917.
- 2 Argiris A, Karamouzis MV, Raben D, et al. Head and neck cancer. *Lancet* 2008;371:1695–709.
- 3 Marur S, D'Souza G, Westra WH, et al. HPV-associated head and neck cancer: a virus-related cancer epidemic. *Lancet Oncol* 2010;11:781–9.
- 4 Schache A, Croud J, Robinson M, et al. *Human Papillomavirus Testing in Head and Neck Squamous Cell Carcinoma: best practice for diagnosis*. New York, NY: Humana Press, 2014:237–55.
- 5 Dayyani F, Etzel CJ, Liu M, et al. Meta-analysis of the impact of human papillomavirus (HPV) on cancer risk and overall survival in head and neck squamous cell carcinomas (HNSCC). *Head Neck Oncol* 2010;2:15.
- 6 Robinson M, Sloan P, Shaw R. Refining the diagnosis of oropharyngeal squamous cell carcinoma using human papillomavirus testing. *Oral Oncol* 2010;46:492–6.
- 7 Lewis JS, Thorstad WL, Chernock RD, et al. p16 positive oropharyngeal squamous cell carcinoma: an entity with a favorable prognosis regardless of tumor HPV status. *Am J Surg Pathol* 2010;34:1088–96.
- 8 Guo M, Gong Y, Deavers M, et al. Evaluation of a commercialized in situ hybridization assay for detecting human papillomavirus DNA in tissue specimens from patients with cervical intraepithelial neoplasia and cervical carcinoma. *J Clin Microbiol* 2008;46:274–80.
- 9 Singhi AD, Westra WH. Comparison of human papillomavirus in situ hybridization and p16 immunohistochemistry in the detection of human papillomavirus-associated head and neck cancer based on a prospective clinical experience. *Cancer* 2010;116:2166–73.
- 10 Ragin CC, Taioli E, Weisfeld JL, et al. 11q13 amplification status and human papillomavirus in relation to p16 expression defines two distinct etiologies of head and neck tumours. *Br J Cancer* 2006;95:1432–8.
- 11 Thomas M, Grogan MD. *Interpretation Guide for Ventana INFORM® HPV Probes In Situ Hybridization (ISH) Staining of Cervical Tissue*. Ventana, 2006:18.
- 12 Toman J, Von Larson S, Umeno H, et al. HPV-Positive Oropharyngeal Cancer Via p16 Immunohistochemistry in Japan. *Annals of Otolaryngology & Laryngology* 2017;126:152–8.
- 13 Posner MR, Lorch JH, Goloubeva O, et al. Survival and human papillomavirus in oropharynx cancer in TAX 324: a subset analysis from an international phase III trial. *Ann Oncol* 2011;22:1071–7.
- 14 Näsman A, Attner P, Hammarstedt L, et al. Incidence of human papillomavirus (HPV) positive tonsillar carcinoma in Stockholm, Sweden: an epidemic of viral-induced carcinoma? *Int J Cancer* 2009;125:362–6.
- 15 Ragin CC, Taioli E. Survival of squamous cell carcinoma of the head and neck in relation to human papillomavirus infection: review and meta-analysis. *Int J Cancer* 2007;121:1813–20.
- 16 Witt BL, Albertson DJ, Coppin MG, et al. Use of in situ hybridization for HPV in head and neck tumors: experience from a national reference laboratory. *Head Neck Pathol* 2015;9:60–4.
- 17 Ang KK, Harris J, Wheeler R, et al. Human papillomavirus and survival of patients with oropharyngeal cancer. *N Engl J Med* 2010;363:24–35.
- 18 Doxtader EE, Katzenstein AL. The relationship between p16 expression and high-risk human papillomavirus infection in squamous cell carcinomas from sites other than uterine cervix: a study of 137 cases. *Hum Pathol* 2012;43:327–32.
- 19 Chernock RD, El-Mofty SK, Thorstad WL, et al. HPV-related nonkeratinizing squamous cell carcinoma of the oropharynx: utility of microscopic features in predicting patient outcome. *Head Neck Pathol* 2009;3:186–94.
- 20 El-Naggar AK, Chan JKC, Grandis JR, et al. WHO Classification of Head and Neck Tumours. *International Agency for Research on Cancer* 2017:347.
- 21 Sarkar S, Alam N, Chakraborty J, et al. Human papilloma virus (HPV) infection leads to the development of head and neck lesions but offers better prognosis in malignant Indian patients. *Med Microbiol Immunol* 2017;206:267–76.
- 22 Ljøkjel B, Lybak S, Haave H, et al. The impact of HPV infection on survival in a geographically defined cohort of oropharynx squamous cell carcinoma (OPSCC) patients in whom surgical treatment has been one main treatment. *Acta Otolaryngol* 2014;134:636–45.
- 23 Azzimonti B, Pagano M, Mondini M, et al. Altered patterns of the interferon-inducible gene IFI16 expression in head and neck squamous cell carcinoma: immunohistochemical study including correlation with retinoblastoma protein, human papillomavirus infection and proliferation index. *Histopathology* 2004;45:560–72.
- 24 Hoffmann M, Görögh T, Gottschlich S, et al. Human papillomaviruses in head and neck cancer: 8 year-survival-analysis of 73 patients. *Cancer Lett* 2005;218:199–206.
- 25 Sethi S, Ali-Fehmi R, Franceschi S, et al. Characteristics and survival of head and neck cancer by HPV status: a cancer registry-based study. *Int J Cancer* 2012;131:1179–86.
- 26 D'Souza G, Anantharaman D, Gheit T, et al. Effect of HPV on head and neck cancer patient survival, by region and tumor site: a comparison of 1362 cases across three continents. *Oral Oncol* 2016;62:20–7.
- 27 Pai SI, Westra WH. Molecular pathology of head and neck cancer: implications for diagnosis, prognosis, and treatment. *Annu Rev Pathol* 2009;4:49–70.
- 28 Huang S, Patel S, O'Sullivan B, et al. Longer survival in HPV-Related head-and-neck cancer patients following positive post-radiation planned neck dissection. *Int J Radiat Oncol Biol Phys* 2014;88:486.
- 29 Kreimer AR, Clifford GM, Boyle P, et al. Human papillomavirus types in head and neck squamous cell carcinomas worldwide: a systematic review. *Cancer Epidemiol Biomarkers Prev* 2005;14:467–75.