

High-risk human papillomavirus infection in pregnant women: a descriptive analysis of cohorts from two centers

Jing Liu,¹ Yuhong Li,² Di Bo,¹ Jiandong Wang ,³ Yudong Wang²

¹Department of Obstetrics, Beijing Obstetrics and Gynecology Hospital, Capital Medical University, Beijing, People's Republic of China

²Department of Gynecologic Oncology, International Peace Maternity and Child Health Hospital, Shanghai Jiao Tong University School of Medicine, Shanghai, People's Republic of China

³Department of Gynecological Oncology, Beijing Obstetrics and Gynecology Hospital, Capital Medical University, Beijing, People's Republic of China

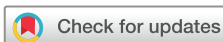Correspondence to

Dr Jiandong Wang, Department of Gynecological Oncology, Beijing Obstetrics and Gynecology Hospital, Capital Medical University, Beijing, China; wangjiandongxy@ccmu.edu.cn

Dr Yudong Wang; wangyudong6688@126.com

JL and YL contributed equally.

Accepted 1 June 2022



© American Federation for Medical Research 2022. No commercial re-use. See rights and permissions. Published by BMJ.

To cite: Liu J, Li Y, Bo D, et al. *J Investig Med* Epub ahead of print: [please include Day Month Year]. doi:10.1136/jim-2022-002442

ABSTRACT

The aim was to descriptively analyze the clinical characteristics, cytopathology, and outcomes of pregnant patients with high-risk human papillomavirus (HPV) infection. Clinical data of 151,516 female patients with high-risk HPV infection were retrospectively collected. Baseline data, cervical cytology results, histopathology, HPV types, delivery mode, and follow-up outcomes were recorded for descriptive analysis. A total of 157 patients were identified as positive for high-risk HPV. There were 32 (24.2%), 6 (4.5%), and 107 (81.1%) cases of HPV-16, HPV-18, and other types, respectively. Additionally, 12 patients showed combined infection with HPV-18 or HPV-16 and other types. Cytopathological examinations showed that the most common type was low-grade squamous intraepithelial lesion (LSIL; 104 cases, 78.8%), followed by high-grade squamous intraepithelial lesion (HSIL; 17 cases, 12.8%), atypical squamous cells of undetermined significance (10 cases, 9.6%), and cervical cancer (1 case, 0.7%). Thirty-seven patients underwent colposcopic biopsy, of whom 9 (24.3%) showed normal results, while 12 (32.4%) and 13 (35.1%) patients had LSIL and HSIL, respectively. χ^2 tests demonstrated that different delivery modes did not show significant difference in patients' cervical cytopathology ($p > 0.05$). However, therapeutic methods were statistically different among patients with different cytopathological types ($p < 0.05$). Cervical alterations in pregnancy mostly go along with high-risk HPV infection. High-risk HPV infection in pregnancy with abnormal cervical cytology should be followed closely during the pregnancy and postpartum period.

INTRODUCTION

Human papillomavirus (HPV) is the primary cause of cervical lesions. It has been well established that long-term HPV infections in the cervical area significantly increase the risk of cervical cancer (CC),¹ which is more evident during pregnancy due to hormone levels, suppression of immunity, and the rich supply of blood of the reproductive organs.² However, the frequency of HPV infection during pregnancy varies according to the characteristics of the population studied and the sensitivity of the viral detection method used, which ranges

WHAT IS ALREADY KNOWN ON THIS TOPIC

- ⇒ Human papillomavirus (HPV) is the primary cause of cervical lesions.
- ⇒ Screening and detection of HPV subtypes, especially high-risk HPV, are of great clinical significance for early prevention of cervical cancer.

WHAT THIS STUDY ADDS

- ⇒ The proportion of women with HPV infection during pregnancy is not high.
- ⇒ Patients with cervical lesions during pregnancy showed a relatively high proportion of combined high-risk HPV infections, with low-grade squamous intraepithelial lesion as the primary cytological abnormality.

HOW THIS STUDY MIGHT AFFECT RESEARCH, PRACTICE AND/OR POLICY

- ⇒ Treatment of pregnancy complicated with cervical cancer should be determined according to gestational weeks, stages, and patient expectations.

from 5.5% to 65%.³ Studies have shown that the prevalence of HPV infection during pregnancy is closely related to the age of women and decreases significantly after 30 years old. The risk factors associated with HPV infection during pregnancy include a high number of sexual partners, especially before the age of 20, and a history of sexually transmitted diseases.⁴ At present, about 200 types of HPV have been discovered.⁵ According to their role in the pathogenesis of cervical diseases, HPV can be divided into high-risk (HR) and low-risk (LR) HPV.⁶ Many studies have shown that HR-HPV types, particularly types 16, 18, and 58, are the main causes of CC.⁷ The distribution of HR-HPV varies in different regions of the world. In North America, HPV types 16, 53, 18, 51, and 31 are the top five common types, while the commonly observed types in Eastern Europe are types 16, 31, 18, 66, and 39.⁸ Even within a country, the prevalence of HPV subtypes is not the same across different regions.^{9–11} Therefore, screening and detection

of HPV subtypes, especially HR-HPV, are of great clinical significance for early prevention of CC.

HPV can be transmitted from the mother to the child. Infection occurs through the transmission of virions or infected epithelial cells by direct contact of the fetus with the infected maternal genital tract. The rate of transmission is correlated with maternal viral load. Arguments in favor of this mode of transmission are the similarity of histological aspects and HPV types in maternal condylomas and infant papillomas. According to the genome detection in newborns, the risk of HPV infection in newborns ranges from 5% to 8%, with a mean proportion of 6.5%, and the overall rate of intrauterine HPV transmission is 4.9% (95% CI 1.6 to 9.8).¹² However, these results should be interpreted with caution due to heterogeneity between the studies considered. Interestingly, the mode of delivery is an important factor affecting the vertical transmission of HPV since the transmission rate in women with cesarean section is significantly lower than with vaginal delivery.¹³ Currently, HPV testing, ThinPrep cytological test (TCT), and colposcopic biopsy are the commonly used methods for classification, screening, and diagnosis of women with cervical lesions. Screening of women with HPV-16 or HPV-18 can improve the detection of cervical intraepithelial neoplasia (CIN) and this method is superior to liquid-based cytology (LBC).^{14,15} Combined HPV testing and LBC can increase the rate of identification of CC in women older than 30 years old.¹⁶ In addition, HPV screening plays a role in improving the outcome of patients with CC.¹⁷ The morbidity and mortality of patients with CC were significantly reduced with adjusted strategies during follow-up by HPV testing.¹⁸ However, few studies have reported the effect of HR-HPV screening and cervical examinations in pregnant women and their infants.

Therefore, in this study, we attempt to investigate the relationship between HR-HPV infection and cervical changes by TCT and pathological examinations and conduct follow-up of outcomes of both pregnant women and their infants, thereby improving our understanding of the prognosis of pregnant women with HR-HPV infection.

METHODS

Informed consent

Our study is an observational study and does not involve sampling of human specimens, does not include personal information, has passed ethical application, and does not require informed consent of patients.

Subjects

We retrospectively included perinatal pregnant women with HR-HPV infection who underwent regular examination at the Department of Obstetrics, Beijing Obstetrics and Gynecology Hospital, Capital Medical University and at Shanghai Jiaotong University School of Medicine from January 2015 to January 2020. According to the Chinese Medical Association 2014 guidelines, clinical diagnosis, and treatment for preterm birth,¹⁵ the perinatal period of pregnancy is defined as gestation ≥ 28 weeks or an infant birth weight of ≥ 1000 g. In our study, we excluded pregnant women with gestation less than 28 weeks. The inclusion criteria were women who delivered from January

2015 to January 2020 at Beijing Obstetrics and Gynecology Hospital and Shanghai First Maternity and Infant Hospital and who underwent cervical cytology and HPV screening. The results showed that HR-HPV was positive, the gestational age of delivery was more significant than or equal to 28 weeks, and the neonatal weight was more significant than or equal to 1000 g. The exclusion criteria were pregnant women who delivered at the hospital during the same period but with missing data on cervical cytology or HPV examination, with examination showing low-risk HPV, delivered before 28 weeks, or with infant birth weight of less than 1000 g.

Clinical data of 151,516 pregnant women were collected, including birth age, week of gestation, birth method, history of therapy, and TCT and HPV test results. Pregnant women all had good outcomes and there were no complications and postpartum hemorrhages related to HPV infection. All neonatal outcomes were also good.

Liquid-based, thin-layer cytology test

A liquid-based, thin-layer cytology test (TCT) was performed in our study at 14–25 weeks of gestation. Epithelial cells of the cervical surface and cervical canal cells were collected with special brushes purchased from Digene. All doctors used the same method in obtaining cervical cells, rotating in three cycles. The cervical tube brush was left for 1 min on the external cervical orifice. Diagnostic standards and classifications were based on The Bethesda System from the cervical cell classification system of the International Cancer Association: no intraepithelial lesions and malignant tumor cells; squamous cell abnormalities (atypical squamous cell, low-grade squamous intraepithelial neoplasia, high-grade squamous intraepithelial neoplasia, squamous cell carcinoma); abnormal glandular epithelial cells (atypical glandular epithelial cells, adenocarcinoma in situ, adenocarcinoma); and other malignant tumors.

HPV test

Detection of HR-HPV load was performed at 8–12 weeks of gestation in patients with CIN using hybrid C-II qualitative and semiquantitative detection methods. Biopsy was performed simultaneously in those with suspected cervical lesions; colposcopy re-examination was also performed. Biopsy was also taken with suspicious cervical lesions and those at high risk.

Colposcopy and cervical biopsy

The cervix and the vagina were exposed after emptying the bladder and cervical secretions and mucus were wiped off. The shape, size, color, plaques, and vegetations in the cervix were observed under naked eyes, and the cervical surface was smeared with a cotton ball dipped in 3%–5% acetic acid to clearly observe morphological changes in the blood vessels. After the acetic acid test, the cervical surface was smeared with compound iodine solution. A biopsy was taken from the opposing area where iodine test was negative and sent for pathological examination.

Following the standards formulated by the International Federation of Cervical Pathology and Colposcopy, an abnormal cervix was described and diagnosed by professional doctors using photoelectric integrated digital

electronic colposcopy. Cervical biopsy was performed in patients with CIN; two experienced doctors made the pathological diagnosis and 5% of the pathological sections of CIN were checked every 4 months for quality control, based on the standards of the International Classification of Diseases compiled by the WHO.

In this study, we collected the general data of all pregnant women with HR-HPV infection who delivered at two hospitals in Beijing and Shanghai within 5 years and whose cervical cytopathological examination showed atypical squamous cells of undetermined significance (ASCUS) or higher. If pregnant women had been given TCT within 1 year, this would not be performed again during pregnancy due to the anxiety brought by abortion; hence, the screening rate in Beijing was only 30%. Patients were immediately treated and their pregnancy terminated when CIN developed into CC.

Statistical analysis

SPSS V.25.0 was used for data analysis. All numerical variables were tested for normality and those with normal distribution were expressed by mean \pm SD. Several cases and percentages presented categorical variables and χ^2 test was used for comparison. $P < 0.05$ was considered to indicate statistically significant difference. Correlation analyses between types of HPV, grade of cervical cytology, and cure rate were performed using χ^2 test.

RESULTS

General data

A total of 151,516 women delivered at the two hospitals from January 2015 to January 2020. All patients (100%) in Shanghai underwent TCT and HPV tests.

Among the women, 132 were identified as positive for HR-HPV infection, ranging in age from 22 to 40 years old, with an average age of 31.26 \pm 4.026 years. Of the women, 71 (53.8%) were in their first pregnancy, while 61 (46.2%) were in their second pregnancy or more; 86 (65.2%) had no history of parturition, while 46 (34.8%) had a history of delivery of more than once. Of the women, 83 (62.8%) had no history of abortion (table 1).

HPV infection in pregnant women

There were 169 pregnant women with HR-HPV infection, with a rate of 0.16%. Of 322 cases, 169 (52.48%) patients had positive HR-HPV, with cervical diseases including CIN, ASCUS, and CC such as squamous cell carcinoma and adenocarcinoma.

The patients were divided into three groups in terms of HPV type: HPV-16, HPV-18, and other high-risk types. Patients with HPV-16 or HPV-18 infection combined with different high-risk types were classified into a fourth group. The results showed 32 cases (24.2%) of HPV-16 and 6 cases (4.5%) of HPV-18, with 107 cases (81.1%) of other types; there were 12 patients with HPV-16 and HPV-18 combined with other high-risk infections (table 1).

Results of cervical cytopathology and biopsy

Of 132 cases, 85 (64.4%) underwent colposcopy examination. Cytopathological analysis showed that the most common type was low-grade squamous intraepithelial

Table 1 Clinical characteristics of included patients

Age (years)	31.26 \pm 4.03 (22–40)
Gravidity	
1	71 (53.79)
≥ 2	61 (46.21)
Pregnancy	
0	86 (65.15)
≥ 1	46 (34.85)
Abortion	
0	83 (62.88)
1	30 (22.73)
≥ 1	19 (14.39)
Cervical cytology	
ASCUS	10 (7.57)
LSIL	104 (78.79)
HSIL	17 (12.88)
Cervical cancer	1 (0.76)
HPV type	
HPV-16	32 (20.38)
HPV-18	6 (2.87)
Other types	107 (68.15)
HPV-16 or HPV-18 with other types	12 (7.64)
Colposcopic examination	
Yes	85 (64.39)
No	47 (35.61)
Histological type	37
Normal	9 (24.32)
LSIL	12 (32.43)
HSIL	13 (35.14)
SCC	2 (5.40)
Adenocarcinoma	1 (2.70)
Delivery mode	
Vaginal birth	68 (51.52)
Cesarean section	64 (48.48)

ASCUS, atypical squamous cells of undetermined significance; HPV, human papillomavirus; HSIL, high-grade squamous intraepithelial lesion; LSIL, low-grade squamous intraepithelial lesion; SCC, squamous cell carcinoma.

lesion (LSIL; 104 cases, 78.8%), followed by high-grade squamous intraepithelial lesion (HSIL; 17 cases, 12.8%), ASCUS (10 cases, 9.6%), and CC (1 case, 0.7%) (table 1). In the case of CC, an exophytic neoplasm was seen and was suspected to be malignant, with cervical adenocarcinoma detected on biopsy. No malignant alterations on cytology were found in other patients.

Of the patients, 37 underwent colposcopic biopsy, of whom 9 (24.3%) showed normal results, while 12 (32.4%) and 13 (35.1%) patients had LSIL and HSIL, respectively. Moreover, two cases (5.4%) of squamous carcinoma and one case (0.7%) of adenocarcinoma were identified (table 1). Two cases of cervical squamous cell carcinoma in our study did not have exophytic neoplasm visible on vaginal examination. In one case, TCT showed HSIL and the HPV type was unknown. In the other case, cytological examination showed an LSIL.

Relationship between delivery mode, therapeutic regimen, and cytopathological types

In our study, we also compared the delivery modes of pregnant women with abnormal TCT and HR-HPV infection. All

Table 2 Delivery mode and therapeutic regimen of patients with different cervical cytological types

	ASCUS	LSIL	HSIL	χ^2	P value
Delivery mode				0.76	0.683
CS	3	37	8		
VB	7	52	9		
Therapeutic regimen				19.31	0.037
No therapy	3	51	3		
LEEP	0	6	4		
CKC	0	1	1		
Operation	1	2	0		
RT+CT	0	1	0		
Operation+RT+CT	0	1	0		

ASCUS, atypical squamous cells of undetermined significance; CKC, cold knife conization; CS, cesarean section; CT, chemotherapy; HSIL, high-grade squamous intraepithelial lesion; LEEP, loop electrosurgical excision procedure; LSIL, low-grade squamous intraepithelial lesion; RT, radiation therapy; VB, vaginal birth.

patients did not have severe neonatal asphyxia and cervical laceration. Of the 132 patients, 68 (51.5%) had vaginal delivery (including forceps delivery) and 64 (48.5%) underwent cesarean section (table 1). In patients who had vaginal delivery, there were 7, 52, and 9 cases of ASCUS, LSIL, and HSIL, respectively, and in patients with cesarean section there were 3, 37, and 8 cases, respectively. No significant difference in cytopathological type was detected between patients with different delivery modes ($p=0.683$; table 2).

Patients who were lost to follow-up were excluded from further analysis. Three patients with ASCUS were not treated. One case with LSIL on TCT during pregnancy and

cervical squamous carcinoma on biopsy after delivery was treated by surgery. Of the patients with LSIL, 51 were not treated, while 6 patients were treated with loop electrosurgical excision procedure (LEEP), 1 underwent cold knife conization (CKC), and 4 received surgery or postoperative chemoradiotherapy. Of the patients with HSIL, three cases were untreated, while four patients were given LEEP and one was treated with CKC. The treatment method was statistically different in patients with varying TCT results ($p=0.037$; table 2).

Follow-up results

Our group planned to follow up with all patients after delivery, half a year after delivery, and 2 years after delivery. All patients should be tested for TCT and HPV type and therapy analyzed according to the corresponding results. However, due to personal factors of patients, there was an individual rate of loss to follow-up. Of 132 patients, 60 were followed up after delivery, 62 were lost to follow-up, 10 were negative for HR-HPV, and 50 remained positive for HR-HPV. Of the patients, 37 were followed up 6 months after delivery, of whom 15 were positive for HR-HPV and 5 were not detected with HPV. Of the patients, 26 were followed up for 2 years, of whom 6 were still positive for HR-HPV and 13 were negative. In seven cases, HR-HPV was not detected again (figure 1).

DISCUSSION

CC is one of the most common gynecological malignancies.¹⁹ According to standardized diagnosis and treatment guidelines for CC and precancerous lesions issued by the National Health and Family Planning Commission, HPV

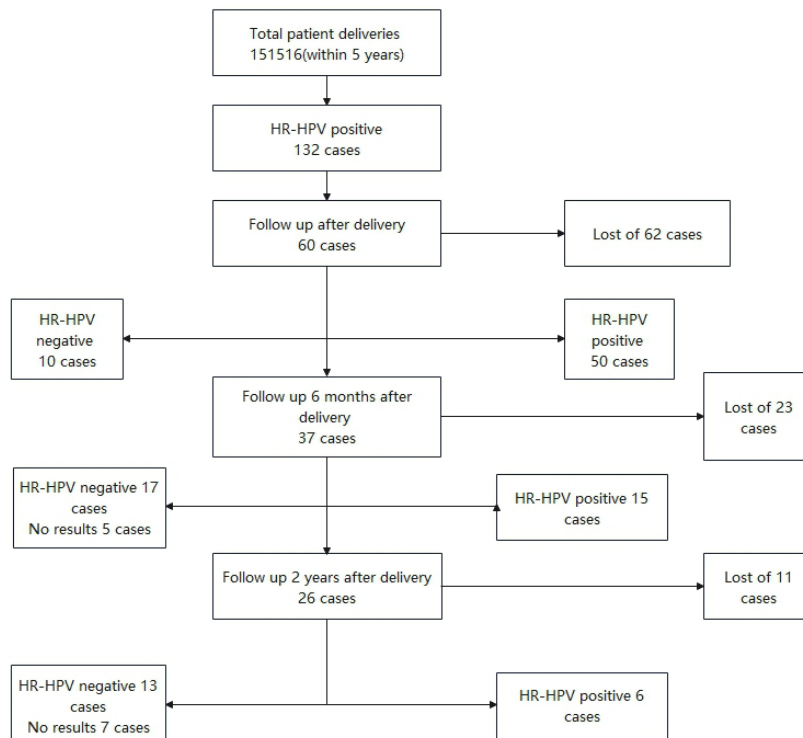


Figure 1 Flow chart of follow-up in the study. HR-HPV, high-risk human papillomavirus.

infection is the leading cause of CC.²⁰ TCT and HPV screening are needed during pregnancy. TCT screening has limitations due to the operator's reasons. Cells from the deep layers of the cervix cannot be obtained, even if professional doctors were collecting them. HPV screening can be done simultaneously with CC screening. The prevalence of HPV infections during pregnancy is higher than that observed in the population outside of pregnancy, probably due to decreased clearance of HPV infection observed in the first two trimesters of pregnancy. At the same time, viral replication is more important during early pregnancy, where the number of viral copies is almost 10 times higher than in non-pregnant women, probably favored by gravidic immunodepression and increase in steroid hormones (progesterone and glucocorticoid). A decrease in the prevalence of HPV infection is observed in the third trimester of pregnancy,²¹ which seems to be related more to modifications in sexual behaviors (greater stability in the couple and less frequent sexual intercourse) than to modifications in the biological determinants of persistent infection. Women of child-bearing age who are sexually active are easily infected with HPV. After pregnancy, combined with change in hormone levels and immunity, HPV infection is more likely to occur. Therefore, in pregnant women who have not undergone TCT or sustained HPV infection screening within 1 year, TCT and HPV screening should be performed. However, due to the anxiety brought by abortion, bleeding, or infection, the screening rate in early pregnancy at our centers was lower than in other studies. Another study showed that the HPV infection rate during pregnancy was 10%–18%,²² which was not consistent with this study. However, in our study, we selected not only patients with HPV infection but also those with cytological alterations.

In clinical practice, the diagnosis of cervical lesions is difficult. Regardless of location, clinical lesions may be associated with subclinical or even latent infection. These associated subclinical lesions are frequent and should be the subject of a complete cytocolposcopic evaluation of the entire lower genital tract. They occur mainly in the transformation zone of the cervix as pure HPV infection (condyloma planus) or HPV-associated neoplasia (CIN). Cervical smear is the usual means of screening for these lesions, but does not provide an accurate diagnosis of the lesion. The indications for colposcopy are the same in pregnant and non-pregnant women. Pregnancy is not a contraindication to directed biopsy. It is preferable to use smaller, perfectly sharp forceps so as not to cause abundant bleeding. Biopsy is particularly indicated in cases of extensive lesions suggestive of high-grade CIN or invasive lesions, and in cases of equivocal or questionable colposcopic abnormalities.²³ Despite the effects of gestational changes on the cervix, colposcopy remains a reliable examination in pregnant women. The proportion of satisfactory colposcopy is higher and increases with gestational age. With directed biopsy, the concordance of the diagnosis during pregnancy with the final diagnosis in the postpartum period is 85% for low-grade CIN and 90% for high-grade CIN.²⁴ This reliability allows CIN to be monitored during pregnancy and treated appropriately after delivery. It usually avoids the need for diagnostic LEEP.²⁵ Indications for LEEP in pregnancy should be limited to patients with a smear suggestive of cancer whose upper limit of the lesion cannot be seen

by unsatisfactory colposcopy and to patients whose biopsy shows microinvasive carcinoma or adenocarcinoma in situ, suggesting a more advanced, that is, invasive, lesion outside the biopsy site.

The relationship between HPV infection and progress of labor is the issue we discussed in our study. In the absence of specific treatment for HPV, the objective of treatment in pregnant women is more on the prevention of maternal symptomatic complications than reduction of HPV transmission to the fetus or the newborn. We compared differences in delivery with cesarean section and vaginal birth, and found there was no significant difference in neonatal complications, premature rupture of membranes, cervical laceration, and postpartum hemorrhage, which was consistent with most previous studies.^{26,27} Therefore, we consider that HR-HPV infection combined with cervical lesions does not affect the regression of the cervix and the expansion of the uterine orifice, and will not lead to changes in cervical texture and increase the risk of cervical laceration. Meanwhile, the regression and expansion of the cervix or even cervical lacerations do not affect the spread of HPV infection.

Relationship between HPV infection and newborns and preterm birth

In 2019, Aldhous and colleagues²⁸ found that there was no significant correlation between HR-HPV infection and preterm birth, but there was an absolute correlation between high-grade cervical lesions caused by HPV infection and preterm birth. In this study, there were nine cases of preterm infants, including one case of HPV infection complicated with low-grade cervical lesions. The cause of preterm birth was pregnancy complicated by severe pre-eclampsia; cesarean section was performed at 36 weeks of pregnancy. One case of high-grade cervical lesions, premature delivery was performed due to premature rupture of membranes at 35 weeks of gestation, oxytocin-induced labor, and vaginal delivery, the remaining eight cases of pregnancy with patients with CC, were not full-term elective cesarean section. This is consistent with Aldhous and colleagues²⁸ research.

Relationship between HPV and neonatal infection

There are significant differences in the influence of HPV infection between pregnant women and newborns. The HPV infection rate of newborns fluctuated between 5% and 72%.²⁹ In 2012, Park³⁰ collected oral samples of 291 newborns of pregnant women with HPV infection. The results showed that the positive rate of HPV infection in newborns was only 3.4% (10 of 291) and the HPV became negative 6 months after birth. The most severe disease of infants with acquired HPV infection was juvenile-onset recurrent respiratory papillomatosis, which is repeatedly blocked by the respiratory tract. However, the disease was mainly caused by low-risk HPV infection, including HPV-6 and HPV-11, with an incidence rate of 4.3 per 100,000.³¹ All newborns had no corresponding complications on physical examination at postpartum and 42-day follow-up and no abnormal growth and development. However, in our study, we only evaluated whether newborns had laryngeal papilloma disease through physical examination and did not

carry out an analysis of neonatal pharyngeal swab-related HPV infections and could not evaluate neonatal HPV infection rate and prognosis. In future studies, we can observe the infection and incidence rates of HPV in newborns and explore the risk factors for the disease and whether children have corresponding acquired immunity to HPV, including the incidence of adult newborns and whether HPV vaccine is needed.

Pregnancy management in women with HR-HPV infection complicated with severe cervical lesions (including HSIL and CC)

Cervical lesions can screen some pregnant women with HR-HPV infection during the second and third trimesters of pregnancy. The postpartum period should also be closely followed up. Because persistent HR-HPV infection is a high-risk factor that leads to further aggravation of cervical lesions, therapy can be more active with cervical LEEP or CKC for the multipara. The treatment of CC during pregnancy can be formulated according to the staging and pathological classification of CC, and can include conservative therapy, CKC+cerclage, chemotherapy during pregnancy, cesarean section, and radical operation. There were three cases of CC in the study. One case of squamous carcinoma was treated with CKC and follow-up was conducted until 2 years after delivery, with the patient showing normal results. One case of squamous carcinoma underwent operation+radiation therapy+chemotherapy, and another case underwent operation+radiation therapy. The results for the two patients were normal 2 years after delivery.

Limitations

The limitations of this study are as follows: (1) The examination of newborns was only limited to determining whether there were laryngeal papilloma lesions. There was no laboratory test assistance, no clear conclusion on whether the newborns had comorbidities, or whether they produced serological HPV antibodies. We will conduct research with long-term follow-up to further confirm the conclusions of this study. (2) Currently, there is no research on the use of HPV vaccine in pregnant and lying-in women. Theoretically, it has not been found to be teratogenic to the fetus. Whether it can be monitored in breast milk during lactation requires further research.

CONCLUSION

In conclusion, the proportion of pregnant women with HPV infection during pregnancy is not high. There is a certain rate of missed diagnosis and misdiagnosis. Patients with cervical lesions during pregnancy showed a relatively high proportion of combined HR-HPV infections. LSIL is the primary cytological abnormality. Whether the alteration is associated with the different classifications and is related to changes in immune mechanisms during pregnancy needs further study; the treatment of cervical neoplasm during pregnancy is mainly conducted post partum. The classification of cervical lesions does not affect the mode of delivery and outcomes of the newborn. The treatment of pregnancy complicated with CC should be determined according to gestational weeks, stages, and patient expectations.

Contributors JL and JW contributed to the conception and design of the study. YL, DB, and YW performed the experiments and collected and analyzed the data. YW and YL wrote the manuscript. All authors reviewed and approved the final version of the manuscript. JW is the guarantor.

Funding This study was supported by Capital's Funds for Health Improvement and Research (no: 2016-1-2112).

Competing interests None declared.

Patient consent for publication Not required.

Ethics approval This study involves human participants and the protocol was approved by the Ethics Committee of Beijing Obstetrics and Gynecology Hospital (no: KY-2014-005). The study is an observational study and does not involve sampling of human specimens, does not include personal information, has passed the ethical application, and does not require informed consent of patients.

Provenance and peer review Not commissioned; externally peer reviewed.

Data availability statement Data are available upon reasonable request. The datasets generated and analyzed during the current study are available from the corresponding author on reasonable request.

ORCID iD

Jiandong Wang <http://orcid.org/0000-0003-4891-1914>

REFERENCES

- Crosbie EJ, Einstein MH, Franceschi S, *et al.* Human papillomavirus and cervical cancer. *Lancet* 2013;382:889–99.
- Louie KS, de Sanjose S, Diaz M, *et al.* Early age at first sexual intercourse and early pregnancy are risk factors for cervical cancer in developing countries. *Br J Cancer* 2009;100:1191–7.
- Medeiros LR, Ethur ABdeM, Hilgert JB, *et al.* Vertical transmission of the human papillomavirus: a systematic quantitative review. *Cad Saude Publica* 2005;21:1006–15.
- Castellsagué X, Drudis T, Cañadas MP, *et al.* Human papillomavirus (HPV) infection in pregnant women and mother-to-child transmission of genital HPV genotypes: a prospective study in Spain. *BMC Infect Dis* 2009;9:74.
- Burk RD, Harari A, Chen Z. Human papillomavirus genome variants. *Virology* 2013;445:232–43.
- Ali MAM, Bedair RN, Abd El Atti RM. Cervical high-risk human papillomavirus infection among women residing in the Gulf cooperation Council countries: prevalence, type-specific distribution, and correlation with cervical cytology. *Cancer Cytopathol* 2019;127:567–77.
- Bonjour M, Charvat H, Franco EL, *et al.* Global estimates of expected and preventable cervical cancers among girls born between 2005 and 2014: a birth cohort analysis. *Lancet Public Health* 2021;6:e510–21.
- de Sanjosé S, Diaz M, Castellsagué X, *et al.* Worldwide prevalence and genotype distribution of cervical human papillomavirus DNA in women with normal cytology: a meta-analysis. *Lancet Infect Dis* 2007;7:453–9.
- Liu X-X, Fan X-L, Yu Y-P, *et al.* Human papillomavirus prevalence and type-distribution among women in Zhejiang Province, Southeast China: a cross-sectional study. *BMC Infect Dis* 2014;14:708.
- Zhao P, Liu S, Zhong Z, *et al.* Prevalence and genotype distribution of human papillomavirus infection among women in northeastern Guangdong Province of China. *BMC Infect Dis* 2018;18:204.
- He L, He J. Distribution of high-risk HPV types among women in Sichuan province, China: a cross-sectional study. *BMC Infect Dis* 2019;19:390.
- Zouridis A, Kalampokas T, Panoulis K, *et al.* Intrauterine HPV transmission: a systematic review of the literature. *Arch Gynecol Obstet* 2018;298:35–44.
- Chatzistamatiou K, Moysiadis T, Moschaki V, *et al.* Comparison of cytology, HPV DNA testing and HPV 16/18 genotyping alone or combined targeting to the more balanced methodology for cervical cancer screening. *Gynecol Oncol* 2016;142:120–7.
- Torres-Ibarra L, Cuzick J, Lorincz AT, *et al.* Comparison of HPV-16 and HPV-18 genotyping and cytological testing as triage testing within human Papillomavirus-Based screening in Mexico. *JAMA Netw Open* 2019;2:e1915781.
- Levi JE, Martins TR, Longatto-Filho A, *et al.* High-risk HPV testing in primary screening for cervical cancer in the public health system, São Paulo, Brazil. *Cancer Prev Res* 2019;12:539–46.
- Kaufman HW, Alagia DP, Chen Z, *et al.* Contributions of liquid-based (Papanicolaou) cytology and human papillomavirus testing in cotesting for detection of cervical cancer and precancer in the United States. *Am J Clin Pathol* 2020;154:510–6.

- 17 Hu S-Y, Rezhake R, Chen F, *et al.* Outcomes in women with biopsy-confirmed cervical intraepithelial neoplasia grade 1 or normal cervix and related cofactors: a 15-year population-based cohort study from China. *Gynecol Oncol* 2020;156:616–23.
- 18 St-Martin G, Viborg PH, Andersen ABT, *et al.* Histological outcomes in HPV-screened elderly women in Denmark. *PLoS One* 2021;16:e0246902.
- 19 Sung H, Ferlay J, Siegel RL, *et al.* Global cancer statistics 2020: GLOBOCAN estimates of incidence and mortality worldwide for 36 cancers in 185 countries. *CA Cancer J Clin* 2021;71:209–49.
- 20 Schiffman M, Wentzensen N. Human papillomavirus infection and the multistage carcinogenesis of cervical cancer. *Cancer Epidemiol Biomarkers Prev* 2013;22:553–60.
- 21 Fitzpatrick M, Pathipati MP, McCarty K, *et al.* Knowledge, attitudes, and practices of cervical cancer screening among HIV-positive and HIV-negative women participating in human papillomavirus screening in rural Zimbabwe. *BMC Womens Health* 2020;20:153.
- 22 Sánchez-Corredor CD, Guerrero-Machado M, Rubio-Romero JA, *et al.* Prevalence of high-risk human papilloma virus infection and abnormal cytology of the anal transformation zone in women with cervical dysplasia. Bogotá, Colombia, 2017-2019. *Rev Colomb Obstet Ginecol* 2020;71:345–55.
- 23 Kyrgiou M, Mitra A, Moscicki A-B. Does the vaginal microbiota play a role in the development of cervical cancer? *Transl Res* 2017;179:168–82.
- 24 Mailath-Pokorny M, Schwameis R, Grimm C, *et al.* Natural history of cervical intraepithelial neoplasia in pregnancy: postpartum histo-pathologic outcome and review of the literature. *BMC Pregnancy Childbirth* 2016;16:74.
- 25 Hurtado-Roca Y, Becerra-Chauca N, Malca M. Efficacy and safety of cryotherapy, cold cone or thermocoagulation compared to LEEP as a therapy for cervical intraepithelial neoplasia: systematic review. *Rev Saude Publica* 2020;54:27.
- 26 Niyibizi J, Zanré N, Mayrand M-H, *et al.* Association between maternal human papillomavirus infection and adverse pregnancy outcomes: systematic review and meta-analysis. *J Infect Dis* 2020;221:1925–37.
- 27 Pandey D, Solleti V, Jain G, *et al.* Human papillomavirus (HPV) infection in early pregnancy: prevalence and implications. *Infect Dis Obstet Gynecol* 2019;2019:1–5.
- 28 Aldhous MC, Bhatia R, Pollock R, *et al.* HPV infection and pre-term birth: a data-linkage study using Scottish Health Data. *Wellcome Open Res* 2019;4:48.
- 29 Hahn HS, Kee MK, Kim HJ, *et al.* Distribution of maternal and infant human papillomavirus: risk factors associated with vertical transmission. *Eur J Obstet Gynecol Reprod Biol* 2013;169:202–6.
- 30 Park S-Y. The effects of message framing and risk perceptions for HPV vaccine campaigns: focus on the role of regulatory fit. *Health Mark Q* 2012;29:283–302.
- 31 Marsico M, Mehta V, Chastek B, *et al.* Estimating the incidence and prevalence of juvenile-onset recurrent respiratory papillomatosis in publicly and privately insured claims databases in the United States. *Sex Transm Dis* 2014;41:300–5.